



9-2020

Cerebral cavernous malformation presenting as seizures

Hazim Brohi

Liaquat national hospital Karachi

Ayisha Farooq

Liaquat national hospital Karachi

Bushra Rehan

Liaquat National hospital, Karachi

Muhammad Mairaj Khan

Liaquat National hospital, Karachi

Follow this and additional works at: <https://ecommons.aku.edu/pjns>

 Part of the [Neurology Commons](#)

Recommended Citation

Brohi, Hazim; Farooq, Ayisha; Rehan, Bushra; and Mairaj Khan, Muhammad (2020) "Cerebral cavernous malformation presenting as seizures," *Pakistan Journal of Neurological Sciences (PJNS)*: Vol. 15 : Iss. 3 , Article 6.

Available at: <https://ecommons.aku.edu/pjns/vol15/iss3/6>

CEREBRAL CAVERNOUS MALFORMATION PRESENTING AS SEIZURES

Hazim Brohi¹, Ayisha Farooq², Bushra Rehan³, Muhammad Mairaj Khan⁴
^{1,2,3,4}Liaquat National hospital, Karachi

Correspondence to: Hazim Brohi Email: hazimbrohi@yahoo.com

Date of submission: February 10, 2020 Date of revision: June 18, 2020 Date of acceptance: June 27, 2020

ABSTRACT:

Background: Cerebral cavernous malformations (CCMs) is one of the rare vascular malformation. It is diagnosed by characteristic lesions on magnetic resonance imaging (MRI). CCMs typically appears as a “popcorn-like” masses on T2-weighted images on MRI studies. And clinically can lead to headaches, seizures, focal neurological deficits or intracerebral hemorrhages. . A familial form is suggested if lesions are multiple, and a sporadic form, if single

Case presentation: This case report involves Status epilepticus in a 45-year-old male was brought to the Emergency department with a history of headache for 2-3 days and seizures lasting 2 hours. MRI showed multiple rounded lesions suggestive of hemorrhagic lesions. These lesions consist of a mixed signal intensity core accompanied by a hypointense hemosiderin rim. Patient was intubated and started on intravenous anti epileptics (midazolam 5mg) along with propofol along with antiepileptics. Fits subsided and propofol was eventually stopped and he was extubated and went back home.

Conclusion: Summing up our patient presented with seizures secondary to cerebral cavernous malformations probably familial as the lesions on MRI were multiple. This is a rare entity and these patients require a close follow up and all the family members must be screened and treated.

INTRODUCTION:

Cerebral cavernous malformation (CCM) is one of the infrequent congenital abnormality with few case reports presented in Pakistan. It is mostly asymptomatic with specific MRI appearance and if left untreated it can cause multiple morbidities such as seizures, focal neurological deficits, recurrent cerebral hemorrhages, raised intracranial pressure (ICP) and even death. Its true prevalence remains a secret. It is essential to outline such rare entities all over the world to spread the awareness to search for other cases, as this will decrease the morbidities associated with this malformation by proper genetic counselling.^[9]

CASE PRESENTATION

Our patient is a 45 year old male, farmer by occupation, known hypertensive, was brought to the Emergency department (ED) with a history of headache for 2-3 days and multiple seizures lasting for 2 hours. Seizures as described by the family were generalized tonic clonic in nature associated with uprolling of eyes, frothing from the mouth and lasted for quite a few minutes. There was associated post ictal confusion. However he was not gaining consciousness in between

the events. On arrival, he was in an altered sensorium and had continued episodes of fits as witnessed in ER. His vitals were, pulse rate 140 beats per minute, respiratory rate: 25 per minute, blood pressure of 150/80 mm Hg; oxygen saturation was 98% (on high flow oxygen). There was no recent history of trauma to the head and his random blood sugar levels were in normal range. . He was labelled as having status epilepticus He received multiple times Intravenous (IV) midazolam was with no effect and the patient was eventually intubated and shifted to ICU setup and propofol was started along with other anti epileptic medications. Baseline workup done was normal. EEG was done, which showed epileptic discharges as shown in (figure 1). MRI brain done showed multiple areas of signal void in both cerebral hemispheres and within the pons suggestive of areas of hemorrhage or calcification. There was an area of abnormality noted in pons just right of the midline on T2W images (figure 2). This was also seen on T1W images with subtle high signal within it, representing tiny hemorrhages. (figure 3) In addition to this, there were tiny high signal abnormality areas noted within the right cerebrum

which were also noted on FLAIR images. However, diffusion study showed no evidence of restricted diffusion to suggest acute ischemia. MRA showed mild to moderate degree segmental narrowing within the branches of the anterior circulation. Mild segmental narrowing also noted in left posterior cerebral artery. Remaining arteries were well outlined. CSF studies done were normal. These lesions looked like popcorn and thus labeled as cavernous malformations. As there were multiple possibilities of familial type was raised. Patient was starting on anti-epileptics along with propofol. Propofol was eventually stopped as fits subsided. He was extubated and discharged from the hospital on long-term management drugs (sodium valproate) for epilepsy.

DISCUSSION

Cerebral cavernous malformations are malformations commonly found in the nervous system. In this malformation, disruption of the normal vascular pattern causes blood or thrombus to be filled in dilated endothelial channels that are lacking a muscle support. Occasionally cavernomas may rupture and lead to many serious complications such as hemorrhagic stroke or death. They are divided into sporadic and familial form with the familial form having multiple lesions on MRI and an autosomal mode of inheritance^[1,3,10]. It is reported that it occurs usually due to loss of function mutation in one of the three genes, *KRIT1*, *CCM2*, or *PDCD10*^[2]. The sporadic disease commonly leads to the formation of single cavernoma. Our study suggested that the patient had a possible familial form as the lesions on MRI were multiple. CCMs usually present with findings such as seizures 40-70%, cerebral hemorrhages 32%, non-specific headaches 10-30% and focal neurological deficits 35-50% between their second to fifth decades. Approximately 50% of individuals with familial cerebral cavernous malformations (FCCM) remain asymptomatic throughout their lives^[2]. MRI is the best imaging modality for diagnosis of cerebral cavernous angiomas^[6]. Studies have confirmed SWI as being more sensitive for detecting CAs than T2*-weighted GRE sequences. [5]. SWI can also help to confirm the diagnosis of CA in cases in which the lesion could not be detected on conventional MRI^[7]. (Susceptibility-weighted (SW) is one of the most helpful imaging in detecting cavernous malformation lesions because they are capable of accurately detecting the hemosiderin and deoxyhemoglobin presence therefore helps in finding unbleeding CM lesions)^[8]. Lesions may be visible as black dots, mixed signal intensity or with hemosiderin rims,

fresh hemorrhages or edema)^[2]. CCMs typically appear as "popcorn-like" masses on T2-weighted images on MRI studies, in which they have mixed signal intensity core along with a hypointense hemosiderin rim presents^[8].

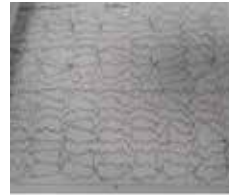


Figure 1: EEG showing epileptic changes

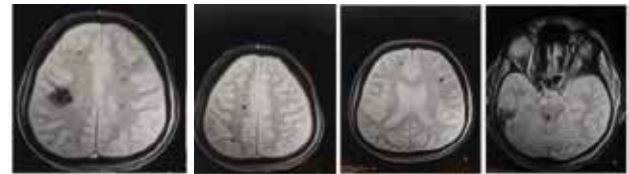

Figure 2: MRI showing multiple areas of signal void in cerebral hemispheres and pons suggestive of areas of hemorrhage or calcification

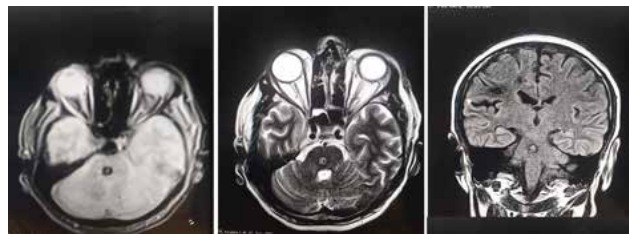

Figure 3: MRI T1 weighted images showing lesions in pons and cerebral hemispheres.

Due to the absence of neurons within cavernous malformations, seizures arise from a complex interaction between astrocytes, neurons, and microvasculature at the margins of CCMs. These lesions are highly epileptogenic; therefore, seizures are the usual presentation of CCMs. Treatment options include conservative management, microsurgical resection, and stereotactic radiosurgery. When seizures result from CCMs and do not respond to anti-epileptic medications, surgical resection of the CCM along with the surrounding epileptic zones is required^[7]. Surgical resection reduces morbidity and mortality risks and is successful in patients presenting within 1 year of symptom onset, in those who present with a cavernoma size less than 1.5 cm and with a single CM lesion. Brainstem cavernomas (BSCMs) are deeply located in the pons, medulla, and brainstem and make up approximately 20-35% of all CCMs. The hemorrhage risk for spontaneous BSCMs has been shown to be around 0.25-6.5% per patient-year, if the patient has a history of prior hemorrhage, this risk rises to 3.8-35%^[8].

The surgical resection of BSCM lesions carries a greater complication risk than resecting other CM lesions^[8]. In our case, as the lesion was multiple and also involved pons, patient was treated conservatively with antiepileptics mentioned earlier. Stereotactic radiosurgery decreases the risks of rebleeding and seizures therefore its indications should be clearly investigated due to high risks of side effects^[4].

Prophylactic resection of asymptomatic lesions does not appear to be indicated^[3]. These lesions increase and decrease with time so in case of any neurological symptom, repeated MRI should be done and patients should be closely followed..

References:

1. Li DY, Whitehead KJ. Evaluating strategies for the treatment of cerebral cavernous malformations. *Stroke*. 2010;41(10 Suppl):S92-S94. doi:10.1161/STROKEAHA.110.594929
2. Zabramski JM, Wascher TM, Spetzler RF, et al. The natural history of familial cavernous malformations: results of an ongoing study. *J Neurosurg*. 1994;80(3):422-432. doi:10.3171/jns.1994.80.3.0422
3. Morrison L, Akers A. Cerebral Cavernous Malformation, Familial. 2003 Feb 24 [Updated 2016 Aug 4]. In: Adam MP, Ardinger HH, Pagon RA, et al., editors. *GeneReviews®* [Internet]. Seattle (WA): University of Washington, Seattle; 1993-2020. Available from: <https://www.ncbi.nlm.nih.gov/books/NBK1293/>
4. (Date, I., Tokunaga, K., (2011) .Clinical features and management of cavernous and venous angiomas in the head, *BRAIN and NERVE* Vol. 63, 17-25, No. 1, January 2011(<https://www.ncbi.nlm.nih.gov/pubmed/21228444>)
5. D'Angelo, Rosalia&Alafaci, Concetta&Scimone, Concetta& Ruggieri, Alessia&Salpietro, Francesco &Bramanti, Placido&Tomasello, Francesco &Sidoti, Antonella. (2013). Sporadic Cerebral Cavernous Malformations: Report of Further Mutations of CCM Genes in 40 Italian Patients. *BioMed research international*. 2013. 459253. 10.1155/2013/459253.
6. Bulut HT, Sarica MA, Baykan AH. The value of susceptibility weighted magnetic resonance imaging in evaluation of patients with familial cerebral cavernous angioma. *Int J ClinExp Med*. 2014;7(12):5296-5302. Published 2014 Dec 15. <https://www.ncbi.nlm.nih.gov/pmc/articles/PMC4307481/>
7. Komotar RJ, Mikell CB, McKhann GM 2nd. "Epilepsy surgery" versus lesionectomy in patients with seizures secondary to cavernous malformations. *ClinNeurosurg*. 2008;55:101-107. <https://pubmed.ncbi.nlm.nih.gov/19248674/>
8. Mouchtouris N, Chalouhi N, Chitale A, et al. Management of cerebral cavernous malformations: from diagnosis to treatment. *ScientificWorldJournal*. 2015;2015:808314. doi:10.1155/2015/808314
9. Nahrir S, Al-Hameed MH, Al-Sinaidi OA, Al Shakweer W. Discovery of familial cerebral cavernous malformation in a Saudi population. *BMJ Case Rep*. 2013;2013:bcr2013009417. Published 2013 Nov 21. doi:10.1136/bcr-2013-009417
10. Whitehead KJ, Smith MC, Li DY. Arteriovenous malformations and other vascular malformation syndromes. *Cold Spring Harb Perspect Med*. 2013;3(2):a006635. Published 2013 Feb 1. doi:10.1101/cshperspect.a006635

Conflict of interest: There is no conflict of interest..

Funding disclosure: Nil

Author's contribution:

Hazim Brohi; data collection, data analysis, manuscript writing, manuscript review

Ayisha farooq; data analysis, manuscript writing, manuscript review

Bushra Rehan; data analysis, manuscript writing, manuscript review

Muhammad Mairaj Khan; data analysis, manuscript writing, manuscript review