

"Musculoskeletal sonoelastography. Pictorial essay"

Botar Jid, Carolina ; Vasilescu, Dan ; Damian, Laura ;
Dumitriu, Dana Loana ; Ciurea, Anca ; Dudea, Sorin M

Abstract

Ultrasonic elastography (real-time elastography, sonoelastography) is a new ultrasound technique being one of the imaging mainstream in the last few years being used for characterizing soft tissue lesions, like breast, thyroid, prostate and lymph nodes. Musculoskeletal pathology was one of the first applications of sonoelastography, but, nevertheless the method is not yet standardized. The purpose of this pictorial essay is to briefly describe the technique and to exemplify the aspects of a variety of musculoskeletal pathologies.

Document type : *Article de périodique (Journal article)*

Référence bibliographique

Botar Jid, Carolina ; Vasilescu, Dan ; Damian, Laura ; Dumitriu, Dana Loana ; Ciurea, Anca ; et. al.
Musculoskeletal sonoelastography. Pictorial essay. In: *Medical Ultrasonography : an international journal of clinical imaging*, Vol. 14, no.3, p. 239-45 (2012)

Musculoskeletal sonoelastography. Pictorial essay

Carolina Botar Jid¹, Dan Vasilescu¹, Laura Damian², Dana Dumitriu¹, Anca Ciurea¹, Sorin M. Dudea¹

¹Radiology Department, „Iuliu Hațieganu” University of Medicine and Pharmacy Cluj-Napoca, Cluj-Napoca, Romania,
²Rheumatology Department, Emergency Clinical County Hospital Cluj, Cluj-Napoca, Romania

Abstract

Ultrasonic elastography (real-time elastography, sonoelastography) is a new ultrasound technique being one of the imaging mainstream in the last few years being used for characterizing soft tissue lesions, like breast, thyroid, prostate and lymph nodes. Musculoskeletal pathology was one of the first applications of sonoelastography, but, nevertheless the method is not yet standardized. The purpose of this pictorial essay is to briefly describe the technique and to exemplify the aspects of a variety of musculoskeletal pathologies.

Keywords: ultrasonic elastography, sonoelastography, musculoskeletal pathology

Introduction

Ultrasonic elastography (USE, Sonoelastography) was originally described by Ophir et al [1], which measures tissue deformation as a response to an external force, assuming that the deformation is lower in rigid tissues, compared with the elastic, soft tissues. There are only a few studies in the literature which have attempted to present the appearance of the musculoskeletal structures' elasticity [2-5].

Evaluation of musculoskeletal pathology is one of the first applications “in vivo” of USE, providing information about soft tissue quality by assessing tissue elasticity, the clinical significance for diagnosis and follow musculoskeletal injuries. Elastography allows a good evaluation function by measuring the stiffness/elasticity of muscle [4,6].

Examination technique

This method is based on comparing the radiofrequency of ultrasonic waves obtained before and after an easy made compression with a conventional transducer, using a free hand technique [4]. The transducer is part of the equipment able to obtain specific information for ultrasonic elastography image. A low pressure is exercised with the transducer in the area of interest in order to determine a proportional deformation between pressure and deformation. In case of excessive pressure, tissue elasticity non-linear effects occur. Applying a pressure exceeding a certain limit makes that the information stated on the elastography image may not vary proportionally with the applied pressure. Thus, applying too much pressure can influence the appearance of the lesion [2,7]. The size of the region of interest (ROI) is determined by the examiner for each area explored, and it must cover the lesion and to overcome explored in all directions with at least 5 mm. In this way are explored the lesions detected on two-dimensional image and invisible damage to gray scale examination [7].

The elasticity is represented by color coding. Each color pixel from region of interest is assigned one of 256 specific colors depending on the amplitude of deforma-

Received Accepted
Med Ultrason
2012, Vol. 14, No 3, 239-245

Corresponding author: Carolina Botar Jid
Radiology Department,
Emergency Clinical County Hospital,
3-5 Clinicilor street
400006, Cluj-Napoca, Romania
E-mail: inabotar@yahoo.com

tion. Color scale ranges from red (soft components – areas with significant deformation) to blue (rigid elements – areas with low distortion). Green indicates the average deformation of ROI. How it uses the three basic colors is called encoding RGB (red-green-blue) [7,8].

In our department we use a Hitachi EUB 8500 equipment with 6,5-13 MHz transducer and the free hand compression technique. The conventional B-mode ultrasound image is displayed on the right side of the screen while the color coded real time sonoelastogram is depicted on the left side of the screen. The transparency of the color can be optimally adjusted such that the underlying grey scale image can be seen through the overlying color map. Compression must be minimal and applied in the vertical direction. Movement in the lateral direction must be suppressed/minimized. Excessive pressure on the probe must also be avoided [4,9].

Elastographic information is obtained in dynamic, real time during the tissue compression and a video can be recorded in internal memory ultrasound device. From the

sequence of consecutive images obtained will be analyzed an image obtained in early stage of compression. There are used several ways of encoding in color, depending on the equipment manufacturer or the examiner’s intention: to increase the contrast to the surrounding tissues or injury to surround the whole body tissue examined [2,4,8].

One advantage of USE is no artifact of anisotropy, one of the most important artifacts affecting bidimensional musculoskeletal ultrasound [4].

Muscles

Muscles represent soft structures which is suitable to USE examination. Elastography examination confirms that, during contraction, muscle structures emphasize their elasticity (fig 1-2) [4].

In case of muscle contusions healthy areas with normal elasticity similar to that during contraction can be found.

In muscular ruptures, haemorrhage zones in muscular trauma appear as homogeneous areas, very soft on elastographic image (fig 3-4).

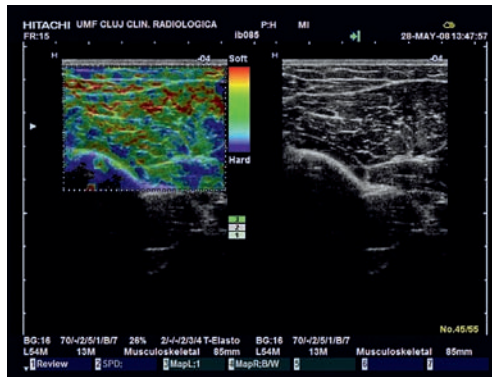


Fig 1. Normal muscle in time of relaxation – ribbed elastic appearance

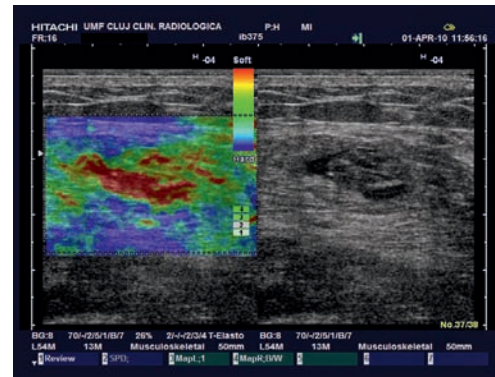


Fig 3. Male, 61 years old, partial quadriceps muscle rupture – very soft aspect of hemorrhage (transversal view)

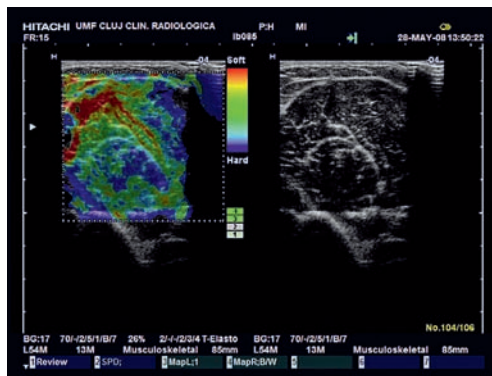


Fig 2. Normal muscle in time of contraction – soft appearance

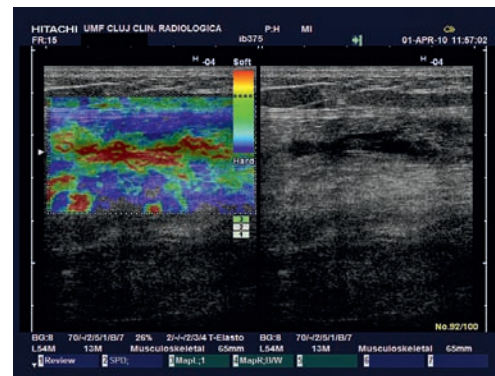


Fig 4. M, 57 years old, partial quadriceps muscle rupture – very soft aspect of hemorrhage (sagittal view)

In patients with muscle injuries elastography examination shows the irregular alteration areas different elasticity of the lesion and, in particular, perilesional, where bidimensional ultrasound could reveal normal aspect. This fact is important in dynamic for evolution of the le-

sions. Such, in the lesions with favourable evolution a soft elastic ribbed appearance will appear, while fibrosis causes a wide range perilesional predominantly stiff appearance (blue image elastography) which could contain soft areas (red elastography image), depending on lesion length (fig 5-7) [4,6,10].

USE could be used to assess the muscle elasticity in some neuromuscular disorders, such as idiopathic inflammatory myopathies, cerebral palsy, muscular contractures, spastic disorders or bone deformities that lead to changes in muscle alignment. Thus, elastography examination revealed changes in muscle elasticity, decreased in most cases of polymyositis, more probably by the appearance of fibrosis and atrophy changes. Increased elasticity and „soft” look appearance of muscular structures were encountered in some cases of dermatomyositis and could be explained by fatty infiltration of the muscle (fig 8-9) [11].

In case of cerebral palsy spasticity the use of US had an important contribution in the easiness of a pre-

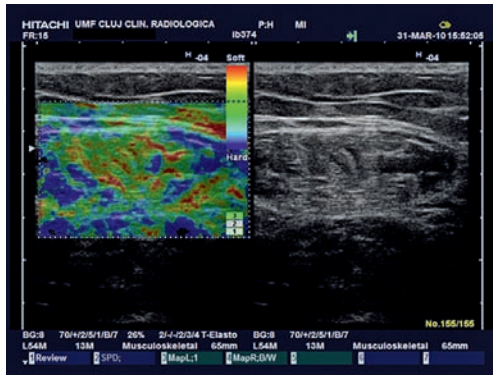


Fig 5. Male, 32 years old, partial quadriceps muscle rupture – initial aspect (transversal view)

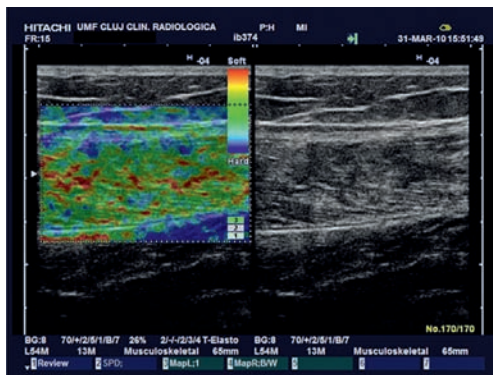


Fig 6. Male, 32 years old, partial quadriceps muscle rupture – 9 days after the rupture (sagittal view)

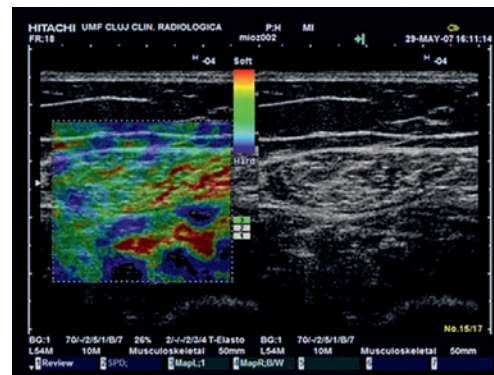


Fig 8. Female, 58 years old, polymyositis, medium third of the right arm – reduced muscular elasticity (transversal view)

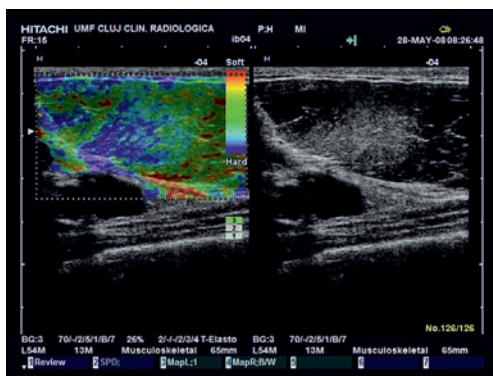


Fig 7. Male, 57 years old, right pectoralis major muscle old rupture – stiff area representing fibrous scar

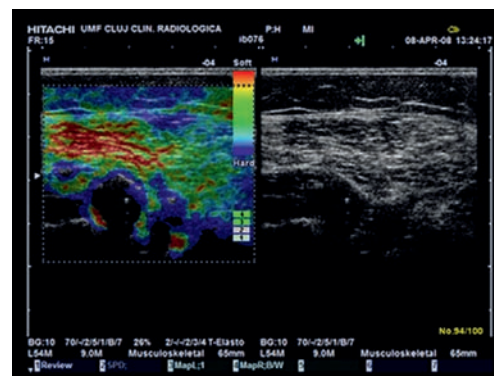


Fig 9. Female, 65 years old, dermatomyositis, medium third of the left thigh – soft aspect of the muscle (transversal view)

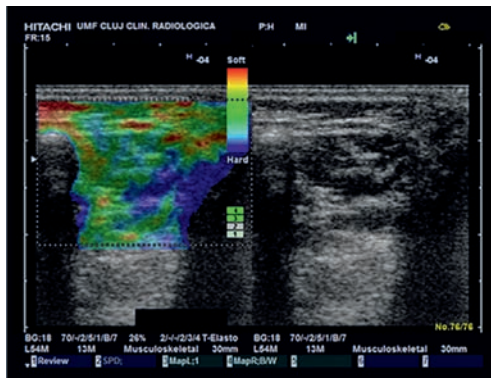


Fig 10. Male, 7 years old, spastic palsy, right abductor pollicis muscle – stiffness of the muscle before injection

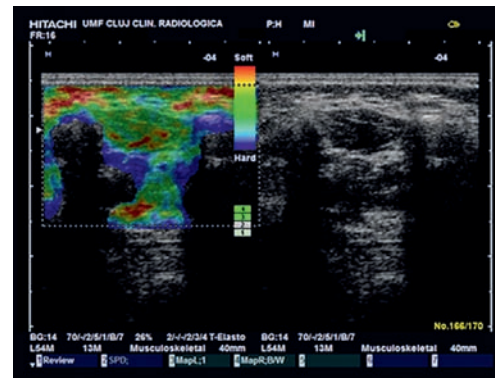


Fig 11. Male, 7 years old, spastic palsy, right abductor pollicis muscle – increased elasticity demonstrating reduced contracture at 4 weeks after injection

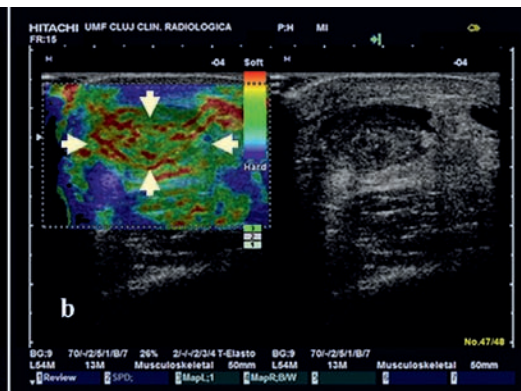
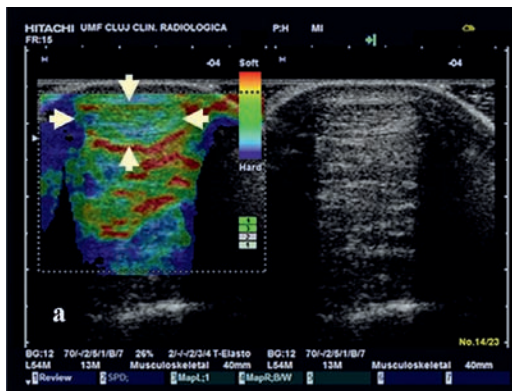


Fig 12. Male, 40 years old, Achilles tendon – ribbed, medium elasticity in a normal tendon (a), increased elasticity in case of tendon rupture (b) (transversal view)

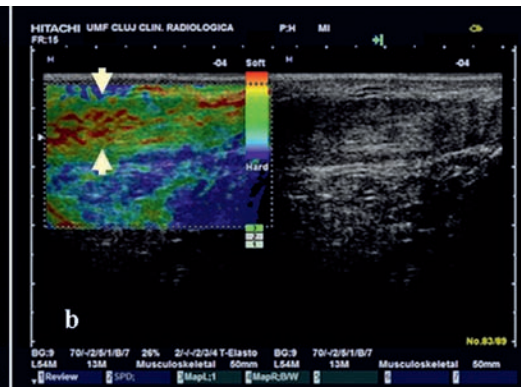
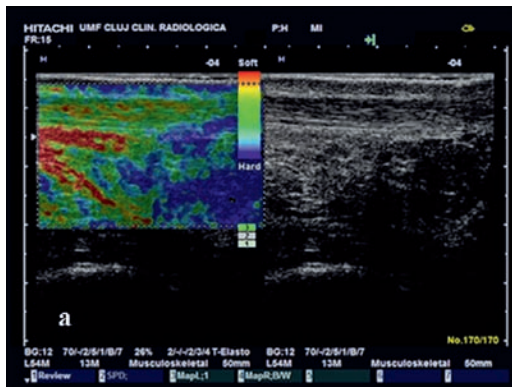


Fig 13. Male, 40 years old, Achilles tendon – ribbed, medium elasticity in a normal tendon (a), increased elasticity in case of tendon rupture (b) (sagittal view)

cise tracking of the muscle groups, being the easiest technique in paediatric patients. Vasilescu et al presented application of USE in these groups of patients and shows important findings in assessing the degree of muscle contraction, especially in the cases with less

information than the ones offered by EMG. Initial these patients presented stiffness of the muscles, demonstrating contraction, and increased in elasticity after injection with Botulinum toxin in cases with favourable evolution [12].

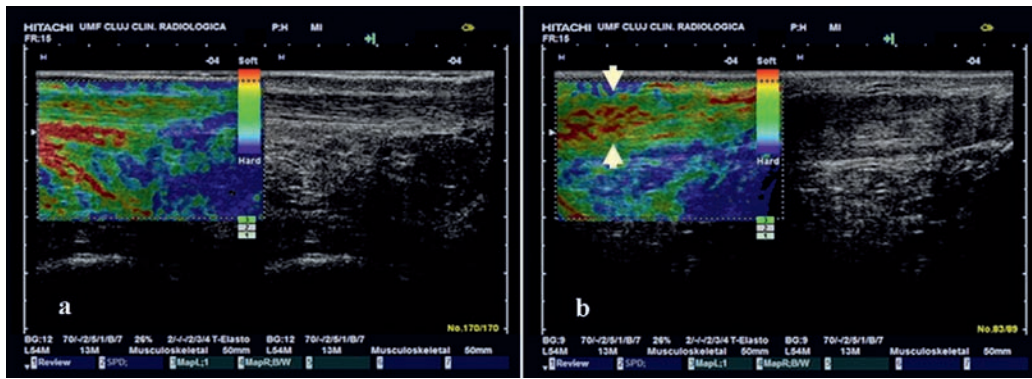


Fig 14. Male, 42 years old, Achilles tendond rupture, postoperative – complexed sonoelastographic appearance: soft area alternating with areas of low elasticity (a – transversal view, b – sagittal view)

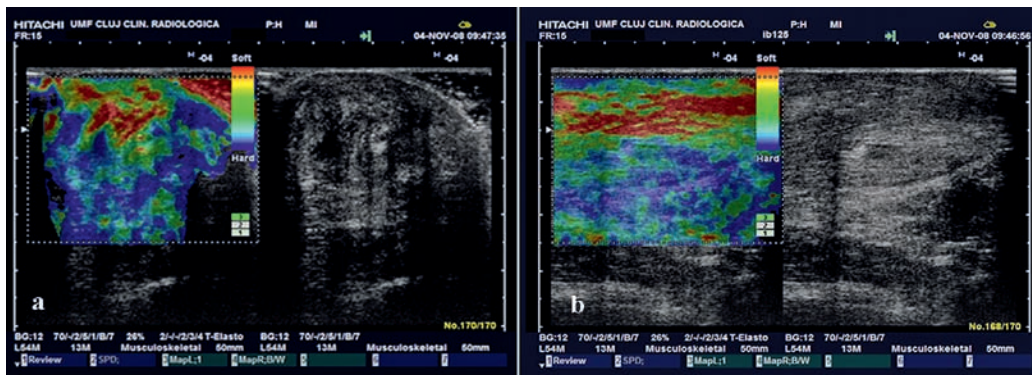


Fig 15. Male 54 years old, Achilles tendon old rupture – reduced elasticity of the tendon with area of fibrosis (blue areas) (a – transversal view, b – sagittal view)

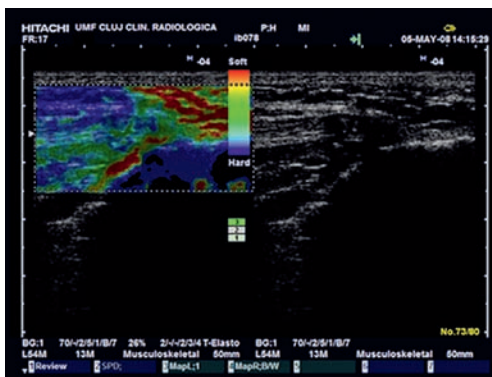


Fig 16. Female, 57 years old, patellar tendinitis – blue areas of reduced elasticity in tendon (sagittal view)

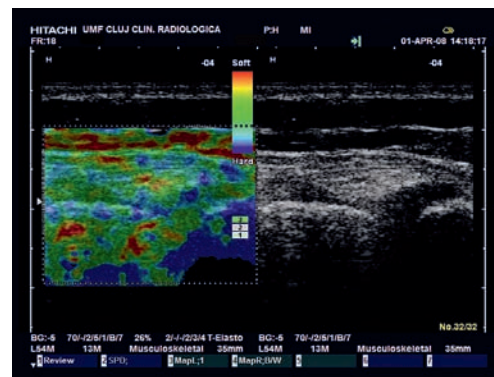


Fig 17. Female, 27 years old, traumatic aspect to the medial collateral ligament (soft area) (sagittal view)

Tendons

In case of tendons, elasticity was found reduced during contraction, which has varying degrees of response, depending on patient position during examination (in supine or standing). Tendinous rupture zones appear at

USE more “soft” compared with the average elasticity of normal tendon (fig 12-13) [4].

Postoperative evaluation highlights elastic fibres maintained and areas of fibrosis scar (fig 14-15) [4,8,10].

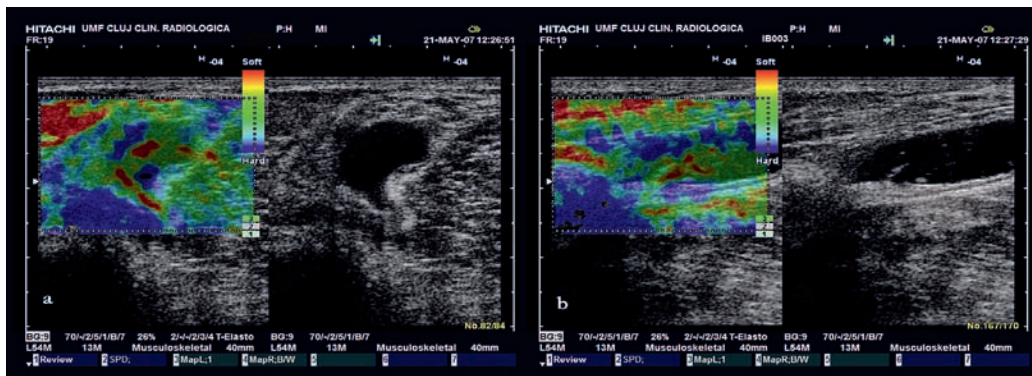


Fig 18. Female, 67 years old, Backer cyst with emphasis of BGR signal aspect (a - transversal view, b - sagittal view)

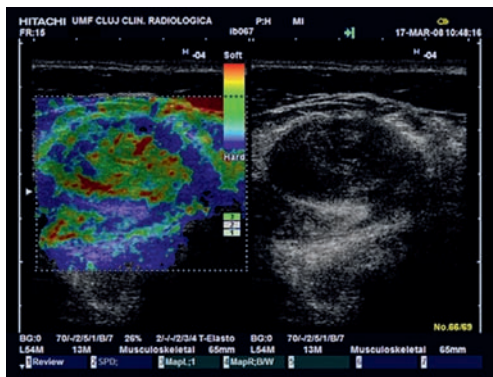


Fig 19. Female, 72 years old, Backer cyst highlighting elastographic complex appearance in a cyst containing inhomogeneous (transversal view)

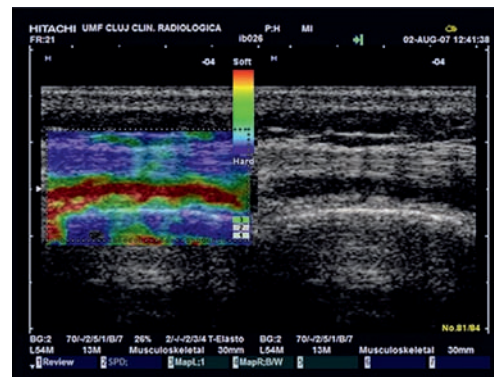


Fig 21. Female, 45 years old, hyarthrosis with minimal synovial proliferation - (suprapatellar, sagittal view)

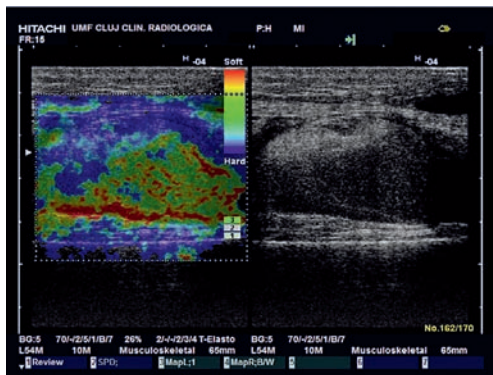


Fig 20. Male, 22 years old, haemarthrosis with complex USE aspect - areas under tension (blue) and partially lysed hematoma with moderate elasticity (green) (suprapatellar, sagittal view)

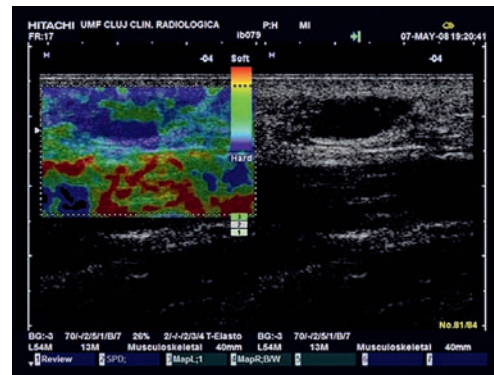


Fig 22. Male, 35 years old, recent hematoma of the middle region of the forearm (sagittal view)

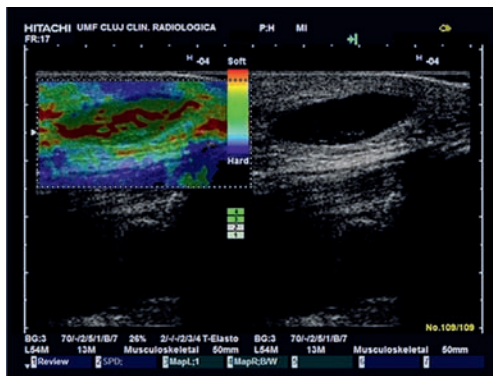


Fig 23. Female, 48 years old, subacute hematoma in the prepatellar region (sagittal view)

Structural changes occurring in inflammatory diseases by reducing elasticity elastographically, with implications in tendon function (fig 16).

Ligaments

In a ligament' tears, as for tendons, areas "softer" than normal ligament can be found (fig 17).

Joints

Elastography may be useful in characterizing synovial cysts with fluid contents confirmation (BlueGreenRed type signal) or heterogeneous content (impure fluid, with synovial proliferation) (fig 18-19) [4]. In cases of cysts under tension reduced elasticity was observed.

Posttraumatic, haemarthrosis appearance may be complex, rigid areas and areas with medium elasticity, depending on the age of hematoma (fig 20).

In cases of inflammatory diseases, synovial hypertrophy is one of the commonly feature, showing moderate elasticity (fig 21) [9].

Soft tissue lesions

We evaluated by USE only few soft tissue lesions. We observed that in cases of hematoma, the USE appearance is different, depending on the time elapsed from the occurrence of trauma. Thus, during the first hours post-traumatic presents low elasticity, increasing in elasticity with hematoma lysis (fig 22-23).

In **conclusion**, USE is a useful method for diagnosis and monitoring of musculoskeletal disorders, by evaluating the elasticity of muscle structures, tendons or ligaments. In the future, while widening the experience and technological developments, we expect that elastography

to become an important tool in the diagnosis and monitoring of musculoskeletal disorders, along with other radio-imaging methods. Further multicenter studies need to be performed in order to establish the clinical utility of USE.

References

- Ophir J, Cespedes I, Ponnekanti H, Yazdi Y, Li X. Elastography: a quantitative method for imaging the elasticity of biological tissues. *Ultrason Imaging* 1991; 13: 111-134.
- Itoh A, Ueno E, Tohno E, Kamma H, et al. Breast disease: clinical application of US elastography for diagnosis. *Radiology* 2006;239:341-350.
- Botar-Jid C, Vasilescu D, Ducea SM, Damian L, Badea R. Ultrasound elastography in musculoskeletal disorders. *Ultraschall in Med*, 2008, suppl 1, OP9.9. http://www.hitachimedical-systems.eu/fileadmin/hitachi_en/downloads/hi-rte-publications-and-communications-clinical-abstracts--musculoskeletal-applications-11-06-10.pdf
- Botar-Jid C, Vasilescu D, Ducea S. Ecografia tridimensională și elastografia în patologia aparatului locomotor. In: Daniela Fodor. *Ecografie clinică musculoscheletală*. Editura Medicală București 2009:381-396.
- Lalitha P, Reddy MCh, Reddy KJ. Musculoskeletal applications of elastography: a pictorial essay of our initial experience. *Korean J Radiol* 2011;12:365-375.
- Monetti G, Minafra P. The Musculoskeletal Elastography; *MEDIX Suppl* 2007:43-45.
- Ducea SM, Dumitriu D, Ciurea A, Botar-Jid C. Elastografia ultrasonoră. In: Badea IR, Ducea SM, Mircea PA, Stamate M. *Tratat de ultrasonografie clinică*. Editura Medicală București 2008; vol III:663-674.
- Derchi LE, Rizzato G. Technical Requirements. În: Bianchi S, Martinoli C. *Ultrasound of the Musculoskeletal System*; Springer-Verlag 2007:3-16.
- Botar-Jid C, Bolboacă SD, Damian L, et al. Assessment of sonoelastography as diagnosis tool of inflammatory myopathies. *Applied Medical Informatics* 2010; 27: 81-89.
- Denis F, Cohen M. Apport de l'estographie dans la pathologie musculo-tendineuse; *JFR* 2004.
- Botar-Jid C, Damian L, Ducea SM, Vasilescu D, Rednic S, Badea R. The contribution of ultrasonography and sonoelastography in assessment of myositis. *Med Ultrason* 2010;12:120-126.
- Vasilescu D, Vasilescu D, Ducea S, Botar-Jid C, Sfrâncu S, Cosma D. Sonoelastography contribution in cerebral palsy spasticity treatment assessment, preliminary report: a systematic review of the literature apropos of seven patients. *Med Ultrason* 2010;12:306-310.