

"Osteoarthritis and scapholunate instability in chondrocalcinosis"

Kahloune, Merouane ; Libouton, Xavier ; Omoumi, Patrick ; Larbi, Ahmed

Document type : *Article de périodique (Journal article)*

Référence bibliographique

Kahloune, Merouane ; Libouton, Xavier ; Omoumi, Patrick ; Larbi, Ahmed. *Osteoarthritis and scapholunate instability in chondrocalcinosis*. In: *Diagnostic & Interventional Imaging*, Vol. 96, no.1, p. 115-119 (2015)

DOI : 10.1016/j.diii.2013.08.017

Available at:

<http://hdl.handle.net/2078.1/172301>

[Downloaded 2019/04/18 at 23:41:03]



E-QUID: ANSWER / *Musculoskeletal imaging*

Osteoarthritis and scapholunate instability in chondrocalcinosis[☆]



M. Kahloune^{a,*}, X. Libouton^b, P. Omoumi^a, A. Larbi^a

^a *Radiology Department, Saint-Luc University Hospitals, av. Hippocrate 10, 1200 Brussels, Belgium*

^b *Orthopedic and Trauma Surgery Department, Saint Luc University Hospitals, av. Hippocrate 10, 1200 Brussels, Belgium*

Observation

A 71-year-old man was referred by his general practitioner for an orthopedic surgery consultation for intermittent pain on the radial side of the right wrist with swelling which had developed over 18 months despite no history of trauma. His history included a fracture of the distal end of the left radius operated on about 12 years previously. Clinical examination found moderate limitation of movement and pain on palpation of the radial side of the wrist. X-ray images of the right wrist (Fig. 1) and a non-contrast-enhanced CT scan of both wrists (Figs. 2 and 3) were available, obtained before the consultation.

DOI of original article: <http://dx.doi.org/10.1016/j.diii.2013.08.016>.

[☆] Here is the answer to the case 'Wrist pain' previously published. As a reminder we publish again the entire case with the response following.

* Corresponding author.

E-mail address: merouane.kahloune@uclouvain.be (M. Kahloune).

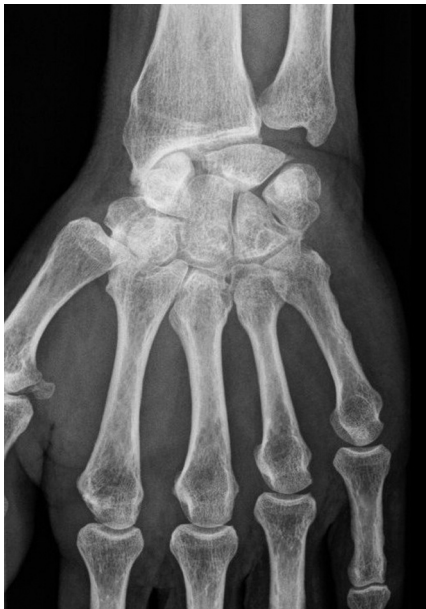

Figure 1. AP X-ray image of the right wrist.

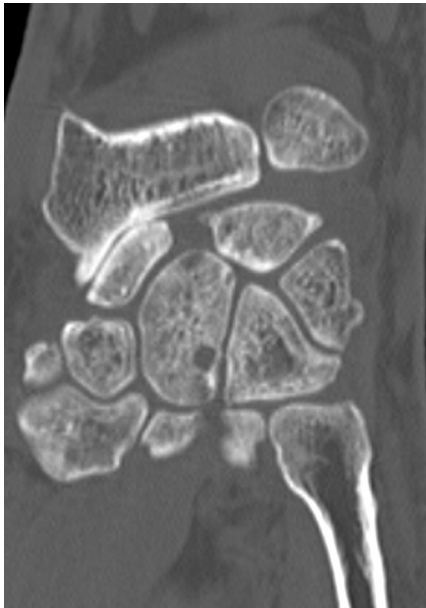

Figure 2. Coronal CT slice of the right wrist.

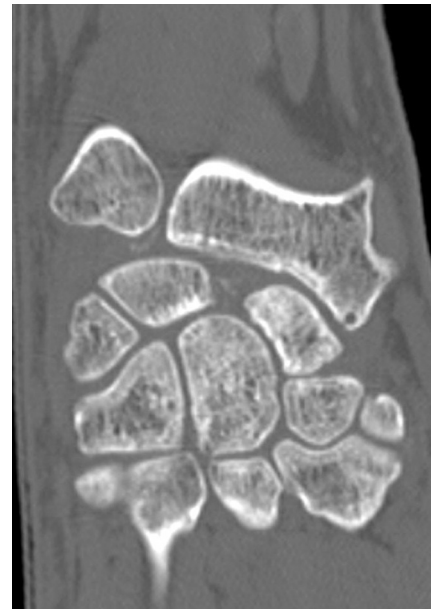


Figure 3. Coronal CT slice of the left wrist.

What is your diagnosis?

From the observations, what would your diagnosis be from among the following?

- gout;
- rheumatoid arthritis;
- SLAC wrist combined with chondrocalcinosis;
- hydroxyapatite.

Diagnosis

Scapholunate advanced collapse (SLAC) of the wrist associated with chondrocalcinosis.

Comments

The AP X-ray image of the right wrist (Fig. 4) shows pathological scapholunate diastasis, a scaphoid in flexion with its tubercle visible (cortical ring sign – white arrows), severe narrowing of the radioscaphoid joint space, narrowing of the lunocapitate joint space (black arrows). The CT coronal slices of the two wrists show, on the right (Fig. 5), pathological scapholunate diastasis, severe right radioscaphoid narrowing with subchondral osteosclerosis (arrows), and on the left (Fig. 6), pathological scapholunate diastasis and calcifications of the triangular fibrocartilage complex (arrow). On the left side (Fig. 7), multiple cysts can also be seen in several carpal bones (arrows) and calcifications in the scapholunate space.

Discussion

SLAC (scapholunate advanced collapse) wrist is osteoarthritis secondary to a lesion of the scapholunate ligament, which, in the long term, induces scapholunate dissociation

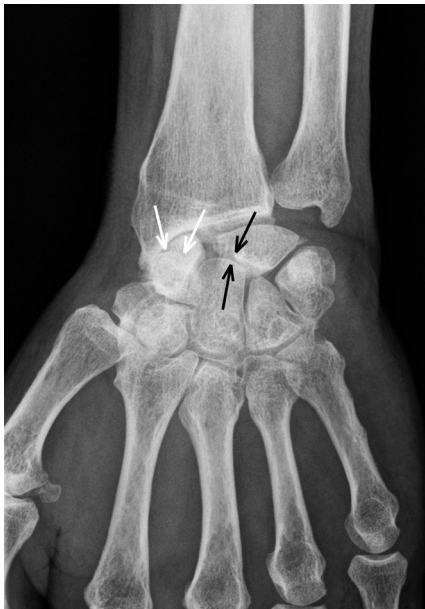

Figure 4. AP X-ray image of the right wrist: scapholunate diastasis with flexion of the scaphoid ('cortical ring sign' of the scaphoid tubercle visible – white arrows), severe radioscaphoid narrowing and narrowing of the lunocapitate joint space (black arrows).

combining flexion of the scaphoid, dorsal inclination of the lunate, and a pathological scapholunate diastasis (>2.5 mm). The scapholunate ligament is the most important intrinsic ligament of the wrist, because it is the main stabilizer of the first row of carpal bones. The origin of SLAC is often traumatic, more rarely degenerative. It is the most common form of osteoarthritis of the wrist typically evolving in three stages, at the beginning affecting the space between the radial styloid process and the scaphoid,

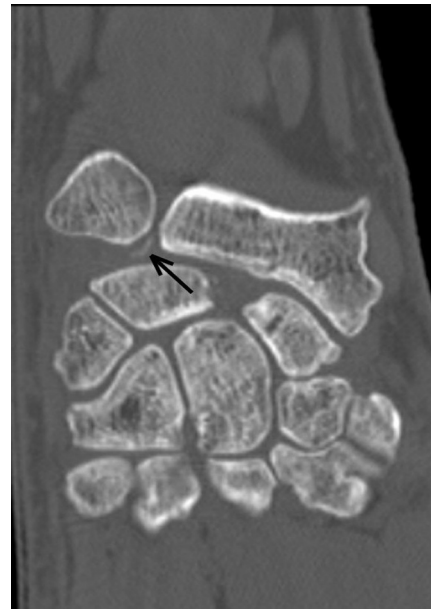

Figure 6. Coronal CT slice of the left wrist: pathological scapholunate diastasis, calcifications of the triangular fibrocartilage complex (arrow) and in the scapholunate space.

then the radioscaphoid joint space, and finally at a more advanced stage, the lunocapitate space [1].

Chondrocalcinosis or calcium pyrophosphate dihydrate (CPPD) crystal deposition disease has been described as being one of the main causes of SLAC [2,3]. It is a microcrystalline arthropathy related to the deposition of CPPD crystals in the articular (cartilage, fibrocartilage) and periarticular (synovial membrane, capsule, bursa, ligament, tendon) structures. This condition occurs sporadically after the age of 50, predominantly in women. Familial forms are

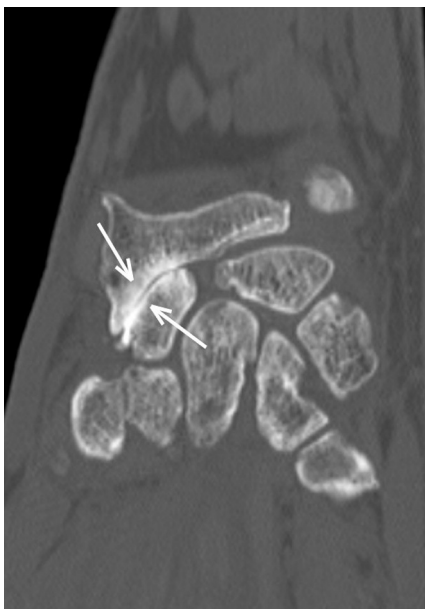


Figure 5. Coronal CT slice of the right wrist: pathological scapholunate diastasis, severe right radioscaphoid narrowing with subchondral osteosclerosis (arrows), fine calcifications in the scapholunate space and opposite the head of the capitate bone.

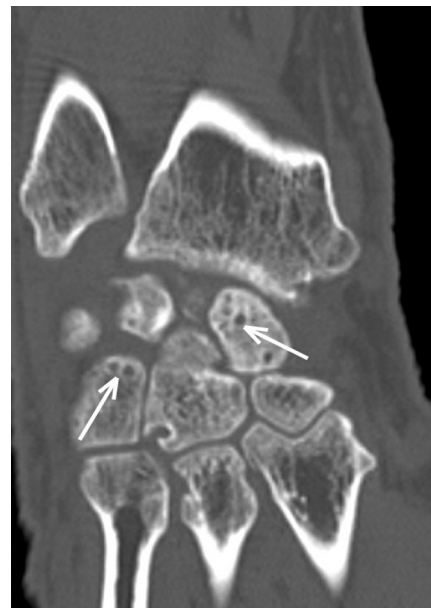


Figure 7. Coronal CT slice of the left wrist: multiple cysts in several carpal bones (arrows) and calcifications in the scapholunate space.

exceptional and commence between the ages of 20 and 40 (the *ANKH* gene) [4]. Secondary forms should be considered in cases where onset occurs before 50 years of age, since here chondrocalcinosis may be associated with hemochromatosis, hyperparathyroidism or hypomagnesemia. Patients may be totally asymptomatic. Symptomatic forms appear in half of the cases as pseudo-osteoarthritis with symmetrical, bilateral, acute flare-ups, and in a quarter of cases as pseudogout, which can mimic septic arthritis. The main joints affected are the knee, wrist, pubis, hip and shoulder.

In the wrist, SLAC is a common but late complication of chondrocalcinosis. In all cases of SLAC, apart from where there is a history of trauma, the presence should be sought of calcifications at the intercarpal joints or in the triangular fibrocartilage complex – the most common and most specific signs, but which are sometimes absent on standard X-ray images. The sensitivity of radiographs for detecting calcifications is indeed only 40 to 50% [5]. Isolated narrowing of the STT (scaphotrapeziotrapezoid) joint with bands of subchondral osteosclerosis is also very suggestive of a diagnosis of chondrocalcinosis [6]. The presence of metacarpophalangeal osteoarthritis (particularly 2nd and 3rd MCP) with hook-like osteophytes, points strongly towards chondrocalcinosis secondary to hemochromatosis [7]. Ultrasonography is more sensitive than standard X-ray images for detecting calcifications when they exist [8]. With ultrasound, CPPB deposits may appear as a hyperechoic band parallel to the surface of the hyaline cartilage or as hyperechoic spots in the fibrocartilage and tendons. Nodular or oval deposits may also be seen in the bursae and articular recesses [9]. Even though the CT scan is still not used much in this indication, its high resolution can detect the presence of articular and periarticular CPPB crystals [8]. It could be offered, according to the clinical picture, in a case where X-ray images are negative and CPPB crystals are not seen with ultrasound. From a CT arthrogram of the wrist, the scapholunate ligament and the triangular fibrocartilage complex, which are often interrupted by the destruction, can be studied, and above all, the state of the articular surfaces can be assessed [10].

Romano (in 2003) described a particular form of chondrocalcinosis that he called SCAC (Scaphoid Chondrocalcinosis Advanced Collapse) wrist, developing through 4 stages similarly to SLAC and SNAC wrist, but with special features, namely impaction of the scaphoid into the radius, frequent absence of scapholunate diastasis and sometimes the presence of isolated mediocarpal osteoarthritis.

Stage 1

Isolated involvement of the radioscapoid joint sometimes with narrowing and subchondral densification.

Stage 2

Clear radioscapoid involvement with narrowing of the joint space, verticalization of the scaphoid which is impacted

into the radius. Lunocapitate narrowing. No scapholunate diastasis.

Stage 3

Mediocarpal dislocation; the scaphoid is completely impacted into the radius in a manner which would be unusual for a SLAC or SNAC wrist.

Stage 4

Rarer, seen as destruction of all the carpal joints with particular involvement of the radiolunate joint.

The treatment of osteoarthritis of the wrist linked with chondrocalcinosis is usually conservative, based on non-steroidal anti-inflammatory drugs, colchicine and immobilization during flare-ups. Rarely, distal resection may be indicated of the scaphoid, in the case of scaphotrapezoid osteoarthritis, or even scaphoidectomy with arthrodesis of the 4 medial carpals [11].

Conclusion

In the first instance, the presence of a SLAC wrist in the absence of trauma suggests chondrocalcinosis, even if the calcifications are not visible on X-ray images.

Disclosure of interest

The authors declare that they have no conflicts of interest concerning this article.

References

- [1] Kirk Watson H, Frederick LB. The SLAC wrist: scapholunate advanced collapse pattern of degenerative arthritis. *J Hand Surg* 1984;9A:358–65.
- [2] Chen C. Scapholunate advanced collapse: a common wrist abnormality in calcium pyrophosphate dihydrate crystal deposition disease. *Radiology* 1990;177:459–61.
- [3] Resnick D, Niwayama G. Carpal instability in rheumatoid arthritis and calcium pyrophosphate deposition disease. *Ann Rheum Dis* 1977;36:311–8.
- [4] Hirose J, Ryan LM, Masuda I. Up-regulated expression of cartilage intermediate-layer protein and ANK in articular hyaline cartilage from patients with calcium pyrophosphate dihydrate crystal deposition disease. *Arthritis Rheum* 2002;46:3218–29.
- [5] Abreu M, Johnson K, Chung CB, et al. Calcification in calcium pyrophosphate dihydrate (CPPD) crystalline deposits in the knee: anatomic, radiographic, MR imaging, and histologic study in cadavers. *Skeletal Radiol* 2004;33:392–8.
- [6] Saffar P. Chondrocalcinosis of the wrist. *J Hand Surg Eur* 2004;29(5):486–93.
- [7] Mrabet D, Zouch I, Sahli H, Fendri L, Chéour E, Meddeb N, et al. Les manifestations ostéoarticulaires de l'hémochromatose. *Tunis Med* 2011;89(12):891–5.
- [8] Magarelli N, Amelia R, Melillo N, Nasuto M. Imaging of chondrocalcinosis: calcium pyrophosphate dihydrate (CPPD) crystal deposition disease – imaging of common sites of involvement. *Clin Exp Rheumatol* 2012;30(1):118–25.

- [9] Frediani B, Filippou G, Falsetti P, Lorenzini S, Baldi F, Acciai C, et al. Diagnosis of calcium pyrophosphate dihydrate crystal deposition disease: ultrasonographic criteria proposed. *Ann Rheum Dis* 2005;64(4):638–40.
- [10] Romano S. Arthrose non traumatique du poignet : la chondrocalcinose. *Chir Main* 2003;30:285–92.
- [11] Saffar P. Évolution et traitement de l'arthrose du poignet. *E-memoires Acad Nat Chir* 2012;11(2):025–30.