

## A COMPARISON BETWEEN HIGH DENSITY MINERALISED PROTRUSIONS IDENTIFIED IN THE KNEES OF CADAVERS AND PATIENTS OF THE OSTEOARTHRITIS INITIATIVE

N.P. Thomas\*<sup>1</sup>, N. Jeffery<sup>1</sup>, V.L. Adams<sup>1</sup>, L.R. Ranganath<sup>1</sup>, A. Boyde<sup>2</sup> and J.A. Gallagher<sup>1</sup>

<sup>1</sup>University of Liverpool, Liverpool, UK; <sup>2</sup>Queen Mary University of London, London, UK

**Submission Category:** Imaging

**Keywords:** Knee OA, Imaging, Biomarker, Cartilage Damage

**Purpose:** Fatigue-induced microcracking is a common, naturally occurring phenomenon in articular calcified cartilage and subchondral bone (SCB). These microcracks are, in some cases, healed by infilling with and mineralisation of an aqueous matrix. High density mineralised protrusions (HDMP) of the same matrix from the tidemark mineralising front into hyaline articular cartilage (HAC) form as an aberrant by-product of this resorptive repair mechanism. First discovered in equine joints, HDMPs have now been confirmed on the articular surfaces of femoral heads in humans with ochronotic and conventional osteoarthritis (OA). Possessed of mineral concentrations greater than any healthy joint tissue and a propensity to disintegrate within HAC, HDMPs undoubtedly affect the biomechanical performance of surrounding tissues and have been identified as one of the earliest detectable morphological changes in OA models. With this in mind, the fact that they arise through normal physiological processes is suggestive of a significant role in the development of arthropathy in incident joints. They are best seen by study of undecalcified tissue blocks but can be studied noninvasively by magnetic resonance imaging (MRI) and x-ray computed microtomography ( $\mu$ CT). The debilitating effects of OA are seen in many weight bearing joints, but human studies of HDMPs have been hitherto limited to *ex-vivo* hips. We prospect for them in the knee and compare their radiological appearance between *ex-* and *in-vivo* subject groups.

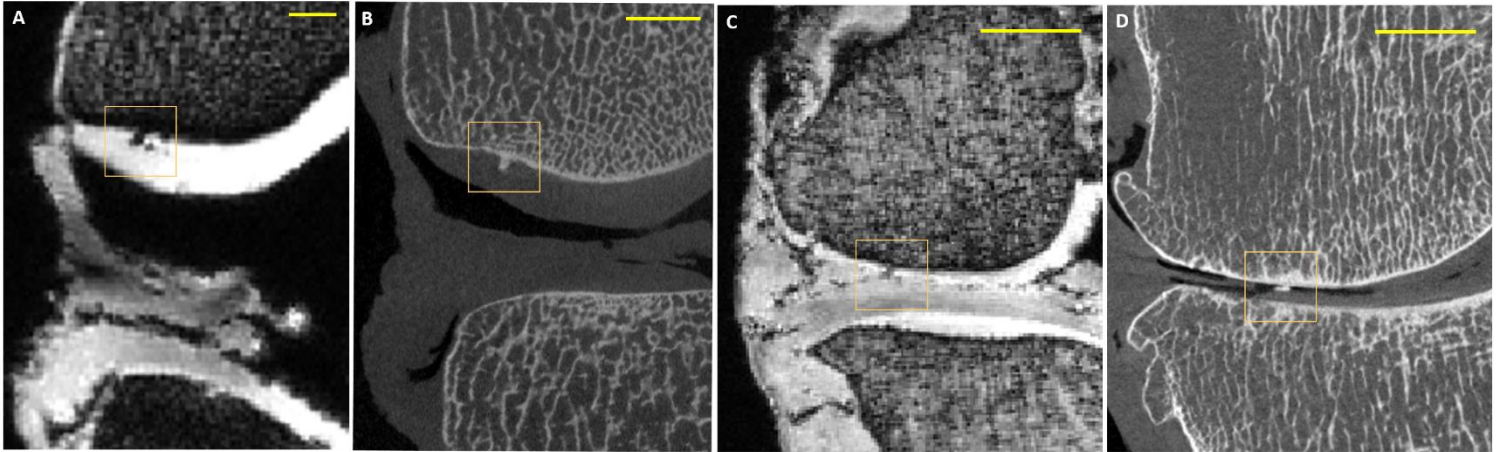
**Methods:** Twenty-three osteoarthritic cadaveric knees were dissected and each placed inside a circularly polarised wrist coil before being imaged by three dimensional dual-echo steady state (3D DESS) MR with water excitation using a 3T Siemens Trio. Variations in sample size produced isotropic image data with resolutions of between 0.26 and 0.48mm. A subset of 13 knees were further dissected and subjected to  $\mu$ CT with a 120kV Nikon XT225 scanner. Isometric voxels were reconstructed to produce tomographs with in-plane resolutions of 20-83 $\mu$ m. Cadaveric findings were compared to clinical data obtained from the Osteoarthritis Initiative (OAI), a longitudinal survey of knee OA. Twenty-one patients were selected from the OAI progression cohort, for whom bilateral knee MRI – including 3D DESS sequences – had been acquired with a similar 3T Siemens Trio system. Information on the radiological appearance of HDMPs from the literature was used to prospect for them in *ex-vivo* MRI. These findings were compared with  $\mu$ CT for validation. OAI imaging data were then surveyed for HDMPs using the same criteria. The appearance of HDMPs identified *in-vivo* was compared to validated *ex-vivo* findings to assess the viability of clinical scanning technology as an identification tool for HDMPs, *in-vivo*.

**Results:** HDMPs were identified in 19 of 23 *ex-vivo* knees by DESS MRI. These were identified as features of low signal yield extending from the SCB into HAC. Highly mineralised structures were confirmed in 5 of 13 knees by  $\mu$ CT. Figure 1 shows examples of HDMPs identified, *ex-vivo*. Seventeen of twenty-one OAI patients exhibited  $\geq 1$  HDMP in at least one knee at baseline visit. Image data from subsequent annual scans showed the persistence and development of many HDMPs, such as the example shown in figure 2. Whilst HDMPs are variable in their size and shape, their general appearance in DESS scans of OAI patients is consistent with those seen in the higher quality images of *ex-vivo* joints.

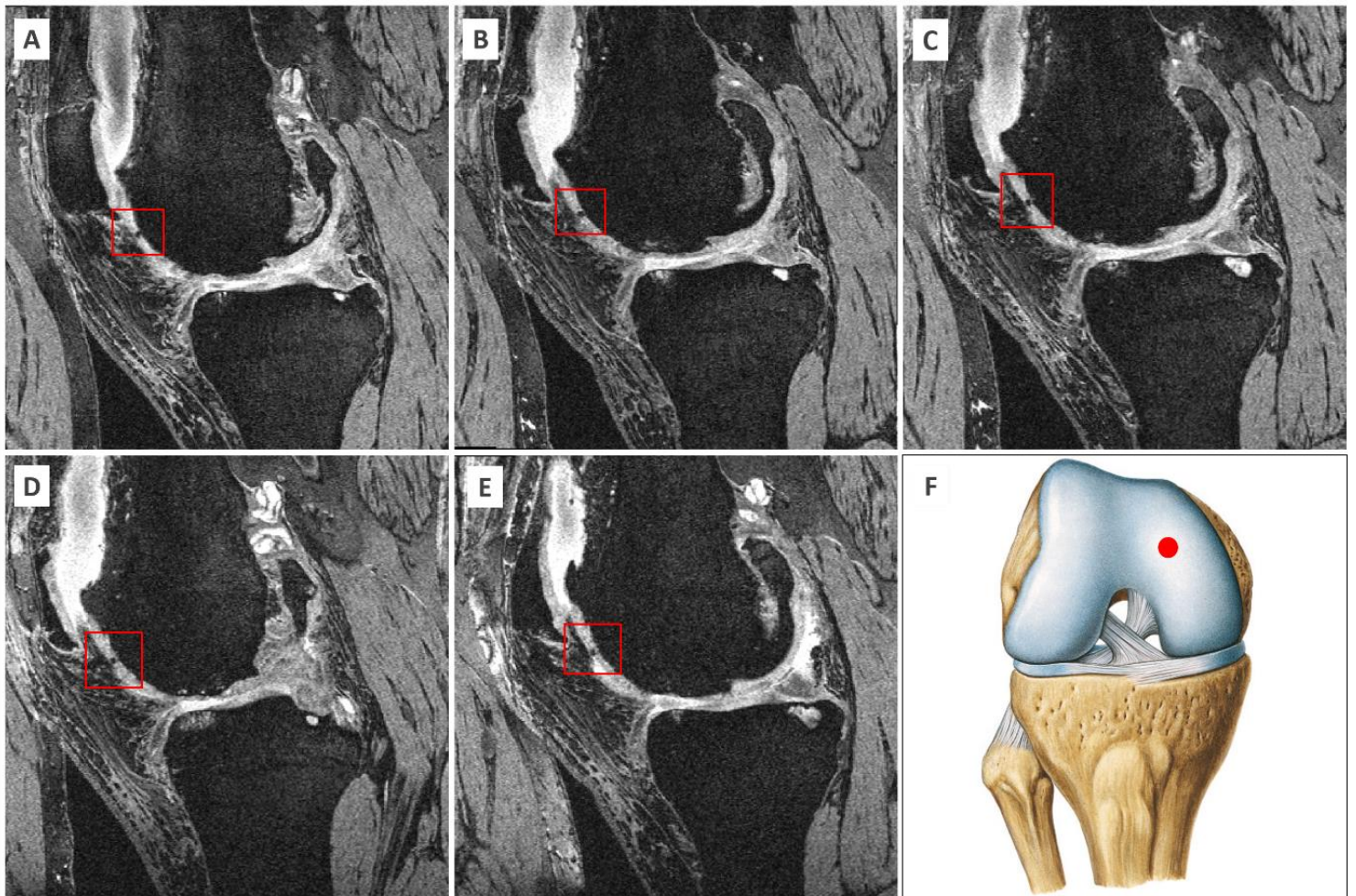
**Conclusions:** We observe HDMPs in the human knee joint for the first time; HDMPs do form in knees with structural OA and they are identifiable by 3D DESS MRI. Confirmation of HDMP density by  $\mu$ CT validates this finding. Instances of *ex-vivo* DESS identification which did not achieve  $\mu$ CT validation may be artefactual, or indicate the natural history of HDMPs – known to be brittle – fragmented under loading. Persistence of HDMPs in consecutive annual scans indicates those identified in OAI patients are unlikely to be artefact. The apparent similarity of HDMPs identified *in-vivo* and *ex-vivo* by similar MR sequences demonstrates the feasibility of DESS as an HDMP detection method that can be used clinically. Given the links made between HDMPs and the development of OA, evidence of their presence in knee joints may be significant in developing a better understanding the OA pathogenesis. With refinement, DESS may constitute a reliable identification method for HDMPs sufficient for their presence to be considered a potential imaging biomarker for predicting joint destruction in some forms of OA.

*Characters used: 4806/5000*

*Figures on next page*



**Figure 1.** Identification and validation of two HDMPs by (A and C) DESS MRI and (B and D)  $\mu$ CT, respectively. Scale bars 5mm.



**Figure 2.** A single HDMP identified by 3D DESS MRI shown in sagittal views at (A) baseline, (B) 12 months, (C) 24 months, (D) 36 months and (E) 48 months. (F) shows HDMP location in coronal view.