



|              |   |
|--------------|---|
| Title        | Well-differentiated fetal adenocarcinoma of the lung in a 20-year-old woman                                   |
| Author(s)    | Kanno, Ryuzo; Yamaura, Takumi; Higuchi, Mitsunori; Suzuki, Hiroyuki; Ohishi, Akio; Gotoh, Mitsukazu           |
| Citation     | Fukushima Journal of Medical Science. 59(2): 89-92  |
| Issue Date   | 2013  |
| URL          | <a href="http://ir.fmu.ac.jp/dspace/handle/123456789/373">http://ir.fmu.ac.jp/dspace/handle/123456789/373</a> |
| Rights       | © 2013 The Fukushima Society of Medical Science   |
| DOI          | 10.5387/fms.59.89   |
| Text Version | publisher   |

This document is downloaded at: 2020-09-02T18:49:43Z

[Case Report]

## WELL-DIFFERENTIATED FETAL ADENOCARCINOMA OF THE LUNG IN A 20-YEAR-OLD WOMAN

RYUZO KANNO<sup>1)</sup>, TAKUMI YAMAURA<sup>2)</sup>, MITSUNORI HIGUCHI<sup>1)</sup>, HIROYUKI SUZUKI<sup>2)</sup>,  
AKIO OHISHI<sup>1)</sup> and MITSUKAZU GOTOH<sup>2)</sup>

<sup>1)</sup>Department of Thoracic Surgery, Fukushima Red Cross Hospital, <sup>2)</sup>Division of Thoracic Surgery, Department of Regenerative Surgery, Fukushima Medical University School of Medicine, Fukushima, Japan

(Received March 4, 2013, accepted May 15, 2013)

**Abstract :** A 20-year-old woman was found to have a tumor shadow on chest X-ray examination during mass screening and was admitted to our hospital. The chest radiograph revealed a round tumor in the right upper lung field. Chest computed tomography (CT) showed a well-defined, 3-cm-diameter mass in the right upper lobe. The patient underwent a right upper lobectomy under video-assisted thoracoscopic surgery. The postoperative pathological diagnosis was well-differentiated fetal adenocarcinoma (W DFA), stage IA (pT1bN0M0). The patient was well and free of disease four years after surgery. W DFA is a rare pulmonary neoplasm resembling fetal lung and classified as a variant of adenocarcinoma. W DFA occurs in younger people more often than the other histological types of primary lung cancer. An additional young case of W DFA is reported, along with a review of the relevant literature.

**Key words :** Well-differentiated fetal adenocarcinoma, lung cancer

### INTRODUCTION

W DFA is a rare malignant lung tumor resembling fetal lung tubules and has been characterized as pulmonary blastoma without sarcomatous features. Recently, W DFA has been classified as a variant of pulmonary adenocarcinoma in the World Health Organization (WHO) classification of lung and pleural tumors<sup>1)</sup>. Although W DFA occurs in younger people more often than the other lung cancers, cases of W DFA under 20 years of age are extremely rare<sup>2)</sup>. An additional case of W DFA in a 20-year-old woman is reported, along with a review of the literature.

### CASE

A 20-year-old woman was found to have a tumor shadow on chest X-ray examination during mass screening and was admitted to our hospital. The chest radiograph revealed a round tumor in the

right upper lung field. On retrospective examination, the pulmonary mass had been growing from one year earlier (Fig. 1). Chest CT revealed a well-defined, 3-cm-diameter mass in the right upper lobe (Fig. 2). The patient had some drug allergies (lidocaine, iodine-based contrast medium, non-steroidal anti-inflammatory drugs) and bronchial asthma. Therefore, the patient did not undergo bronchoscopy. Hematologic data including tumor markers showed no abnormalities. A preoperative clinical diagnosis of pulmonary hamartoma or primary lung cancer was considered.

A right upper lobectomy was performed under video-assisted thoracoscopic surgery. The intraoperative pathological diagnosis was adenocarcinoma, and ND 2a mediastinal lymph node dissection was added. Grossly, the tumor was well demarcated from the surrounding lung parenchyma and had a gray cut surface (Fig. 3). The tumor size was 28×25×20 mm. The pathological findings showed a primitive glandular and irregularly branching tubu-

Corresponding author : Ryuzo Kanno, MD E-mail address : [ikyoku07@fukushima-med-jrc.jp](mailto:ikyoku07@fukushima-med-jrc.jp)  
<https://www.jstage.jst.go.jp/browse/fms> <http://www.fmu.ac.jp/home/lib/F-igaku/>

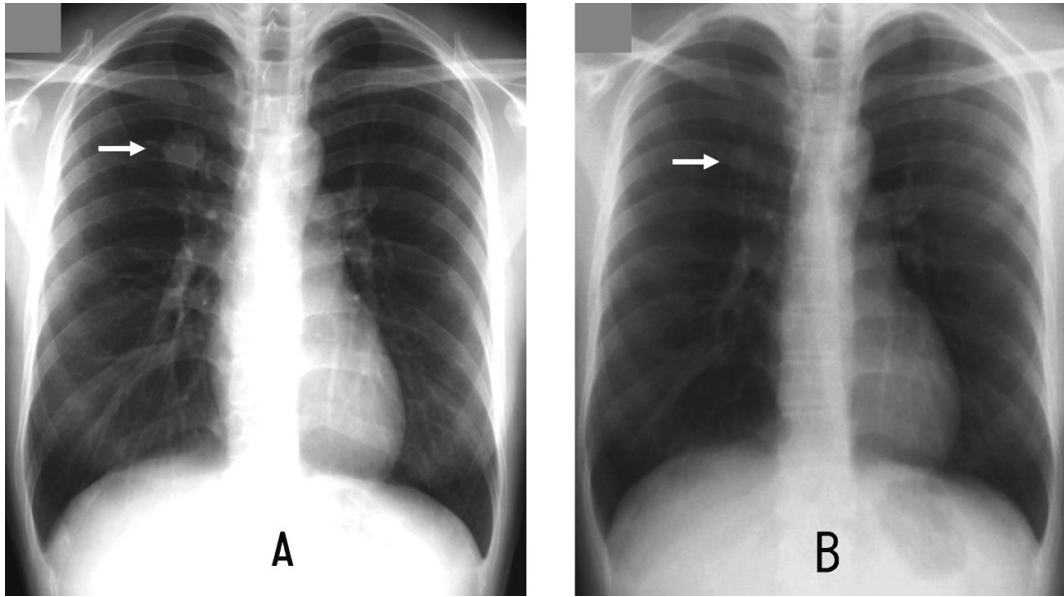


Fig. 1. Chest radiograph on admission (A) showing a nodule in the right upper lung field (*arrow*)  
Chest radiograph at mass screening one year earlier (B); the nodule is visible and appears smaller than in (A) above (*arrow*).

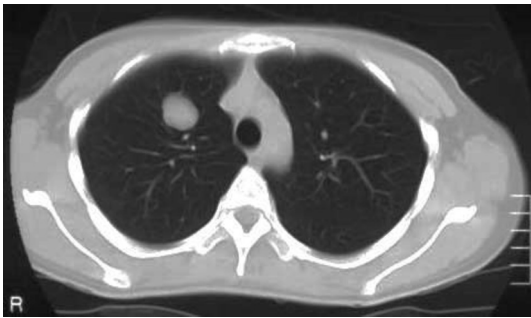

Fig. 2. Chest CT showing a well-defined nodule in the right upper lobe.

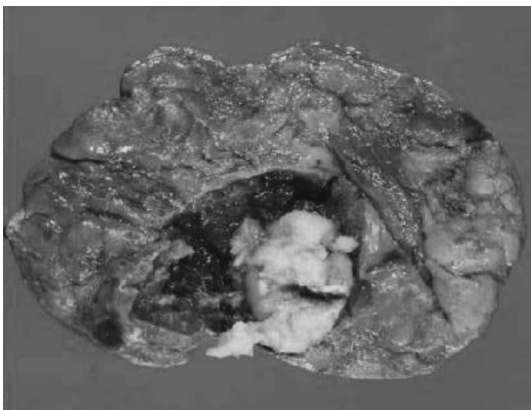


Fig. 3. The resected specimen showing a well demarcated whitish-grey tumor in the right upper lobe.

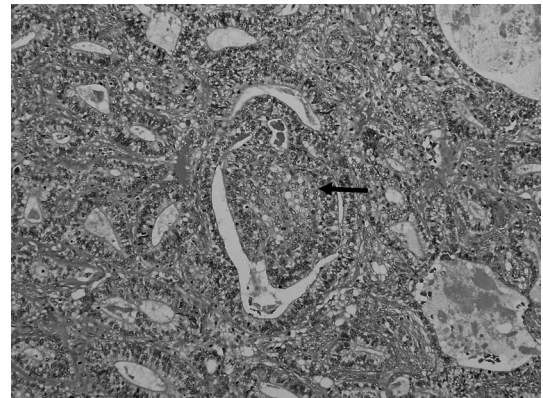


Fig. 4. Microscopic findings of the tumor show irregular ductal and papillary proliferation of columnar cells, resembling fetal lung. Squamoid morules are also seen (*arrow*) (HE stain,  $\times 200$ ).

lar pattern resembling fetal lung. The tumor cells were characterized by subnuclear and supranuclear vacuoles similar to an endometrioid appearance.

Squamoid morules were also present at the bases of glands (Fig. 4). Therefore, a diagnosis of WDFA was made. No regional lymph node metastases were detected. The patient's postoperative course was uneventful. No distant metastases were found on postoperative brain magnetic resonance imaging and positron emission tomography (PET). The pathological stage was T1bN0M0, and the patient did not undergo postoperative adjuvant chemotherapy. Four years after surgery, the patient was well and free of disease.

## DISCUSSION

W DFA is a rare malignant lung tumor resembling fetal lung tubules. Historically, W DFA was regarded as being derived from pulmonary blastoma (PB). In 1982, Kradin *et al.*<sup>4</sup> reported pulmonary blastoma lacking sarcomatous features, and they referred to such tumors pulmonary endodermal tumor resembling fetal lung; this was the first report of W DFA. In 1991, Koss *et al.*<sup>5</sup> divided PB into the following two histological groups: a monophasic form represented by W DFA; and the classic biphasic pulmonary blastoma (BPB) that consisted of both primitive glandular and mesenchymal components. BPB has a poor prognosis, but W DFA has a relatively good prognosis. They reported that the 5-year survival of resected cases of BPB was 50%, whereas that of W DFA was 80%. Recently, W DFA has been classified as a variant of pulmonary adenocarcinoma in the WHO classification of lung and pleural tumors. Zaidi *et al.*<sup>3</sup> reported that 3 (0.1%) of 2,720 cases of lung cancers were W DFAs. W DFA occurs most commonly in the third to fourth decade of life, which is earlier than the other histological types of primary lung cancer. However, cases of W DFA under 20 years of age are extremely rare, and only 10 cases (including the present case) have been reported (Table). Six of the cases are summarized, since four cases were not described in detail. Of these six cases (three males, three females, age range 10-20 years), four (67%) were asymptomatic, and their tumors were found on radiography as part of a medical checkup. The present patient was also asymptomatic, and the tumor was identified on chest radiography during mass screen-

ing. In all cases, including the present case, a correct preoperative diagnosis was difficult; all six cases received the diagnosis of W DFA postoperatively. Only one case (No. 9) was diagnosed as adenocarcinoma. It is important to determine whether the tumor is malignant before deciding on the operative procedure, especially in young patients. In the present case, bronchoscopy could not be performed due to drug allergy. Paull *et al.*<sup>6</sup> reported that W DFA demonstrated intense focal uptake on PET, so that PET scanning should be performed preoperatively. The diameter of the tumor in the resected specimens was 1.5 to 5.5 cm. Postoperative adjuvant chemotherapy was performed in only one case (case No. 9). In the present case, postoperative adjuvant chemotherapy was considered unnecessary because it was stage IA. The follow-up period was 24-48 months. Five cases were alive and free of disease, but the status of one case was unknown<sup>2, 7-10</sup>. The incidence of resected lung cancer in patients under 20 years of age was 0.02% (7/31,301 cases), and that under 30 years of age was 0.1% (37/31,301 cases) in Japan in 2009<sup>11</sup>. Mizushima *et al.*<sup>12</sup> reported that a high incidence of female sex and so-called low grade malignant tumor, and a low incidence of squamous cell carcinoma were characteristics of lung cancer in patients younger than 30 years of age. From the viewpoint of prognosis, W DFA in young patients is a low-grade malignant tumor. Complete surgical removal is the only effective method of treatment for W DFA. The necessity for adjuvant therapy and the efficacy of chemoradiotherapy for W DFA remain unclear. To establish the appropriate therapy of this tumor, it is necessary to review information about more cases.

Table. W DFA cases under 20 years of age

| No  | Authors (year)      | Age/Sex  | Symptoms            | Clinical diagnosis                      | Size (cm) | Location | Follow-up (months) |
|-----|---------------------|----------|---------------------|---|-----------|----------|--------------------|
| 1   | Manning (1985)      | 12/M     | no                  | hamartoma                               | 4.0       | RLL      | alive (39)         |
| 2~5 | Koss (1991)         | 12-19/NA | NA                  | NA                                      | NA        | NA       | NA                 |
| 6   | Singh (1997)        | 14/F     | back pain, cough    | hamartoma or arteriovenous malformation | 4.0       | LUL      | alive (28)         |
| 7   | Nakatani (1998)     | 19/M     | no                  | NA                                      | 1.5       | LUL      | NA                 |
| 8   | DiFurio (2003)      | 10/M     | shortness of breath | NA                                      | 5.5       | LUL      | alive (24)         |
| 9   | Yanaguchi (2011)    | 15/F     | no                  | lung cancer (adeno.)                    | 5.5       | RLL      | alive (8)          |
| 10  | Present case (2013) | 20/F     | no                  | hamartoma or lung cancer                | 2.8       | RUL      | alive (48)         |

NA, not available; RLL, right lower lobe; LUL, left upper lobe; RUL, right upper lobe; adeno., adenocarcinoma

### CONCLUSION

A rare case of WDFA in a 20-year-old woman was described. The possibility of lung cancer should always be kept in mind, even in young patients.

### REFERENCES

1. Colby TV. Adenocarcinoma. *In*: Travis WD, Brambilla E, Muller-Hermelink HK, Harris CC. World Health Organization Classification of Tumors: Pathology and Genetics of Tumor of the Lung, Pleura, Thymus and Heart. IARC Press, Lyon, 35-44, 2004.
2. Difurio MJ, Auerbach A, Kaplan KJ. Well-Differentiated Fetal Adenocarcinoma: Rare Tumor in the Pediatric Population. *Pediatric and Development Pathology*, **6**: 564-567, 2003.
3. Zaidi A, Zamvar V, Macbeth F, Gibbs AR, Kulatilake N, Butchart EG. Pulmonary Blastoma: Medium-Term Results From a Regional Center. *Ann Thorac Surg*, **73**: 1572-1575, 2002.
4. Kradin RL, Kirkham SE, Young RH, Mark EJ, Dickersin DR. Pulmonary Blastoma with Argyrophil Cells and Lacking Sarcomatous Features (Pulmonary Endodermal Tumor Resembling Fetal Lung). *Am J Surg Pathol*, **6**: 165-172, 1982.
5. Koss MN, Hochholzer L, Timothy OL. Pulmonary Blastoma. *Cancer*, **67**: 2368-2381, 1990.
6. Paull DE, Moezzi J, Katz N, Little AG, Adevojo SA. Positron Emission Tomography in Well-Differentiated Fetal Adenocarcinoma of the Lung. *Clinical Nuclear Medicine*, **31**: 213-214, 2006.
7. Manning JT, Ordonez NG, Rosenberg HS, Walker WE. Pulmonary Endodermal Tumor Resembling Fetal Lung. Report a Case with Immunohistochemical Studies. *Arch Pathol Lab Med*, **109**: 48-50, 1985.
8. Singh SP, Bensner GE, Schauer GM. Pulmonary Endodermal Tumor Resembling Fetal Lung: Report a Case in a 14-Year-Old Girl. *Pediatric Pathology*, **17**: 951-958, 1997.
9. Nakatani Y, Kitamura H, Inayama Y, Kamijo S, Nagashima Y, Shimoyama K, Nakamura N, Sano J, Ogawa N, Shibagaki T, Resl M, Mark EJ. Pulmonary Adenocarcinomas of the Fetal Lung Type. A Clinicopathologic Study Indicating Differences in Histology, Epidemiology, and Natural History of Low-Grade and High-Grade Forms. *Am J Surg Pathol*, **22**: 399-411, 1998.
10. Yamaguchi O, Osaki T, Oba H, Sugimoto Y, Ebi N, Yamamoto H. A Case of Well-Differentiated Fetal Adenocarcinoma Diagnosed in a 15-Year-Old Girl. *Jap J Lung Cancer*, **51**: 742-746, 2011.
11. Sakata R, Fujii Y, Kuwano H. Thoracic and Cardiovascular Surgery in Japan during 2009. *Gen Thorac Cardiovasc Surg*, **59**: 636-667, 2011.
12. Mizushima Y, Yokoyama A, Ito M, Manabe H, Hirai T, Minami H, Anzai Y, Satoh H, Kusajima Y, Yamashita R, Kobayashi K, Sugiyama S, Kobayashi M. Lung Carcinoma in Patients Age Younger than 30 Years. *Cancer*, **85**: 1730-1733, 1999.