



Title	Pathoanatomic investigation of cervical spondylotic myelopathy
Author(s)	Iwabuchi, Masumi; Kikuchi, Shinichi; Sato, Katsuhiko
Citation	Fukushima Journal of Medical Science. 50(2): 47-54
Issue Date	2004-12
URL	<a href="http://ir.fmu.ac.jp/dspace/handle/123456789/157">http://ir.fmu.ac.jp/dspace/handle/123456789/157</a>
Rights	© 2004 The Fukushima Society of Medical Science
DOI	
Text Version	publisher

This document is downloaded at: 2020-09-02T18:45:00Z

## PATHOANATOMIC INVESTIGATION OF CERVICAL SPONDYLOTIC MYELOPATHY

MASUMI IWABUCHI, SHINICHI KIKUCHI and KATSUHIKO SATO

*Department of Orthopaedic Surgery,  
Fukushima Medical University School of Medicine, Fukushima*

(Received December 3, 1999, accepted October 8, 2004)

**Abstract** : Multiple dural sac and spinal cord indentations are often observed on MRI in cervical spondylotic myelopathy. However, it is rare that all of the indented levels contribute to clinical symptoms. Pathological changes in cervical compression myelopathy have previously been reported. Still the critical degree of spinal cord compression needed to induce pathologic changes is unknown. To clarify this matter the relationships between the spinal cord as well as the dural sac indentations, and pathological changes of the cervical spinal cord were investigated in cadavers. Sixty-eight cadavers were used for this study. The dural sac and the spinal cord were observed especially regarding presence of indentations. The spinal cord was removed from the specimens in order to perform histopathological examination. The indentations of the dural sac and the spinal cord were observed at C4/5, C5/6, C6/7 and C3/4 intervertebral levels in order of incidence. However, all of the dural sac indentations were not correlated with spinal cord indentations. Pathological changes in the spinal cord were observed in two specimens with less than 30% of the AP compression ratio. One specimen with 20.9% in the AP compression ratio had remarkable histopathological changes. In the other specimen with 29.6% in the AP compression ratio, diffuse demyelination was distributed in the lateral white matter. The results indicate that the critical degree of the AP compression ratio is 30% to induce histopathological changes in the spinal cord. If a spinal cord indentation in the patient with cervical spondylotic myelopathy on imaging, i.e. MRI, show less than 30% in the AP compression ratio, the clinical symptoms, i.e. numbness, tickling and paresthetic pain, may not be improved after the surgery because of some histopathological changes in the spinal cord.

**Key words** : cervical spine, spinal cord, cervical spondylotic myelopathy, pathoanatomy

---

岩淵真澄, 菊地臣一, 佐藤勝彦

Correspondence to : Masumi Iwabuchi, Department of Orthopaedic Surgery, Fukushima Medical University School of Medicine, Fukushima City 960-1295, Japan.

E-mail : miwabu@fmu.ac.jp

## INTRODUCTION

Multiple dural sac and spinal cord indentations are often observed on imaging, i.e. MRI, CT scan and myelogram, in cervical spondylotic myelopathy. However, it is rare that all of the indented levels contribute to the symptoms of the patient. Some authors have reported about experimental or clinical studies of the pathological changes in cervical compression myelopathy<sup>1-7</sup>. Still the critical degree of spinal cord compression needed to induce pathologic changes is unknown. In order to clarify this matter the relationships between the spinal cord as well as the dural sac indentations and pathological changes of the cervical spinal cord were investigated in cadavers.

## MATERIALS AND METHODS

Sixty-eight cadavers (men ; 40, women ; 28, mean age ; 75.6 years, range ; 37-102 years) were used for this study. Laminectomy was performed in the cervical spine. The posterior part of the dural sac and the spinal cord were macroscopically observed, especially regarding possible presence of indentations. An indentation

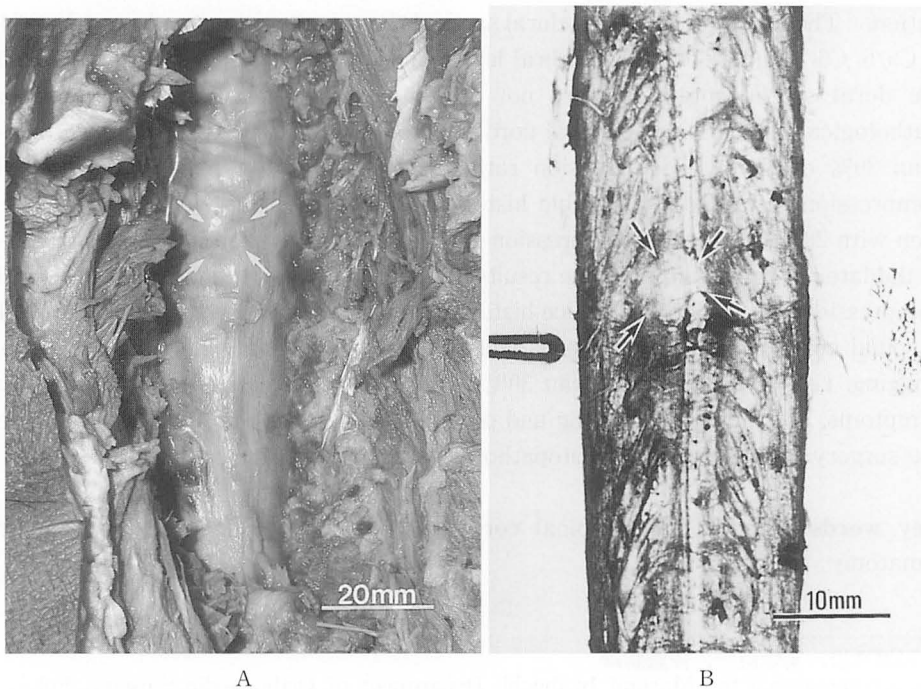
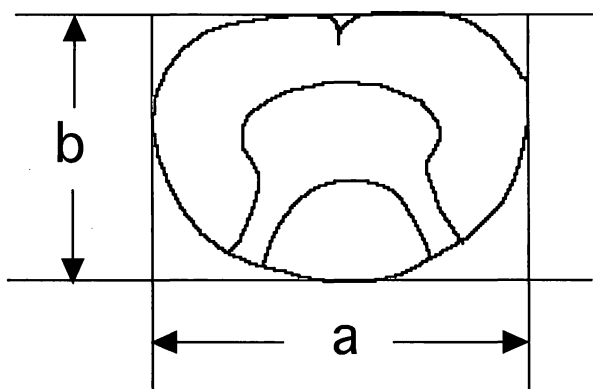


Fig. 1A, B. Posterior dural sac (A) and anterior spinal cord (B) indentations (arrows). An indentation was defined as a local deformation of dural sac and/or spinal cord with a diameter of more than 5 mm.



$$\text{AP compression ratio} = b/a \times 100$$

Fig. 2. AP compression ratio

was defined as a local deformation of dural sac and/or spinal cord with a diameter of more than 5 mm (Figure 1A, B). The diameter was measured with a caliper. The spinal cord was removed from the specimen in order to observe indentations located on the anterior side of the dural sac and the spinal cord.

For histopathological evaluation, the spinal cord was cut in horizontal planes at the intervertebral disc level at which indentation had been observed. The sections were fixed with 20% formalin and sliced into 10 micron-thick. Klüver-Barrera (KB) stain was applied to these sections. Anteroposterior compression ratio (AP compression ratio)<sup>3)</sup> was also measured to assess the degree of compression in each section (Figure 2). Then the AP compression ratio of the specimens with pathological changes<sup>3,4)</sup> was compared with that of the specimens without pathological changes.

## RESULTS

### *Macroscopic findings*

Anterior dural sac indentation was observed in 23 out of 68 specimens (34%) and that at 58 out of 272 intervertebral disc levels (21%). The anterior spinal cord indentation correlated with the anterior dural sac indentation was observed in 22 out of 68 specimens (32%) and at 43 out of 272 intervertebral disc levels (16%) (Figure 3A). Posterior dural sac indentation was observed in 23 out of 68 specimens (34%) and at 41 out of 272 intervertebral disc levels (15%). The posterior spinal cord indentation correlated with the posterior dural sac indentation was observed in 8 out of 68 specimens (12%) and at 9 out of 272 intervertebral disc levels (3%) (Figure 3B). Therefore all of the dural sac indentations were not correlated with spinal cord

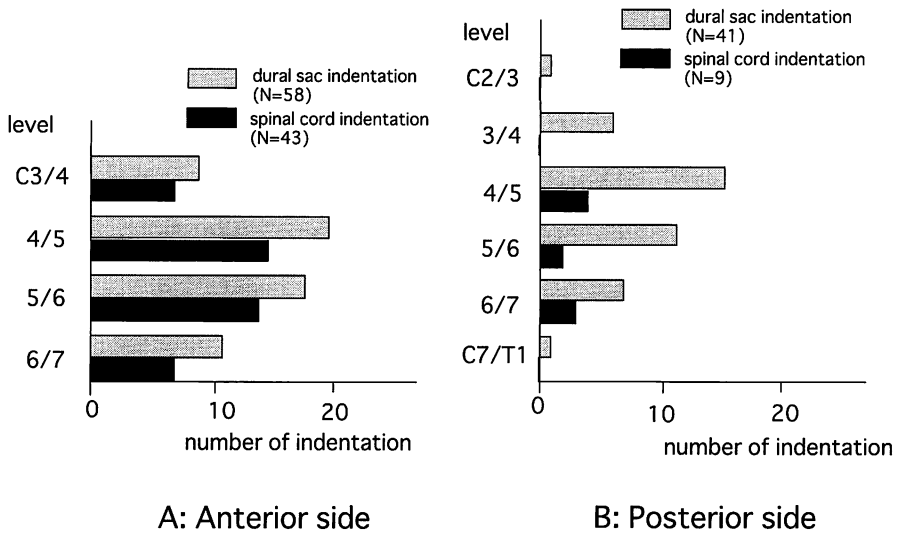


Fig. 3A, B. Distribution of the anterior (A) and the posterior (B) indentations. All of the dural sac indentations were not correlated with the spinal cord indentations. The C4/5 and the C5/6 intervertebral disc levels had the most number of the dural sac and the spinal cord indentations.

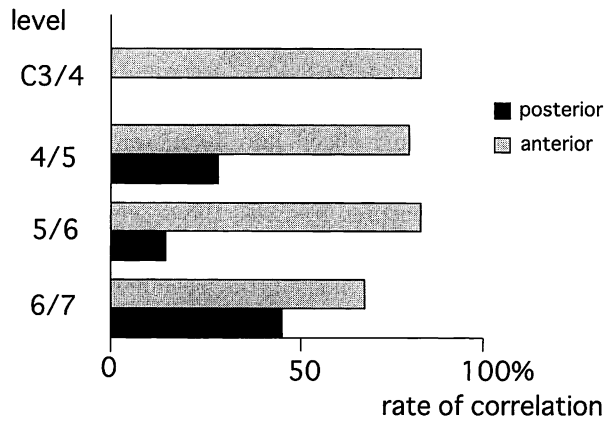


Fig. 4. Rate of correlation between the dural sac and the spinal cord indentations. The rate of correlation between the dural sac and the spinal cord indentation was significantly higher on the anterior side than on the posterior side of the dural sac ( $P < 0.00005$ , chi-square test).

indentations. The most number of the dural sac and the spinal cord indentations were observed at the C4/5 intervertebral disc level both in the anterior side and in the posterior side. The rate of correlation between the dural sac and the spinal cord indentation was significantly higher on the anterior side than on the posterior side of the dural sac ( $p < 0.00005$ , chi-square test) (Figure 4).

Table 1. Correlation between the AP compression ratio and histopathological changes.

specimen	level without indentation APCR%	level with indentation APCR%	histopathological changes
1	50.0	41.0	—
2	40.9	45.0	—
3	40.5	37.3	—
4	60.0	20.9	+
5	58.0	52.0	—
6	56.0	48.0	—
7	50.0	46.2	—
8	34.5	30.4	—
9	56.5	57.1	—
10	56.0	50.0	—
11	35.0	31.6	—
12	40.9	39.1	—
13	40.0	29.6	+
14	45.0	43.0	—

APCR=anteroposterior compression ratio

### *Pathological findings*

The mean of the AP compression ratio at the intervertebral disc levels without indentation was 47.4%, whereas that with indentation was 40.8%. In 2 out of 22 specimens (9.1%) with the AP compression ratio less than 30%, pathological changes were detected in histology. An extensive cavitation of the gray matter was observed at the indented level in a specimen with the AP compression ratio of 20.9%. And diffuse demyelination of the lateral white matter was observed in the other specimen with the AP compression ratio of 29.6% (Table 1).

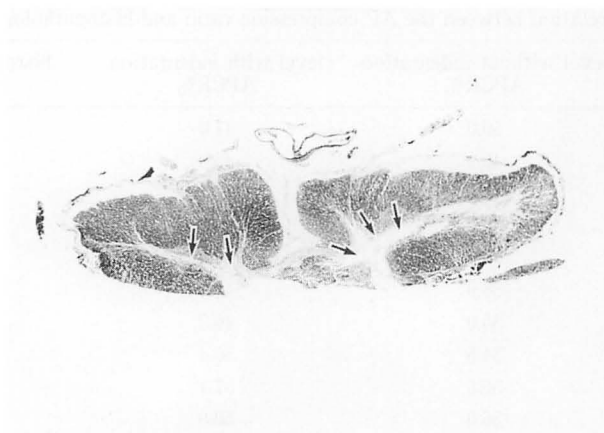### *Example of pathological changes*

#### *Specimen No. 4, 78 year-old-woman*

Spinal cord indentations located at both anterior and posterior part of the spinal cord were observed at the level of C6/7 intervertebral disc. The AP compression ratio at the level was 20.9%. Extensive necrosis and cavitation was detected in the gray matter of the spinal cord (Figure 5A). Extensive necrosis and gliosis was also observed in the lateral white matter (Figure 5B).

#### *Specimen No. 13, 90 year-old-woman*

Anterior spinal cord indentation was observed at the level of C4/5 intervertebral disc. The AP compression ratio at the level was 29.6%. Diffuse demyelination was distributed in the lateral white matter (Figure 6).



A



B

Fig. 5A, B. Pathological findings of the specimen No. 4, C6/7 intervertebral disc level. K.B. stain. (A:  $\times 10$ , B:  $\times 60$ )

A: Extensive necrosis and cavitation was detected in the gray matter of the spinal cord (arrows).

B: Extensive necrosis and gliosis was also observed in the lateral white matter (arrows).

#### DISCUSSION

It has been reported that the canal diameter of the cervical spine is related to cervical spondylotic myelopathy<sup>1,3-5,8-11</sup>). Some authors have reported about the pathological changes in cervical compression myelopathy<sup>1-7</sup>). However, the critical degree of spinal cord compression needed to induce pathologic changes is unknown.

In the present study the rate of correlation between the dural sac and the spinal cord indentation was higher on the anterior side of the dura and spinal cord than in the posterior side of them. This result indicates that the patients with an anterior

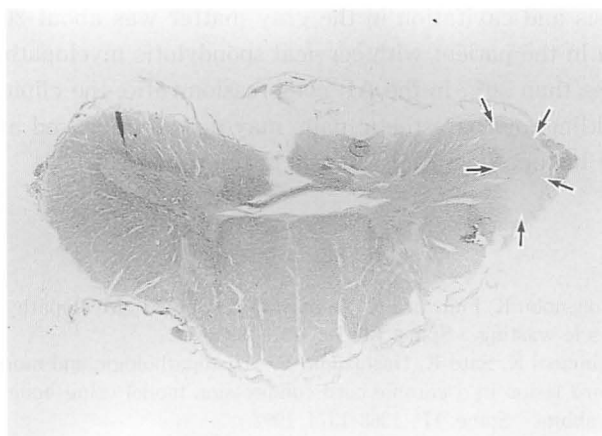


Fig. 6. Pathological findings of the specimen No. 13, C4/5 intervertebral disc level.  
K.B. stain. ( $\times 10$ )  
Diffuse demyelination was distributed in the lateral white matter (arrows).

dural sac indentation on myelogram are more likely to have a spinal cord indentation than the patients with a posterior dural sac indentation are. Furthermore, all of the specimens with a dural sac indentation did not always have a spinal cord indentation. Therefore, all of the dural sac indentations as seen on myelograms would not have a spinal cord indentation. The C4/5 and the C5/6 intervertebral disc levels had the most number of the dural sac and the spinal cord indentations. This result correlates with the clinical situation that many patients with cervical spondylotic myelopathy have the dural sac and the spinal cord indentations at the C4/5 and the C5/6 intervertebral disc levels on MRI or myelogram.

The pathological changes of the spinal cord were classified into three grades by Ogino *et al.*<sup>3)</sup> and Ono<sup>4)</sup>. In the literatures, the severest pathological change, i.e. extensive cavitation, was detected in two cases with less than 20% in the AP compression ratios. In the present study, extensive necrosis and cavitation in the gray matter was observed in one specimen with the AP compression ratio of 20.9%. Extensive necrosis and gliosis was also observed in the lateral white matter. This result is in agreement with the report by Ogino<sup>3)</sup>. Therefore, in a case with spinal cord indentation in which the AP compression ratio is about 20% or lower, extensive cavitation, which is a severe pathological change, might occur in the spinal cord. In the other specimen with the AP compression ratio of 29.6%, diffuse demyelination was distributed in the lateral white matter<sup>3,4)</sup>. Other 12 specimens have no histopathological changes at the levels with spinal cord indentation. These results indicate that the critical degree of the AP compression ratio to induce some histopathological changes in the spinal cord was about 30%.

In conclusion, the critical degree of the AP compression ratio to induce histopathological changes in the spinal cord was about 30%. Furthermore, the degree of the AP compression ratio enough to induce the severe pathological changes, i.e.



extensive necrosis and cavitation in the gray matter was about 20%. If a spinal cord indentation in the patient with cervical spondylotic myelopathy on imaging, i. e. MRI, show less than 30% in the AP compression ratio, the clinical symptoms, i. e. numbness, tickling and paresthetic pain, may not be improved after the surgery because of some histopathological changes in the spinal cord.

## REFERENCES

1. Ebara S, Yonenobu K, Fujiwara K, Yamashita K, Ono K. Myelopathy hand characterized by muscle wasting. *Spine*, **13**: 785-791, 1988.
2. Saito H, Mimatsu K, Sato K, Hashizume Y. Histopathologic and morphometric study of spinal cord lesion in a chronic cord compression model using bone morphogenetic protein in rabbits. *Spine*, **17**: 1368-1374, 1992.
3. Ogino H, Tada K, Okada K, Yonenobu K, Yamamoto T, Ono K, Namiki H. Canal diameter, anteroposterior compression ratio and spondylotic myelopathy at the cervical spine. *Spine*, **8**: 1-15, 1983.
4. Ono K. Clinical feature and pathology of compression myelopathy. *J Jpn Orthop Assoc*, **60**: 103-118, 1986.
5. Payne EE, Spillane JD. The cervical spine. An anatomico-pathological study of 70 specimens (using a special technique) with particular reference to the problem of cervical spondylosis. *Brain*, **80**: 571, 1957.
6. Schramm J, Takahashi H, Krause R. Reversibility of changes in evoked spinal response following graded spinal cord compression. *Acta Neurochir Suppl Wien*, **28**: 599-604, 1979.
7. Schramm J, Shigeno T, Brock M. Clinical signs and evoked response alternations associated with chronic experimental cord compression. *J Neurosurg*, **58**: 734-741, 1983.
8. Edwards WC, LaRocca SH. The developmental sagittal diameter in combined cervical and lumbar spondylosis. *Spine*, **10**: 42-49, 1985.
9. Parke WW. Correlative anatomy of cervical spondylotic myelopathy. *Spine*, **13**: 831-37, 1988.
10. Lestini WF, Wiesel SW. The pathogenesis of cervical spondylosis. *Clin Orthop*, **239**: 69-93, 1989.
11. Murone I. The importance of the sagittal diameters of the cervical spinal canal in relation to spondylosis and myelopathy. *J Bone Joint Surg*, **56B**: 30-36, 1974.
12. Wilkinson HA, Lemay ML, Ferris EJ. Clinical-radiographic correlations in cervical spondylosis. *J Neurosurg*, **30**: 213-218, 1979.