

Received: 31 December 2019

Revised: 22 May 2020




Accepted: 1 June 2020

DOI: 10.1002/mgg3.1389

ORIGINAL ARTICLE

Molecular Genetics & Genomic Medicine  WILEY

Investigation on the role of biallelic variants in *VEGF-C* found in a patient affected by Milroy-like lymphedema

Sylvain Mukenge¹  | Sawan K. Jha² | Marco Catena¹ | Elena Manara³  |
Veli-Matti Leppänen⁴ | Elisa Lenti⁵ | Daniela Negrini⁶  | Matteo Bertelli³ |
Andrea Brendolan⁵ | Michael Jeltsch^{2,4} | Luca Aldrighetti¹

¹Department of Surgery, Istituto di Ricovero e Cura a Carattere Scientifico (IRCCS), San Raffaele Scientific Institute, Milan, Italy

²Translational Cancer Biology Program, Biomedicum Helsinki, University of Helsinki, Helsinki, Finland

³Research Unit, MAGI Euregio, Bolzano, Italy

⁴Wihuri Research Institute, Helsinki, Finland

⁵Department of Experimental Oncology, Istituto di Ricovero e Cura a Carattere Scientifico (IRCCS), San Raffaele Scientific Institute, Milan, Italy

⁶Department of Medicine and Surgery, University of Insubria, Varese, Italy

Correspondence

Sylvain Mukenge, Department of Surgery
Istituto di Ricovero e Cura a Carattere
Scientifico (IRCCS) San Raffaele Scientific
Institute Via Olgettina 60, Milan, Italy.
Email: mukenge.mvunde@gmail.com

Funding information

Hepatobiliary Surgery Department of
IRCCS Ospedale San Raffaele; Novo
Nordisk Foundation and the Sigrid
Jusélius Foundation; Finnish Foundation
for Cardiovascular Research, Grant/
Award Number: 160038; Wihuri Research
Institute, maintained by the Jenny and
Antti Wihuri Foundation; Jane and Aatos
Erkko Foundation; Academy of Finland
Centre of Excellence Program 2014-2019,
Grant/Award Number: 307366; European
Research Council (ERC) under the
European Union's Horizon 2020, Grant/
Award Number: 743155; Integrated Life
Science Doctoral Program; Academy
of Finland, Grant/Award Number:
303778303778, 273612 and 265982

Abstract

Background: Milroy-like disease is the diagnostic definition used for patients with phenotypes that resemble classic Milroy disease (MD) but are negative to genetic testing for *FLT4*. In this study, we aimed at performing a genetic characterization and biochemical analysis of VEGF-C variations found in a female proband born with congenital edema consistent with Milroy-like disease.

Methods: The proband underwent next-generation sequencing-based genetic testing for a panel of genes associated with known forms of hereditary lymphedema. Segregation analysis was performed on family members by direct sequencing. In vitro studies were performed to evaluate the role of a novel identified variant.

Results: Two *VEGF-C* variations were found in the proband, a novel p.(Ser65Arg) and a pathogenic c.148-3_148-2delCA, of paternal and maternal origin, respectively. Functional characterization of the p.(Ser65Arg) variation in vitro showed alterations in VEGF-C processing.

Conclusions: Our findings reveal an interesting case in which biallelic variants in *VEGF-C* are found in a patient with Milroy-like lymphedema. These data expand our understanding of the etiology of congenital Milroy-like lymphedema.

KEYWORDS

lymphatic system, Milroy disease, mutation, primary lymphedema, VEGF-C

Sylvain Mukenge and Sawan Kumar Jha have equally contributed to the work.

This is an open access article under the terms of the Creative Commons Attribution-NonCommercial-NoDerivs License, which permits use and distribution in any medium, provided the original work is properly cited, the use is non-commercial and no modifications or adaptations are made.

© 2020 The Authors. *Molecular Genetics & Genomic Medicine* published by Wiley Periodicals LLC.

1 | INTRODUCTION

Lymphedema comprises a series of conditions characterized by impaired lymph transport, leading to lymph stagnation in the interstitium, especially in subcutaneous tissues (Rockson, 2006). Fluid accumulation in tissues can manifest as swelling in specific parts of the body, mainly in the lower limbs, but also in the upper limbs, face, and genitals. Primary lymphedema is the term used when the lymphedema is not caused by another medical condition. Milroy disease (MD) is a congenital form of lymphedema with autosomal dominant inheritance, characterized by painless unilateral edema, often present at birth, usually affecting the dorsum of the feet and extending to the lower limb. In about 70% of cases, MD is associated with missense point mutations of the FMS-like tyrosine kinase 4 gene, *FLT4* (MIM 136352), which encodes the vascular endothelial growth factor receptor 3 (*VEGFR-3*) (Connell et al., 2009). Recent studies have shown that variants in *VEGF-C* (MIM 601528), the gene coding for one of the VEGFR-3 ligands, can lead to a MD-like phenotype; five families with dominantly inherited lymphedema have been so far described to present heterozygous *VEGF-C* variants (Balboa-Beltran et al., 2014; Fastré et al., 2018; Gordon et al., 2013b; Nadarajah et al., 2018).

VEGF-C, important for lymph vessel development, is synthesized as precursor protein, which undergoes proteolytic processing which increases its affinity for its receptors, VEGFR-2 and VEGFR-3, with the consequent activation of intracellular signaling involved in lymphangiogenesis (Alitalo, Tammela, & Petrova, 2005; Tammela & Alitalo, 2010). The metalloproteinase ADAMTS3 has been shown to directly interact with VEGF-C and induce its proteolytic processing. However, the processing of VEGF-C by ADAMTS3 is enhanced by the collagen and calcium-binding EGF domain-containing protein 1 (CCBE1) (Bui et al., 2016).

Here, we report an interesting family case of a patient with a disease resembling MD that, by a sequencing analysis, showed biallelic variants in *VEGF-C*. To clarify the role of these variants, further investigations were carried out. Clinical examination of the family by lymphoscintigraphy as well as biochemical in vitro assays is supportive for a role of both variants in the development of the proband phenotype. Our experiments demonstrate that proteolytic processing of the novel VEGF-C Ser65Arg variant is decreased compared to wild-type VEGF-C. These data expand our understanding of the etiology of congenital Milroy-like lymphedema.

2 | METHODS

All studies on human subjects were performed according to the Declaration of Helsinki rules and after approval of the Ethical Committee of the San Raffaele Hospital.

2.1 | Lymphoscintigraphic assessment

All clinical diagnostics and tests were performed at the Department of Radiology of Cuneo hospital. Lymphoscintigraphic examination was based on 99mTc-albumin nanocolloid (NANOCOLL*0.5 Mg Kit, GE Healthcare S.r.l.), injected into the interdigital space in both feet. The dosing was: 41 + 41 MBq in the proband, 60 + 60 MBq in the father, 55 + 5 MBq in the mother, 60 + 60 MBq in the elder brother, and 40 + 40 MBq in the proband's twin brother. The lymphoscintigrams were recorded in three phases according to the protocol of Bourgeois et al. (Bourgeois, Leduc, Belgrado, & Leduc, 2009). Briefly, in phases 0–3, the images were acquired at the points of injection to verify tracer clearance; in phase 1, the inguinal regions were evaluated at rest and a whole-body scan of ninety 20-s frames was acquired in 30 min; phase 2 consisted of dynamic scans centered on the groins and whole-body scan during moderate exercise (tip-toeing movement of feet and toes); phase 3 consisted of whole-body scan after 1 hr of walking or 30 min of stationary cycling. Lymphoscintigraphic images obtained from phases 1 and 3 were analyzed offline by using the automatic area plugin of ImageJ software (NIH, <http://rsb.info.nih.gov/ij/>) to determine, in the frontal projection, the distribution area of the 99mTc-albumin nanocolloid within lymphatic structures.

2.2 | Sequencing

The genetic diagnosis was done in MAGI's Lab. All subjects received genetic counseling to explain the risks and benefits of genetic testing and they signed a consent to make their clinical and genetic data available for research purposes. DNA was extracted using the Blood DNA kit E.N.Z.A. (Omega bio-tek) from blood samples of the proband and her four relatives. Genetic profile of the proband was obtained using the next generation sequencing (NGS) approach and a panel designed to include the main genes involved in primary lymphedema (including MD, Emberger syndrome, lymphedema-distichiasis, and other syndromes). The coding and adjacent intron regions of the *CCBE1* (MIM 235510; NM_133459), *FLT4* (MIM 153100; NM_182925, NM_002020), *FOXC2* (MIM 153400; NM_005251), *GATA2* (MIM 614038; NM_001145661), *GJC2* (MIM 613480; NM_020435), *SOX18* (MIM 607823; NM_018419), *VEGF-C* (MIM 615907; NM_005429), *KIF11* (MIM 152950; NM_004523), *HGF* (MIM 142409; NM_000601, NM_001010934, NM_001010931), and *MET* [11] (MIM 164860; NM_000245, NM_001127500, NM_001324401) were analyzed using Nextera Rapid Custom Capture Enrichment (Illumina) and NGS on Illumina MiSeq platform (150 bp paired-end reads). To exclude polymorphisms, we also searched the public database of single nucleotide

variants (dbSNP; www.ncbi.nlm.nih.gov/SNP). To assess the pathogenicity of new nucleotide alterations involving a change of amino acid residues, we used the PolyPhen 2 algorithm (Polymorphism Phenotyping v2; <http://genetics.bwh.harvard.edu/pph2>) with the HumVar-trained model, the SIFT algorithm (Sorting Intolerant From Tolerant; <http://sift.bii.a-star.edu.sg>) (Kumar, Henikoff, & Ng, 2009), and the Variation Taster online predictive tool (<http://www.mutat.iontaster.org>) (Desmet et al., 2009). Splicing defects were evaluated using the Human Splicing Finder online software version 3 (<http://www.umd.be/HSF3/HSF.html>) [14]. The laboratory methods used for genotyping, the bioinformatics pipeline, variants prioritization, and Sanger validation of potential pathogenic variants selected have previously been described (Manara et al., 2019) and they follow the criteria of the American College of Medical Genetics and Genomics (ACMG) Standards and Guidelines (Richards et al., 2015). Segregation of variants with possible clinical significance was performed in family members by direct sequencing.

2.3 | Immunoprecipitation, processing, and activity assay

293T cells were transfected with plasmid expression vectors encoding V5-tagged human ADAMTS3 (ADAMTS3-V5-H6) (Jeltsch et al., 2014) and empty vectors. Conditioned media were immunoprecipitated with VEGF-C-NT/Fc (Jha et al., 2017) or VEGFR-1/Fc (Mäkinen et al., 2001) using protein A sepharose (PAS, GE Healthcare). The precipitated proteins were subjected to SDS-PAGE, transferred to PVDF membrane, followed by ECL detection with anti-V5 antibody (Invitrogen, #46-0705, 1:6000). The Ser65Arg VEGF-C mutant was generated by amplifying the coding sequence of full length human *VEGF-C* (*hVEGF-C*) in a pCDNA3.1-zeo vector according to the QuikChange II XL Site-Directed Mutagenesis protocol (Stratagene), using the primer pair 5'-gttacggctgtgtccagggtagatgaactcatgact-3' and 5'-agtcgatgagttcatctaccctggacacagaccgtaac-3'. The resulting mutant construct was sequenced to confirm the presence of the mutation using the primers 5'-tccggactcgacctctcgg-3' and 5'-ctctctgtcctgagttgagg-3'.

For the co-immunoprecipitation of VEGF-C with ADAMTS3, 293T cells were transfected with DNA expression vectors encoding for wild-type human *VEGF-C* (VEGF-C-WT), mutant human *VEGF-C* (VEGF-C-MUT), *ADAMTS3-V5-H6* (Jeltsch et al., 2014) StrepIII-tagged human *CCBE1* (CCBE1-StrIII (Jeltsch et al., 2014), and empty vector. After 48 hr, the supernatants were harvested and mixed. After 36 hr at 4°C, immunoprecipitation was performed with anti-VEGF-C antiserum (Jha et al., 2017) for 24 hr at 4°C. After washing, the samples were boiled in reducing Laemmli buffer and resolved in 10% SDS-PAGE

gels (for ADAMTS3 detection) or 4%–20% gradient gels (for VEGF-C detection) followed by transfer to PVDF membrane and detection with anti-ADAMTS3 antibody (Santa Cruz, sc-21486, 1:700) or with anti-VEGF-C antibody (Santa Cruz, sc-374628, 1:500). To assess VEGF-C processing and activity, 293T cells were transfected with expression vectors encoding for *CCBE1-StrIII* (Jha et al., 2017) *VEGF-C-WT*, *VEGF-C-MUT*, *ADAMTS3-V5-H6* (Jeltsch et al., 2014), or empty vector. For metabolic labeling experiments, the medium was changed after 24 hr to labeling medium (8 μ l [35S]cysteine/[35S]methionine EasyTag label/ml medium; PerkinElmer). After 48 hr of labeling, the supernatants were harvested and mixed. The mixtures were immunoprecipitated with VEGFR-3(D1-7)/Fc fusion protein and resolved in a 4%–20% gradient gel. The dried gel was analyzed by phosphoimaging, and scanned using a Typhoon FLA 7000 (GE Healthcare).

2.4 | Statistical analysis

The intensity of Western blot bands was quantified using the ImageJ software, analyzed using GraphPad Prism statistical analysis software (Version 7), and presented as means \pm SD. The comparison of two means was performed using unpaired Student's *t* test, and considered significant at $p < .05$.

3 | RESULTS

The proband, a 10 years old female, was discovered as the only subject with clinical manifestations of Milroy-like lymphedema of the right lower limb in a family with living parents and two apparently healthy brothers. The family history was negative for other diseases, and there were no cases of lymphatic pathology impairment in the genealogical tree. Medical history included natural birth at term of heterozygous twins. Neonatal jaundice and fluctuating swelling of the right lower limb were reported since 4 weeks of age; despite constant use of compression garments, the patient presented with a painless inguavescent stage 3 lymphedema of the right lower limb (Figure 1a), particularly affecting the dorsum of the feet and extending to the lower limb, typical for Milroy's disease. No varicose veins or signs of lymphangitis were ever observed. To better investigate the clinical and genetic profile of the disease, clinical and lymphoscintigraphic examination was carried out on the proband and all other family members. In addition, genetic screening of known lymphedema associated genes and their segregation in the family was performed.

The diagnosis of lymphedema was confirmed by three-phase anterior lymphoscintigraphy (Figure 1b and Table 1). Phases 0–3 showed a dramatically reduced clearance of the tracer from the injection point in the right limb and only slight clearance in the left limb. In phase 1, dynamic

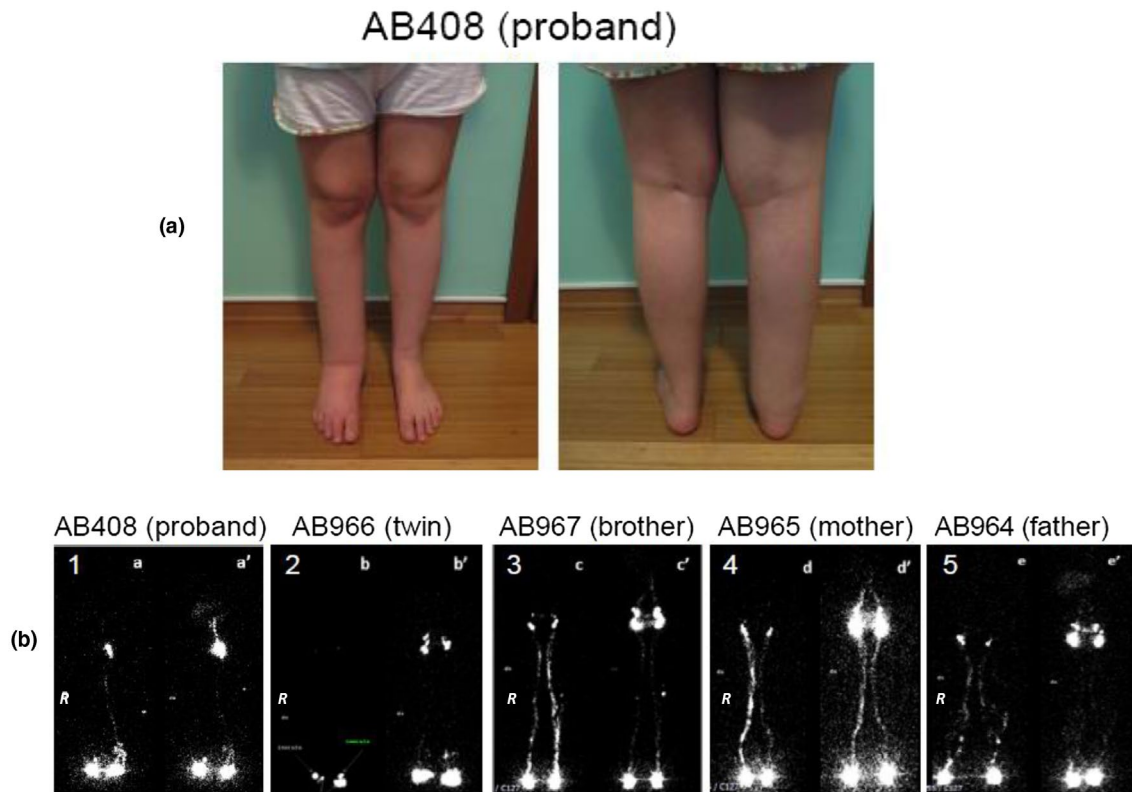


FIGURE 1 (A). Images of the lower limbs of the 10-year-old proband (AB408) show high degree of swelling at the right limb, particularly affecting the dorsum of the feet and the lower limb, clearly demonstrating the presence of lymphedema. (B). Anterior bilateral lymphoscintigraphy of the lower limbs of proband (panel 1), her twin brother (panel 2), the older brother (panel 3), the mother (panel 4), and the father (panel 5) attained at phase 1 (images a, b, c, d, e) and at phase 3 (images a', b', c', d', e'), respectively

TABLE 1 Lymphoscintigraphy results. Results of lymphoscintigraphy analysis and corresponding clinical scores for the right (RL) and left (LL) limbs in each member of the investigated family. Based on standard lymphoscintigraphy scores, lower limbs were considered normal (7–11), mildly altered (12–17), and much altered (18–27)

ID	Family grade	Gender	Age	Lymphoscintigraphy score	Lymphatic drainage score	Clinical manifestation
AB408	Proband	Female	10	RL: 19 LL: 11	RL: severe LL: normal	RL: edematous LL: no edema
AB964	Father	Male	54	RL: 13 LL: 15	RL: mild LL: moderate	RL: no edema LL: no edema
AB965	Mother	Female	47	RL: 9 LL: 10	RL: normal LL: normal	RL: no edema LL: no edema
AB967	Twin Brother	Male	10	RL: 14 LL: 17	RL: mild LL: severe	RL: no edema LL: no edema
AB966	Brother	Male	23	RL: 11 LL: 11	RL: normal LL: normal	RL: no edema LL: no edema

inguinal scanning did not show any tracer in the right inguinal lymph nodes, whereas the tracer reached the left inguinal lymph node, suggesting either hypoplastic lymphatic ducts and/or aplasia/hypoplasia of the lymph nodes. In phase 2, during moderate exercise, the images did not show any tracer on the right side, whereas a moderate increase in tracer was evident in the left groin. In phase 3, whole-body lymphoscintigrams, recorded after 45 min of

moderately intense bicycle ergometer exercise followed by 1 hr of walking, indicated dermal back-flow but no lymphatic drainage of the right lower limb. Analysis of the left side revealed normal visualization of superficial, deep, and inguinal lymph nodes and weak activity in abdominal and lumbar lymph nodes.

Lymphoscintigraphy of the proband's twin brother (AB966) (Figure 1b) indicated reduced clearance from

the point of injection bilaterally in phases 0–3. A dynamic scan of the groins at rest showed tracer in right and left lymph nodes in phase 1 and, in phase 2, a rapid increase in lymphatic drainage bilaterally after moderate exercise. In phase 3, whole-body scan performed at 45 min after injection showed few inguinal lymph nodes on the right side. Dermal back-flow was evident in the medial third of the right leg, but was attenuated in the second body scan, after 1 hr of walking. Hence, in spite of the lack of clinical manifestations, the patient showed a bilateral delay in lymphatic drainage, which was slight in the right leg and severe in the left leg.

Lymphoscintigraphy of the proband's elder brother (Figure 1b, AB967) did not reveal any relevant impairment of lower limb lymphatic drainage in the three phases of the examination. None of the two boys presented hydrocele or varicose veins.

Lymphoscintigraphy of the mother (Figure 1b, AB965) showed a normal bilateral tracer clearance from the point of injection in phases 0–3, right and left inguinal lymph node activity in phase 1, progressive bilateral increase in lymph drainage during moderate exercise in phase 2, and normal visualization of superficial lymphatic circulation and of inguinal lymph nodes on both sides in whole-body lymphoscintigrams (phase 3). Lymphoscintigraphy of the father (Figure 1b, AB964) showed bilaterally reduced tracer clearance in phases 0–3, no left or right inguinal lymph node activity in phase 1 dynamic scan, and a rapid increase in lymph drainage on the right and only a minimal increment on the left in phase 2 during moderately intense exercise. Finally, the whole-body lymphoscintigram scans in phase 3 showed a bilateral delay in lymph drainage, slight on the right and moderate on the left.

To investigate the molecular bases of the proband disease, we performed a NGS-based genetic testing for a panel of genes associated with most known forms of Mendelian lymphedema. The analysis revealed the presence of two heterozygous variations in the *VEGF-C*: (a) a novel p.(Ser65Arg) mutation, never described before and of which no frequencies are available in any questioned database and (b) c.148-3_148-2delCA (Figure 2b,c) which was recently demonstrated as pathogenic (Fastré et al., 2018) since it affects splicing of the *VEGF-C* mRNA, leading to the skipping of exons 2 and 3 with the consequent deletion of 135 of the 419 amino acids of the protein (Fastré et al., 2018).

In silico prediction software Polyphen2, SIFT, and Mutation Taster classified the novel Ser65Arg missense variant as “probably damaging,” “deleterious,” and “disease causing”, respectively.

The results of the family segregation study performed to determine whether the variations were in *cis* (on the same allele) or in *trans* (on different alleles) configuration revealed that the variants in the proband are biallelic. Indeed,

the father and the proband's twin brother (both with subclinical signs of lymphedema, Figure 1b,c) are heterozygous for p.(Ser65Arg), the mother (no altered phenotype) carries the c.148-3_148-2delCA, whereas the older healthy brother did not inherit either variation of the *VEGF-C* from his parents (Figure 2a).

With the aim to investigate the role of the novel variant, we performed in vitro assays. Since the p.(Ser65Arg) mutation is in the N-terminal propeptide of VEGF-C (VEGF-C-NT), to exclude the presence of subtle differences in protein activity between the wild-type and mutant protein, we first analyzed the interaction between VEGF-C-NT and ADAMTS3 in an immunoprecipitation assay. Immunoblot analysis revealed a strong interaction between an Fc-tagged version of the N-terminal domain of VEGF-C (VEGF-C-NT/Fc) and ADAMTS3 (Figure 3a, lane 1). We next speculated that the Ser65Arg mutation might influence the binding of VEGF-C to ADAMTS3. To test this interaction, we mixed conditioned media from 293T cells separately transfected with *CCBE1*, *ADAMTS3*, and wild-type *VEGF-C* (*VEGF-C-WT*) or mutant *VEGF-C* (*VEGF-C-MUT*), where *CCBE1* was used in ratio of 1:16 in the final reaction volume. The expression of VEGF-C-WT and VEGF-C-MUT, *CCBE1*, and *ADAMTS3* in 293T cells was confirmed by Western blotting (Figure 4a–c). We observed a strong interaction between *ADAMTS3* and VEGF-C-WT while the binding of *ADAMTS3* to VEGF-C-MUT was clearly reduced (Figure 3b, compare lanes 1 and 3, quantification in Figure 3c). Based on our previous studies [17], we reasoned that high concentrations of *CCBE1* and/or *ADAMTS3* could mask differences in the efficiency of VEGF-C activation. Assuming that differences would become more apparent when *CCBE1* and/or *ADAMTS3* availability were rate-limiting for VEGF-C activation, we performed the assay by mixing different amounts of conditioned media from cells transformed separately with expression vectors for *CCBE1*, *ADAMTS3*, and *VEGF-C-WT* or *VEGF-C-MUT*. When using a ratio of *CCBE1*-conditioned to *ADAMTS3*-conditioned to VEGF-C-conditioned media of 1:5:5, we observed a clearer reduction in the processing of VEGF-C-MUT (Figure 3d).

4 | DISCUSSION

In this report, we describe an interesting case of a patient affected by Milroy-like disease that is associated with biallelic variants in *VEGF-C*, a gene that has been previously associated to Milroy-like disease consistently with an autosomal dominant model of inheritance. The variants so far reported in just five different families are predicted to form dysfunctional proteins (Balboa-Beltran et al., 2014; Fastré et al., 2018; Gordon et al., 2013a; Nadarajah et al., 2018) and studies in animal models suggest that the disease is caused by haploinsufficiency (Gordon et al., 2013b).

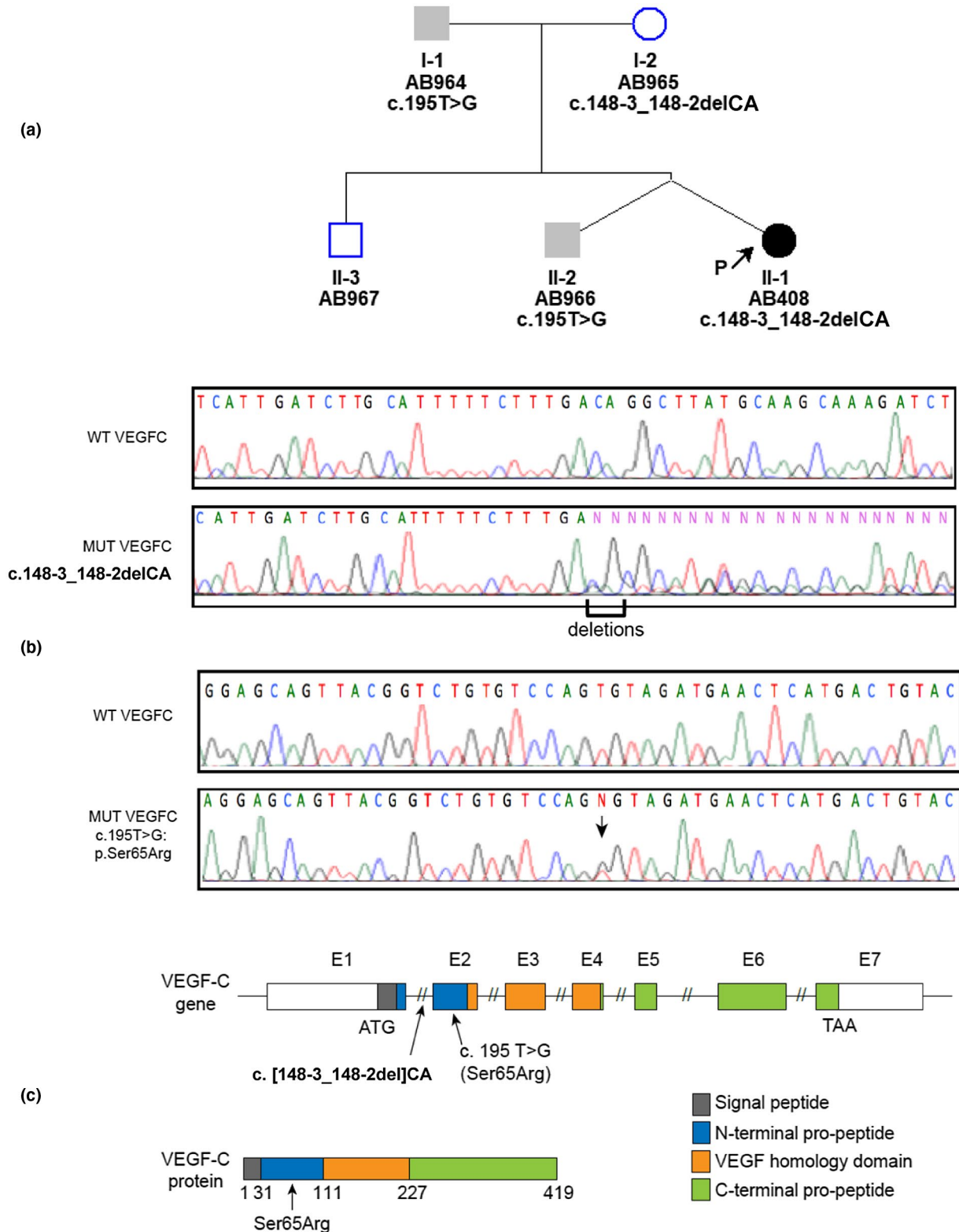


FIGURE 2 (a) Genetic pedigree illustrating the sequencing results performed in all family members. The genetic analysis identified the presence of two heterozygous variants in the *VEGF-C* (NM_005429.5), c.195T>G, and c.148-3_148-2delCA, that are in a *trans* configuration in the proband (arrow), the only family member that manifests the lymphedema with the most severe phenotype (black). Subclinical manifestations are illustrated in grey. (b) Electropherogram of a control (WT) and of the proband revealing the deletion and mutation at base position 148 and 195, respectively. (c) Schematic representation of the *VEGF-C* and protein sequences, and location of the newly discovered gene deletion (c.148-3_148-2delCA) and mutation (c.195T>G (Ser65Arg))

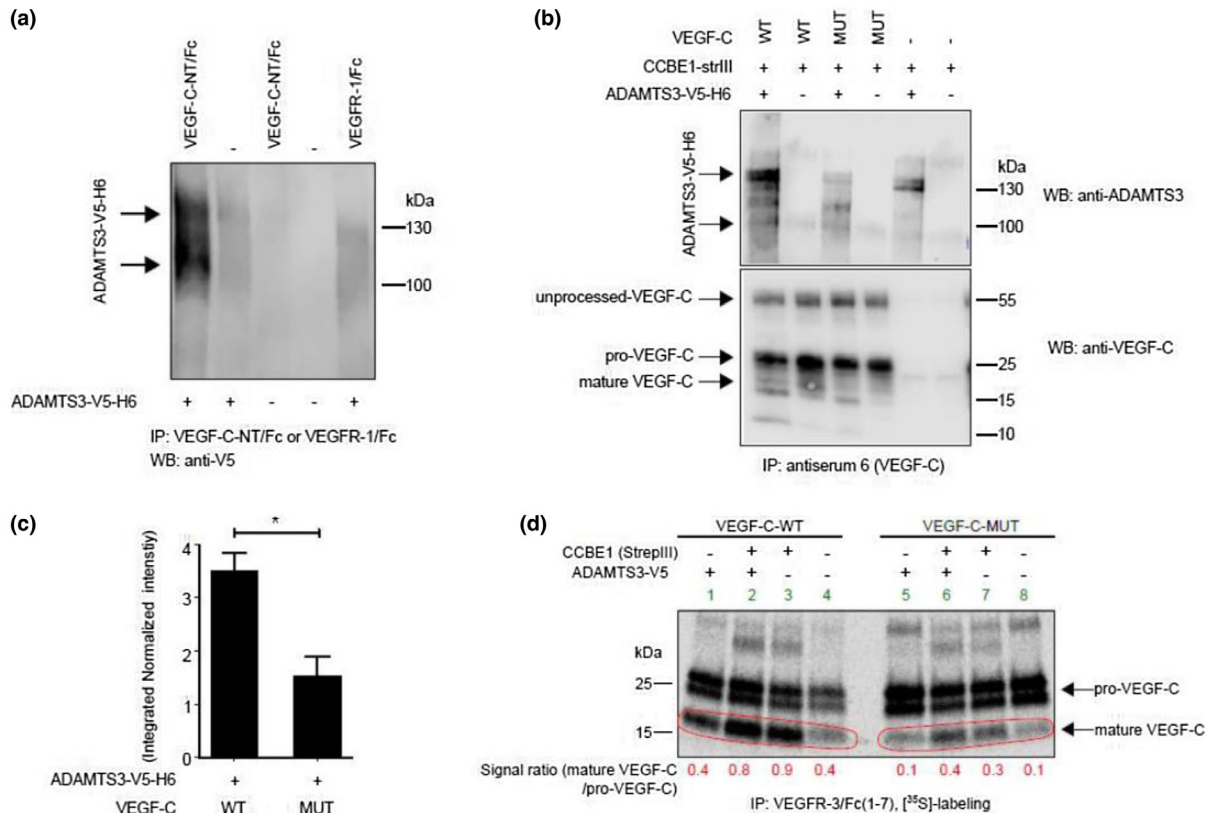


FIGURE 3 (a) ADAMTS3 binds to the N-terminal domain of VEGF-C (VEGF-C-NT/Fc). Conditioned media from ADAMTS3-V5-H6 transfected cells were immunoprecipitated with VEGF-C-NT/Fc fusion protein. ADAMTS3 coprecipitates with VEGF-C-NT/Fc. VEGFR-1/Fc was used as control for the Fc part of fusion protein. Notably, a small amount of ADAMTS3 nonspecifically binds to protein A sepharose (PAS, lane 2). (b) The Ser65Arg mutation in VEGF-C interferes with ADAMTS3 binding. Conditioned media from CCBE1, ADAMTS3, VEGF-C-WT, and VEGF-C-MUT transfected 293T cells were co-incubated with CCBE1 in the ratio of 1:16 and other media at equal amounts for 36 hr at 4°C. The mix was then immunoprecipitated with antiserum 6. Compared to VEGF-C-MUT, VEGF-C-WT bound strongly to ADAMTS3-V5-H6 (upper panel, lane 1 vs. lane 3). Note that small amounts of ADAMTS3 bind nonspecifically to PAS (upper panel, lane 5). The figure shows two Western blots from parallel runs of the same sample. (c) The graph shows densitometric quantification of Western blot band intensity (mean ± SD; *n* = 3). **p* < .05. (d) Small amounts of CCBE1 affect processing of the VEGF-C Ser65Arg mutant. Conditioned media from CCBE1 and ADAMTS3 transfected cells were mixed with [³⁵S]-labeled VEGF-C-WT or VEGF-C-MUT conditioned media (CCBE1:VEGF-C:ADAMTS3 ratio 1:5:5). For wild-type VEGF-C, small amounts of ADAMTS3 and/or CCBE1 result in appreciable generation of mature VEGF-C, whereas the same amounts of CCBE1 and ADAMTS3 have little or no effect on VEGF-C-MUT (compare red boxed mature VEGF-C). The signal ratio of mature VEGF-C to pro-VEGF-C is shown in red

Here, the variants identified in the proband are a deletion (c.148-3_148-2delCA) recently described as causative of lymphedema by Fastrè et al, although with 50% penetrance (Fastrè et al., 2018) and a novel c.195T>G variant, never described before and of which no frequencies are available in any questioned database. The deletion was inherited from the mother, while the novel variant has been transmitted by the father to both the proband and her twin brother.

In an attempt to disclose the role of the new identified variant in the pathogenesis of the disease, we clinically investigated the actual morphofunctional behavior of the lymphatic district of the lower limbs of the family members by performing individual lymphoscintigraphy. Hence, we may conclude

that the proband showed a clear bilateral delay of foot-to-inguinal region dye distribution, when compared to a normal control, thus suggesting an intrinsic defect of the lymphatic propulsive machinery at rest. Indeed, normal lymphatics are equipped with intraluminal valves between lymphangions and with the so-called “anchoring filaments”, macromolecular fibrils that connect the wall of the lymphatic vessels to the extracellular macromolecules and the skeletal muscles, thus allowing the transmission of forces to the lymphatic wall upon tissue displacement and muscle contraction. The lack of increment of dye distribution upon exercise in both limbs in the proband strongly suggests that these lymphatics not only lack their normal intrinsic contractility but are also affected by structural-morphological defects or even partial absence

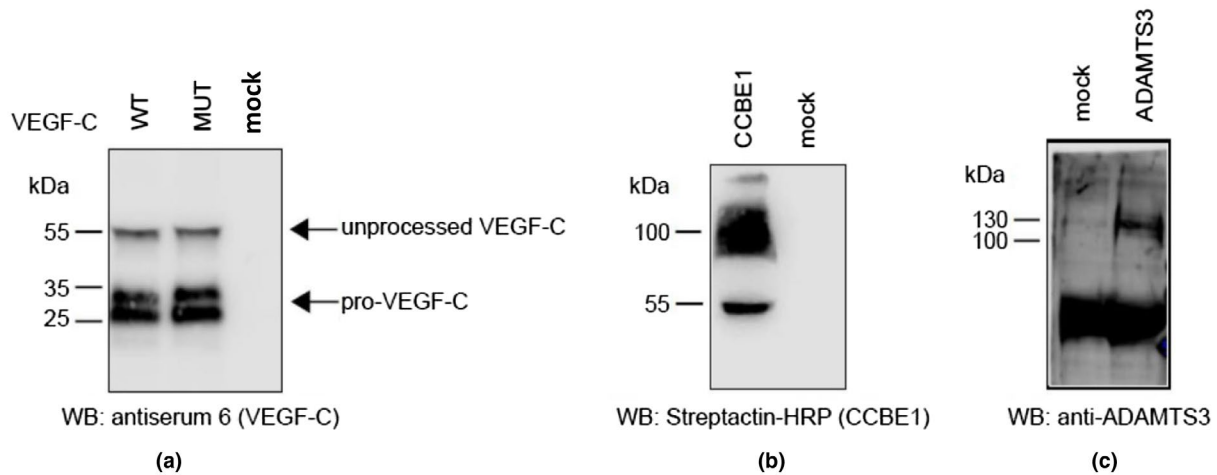


FIGURE 4 (a) VEGF-C-MUT is normally expressed when transfected in 293T cells and the expression pattern is similar to VEGF-C-WT when analyzed by Western blotting. The expression of (b) CCBE1 and (c) ADAMTS3 in 293T cells was detected by streptactin-HRP (iba, #2-1502-001, 1:100,000) and anti-ADAMTS3 (Santa Cruz, sc-21486, 1:700), respectively

of either the unidirectional intraluminal valves and/or of the fibrous molecular links between the outer surface of the lymphatic wall and the surrounding tissue fibers.

Lymphoscintigraphic evidences for the limbs of the twin brother and father show a significantly reduced foot-to-inguinal dye distribution after mild exercise, suggesting again that the lower limbs lymphatic trunks did not benefit of the extrinsic propulsive contribution. However, at least at this stage of development, no sign of clinical lymphedema has been observed yet. Indeed, in line with the incomplete penetrance showed by the Fastrè et al (Fastrè et al., 2018), the proband's mother carrying the c.148-3_148-2delCA variation had no lymphoscintigraphic alterations or signs of lymphedema.

Given the role of the novel variant in our family, we performed an in vitro study with the aim to explain the phenotype of the carriers of the VEGF-C Ser65Arg variant. Our findings showed that the proteolytic processing of the mutant is decreased in comparison with wild-type VEGF-C. ADAMTS3 interacts directly with the N-terminal propeptide of VEGF-C (VEGF-C-NT), and the Ser65Arg mutation alters the ability of VEGF-C to interact with ADAMTS3, thus reducing the processing and therefore the activation of VEGF-C. Together, our findings support the role of the mutant protein in lymphedema, since both the twin brother and the father have reduced lymphatic drainage, although not yet showing symptoms of the disease.

Given this, the interpretation of the role of these two variants in the proband remains to be clarified. Milroy-like disease has been described as transferred by variant in autosomal dominant state. However, we cannot exclude that they both have a pathogenic effect. Thus, based on our clinical and experimental findings, we propose that the Ser65Arg mutation affects VEGF-C processing and thus may contribute to lymphedema. The arguments in favor of the role of the Ser65Arg variant are: (a) it is a rare variant; (b) in silico

prediction is supportive of a pathogenic role for the variant; (c) in vitro study confirmed a role in the reduction of activity of VEGF-C; (d) the variant co-segregate with a subclinical phenotype in the family. Instead, the variant c.148-3_148-2delCA has been shown elsewhere to be causative of lymphedema due to exon 2 and 3 skipping with the consequent deletion of 135 of the 419 amino acids of the protein. Moreover, we can hypothesize that the overt phenotype in the proband is due to the additive inactivation of VEGF-C due to the hypomorphic VEGF-C missense variant in a haploinsufficiency setting. This is not new in lymphedema; in particular, the work of Ghalamkarpour et al. described that VEGFR-3 lymphedema, usually associated with a dominant transmission, can be caused also by an hypomorphic homozygous VEGFR-3 mutation (p.Ala855Thr) that impact the functioning of the receptor to a lesser extent than a dominantly inherited VEGFR-3 mutation (Ghalamkarpour et al., 2009). In addition, also in VEGF-C animals model, a residual activity of an hypomorphic *vegfc* allele has been documented by Vivien et al., which showed in zebrafish that hypomorphic *vegfc* allele in association with a loss of function of *vegfd* could still retain few lymphatic vessels on the bulbous arteriosus while this was not possible in a double mutant line (Vivien et al., 2019). In conclusion, the present data may provide an important contribution to unveil the etiology of Milroy-like lymphedema and improve the possible inheritance pathway associated to VEGF-C. Indeed, this study suggests that polymorphism on the other allele might modify the illness presentation explaining the huge variation of penetrance observed in families with VEGF-C mutations.

ACKNOWLEDGMENTS

This work was supported by: Hepatobiliary Surgery Department of IRCCS Ospedale San Raffaele; the Academy of Finland (award numbers 303778, 273612,

265982) and the Finnish Foundation for Cardiovascular Research (grant number 160038); the Jane and Aatos Erkko Foundation, European Research Council (ERC) under the European Union's Horizon 2020 research and innovation programme under grant agreement No 743155; the Wihuri Research Institute, maintained by the Jenny and Antti Wihuri Foundation; the Academy of Finland Centre of Excellence Program 2014–2019 (307366), the Novo Nordisk Foundation and the Sigrid Jusélius Foundation. The Integrated Life Science Doctoral Program supported the salary of SKJ.

CONFLICT OF INTEREST

Authors declare no competing interests

AUTHOR CONTRIBUTION

Sylvain Mukenge planned, developed, and coordinated the whole study; wrote, revised, and submitted the manuscript; Sawan Kumar Jha performed the biochemical and genetic analysis; Marco Catena provided a critical review of the bibliography and revised the manuscript; Elena Manara performed the genetic analysis and revised the manuscript, Veli-Matti Leppänen performed the genetic and biochemical analysis; Elisa Lenti provided a critical review of the bibliography and revised the manuscript; Daniela Negrini discussed and analyzed the functional data; wrote, revised, and submitted the manuscript; Matteo Bertelli analyzed patients samples and performed the genetic diagnosis; Andrea Brendolan contributed with analysis and helped in writing the manuscript; Michael Jeltsch coordinated and supervised the genetic biochemical analysis and discussed the data; Luca Aldrighetti provided financial support to the study and discussed the data.

DATA AVAILABILITY STATEMENT

Data available on request due to privacy/ethical restrictions

ORCID

Sylvain Mukenge  <https://orcid.org/0000-0003-1500-1914>

Elena Manara  <https://orcid.org/0000-0002-1176-3359>

Daniela Negrini  <https://orcid.org/0000-0001-8048-1366>

REFERENCES

- Alitalo, K., Tammela, T., & Petrova, T. V. (2005). Lymphangiogenesis in development and human disease. *Nature*, *438*(7070), 946–953. <https://doi.org/10.1038/nature04480>
- Balboa-Beltran, E., Fernández-Seara, M. J., Pérez-Muñuzuri, A., Lago, R., García-Magán, C., Couce, M. L., ... Barros, F. (2014). A novel stop mutation in the vascular endothelial growth factor-C gene (VEGFC) results in Milroy-like disease. *Journal of Medical Genetics*, *51*(7), 475–478. <https://doi.org/10.1136/jmedgenet-2013-102020>
- Bourgeois, P., Leduc, O., Belgrado, J.-P., & Leduc, A. (2009). Scintigraphic investigations of the superficial lymphatic system: Quantitative differences between intradermal and subcutaneous injections. *Nuclear Medicine Communications*, *30*(4), 270–274. <https://doi.org/10.1097/MNM.0b013e32831bec4d>
- Bui, H. M., Enis, D., Robciuc, M. R., Nurmi, H. J., Cohen, J., Chen, M., ... Kahn, M. L. (2016). Proteolytic activation defines distinct lymphangiogenic mechanisms for VEGFC and VEGFD. *The Journal of Clinical Investigation*, *126*(6), 2167–2180. <https://doi.org/10.1172/JCI83967>
- Connell, F. C., Ostergaard, P., Carver, C., Brice, G., Williams, N., Mansour, S., ... Jeffery, S. (2009). Analysis of the coding regions of VEGFR3 and VEGFC in Milroy disease and other primary lymphoedemas. *Human Genetics*, *124*(6), 625–631. <https://doi.org/10.1007/s00439-008-0586-5>
- Desmet, F.-O., Hamroun, D., Lalonde, M., Collod-Bérout, G., Claustres, M., & Bérout, C. (2009). Human Splicing Finder: An online bioinformatics tool to predict splicing signals. *Nucleic Acids Research*, *37*(9), e67. <https://doi.org/10.1093/nar/gkp215>
- Fastré, E., Lanteigne, L.-E., Helaers, R., Giacalone, G., Revencu, N., Dionysiou, D., ... Vikkula, M. (2018). Splice-site mutations in VEGFC cause loss of function and Nonne-Milroy-like primary lymphedema. *Clinical Genetics*, *94*(1), 179–181. <https://doi.org/10.1111/cge.13204>
- Ghalamkarpour, A., Holnthoner, W., Saharinen, P., Boon, L. M., Mulliken, J. B., Alitalo, K., & Vikkula, M. (2009). Recessive primary congenital lymphoedema caused by a VEGFR3 mutation. *Journal of Medical Genetics*, *46*(6), 399–404. <https://doi.org/10.1136/jmg.2008.064469>
- Gordon, K., Schulte, D., Brice, G., Simpson, M. A., Roukens, M. G., van Impel, A., ... Ostergaard, P. (2013a). Mutation in vascular endothelial growth factor-C, a ligand for vascular endothelial growth factor receptor-3, is associated with autosomal dominant milroy-like primary lymphedema. *Circulation Research*, *112*(6), 956–960. <https://doi.org/10.1161/CIRCRESAHA.113.300350>
- Gordon, K., Schulte, D., Brice, G., Simpson, M. A., Roukens, M. G., van Impel, A., ... Ostergaard, P. (2013b). Mutation in vascular endothelial growth factor-C, a ligand for vascular endothelial growth factor receptor-3, is associated with autosomal dominant Milroy-like primary lymphedema. *Circulation Research*, *112*(6), 956–960. <https://doi.org/10.1161/CIRCRESAHA.113.300350>
- Jeltsch, M., Jha, S. K., Tvorogov, D., Anisimov, A., Leppänen, V.-M., Holopainen, T., ... Alitalo, K. (2014). CCBE1 enhances lymphangiogenesis via A disintegrin and metalloprotease with thrombospondin motifs-3-mediated vascular endothelial growth factor-C activation. *Circulation*, *129*(19), 1962–1971. <https://doi.org/10.1161/CIRCULATIONAHA.113.002779>
- Jha, S. K., Rauniyar, K., Karpanen, T., Leppänen, V.-M., Brouillard, P., Vikkula, M., ... Jeltsch, M. (2017). Efficient activation of the lymphangiogenic growth factor VEGF-C requires the C-terminal domain of VEGF-C and the N-terminal domain of CCBE1. *Scientific Reports*, *7*(1), 4916. <https://doi.org/10.1038/s41598-017-04982-1>
- Kumar, P., Henikoff, S., & Ng, P. C. (2009). Predicting the effects of coding non-synonymous variants on protein function using the SIFT algorithm. *Nature Protocols*, *4*(7), 1073–1081. <https://doi.org/10.1038/nprot.2009.86>
- Mäkinen, T., Jussila, L., Veikkola, T., Karpanen, T., Kettunen, M. I., Pulkkanen, K. J., ... Alitalo, K. (2001). Inhibition of lymphangiogenesis with resulting lymphedema in transgenic mice expressing soluble VEGF receptor-3. *Nature Medicine*, *7*(2), 199–205. <https://doi.org/10.1038/84651>

- Manara, E., Paolacci, S., D'Esposito, F., Abeshi, A., Ziccardi, L., Falsini, B., ... Bertelli, M. (2019). Mutation profile of BBS genes in patients with Bardet-Biedl syndrome: An Italian study. *Italian Journal of Pediatrics*, *45*(1), 72. <https://doi.org/10.1186/s13052-019-0659-1>
- Nadarajah, N., Schulte, D., McConnell, V., Martin-Almedina, S., Karapouliou, C., Mortimer, P. S., ... Ostergaard, P. (2018). A novel splice-site mutation in VEGFC is associated with congenital primary lymphoedema of Gordon. *International Journal of Molecular Sciences*, *19*(8), 2259. <https://doi.org/10.3390/ijms19082259>
- Richards, S., Aziz, N., Bale, S., Bick, D., Das, S., Gastier-Foster, J., ... Rehm, H. L. (2015). Standards and guidelines for the interpretation of sequence variants: A joint consensus recommendation of the American College of Medical Genetics and Genomics and the Association for Molecular Pathology. *Genetics in Medicine*, *17*(5), 405–423. <https://doi.org/10.1038/gim.2015.30>
- Rockson, S. G. (2006). Lymphedema. *Current Treatment Options in Cardiovascular Medicine*, *8*(2), 129–136. <https://doi.org/10.1007/s11936-006-0005-y>
- Tammela, T., & Alitalo, K. (2010). Lymphangiogenesis: Molecular mechanisms and future promise. *Cell*, *140*(4), 460–476. <https://doi.org/10.1016/j.cell.2010.01.045>
- Vivien, C. J., Pichol-thievend, C., Sim, C. B., Smith, J. B., Bower, N. I., Hogan, B. M., & Porrello, E. R. (2019). Vegfc/d-dependent regulation of the lymphatic vasculature during cardiac regeneration is influenced by injury context. *NPJ Regenerative Medicine*, *4*(1), 18–32. <https://doi.org/10.1038/s41536-019-0079-2>

How to cite this article: Mukenge S, Jha SK, Catena M, et al. Investigation on the role of biallelic variants in *VEGF-C* found in a patient affected by Milroy-like lymphedema. *Mol Genet Genomic Med*. 2020;8:e1389. <https://doi.org/10.1002/mgg3.1389>