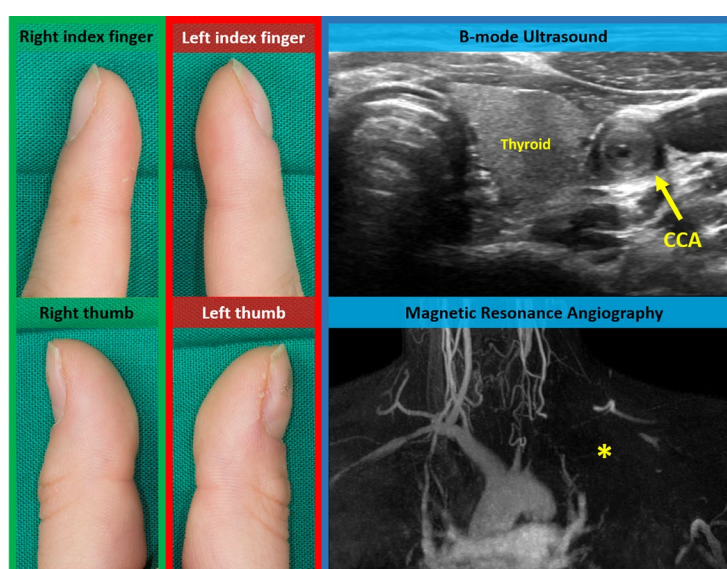



42. Pot C, Jin H, Awasthi A, Liu SM, Lai CY, Madan R, et al. Cutting edge: IL-27 induces the transcription factor c-Maf, cytokine IL-21, and the costimulatory receptor ICOS that coordinately act together to promote differentiation of IL-10-producing Tr1 cells. *J Immunol* 2009;183:797–801.
43. Kimura D, Miyakoda M, Kimura K, Honma K, Hara H, Yoshida H, et al. Interleukin-27-producing CD4+ T cells regulate protective immunity during malaria parasite infection. *Immunity* 2016;44:672–82.
44. Verstappen GM, Corneth OB, Bootsma H, Kroese FG. Th17 cells in primary Sjögren's syndrome: pathogenicity and plasticity. *J Autoimmun* 2018;87:16–25.
45. Nezos A, Gravani F, Tassidou A, Kapsogeorgou EK, Voulgarelis M, Koutsilieris M, et al. Type I and II interferon signatures in Sjögren's syndrome pathogenesis: contributions in distinct clinical phenotypes and Sjögren's related lymphomagenesis. *J Autoimmun* 2015;63:47–58.

DOI 10.1002/art.41313

Clinical Images: Unilateral Hippocratic fingers and macaroni sign

The patient, a 17-year-old girl, presented to the emergency department with a 2-week history of pain in her left arm and swelling of the fingers on her left hand. Her history was otherwise unremarkable. Notably, there were no symptoms of systemic inflammation (night sweats, fever, or weight loss). Clinical examination of the left arm revealed absence of pulses. Blood pressure was low (systolic 50 mm Hg) when measured on the left arm and elevated (170/100 mm Hg) when measured on the right arm. Physical examination revealed finger clubbing (Hippocratic fingers) only on the left hand. The C-reactive protein level was mildly elevated (1.8 mg/dl [normal <0.5]). Color duplex sonography showed filiform long-segment stenosis in the left common carotid artery (CCA) with marked concentric intimal thickening (arrow). This sonographic feature, known as macaroni sign, confirmed the diagnosis of Takayasu arteritis (TAK). Ultrasound and magnetic resonance angiography revealed an occlusion of the left subclavian and axillary artery (asterisk) as an underlying cause of finger clubbing on the left hand. Further imaging also revealed significant bilateral renal artery stenosis causing renovascular hypertension. Immunosuppressive and antihypertensive treatment was initiated. Subsequently, renal artery stenosis was treated with stent angioplasty. Bilateral clubbing can be seen in patients with severe cardiopulmonary disease, classically in patients with congenital cyanotic heart disease. Unilateral clubbing is a very rare presentation of TAK, resulting from severe chronic upper limb ischemia (1–3).

1. Kaditis AG, Nelson AM, Driscoll DJ. Takayasu's arteritis presenting with unilateral digital clubbing. *J Rheumatol* 1995;22:2346–8.
2. Ishikawa M, Okada J, Kondo H. Takayasu's arteritis with transient clubbed finger. *Clin Exp Rheumatol* 1999;17:629–30.
3. Çivilibal M, Selçuk Duru N, Doğdu G, Elevli M, Ayta S. A Takayasu's arteritis case with unilateral digital clubbing. *Turk J Rheumatol* 2011;26:163–6.

Christian Lottspeich, MD 
 Michael Czihal, MD
 Medical Clinic and Policlinic IV
 Hospital of the Ludwig-Maximilians-University
 Annette Friederike Jansson, MD
 Ava Oberlack, MD
 Dr. von Hauner Children's Hospital
 Hospital of the Ludwig-Maximilians-University
 Munich, Germany