



The Egyptian Cardiothoracic Surgeon

Vol. 2, No. 4, 134 - 140

Original Article

Sternal healing after bilateral internal mammary arteries use for Coronary artery bypass grafting in diabetic Patients; short-term results

Islam Moheb Ibrahim¹, Ahmed Labib Dokhan¹, Yahia Balbaa Anwar Balbaa², Ibrahim Mohammed Khalil¹, Mohammed Ahmed El-Hag-Aly¹

¹ Department of Cardiothoracic Surgery, Faculty of Medicine, Menoufia University, Menoufia, Egypt

² Department of Cardiothoracic Surgery, Faculty of Medicine, Cairo University, Giza, Egypt

Abstract

Background: Bilateral internal mammary artery (BIMA) use may improve long-term outcomes after coronary artery bypass grafting (CABG); however, the risk of infection is high. Skeletonization of the internal mammary may decrease the risk of infection, especially in patients with diabetes. Our study aimed at evaluation of sternal healing in diabetic patients with different techniques of bilateral internal mammary artery harvesting.

Methods: This prospective randomized study included 200 diabetic patients who underwent CABG using BIMA between 2017 and 2019. We divided patients into two groups; Group A had skeletonization of both internal mammary arteries, and Group B had pedicled left mammary and skeletonized right mammary. Patients were observed for three months, post-operatively for any sternal wound problems.

Results: There was no significant difference regarding the baseline variables. Type I diabetes mellitus was present in 25% in group A (n= 24) and 13.64% in group B (n= 12) (p= 0.324). There was no difference in harvest time between groups (83 ±4 vs. 81 ±3 minutes in group A vs. B, respectively. P= 0.1). The mean number of grafts was 3± 0.5 in Group A and 3± 0.6 in Group B (p= 0.8). Postoperative drainage was 402.9 ± 174.1 ml in Group A vs. 387.2 ± 153.6 ml in Group B (p= 0.474). The duration of ICU stay did not differ significantly between groups (2± 0.7 in Group A vs. 2± 0.5 in Group B; p= 0.8). Deep sternal wound infection occurred in 4.17% in group A (n= 4) and 4.55% in group B (n= 4) (p= 0.705). Superficial wound infection occurred in eight patients in group A (8.33%) and eight patients in group B (9.1%) (p= 0.59). No patient had sternal dehiscence in group A vs. four patients in group B (4.55%) (p= 0.39).

Conclusion: We did not find differences between bilateral mammary artery harvest with skeletonization of both arteries versus skeletonization of the right mammary only on sternal healing nor wound infection in diabetic patients undergoing CABG. A larger study is recommended.

KEYWORDS

Coronary artery bypass grafting; Right mammary, Bilateral mammary

Article History

Submitted: 8 May 2020

Revised: 20 May 2020

Accepted: 29 May 2020

Published: 1 Oct 2020

Introduction

Coronary artery bypass grafting (CABG) have superior long-term survival compared to percutaneous interventions, particularly in diabetic

patients with a multi-vessel disease [1]. The left internal mammary artery (LIMA) is the gold standard conduit for myocardial



revascularization because of the established clinical and survival benefits when compared to saphenous vein grafts [2].

LIMA has excellent long-term patency, reaching 90% after ten years. In contrast to vein grafts, where around half are occluded, and the other half is severely diseased at the same follow-up period [3]. Angiographic studies demonstrated markedly superior patency of bilateral internal mammary arteries (BIMA) compared to vein grafts, with patency rates of BIMA grafts being as high as 95% at two years and 90% at seven years [4,5].

However, BIMA harvesting is more challenging, and there are concerns that it is associated with longer operation time and increases the risk of early mortality and major morbidity impaired wound healing. Thus, BIMA grafting is only used routinely in around 10% of the CABG patients in Europe and 4% of the CABG patients in the USA [6].

Keeley first described the skeletonization of IMA in 1987, which involved the harvest of only the IMA without any surrounding tissue. Skeletonization of the IMA has been proposed as a solution to many of the problems associated with IMA harvesting [7]. Skeletonization may increase the graft flow and length, decrease sternal infection rates, and reduce pain [8].

The objective of our study was to compare sternal healing in diabetic patients with different techniques of bilateral internal mammary artery harvesting.

Patients and Methods:
Design and patients

We conducted this randomized clinical study from January 2017 to January 2020. One hundred and eighty-four diabetic patients who had ischemic heart disease and underwent CABG using BIMAs were analyzed in this study.

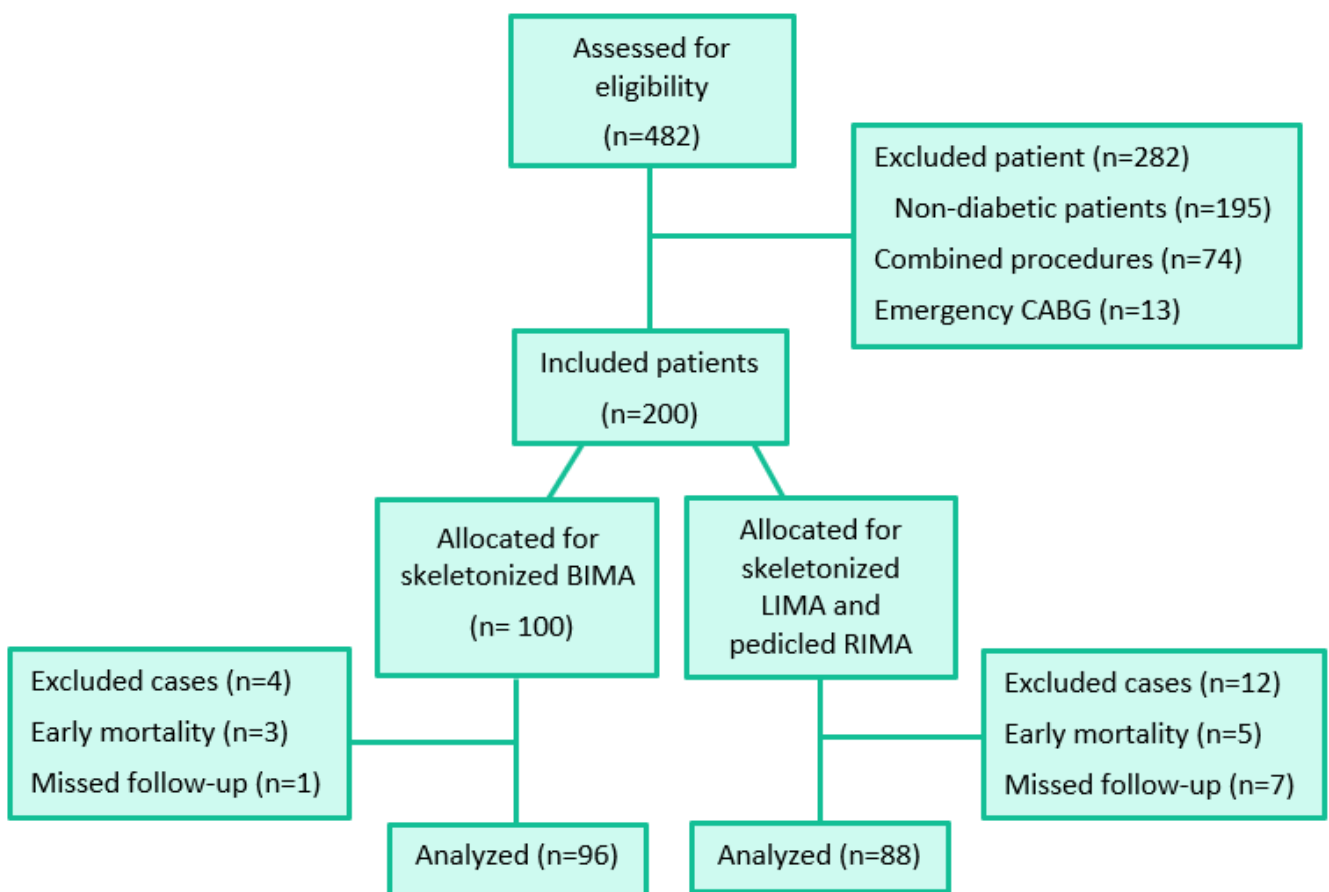


Figure 1: Flow chart of the patients allocated for the study

Patients who had associated other cardiac procedures, such as mitral valve repair or replacement, tricuspid valve repair or replacement and aortic valve replacement surgery, previous open-heart surgery, or emergency CABG were excluded. Patients who were lost for follow up were also excluded.

Patients were randomly assigned to either Group A (n=96 patients) in which we performed bilateral skeletonization of the IMA or Group B (n=88 patients) in which we used LIMA as pedicled and right internal mammary artery (RIMA) as skeletonized. The study flow chart is shown in [Figure 1](#). Out of 482 patients who underwent CABG, 184 cases were included in our study. Each group initially had 100 patients. Four patients were excluded from group A; three patients had early mortality, and one patient was lost for follow-up. Twelve patients were excluded from group B, five patients had early mortality, and seven patients were lost for follow-up.

Data and technique:

After the routine examination and preoperative preparation of the patients, standard preparation in the operation room was done. After standard midline sternotomy was performed, both internal mammary arteries were harvested using low energy diathermy.

The LIMA was harvested first after opening the pleura, using the skeletonized technique in Group

(A) and pedicled technique in Group (B). The RIMA was harvested using the skeletonized technique in both groups.

Operative variables, including harvesting time, number of grafts, operation time, total bypass time, and units of blood transfused, were collected before the patient was transferred to the Intensive Care Unit (ICU).

Study outcomes:

We compared both groups regarding the ICU stay, total drainage, and the need for blood product transfusion. The follow-up included wound assessment, which was done daily until discharge for the detection of any infection or dehiscence. The outpatient follow-up continued for three months, chest computed tomography (CT) was done for detection of sternal dehiscence.

Statistical analysis:

Results were collected, tabulated, and statistically analyzed using the statistical package of social sciences, version 20 (SPSS Inc. released 2011, IBM SPSS statistics for windows, version 20.0; IBM Corp., Armonk, New York, USA). Continuous data were expressed as mean \pm standard deviation (SD) and were compared with the Student t-test. The distribution of qualitative variables across groups was analyzed with Chi-square test or Fischer exact test as appropriate. All comparisons were bilateral, and a p-value <0.05 was the limit of statistical significance.

Table 1: preoperative characteristics and comorbidities

| | Studied groups | | P-value |
|-------------------------------|------------------|-------------------|---------|
| | Group A (n = 96) | Group B (n= 88) | |
| Age (years) | | | |
| mean \pm SD | 55.3 \pm 4.8 | 44.55 \pm 10.68 | 0.779 |
| Range | 47 – 63 | 49 – 61 | |
| Sex (Male) n (%) | 84 (87.5%) | 84 (95.45%) | 0.598 |
| BMI (kg/m²) | 31.34 \pm 0.21 | 30.86 \pm 0.33 | 0.634 |
| Smoking n (%) | 80 (83.33%) | 72 (81.82%) | 0.944 |
| COPD n (%) | 12 (12.5%) | 8 (9.1%) | 0.611 |
| CKD n (%) | 20 (20.83%) | 12 (13.64%) | 0.898 |
| DM (type I) | 24 (25%) | 12 (13.64%) | 0.324 |

BMI; body mass index, COPD: chronic obstructive pulmonary disease, CKD: chronic kidney disease, DM; diabetes mellitus.

Results

Preoperative data:

Both groups were comparable regarding the demographic data and preoperative risk factors; smoking, chronic obstructive pulmonary disease (COPD), and chronic kidney disease (CKD) with no statistically significant difference, as shown in [Table 1](#). Our study included diabetic patients, type I DM was present in 24 patients (25%) in Group A and 12 patients (13.64%) in Group B ($p= 0.324$).

Operative data:

There was no statistically significant difference between both groups regarding total operative time, harvesting time, cross-clamp time, and the number of grafts, as shown in ([Table 2](#)).

Postoperative data:

Regarding the postoperative parameters, ICU stays, amount of drainage, blood units transfused, and the need for reoperation, there was no statistically significant difference between both groups, as shown in ([Table 3](#)).

Wound infection

Postoperative follow-up of the wound, including superficial or deep infection and sterile sternal dehiscence, showed no statistically significant difference between both groups, as shown in ([Table 4](#)). While wound debridement was done for eight patients in each group, rewiring was done four times in group A.

Discussion

Almost 95% of the CABG patients receive a single internal mammary artery graft with excellent long-term patency compared to other conduits [3]. The superior clinical outcome associated with a LIMA graft encouraged several groups to investigate the use of bilateral internal mammary arteries (BIMA) with reports of even better clinical outcomes [9]. Angiographic studies demonstrate markedly superior patency of BIMA grafts compared with vein grafts, with patency rates of BIMA grafts being as high as 90% seven years [10,11].

Despite that, BIMA harvesting is more challenging, and there are concerns about the infection rates after BIMA use. Therefore, BIMA is not widely used worldwide [6,12]. Proposed benefits of skeletonization include increased flow and length, decreased sternal infection rates, and reduced pain. However, these assertions are supported primarily by nonrandomized, observational studies. Not surprisingly, there is considerable debate about the optimal harvesting technique for the IMA [8].

In our study, both groups were comparable regarding cross-clamp and total operative time despite harvesting time was longer in Group A with no significant difference. The number of grafts ranged from 2-4 grafts in both groups with a mean of 3 grafts.

Table 2: Operative data

| | Studied groups | | P-value |
|-----------------------------------|-----------------|------------------|---------|
| | Group A (n= 96) | Group B (n = 88) | |
| Harvesting time (min) | | | |
| Mean \pm SD | 83 \pm 4 | 81 \pm 3 | 0.1 |
| Range | 78-90 | 70-88 | |
| Cross-clamp time (min) | | | |
| Mean \pm SD | 47.8 \pm 11.1 | 46.5 \pm 12.4 | 0.719 |
| Range | 32 – 70 | 28 – 72 | |
| Total operative time (min) | | | |
| Mean \pm SD | 191 \pm 28 | 181 \pm 25 | 0.627 |
| Range | 170-240 | 150-225 | |
| Grafts | | | |
| Mean \pm SD | 3 \pm 0.6 | 3 \pm 0.5 | 0.810 |
| Range | 2 – 4 | 2 – 4 | |

Table 3: Post-operative data

| | Studied groups | | P-value |
|--------------------------|-------------------|-------------------|---------|
| | Group A (n = 96) | Group B (n = 88) | |
| ICU stay (days) | | | |
| mean \pm SD | 2 \pm 0.7 | 2 \pm 0.5 | 0.821 |
| Range | 1 – 4 | 1 – 4 | |
| Drainage (ml) | | | |
| mean \pm SD | 402.9 \pm 174.1 | 387.2 \pm 153.6 | 0.474 |
| Range | 210 – 900 | 250 – 860 | |
| Blood transfusion | | | |
| mean \pm SD | 1.9 \pm 0.6 | 1.6 \pm 0.6 | 0.183 |
| Range | 1 – 3 | 1 – 3 | |
| Reoperation n (%) | 8 (8.33%) | 4 (4.55%) | 0.884 |

ICU: intensive care unit

Our operative data were comparable to a study by Elnaggar and colleagues [13] conducted to study the use of BIMA, either skeletonized or pedicled. Less reoperation was needed; 8.33% for group A and 4.55% for group B, while being higher in Elnaggar and colleagues [13] with 12% need for re-sternotomy in BIMA group, which might be justified by the higher drainage in their study group.

Another study by Rubens and collaborators [14] showed that reoperation was required in 2.82% after skeletonized BIMA harvest and 2.06% for the pedicled BIMA technique, which is much less than our results. This ratio might explain fewer wound complications, superficial and deep sternal wound infection, than our study.

Rubens and coworkers [14] had no significant difference between both groups in superficial and deep sternal wound infections. Superficial wound infection was 3.4% vs. 3.8% in skeletonized and pedicled BIMA groups. In comparison, the deep infection was 2.5% vs. 2.4% in skeletonized and

pedicled BIMA groups, respectively, while superficial sternal wound infection was 8.33% in group A and 9.1% in group B and deep sternal wound infection was 4.17% in group A and 4.55% in group B.

Therefore, reoperation for bleeding might be related to an increased rate of sternal wound complications. This can be avoided by meticulous hemostasis, especially with direct control of IMA branches in skeletonized technique with less raw area in the chest wall.

The wound infection was managed by frequent dressing and proper antibiotics after microbiological tests. The vacuum-assisted dressing was used for deep sternal infections after surgical debridement.

Thus, it seemed justifiable that the skeletonization technique gives the advantage of bilateral mammary revascularization and limits sternal ischemia by maintaining substantial blood flow through collaterals from preserved

Table 4: Comparison of wound infection between group A and group B

| | | Studied groups | | P-value |
|---------------------------------|-------------|------------------|------------------|---------|
| | | Group A (n = 96) | Group B (n = 88) | |
| Infection n (%) | Superficial | 8 (8.33%) | 8 (9.1%) | 0.586 |
| | Deep | 4 (4.17%) | 4 (4.55%) | 0.705 |
| Sterile dehiscence n (%) | | 0 | 4 (4.55%) | 0.386 |
| Debridement n (%) | | 8 (8.33%) | 8 (9.1%) | 0.586 |
| Rewiring n (%) | | 4 (4.17%) | 0 | 0.436 |

intercostal and sternal branches, which is confirmed by Filho and coworkers [15] who assessed sternal perfusion with scintigraphy.

The risk of sternal wound infection limits the routine use of BIMA. However, there is an arterial network around IMA, which, if not damaged, would maintain adequate sternal perfusion after the BIMA harvest [16,17]. Diabetic patients are at higher risk of sternal wound infections. In a recent meta-analysis, there was no difference in deep sternal wound infection between skeletonized BIMA and LIMA harvest. On the other hand, the pedicled technique showed an increased risk of infection because of the acute sternal ischemia [16].

Study limitations

The study is limited by the sample size and a low number of events, and more extensive research is required to confirm the results. The study included diabetic patients only, and the results cannot be generalized to all patients. The study presents a single-center experience.

Conclusion

We did not find differences between bilateral mammary artery harvest with skeletonization of both arteries versus skeletonization of the right mammary only on sternal healing nor wound infection in diabetic patients undergoing CABG. A larger study is recommended.

Conflict of interest: Authors declare no conflict of interest.

References

1. Deo SV, Shah IK, Dunlay SM, et al. [Bilateral Internal Thoracic Artery Harvest and Deep Sternal Wound Infection in Diabetic Patients](#). *Ann Thorac Surg* 2013; 95: 862–9.
2. Cheng K, Rehman SM, Taggart DP. [A Review of Differing Techniques of Mammary Artery Harvesting on Sternal Perfusion: Time for a Randomized Study?](#) *Ann Thorac Surg* 2015; 100: 1942–53.
3. Gansera B, Schmidtler F, Angelis I, Kiask T, Kemkes BM, Botzenhardt F. [Patency of internal thoracic artery compared to vein grafts—postoperative angiographic findings in 1189 symptomatic patients in 12 years](#). *Thorac Cardiovasc Surg* 2007; 55:412–417.
4. Taggart DP, D’Amico R, Altman DG. [The effect of arterial revascularization on survival: a systematic review of studies comparing bilateral and single internal mammary arteries](#). *Lancet* 2001; 358:870–875.
5. Endo M, Nishida H, Tomizawa Y, Kasanuki H. [Benefit of bilateral over single internal mammary artery grafts for multiple coronary artery bypass grafting](#). *Circulation* 2001; 104:2164–2170.
6. Kurlansky P. [Thirty-year experience with bilateral internal thoracic artery grafting: where have we been and where are we going?](#) *World J Surg* 2010; 34:646–651.
7. Keeley SB. [The Skeletonized Internal Mammary Artery](#). *Ann Thorac Surg* 1987; 44:324–325.
8. Takami Y, Ina H. [Effects of skeletonization on intraoperative flow and anastomosis diameter of internal thoracic arteries in coronary artery bypass grafting](#). *Ann Thorac Surg*. 2002; 73:1441–1445.
9. Buxton BF, Ruengsakulrach P, Fuller J, Rosalion A, Reid CM, Tatoulis J. [The right internal thoracic artery graft—benefits of grafting the left coronary system and native vessels with a high-grade stenosis](#). *Eur J Cardiothorac Surg* 2001; 18:255–261.
10. Rizzoli G, Schiavon L, Bellini P. [Does the use of bilateral internal mammary artery \(IMA\) grafts provide incremental benefit relative to the use of a single IMA graft? A meta-analysis approaches](#). *Eur J Cardiothorac Surg* 2002; 22:781–786.
11. Calafiore AM, Contini M, Vitolla G, et al. [Bilateral internal thoracic artery grafting: long-term clinical and angiographic results of in situ versus Y grafts](#). *J Thorac Cardiovasc Surg* 2000;120: 990–996.
12. Galbut DL, Kurlansky PA, Traad EA, Dorman MJ, Zucker M, Ebra G. [Bilateral internal thoracic artery grafting improves long-term survival in patients with reduced ejection fraction: A propensity-matched study with 30-year follow-up](#). *J Thorac Cardiovasc Surg* 2012;143: 844–53.

13. Elnaggar A, Rassekh F, Nosair A, Zarif P. Bilateral mammary artery harvesting and sternal wound infection: Importance of skeletonization. *Journal of The Egyptian Society of Cardio-Thoracic Surgery* 2013; 21(2):35-40.
14. Rubens FD, Chen L, Bourke M. [Assessment of the Association of Bilateral Internal Thoracic Artery Skeletonization and Sternal Wound Infection After Coronary Artery Bypass Grafting](#). *Ann Thorac Surg* 2016; 101:1677–83.
15. Santos Filho ECD, Moraes Neto FRD, Silva RAM, Moraes CRRD. [Should the diabetics have the internal thoracic artery skeletonized?](#) *Assessment of sternal perfusion by scintillography*. *Rev Bras Cir Cardiovasc* 2009; 24(2): 157-164.
16. Davierwala PM, Mohr FW. [Bilateral internal mammary artery grafting: Rationale and evidence](#). *International Journal of Surgery* 2015; 16: 133-139.
17. Shaheen YA, El-Shafiey MA, Hebishy MG, Emara AS. [The outcomes of Skeletonized and Pedicled Internal Thoracic Artery in Patients undergoing coronary artery bypass grafting: a randomized clinical study](#). *The Egyptian Cardiothoracic Surgeon* 2020; 2(1): 8 – 14.