

Department of Oral and Maxillofacial Diseases
University of Helsinki

Helsinki University Central Hospital
Helsinki, Finland

COMPLICATIONS AND COMPROMISED HEALING IN MANDIBULAR BILATERAL SAGITTAL SPLIT OSTEOTOMIES

Marina Kuhlefeldt

ACADEMIC DISSERTATION

To be presented, with the permission of the faculty of Medicine
of the University of Helsinki, for public examination
in the Richard Faltin Room of the Surgical Hospital,
Helsinki University Central Hospital, Kasarminkatu 11-13,
on May 27, 2016, at 12 noon.

Helsinki 2016

Supervisors

Docent Hanna Thorén, MD, DDS, PhD

Department of Oral and Maxillofacial Diseases
University of Helsinki and Helsinki University Central Hospital
Helsinki, Finland

Professor Pekka Laine, DDS, PhD

Department of Oral and Maxillofacial Diseases
University of Helsinki and Helsinki University Central Hospital
Helsinki, Finland

Reviewers

Docent Tero Soukka, DDS, PhD

Department of Oral and Maxillofacial Diseases
Turku University Hospital

Department of Oral and Maxillofacial Surgery
Institute of Dentistry, Faculty of Medicine, University of Turku
Turku, Finland

Professor Timo Peltomäki, DDS, PhD

Oral and Maxillofacial Unit,
Tampere University Hospital and School of Medicine,
University of Tampere,
Tampere, Finland

Opponent

Professor Kyösti Oikarinen, DDS, PhD

Research Unit of Health Sciences, Faculty of Medicine,
University of Oulu, Oulu, Finland

ISBN 978-951-51-2109-7 (paperback)

ISBN 978-951-51-2110-3 (PDF)

<http://ethesis.helsinki.fi>

Unigrafia

Helsinki 2016

To Emma, Linus and Gunnar

CONTENTS

LIST OF ORIGINAL PUBLICATIONS	7
ABBREVIATIONS	9
ABSTRACT	11
1 INTRODUCTION	15
2 REVIEW OF THE LITERATURE	17
2.1 Anatomy of the mandible.....	17
2.2 Historical development of mandibular sagittal split osteotomy	18
2.2.1 Osteotomies of the mandible.....	18
2.2.2 Orthognatic surgery	19
2.2.3 BSSO	20
2.2.4 Current surgical technique for BSSO	21
2.2.5 Osteosynthesis of the mandible	26
2.2.6 The fate of osteosynthesis material after bony healing	26
2.3 Indications and patient related motives for having BSSO	28
2.4 Tissue healing.....	29
2.4.1 Normal tissue healing.....	29
2.4.2 Factors affecting tissue healing	30
2.5 Complications in BSSO patients.....	30
2.5.1 Rare complications.....	31
2.5.2 Serious hemorrhage.....	31
2.5.3 Infections	32
2.5.4 Bad split	33
2.5.5 Neurosensory disturbance	34
2.5.6 TMD and complications	36
2.6 Factors that affect patient satisfaction.....	38
3 AIMS OF THIS STUDY	41
4 HYPOTHESES OF THIS STUDY	43

5 PATIENTS AND METHODS	45
5.1 Study populations	45
5.2 Outcome variables	46
5.2.1 Definition of surgical site infections (Study II)	46
5.2.2 Evaluation of neurosensory disturbance and patient satisfaction (Study III)	46
5.2.3 Evaluation of TMD (Study IV)	46
5.3 Predictor variables	47
5.4 Statistics	47
5.5 Ethical considerations	48
6 RESULTS	49
6.1 Factors and their prevalences that contributed to the removal of symptomatic titanium miniplates after BSSO (Study I)	49
6.2 Risk factors and their prevalences for infections after orthognatic surgery (Study II)	51
6.3 Factors and their prevalences for NSD, and patient satisfaction at one year after BSSO (Study III)	53
6.4 TMD before and at one year after BSSO in patients with mandibular rethrognatia (Study IV).....	54
7 DISCUSSION	57
7.1 Methodological aspects	57
7.1.1 Study populations and sizes	57
7.1.2 Indices for TMD	57
7.1.3 Osteosynthesis technique	58
7.2 Compromised tissue healing and infections	58
7.3 Neurosensory disturbance	60
7.4 TMD	63
7.5 Future trends in orthognatic surgery	64
8 KEY FINDINGS AND CONCLUSIONS	67
ACKNOWLEDGEMENTS	69
REFERENCES	71
ORIGINAL PUBLICATIONS	81

LIST OF ORIGINAL PUBLICATIONS

These studies are hereafter referred to in the text by their Roman numerals

- I Risk factors contributing to symptomatic miniplate removal: a retrospective study of 153 bilateral sagittal split osteotomy patients. Kuhlefeldt M, Laine P, Suominen-Taipale L, Ingman T, Lindqvist C, Thorén H. *Int J Oral Maxillofac Surg* 39: 430 -435, 2010
- II Smoking as a significant risk factor for infections after orthognatic surgery. Kuhlefeldt M, Laine P, Suominen A. L, Lindqvist C, Thorén H. *J Oral Maxillofac Surg* 70: 1643 -1647, 2012
- III Nerve manipulation during bilateral sagittal split osteotomy increases neurosensory disturbance and decreases patient satisfaction. Kuhlefeldt M, Laine P, Suominen A. L, Lindqvist C, Thorén H. *J Oral Maxillofac Surg* 72: 2052.e1 -2052.e5, 2014
- IV Bilateral sagittal split surgery is not a predictable treatment for temporomandibular dysfunction in retrognathic patients. Kuhlefeldt M, Laine P, Thorén H. *Oral Surg, Oral Med, Oral Path, Oral Rad.* In press, published online January 2, 2016

ABBREVIATIONS

Ai	Helkimo anamnestic dysfunction Index
BSSO	Bilateral sagittal split osteotomy
Di	Helkimo clinical dysfunction Index
NSD	Neurosensory disturbance
IAN	Inferior alveolar nerve
TMD	Temporomandibular dysfunction
SSI	Surgical site infection
RDC/TMD	Research Diagnostic Criteria for Temporomandibular Disorders

ABSTRACT

BACKGROUND AND PURPOSE

Orthognatic surgery is elective surgery for the correction of congenital discrepancies in the facial skeleton. Bilateral sagittal split osteotomy (BSSO) is the work horse procedure used when the dimensions of the lower jaw have to be corrected in adult patients. Orthodontic treatment is used before and after surgery to create a harmonious occlusion at the end of treatment. The lower jaw can be brought forward, backward or rotated with the aid of BSSO. The great majority of patients are young and healthy. This procedure also has complications as with all other forms of surgery. Complications and unsuccessful healing have been shown to decrease patient satisfaction. It is therefore of great importance to identify those factors that have an impact on these complications in order to be able to diminish or even eliminate them.

The main aim of this study was to identify factors that increase surgical site infections (SSI), removal of osteosynthesis material, neurosensory disturbance (NSD) and temporomandibular dysfunction (TMD). An additional aim was to identify factors that decrease patient satisfaction in BSSO patients.

PATIENTS

This study comprised four populations of orthognatic patients, all treated at the Department of Oral and Maxillofacial Diseases, Helsinki University Central Hospital, Helsinki, Finland.

Medical records of 153 consecutive BSSO patients who had undergone fixation by titanium miniplates were obtained for Study I. The medical records for 286 consecutive orthognatic patients with one jaw surgery were retrieved retrospectively for Study II. The patients in both of these studies had been operated on between January 1997 and December 2003.

Patients planned for BSSO in studies III and IV were recruited between November 2006 and June 2008. The follow-up was one year. Study III included 41 patients and Study IV 40 patients.

METHODS

The outcome variable in Study I was the removal of one symptomatic titanium miniplate, whereas in Study II it was any SSI. The predictor variables were age, gender, smoking status, duration of operation and general diseases. The dimensions of mandibular movement in Study I were also recorded, whereas in Study II the osteosynthesis supporting material and the use of drains were additionally recorded as variables.

The main outcome variable in Study III was neurosensory disturbance (NSD), whereas in Study IV it was TMD at one year post-operative. Patient satisfaction was also evaluated in Study III. The main predictor variable in Study III was the degree of manipulation of the inferior alveolar nerve (IAN). Age, gender, smoking status, mandibular advancement and duration of operation were also recorded. The main predictor variable in Study IV was TMD before surgery. The Helkimo Dysfunction (Di) and Anamnestic (Ai) indices were used to evaluate the TMD status in Study IV. Age, gender, smoking status, mandibular advancement and previous TMD were also recorded.

Chi-squared tests and logistic regression analyses were used to evaluate the statistical significances of the associations between the outcome and predictor variables in the first three studies. The prevalence of the outcome is presented in study four.

RESULTS

Nearly one-fifth (19.0%) of the inserted miniplates were removed in Study I because of a variety of symptoms. However, plate removals were all for plate-related reasons and subjective discomfort. Plate-related reasons were infection and screw-loosening. The subjective discomfort symptoms were sensitivity to cold, palpability and discomfort associated with foreign matter. Smoking was the only significant predictor for plate removal.

Nearly one in ten (9.1%) of the patients in Study II had a SSI. None of these altered the outcome of the treatment, even when additional interventions were needed. The only statistically significant risk factor for SSI in Study II was smoking.

Although the great majority of the patients in Study III were not excessively perturbed by the NSD symptoms they experienced in everyday life as much as 90.2% of them reported NSDs. The NSDs tended to be more frequent the more the IAN was manipulated or damaged during surgery. Four patients had a lacerated IAN and all four experienced a major burden of NSD. Two patients (4.9%) had severe NSDs, which were classified as neurophathic pain. Most patients were satisfied

with the treatment, but the four patients with the lacerations to the IAN were not satisfied and declared they would not undergo the treatment again.

A substantial proportion (42.5%) of the patients in Study IV had TMD as one of the reasons for seeking treatment. The TMD did not change after treatment in the majority of patients (60%), 30% improved and for 10% the situation impaired as indicated by their Helkimo Dysfunction index (Di) scores.

CONCLUSIONS

There are factors that can be altered by the surgeon or by the patient that will decrease complications in BSSO patients. Smoking cessation will reduce SSI and the need for removal of osteosynthesis material. The surgical technique does matter, and nerve manipulation and lacerations should be avoided at almost any cost since NSD increase suffering and decrease patient satisfaction. TMD symptoms improved for only 30% of the BSSO symptoms, thus it is not a predictable treatment for TMD patients, and might just reflect the normal fluctuation of symptoms in TMD patients. Mandibular retrognathia and TMD symptoms should be treated independent of each other.

1 INTRODUCTION

Patients who undergo orthognatic surgery are usually young, healthy adults with dental relationships that are severe enough to be functionally and esthetically disturbing. Orthodontic treatment with functional appliances during the pubertal growth spurt in most patients will result in sufficient correction of the occlusion and facial soft tissue profile. In some adult patients camouflage treatment is possible. However, orthognatic surgery is often needed for young patients with a severe discrepancy of the jaws and also for adult patients that have completed jaw growth and have severe malocclusion. Orthognatic surgery will, in the great majority of these patients, give the best facial esthetic outcome (Kinzinger et al. 2008)

Bilateral sagittal split osteotomy (BSSO) is the main surgical tool for correcting skeletal discrepancies in the lower face (Patel and Novia 2007). BSSO is often performed in young, otherwise healthy individuals as for orthognatic surgery in general, and there should therefore be a low occurrence of complications and adverse events. Complications do occur, however, just as they do in any other surgery. Steel and Cope (2012, p. 1678) stated the following: “If you have not had any complications, you have not done enough surgery yet”.

Even though various types of complications have been described in association with orthognatic surgery (Panula et al. 2001, Steel and Cope 2012, Robl et al. 2014, Kim and Park 2007, Telzrow et al. 2005), they are probably underestimated. It is more likely that serious and unusual complications are published as dramatic case reports. Yet, all types of complications and compromised healing have an adverse impact on patient satisfaction, increased suffering and they also add to costs. Therefore, there is a need for studies to deal with complications and compromised healing in patients that undergo orthognatic surgery in general, and BSSO in particular.

2 REVIEW OF THE LITERATURE

2.1 ANATOMY OF THE MANDIBLE

It is of the utmost importance to have a good understanding of mandibular anatomy and function to be able to understand the development of the mandibular procedures and the difficulties associated with them.

The mandible (Figure. 1) consists of a horseshoe formed bone with a tooth bearing part, and two condylar heads. The condylar heads fit into the glenoid fossa, which is located on each side of the skull base. The masticatory muscles have one of their insertions in the mandible and the other in the surrounding structures. This arrangement enables the mandible to be moved in all three spatial dimensions during normal function.

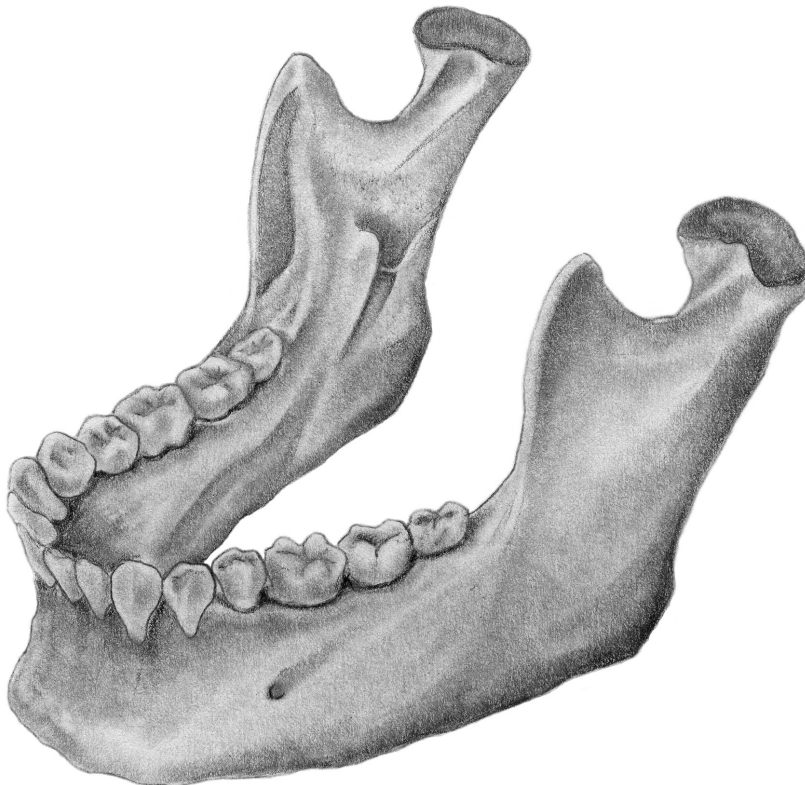


Figure 1 The mandible. (Illustration: Emma Sundström)

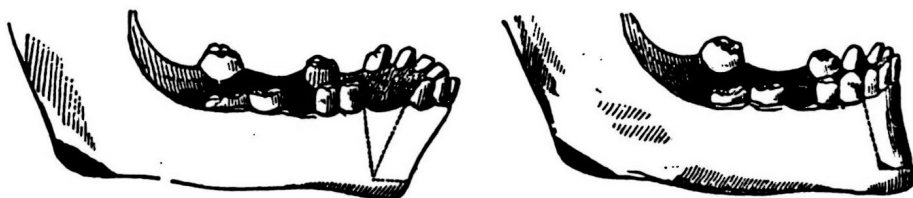The third branch of the trigeminal nerve, i.e., the mandibular nerve, divides into several branches. One branch, namely the inferior alveolar nerve (IAN), is a sensory branch that enters the mandible via the mandibular foramen. The nerve can be identified during surgery and it is located under the lingula. The mylohyoid groove is situated posterior to the lingula. The IAN runs inside the mandibular bone and it innervates the lower teeth and gums. It leaves the mandibular bone through the mental foramen to innervate the lip and skin of the mental region.

2.2 HISTORICAL DEVELOPMENT OF MANDIBULAR SAGITTAL SPLIT OSTEOTOMY

2.2.1 Osteotomies of the mandible

Simon P. Hüllihen published an account of the first mandibular osteotomy in the mid-19th century long before the era of antibiotics and general anesthesia. His work “Case of elongation of the underjaw and distortion of the face and neck caused by a burn, successfully treated” was published in 1849 in the American Journal of Dental Science (Hüllihen 1849) (Figure 2). He performed a mandibular osteotomy and soft tissue corrections in a young female patient. Her face had been distorted during growth, due to scarring after a severe burn she experienced in her childhood. She was not able to move her head, the cheek was drawn down to the chest by the scars and the mandibular growth had been disturbed by the tissue tension due to the scarring. After successful treatment of the patient Hüllihen concludes in his publication that “the young lady, though still carrying evidences of the burn has free use of her head, eyelids, jaws and lips, and may mingle in society without particular note or remark” (Hüllihen 1849, p. 164). During his career Hüllihen primarily focused on oral surgery and became particularly well known for his treatment of cleft lip and palate (Steinhaeuser 1996, Aziz 2004).

Figure 2 The first osteotomy of the mandible performed by Dr. S.P. Hüllihen in 1848 (Hüllihen 1849).



a Treatment planning and preoperative clinical situation

b The final outcome after the osteotomy

2.2.2 Orthognatic surgery

Orthodontist Edward H. Angle and surgeon Vilray P. Blair worked closely together in St. Louis and their collaboration was the start of what we today consider as orthognatic surgery.

The first described double osteotomy of the mandible for the correction of prognathism was performed 1897 on a medical student at the St. Louis Medical College (Whipple 1898, Angle 1898, Blair 1906). The patient had severe esthetic, speech and masticatory problems. The operator-in-chief was V. P. Blair, who was assisted by a voluntary surgical and clinical staff team in order to lower the costs for the young student. The operation was performed under chloroform anesthesia. After an extra oral incision, one segment of bone was removed from each side of the mandible in the bicuspid region, with a specially designed two bladed saw. On the right side a premolar had been removed prior to the main procedure to create space for the osteotomy. On the other side, however, there was a natural gap between the teeth for the osteotomy in the premolar region. No bleedings were ligated and no consideration was given to the potential for damage to the IAN. Copper wire was chosen as the osteosynthesis support material to keep the bony fragments in the right position. A splint of guttapercha and intermaxillary fixation was applied. However, the intermaxillary fixation had to be removed the same day because of vomiting after the chloroform anesthesia. A plaster bandage was applied instead of the intermaxillary fixation.

Three weeks after the procedure the plaster bandage was removed because of worries of the young student. After that there was a non-union of the fragments and discharge of pus from the wounds. The patient was brought to the orthodontist E. Angle who constructed an orthodontic appliance to keep the occlusion and the bony fragments in the right position. The copper wires were tightened and a new plaster bandage was applied. The wounds were kept open with drainage gauze because of the infection.

After an eventful healing period, the infection resolved, a bony reunion was apparent, and the copper wires were removed. The occlusion and esthetics were greatly improved. The patient had a total loss of sensation in the lower lip, which was hoped would resolve over time. The sensory loss caused no inconvenience to the patient. The patient was satisfied with the treatment outcome and he did not suffer from the sensory loss. Despite modern medical knowledge and surgical techniques, many of the problems and complications mentioned above still remain debated topics in oral and maxillofacial surgery.

Blair was the first to realize the benefits of cooperation between orthodontists and surgeons. He wrote in the last sentence of his article a distinct recommendation concerning treatment of facial deformities: "It is really surgical work, but the earlier a competent, congenital orthodontist is associated in the case, the better it will be

for both the surgeon and the patient” (Blair 1907, p.78). Nothing could be more true in orthognatic surgery even today.

2.2.3 BSSO

In the beginning of the 20th century a variety of blind horizontal or condylar osteotomy techniques of the ramus were used to correct mandibular malformations (Kostecka 1931). These procedures were unpredictable and for many of the patients they led to serious complications. Some of these complications included partial or total relapse, open bite, pseudo arthrosis, injuries of the mandibular or facial nerve and parotid gland fistulas (Trauner and Obwegeser 1957, Steinhäuser 1996, Obwegeser 2007). A Finnish study published in 1981 described a modification of a closed condylotomy as a treatment for mandibular prognathism (Tasanen et al. 1981). Although the method itself was reported to be safe and minimally invasive, the patients had a variety of postoperative difficulties.

In 1955 Trauner and Obwegeser published the work entitled: “Zur Operations-technik bei der Progenia und anderen Unterkieferanomalien” in the German Journal for Oral and Maxillofacial Surgery (Trauner and Obwegeser 1955). Those authors described the procedure of BSSO during which the ramus of the mandible of a young woman was split by using a new intraoral technique that was introduced in 1953. During the operation the patient was in a half sitting position and the procedure was performed under sedation and local anesthesia, under poor visualization and without any special instruments. The osteotomy lines were above the lingula and below the occlusal plane of the lower molars. When the sagittal split was performed in this way, and not just as a single horizontal osteotomy line, it increased the contact area for the healing bone fragments and at the same time they took into consideration any hazards to the IAN. The wound was irrigated with an antibiotic rinse before closure. The patient had a splint and intermaxillary fixation during bony healing (Trauner and Obwegeser 1957, Obwegeser 2007).

Obwegeser performed his first case under general anesthesia in 1956 (Obwegeser 2007). The 14-year-old patient was extremely swollen and bruised after the procedure and Obwegeser feared serious complications. This prompted him to go to the monastery Church of Einsiedeln to pray and promised god never to do this procedure again. However, the patient later sent him her wedding photo and we all know that in the end, Obwegeser did not keep his promise.

Dal Pont published a modification of the intraoral sagittal split procedure developed by Obwegeser (Dal Pont 1958). The anterior osteotomy line was advanced anteriorly to the region of the first and second molars, which resulted in a larger area for bony healing. Hunsuck advocated that the lingual osteotomy line must be extended to just behind the lingula and not to the distal part of the ramus (Hunsuck 1968). These changes opened up new opportunities for mandibular

surgery (Obwegeser 2007, Monson 2013, Böckmann et al. 2014). The first BSSO conducted at Helsinki University Central Hospital was performed by professors Paul Stoelinga and Christian Lindqvist in 1984 (Figure 3.) (Christian Lindqvist, personal communication, 23.5.2015).

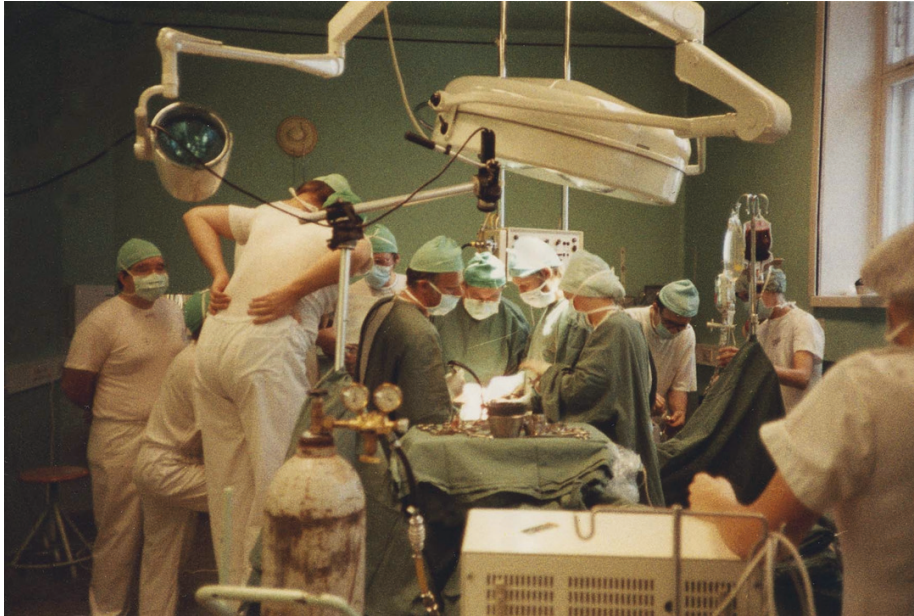


Figure 3 The first BSSO at the Department of Oral and Maxillofacial Diseases, Helsinki University Central Hospital performed by Professor Paul Stoelinga and Professor Christian Lindqvist (Picture: Valle J. Oikarinen).

2.2.4 Current surgical technique for BSSO

There are many modifications of the standard BSSO procedure (Figure 4). The surgical treatment of one patient with a lengthening (3.5 mm) and rotation of the mandible is shown in Figure 5 as one example.

Surgery is performed under general anesthesia with nasal intubation. A local anesthetic with a vasoconstrictor is infiltrated into the operation field. An incision is made in the sulcus in the first molar region and this continues to the ramus approximately 1-2 cm above the occlusal plane, leaving sufficient tissue for a good closure at the end of the surgery. The mucoperiosteum is dissected from the buccal and lingual sides of the mandibular bone taking care to avoid unnecessary stripping. The lingula is then identified without stretching the medial tissue and also the IAN, any more than is absolutely necessary for sufficient visibility and instrumentation. The first osteotomy line is made securely above the lingula parallel to the occlusal plane, and between the anterior border and the mylohyoid groove. The osteotomy

line is then continued down the ramus and is ended just anterior to the second molar. The buccal line is started vertically from the lower border of the mandible and joined with the vertical osteotomy line. The osteotomy line can be made with an oscillating saw, rotating burrs or by piezo surgery. The soft tissues are carefully protected, without unnecessary stretching. The mandible is then split through the mandible's weakest plane, which comprises cancellous bone. The medial tooth bearing segment and the lateral condylar segment are separated, while extreme care is taken not to injure the IAN. If there is any resistance during splitting, the possibility for a bad split should be considered and the osteotomy lines checked.

When both sides of the mandible are split the new position of the mandible is secured by a surgical splint attached to the orthodontic braces. Both condyles are carefully positioned into the respective glenoid fossa, and the mandible is secured in the new position with bicortical positioning screws or with one monocortical miniplate on each side. There might be a need for some recontouring of the bone before this is done, especially when the mandible is moved backwards or rotated. After closure of the wound, the new occlusion is carefully checked before extubation. Guiding elastics, but no intermaxillary fixation, is used during the first postoperative weeks (Patel and Novia 2007, Obwegeser 2007, Monson 2013).

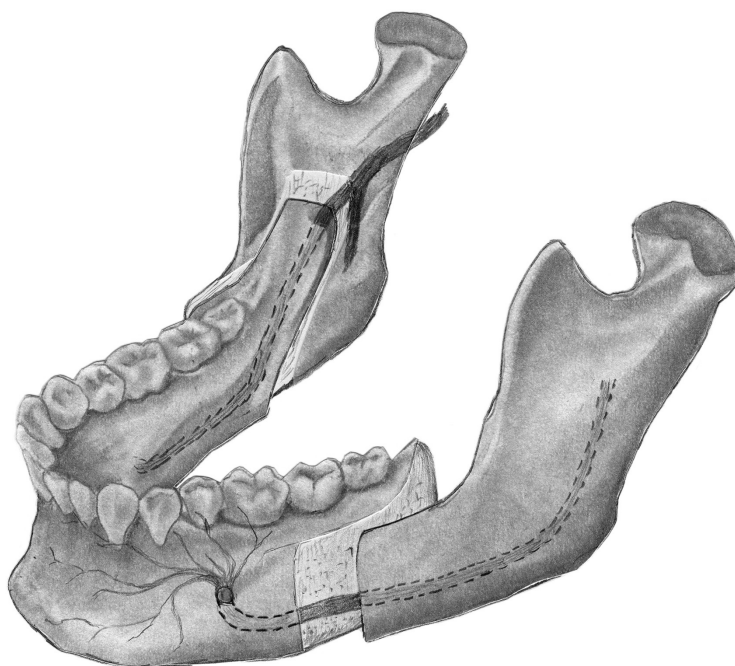


Figure 4 The bilateral sagittal split osteotomy and the inferior alveolar and mental nerve (Illustration Emma Sundström)

Figure 5 Surgical treatment of a patient with mandibular retrognathia.

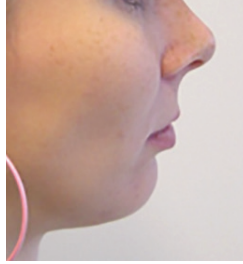

Figure 5 a Profile before treatment.

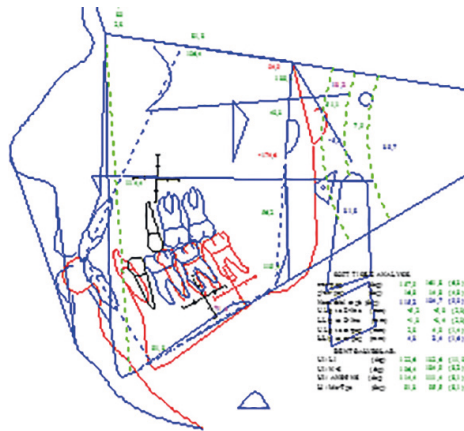


Figure 5 b Treatment planning (different patient). Skeletal analyses and prediction.

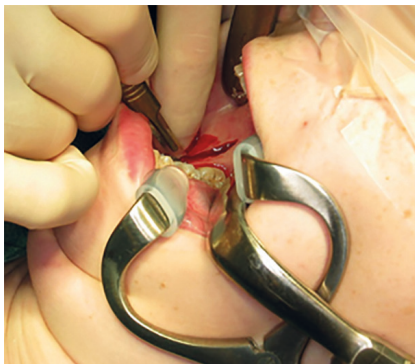


Figure 5 c Incision in the buccal sulcus.

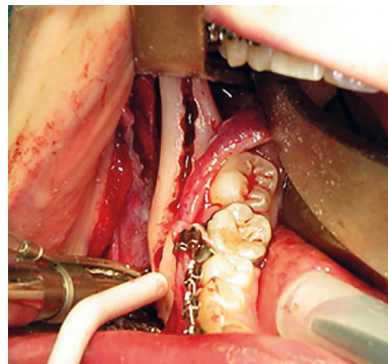


Figure 5 d The osteotomy line ready for the split.

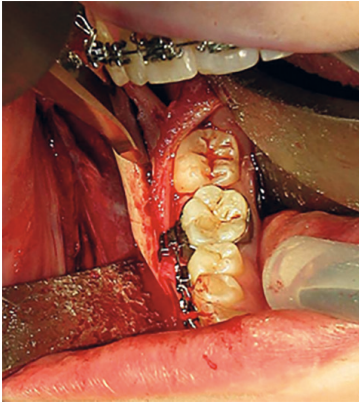


Figure 5 e The split with chisels.

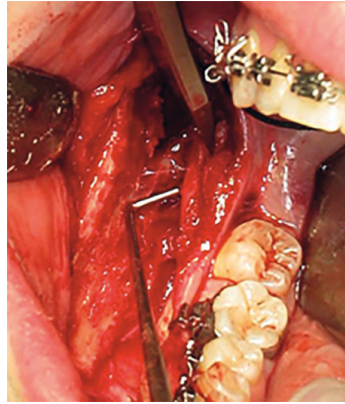


Figure 5 f The inferior alveolar nerve exposed between mandibular fragments.

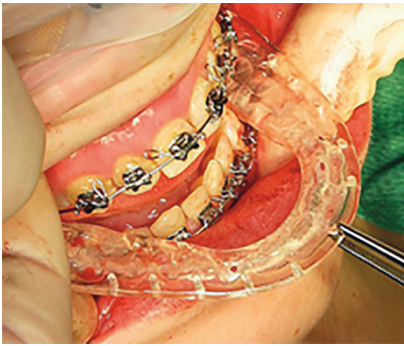


Figure 5 g The splint indicating the postoperative occlusion.

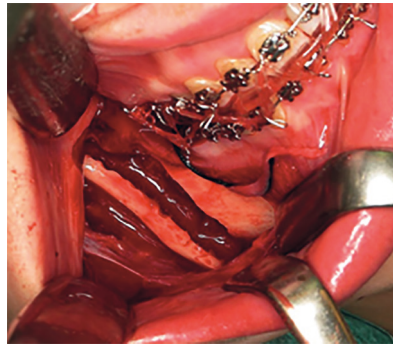


Figure 5 h The split, and the mandible secured in the new position.

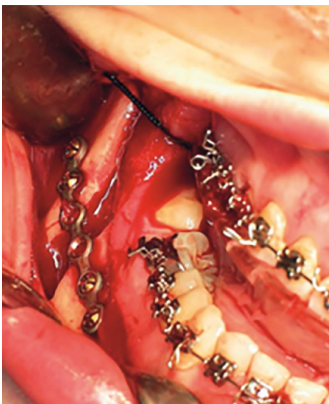

Figure 5 i The osteosynthesis with one miniplate and monocortical screws.

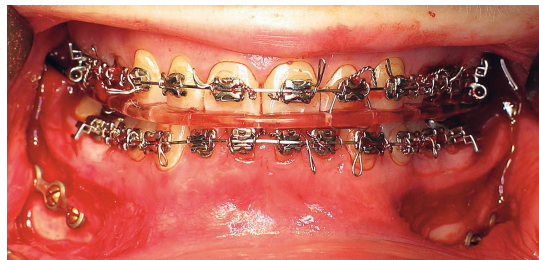

Figure 5 j Occlusion before closure.

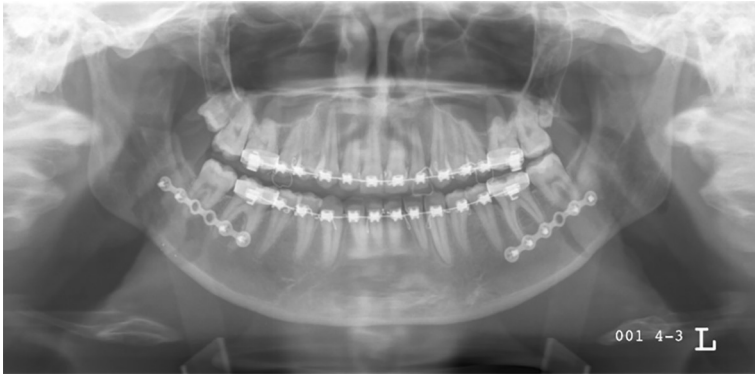

Figure 5 k The post operation orthopantomogram.

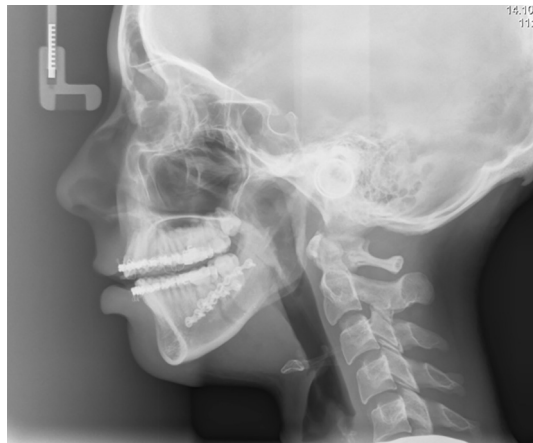

Figure 5 l The final profile.

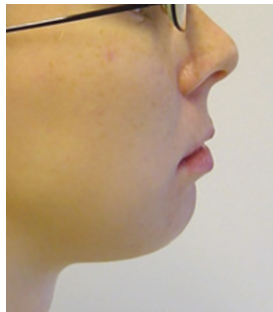

Figure 5 m The clinical outcome one week post operation.

2.2.5 Osteosynthesis of the mandible

Reliable osteosynthesis techniques have also evolved during the same time as the osteotomy techniques. Blair states in his publication in 1907: “I have used all kinds of bands, but have found that the finest grade of soft iron wire (such as that used by florists) replaces these to advantage” (Blair 1907, p. 74), referring to the repositioning of the bone fragments. For many years splints, wires and intermaxillary fixation were used during the period of bony healing. The bony fragments were wired into the new position as described in the first publication on the BSSO (Trauner and Obwegeser 1955).

Spiessl was the first to publish a study that described a rigid screw fixation with compression screws in BSSO patients (Spiessel 1974). Miniplates for the facial skeleton were developed during the same time period, in addition to the larger plates for orthopedic use (Michelet et al. 1973, Champy et al. 1978). There has been a tremendous development of the osteosynthesis supporting materials and techniques since these methods first were published. Rigid internal fixation has been considered the “state of the art” since the 1980s (Steinhaeuser 1996).

2.2.6 The fate of osteosynthesis material after bony healing

With the exception of the Champy system (Champy et al. 1978), the early miniplates were quite bulky. They were made of stainless steel, cobalt-chromium or other alloys, and were routinely removed after bony healing. Plate removal was also practiced at the department of Oral and Maxillofacial Diseases, Helsinki University Hospital, Finland (Izuka and Lindqvist 1992): the plates were removed as foreign bodies from all patients, with the exception of patients with a severely compromised general health. The removal of osteosynthesis material was performed under general anesthesia and required hospitalization.

Reasons for miniplate removal during the early years included the following: a fear of cortical osteopenia caused by vascular shielding under the plates, toxicity, allergy, metallosis, corrosion and carcinogenicity (Alpert and Seligson 1996, Haug 1996). Another reason for plate removal was thermal sensitivity (Iizuka and Lindqvist 1992). “Thermal sensitivity is a real problem even in temperate climates. Both large and small plates are subject to this phenomenon. Though this is a minor annoyance it usually results in ultimate plate removal” (Alpert and Seligsson 1996, p. 619). A Finnish study (Panula et al. 2001) reported that 8% of the orthognatic patients had removal of the osteosynthesis material because of local irritation, infection or breakage of the osteosynthesis material. Some patients had the plates removed because of discomfort in cold weather. All metallic plates were routinely removed in some clinics after healing (Alpert and Seligson 1996, Iizuka and Lindqvist 1992). Since metallic plates in orthognatic surgery patients had to be removed, bioresorbable plates were developed as an alternative to promote the osteosynthesis

of the bony fragments (Kulkarni et al. 1966, Suuronen et al. 1992, Suuronen et al. 1994, Laine et al. 2004, Fedorowicz et al. 2007, Tuovinen et al. 2010). However, today when high quality titanium osteosynthesis materials are used, the removal of the same has to be reconsidered. Dental implants, made of the same titanium alloys as the osteosynthesis plates and screws, are widely used as permanent replacements for missing teeth. Despite this fact there is still no consensus among the oral and maxillofacial surgery community concerning the need and indications for removal of the titanium osteosynthesis material. A removal of the titanium osteosynthesis material after successful bony healing is shown in Figure 6. Therefore the question remains: when does the patient benefit from the removal of the plates instead of leaving them *in situ*?

Figure 6 Removal of a titanic miniplate because of exposure of the osteosynthesis material.

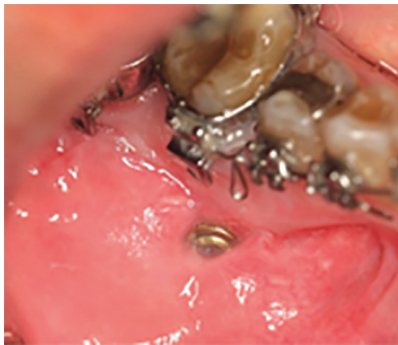

Figure 6 a Exposed miniplate with no signs of infection.

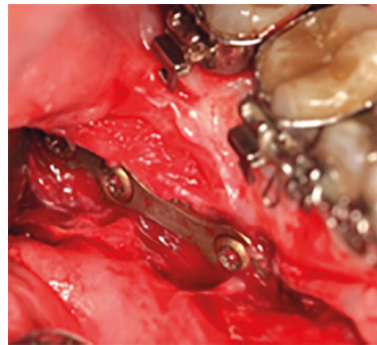


Figure 6 b Incision, and plate exposed in local anesthesia

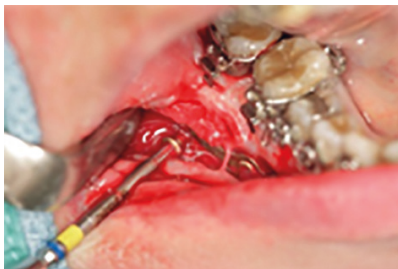

Figure 6 c Screws removed



Figure 6 d Miniplate and monocortical screws removed.

2.3 INDICATIONS AND PATIENT RELATED MOTIVES FOR HAVING BSSO

A BSSO is performed in adult patients that have a discrepancy in the relationship between the upper and lower jaw, which is too severe for correction by camouflage treatment or facial orthopedics during growth (Kinzinger et al. 2008). A Finnish study found that a large majority (84%) of the patients were referred for BSSO because of mandibular retrognathia, combined with an open bite (9%) or a deep bite (6%) (Forssell et al. 1998). The patient has to have a severe skeletal discrepancy and at least one additional clinical symptom, problem or disease to fulfill the uniform criteria for access to orthognatic surgery in governmental hospitals in Finland (Ministry of Social Affairs and Health 2010). Such symptoms and signs could be that the patient has a serious problem in chewing food, speech problems, obstructive sleep apnea or another serious functional problem or disease. This reflects the Scandinavian tradition that malfunction is a better accepted than esthetics as an indication for treatment, even though patients with compromised esthetics or function can be referred for social and psychological reasons.

Some Finnish studies on the motives for Finnish orthognatic surgery patients seeking treatment have been published. According to Forssell et al. (1998), highly ranked motives for seeking orthognatic surgery treatment were: the correction of occlusion (92%), reasons related to temporomandibular dysfunction (TMD) (70%), better chewing ability (68%) and unsatisfying dental esthetics (67%). Facial esthetics was usually not the reason for undergoing the treatment. Factors such as self-esteem and social interactions were not highly ranked. These results are in line with those of another Finnish study from the late 1990's (Nurminen et al. 1999), which reported that 68% of the patients had problems chewing food and eating. Many patients also had TMD complaints (32%) and headache (32%). Yet, only 36% were dissatisfied with their facial appearance. A study conducted 10 years later reported the main reason for orthognatic treatment in Finland was regular headache and facial pain (43%), TMD problems (30%) and difficulties chewing food (23%) (Pahkala and Kellokoski 2007). In that later study only 11% were dissatisfied with their facial appearance. This shows that one of the main motives for seeking orthognatic treatment in Finland has consistently been TMD complaints (30 -70%) (Forssell et al. 1998, Nurminen et al. 1999, Pahkala and Kellokoski 2007). Consequently, the question that arises is how reliable is orthognatic surgery at solving TMD problems in patients with facial malformations. Can we reliably meet these patient's needs?

In the above mentioned Finnish studies a wide majority of patient's motives for undergoing orthognatic surgery were functional concerns, related to TMD, occlusion or chewing ability. In other countries the motive for seeking treatment have tended to be esthetic concerns, although TMD has also been an important reason (Espeland et al. 2008). A study from the US reported that 26% of male and 46% of female

patients had TMD concerns (Phillips et al. 1997). A recently published Chinese study (Yu et al. 2013) found the major motives for orthognatic surgery was the improvement of facial appearance (83.3%), occlusion (50%) and self-confidence (48.1%). Only a few patients in the same study gave TMD (14.8%) and headache (2.8%) as the reason for having treatment. There has also been a shift in patients today towards treatment motives that focus on self-appearance, self-esteem and social functioning in Finland. A recent doctoral thesis by Silvola (2014) showed that both functional and esthetics reasons matter, and that orthognatic surgery has an impact on the quality of life in patients with compromised facial esthetics (Silvola et al. 2014). Many orthognatic surgery patients have experienced bullying, many of them also have a poorer body image and significant psychological symptoms (Alanko et al. 2014). It has been shown, that compromised facial esthetics has such a far-reaching impact on the patient's everyday life and wellbeing, thus esthetic reasons for orthodontics and orthognatic surgery should be recognized and approved, in addition to occlusal and functional indicators. An increasing number of patients are also treated for general health concerns, related to obstructive sleep apnea, especially in patients with a rethronatic mandible (Raunio et al. 2012). What are the factors, which at the end of the day matter to the patient, and increase patient satisfaction and overall patient well-being?

2.4 TISSUE HEALING

2.4.1 Normal tissue healing

Wound healing is a co-ordinated, complex and well-regulated process. An uneventful surgical wound in the oral cavity, heals by primary healing. The healing process can be divided into four phases in the following order: hemostasis, inflammation, proliferation and tissue remodeling. Every phase is highly regulated and requires a certain amount of time (Schreml et al. 2010).

The healing phase begins with hemostasis, which consists of vascular constriction and blood-clot formation. The wound area then releases growth factors and cytokines. Inflammatory cells (neutrophils, macrophages and lymphocytes) then migrate to the wound site. The neutrophils clean the wound from debris and form a defense against microorganisms, which help prevent microorganisms from invading the fresh wound. At the end of the inflammatory phase the macrophages stimulates keratinocytes, fibroblasts and induces angiogenesis. These factors thereby promote the transition from the inflammatory to the proliferatory phase. The proliferation phase follows, and partly overlaps with the inflammatory phase. The proliferative phase is characterized by epithelia formation. During this stage there is capillary growth, re-epithelialization, collagen formation and formation of granulation tissue.

After this, the wound enters the final maturation stage. This may last for many years. During this period vascular density returns to normal. There is a contraction of the wound during the whole healing process (Guo and Di Pietro 2010).

2.4.2 Factors affecting tissue healing

If there is any disturbance in the delicate process of normal tissue healing, the wound healing will be compromised or delayed. There are many local and systemic factors that affect this process (Guo and Di Pietro 2010).

Local factors that affect healing are oxygenation, venous sufficiency, infection and foreign bodies. There are many systemic factors that can compromise or delay the healing process. Any condition that reduces normal tissue oxygenation will impair healing. Hypoxia can amplify the early inflammatory response and thereby prolong healing of the injury, by increasing the levels of oxygen radicals in the wound area. Other factors that affect healing are age, gender and sex hormones. Stress, malnutrition, smoking and heavy alcohol consumption can also adversely affect healing. Many diseases such as diabetes, hereditary healing disorders and obesity also adversely affect healing. Medications that affect clot formation in the blood, blood platelet function, inflammatory response or cell proliferation, such as glucocorticoids and nonsteroidal anti-inflammatory drugs, which are routinely used in orthognatic surgery, can also negatively affect healing.

2.5 COMPLICATIONS IN BSSO PATIENTS

The term complication is used in this thesis as “an unintended consequence of the surgery that causes harm to the patient, occurring either intraoperatively or postoperatively” (Steel and Cope 2012, p. 1678). Compromised healing, on the other hand, is to be understood and used in this thesis to define a healing process that is prolonged or complicated, without any consequences on the final result.

The BSSO procedure is considered to be a safe and reliable surgical procedure nowadays, but as in surgery in general there is and will always be a risk for complications and uneventful healing. Orthognatic surgery patients can have complications before, during or after the actual surgery (Robl et al. 2014). In general, complications can be divided into rare complications, which might even be life-threatening, or into complications that can be expected as a relatively normal consequence in the treatment of a specific condition. Surgical experience also has an impact on the type and incidence of complications (Al-Nawas et al. 2014).

2.5.1 Rare complications

There is a wide variety of case-reports of rare complications that are published in the literature, even though serious or life threatening events are quite uncommon in BSSO patients nowadays. Complications can be related to the surgical technique or to other parts of the process (Chow et al. 2007). These can be related to the anesthesia, positioning of the patient during surgery and other factors related to the intraoperative process. The full medical history of the patient is of the utmost importance. The patient can still have undiagnosed conditions, which can lead to serious complications (Van De Perre et al. 1996). When intermaxillary fixation was used in surgery, vomiting and aspiration after anesthesia was a feared complication (Guernsey and DeChamplain 1971).

There is only one reported death in the literature. A 17 year old male who had undergone BSSO and genioplasty and died of cardiac arrest six hours after surgery (Van De Perre et al. 1996). The most likely cause of death was a preexisting cardiomyopathia. Respiratory difficulties after surgery are possible and foreign bodies can accidentally be aspirated (Steel and Cope 2012). Tracheostomies have been reported in a few patients due to excessive swelling that compromised the airways after BSSO (Telzrow et al. 2005), although the airway in most patients is unaltered. Meisami et al. (2007) could not detect any postoperative airway edema by magnetic resonance imaging, even after bimaxillary procedures, despite there being visible extra oral swelling.

Facial nerve injuries have been reported in a few BSSO patients. Most of them resolve over time (Lanigan and Hohn 2004, Telzrow et al. 2005, Sammartino et al. 2005, Choi et al. 2010, Ruiz and Lara 2011). The probable mechanisms for facial nerve palsy are damage or pressure of the nerve trunk during retraction of tissues by instruments, by damage from fractured bone segments, compression due to excessive postoperative swelling, variation of anatomical course that altered the need for protection of the nerve during surgery or due to ischemia caused by vasoconstrictors injected in the operating field (Rai et al. 2008).

Breakages of instruments and contamination by surgical materials were reported in 1% of the patients in one study (Kim and Park 2007). Foreign bodies can sometimes be left in the operating field (Kim and Park 2007, Telzrow et al. 2005). Typical examples of foreign bodies in BSSO patients are orthodontic brackets, screw posts and broken drills (Sousa and Turrini 2012). Excessive attempts to remove such debris often cause more damage to the patient than leaving these debris *in situ*. When they are *in situ* foreign objects seldom cause any problems to the patient.

2.5.2 Serious hemorrhage

Today hypotensive anesthesia, slightly elevated head position, vasoconstrictors and good surgical hemostasis have diminished the numbers of bleeding complications.

Serious bleeding episodes are very rare today. The reason for serious intraoperative hemorrhage is usually technical or due to anatomical problems that lead to a tear or cut of a major vessel. Compromised visualization of the operating field, lack of recognition of vascular structures or altered anatomy may lead to serious bleeding complications (Sousa and Turrini 2012, Robl et al. 2014). There are reports in the literature that life-threatening bleedings have been caused by a pseudo aneurysm in the facial (Pappa et al. 2008) or maxillary (Silva et al. 2007) arteries after BSSO surgery. Major hemorrhage in BSSO patients can occur from the maxillary artery or vein, the facial artery or vein, the inferior alveolar artery or the retromandibular vein.

A Finnish study (Panula et al. 2001) reported one serious bleeding episode in a BSSO patient after a tear of the left internal maxillary artery with a blood loss of 4000 ml in one hour: the normal blood loss for BSSO is under 350 ml. Those same authors also reported severe bleedings that required transfusion in a few BSSO patients. Another study reported 15 cases of serious bleeding caused by the rupture of the retromandibular vein (Telzrow et al. 2005). In a study of 1000 orthognatic patients in the US, no serious bleedings were registered (Robl et al. 2014). A great majority of the rare excessive bleeding events in orthognatic surgery patients were reported among Le Fort I osteotomy patients (Robl et al. 2014).

Bleedings can be managed by using surgical hemostasis (i.e. electrocoagulation, clipping, ligation), packings, injections of vasoconstrictors, pressure on site or with the help of interventional radiology (Robl et al. 2014). Very few hematomas require evacuation (Sousa and Turrini 2012).

2.5.3 Infections

A clean-contaminated wound is present in BSSO patients. A foreign body, i.e., osteosynthesis material, is furthermore inserted into the wound area. Despite this, serious and life threatening infections are fortunately rare and wounds in the oral cavity usually heal uneventfully. Osteomyelitis (Telzrow et al. 2005, Salman et al. 2011) and actinomycosis (Schwartz and Wilson 2001, Chow et al. 2007) have been reported in a few BSSO patients. In one study 2.8% of orthognatic patients had an infection that required an extra oral incision and drainage (Telzrow et al. 2005), but most infections are local and can be treated successfully by antibiotics and intraoral drainage (Chow et al. 2007, Robl et. al. 2014). A Finnish study reported an infection rate in orthognatic patients of 4% (Panula et al. 2001). Infections are also one of the main reasons for removal of the osteosynthesis material in many studies (Panula et al. 2001, Bhatt et al. 2005, Falter et al. 2011, Verweij et al. 2014). These studies reported the infection rates for orthognatic surgery patients in general, which included both maxillary and mandibular procedures. There is however a lack of knowledge about the rate of infections specifically in BSSO patients.

All oral and maxillofacial surgeons that perform orthognatic surgery have experienced surgical site infections (SSI) in BSSO patients. Infections are quite common and probably underreported in the literature. There is, therefore, a need for studies on the occurrence of infections. The SSIs lead to additional interventions, unnecessary suffering and add to costs. However SSIs seldom alter the final treatment outcome or are life-threatening *per se*. Consequently, the question arises: are there any factors that could be altered by the surgeon or by the patient that would decrease the risk for infections, and thereby diminish the need for secondary interventions or the use of antibiotics?

2.5.4 Bad split

Unfavorable fractures were a feared complication when BSSO surgery was introduced. In 1971 a rate of 22.7% was reported in 22 patients (Guernsey et al. 1971). A typical bad split can be a fracture of the condyle, the coronoid process, the lingual plate of the anterior fragment or the anterior buccal plate of the distal fragment (Telzrow et al. 2005). The most frequent bad split fractures are the buccal plate of the proximal fragment and the posterior aspect of the distal segment (Chrcanovic and Freire-Maia 2012). Another study reported 11 buccal plate fractures, five fractured lingual plates and one fracture of the condylar neck , a total of 17 bad splits in 427 patients (4.0%) (Mensink et al. 2013). All were unilateral, and the planned BSSO procedure for some patients was altered or postponed.

During the years the splitting technique has been revised and improved (Dal Pont 1958, Hunsuck 1968, Obwegeser 2007, Steinhäuser 1996, Monson 2013, Böckmann 2014, Patel and Novia 2007) and today the split of the mandible is highly predictable. Originally the whole width of the ramus was split with the Obwegeser-Dal Point technique. In the early years the bad split rate was as high as 23% (Guernsey and DeChamplain 1971). A total bad split rate of 5.4% was reported in the retrospective study by Al-Nawas et al. (2014). Those authors also reported that the Obwegeser-Dal Point technique used in the same study resulted in a bad split rate of 7.5%, but when the distal osteotomy line was advanced to the retrolingular depression, as in the Hunsuck-Epker technique, the bad split rate decreased to 3.8%. Moreover, the bad split rate for novice surgeons was 8.9% compared with 4.3% for more experienced surgeons (Al-Nawas et al. 2014). However, another study found no difference in the rate of bad splits between senior staff and residents (Mensink et al. 2013). Robl et al. (2014) reported a bad split rate of 3.9%, the corresponding rate in a Finnish study being 2% (Panula et al. 2001). It can be concluded that the mandibular split is technique sensitive, but bad split complications can be reduced to a minimum with careful handling and surgical experience. With modern osteosynthesis techniques most bad splits can be successfully treated, without intermaxillary fixation or impact

on the final result, and now bad splits can be regarded as complications without long term consequences (Verweij et al. 2014).

2.5.5 Neurosensory disturbance

Since the first reported orthognatic surgery procedure was reported (Whipple 1898) there has been an ongoing discussion among oral and maxillofacial surgeons concerning neurosensory disturbance (NSD) after mandibular osteotomies. The procedure has been refined over the intervening years, but still a great majority of BSSO patients report NSD. An incidence of 95.5% for NSD was reported by Guernsey and DeChamplain (1971). In the same paper the authors also reported that the IAN was avulsed from the mandibular canal in as many as 13.2% of the patients. A recent study reported an incidence of 81% for NSD at six months after BSSO, but some of these patients also had a genioplasty simultaneously (Essik et al. 2007). Genioplasty is known to increase the rate of NSD. Disturbing NSD has been reported in 0-8.5% (Ylikontiola et. al 1998, Panula et al. 2001, Panula et al. 2004, Thygesen et al. 2008) and chronic neurophathic pain in 0-5% (Ylikontiola et al. 1998, Marchiori et al. 2013, Jääskeläinen et al. 2004) one year after BSSO. Although there has been a definition for neurophathic pain (Merskey 1986), it is likely that disturbing NSD and chronic neurophathic pain describe the same condition, at least as described in earlier publications. No nerve injury at all can be detected for a very few patients (2.5%) after careful subjective and objective examinations during surgery, and a follow up of 12 months (Jääskeläinen et al. 2004). The NSD will usually resolve in most patients or be minor in everyday life over time.

A previous study suggested multiple risk factors for NSD such as age, gender, range of movement, operation time (Sickels et al. 2002). The operation technique and the morphology of the mandible seems to have a great influence on the incidence of nerve injury and thereby of NSD. Manipulation of the IAN has also been shown to increase NSD (Ylikontiola et al. 2000). A lateral course of the mandibular canal (Ylikontiola et al. 2002), in a mandible with a small bone marrow space and a long mandibular angle may increase the risk for injury to the IAN (Teerijoki-Oksa et al. 2002, Yamauchi et al. 2012). A small distance between the lingula and the mandibular notch has also been shown to increase NSD (Kuroyanagi and Shimozato 2013). This is probably related to the fact that prolonged compression and stretching of the medial tissue has been shown to increase NSD (Teerijoki-Oksa et al. 2002, Panula et al. 2004). Increasing age of the patient has also been shown to increase the occurrence of NSD (Ylikontiola et al. 2000, Espeland et al. 2008, Mensink et al. 2012, Marchiori et al. 2013). Moreover, female gender and depression have been shown to increase the risk for neuropathic pain (Marchiori et al. 2013).

Orthognatic surgery patients with NSD can have hypoesthesia, paresthesia or dysesthesia. They describe these symptoms as numbness, a rubbery or wooden like

feeling (hypoesthesia), as tingling, tickling or pulling (paresthesia) as tenderness, or a burning or electric sensation (dysesthesia) (Phillips et al. 2006). Patients with neuropathic pain describe harsher symptoms such as severe burning, stubbing, cold-freezing, aching, wrenching or electric shocks. They also describe the symptoms as terrible and unbearable (Marchiori et al. 2013). These descriptions of NSD have dimensions that show the importance of subjective evaluation of the outcome.

Damage of the IAN and associated NSD can be examined in a several ways, and today there is still no consensus for identifying and evaluating the severity or monitoring the recovery of an injury to the IAN (Poort et al. 2009, Colella et al. 2007, Agbaje et al. 2015). Interviews or self-administered questionnaires, clinical neurosensory tests or clinical electrophysiological tests have been suggested (Ylikontiola et al. 1998, Teerijoki-Oksa et al. 2003, Poort et al. 2009, Agbaje et al. 2015). An ideal test should be sensitive enough to be positive for any injury of the nerve and simultaneously be negative in the absence of the same (Ylikontiola et al. 2000). At surgery the nerve can be visibly inspected for lacerations or loss of continuity. The degree of manipulation of the IAN can also be recorded. Different clinical and electrophysiological methods evaluate different sensory fibers, and the results show a wide variation. The incidence can vary from 10-94% in the same population depending on the testing site and method chosen (Teerijoki-Oksa et al. 2003). The widely used clinical neurosensory tests include: brush stroke directional discrimination, sharp and blunt discrimination, touch detection threshold, two point discrimination and warm/cold discrimination tests. More advanced neurophysiological tests that are used for the IAN include semi-subjective quantitative sensory tests such as cold detection or pain threshold and warm detection threshold or heat pain threshold tests. Objective electrophysiological tests such as the mental nerve blink reflex and nerve conduction tests measure nerve conduction without any patient related evaluation (Teerijoki-Oksa et al. 2003, Poort et al. 2009, Agbaje et al. 2015).

Sophisticated and costly neuro- or electrophysiological tests are not available to the clinician in many clinical settings. Therefore, it is of great importance to be able to identify patients at risk for NSD using pre- or intraoperative findings and/or subjective symptoms reported by the individual patient. If the patients at risk could be identified, then the treating surgeon could apply treatment that diminishes the suffering from severe NSD or neuropathic pain, either prophylactically or at an early stage. Are there factors that can be altered or taken into consideration by the surgeon that will also decrease NSD? This is a question that still requires an answer.

2.5.6 TMD and complications

Few perioperative surgical complications of the temporomandibular joint have been reported in the literature. There are case reports about bad split fractures of the condylar head (Telzrow et al. 2005) and dislocation of the condylar head from the glenoid fossa (Mitsukava et al. 2013, Guernsey et al. 1971). Excessive stripping during BSSO, which decreases oxygenation and nutrition of the condylar head, should be avoided. Wide, forceful and long lasting mouth opening for visualization of the operating field during surgery will probably adversely affect the temporomandibular joint and surrounding tissues, which increases the risk of TMD.

There has been great confusion and a variety in terminology that describes the remodeling of the temporomandibular joint, and especially the condylar head, after orthognatic surgery in some patients. Terms such as aseptic necrosis (Lanigan and West 1990), idiopathic condylar resorption (Arnet et al. 1996), idiopathic condylolysis (Wolford and Cardenas 1999), condylar atrophy, dysfunctional remodeling of the condyle or progressive condylar resorption have all been used to describe the decrease in volume of the condyle that can occur after a successful treatment. This confusion of terminology reflects the fact that the underlying mechanisms behind the alterations in the temporomandibular joint after surgery are still debated.

Pathologic remodeling of the condyle (Panula et al. 2001, Borstlap et al. 2004, Kobayashi et al. 2012, Dicker et al. 2015) has been a debated topic in oral and maxillofacial surgery over the years. It has been shown that 4-11% of the patients end up with pathologic condylar resorption after BSSO (Borstlap et al. 2004, Panula et al. 2001). A recently published study, however, showed that as many as 55% of the patients have minor alterations of the condylar volume when the condyles were evaluated by cone beam computer tomography (Xi et al. 2015). Nevertheless, the condylar remodeling was reported to have had an impact on the treatment result in only a few of these patients. In contrast, severe condylar resorption will decrease the height of the ramus and change the position of the mandible, which leads to alterations of the occlusion or to skeletal relapse. Some patients with condylar resorption end up with TMD symptoms and others not, and the risk factors for manifest TMD symptoms are still unidentified. The exception is patients with known condylar pathologies, such as rheumatoid arthritis. Therefore the question arises: is a moderate remodeling of the bony structures a pathologic process, or a functional adaptation to altered occlusal forces that occur after surgery?

The most common cause of pain and musculoskeletal problems, and the clinical findings we usually refer to when patients have pain in the temporomandibular joint and surrounding structures is TMD. TMD includes a wide variety of musculoskeletal symptoms and pain that emanate from the temporomandibular joint or surrounding musculoskeletal structures (Scrivani et al. 2008, Al-Riyami et al. 2009a). Common findings related to the joint are hypomobility or deviations of the jaw, locking,

luxation or joint sounds. The masticatory muscles are usually tender to palpation. Many patients also suffer from ear ache, tensional head ache and neck pain. TMD is most common in young female adults, and there are indications that symptoms resolve spontaneously. TMD symptoms and clinical findings fluctuate over time (Magnusson et al. 2005). Depression, anxiety and stress often increase TMD symptoms. There has been strong believe among clinicians that a good occlusion will solve or prevent TMD problems, even when there is a scant evidence in the literature and great variability among the few studies that do exist (Al-Riyami et al. 2009a, Al-Riyami et al. 2009b). Thus, the causal link between TMD and malocclusion is largely unproven. For example, a Finnish prospective study found that 73.3% of orthognatic surgery patients had TMD at the beginning of treatment, and after a mean follow-up time of four years 60% of the patients still had TMD (Panula et al. 2000). They were not able to show that a specific malocclusion predisposed to TMD, even when it has been suggested that patients with mandibular retrognathia benefit from a lengthening of the mandible. Patients with mandibular retrognathia, often move the mandible forward to improve esthetics and facilitate breathing. This action can result in continuous muscle activity and tension, which leads to tensional pain in the masticatory muscles. Is a lengthening of the mandible a solution for these patients?

During surgery the correct positioning of the condylar head in the glenoid fossa is of the utmost importance (Patel and Novia 2007). The positioning of the condylar head is performed blindly, thus it is mostly in the hands of the surgeons experience and therefore prone to alterations. There have been attempts to develop different condylar positioners during the years (Lindqvist and Söderholm 1988). Deviations from the normal condylar position will result in a torque of the condylar head, which most probably will have an adverse impact on the treatment outcome.

During surgery the mandible is usually secured into the new position either with bicortical positional screws or with miniplates and monocortical screws. A rigid fixation may force the fragments in the wrong position and thereby cause a torque of the condylar head. Semi-rigid fixation with the aid of miniplates seems to be more forgiving than rigid-fixation with bicortical positional screws, and thereby potentially cause fewer TMD problems in the long-run. Yamashita et al. (2011) found no significant difference in masticatory function during the first postoperative year when patients had undergone fixation with miniplates were compared to those that received fixation with bicortical screws. However, when the follow-up was continued, they showed fewer TMDs in the patients that had undergone fixation with miniplates.

Even at a time when TMD and condylar pathologies are one of the main topics in orthognatic surgery many questions still remain, three of which are: Is orthognatic surgery really a solution for patients with TMD? Why do some patients benefit from

the treatment and some not? Is there any way to identify patients at risk for TMD in the early stages of treatment planning?

2.6 FACTORS THAT AFFECT PATIENT SATISFACTION

There is a growing awareness that patient satisfaction is a central factor when the quality of medical care is evaluated. Patient satisfaction is the fulfillment of the patients' needs or wants, or in other words the patients' met or unmet expectations. The patients' expectations or even the referring colleagues', expectations can be unrealistic, and thereby difficult or impossible to meet. It is also true that most patients pre-visit expectations of what would happen are realistically lower, than their ideal picture of the visit or treatment (Bowling et al. 2012). If the patient's expectations are not in line with the outcome of the treatment process, then the patient's satisfaction response will be lower (Bowling et al. 2012, Bowling et al. 2013, Kennedy et al. 2014, Danforth et al. 2014, Cunningham and Shute 2008). It has been shown that complications decrease patient satisfaction (Danforth et al. 2014), though there are studies that report the opposite (Kennedy et al. 2014). Kennedy et al. (2014) concluded that factors other than the surgical outcomes appear to influence upon the patients perceptions of the treatment.

Patients seeking medical care do not only have high expectations regarding the final outcome of the treatment, they also expect a knowledgeable doctor and a reduction or even total elimination of symptoms. There are many factors during the treatment period that affect the patient's expectations of health care services, which include: the healthcare structures, processes and health outcome (Bowling et al. 2012). Healthcare structures include buildings, equipment and staff. Healthcare processes can be represented by protocols for treatment referral and waiting lists, or the interaction between staff and patients. Health outcome is the result of the medical treatment on patient's health and wellbeing.

The surgeon's communication skills and emotional intelligence make a difference (Bowling et al. 2012, Bowling et al. 2013, Danforth et al. 2014). It is important to establish a working relationship with the patient. Patients expect that the surgeon show interest in them, explain their medical conditions, invite the patients to ask questions and answer these in terms and expressions that are familiar to the patient (McLafferty et al. 2006, Bowling et al. 2012). It can be concluded that the things that matter most to the patients are effective communication, adequate information and good outcomes (Bowling et al. 2013).

There are multiple ways to measure patient satisfaction. Kennedy et al. (2014) used the question "would you recommend this treatment to your friends or family" (Kennedy et al. 2014). Another possible question could have been "would you choose the same treatment again?" Questions related to patient satisfaction are of

importance, in addition to questions about the treatment process, when the quality of medical care is evaluated. To date there are very few studies on the factors that affect treatment expectations and treatment satisfaction in BSSO patients. At the end of the day, are positive answers to the aforementioned questions the things that really make a difference to the patient?

3 AIMS OF THIS STUDY

The general aim of this study was to identify the occurrence and predisposing factors of complications and compromised healing in BSSO patients. The specific aims of the study were to study the following:

- identify the need for having symptomatic titanium miniplate removal after BSSO and the factors that contribute to it (**Study I**)
- determine the risk factors for SSI after orthognatic surgery and their occurrence (**Study II**).
- determine the risk factors for NSD at one year after BSSO and their occurrence (**Study III**)
- determine the impact of NSD on patient satisfaction (**Study III**).
- determine the impact of forward BSSO on TMD one year after surgery (**Study IV**).

4 HYPOTHESES OF THIS STUDY

The general hypothesis for this study was that there are factors that can be identified, which will increase complications or compromised healing in BSSO patients, and thereby decrease patient satisfaction.

The specific hypotheses for this study were that:

- there are factors that increase the need for the removal of osteosynthesis supporting material and influence on the occurrence of SSI (Study I and II).
- there are factors that increase NDS in BSSO patients (Study III).
- patients with mandibular rethrogнатia benefit from orthognatic surgery in respect to TMD (Study IV).
- complications and compromised healing following BSSO decrease patient satisfaction (study III).

5 PATIENTS AND METHODS

Detailed descriptions of the materials and methods of all four studies are given in the respective published manuscripts, which are also included in this dissertation. Briefer descriptions of the materials and methods of all four studies are given below.

5.1 STUDY POPULATIONS

This study comprised four populations of patients treated for facial dento-skeletal malocclusions at the Department of Oral and Maxillofacial Diseases, Helsinki University Central Hospital, Helsinki, Finland.

Study I

The medical records of patients who had undergone BSSO between January 1st 1997 and December 31st 2003 were identified from the database of the Department. Those patients who had undergone fixation with titanium miniplates and monocortical screws were included in the analysis. Patients with any other type of surgical procedure or fixation were excluded. A total of 159 patients met the inclusion criteria. Medical records of six patients were not found, which left 153 patients (96%) for the analysis.

Study II

The medical records of patients who had undergone one jaw surgery of the mandible (i.e., BSSO with or without simultaneous genioplasty) or maxilla (i.e., Le Fort I osteotomy) between January 1st 1997 and December 31st 2003 were identified from the database of the Department. Those patients who had had a follow-up of at least 30 days were included in the analysis. The medical records of 286 patients were retrieved. The records of nine patients (3.0%) were unrecoverable.

Studies III and IV

Volunteer patients with skeletal class II malocclusion who were scheduled to undergo BSSO and fixation by miniplates were recruited at the Department between November 1st 2006 and June 15th 2008. A one year follow-up was required as an inclusion criterion for the patients and this was used in the final analysis. Forty-three patients agreed to participate. Two of them did not appear at the one-year follow-up, which left 41 completers for Study III. One further patient in Study IV was excluded because resorbable miniplates had been used in her BSSO, which left 40 completers.

5.2 OUTCOME VARIABLES

The main outcome variable in Study I was the removal of at least one symptomatic titanium miniplate, whereas in Study II the main outcome variable was SSI. The main outcome variables in Study III were NSD and patient satisfaction at one year after surgery. The main outcome variable for Study IV was temporomandibular function at one year after surgery.

5.2.1 Definition of surgical site infections (Study II)

SSI was defined as a prolonged alteration in wound healing (i.e., wound dehiscence), formation of granulation tissue, local swelling and redness, or abscess formation.

5.2.2 Evaluation of neurosensory disturbance and patient satisfaction (Study III)

All enrolled patients were interviewed according to a standard protocol at one year after surgery by the author (MK). The patients were asked whether they experienced NSD or not. They were instructed to report any alteration or disturbance in sensation. In the event that NSD was reported to be present the patients were asked about the degree of harm of NSD. The degree of harm was categorized as follows: no harm, slight harm or major harm.

Patients were also asked about their satisfaction regarding the treatment. Satisfaction was categorized as follows: satisfied, fairly satisfied or not satisfied. In addition, patients were asked whether they would be prepared to undergo the same treatment again.

5.2.3 Evaluation of TMD (Study IV)

TMD was evaluated by using the Helkimo Anamnestic index (Ai) and also the Dysfunction index (Di) (Helkimo 1974).

The Ai is an index that is based on an interview with the patient. The Ai score has three grades. Ai 0 indicates a subjectively symptom-free situation. The group with mild symptoms (Ai I) comprise patients with one or more of the following symptoms: temporomandibular joint sounds, feeling of fatigue of the jaws or feeling of stiffness of the jaws on awakening or on movements. Patients with severe symptoms of dysfunction (Ai II) have one or more of the following symptoms: restricted mouth opening, locking or luxation of the joint, or pain in the temporomandibular region or pain of the masticatory muscles during mandibular movement.

The Di is an index that is based on a clinical examination. The following five clinical dimensions are evaluated on a three graded scale: the range of mandibular

movement, the function of the temporomandibular joint, pain during mandibular movement, pain when the masticatory muscles are palpated or temporomandibular joint pain. These five findings are scored individually according to the severity of impairment of the dimension. The scores for the individual findings are added and summed giving four grades of severity of clinical dysfunction: symptom free (Di 0), mild dysfunction (Di I), moderate dysfunction (Di II) and severe dysfunction (Di III). The patients must have multiple mild or one severe finding to be classified as having a moderate dysfunction. The patients with severe dysfunction must have at least two of the five dimensions to be categorized as severe.

5.3 PREDICTOR VARIABLES

The predictor variables in Study I were age, gender, smoking status (i.e. smoker or non-smoker), type of BSSO surgery (i.e. mandibular advancement, set back or rotation), extent of skeletal movement (in mm), and duration of operation (in minutes).

The predictor variables in Study II were age, gender, general disease (categorized as yes or no), smoking status (i.e. smoker or non-smoker), type of surgery (i.e. BSSO or Le Fort I), duration of operation (in minutes), type of osteosynthesis material used (i.e. titanium or bioresorbable miniplate) and the use of postoperative drains (categorized as yes, no, or unknown).

The main predictor variable in Study III was the degree of manipulation of the IAN. The degree of manipulation of the IAN was based on intraoperative observations and recorded as not exposed, exposed, dissected from the underlying bone, lacerated or loss of continuity. Other predictor variables were gender, age, smoking status (i.e. smoker or non-smoker), the extent of mandibular advancement (categorized as < 5 mm as small, 5-7 mm as medium, and > 7 mm as large), and duration of operation (in minutes).

In Study IV, preoperative Ai and Di were compared to the respective postoperative indices.

5.4 STATISTICS

The Chi-squared test was used to evaluate the statistical significances of the associations between the outcome and predictor variables in Studies I, II and III. In addition, logistic regression analyses were used in Studies I and II to evaluate further the adjusted associations. In Study IV, the preoperative and one-year postoperative prevalences of TMD were presented in percentages (measured by Di and Ai).

5.5 ETHICAL CONSIDERATIONS

Studies I and II were approved by the Internal Review Board of the Division of Musculoskeletal Surgery, Helsinki University Central Hospital, Finland.

The protocols of Studies III and IV were approved by the Research Ethics Board of the Department of Surgery and the Internal Review Board of the Division of Musculoskeletal Surgery, Helsinki University Central Hospital, Finland. All patients in Studies III and IV signed a written consent, and they also signed an agreement that their clinical photographs may be published.

6 RESULTS

6.1 FACTORS AND THEIR PREVALENCES THAT CONTRIBUTED TO THE REMOVAL OF SYMPTOMATIC TITANIUM MINIPLATES AFTER BSSO (STUDY I)

A total of 153 BSSO patients fulfilled the inclusion criteria for study I. The great majority of the patients were healthy (150 patients, 98.0%). One patient had juvenile onset diabetes, and two patients had rheumatoid arthritis, without immunosuppressive medication. One of the rheumatoid arthritis patients had a juvenile onset of the disease. Thirty-four patients (22.2%) were smokers and the records of nine patients contained no information of their smoking status. The great majority of the patients had mandibular rethrogathia. A total of 308 titanium miniplates had been inserted in the 153 patients. Two patients had an additional plate inserted because of a bad split. Almost all patients (97%) had a drain, which was used during the first postoperative day. The great majority of patients was healthy and also had postoperative drains inserted, thus no statistical analyses were made on these parameters. The descriptive statistics and key findings are presented in Table 1.

Twenty-nine patients (19.0%) had at least one symptomatic miniplate removed during follow-up. Seven patients were male (24.1%) and 22 female (75.9%). Both plates were removed for 14 patients, even though the patient had plate-related complications on only one side. A total of 56 plates (18.2%) were removed. The reasons for removal were plate-related complications (n=16 patients) and subjective discomfort (n=13 patients). Pictures of clinical findings in situations where the removal of the osteosynthesis supporting material was necessary are shown in Figure 7. Plate related complications were infection (n=12 patients) and screw loosening (n=4 patients). The osteosynthesis material was removed from 13 patients because of subjective discomfort, namely sensitivity to cold (n=4 patients), palpability (n=5 patients) and discomfort from foreign matter (n=4 patients). Twenty-nine of the plates (51.8%) were removed during the first postoperative year. Plate removal was more common in females, but the difference was not statistically significant.

In summary there was no significant association between plate removal and age, gender, type of surgery (i.e. mandibular advancement, set back or rotation), extent of skeletal movement or duration of operation. Smoking was the only significant predictor for plate removal ($p=0.032$).

Table 1 Symptomatic removal of osteosynthesis material.
Descriptive statistics and key findings for 153 BSSO patients Study I

Variable	Descriptive statistics				Miniplates removed		Statistics p
	Patients (n)	%	Average	Range	Patients (n)	%	
Gender	153	100			29	19.0	0.529
Female	90	41.2			22	24.4	
Male	63	58.8			7	11.1	
Age (years, continuous variable)			35.1	17.0-56.4			0.292
Smoking habits							
Non-smoker	110	71.9			18	16.4	0.032
Smoker	34	22.2			10	29.4	
Records missing	9	5.9			1	3.4	
Reasons for plate removal			Female	%	Male	%	
All removed plates	29	19.0	22	75.9	7	24.1	
Plate related	16	55.2	12	75.0	4	25.0	
Screw loosening	4	13.8					
Infection	12	41.4					
Other reasons	13	44.8	10	76.9	3	10.3	
Sensitivity to cold	4	13.8					
Discomfort	4	13.8					
Palpability	5	17.2					

Figure 7 Reasons for removal of osteosynthesis material after bony healing (Study I).

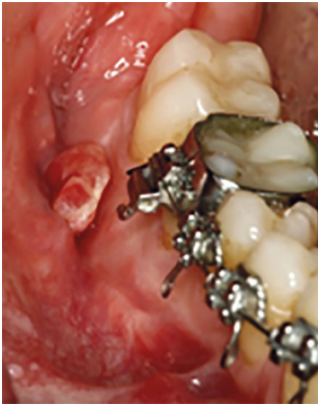

Figure 7 a Granulation tissue and local infection.

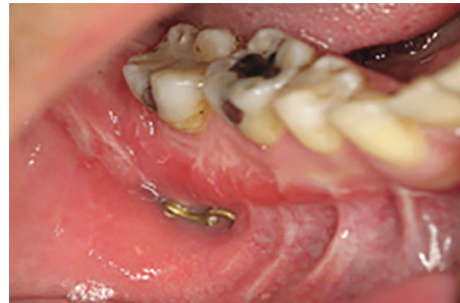

Figure 7 b Exposure of osteosynthesis material.

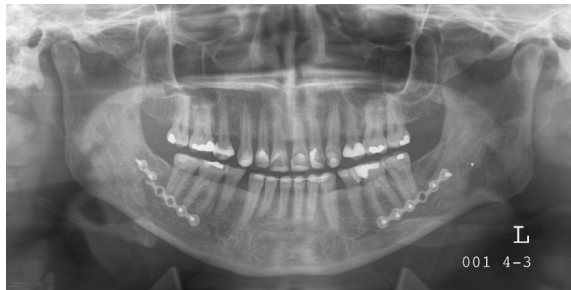

Figure 7 c Fracture of the osteosynthesis material to the right on the orthopantomogram.

6.2 RISK FACTORS AND THEIR PREVALENCES FOR INFECTIONS AFTER ORTHOGNATHIC SURGERY (STUDY II)

The descriptive statistics of the 286 orthognatic surgery patients, that fulfilled the inclusion criteria for study II, are shown in Table 2. The majority of the patients were female (60.8%).The patients were healthy in general. Eight patients (2.8%) had a general disease. Four patients had rheumatoid arthritis, two had diabetes (type one), one had scleroderma and one had Sjögren's syndrome. Seventy patients were smokers (24.5%). Most (86.7%) patients underwent mandibular surgery. Drains were used in almost all mandibular procedures (90.7%), and in none in the maxillary procedures. Titanium miniplates were used in 207 patients (72.4%). All patients received antibiotics perioperatively. The mean follow-up time was 29 months (Range 90 days to 7.6 years).

Twenty-six of the 286 patients (9.1%) had SSI. The wound remained open in 13 patients, granulation or slight local swelling occurred in 10 patients, and three patients had an abscess. The SSI healed spontaneously in three patients, oral antibiotics were required for 19 patients and intravenous antibiotics were given to four patients. In addition, three patients underwent incision and drainage of an abscess.

There was no statistically significant association between SSI and age, gender, general health status, type of surgery, duration of operation, type of osteosynthesis material used, and use of postoperative drains. Ten (14.4%) of the seventy smokers had an infection. The logistic regression analysis with all explanatory variables considered simultaneously, revealed that the only statistically significant risk factor for infection was smoking ($p= 0.023$).

Table 2 Descriptive statistics and results for 286 orthognatic surgery patients Study II

	Descriptive statistics				Infections		Significance
	Patients (n)	%	Average	Range	Patients (n)	%	p-value
Gender	286	100			26	9.1	0.671
Women	174	60.8			16	9.2	
Men	112	39.2			10	8.9	
Healthy	278	97.2			26	9.4	0.023
Smoking: Smoker	70	24.5			10	14.4	
Non smoker	228	79.7			16	7.0	
Age (years)			34.8	17.0-56.5			
Surgical procedure							0.626
BSSO (genioplasty n=6)	248	86.7			24	9.7	
Le Fort I (multipiece n=5)	38	13.3			2	5.3	
Drains: Drains	225	78.7			23	10.2	0.240
No drains	32	11.2			1	3.1	
Unknown	29	10.1			2	6.9	
Operation time (minutes)			154	75-320			
Type of osteosynthesis material							0.088
Titanium plates	207	72.4			16	7.7	
Bioresorbable plates	79	27.6			10	12.7	

6.3 FACTORS AND THEIR PREVALENCES FOR NSD, AND PATIENT SATISFACTION AT ONE YEAR AFTER BSSO (STUDY III)

The descriptive statistics and results for 41 patients fulfilling the inclusion criteria for study III are shown in Table 3. The majority of the patients were female (65.9%). The age range of the population was 22.2- 59.5 years (average 37.0 years). The patients were healthy in general. Three patients had hypothyreosis, one had migraine and one was obese. None of the patients had a health condition that altered the immune system or predisposed for NDS. Six patients (14.6%) were smokers. The average operation time was 127 minutes (range 75-240 minutes). Fifty out of 82 IANs (61%) were exposed, eight (9.7%) had to be dissected from the underlying bone, and four (4.9%) were lacerated. None of the nerves lost continuity. The lacerated nerves were not sutured or repaired in any way.

Table 3 Descriptive statistics and neurosensory disturbance (NSD) for 41 BSSO patients Study III

	Descriptive Statistics				NSD at one year follow up	
	Number (n)	Percentage (%)	Average	Range	Number (n)	Percentage (%)
TOTAL	41	100			37	90.2
Women	27	65.9			25	92.6
Men	14	34.1			12	85.7
Age			37.0	22.2- 59.5		
< 30 years	7	17.1			5	71.4
30-39 years	18	43.9			17	94.0
> 40 years	16	39.0			15	93.8
Smoking						
Nonsmoker	36	87.8			32	88.9
Smoker	6	14.6			5	83.3
Operation time	40*	100	127	75- 240	36	90.0
< 120 min	15	37.5			14	93.3
120- 140 min	15	37.5			13	86.7
> 140 min	10	25.0			9	90.0
Mandibular advancement						
< 5 mm	10	24.4			10	100.0
5-7 mm	19	46.3			16	82.2
> 7 mm	12	29.3			11	91.7
Nerve injury / nerve	82	100.0			56	68.3
Not exposed	20	24.4			11	55.0
Exposed	50	61.0			35	70.0
Dissected	8	9.8			6	75.0
Visible laceration	4	4.9			4	100.0

* Data for one patient missing

At the one-year follow up, 37 patients (90.2%) reported NSD. In two of the 41 patients (4.9%) NSD was severe, and classified as neuropathic pain.

NSD occurred more frequently after: laceration of the IAN (100%), its dissection (75%) and exposure (75%) than when the IAN had not been exposed at all (55%), but the differences were not statistically significant. There were no significant associations between NSD and gender, age, smoking status, extent of mandibular advancement, and duration of the operation.

Despite the NSD, 89.2% of the patients were satisfied or fairly satisfied with treatment and would choose the same treatment again. All four patients with nerve lacerations experienced NSD as a major burden. These four patients were not satisfied with the treatment and would not choose to have the same treatment again. Moreover, the NSD was classified as chronic neuropathic pain in two of these patients.

6.4 TMD BEFORE AND AT ONE YEAR AFTER BSSO IN PATIENTS WITH MANDIBULAR RETHROGNATIA (STUDY IV)

Descriptive statistics for the 40 BSSO patients that fulfilled the inclusion criteria for study IV are shown in Table 4. The patients were generally healthy. Three patients had hypothyreosis, one had migraine and one was obese. None of the patients had a health condition that could alter the immune system or predispose towards condylar pathologies, other than TMD. Six patients (15.0%) were smokers. Four patients had a slight flattening of the condyle in the preoperative orthopantomogram. The average forward movement of the mandible was 6.3 mm (range 4.5-10.0 mm) and in four patients the mandible was slightly rotated. One horizontal titanic miniplate was inserted on each side of the mandible in all the patients. All patients also had a surgical splint and light guiding elastics for the four first post-operative weeks.

At the first appointment, 17 out of 40 patients (42.5%) had a notation of TMD as one of the reasons for seeking treatment and 12 patients (30%) had a history of an occlusal splint due to TMD.

The Ai scoring revealed that 15 (37.5%) of the patients were symptom free, five (12.5%) had mild symptoms and 20 (50.0%) had severe TMD symptoms at the beginning of treatment. When the Di was used, 11 patients (27.5%) had no TMD, 14 patients (35.0%) had mild and 13 patients (32.5%) had moderate TMD symptoms before surgery. Two patients (5.0%) had severe symptoms before treatment according to Di.

The difference in Ai and Di scores are shown in Table 5. The majority of patients had no change in the TMD status (Ai 65%, Di 60%) at one year follow-up. Some patients improved (Ai 25%, Di 30%), whereas TMD symptoms worsened in four patients (Ai 10%, Di 10%).

Twelve patients were symptom free during the entire study period. Three symptom free patients developed mild symptoms, and one patient initially with mild symptoms ended up with severe symptoms, when the Di was used as the evaluation system. Twelve patients improved their Di/TMD scores. Of these 12, two patients with severe symptoms had mild symptoms at follow-up. The improvement in Di scores was explained by an amelioration in muscle related symptoms in the majority of patients. However, joint related symptoms increased in three of the four patients that had worsened symptoms.

When the Ai was used as the evaluation system the condition of four patients worsened. Three symptom-free patients ended up with severe symptoms. Ten patients improved, and of them five had mild symptoms and five were symptom free at one year follow-up .

The change in the severity of TMD symptoms in an individual patient following BSSO was unpredictable.

Table 4 Descriptive statistics for 40 BSSO patients Study IV

	Patients	%	Average	Range
Gender (female)	26	65		
Age (years)			36.9	22.2-59.4
Smokers	6	15		
Operation time (minutes)			123	75-165
Mandibular lengthening			6.3	4.5-10.0
Rotation of the mandible	4	10		

Table 5 Change in TMD in 40 BSSO patients with a one year follow up Study IV

TMD	Anamnestic index (Ai)		Dysfunction index (Di)	
	Patients (n)	%	Patients (n)	%
Change one year after surgery				
No change	26	65.0	24	60.0
Improvement	10	25.0	12	30.0
Impairment	4	10.0	4	10.0

7 DISCUSSION

7.1 METHODOLOGICAL ASPECTS

7.1.1 Study populations and sizes

The need for symptomatic removal of miniplates in BSSO patients (Study I) and the occurrence of SSI in patients after having orthognatic surgery (Study II) were analyzed retrospectively in both studies. A total of 159 patients in Study I who fulfilled the inclusion criteria were identified, but the files for six of these patients were not found, which left 153 patients (96.2%) for the final analysis. The records of 286 patients were retrieved in Study II. The records of nine patients were unrecoverable, and it is uncertain whether these patients would have fulfilled the inclusion criteria. Consequently, at least 97% of potential 295 patients were analyzed in Studies I and II. The numbers of patients in Studies I and II were sufficient for statistically robust analyses.

All patients who fulfilled the inclusion criteria for the prospective studies (III and IV) initially accepted to take part in the investigation. The drop-out rate was below 5%, thus both studies are strongly reliable (Zelle et al. 2013). All patients had skeletal class II malocclusion and underwent the same surgical procedure, which made the population homogenous. Patients were followed-up for at least one year, which is generally considered sufficient for nerve regeneration and subsequent evaluation of NSD (Mensink et al. 2014).

7.1.2 Indices for TMD

The goal of Study IV was to evaluate TMD by using a well-known and widely used index system (Ai and Di) in order to be able to compare the present study results with those of earlier studies. The system that was chosen, was initially published by Helkimo (Helkimo 1974). This system is well known and frequently used for evaluating orthognatic surgery patients (Al-Riyami 2009a, Al-Riyami 2009b), even though the knowledge about TMD related signs and symptoms such as joint sounds (Naeije et al. 2013) or bruxism (Lobbezoo et al. 2013), has increased since the Helkimo index was published. One shortcoming of Ai or Di indices are that they do not differentiate between the pathologies that occur in the bony structures of the jaw and those of the surrounding soft tissues. Another shortcoming is that the patient's psychological and behavioral profile is not taken into consideration.

The broadly used Research Diagnostic Criteria for Temporomandibular Disorders (RDC/TMD) (Dworkin and LeResche 1992, Truelove et al. 1992) could

have been another choice for Study IV. The RDC/TMD index has since been revised and refined (Ahmad et al. 2009, Schiffman et al. 2010). The latest version of this index would probably be the index of choice for a similar study today. The fact remains that a comprehensive research index should be in use for an extended time period to allow for direct comparisons of multiple well designed studies over lengthy periods of time (Abrahamsson et al. 2007). There are only a few studies on TMD before and after correction of dentofacial deformities by orthodontic and orthognatic surgery treatment that have used the RDC/TMD index for evaluation (Abrahamsson et al. 2013, Farella et al. 2007) and, as far as the author is aware, no studies have evaluated patients with mandibular rethronatia that was corrected by a lengthening of the mandible with the aid of BSSO.

7.1.3 Osteosynthesis technique

Miniplates and monocortical screws were used for all patients. They provide a semi rigid fixation, which allows small adaptive changes to the condyle. The use of bicortical screws can, at least in inexperienced hands, produce a torque of the condylar head, which may actually increase TMD after surgery. Bicortical screws can also damage or compress the IAN, if the screw accidentally penetrates the mandibular canal or the nerve is crushed between the bone fragments (Teerijoki-Oksa et al. 2002). It has been shown that bicortical screw fixation and miniplate fixation initially have the same treatment outcome with regard to alleviating TMD (Yamashita et al. 2007, Yamashita et al. 2011). However, bicortical screws associate more often with TMD symptoms with increasing follow-up times (Yamashita et al. 2011).

7.2 COMPROMISED TISSUE HEALING AND INFECTIONS

Tissue healing is a highly regulated and complex process that proceeds in a specific order over a certain amount of time (Schreml et al. 2010). There are many factors that can affect healing in patients that have undergone BSSO. These include age, gender, sex hormones, general diseases, medications and nutrition. Tissue oxygenation is of the utmost importance for successful healing. Foreign bodies can adversely affect tissue healing (Guo and DiPietro 2010). Some of these factors can be altered by the surgeon or by the patient and others not.

In Study II wound healing problems and infections were categorized together as SSI, because there is no reliable way to dissociate these conditions from each other in the clinical situation. Compromised wound healing in Study II was recorded when local swelling or redness, abscess formation or purulent discharge, granulation or

wound dehiscence was present in line with that done in previous studies (Alpha et al. 2006, Falter et al. 2011, Spaey et al. 2005).

Twenty-nine out of the 153 patients (19.0%) had their osteosynthesis material removed and a total of 56 of the 308 inserted plates (18.2%) were removed in study I. The plates were removed for 12 out of 29 patients (41.3%) who had plate removal, because of infection and in four patients (13.8%) because of screw loosening. It is difficult to know whether the loose screws in those four patients with screw loosening caused the infection, or whether the infection was the reason for the screw loosening in the first place. More than half (55.2%) of all plates that were removed were for plate related reasons, and 44.8% because of subjective discomfort. None of the infections or plate removals altered the final outcome of the treatment.

SSI was found in 9.1% of the patients with one jaw surgery in Study II (BSSO or Le Fort I). The authors of a previous study reported wound healing problems in 26% of the patients and 15% of the osteotomy sites (Alpha et al. 2006). An infection rate of 7.4% was reported in another study (Chow et al. 2007). Those authors also reported that 58.3% of the infections in their patients were acute and 41.7% chronic. There is a wide variety in the rate of miniplate removal in orthognatic patients reported in the literature. Nowadays, most plates are removed because of infections (Falter et al. 2011), which is in line with the results of Study I. If there are indeed signs of infection or compromised healing of the wound, then the osteosynthesis material should be removed after bony healing, but otherwise titanium miniplates and screws do not need removal. Today most plates are made of titanium, which is a safe and inert material and widely used as dental implants. Study I data indicate that plates were also removed because of sensitivity to cold and discomfort. A recently published study found that no plates were removed because of sensitivity to cold (Falter et al. 2011). This discrepancy between the present study findings and that of Falter et al. probably reflects a recent growing awareness that sensitivity to cold is caused by NSD after injury to the IAN during surgery and not by the metallic plate, and therefore is not an indication for plate removal.

Smoking was the only significant factor in Studies I and II that associated with SSI and removal of osteosynthesis material. Smoking decreases tissue oxygenation and adversely affects tissue healing (Guo and DiPietro 2010). A systematic review and meta-analysis by Sørensen showed that smokers have a higher incidence of infectious complications after surgery compared to nonsmokers across all surgical fields (Sørensen 2012). Another study showed that patients who were smokers at the time of surgery had two-fold the wound healing complications of nonsmokers (Wong et al. 2012). Smokers also have a lifetime higher risk for problems with healing even though it has been shown that smoking cessation before surgery will decrease the risks significantly (Sørensen 2012). Anesthesiologists had earlier been reluctant to suggest smoking cessation immediately before surgery, because cessation so close to the surgery would not have sufficient time to significantly alter any a possible risk

for respiratory or cardiovascular complications, in contrast to smoking cessation some weeks prior to the surgery. Smoking cessation at least four weeks before surgery has therefore been recommended (Sörensen 2012). It has been shown that at least four weeks of abstinence from smoking reduces respiratory complications and at least three to four weeks abstinence from smoking reduces the numbers of wound healing complications (Wong et al. 2012). Orthognatic surgical patients have a long orthodontic treatment phase before surgery. The mean duration of the preoperative orthodontic treatment phase in Finland was 17.5 months (Häll et al. 2008). Therefore there is an exceptionally good opportunity in terms of time before surgery for smoking cessation interventions in these patients.

Foreign bodies can also adversely affect healing. All BSSO patients have foreign bodies inserted into the wound area, namely the osteosynthesis material. Moreover, all BSSO patients in Study I had intra-oral drains inserted for the first postoperative day to reduce swelling, which may also increase the risk for infection. It has been shown that the use of fibrin glue instead of drains in the sagittal split wound area reduces the wound infection rate from 6.6% to 2.6% (Spaey et al. 2005). It is interesting to note that drains are no longer used in BSSO operations in our Department.

All patients in this study had at least a one-week course of postoperative prophylactic antibiotics. There is still no consensus on the usefulness of antibiotics in preventing SSI or systemic infections in BSSO patients, even when there are reported indications that antibiotic prophylaxis lasting more than one day after surgery reduces the risk of SSI (Brignardello-Petersen et al. 2015). It is most likely that in the future, fewer and shorter courses of antibiotics will be used in association with orthognatic surgery. In general, when antibiotics are used in surgery, they should be effective against the most likely cause of surgical site infections, they should have a sufficient concentration in the target tissue during surgery and they should be administered over the shortest possible time during the period of wound healing.

7.3 NEUROSENSORY DISTURBANCE

There are a multiple ways to investigate and report injury to IAN during surgery and associated NSD. The manipulation of the nerve and any visible lacerations were recorded in the present study. This is an easy, fast and cheap examination, available to clinicians on an everyday basis. None of the patients had NSD before BSSO. The prevalence of NSD was only recorded before and at one year after surgery in our study populations. It would have been of interest to record the incidence of NSD at multiple time points during follow-up, but unfortunately this was not done in this prospective study. The patients were interviewed, and asked if they had any change in sensation or not. It is hard for the patient to grade their own NSD, and

therefore we chose to report “no NSD” or “present NSD”, even when the latter did not disturb the patient in any way. In previous studies no and mild NSD have been reported together for the same reason (Ylikontiola et al. 2000). There are differing opinions about clinical tests such as the use of two point discrimination and filaments, but these could also have been options for the present study. These tests are also fast, cost effective and available to every clinician, in contrast to the more advanced neurosensory and electrophysiological examinations. At the end of the day, however, the patient’s own experience is what matters, and these have a direct impact on patient satisfaction.

A considerably high rate (90.2%) of subjectively assessed NSD one year after surgery was found. The frequency of nerve impairment and NSD as evaluated by subjective sensory alterations seems to be higher than in evaluations that use objective methods (Ylikontiola et al. 1998, Jääskeläinen et al. 2004, Teerijoki-Oksa et al. 2004, Collela et al. 2007, Agbaje et al. 2015). Subjective testing methods can be sensitive to the influence of the interviewer, and this factor may be one of the reasons for the high rate of NSD in the present study. On the other hand, the subjective perception of the NSD, or symptom for any other condition, is part of the individual patient’s everyday life, and thereby has a great impact on patient treatment satisfaction.

The damage to the IAN during surgery is multifactorial. Atraumatic and careful tissue handling is of the utmost importance and the nerve trunk should be meticulously protected. Manipulation of the nerve increases NSD. The surgeon has to bear in mind the whole course of the mandibular nerve. It has been shown that the delicate and careful handling of the medial tissue is of great importance in limiting damage to the IAN (Teerijoki-Oksa et al. 2002, Panula et al. 2004). The appliances used to achieve the split can also have an impact on NSD. As shown by Mensink et al. (2014), a gentle spreading of the mandible during the split will cause less NSD than the techniques that used only chisels and mallets. Stretching of the nerve will occur during surgery and by the repositioning of the mandible, especially in cases where the mandible is extensively lengthened (van Sickels et al. 2002). The extent of lengthening of the mandible in Study III did not appear to have any influence on NSD, however. Fixation using bicortical screws can accidentally cause a direct injury to the nerve during the procedure. Axonal crush injuries can occur during fixation of the bone fragments when using bicortical screws (Jääskeläinen et al. 2004).

All third molars were removed at least six months before surgery to avoid a possible bad split. There are differing results of the benefit of removing third molars before BSSO with regard to a possible bad split (Douchet et al. 2012a, Kriwalsky et al. 2007, Precious et al. 1998, Werveijer et al. 2014, Mensink et al. 2013, Mehra et al. 2001, Reynecke et al. 2002). The rates of bad splits are low and has been reported to range from 1.3% to 5% (Douchet et al. 2012a, Robl et al. 2014, Mensink et al. 2012,

Al-Navas et al. 2014). A bad split, however, almost never has a negative influence on the final treatment outcome with modern splitting and plating techniques (Verweij et al. 2014). On the other hand, it has been shown that concomitant third molar removal decreases the risk for proximal segment nerve entrapment (Douchet et al. 2012b). The manipulation of the entrapped IAN can increase NSD, thus the regimen of removal of third molars at least six months in advance as practiced at the Department of Oral and Maxillofacial Diseases, Helsinki University Central Hospital, has to be reconsidered. At the same time a second surgical intervention can be avoided.

Intraoperative IAN injuries can be classified as either demyelinating or axonal. In demyelinating injuries only the outer myelin coverage is injured, which often recovers completely within 2-4 months as a result of the remyelination process. However, in axonal injuries the nerve trunk itself is affected. Patients with visible nerve lacerations have axonal injuries. The recovery is often slow or incomplete in such patients. These patients usually experience an initial numbness, and then months after the surgery, they experience unpleasant or painful sensations in the mental region. Some of these patients experience pain during the whole recovery period. An axonal injury and persistent postoperative pain one month after surgery are prognostic factors for the persistence of NSD and development of neuropathic pain. The predicted outcome regarding NSD and chronic pain is often poor (Teerijoki-Oksa et al. 2011). All patients in Study III with visible nerve lacerations had severe NSD and were unsatisfied with the treatment they received.

This study showed that most of the BSSO patients have no or mild NSD, and are highly satisfied with the treatment. The rate of nerve lacerations was 4 nerves in 82 operative sites (4.9%), which is in line with a previous prospective study, which reported that the rate of NSD in BSSO patients was 5.1% (Mensink et al. 2012). However, nerve lacerations increase the occurrence of severe NSD, which decrease patient satisfaction (Espeland et al. 2008). It is therefore of great importance to use an atraumatic surgical technique that avoids manipulation of the IAN or trauma to the IAN.

Patients with visible nerve lacerations, otherwise verified axonal injuries or who report increasing unpleasant and painful sensations during recovery should be identified and treated to prevent the development of chronic postsurgical pain whenever possible (Teerijoki-Oksa et al. 2011, Marchiori et al. 2013). Any delay in the onset of such treatment must be avoided (Lynch et al. 2008, Katz and Seltzer 2009, Kehlet et al. 2006, McGreevy et al. 2011). Gabapentin, pregabalin or amitriptyline, can be used peri- or postoperatively (Clarke et al. 2012), or as a treatment for neuropathic pain (Marchiori et al. 2013, Finnerup et al. 2015). In conclusion nerve manipulation will probably increase NSD. All patients with visible lacerations had severe NSD. Severe NSD, in turn, has a negative impact on patient satisfaction and should be avoided or treated adequately whenever it presents. The only patients

in the present study who were dissatisfied with the treatment and professed they would not go through it again were such patients.

7.4 TMD

Many patients with TMD and concomitant severe malocclusion are referred for orthognatic surgery (Forssell et al. 1998, Nurminen et al. 1999). At the first appointment in Study IV, 42.5% of the patients had a notation of TMD as one of the reasons for seeking treatment and a further 30.0% had a previous history of an occlusal splint due to TMD. Abrahamsson et al. (2009) showed that patients referred for orthognatic surgery have more TMD than patients referred for regular dental treatment. Those authors also reported that the reason for seeking treatment was impaired chewing capacity (75%) and symptoms relating to the masticatory muscles, TMD and headache in (72%). Moreover, the same study found 66% of patients reported esthetic reasons. Many of the patients in the Abrahamsson study reported multiple reasons for seeking treatment. Orthognatic patients, and their referring caregivers, often have high expectations that the treatment will solve TMD.

As much as 65% of the patients had no change in TMD as indicated by their Ai scores, 25% of the patients improved and in 10.0% the symptoms actually worsened. The corresponding Di scores indicated there was no change for 60% of the patients, 30% improved and in 10% the symptoms worsened. An earlier Finnish study reported that the rate of TMD was significantly reduced after BSSO, although in 12% of patients the symptoms worsened (Pahkala and Kellokoski 2007) and in another study 60% of orthognatic patients in whom maxillary and mandibular procedures had been performed, improved (Panula et al. 2000). Panula et al. (2000) were not able to show any difference in occurrence or change in TMD symptoms during follow up for a variety of skeletal malocclusions, however.

Nowadays, there is an increasing awareness that orthognatic surgery is unpredictable for solving TMD, as shown in Study IV. Some patients improve and some impair over time, and to date there are no predictors for the individual outcome. Despite this it is more likely that patients will show some improvement than deterioration at follow-up (Al-Riyami et al. 2009b). Our findings are generally in line with those of a previous study that showed that it is likely that muscle pain on palpation will resolve (Al-Riyami et al. 2009b). The placebo effect of the long lasting and invasive treatment is very probably considerable. There are signs that TMD in patients that require orthognatic surgery might simply follow the natural course of TMD, which is known to fluctuate over time, even though many patients do improve and are highly satisfied with the treatment outcome (Panula et al. 2000, Abrahamsson et al. 2013). Alterations of TMD symptoms after orthognatic surgery do not always result from the actual correction of the malocclusion (Onizava

et al. 1995). Orthognatic surgery cannot therefore be used as a predictable or curative treatment for TMD, and TMD symptoms should be treated independent of the dentofacial deformity. It is preferable that the TMD symptoms should be addressed first (Nale 2014, Nadershah and Mehra 2015). Patients who do not respond to conservative treatment of TMD will probably not benefit from BSSO either. Reversible treatments such as patient education, medications, physiotherapy and occlusal splints should be initially considered when the patient's main complaint is TMD (Nale 2014, Greene and Obrez 2015). It has been shown that the more pronounced TMD symptoms correlate with lower patient satisfaction (Bock et al. 2007). On the other hand Silvola et al. (2016) showed that orthodontic and orthognatic surgery patient's increase in quality of life (Oral Health Quality of Life) was associated with the alleviation of facial pain, rather than the alleviation of TMD as measured by Di and Ai scoring. There is a high risk of reduced treatment satisfaction in those patients whose main motive for the long lasting and invasive treatment is the reduction of the TMD symptoms, since the outcome regarding these symptoms are unpredictable and may even worsen.

7.5 FUTURE TRENDS IN ORTHOGNATIC SURGERY

Orthognatic surgery is long lasting (Häll et al. 2008), it is resource demanding (Panula et al. 2002) and therefore in times of restricted resources, it should provide a measurable increase in well-being and health of the patient. The main aims of orthognatic treatment must be to correct the malocclusion and optimize facial esthetics. It is not always the case that a technically good outcome will make the patient satisfied, or conversely that a compromised outcome will affect the patient negatively. Patient satisfaction and quality of life have during the last years gained increasing attention, including in orthognatic surgery. Some studies show that patients really do benefit from the treatment, in the terms of their quality of life and psychosocial well-being (Alanko et al. 2010, Silvola et al. 2014, Silvola et al. 2016). A Quality of life instrument has been published for orthognatic surgery patients: it is the Orthognatic Quality of life Questionnaire (Cunningham et al. 2000, Cunningham et al. 2002). The aims in orthognatic surgery have shifted from a strict focus on occlusal and functional parameters to a concern for the patient's facial esthetics and well-being in social situations and everyday life.

The indications for BSSO will probably be reassessed in the future. For example, a new and growing group of patients will probably be patients with obstructive sleep apnea because of mandibular retrognathia. The results of many previous surgical upper airway procedures have been moderate, at least in the long run (Caples et al. 2010). Body weight control is of great importance in patients with obstructive sleep apnea. Obstructive sleep apnea is diagnosed by polysomnography, and conservative

treatment with splints and with a continuous positive air pressure device are the first line treatments. If this conservative approach were to be tried first on some patients and subsequently fail, then orthognatic surgery can be considered. In most of these patients BSSO is combined with a Le Fort I osteotomy to archive a sufficient forward movement of the mandible, which should increase the free airway space during sleep. The treatment usually aims at a forward movement of the maxillomandibular complex by a minimum of 10 mm, which is not possible in all patients from an esthetic point of view. It has recently been shown that a forward movement of 7-8 mm of the mandible only can be beneficial for patients with obstructive sleep apnea (Ubaldo et al. 2015). Overall the results are promising: nightly arousals, daytime tiredness and tendency to fall asleep decreased in patients treated for obstructive sleep apnea. The favorable outcome is sustained during follow-up (Raunio et al. 2012). An increase of 4 mm of the posterior airway space has been reported in patients that have only mandibular lenghtening (Ubaldo et al. 2015). It can be concluded that maxillomandibular advancement is an invasive but effective surgical option for some patients with severe obstructive sleep apnea (Caples et al. 2010, Raunio et al. 2012, Zaghi et al. 2015).

BSSO is currently the main surgical tool for correction of mandibular discrepancies. There have been great advances in treatment planning (Larson 2014). Modern radiological techniques and computer aided simulations offers new tools, which will hopefully reduce the numbers of complications and make the treatment results more predictable for BSSO (Herford et al. 2014, Farell et al. 2014). New mandibular osteotomy techniques (Herford et al. 2014) have been invented, and cosmetic surgery processes such as soft and hard tissue augmentations or reductions, cosmetic lip procedures and rhinoplasty will probably increasingly become a part of the facial treatment plan (Mohamed and Perenack 2014). At the same time young patients have an increasing desire for a favorable treatment outcome and thus seek having the process. The world-wide web has become a source for information, albeit good and bad (Bhamram et al. 2015). There is also a great risk of unrealistic expectations not being met and a consequent increase in the level of dissatisfaction with treatment in some patients. This may also occur for some patients even when the treatment results for those patients have objectively improved and most other patients would have been highly satisfied with the outcome. In this context the patient's subjective motives for seeking treatment and expectations of the final treatment outcome at baseline are of great importance for treatment satisfaction as are the individual patient's everyday wellbeing and quality of life (Cunningham and Shute 2008).

8 KEY FINDINGS AND CONCLUSIONS

The following conclusions can be drawn from the present series of studies:

I. Symptomatic titanium miniplate removal was frequent after BSSO, as it was required in 19% of the patients. The reasons for plate removal were plate related (i.e., infection or screw loosening) slightly more often (55.2%) than different types of subjective discomfort (i.e., palpability, cold sensitivity or discomfort about the idea of having a foreign body in the jaw) (44.8%). SSI occurred in 9.1% of patients who had undergone either BSSO or Le Fort I osteotomy. Of all the predictors included in the analyses, only smoking associated statistically significantly with plate removal and with SSI. Patients undergoing orthognathic surgery generally also have to undergo a long phase of preoperative orthodontic treatment, which provides an exceptional opportunity for a cessation of smoking. Patients should be informed about the adverse effects that smoking has on surgical wound healing, and be encouraged and supported to cease smoking, at least perioperatively (**Studies I and II**).

II. The incidence of NSD was very high at one year after BSSO (90.2%). However, severe NSD was relatively infrequent (4.9%), and as much as 89.2% of the patients were satisfied or fairly satisfied with the treatment and would undergo it again if necessary. Although not statistically significant, NSD was greater when the IAN had been manipulated during surgery. Moreover, all four patients who had IAN laceration experienced NSD as a major burden and when asked stated they would not go through the same treatment again. Two of these four patients were additionally diagnosed as having neuropathic pain. The results underline the importance of atraumatic and careful tissue handling in addition to protection of the IAN during surgery. The treatment outcome of manifest chronic pain is often poor. It is therefore to be recommended that patients with visible nerve laceration during surgery or increasing unpleasant and painful sensations during recovery should be identified and treated early in order to prevent chronic pain (**Study III**).

III. There was no change in TMD symptoms (Ai 65%, Di 60%) for a majority of the patients, even when some of these patients improved (Ai 25%, Di 30%). The symptoms even worsened (Ai 10%, Di 10%) for a minority of patients. Orthognathic surgery should therefore not be recommended as a treatment for patients whose primary motive for the long lasting and invasive treatment is TMD symptoms. The results most probably reflect the normal fluctuation in TMD symptoms, which is well known to clinicians that treat TMD patients. Mandibular retrognathia and malocclusions should therefore be treated as being independent of the patients' TMD

symptoms. Patients and colleagues should be well informed about this probable outcome to reduce unrealistic treatment expectations, which will reduce treatment satisfaction.

In the future more well-designed prospective studies will be needed to refine methods and further reduce complications and compromised healing in orthognatic patients.

ACKNOWLEDGEMENTS

This project was carried out at the Department of Oral and Maxillofacial Diseases, University of Helsinki, Finland. Patients were recruited and both the clinical part of the studies was conducted or the patients' files were retrospectively re-evaluated at the Department. I offer my very warm thanks to anyone that has supported me during these years. There are several persons I specially want to thank, for making this thesis a reality:

Docent Hanna Thorén, my supervisor, for her tireless support, guidance and encouragement. Without you this thesis would not have come true! During the ups and downs in the past decade we have learned a lot about hard work, science and each other. You have not only been the best supervisor I could possibly have had, but through true hard work and cooperation we also got to know each other and grew into being friends for life.

Professor Pekka Laine, my other supervisor, who has thought me to be the clinician I am today. With his encouraging attitude he has taught me to believe in my skills. I especially thank you for opening my eyes and revealing the fascinating world of orthognatic surgery to me. You have been a true mentor for me during the years, and I have really been fortunate to share your warm and effortless guidance during the past years. I thank you with all my heart for your support!

Professor Christian Lindqvist has supported me during my clinical training in addition to helping me with this thesis. As the head of the department during my clinical training, he offered me the best possible facilities and willingly shared his in-depth knowledge in our field. I am deeply grateful for everything you have done for me!

I thank my coauthors for your contribution and support. Lisa Suominen for her invaluable help with the statistical work and her comments during the writing process. I also thank Tuula Palotie for starting up this project together with my supervisor Hanna Thorén.

I am thankful to the reviewers professor Timo Peltomäki and docent Tero Soukka for their in-depth comments and valuable suggestions that further improved this thesis.

I extend my warm thanks to Alisdair Mclean PhD for the revision of the language of this thesis and some of the original publications. You really succeeded in editing my "köks-svengelska" and refined the language in these papers into publications that I am proud to present to the scientific community.

I should like to offer my very warm thanks to all my colleagues and co-workers at Helsinki University Central Hospital. Without you I would not have got and maintained the inspiration and motivation to fulfill this task. We had a lot of hilarious

moments together, besides all the hard work. I specially want to thank Johanna Snäll who guided me through all the practical matters and formalities before the dissertation.

I also thank all my colleagues at PKS-SEHYK for your support and friendship. You really make my day! I also want to thank Marja Nojonen for her great understanding about the absence's that were ultimately crucial for the completion of this thesis.

I am grateful to all the patients who were willing to take part in this and other studies. There would not be any clinical research done without you and your forbearance.

I want to thank Helena Javén and Anni Träff at the Dental Library.

I am also deeply grateful to my family and friends. You all remind me that there are other things to life than work and they really matter. My life would not be the same without you! There are still more people who have helped and inspired me to complete this work. I extend my sincere thanks to all of them.

I thank my two children Linus and Emma for giving meaning to my life. I also thank Emma for the illustrations in this thesis and Linus for his technical support, even in the middle of the night. I hope that this work will inspire you to believe in and work hard for the things you find important in your own lives. That is the way dreams come true!

Finally, I thank my husband Gunnar for his love. With you by my side anything is possible.

This study was supported by grants from Odontologiska Samfundet i Finland, the Finnish Women Dentists Association, Finnish Association for Oral and Maxillofacial Surgery and Finnish Dental Society Apollonia.

Helsinki 2016

Marina Kuhlefelt

REFERENCES

- Abrahamsson C, Ekberg E, Henrikson T, Bondemark L.** Alterations of temporomandibular disorders before and after orthognatic surgery. *Angle Orthod* 77: 729-734, 2007
- Abrahamsson C, Ekberg E, Henriksson T, Nilner M, Sunzel B, Bondemark L.** TMD in consecutive patients referred for orthognatic surgery. *Angle Orthod* 79: 621-627, 2009
- Abrahamsson C, Henrikson T, Nilner M, Sunzel B, Bondemark L, Ekberg E.** TMD before and after correction of dentofacial deformities by orthodontic and orthognatic treatment. *Int J Oral Maxillofac Surg* 42: 752-758, 2013
- Agbaje J, Salem A, Lambrichts I, Jacobs R, Politis C.** Systematic review of the incidence of inferior alveolar nerve injury in bilateral sagittal split osteotomy and the assessment of neurosensory disturbances. *Int J Oral Maxillofac Surg* 44: 447-451, 2015
- Ahmad M, Hollender L, Anderson Q, Kartha K, Orbach R, Truelove E, John M, Schiffmann E.** Research diagnostic criteria for temporomandibular disorders (RDC/TMD): development of image analysis criteria and examiner reliability for image analysis. *Oral Surg Oral Med Oral Pathol Oral Radiol Endod* 107: 844-860, 2009
- Alanko O, Svedström-Oiristo A-L, Tuomisto M.** Patients´ perceptions of orthognatic treatment, well-being, and psychological or psychiatric status: a systematic review. *Acta Odontologica Scandinavica* 68: 249-260, 2010
- Al-Nawas B, Kämmerer P, Hoffmann C, Moergel M, Koch F, Wriedt S, Walter C.** Influence of osteotomy procedure and surgical experience on early complications after orthognatic surgery in the mandible. *J Craniomaxillofac Surg* 42: e284-e288, 2014
- Al-Riyami S, Moles D, Cunningham S.** Orthognatic treatment and temporomandibular disorders: A systematic review. Part 1. A new quality-assessment technique and analysis of study characteristics and classifications. *Am J Orthod Dentofacial Orthop* 136: 624.e1-624.e15, 2009
- Al-Riyami S, Cunningham S, Moles D.** Orthognatic treatment and temporomandibular disorders: A systematic review. Part 2. Signs and symptoms and meta-analyses. *Am J Orthod Dentofacial Orthop* 136: 626.e1-626.e16, 2009
- Alpert B, Seligson D.** Removal of asymptomatic bone plates used for orthognatic surgery and facial fractures. *J Oral Maxillofac Surg* 54: 618-621, 1996
- Alpha C, O´Ryan F, Silva A, Poor D.** The incidence of postoperative wound healing problems following sagittal ramus osteotomies stabilized with miniplates and monocortical screws. *J Oral Maxillofac Surg* 64: 659-668, 2006
- Angle E.** Double resection of the lower maxilla. *Dent Cosmos* 40: 631-638, 1898
- Arnett G, Milam S, Gottesman L.** Progressive mandibular retrusion- idiopathic condylar resorption. Part II. *Am J Orthod Dentofac Orthop* 110: 117-127, 1996
- Aziz S.** Simon P. Hüllihen and the origin of orthognatic surgery. *J Oral Maxillofac Surg* 62: 1303-1307, 2004

- Bhamrah G, Ahmad S, NiMhurchadha S.** Internet discussion forums, an information and support resource for orthognatic patients. *Am J Orthod Dentofacial Orthop* 147: 89-96, 2015
- Bhatt V, Chhabra P, Dover M.** Removal of miniplates in maxillofacial surgery: a follow-up study. *J Oral Maxillofac Surg* 63: 756-760, 2005
- Blair V.** Report of a case of double resection for the correction of protrusion of the mandible. *Dent Cosmos* 48: 817-820, 1906
- Blair V.** Operations on the jaw-bone and face. *Surg Gynecol Obstet* 4: 67-78, 1907
- Bock J, Maurer P, Fuhrmann R.** The importance of temporomandibular function for patient satisfaction following orthognatic surgery. *J Orofac Orthop* 68: 299-307, 2007
- Borstlap W, Stoelinga P, Hoppenreijts T, van ´t Hof M.** Stabilisation of sagittal split advancement osteotomies with miniplates: a prospective multicentre study with two-year follow-up. Part III–condylar remodeling and resorption. *Int J Oral Maxillofac Surg* 33: 649-655, 2004
- Bowling A, Rowe G, Lambert N, Waddington M, Mahtani K, Kenten C, Howe A, Francis S.** The measurement of patients´ expectations for health care: a review and psychometric testing of a measure of patients´ expectations. *Health Technol Assess* Vol.16: No 30, 2012
- Bowling A, Rowe G, McKee M.** Patients´ experiences of their healthcare in relation to their expectations and satisfaction: a population survey. *J R Soc Med* 106: 143-149, 2013
- Brignardello-Petersen R, Carrasco-Labra A, Araya I, Yanine N, Cordova Jara L, Villanueva J.** Antibiotic prophylaxis for preventing infectious complications in orthognatic surgery (Review). *Cochrane Database of systematic reviews* Issue 1, 2015
- Böckmann R, Meyns J, Dik E, Kessler P.** The modifications of the sagittal ramus split osteotomy: a literature review. *Plast Reconstr Surg Glob Open* 2: e271, 2014
- Caples S, Rowley J, Prinsell J, Pallanch J, Elamin M, Katz S, Harwick J.** Surgical modifications of the upper airway for obstructive sleep apnea in adults: a systematic review and meta-analysis. *SLEEP* 33: 1396-1407, 2010
- Champy M, Loddé J, Schmitt R, Jaeger J, Muster D.** Mandibular osteosynthesis by miniature screwed plates via a buccal approach. *J Maxillofac Surg* 6: 14-21, 1978
- Choi B-K, Goh R, Chen P, Chuang D, Lo L-J, Chen Y-R.** Facial nerve palsy after sagittal split ramus osteotomy of the mandible: mechanism and outcoms. *J Oral Maxillofac Surg* 68: 1615-1621, 2010
- Chow L, Singh B, Chiu W, Samman N.** Prevalence of postoperative complications after orthognatic surgery: a 15-year review. *J Oral Maxillofac Surg* 65: 984-992, 2007
- Chrcanovic B, Freire-Maia B.** Risk factors and prevention of bad splits during sagittal split osteotomy. *Oral Maxillofac Surg* 16: 19-27, 2012
- Clarke H, Bonin R, Orser B, Englesakis M, Wijesundera D, Katz J.** The prevention of chronic postsurgical pain using gabapentin and pregabalin: A combined systematic review and meta-analysis. *Anesth Analg* 115: 428-442, 2012
- Colella G, Cannavale R, Vicidomini A, Lanza A.** Neurosensory disturbance of the inferior alveolar nerve after bilateral sagittal split osteotomy: a systematic review. *J Oral Maxillofac Surg* 65: 1707-1715, 2007

Cunningham S, Garratt A, Hunt N. Development of a condition-specific quality of life measure for patients with dentofacial deformity: I. Reliability of the instrument. *Community Dent Oral Epidemiol* 28: 195-201, 2000

Cunningham S, Garratt A, Hunt N. Development of a condition-specific quality of life measure for patients with dentofacial deformity: II. Validity and responsiveness testing. *Community Dent Oral Epidemiol* 30: 81-90, 2002

Cunningham S and Shute S. Orthognatic treatment: see how they feel? *J Orthod* 36: 61-66, 2009

Dal Pont G. Lósteotomia retromolare per la correzione della progenia. *Minerva Chir* 1: 1138-1141, 1958

Danforth R, Pitt H, Flanagan M, Brewster B, Brand E, Frankel R. Surgical inpatient satisfaction: what are the real drivers? *Surgery* 156: 328-335, 2014

Dicker G, Castelijns J, Tuinzing D, Stoelenga P. Do the changes in muscle mass, muscle direction, and rotations of the condyles that occur after sagittal split advancement osteotomies play a role in the aetiology of progressive condylar resorption? *Int J Oral Maxillofac Surg* 44: 627-631, 2015

Douchet J-C, Morrison A, Davis B, Gregoire C, Goodday R, Precious D. The presence of mandibular third molars during sagittal split osteotomies does not increase the risk of complications. *J Oral Maxillofac Surg* 70: 1935-1943, 2012

Douchet J-C, Morrison A, Davis B, Robertson C, Goodday R, Precious D. Concomitant removal of mandibular third molars during sagittal split osteotomy minimizes neurosensory dysfunction. *J Oral Maxillofac Surg* 70: 2153-2163, 2012

Dworkin S, LeResche L. Research diagnostic criteria for temporomandibular disorders: review, criteria, examinations and specifications, critique. *J Craniomandib Disord* 6: 301-355, 1992

Espeland L, Högevoid H, Stenvik A. A 3-year patient-centered follow-up of 516 consecutively treated orthognatic surgery patients. *Eur J Orthod* 30: 24-30, 2008

Essick G, Phillips C, Turvey T, Tucker M. Facial altered sensation and sensory impairment after orthognatic surgery. *Int J Oral Maxillofac Surg* 36: 557-582, 2007

Falter B, Schepers S, Vrielink L, Lambrichts I, Politis C. Plate removal following orthognatic surgery. *Oral Surg Oral Med Oral Pathol Oral Radiol Endod* 112: 737-743, 2011

Farrell B, Franco P, Tucker M. Virtual surgical planning in orthognatic surgery. *Oral Maxillofacial Surg Clin N Am* 26: 459-473, 2014

Farella M, Michelotti A, Bocchino T, Cimino R, Laino A, Steenks M. Effects of orthognatic surgery for class III malocclusion on signs and symptoms of temporomandibular disorders and on pressure pain thresholds of the jaw muscles. *Int J Oral Maxillofacial Surg* 36: 583-587, 2007

Fedorowicz Z, Nasser M, Newton T, Oliver R. Resorbable versus titanium plates for orthognatic surgery. *Cochrane Database of Systemic reviews Issue 2*, 2007

Finnerup N, Attal N, Haroutounian S, McNicol E, Baron R, Dworkin R, Gilron I, Haanpää M, Hansson P, Jensen T, Kamerman P, Lund K, Moore A, Raja S, Rice A, Rowbotham M, Sena E, Siddall P, Smith B, Wallace M. Pharmacotherapy for neuropathic pain in adults: a systematic review and meta-analysis. *Lancet Neurol* 14: 162-173, 2015

- Forssell H, Finne K, Forssell K, Panula K, Blinnikka L-M.** Expectations and perceptions regarding treatment: a prospective study of patients undergoing orthognatic surgery. *Int J Adult Orthod Orthognath Surg* 13: 107-113, 1998
- Greene C, Obrez A.** Treating temporomandibular disorders with permanent mandibular repositioning: is it medically nessessary? *Oral Surg Oral Med Oral Pathol Oral Radiol* 119: 489-498, 2015
- Guernsey L, DeChamplain R.** Sequelae and complications of the intraoral sagittal osteotomy in the mandibular rami. *Oral Surg* 32: 176-192, 1971
- Guo S, DiPietro L.** Factors affecting wound healing. *J Dent Res* 89: 219-229, 2010
- Haug R.** Retention of asymptomatic bone plates used for orthognatic surgery and facial fractures. *J Oral Maxillofac Surg* 54: 611-617, 1996
- Helkimo M.** Studies on function and dysfunction of the masticatory system. II. Index for anamnestic and clinical dysfunction and occlusal state. *Sven TandlakTidskr* 67: 101-121, 1974
- Herford A, Stringer D, Tandon R.** Mandibular surgery. Technologic and technical improvements. *Oral Maxillofac Surg Clin N Am* 26: 487-521, 2014.
- Hullihen S.** Case of elongation of the under jaw and distortion of the face and neck, caused by a burn, successfully treated. *Am J Dent Sci* 9: 157-165, 1849
- Hunsuck E.** A modified intraoral sagittal splitting technic for correction of mandibular prognathism. *J Oral Surg.* 26: 250-253, 1968
- Häll B, Jämsä T, Soukka T, Peltomäki T.** Duration of surgical-orthodontic treatment. *Acta Odontologica Scandinavica* 66: 274-277, 2008
- Izuka T, Lindqvist C.** Rigid internal fixation of mandibular fractures. An analysis of 270 fractures treated using the AO/ASIF method. *Int J Oral Maxillofac Surg* 21: 65-69, 1992
- Jääskeläinen S, Teerijoki-Oksa T, Virtanen A, Tenovuo O, Forssell H.** Sensory regeneration following intraoperatively verified trigeminal nerve injury. *Neurology* 62: 1951-1957, 2004
- Katz J, Seltzer Z.** Transition from acute to chronic postsurgical pain: Risk factors and protective factors. *Expert Rev. Neurother* 9: 723-744, 2009
- Kehlet H, Jensen T, Woolf C.** Persistent postsurgical pain: risk factors and prevention. *Lancet* 367: 1618-1625, 2006
- Kennedy G, Tevis S, Kent K.** Is there a relationship between patient satisfaction and favorable outcomes? *Ann Surg* 260: 592-600, 2014
- Kim S-G, Park S-S.** Incidence of complications and problems related to orthognatic surgery. *J Oral Maxillofac Surg* 65: 2438-2444, 2007
- Kinzinger G, Frye L, Diedrich P.** Class II Treatment in adults: comparing camouflage orthodontics, dentofacial orthopedics and orthognatic surgery – A cephalometric study to evaluate various therapeutic effects. *J Orofac Orthop* 69: 63- 91, 2008
- Kobayashi T, Izumi N, Kojima T, Sakagami N, Saito I, Saito C.** Progressive condylar resorption after mandibular advancement. *Br J Oral Maxillofac Surg* 50: 176-180, 2012
- Kostecka F.** Die chirurgische therapie der progenie. *Zahnärztl Rundschau* 40: 670-687, 1931
- Kriwalsky M, Maurer P, Veras R, Eckert A, Schubert J.** Risk factors for a bad split during sagittal split osteotomy. *Br J Oralmaxillofac surg* 46: 177-179, 2008

- Kulkarni R, Pani K, Neuman C, Leonard F.** Polylactic acid for surgical implants. *Arch Surg* 93: 839-843, 1966
- Kuroyanagi N, Shimosato K.** Prediction of neurosensory alterations after sagittal split ramus osteotomy. *Int J Oral Maxillofac Surg* 42: 814-822, 2013
- Laine P, Kontio R, Lindqvist C, Suuronen R.** Are there any complications with bioabsorbable fixation devices? A 10 year review in orthognatic surgery. *Int J Oral Maxillofac Surg* 33: 240-244, 2004
- Lanigan D, Hohn F.** Facial nerve injuries after sagittal split mandibular ramus osteotomies for advancement: a report of 2 cases and review of the literature. *J Oral Maxillofac Surg* 62: 503-507, 2004
- Lanigan D, West R.** Aseptic necrosis of the mandible: report of two cases. *J Oral Maxillofac Surg* 48: 296-300, 1990
- Larson B.** Orthodontic preparation for orthognatic surgery. *Oral Maxillofacial Surg Clin N Am* 26: 441-458, 2014
- Lindqvist C, Söderholm A-L.** A simple method for establishing the position of the condylar segment in sagittal split osteotomy of the mandible. *Plast Reconstr Surg* 82: 707-709, 1988
- Lobbezoo F, Ahlberg J, Glaros A, Kato T, Koyano K, Lavigne G, Leeuw R, Mannfredini D, Svensson P, Winocur E.** Bruxism defined and graded: an international consensus. *J Oral Rehabil* 40: 2-4, 2013
- Lynch M, Campbell F, Clark A, Dunbar M, Goldstein D, Peng P, Stinson J, Tupper H.** A systematic review of the effect of waiting for treatment for chronic pain. *Pain* 136: 97-116, 2008
- Magnusson T, Egermark I, Carlsson G.** A prospective investigation over two decades on signs and symptoms of temporomandibular disorders and associated variables. A final summary. *Acta Odontologica Scandinavica* 63, 99-109, 2005
- Marchiori E, Barber J, Williams W, Bui P, O’Ryan F.** Neurophatic pain following sagittal split ramus osteotomy of the mandible: prevalence, riskfactors and clinical course. *J Oral Maxillofac Surg* 71: 2115- 2122, 2013
- McGreevy K, Bottros M, Raja S.** Preventing chronic pain following acute pain: risk factors, preventing strategies, and their efficacy. *Eur J Pain Suppl* 11: 365-372, 2011
- McLafferty R, Williams R, Lambert A, Dunnington G.** Surgeon communication behaviors that lead patients to not recommend the surgeon to family members or friends: Analysis and impact. *Surgery* 140: 616-624, 2006
- Mehra P, Castro V, Freitas R, Wolford L.** Complications of the mandibular sagittal split ramus osteotomy associated with the presence or absence of third molars. *J Oral Maxillofac Surg* 59: 854-858, 2001 of airway status after orthognatic surgery. *Pathol Oral Radiol Endod* 103: 458-463, 2007
- Meisami T, Musa M, Keller A, Cooper R, Clockie C, Sandor G.** Magnetic resonance imaging assessment of airway status after orthognatic surgery. *Oral Surg Oral Med Oral Pathol Oral Radiol Endod* 103: 458-463, 2007
- Mensink G, Gooris P, Bergsma J, Hooft E, van Merkesteyn R.** Influence of BSSO surgical technique on postoperative inferior alveolar nerve hypoesthesia: a systematic review of the literature. *J Craniomaxillofac Surg*, 42: 976-982, 2014

Mensink G, Verweij J, Frank M, Bergsma J, van Merkesteyn R. Bad split during bilateral sagittal split osteotomy of the mandible with separators: a retrospective study of 427 patients. *Br J Oralmaxillofac surg* 51: 525-529, 2013

Mensink G, Zweers A, Wolterbeek R, Dicker G, Groot R, van Merkesteyn R. Neurosensory disturbances one year after bilateral sagittal split osteotomy of the mandibular performed with separators: a multi-centre prospective study. *J Craniomaxillofac Surg* 40: 763-767, 2012

Merskey H. Classification of chronic pain: Description of chronic pain syndromes and definition of pain terms. *Pain suppl*: 3, 1-226, 1986

Michelet F, Deymes J, Dessus B. Osteosynthesis with miniaturized screwed plates in maxillo-facial surgery. *J Maxillofac Surg* 1: 79-84, 1973

Ministry of Social Affairs and Health. Uniform criteria for access to non-emergency treatment 2010. *Sosiaali- ja terveystieteiden tutkimuskeskus* 31: 1-220, 2010

Mitsukawa N, Morishita T, Saiga A, Kobuta Y, Omori N, Akita S, Satoh K. Dislocation of temporomandibular joint: complication of sagittal split ramus osteotomy. *J Craniofac Surg* 24: 1674-1675, 2013

Mohamed W, Perenack J. Aesthetic adjuncts with orthognathic surgery. *Oral Maxillofacial Surg Clin N Am* 26: 573-585, 2014

Monson L. Bilateral Sagittal Split Osteotomy. *Semin Plast Surg* 27: 145-148, 2013

Nadershah M, Mehra P. Orthognathic surgery in the presence of temporomandibular dysfunction: What happens next? *Oral Maxillofacial Surg Clin N Am* 27: 11-26, 2015

Naeije M, Veldhuis A, Veldhuis E, Visscher C, Lobbezoo F. Disc displacement within the human temporomandibular joint: a systematic review of a 'noisy annoyance'. *J Oral Rehabil* 40: 139-158, 2013

Nale J. Orthognathic surgery and the temporomandibular joint patient. *Oral Maxillofacial Surg Clin N Am* 26: 551-564, 2014

Nurminen L, Pietilä T, Vinkka-Puhakka H. Motivation for and satisfaction with orthodontic-surgical treatment: a retrospective study of 28 patients. *Eur J Orthod* 21: 79-87, 1999

Obwegeser H. Orthognathic surgery and a tale of how three procedures came to be: a letter to the next generations of surgeons. *Clin Plast Surg* 34: 331-355, 2007

Onizawa K, Schmelzeisen R, Vogt S. Alteration of temporomandibular joint symptoms after orthognathic surgery: comparison with healthy volunteers. *J Oral Maxillofac Surg* 53: 117-121, 1995

Pahkala R, Kellokoski J. Surgical-orthodontic treatment and patients' functional and psychosocial well-being. *Am J Orthod Dentofacial Orthop* 132: 158-164, 2007

Panula K, Somppi M, Finne K, Oikarinen K. Effects of orthognathic surgery on temporomandibular joint dysfunction. A controlled prospective 4-year follow-up study. *Int J Oral Maxillofac Surg* 29: 183-187, 2000

Panula K, Finne K, Oikarinen K. Incidence of complications and problems related to orthognathic surgery: a review of 655 patients. *J Oral Maxillofac Surg* 59: 1128-1136, 2001

Panula K, Keski-Nisula L, Oikarinen K. Costs of surgical-orthodontic treatment in community hospital care: An analysis of the different phases of treatment. *Int J Adult Orthognath Surg* 17: 297-306, 2002

- Panula K, Finne K, Oikarinen K.** Neurosensory deficits after bilateral sagittal split ramus osteotomy of the mandible- influence of soft tissue handling medial to the ascending ramus. *Int J Oral Maxillofac Surg* 33: 543-548, 2004
- Pappa H, Richardson D, Niven S.** False aneurysm of the facial artery as complication of sagittal split osteotomy. *J Craniomaxillofac Surg* 36: 180-182, 2008
- Patel P, Novia M.** The surgical tools: The Le Fort I, bilateral sagittal split osteotomy of the mandible, and the osseous genioplasty. *Clin Plastic Surg* 34: 447-475, 2007
- Phillips C, Broder H, Bennett M.** Dentofacial disharmony: motives for seeking treatment. *Int J Adult Orthodon Orthognath Surg* 12: 7-15, 1997
- Phillips C, Essic G, Zuniga J, Tucker M, Blakey G.** Qualitative descriptors used by patients following orthognathic surgery to portray altered sensation. *J Oral Maxillofac Surg* 64: 1751-1760, 2006
- Poort L, van Neck J, van der Wal K.** Sensory testing of inferior alveolar nerve injuries: a review of methods used in prospective studies. *J Oral Maxillofac Surg* 67: 292-300, 2009
- Precious D, Lung K, Pynn B, Goodday R.** Presence of impacted teeth as a determining factor of unfavorable splits in 1256 sagittal-split osteotomies. *Oral Surg Oral Med Oral Pathol Oral Radiol Endod* 85: 362-365, 1998
- Rai K, Shivakumar H, Sonar M.** Transient facial nerve palsy following bilateral sagittal split ramus osteotomy for setback of the mandible: a review of incidence and management. *J Oral Maxillofac Surg* 66: 373-378, 2008
- Raunio A, Rauhala E, Kiviharju M, Lehmijoki O, Sandor G, Oikarinen K.** Bimaxillary advancement as the initial treatment of obstructive sleep apnea: Five years follow-up of the Pori experience. *J Oral Maxillofac Res* 3: e5, 2012
- Reynecke J, Tsakiris P, Becker P.** Age as a factor in the complication rate after removal of unerupted/impacted third molars at the time of mandibular sagittal split osteotomy. *J Oral Maxillofac Surg* 60: 654-659, 2002
- Robl M, Farell B, Tucker M.** Complications in orthognathic surgery. A report of 1000 cases. *Oral Maxillofacial Surg Clin N Am* 26: 599-609, 2014.
- Ruiz L., Lara C.** Facial nerve palsy following bilateral sagittal split ramus osteotomy for setback of the mandible. *Int J Oral Maxillofac Surg* 40: 884-886, 2011
- Salman S, Young M, Van Sickels J.** Osteomyelitis after bilateral sagittal split osteotomy: case report and a review of the management. *Oral Surg Oral Med Oral Pathol Oral Radiol Endod* 111: 442-448, 2011
- Sammartino G, Califano L, Grassi R, Liccardo F, Marenzi G, Grivetto F, Palmeri A, Berrone M, Mortellaro C.** Transient facial nerve paralysis after mandibular sagittal osteotomy. *J Craniofac Surg* 16: 1110-1115, 2005
- Schiffmann E, Orbach R, Truelove E, Feng T, Anderson G, Pan W, Gonzales Y, John M, Sommers E, List T, Velly A, Kang W, Look J.** The revised research diagnostic criteria for temporomandibular disorders: methods used to Establish and validate revised axis I diagnostic algorithms. *J Orofac Pain* 24: 63-78, 2010
- Schreml S, Szeimies R-M, Prantl L, Landthaler M, Babilas P.** Wound healing in the 21st century. *J Am Acad Dermatol* 63: 866-881, 2010
- Schwartz H, Wilson M.** Cervicofacial actinomycosis following orthognathic surgery: report of 2 cases. *J Oral Maxillofac Surg* 59: 447-449, 2001

- Scrivani S, Keith D, Kaban L.** Temporomandibular disorders. *N Engl J Med* 359: 2693-2705, 2008
- Sickels J, Hatch J, Dolche C, Bays R, Rugh J.** Effects of age, amount of advancement and genioplasty on neurosensory disturbance after a bilateral sagittal split osteotomy. *J Oral Maxillofac Surg* 60: 1012-1017, 2002
- Silva A, O’Ryan F, Beckley M, Young H, Poor D.** Pseudoaneurysm of a branch of the maxillary artery following mandibular sagittal split ramus osteotomy: case report and review of the literature. *J Oral Maxillofac Surg* 65: 1807-1816, 2007
- Silvola A-S, Varimo M, Tolvanen M, Rusanen J, Lahti S, Pirttiniemi P.** Dental esthetics and quality of life in adults with severe malocclusion before and after treatment. *Angle Orthod* 84: 594-599, 2014
- Silvola A-S.** Effect of treatment of severe malocclusions and related factors on oral health-related quality- of-life. *Acta Univ. Oul. D* 1270, 2014
- Silvola A-S, Tolvanen M, Rusanen J, Sipilä K, Lahti S, Pirttiniemi P.** Do changes in oral health-related quality- of-life, facial pain and temporomandibular disorders correlate after treatment of severe malocclusion? *Acta Odontologica Scandinavica* 74: 44-50, 2016
- Sousa C, Turrini R.** Complications in orthognatic surgery: a comprehensive review. *J Oral Maxillofac Surg Med Pathol* 24: 67-74, 2012
- Spaey Y, Bettens R, Mommaerts M, Adriaens J, van Landuyt H, Abeloos J, De Clercq C, Lamoral P, Neyt L.** A prospective study on infectious complications in orthognatic surgery. *J Craniomaxfac Surg* 33: 24-29, 2005
- Spiessl B.** Osteosynthese bei sagittaler osteotomie nach Obgeweser-Dal Pont. *Fortschr Kiefer Gesichtschir.* 18: 145-148, 1974
- Steinhäuser E.** Historical development of orthognatic surgery. *J Craniomaxillofac Surg* 24: 195-204, 1996
- Steel B, Cope M.** Unusual and rare complications of orthognatic surgery: a literature review. *J Oral Maxillofac Surg* 70: 1678-1691, 2012
- Suuronen R, Laine P, Sarkiala E, Pohjonen T, Lindqvist C.** Sagittal split osteotomy fixed with biodegradable, self-reinforced poly-L-lactide screws. A pilot study in sheep. *Int J Oral Maxillofac Surg* 21: 303-308, 1992
- Suuronen R, Laine P, Pohjonen T, Lindqvist C.** Sagittal ramus osteotomies fixed with biodegradable screws:a preliminary report. *J Oral Maxillofac Surg* 52: 715-720, 1994
- Sörensen L.** Wound healing and infection in surgery. *Arch Surg* 147: 373-383, 2012
- Tasanen A, Ylipaavalniemi P, Haavikko K.** Closed condylotomy in the treatment of mandibular prognathism. *Proc Finn Dent Soc* 77: 312-317, 1981
- Teerijoki-Oksa T, Jääskeläinen S, Forsell H, Forssell K, Vähätalo K, Tammissalo T, Virtanen A.** Risk factors of nerve injury during mandibular sagittal split osteotomy. *Int J Oral Maxillofac Surg* 31: 33-39, 2002
- Teerijoki-Oksa T, Jääskeläinen S, Forssell K, Virtanen A, Forssell H.** An evaluation of clinical and electrophysiologic tests in nerve injury diagnoses after mandibular sagittal split osteotomy. *Int J Oral Maxillofac Surg* 32: 15-23, 2003
- Teerijoki-Oksa T, Jääskeläinen S, Forssell K, Forssell H.** Recovery of nerve injury after mandibular sagittal split osteotomy. Diagnostic value of clinical and electrophysiologic tests in the follow up. *Int J Oral Maxillofac Surg* 33: 134-140, 2004

- Teerijoki-Oksa T, Jääskeläinen S, Soukka T, Virtanen A, Forssell H.** Subjective sensory symptoms associated with axonal and demyelinating nerve injuries after mandibular sagittal split osteotomy. *J Oral Maxillofac Surg* 69: e208-e213, 2011
- Teltzrow T, Kramer F-J, Schulze A, Baethge C, Brachvogel P.** Perioperative complications following sagittal split osteotomy of the mandible. *J Craniomaxillofac Surg* 33: 307-313, 2005
- Thygesen T, Bardow A, Helleberg M, Norholt S, Jensen J, Svensson P.** Risk factors affecting somatosensory function after sagittal split osteotomy. *J Oral Maxillofac Surg* 66: 469-474, 2008
- Trauner R, Obwegeser H.** Zur operationstechnik bei der progenie und anderen unterkieferanomalien. *Dtsh Zahn Mund Kieferhkd* 23: 1-26, 1955
- Trauner R, Obwegeser H.** The surgical correction of mandibular prognathism and rethognathia with consideration of genioplasty. *Oral Surg Oral Med Oral Pathol* 10: 677-689, 1957
- Truelove E, Sommers E, LeResche L, Dworkin S, von Korff M.** Clinical diagnostic criteria for TMD. New classification permits multiple diagnoses. *JADA* 123: 47-54, 1992
- Tuovinen V, Suuronen R, Teittinen M, Nurmenniemi P.** Comparison of the stability of bioabsorbable and titanium osteosynthesis materials for rigid internal fixation in orthognatic surgery. A prospective randomized controlled study in 101 patients with 192 osteotomies. *Int J Oral Maxillofac Surg* 39: 1059-1065, 2010
- Ubaldo E, Greenlee G, Moore J, Sommers E, Bollen A.** Cephalometric analysis and long-terme outcomes of orthognatic surgical treatment for obstructive sleep apnoea. *Int J Oral Maxillofac Surg* 44: 752-759, 2015
- Van De Perre J, Stoelinga P, Blijdorp P, Brouns J, Hoppenreijts T.** Perioperative morbidity in maxillofacial orthopaedic surgery: a retrospective study. *J Craniomaxillofac Surg* 24: 263-270, 1996.
- Van Sickels J, Hatch J, Dolche C, Bays R, Rugh J.** Effects of age, amount of advancement, and genioplasty on neurosensory disturbance after a bilateral sagittal split osteotomy. *J Oral Maxillofac Surg* 60: 1012-1017, 2002
- Verweij J, Houppermans P, Mensink G, van Merkesteyn R.** Removal of bicortical screws and other osteosynthesis material that caused symptoms after bilateral sagittal split osteotomy: a retrospective study of 251 patients, and review of published papers. *Br J Oral Maxillofac Surg* 52: 756-760, 2014
- Verweij J, Mensink G, Fiocco M, van Merkesteyn R.** Presence of mandibular third molars during bilateral sagittal split osteotomy increases the possibility of bad split but not the risk of other post-operative complications. *J Craniomaxillofac Surg* 42: e359-e363, 2014
- Whipple J.** Double resection of the inferior maxilla for protruding lower jaw. *Dent Cosmos* 40: 552-557, 1898
- Wolford L, Cardenas L.** Idiopathic condylar resorption: diagnosis, treatment protocol, and outcomes. *Am J Orthod Dentofacial Orthop* 116: 667-677, 1999
- Wong J, Lam D, Abrishami A, Chan M, Chung F.** Short-term preoperative smoking cessation and postoperative complications: a systematic review and meta-analysis. *Can J Anesth* 59: 268-279, 2012

- Xi T, Schreurs R, van Loon B, de Koning M, Bergé S, Hoppenreijts T, Maal T.** 3D analysis of condylar remodelling and skeletal relaps following bilateral sagittal split advancement osteotomies. *J Craniomaxillofac Surg* 43: 462-468, 2015
- Yamashita Y, Mizuashi, K, Shigematsu M, Goto M.** Masticatory function and neurosensory disturbance after mandibular correction by bilateral sagittal split ramus osteotomy: a comparison between miniplate and bicortical screw rigid internal fixation. *Int J Oral Maxillofac Surg* 36: 118-122, 2007
- Yamashita Y, Otsuka T, Shigematsu M, Goto M.** A long-term comparative study of two rigid internal fixation techniques in terms of masticatory function and neurosensory disturbance after mandibular correction by bilateral sagittal split ramus osteotomy. *Int J Oral Maxillofac Surg* 40: 360-365, 2011
- Yamauchi K, Takahashi T, Kaneuji T, Nogami S, Yamamoto N, Miyamoto I, Yamashita Y.** Risk factors for neurosensory disturbance after bilateral sagittal split osteotomy based on position of mandibular canal and morphology of mandibular angle. *J Oral Maxillofac Surg* 70: 401-406, 2012
- Ylikontiola L, Kinnunen J, Oikarinen K.** Comparison of different tests assessing neurosensory disturbances after bilateral sagittal split osteotomy. *Int J Oral Maxillofac Surg* 27: 417-421, 1998
- Ylikontiola L, Kinnunen J, Laukkanen P, Oikarinen K.** Prediction of recovery from neurosensory deficit after bilateral sagittal split osteotomy. *Oral Surg Oral Med Oral Pathol Oral Radiol Endod* 90: 275-281, 2000
- Ylikontiola L, Kinnunen J, Oikarinen K.** Factors affecting neurosensory disturbance after mandibular bilateral sagittal split osteotomy. *J Oral Maxillofac Surg* 58: 1234-1239, 2000
- Ylikontiola L, Moberg K, Huuonen S, Soikkonen K, Oikarinen K.** Comparison of three radiographic methods used to locate the mandibular canal in the buccolingual direction before bilateral sagittal split osteotomy. *Oral Surg Oral Med Oral Pathol Oral Radiol Endod* 93: 736-742, 2002
- Yu D, Wang F, Wang X, Fang B, Shen S.** Presurgical motivations, self-esteem, and oral health of orthognatic surgery patients. *J Craniofac Surg* 24: 743-747, 2013
- Zaghi S, Holty J-E, Certal V, Abdullatif J, Guilleminault C, Powel N, Riley R, Carnacho M.** Maxillomandibular advancement for treatment of obstructive sleep apnea. A meta-analysis. *JAMA Otolaryngol Head Neck Surg* Published online November 25: e1-e9, 2015
- Zelle B, Bandari M, Sanchez A, Probst C, Pape H-C.** Loss of follow-up in trauma: is 80% follow-up still acceptable? *J Orthop Trauma* 27: 177-181, 2013