

# We are IntechOpen, the world's leading publisher of Open Access books Built by scientists, for scientists

5,300

Open access books available

130,000

International authors and editors

155M

Downloads

Our authors are among the

154

Countries delivered to

TOP 1%

most cited scientists

12.2%

Contributors from top 500 universities



WEB OF SCIENCE™

Selection of our books indexed in the Book Citation Index  
in Web of Science™ Core Collection (BKCI)

Interested in publishing with us?  
Contact [book.department@intechopen.com](mailto:book.department@intechopen.com)

Numbers displayed above are based on latest data collected.  
For more information visit [www.intechopen.com](http://www.intechopen.com)



# Pathology of Gangrene

*Yutaka Tsutsumi*

## Abstract

Pathological features of gangrene are described. Gangrene is commonly caused by infection of anaerobic bacteria. Dry gangrene belongs to noninfectious gangrene. The hypoxic/ischemic condition accelerates the growth of anaerobic bacteria and extensive necrosis of the involved tissue. Clostridial and non-clostridial gangrene provokes gas formation in the necrotic tissue. Acute gangrenous inflammation happens in a variety of tissues and organs, including the vermiform appendix, gallbladder, bile duct, lung, and eyeball. Emphysematous (gas-forming) infection such as emphysematous pyelonephritis may be provoked by *Escherichia coli* and *Klebsiella pneumoniae*. Rapidly progressive gangrene of the extremities (so-called “flesh-eating bacteria” infection) is seen in fulminant streptococcal, *Vibrio vulnificus*, and *Aeromonas hydrophila* infections. Fournier gangrene is an aggressive and life-threatening gangrenous disease seen in the scrotum and rectum. Necrotizing fasciitis is a subacute form of gangrene of the extremities. Of note is the fact that clostridial and streptococcal infections in the internal organs may result in a lethal hypercytokinemic state without association of gangrene of the arms and legs. Uncontrolled diabetes mellitus may play an important role for vulnerability of the infectious diseases. *Pseudomonas*-induced malignant otitis externa and craniofacial mucormycosis are special forms of the lethal gangrenous disorder.

**Keywords:** anaerobic bacteria, clostridial gas gangrene, flesh-eating bacteria, necrotizing fasciitis, non-clostridial gas gangrene

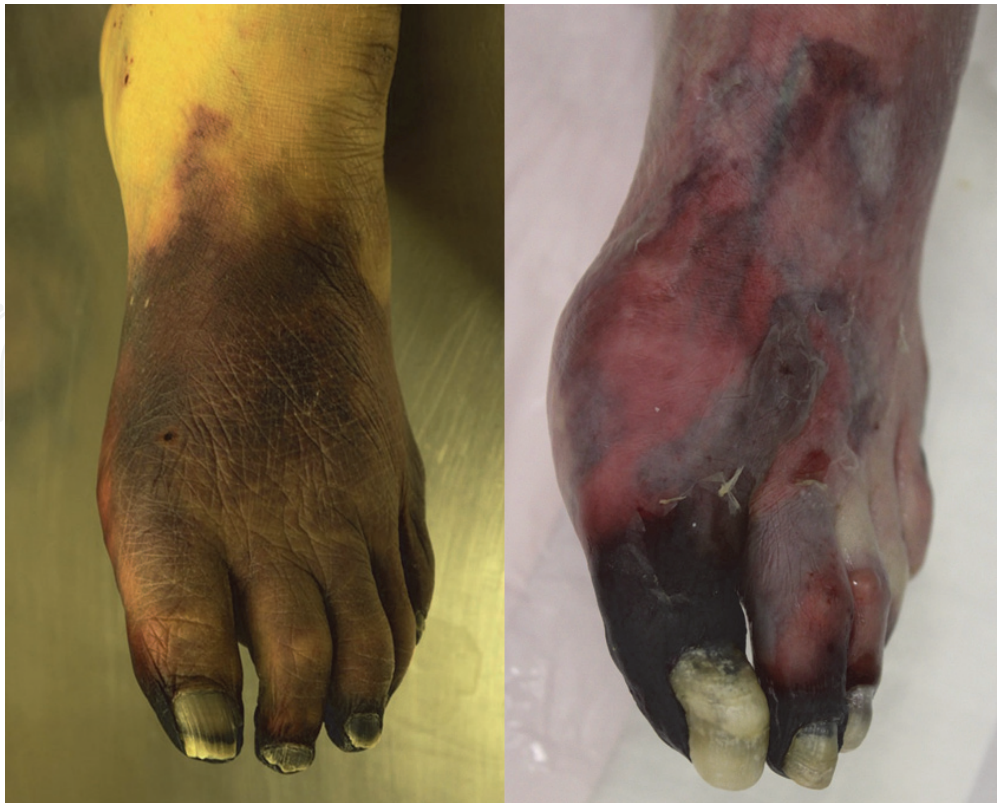## 1. Introduction

Gangrene is a lesion of ischemic tissue death. Typically, the acral skin of the hand and foot accompanies numbness, pain, coolness, swelling, and the skin color changes to reddish black. When severe infection is associated, fever and sepsis may follow. Risk factors of gangrene include diabetes mellitus, atherosclerosis, smoking, major trauma, alcoholism, liver cirrhosis, renal insufficiency, immunosuppression, acquired immunodeficiency syndrome (AIDS), drug abuse, malnutrition, and pernio. Clinically, the disease is divided into dry gangrene, wet gangrene, gas gangrene, internal gangrene, and necrotizing fasciitis. In all cases except for dry gangrene, the necrotic tissue is infected. Treatments include surgery, antibiotics administration, and efforts to control the underlying cause. Hyperbaric oxygen therapy can be tried. Amputation and debridement are performed as surgical treatments. Maggot therapy (artificial implantation of maggots in cavitated lesions) may be performed for digesting tissue debris of diabetic wet gangrene on the extremities.

In the present review article, pathologic features of varied gangrenous lesions are illustrated. In addition to gross findings, microscopic features are presented mainly with hematoxylin and eosin (H&E) and Gram stains. When needed, immunohistochemical approach is combined [1, 2]. Immunostaining using rabbit antisera raised against *Bacillus Calmette-Guérin* (BCG; *Mycobacterium bovis*), *Bacillus cereus*, *Treponema pallidum*, and *Escherichia coli* is employed. These low-specificity (widely cross-reactive) antimicrobial antisera effectively yield clear high-sensitivity signals with a low background [3, 4]. Please visit the author's Website at <https://pathos223.com/en/> [5].

## 2. Dry gangrene

Dry gangrene represents coagulative necrosis of ischemic tissue, caused by inadequate blood supply due to peripheral artery disorders. The term dry gangrene is used only for necrosis of the acral limb [6, 7]. Patients with atherosclerosis, hypercholesterolemia, and diabetes mellitus are susceptible to dry gangrene, particularly when they smoke. The low local oxygen level provokes putrefaction without bacterial growth. The affected portions become dry, solidified, and reddish black (**Figure 1**). Once gangrene has developed, the affected tissue is no longer salvageable. The boundary of the dried lesion is sharply demarcated from the nonischemic skin so that autoamputation may follow [8]. Because of the lack of infection, dry gangrene is not so emergent as wet gangrene and gas gangrene. However, dry gangrene may develop to wet gangrene when the secondary infection happens. Diabetes mellitus is a serious and the most important risk factor for developing both dry and wet gangrenes.



**Figure 1.** Dry gangrene (gross appearance of two cases). Atherosclerosis-induced dry gangrene is seen in the foot (left). The border of necrotic lesion is relatively sharp. In the right panel, the toes of a diabetic patient are dry and black-colored, and wet gangrene with red swelling and epidermal blister formation followed (the courtesy of Drs. Mitsuhiro Tachibana and Yasuhito Kaneko at Department of Diagnostic Pathology and Dermatology, Shimada Municipal Hospital, Shimada, Japan).

### 3. Wet gangrene

Wet or infected gangrene is featured by bacterial infection of the necrotic tissue, and secondary sepsis accompanies a poor prognosis when compared with dry gangrene [9–11]. The affected part becomes markedly edematous, soft, rotten, and dark. Blisters filled with turbid fluid are formed on the discolored and cold-on-touch skin (**Figure 2**). Secondary infection of Gram-positive cocci is common. Infection of saprogenic (anaerobic) bacteria causes a foul smell. Gas formation is often associated, eliciting crepitation on touch. Causative bacteria are polymicrobial or monobacterial. In case of monobacterial infection by *Clostridium perfringens*, we call the status as clostridial gas gangrene. Wet gangrene rapidly progresses via the blockage of blood flow, and the hypoxic stagnant blood promotes rapid growth of anaerobic bacteria that often release exotoxins. The mortality rate of wet gangrene is high so that emergency salvage amputation is often necessary. Disseminated infection (sepsis) eventually leads the patient to death. The predisposing disorders for developing wet gangrene include diabetes mellitus, arteriosclerosis obliterans (atherosclerotic arterial obstruction), and calciphylaxis/calcific uremic arteriopathy or “gray scale” (painful and intractable ulcers caused by arteriolar wall calcification in patients with chronic renal failure under dialysis).

Several lethal conditions described below are encompassed in the category of wet gangrene. These include polymicrobial necrotizing fasciitis, gas gangrene, Fournier’s gangrene, fulminant streptococcal infection, *Vibrio vulnificus* infection, and *Aeromonas hydrophila* infection.

### 4. Pernio (frostbite or chilblains)

Pernio (frostbite or chilblains) is a vascular disease affecting small vessels of the peripheral skin. Persistent low temperature (cooling) or freezing of the skin causes pernio. Persistent hypoxia of the tissue eventually results in necrosis and ulceration. In a chronic stage, scleroderma-like change may follow. Histopathological features of pernio include mild inflammation around small vessels, peri-eccrine inflammation, and necrosis of the subcutaneous fat tissue with formation of multinucleated giant cells. The epidermis may reveal spongiosis, basal vacuolation, and



**Figure 2.**

Wet gangrene (gross appearance of two cases and H&E). Infected deep irregular ulcers are formed in the back of the foot (left) and the base of the second toe after autoamputation (right). Histologically, Gram-positive cocci in the necrotic upper dermis are observed in the debridement specimen (the courtesy of Dr. Yasuhito Kaneko at Department of Dermatology, Shimada Municipal Hospital, Shimada, Japan).



keratinocyte necrosis [12–14]. Representative features are displayed in **Figure 3**. These histopathologic pictures are seen in other vascular disorders, provoking a chronic irritative process of the skin.

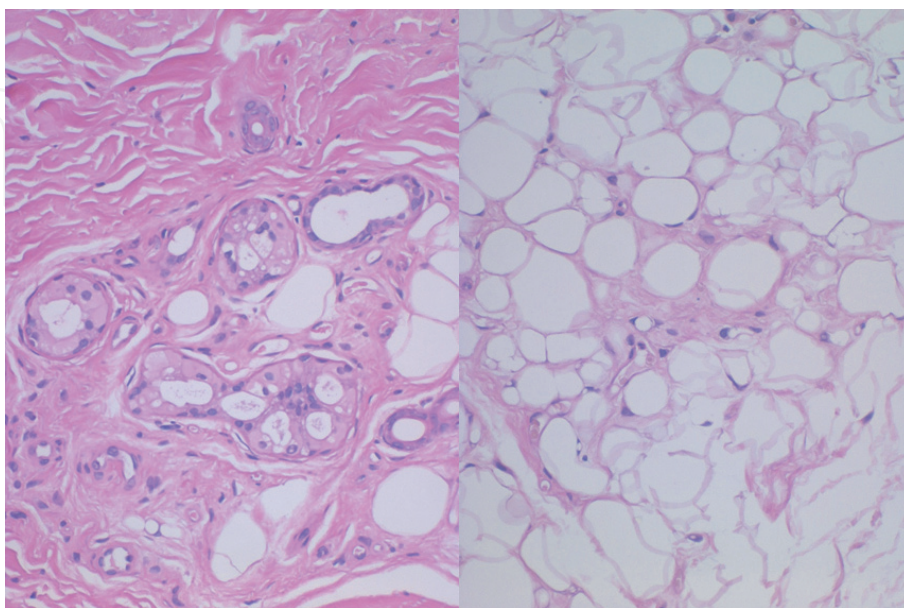
## 5. Decubitus (pressure ulcer or bedsore)

Decubitus (pressure ulcer or bedsore) is formed as a result of long-term pressure, completely or partially blocking the skin blood flow [15]. The sites on a bony prominence are commonly affected, including the skin overlying the sacrum, the greater trochanter, the heel, and the scalp. Decubitus commonly develops in individuals who are on chronic bedrest or consistently use a wheelchair. Factors influencing the skin tolerance against pressure include malnutrition, skin wetness, diseases reducing the blood flow to the skin such as atherosclerosis, and diseases reducing the skin sensation such as paralysis or neuropathy. The advanced age, smoking, complicated diseases (atherosclerosis, diabetes mellitus, and secondary infection), and the use of anti-inflammatory drugs may hamper healing of decubitus.

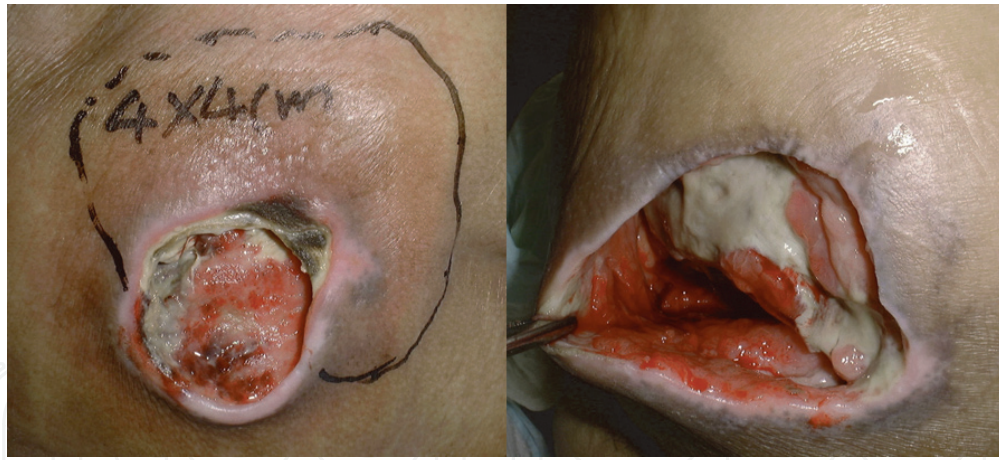
There is a preceding erythematous stage before ulceration. The late stage presents as a black eschar form. The ulcer often deeply reaches the periosteal tissue. When a pocket is formed, secondary infection may become serious (**Figure 4**). Infection provokes slow or stalling healing and pale granulation tissue [16, 17]. Infected wounds may have a gangrenous odor. Bacterial biofilm formation leads to delayed healing of the decubital ulcer. Infected decubitus may progress to wet gangrene or clostridial/non-clostridial gas gangrene (**Figure 5**) [18], as described in Section 7. The colonization of *Staphylococcus aureus*, particularly methicillin-resistant *Staphylococcus aureus* (MRSA), in the decubitus must be the important target of infection control [19]. It should be noted that the eradication of MRSA can be achieved only after healing of ulceration.

The National Pressure Ulcer Advisory Panel (NPUAP) in the United States proposed the staging of decubital ulcer [20].

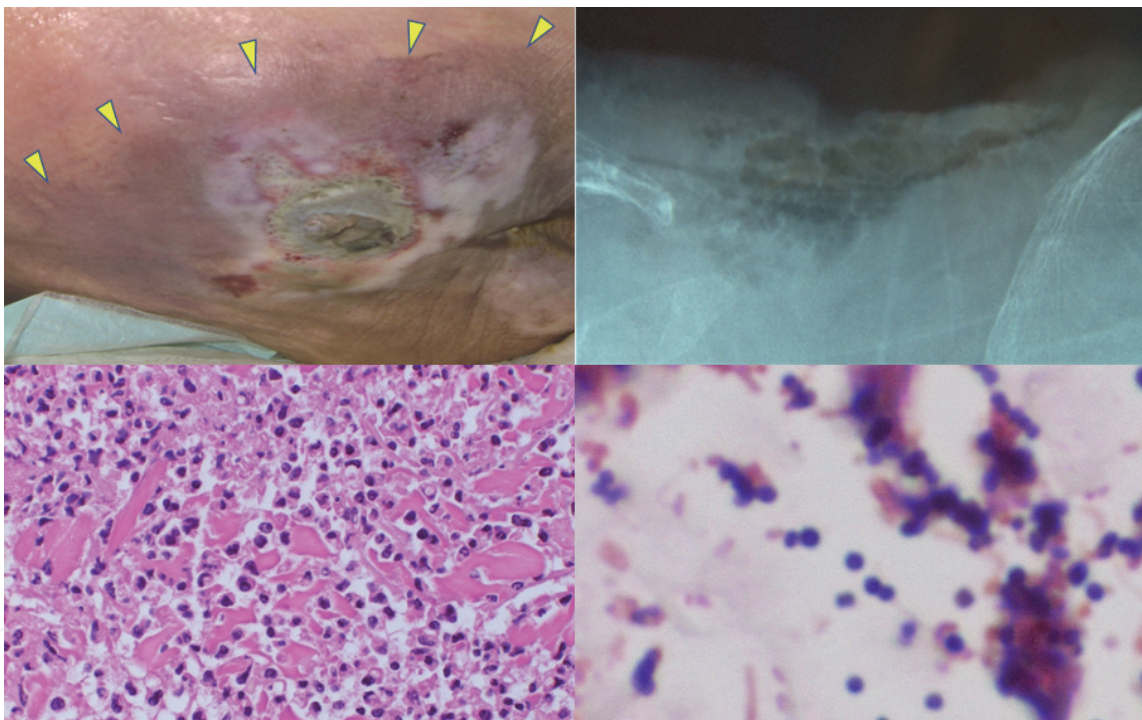
**Stage I:** Intact skin with non-blanchable redness of a localized area usually over a bony prominence.



**Figure 3.** *Pernio (H&E). Biopsy from the skin of sole demonstrates angiectasia of capillary vessels around the eccrine sweat gland (left) and fat necrobiosis (right). Loss of fat cell nuclei, membranous deposition in the cytoplasm, and focal stromal hyalinizing fibrosis are observed.*



**Figure 4.** Large and deep decubiti with purulent exudation and pocket formation at the sacral region (two cases). Deep mining ulcers, so-called pockets, are noted. In the left case, the 40 × 40 mm pocket is indicated by dotted lines on the skin. Secondary infection is inevitable (the courtesy of Dr. Sandai Ohnishi at Hakuohkai Home Healthcare Clinic, Nagoya, Japan).



**Figure 5.** Non-clostridial gas gangrene caused by group A  $\beta$ -hemolytic streptococcal infection (gross and radiologic findings, H&E and Gram). Infected sacral decubitus seen in a 72-year-old diabetic female patient with a history of brain infarction progressed to gas gangrene. The arrowheads indicate the red-colored skin area with crepitation on touch. X-ray examination discloses gas formation in the soft tissue. Debridement tissue reveals massive gangrenous inflammation with infection of Gram-positive cocci.

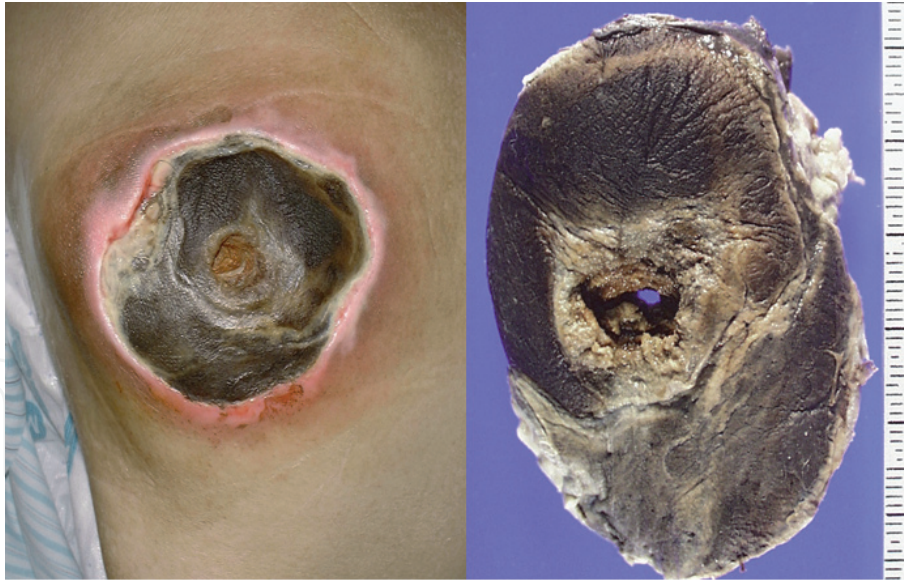**Stage II:** A shallow open ulcer with a red, pink wound bed, without slough.

**Stage III:** Full thickness tissue loss. Subcutaneous fat may be visible but bone, tendon, and muscle are not exposed. Slough may be present but does not obscure the depth of tissue loss.

**Stage IV:** Full thickness tissue loss with exposed bone, tendon, or muscle. Slough or eschar may be present on some parts of the wound bed. Undermining/tunneling (pocket formation) is often seen.

For the treatment purpose, the eschar stage decubitus can surgically be removed and skin-grafted (**Figure 6**). Histologically, the advanced lesion shows the full-thickness dermal necrosis with deep ulceration and abscess/gangrene formation.

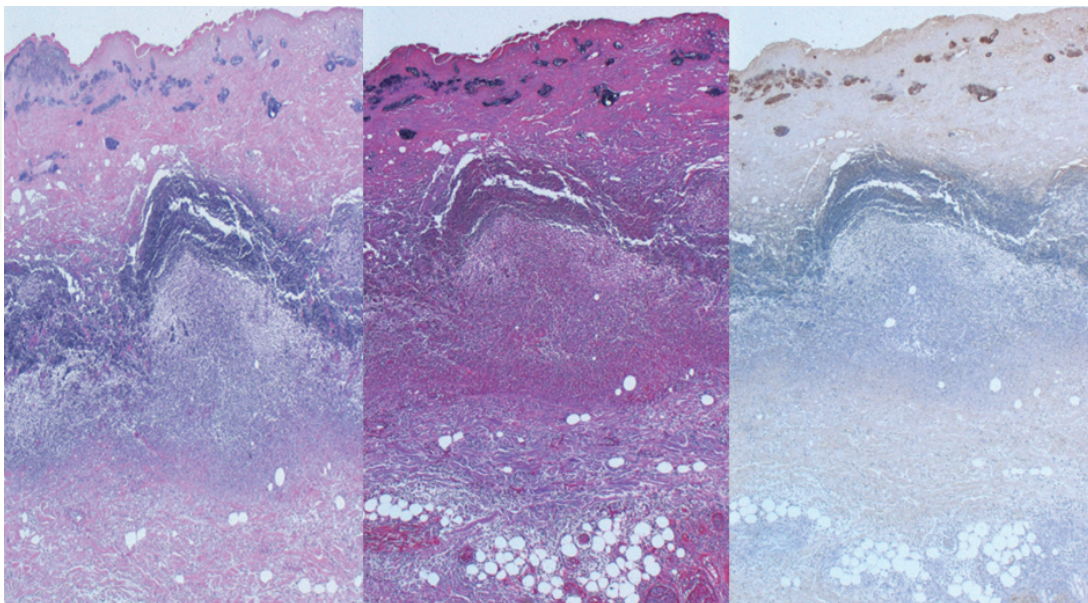




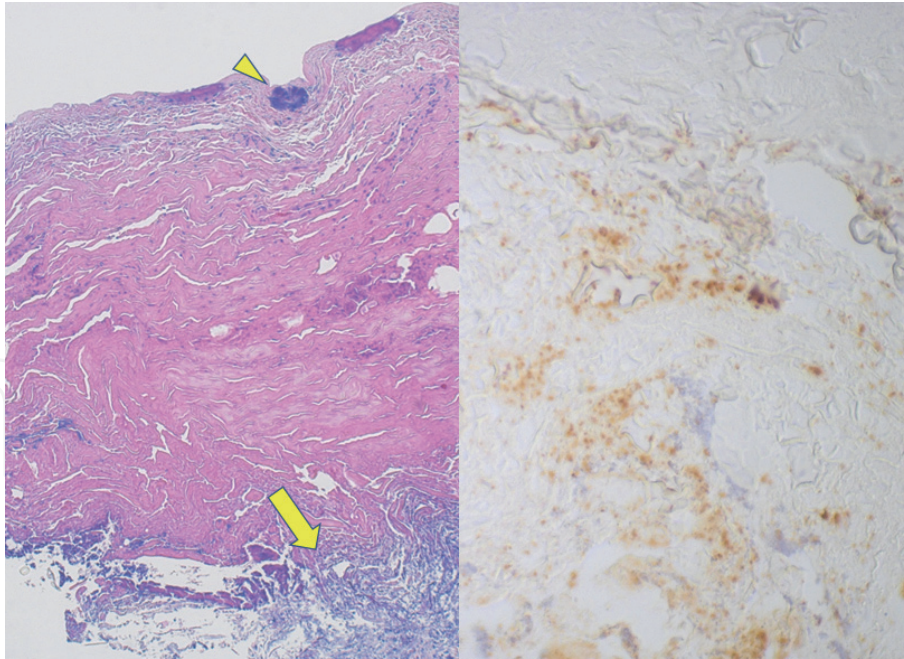
**Figure 6.** Surgical removal of a large decubital ulcer covered with black eschar at the trochanter region. Surgical treatment was effective in this intractable ulceration (the courtesy of Dr. Sandai Ohnishi, Nagoya, Japan).

Patterns of bacterial infection are often unique. *Staphylococcus aureus*, including MRSA, mainly colonizes the superficial layer (**Figure 7**), while Gram-negative rods, including *Pseudomonas aeruginosa* and *Escherichia coli*, are observed in the deep layer (**Figures 8 and 9**) [2].

The phenotype of MRSA can be demonstrated immunohistochemically in routinely formalin-fixed, paraffin-embedded lesions [21]. *S. aureus* is immunoreactive not only for staphylococcal antigens but also for protein A, an immunoglobulin-binding protein specifically expressed on the cell wall of *S. aureus*. The multidrug resistance of MRSA, determined by the expression of penicillin-binding protein 2' (PBP2') encoded by the *mecA* gene, can be immunophenotyped with monoclonal antibodies. Representative findings are demonstrated in **Figure 10**.



**Figure 7.** Microscopic double-layered appearance of the resected decubital ulcer (H&E, Gram and immunostain). Colonization of *Staphylococcus aureus*, probably MRSA, is observed along the eroded surface and clearly illustrated by Gram stain and immunostaining for staphylococcal antigens. Abscess formation with ischemic gangrene is noted in the deep zone.



**Figure 8.** *Pseudomonas* infection in the deep part of the decubitus (H&E and immunostain). In the subcutaneous abscess (arrow), immunostaining using a monoclonal antibody against *Pseudomonas aeruginosa* demonstrates phagocytized microbes in neutrophils. *E. coli* antigens are negative. Arrowhead indicates superficially colonized *Staphylococcus aureus*, as shown in **Figure 7**.



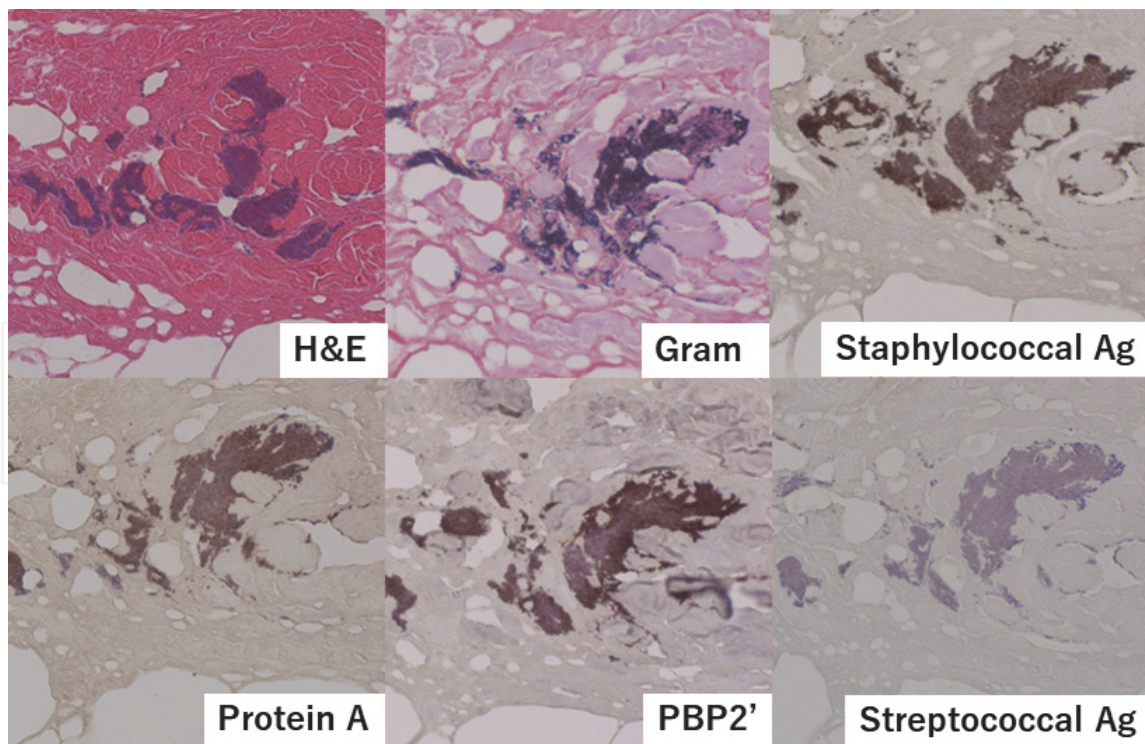
**Figure 9.** Another decubital ulcer with massive colonization of Gram-negative rods in the deep gangrenous tissue (H&E and immunostain). Gas formation is associated. A monoclonal antibody (J5) against lipopolysaccharide common in Enterobacteriaceae illustrates an advanced infective process in the decubitus.

## 6. Gas gangrene (clostridial myonecrosis)

### 6.1 Traumatic gas gangrene


Gas gangrene caused by infection of *Clostridium perfringens* (formerly called *C. welchii*) is a life-threatening emergency, as a representative and grave form of wet gangrene [22–25]. *C. perfringens* is an obligate anaerobic Gram-positive bacillus forming spores on culture plates. Traumatic skin invasion of the microbe results in





**Figure 10.** Immunohistochemical identification of MRSA in formalin-fixed, paraffin-embedded sections (H&E, Gram and immunostain). The Gram-positive coccal colonies in the gangrenous decubital lesion express staphylococcal antigens, protein A (staphylococcal IgG Fc-binding protein) and penicillin-binding protein 2' (PBP2'), confirming the nature of MRSA. Streptococcal antigens are negative.

massive ischemic necrosis (gangrene) of the soft tissue involving the striated muscle. Gas production is quite characteristic, and the involved tissue thus reveals crepitation on touch (**Figure 11**). The gas is composed of 5.9% hydrogen, 3.4% carbon dioxide, 74.5% nitrogen, and 16.1% oxygen. As the bacteria grow under an anaerobic condition, the degree of ischemia in the involved tissues and organs becomes advanced. Tissue necrosis is accelerated by  $\alpha$ -toxin production of the microbe. Putrid odor is associated. Intravascular hemolysis is a common event due to bacterial production of hemolysin ( $\alpha$ -toxin). The prognosis is very poor. The disease is also called as clostridial histotoxic syndrome. Gram-positive rods are microscopically localized adjacent to gas bubbles (see below).



**Figure 11.** Traumatic gas gangrene of the right thigh (gross appearance). Gas-forming gangrenous process of the soft tissue results in marked swelling of the thigh. Crepitation was palpable on touch. Surgical debridement has been performed for the treatment purpose.

## 6.2 Nontraumatic gas gangrene


*C. perfringens* commonly resides in the gut lumen of healthy individuals, so that the nontraumatic gas gangrene is encountered in the internal organs such as the gut, bile duct, and pancreas [26, 27]. Representative autopsy cases are presented below.

The pancreas is occasionally assaulted by *C. perfringens* [28–30]. An autopsy case of fulminant pancreatitis (emphysematous pancreatitis) in a 66-year-old diabetic man, presenting just a two-day clinical course, is demonstrated. Diabetes mellitus was poorly controlled. The patient suffered sudden abdominal and back pain, and acute pancreatitis was diagnosed by a markedly elevated serum amylase level. Abdominal computed tomography scan demonstrated gas retention in the pancreatic head, intrahepatic branches of the bile duct, and in the abdominal cavity. At autopsy, features of acute hemorrhagic and necrotizing pancreatitis with infiltration of neutrophils were observed (**Figure 12**). Clusters of rods were identified in necrotic, gas-forming areas, and the bacteria grew also along the pancreatic duct. Neutrophilic reaction was sparse in the hypoxic area showing bacterial growth. Not all of the bacteria were stained blue with Gram stain (some remain unstained), and the formation of spores was abortive within the living body (**Figure 13**). These microscopic features were consistent with infection of *C. perfringens*.

Another case of pancreatic gas gangrene in a diabetic male patient aged 70's showed numerous Gram-positive rods around the gas-filled space formed in the necrotic pancreas, confirming the diagnosis of *C. perfringens* infection. Gross and microscopic findings of the foamy liver are illustrated in **Figure 14**. The cut surface of the formalin-fixed liver shows numerous gas-filled spaces, giving characteristic spongy/foamy appearance.

Nontraumatic gas gangrene may be associated with colon cancer [31, 32]. An 81-year-old female patient with rectal cancer became acutely ill with abdominal pain and paralytic ileus. The patient soon died of septic shock. Autopsy clarified nontraumatic gas gangrene of the colorectum caused by clostridial infection in rectal adenocarcinoma. The growth of Gram-positive, gas-forming rods was observed in the cancer tissue, crypts of the noncancerous colorectal mucosa, and also in the liver. Gangrenous inflammation was observed in the entire layer of the colorectal wall. Acute tubular necrosis represented the shock kidney. The microscopic appearance is displayed in **Figure 15**.

Gastric gas gangrene is infrequently experienced [33]. A 65-year-old diabetic male patient underwent endoscopic mucosal resection of intramucosal gastric



**Figure 12.** Clostridial acute hemorrhagic and necrotizing pancreatitis (CT scan and H&E). Computed tomography scan demonstrates gas formation in the pancreatic head (arrowhead). At autopsy, neutrophils infiltrate the pancreatic parenchyma, giving features of severe acute pancreatitis.



IntechOpen

**Figure 13.**

*C. perfringens* grown in acute necrotizing pancreatitis (H&E and Gram). Gas bubbles are observed in the necrotic pancreatic tissue with sparse inflammatory infiltration. The rods growing in the bubble are unevenly Gram-positive (some bacilli are not stained blue). Spores (representing unstained dots in the bacterial body) are only focally recognizable in the living body.



**Figure 14.**

Gas gangrene involving the liver (gross and Gram). Numerous gas bubbles replace the liver parenchyma, giving foamy or spongy appearance. The hepatocytes reveal ischemic changes, and Gram-positive rods are clustered around the gas bubble. Note that the condition allowing the growth of obligate anaerobic *Clostridium perfringens* must be highly hypoxic.

adenocarcinoma located at the gastric angle. Next day, he became acutely ill with abdominal pain and distention, and circulatory collapse soon followed. At autopsy, colonization of Gram-positive rods was noted at the base of ulcer caused by the endoscopic operation (**Figure 16**). The liver revealed multifocal foamy appearance due to gas formation by Gram-positive rods growing among the liver cell cord. The final diagnosis was gas gangrene caused by clostridial infection on the iatrogenic gastric mucosal trauma.

*C. septicum* may cause spontaneous, nontraumatic gas gangrene [34], and *C. sordellii* may induce gas gangrene of the uterus, as a consequence of spontaneous abortion, normal vaginal delivery, and traumatic injury [35]. As illustrated in **Figure 17**, *C. butyricum* happened to infect the stomach, resulting in fulminant death of a male patient aged 60's. *C. butyricum*, a resident of healthy human gut, uniquely produces butyric acid as a metabolite, hence named. Foamy appearance of the gastric wall was quite characteristic. The liver also appeared foamy/spongy. The formation of spores inside the rugby ball-shaped Gram-positive rod bodies is microscopically characteristic of *C. butyricum*. This is in sharp contrast to poor spore






IntechOpen

**Figure 15.**

Rectal cancer-associated nontraumatic gas gangrene in an 81-year-old female patient (gross and H&E). The rectal cancer (arrow) and the edematous proximal colon reveal hemorrhagic necrosis. Gas formation is observed in the tissue of rectal adenocarcinoma with marked ischemic change. Large-sized rods colonize the crypts of the non-cancerous necrotic colorectal mucosa (the courtesy of Dr. Hirokazu Kurohama, Regional Pathological Diagnosis Support Center, Atomic Bomb Disease Institute, Nagasaki University, Nagasaki, Japan).



**Figure 16.**

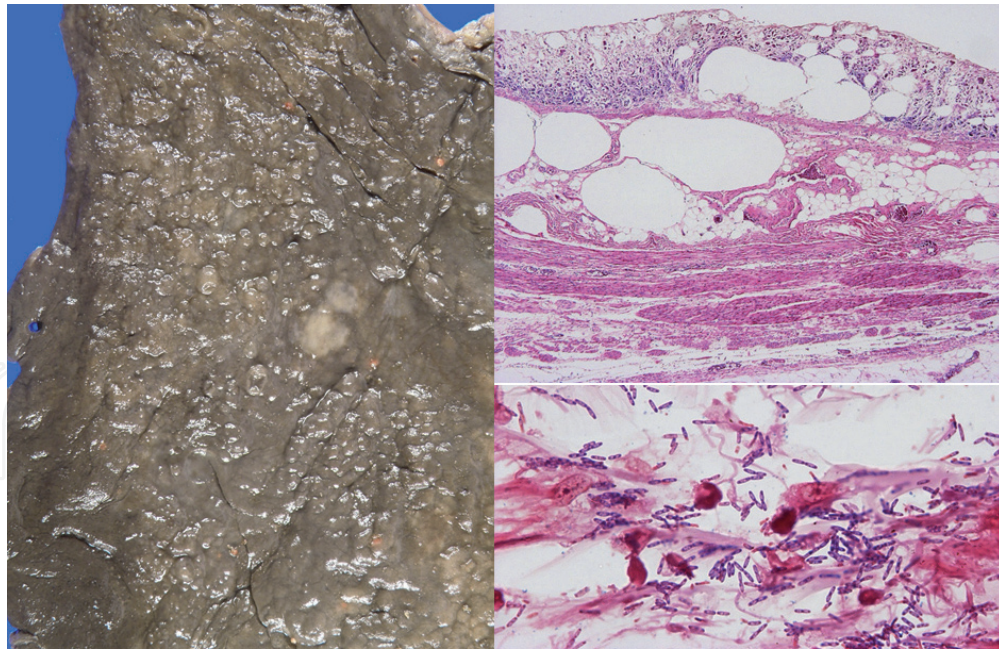
Gastric gas gangrene in a 65-year-old diabetic male patient (gross and H&E). Red-swollen stomach after endoscopic mucosal resection for early gastric cancer has an artificial ulcer at the gastric angle. Rods colonize the ulcer base. Gas formation is evident in the liver tissue (inset). Arrowheads indicate bacterial colonies (the courtesy of Dr. Chunlin Ye, Emergency Department, Saishukan Hospital, Kitanagoya, Japan).

formation by *C. perfringens*. Surgically curable *C. butyricum*-induced intestinal gas gangrene is described in the Section 14.3.

## 7. Non-clostridial gas gangrene

Gas gangrene is commonly caused by clostridial infection, but non-clostridial bacteria may also provoke gas gangrene mostly in the extremities [36–38]. Early diagnosis and therapy are required, because the disease rapidly progresses to fatal toxemia. This unique dermatologic emergency is featured by the detection of nontraumatic subcutaneous emphysema of the leg with or without association of





**Figure 17.** *Clostridium butyricum*-induced lethal gastric gas gangrene (gross, H&E and Gram). The gastric wall demonstrates formation of gas bubbles both grossly and microscopically. The growing Gram-positive rods exhibit distinct spore formation in rugby ball-shaped bacterial bodies, morphologically consistent with *C. butyricum* (the courtesy of Dr. Mayu Fukushima, a pathologist at Hamamatsu Medical University Hospital, Hamamatsu, Japan).

erythema, tenderness, or bullous lesions. Non-clostridial gas gangrene most often results from polymicrobial infection of mixed kinds of microbes, and it is mainly seen in diabetic patients [39–41]. The causative gas-producing bacteria include *Escherichia coli*, *Klebsiella pneumoniae*, *Enterobacter cloacae*, *Pseudomonas aeruginosa*, *Aeromonas hydrophila*, *Bacteroides* spp., and *Streptococcus anginosus* group (former *S. milleri* group) [42]. Groups A, B, and G streptococci also cause gas gangrene, as a form of fulminant streptococcal infection [43], as described in the Section 10.1.

**Figure 5** illustrates the gas-forming fulminant group A  $\beta$ -hemolytic streptococcal infection, caused by a deeply ulcerated (pocket-forming) decubitus at the sacral region of a 72-year-old diabetic woman. Another diabetic male patient aged 70's with advanced rectal adenocarcinoma suddenly manifested nontraumatic and non-clostridial gas gangrene in the abdominal cavity. Massive transportal infection of gas-forming *E. coli* resulted in the formation of foamy liver (**Figure 18**). Intrahepatic vascular-invasive growth of Gram-negative rods was observed under a microscope, and infection of *E. coli* was immunohistochemically confirmed.

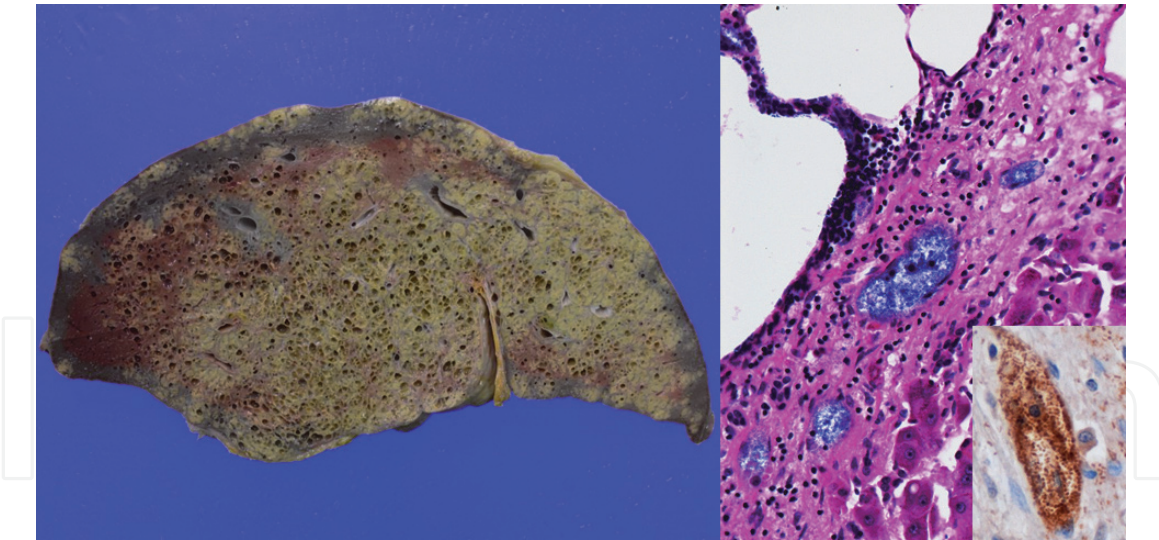
Emphysematous (gas-producing) inflammation may be encountered in a variety of organs and tissues, as described in the next section.

## 8. Gangrenous inflammation of internal organs

Gangrenous inflammation may occur in a wide variety of internal organs, such as the vermiform appendix, gallbladder, bile duct, pancreas, lung, kidney, eyeball, etc. The lesion may be localized within the organ, but it often extends to the surrounding tissues, so as to be fatal. When the anaerobic pathogens produce gas, we call the serious condition as “emphysematous” inflammation (as a form of localized gas gangrene).

### 8.1 Gangrenous appendicitis

Acute appendicitis is featured by sudden onset epigastric pain radiating to pelvis and high tachycardiac fever. When perforated, generalized abdominal tenderness



**Figure 18.**  
*E. coli*-induced non-clostridial gas gangrene accompanying foamy liver seen in a diabetic male patient aged 70's with advanced rectal adenocarcinoma (gross and H&E, inset: immunostain). Transportal infection of *E. coli* provoked foamy liver due to gas formation by the infected bacteria. The rods embolic in capillary vessels of the liver are immunoreactive with a monoclonal antibody against *E. coli* antigen (inset).

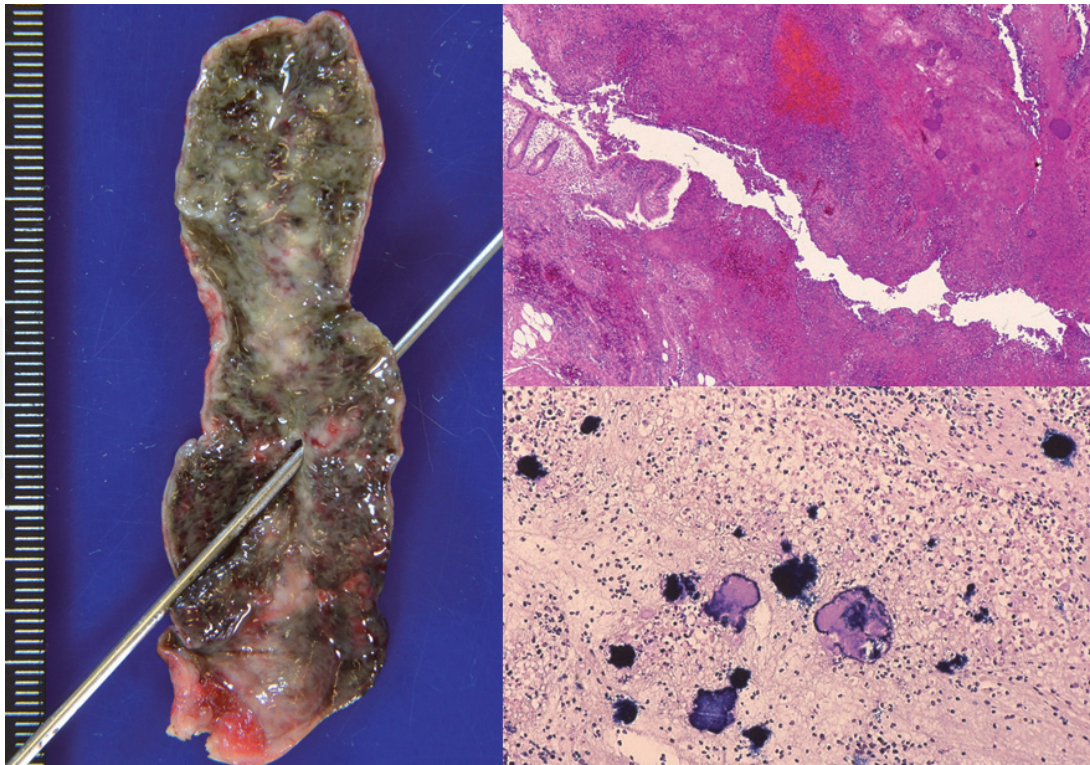
and peritonism occur. Acute appendicitis is caused by the blockage of the appendiceal lumen (most commonly by fecalith impaction). The blockage results in increased luminal pressure, impaired blood flow, and invasive infection of bacterial flora. When the gangrenous process proceeds, rupture of the appendix can result [44–46]. Mixed bacterial infection is proven. Causative pathogens include *Escherichia coli*, *Bacteroides fragilis*, *B. splanchnicus*, *B. intermedius*, *Peptostreptococcus*, *Pseudomonas*, *Lactobacillus*, *Bilophila wadsworthia*, *Fusobacterium nucleatum*, *Eggerthella lenta*, and *Streptococcus anginosus* (or *milleri*) group. An average of 10.2 different microorganisms have been isolated from the infected lesion. Microscopically, the appendiceal wall reveals marked transmural collection of neutrophils and massive necrosis with the disappearance of the proper muscle layer. Colonization of cocci and rods is easily observed within the gangrenous lesion. Fibrinopurulent peritonitis is associated. Medium-sized blood vessels are thrombosed, accelerating the gangrenous change. Representative findings are displayed in **Figure 19**.

## 8.2 Gangrenous and emphysematous cholecystitis


Gangrenous cholecystitis is defined as infection-associated transmural necrosis and perforation of the gallbladder wall, as a result of secondary ischemia due to vascular thrombosis. Mural necrosis (infarction) provokes perforation in 25% of cases. Gangrenous cholecystitis represents a form of acute acalculous cholecystitis (**Figure 20**), and the pathology and epidemiology differ from chronic cholecystitis induced by gallstones [47–49]. *Enterobacteriaceae* and anaerobic bacteria are frequently cultured from the bile. The mortality rate is high between 15 and 50%. Risk factors for the development of gangrenous cholecystitis include male sex, advanced age, delayed surgery, cardiovascular diseases, and diabetes mellitus.

Emphysematous cholecystitis is a fulminant and sinister form of acute gangrenous cholecystitis, and it is characterized by the presence of gas both in the lumen (pneumobilia) and wall of the gallbladder. Gas may be extended to the biliary tree or adjacent structures. Either clostridial or non-clostridial etiology is encountered [50]. In case of non-clostridial infection, mixed infection of rods and cocci is often proven microscopically (**Figure 21**). Emphysematous cholecystitis, a form of gas





**Figure 19.** Gangrenous appendicitis (gross, H&E and Gram). Massive necrotizing inflammation of the appendiceal wall results in perforated purulent peritonitis. A probe is inserted at the site of perforation. Gram-positive bacterial colonies are scattered in the necrotic exudation.



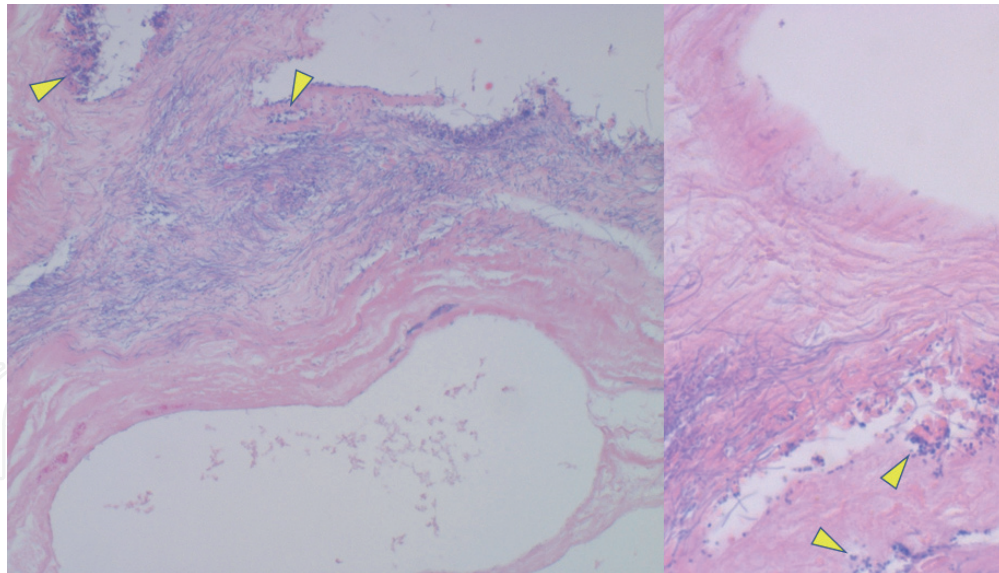
**Figure 20.** Gangrenous cholecystitis (gross, H&E and immunostain). Surgically removed gallbladder reveals marked necrotizing inflammation with bile-stained (green-colored) multiple mucosal ulceration. Bacterial colonies growing in the necrotic exudation are strongly immunoreactive for *E. coli* antigens.

gangrene of gallbladder origin, carries a very high mortality rate. Those who suffer from diabetes mellitus or immunosuppression are especially susceptible to this serious condition.

### 8.3 Gangrenous cholangitis


Gangrenous cholangitis is a severe form of acute cholangitis without biliary stones [47, 51, 52]. Varied pathogens such as *Enterococcus*, *Escherichia coli*, and *Pseudomonas aeruginosa* cause ascending biliary tract infection [53].

A 70-year-old man complained of epigastralgia, vomiting, and difficulty in walking. Abdominal computed tomography scan suggested panperitonitis.



**Figure 21.**  
*Emphysematous cholecystitis (gas gangrene of the gallbladder) (H&E). The gallbladder wall accompanies gas bubbles released from thin long rods growing in the necrotic tissue. Co-infection of cocci (arrowheads) is noted. There is little cellular reaction in this highly hypoxic tissue.*


Emergency laparotomy indicated an 8 mm-sized perforation in the common bile duct in association with biliary peritonitis. Gallbladder was dilated, but without gallstones. Cholecystectomy and partial resection of the common bile duct was performed. T-tube drainage and pazufloxacin administration were effective to control the infection. Surgical specimens of the common bile duct and gallbladder microscopically showed transmural necrosis with perforation/ulceration and massive infection of Gram-positive cocci. The cocci were immunoreactive for enterococcal antigens, and culture of the bile demonstrated *Enterococcus faecalis* (**Figure 22**). Neutrophilic reaction was mild in the gangrenous lesion. Scanning electron microscopy demonstrated clustered cocci at the site of perforation (**Figure 23**).



IntechOpen

**Figure 22.**  
*Perforated enterococcal cholangitis (gross, H&E and immunostain). Massive infection of *Enterococcus faecalis* provokes transmural necrosis and perforation of the common bile duct (arrow). Enterococcal antigens (inset) are immunohistochemically demonstrated in the cocci overwhelmingly growing throughout the destroyed bile duct.*

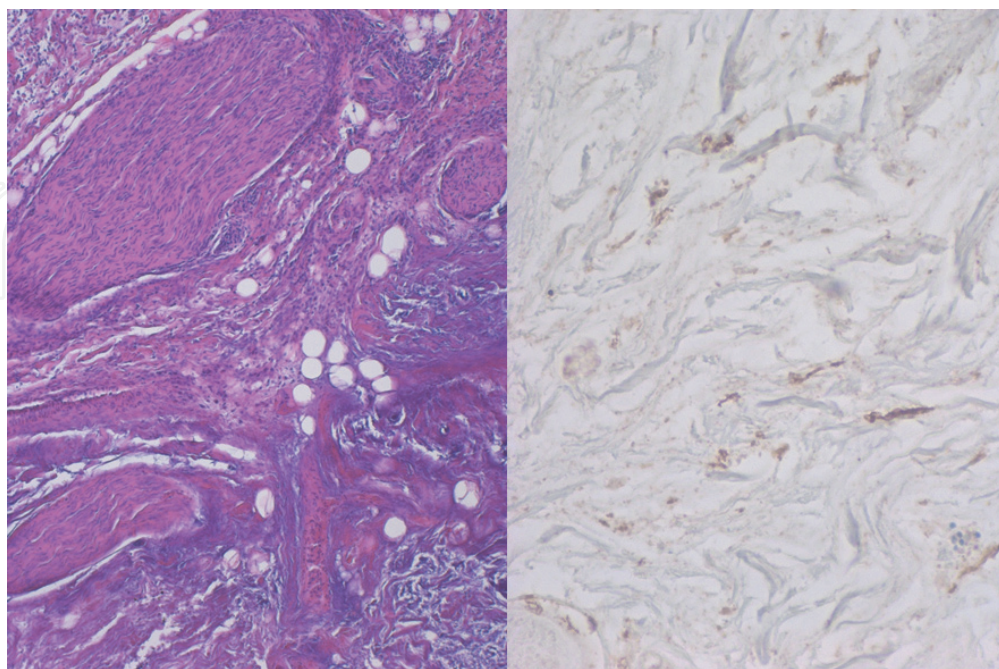




**Figure 23.**

Scanning electron microscopy of perforated enterococcal cholangitis. Numerous cocci, 0.7  $\mu\text{m}$  in size, are clustered at the site of perforation. Bar indicates 5  $\mu\text{m}$ .

A diabetic lady aged 40's complaining of severe abdominal and back pain visited an emergency suite. Diabetes mellitus had been poorly controlled. Mild obstructive dilatation of the bile duct and gallbladder were associated. Endoscopic retrograde biliary drainage was performed, but the patient soon died of septic shock. Autopsy demonstrated severe gangrenous and acalculous cholangitis and cholecystitis. Necrotic change with active growth of Gram-negative rods was proven in the biliary tree. Immunostaining using a monoclonal antibody disclosed the *Pseudomonas aeruginosa* antigen in the invasive bacilli (**Figure 24**). Neutrophilic reaction was relatively mild. The lower (intrapancreatic) part of the common bile duct remained intact. The association of diabetes mellitus was evident: the pancreatic islets revealed pronounced deposition of amyloid substances, and the kidney showed diabetic glomerulosclerosis with nodular lesions.



**Figure 24.**

Acute *Pseudomonas cholangitis* (H&E and immunostain). Diabetes mellitus accelerated severe necrotizing (gangrenous) inflammation of the extrahepatic biliary tree. Neutrophilic reactions are limited. The rods are immunoreactive for a *Pseudomonas aeruginosa* antigen visualized with a monoclonal antibody. Acalculous necrotizing cholecystitis was associated.

Luminal obstruction of the bile duct by pancreatobiliary malignancy is often associated with bactibilia and provokes secondary (ascending) bacterial infection. Enterococci often colonize the cancer tissue, and obstructive cholangitis and liver abscess may follow [54]. They are responsible for postoperative septic complications. The surgical specimen of cholangiocellular carcinoma in a female patient aged 80's showed necrotizing inflammation of the intrahepatic bile duct, as illustrated in **Figure 25**. Gram-positive cocci infected the necrotic cancer tissue. Culture of the bile was positive for *Enterococcus faecalis*.

#### 8.4 Pulmonary gangrene

Pulmonary gangrene is a rare form of acute and severe necrotizing pneumonia [55–57]. A necrotic process with cavity formation is observed in a pulmonary segment or lobe. The term pulmonary gangrene is applied when a large amount of lung tissue is sloughed off. The extent of necrosis is far extensive in pulmonary gangrene when compared with usual pulmonary abscess (**Figure 26**). The lesion is often located in the upper lobe of the lung. Thrombosis of large and small vessels plays a significant role in the ischemic pathogenesis. *Klebsiella pneumoniae* is often isolated from the gangrenous lesion. Infection of anaerobes should be the cause of foul smell. The anaerobes may secondarily infect the lung slough under the progressively anaerobic environment.

#### 8.5 Emphysematous pyelonephritis and renal papillary necrosis

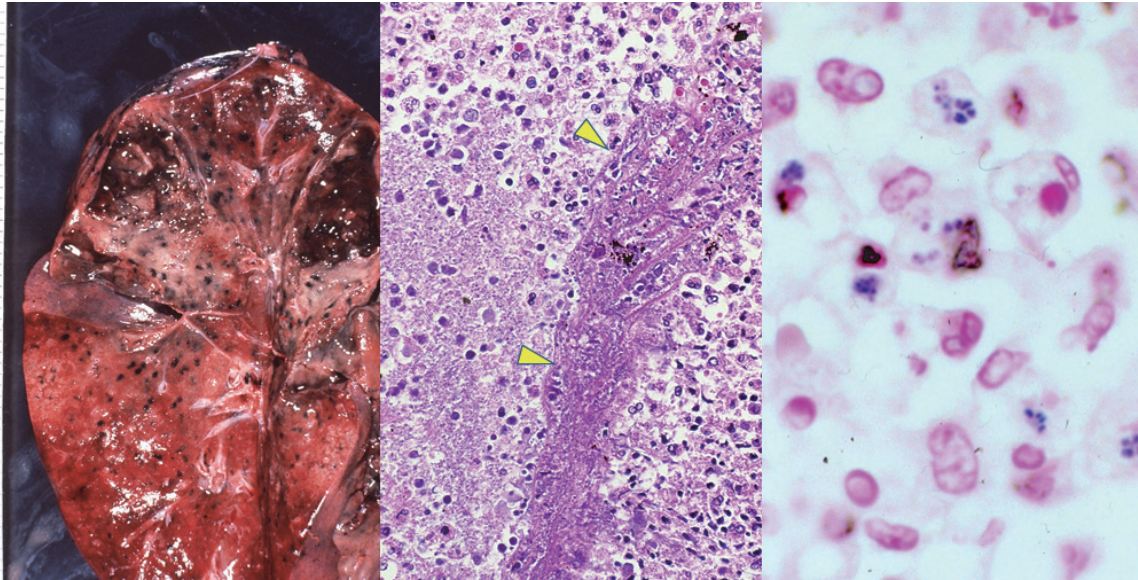
Emphysematous pyelonephritis is a severe, multifocal, necrotizing, and gas-forming form of acute ascending bacterial infection of the renal parenchyma. Extracapsular extension is common. The disease is most often seen in patients with poorly controlled diabetes mellitus. The common causative pathogens are *Enterobacteriaceae*, particularly *Escherichia coli* and *Klebsiella pneumoniae* [58–60].

*E. coli*-induced emphysematous pyelonephritis in a male patient aged 60's is demonstrated. The patient suffering from alcoholic cirrhosis manifested lumbar pain and high fever. Septic shock killed the patient. The total clinical course was



**Figure 25.** Enterococcal intrahepatic cholangitis superimposed on cholangiocellular carcinoma in the surgically resected liver (gross and H&E). Colonization of culture-proven *Enterococcus faecalis* is demonstrated in the necrotic cancer tissue (arrowheads), provoking acute intrahepatic cholangitis. Asterisk indicates poorly differentiated adenocarcinoma. High-powered H&E picture of the cocci is shown in the right panel.

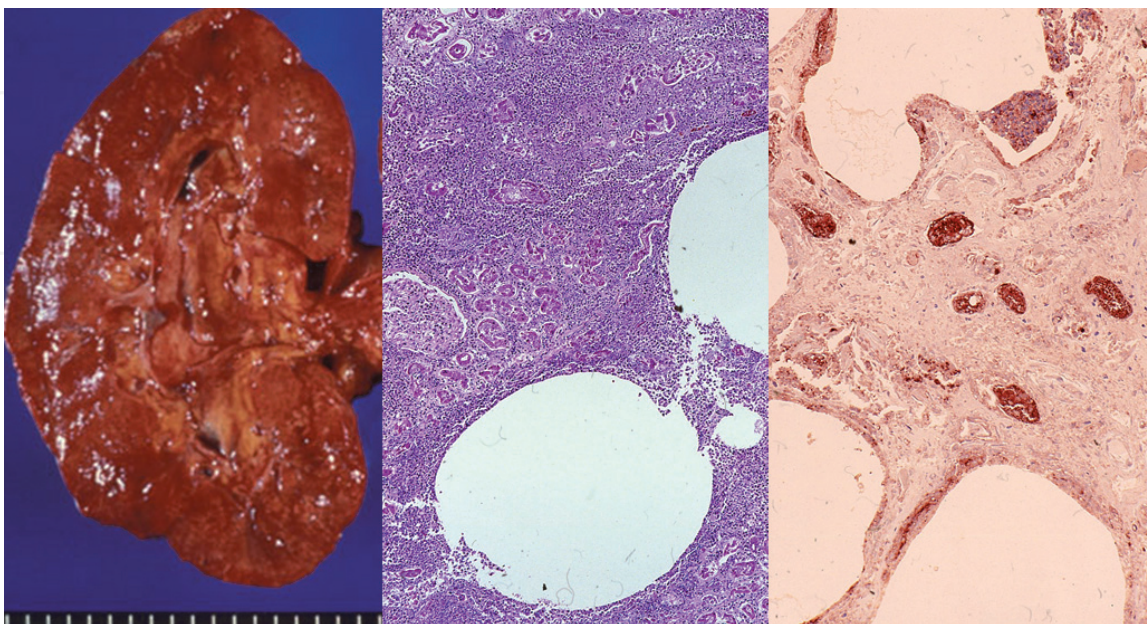




**Figure 26.**

*Pulmonary gangrene (gross, H&E, Gram). Necrotizing (cavity-forming) pneumonia is noted in bilateral upper lobes of the lung. Foul smell was characteristic. Gangrenous inflammation is evident histologically. Microbial culture from the lung lesion identified Bacteroides, Pseudomonas aeruginosa and Peptostreptococcus. Pseudomonal infection is indicated by arrowheads, and Gram-positive cocci (probably representing Peptostreptococcus) are phagocytized by neutrophils.*

9 days. At autopsy, both kidneys were enlarged and accompanied multifocal gangrenous changes in association with small foamy bubbles. Foul smell was not associated. Microscopically, gas formation was evident in the necrotic renal parenchyma, in association with diffuse neutrophilic infiltration (**Figure 27**). Numerous Gram-negative rods immunohistochemically expressing *E. coli* antigens are clustered within the necrotic renal tubules and around gas-filled bubbles. Microbial culture confirmed infection of *E. coli*. The condition can be categorized in non-clostridial gas gangrene.



**Figure 27.**

*E. coli-infected emphysematous pyelonephritis in a diabetic male patient aged 70's (gross, H&E and immunostain for E. coli antigens). The enlarged kidney shows multifocal gangrenous changes with formation of small bubbles. Gas-forming infection of E. coli is evident both histologically and immunohistochemically in severe acute purulent pyelonephritis.*

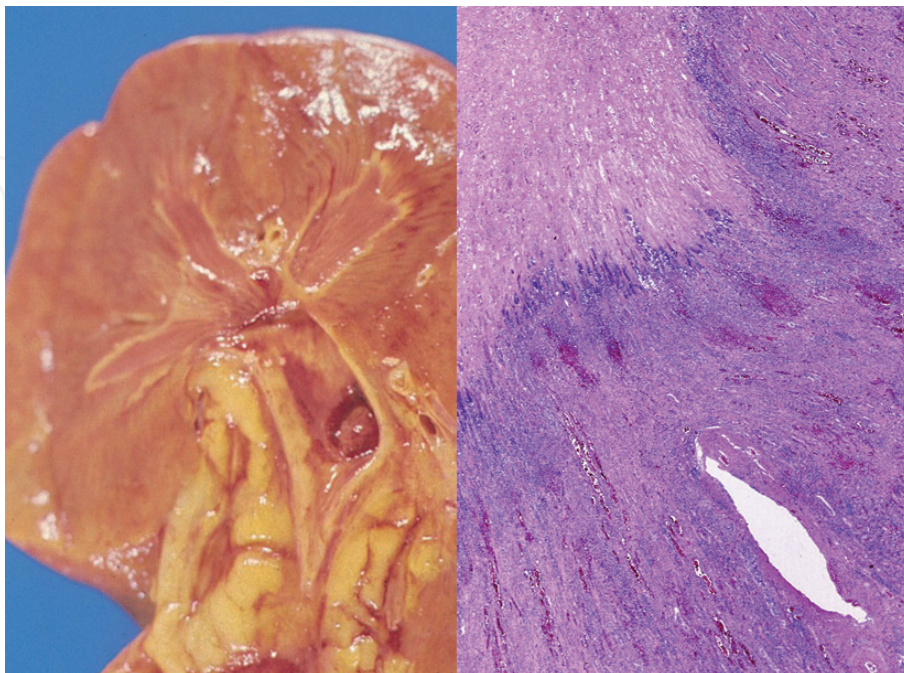


Renal papillary necrosis is another form of lethal renal infection of *E. coli* seen in poorly controlled diabetic patients (**Figure 28**). The disease is characterized by coagulation necrosis of the renal medullary pyramid: the renal papillae are anatomically vulnerable to ischemic changes [61]. *E. coli* septicemia often follows, and the prognosis is poor.

## 8.6 Endophthalmitis

Endophthalmitis represents bacterial or fungal infection of the eyeball, as an acute illness (medical emergency) having up to a few days duration [62–64]. Patients complain of blurred vision, red eye, pain, and lid swelling. Due to progressive vitritis, hypopyon can be seen at the time of presentation. Exogenous organisms invade the eyeball via trauma, surgery, or corneal infection. When infection spreads to the adjacent orbital soft tissue, it is called as panophthalmitis. Endophthalmitis is localized to the eye, and it does not result in bacteremia or fungemia. Patients with Hansen's disease (leprosy) are highly susceptible to traumatic eyeball infection. Streptococcal infection may be proven in the surgical specimen. Prolonged inflammation results in ophthalmophthisis (**Figure 29**). Gram-positive cocci, including *Staphylococcus epidermidis* and *Streptococcus viridans*, are commonly isolated after surgery for cataract or intravitreal injection. Gram-negative bacteria such as *Pseudomonas aeruginosa*, *Hemophilus influenzae*, and *Moraxella catarrhalis* infrequently cause endophthalmitis. *Bacillus cereus* and fungi, particularly *Fusarium* spp., are the major cause of post-traumatic endophthalmitis [65]. **Figure 30** illustrates a surgical specimen of a *Fusarium*-infected eyeball. Traumatic corneal infection extended to the surrounding tissues such as the lens, palpebra, and orbit to provoke panophthalmitis. The fungal colonies on the surface microscopically reveal several-celled (chained or beaded), fusiform to sickle-shaped macroconidia (hyphae).

Endocarditis-associated endogenous endophthalmitis is usually caused by *Staphylococcus aureus* and streptococci. *Klebsiella pneumoniae* is another important



**Figure 28.**  
*Renal papillary necrosis in a male patient aged 60's with uncontrolled diabetes mellitus (gross and H&E). The patient manifested symptoms of acute pyelonephritis and died of acute renal failure. At autopsy, the renal papillae are necrotic and demarcated with yellowish zones. Ascending infection of *E. coli* was associated.*





IntechOpen

**Figure 29.**

*Endophthalmitis in a leprosy patient (gross, H&E and immunostain). The eyeball is totally collapsed and deteriorated. Traumatic infection resulted in ophthalmophthisis. Gram-positive cocci inside the eyeball are immunoreactive for streptococcal antigens. Black melanin pigment in the iris is shown in the right bottom corner.*



**Figure 30.**

*Traumatic ophthalmitis caused by Fusarium infection in a Cambodian teenager (gross and H&E). The corneal fungal infection extended to the lens, palpebra and orbital connective tissue. Chained or beaded (several-celled) appearance of hyphae is characteristic of Fusarium spp. (the courtesy of Dr. Chhut Vanthana, a pathologist at Sihanouk Hospital Center of HOPE, Phnom Penh, Cambodia).*

pathogen for endogenous endophthalmitis. Hyperalimentation may lead to endophthalmitis caused by *Candida albicans*.

### 8.7 Gangrenous/emphysematous inflammation in other organs

Gangrenous/emphysematous inflammation may occur in the stomach [33, 66] (see **Figures 16 and 17**), esophagus [67], colorectum [68] (see **Figures 15 and 18**), urinary bladder [69, 70], ureter [71], urethra [72], penis [73], epididymis/testis [74, 75], endometrium [76], vagina [77], breast [78], bone [79], striated muscle [80], aorta [81], mediastinum [82], and endocardium [83]. Most cases are categorized in the non-clostridial etiology. Clostridial infection is seen in the gastrointestinal tract and pancreas, including emphysematous pancreatitis [28], as described in the Section 6.2.

## 9. Vincent angina and noma (cancrum oris, gangrenous stomatitis)

Vincent angina, named after the French physician Jean H. Vincent (1862–1950), represents acute necrotizing ulcerative gingivitis caused by fusiform bacteria and spirochetes [84, 85]. It is also called as trench mouth or fusospirochetosis. The patients complain of progressive painful swelling and hemorrhagic ulceration of the gum. The punched-out ulcer, 2–4 mm in size, is seen in the interdental papilla, and is covered with white pseudomembranes. Bad breath is associated. The infection can effectively be treated with penicillin. Infrequently, Vincent angina may spread to involve the mouth and throat to be diagnosed as acute necrotizing periodontitis.

Noma is a rapidly progressive and necrotizing infection of the soft and hard tissues around the oral cavity, as an advanced clinical form of Vincent angina [86, 87]. It is also called as fusospirochetal gangrene. It represents gangrenous stomatitis or necrotizing fasciitis of the oral cavity. The preferred age of the patients is below 10 years, and the disease mostly occurs in malnourished children of African poverty. The prognosis is poor. In developed countries, severely immunosuppressed patients (including acquired immunodeficiency syndrome) with poor oral hygiene may suffer from this critical condition. It begins in the form of Vincent angina, and is rapidly followed by painless and extensive necrosis of the oral cavity. Eventually, the extensive involvement of the cheek, nose, palate, and maxillary bones results in serious facial destruction. Hence, the name of “cancrum oris” (meaning oral cancer). Gas formation may be associated. In noma neonatorum, the disease manifests massive orofacial (mucocutaneous) gangrene in the neonate [88]. A similar disorder may be encountered in the genitalia and is called as noma pudendi.

The polymicrobial etiology is known in both conditions. Gram stain smeared from the ulcer easily identifies both fusiform bacteria and long spiral-shaped spirochetes (**Figure 31**). The key players are anaerobic, Gram-negative fusiform pathogens, *Fusobacterium nucleatum* (older term: *Bacillus fusiformis*) and *Prevotella intermedia*. The spiral microbes are identified as *Borrelia vincentii*. Many other bacteria have been co-isolated, including *Porphyromonas gingivalis* (an anaerobic, Gram-negative, porphyrin-producing bacillary pathogen of periodontitis), *Tannerella forsythensis*, *Treponema denticola*, *Staphylococcus aureus*, and nonhemolytic streptococci.



**Figure 31.** Vincent angina (Gram). Gram-stained smear prepared from a painful gingival ulcer demonstrates mixed bacterial infection, including Gram-negative fusiform bacilli and filamentous spiral microbes. Gram-positive cocci and long rods are also intermingled.



IntechOpen

**Figure 32.**

*Noma-like condition in a diabetic male patient aged 80's (progressive ulcerative gingivitis) (H&E, Grocott and immunostain). A gas-forming, necrotizing lesion is observed in the biopsied maxillary bone. Grocott methenamine silver stain identifies colonies of filamentous bacteria in the lesion, probably representing Actinomyces colonization. The Gram-negative bacteria around the gas bubble are immunoreactive with a commercial antiserum against Escherichia coli, which shows wide cross-reactivity to Gram-negative bacteria (the courtesy by Dr. Tatsuru Ikeda, Pathology Center, Hakodate Goryoukaku Hospital, Hakodate, Japan).*

**Figure 32** demonstrates a diabetic male patient aged 80's, suffering from noma-like condition (progressive ulcerative gingivitis with massive maxillary necrosis). Numerous bacilli accompanying gas formation and immunoreactive with *E. coli* antiserum grew in the maxillary bone. Colonies of filamentous bacteria, representing anaerobic *Actinomyces* spp., were coinfecting.

## 10. Flesh-eating bacteria infection

A variety of microbes cause progressive and often lethal gangrenous lesions in the soft tissue, particularly on the extremities. The mass media often call this frightening condition as “flesh-eating bacteria infection.” Three representative forms, fulminant streptococcal infection, *Vibrio vulnificus* infection, and *Aeromonas hydrophila* infection, are described below.

### 10.1 Fulminant streptococcal infection (streptococcal myonecrosis)

Streptococcal myonecrosis, a fulminant form of necrotizing fasciitis, presents a rapidly progressive gangrene of the extremities caused by infection of *Streptococcus pyogenes* (group A  $\beta$ -hemolytic *Streptococcus*), representing a prototype of “flesh-eating bacteria infection” [89, 90]. The disease affects persons of any age. Groups B and G  $\beta$ -hemolytic *Streptococcus* may also cause an identical fulminant condition [91, 92]. In some cases, protein S deficiency may be responsible for the necrotizing inflammation. It has been reported that vimentin, an intracellular intermediate filament of nonepithelial cells, is upregulated in the injured skeletal muscle cells and functions as the major skeletal-muscle protein binding to streptococci [93]. The life-threatening gangrene follows the subacute form of necrotizing fasciitis or occurs suddenly without preexisting ulceration. As shown in **Figure 5**, an advanced, deep pocket-forming decubitus in the sacral region may cause the lethal gangrenous lesion categorized in non-clostridial gas gangrene [18].

Clinically, high fever, pain at the site of infection, and skin necrosis (gangrene) with hemorrhagic bulla formation are associated. Scarlatiniform rash may be noted. Finally, massive gangrenous necrosis involves the extremity.

Microscopically, pronounced myonecrosis with foci of infection of Gram-positive cocci is observed. Gram-positive cocci grow within the lesion of advancing gangrenous necrosis of soft tissue. Cellular reactions are minimal, because of the ischemic (anaerobic) state with poor blood flow. In the cultured blood, short chains of Gram-positive cocci, morphologically typical of *Streptococcus*, are seen (Figure 33). Streptococcal septicemia provokes streptococcal toxic shock-like syndrome [94]. The bacterial exotoxins (superantigens) such as streptococcal pyrogenic exotoxins-A, B, C, F, and streptococcal superantigen provoke a severe cytokine storm. Hypercytokinemia activates hemophagocytosis by macrophages. Activation of NLRP3 inflammasome may be an essential event for the cytokine storm in streptococcal toxic shock-like syndrome [95].

The bacteria are commonly sensitive to penicillin and its derivatives, but the intravenous antibiotics administration is clinically ineffective, principally because of the absence of blood flow. The drug can hardly reach the site of infection.

## 10.2 *Vibrio vulnificus* infection

Progressive gangrene of the extremities caused by infection of *Vibrio vulnificus* is characteristically seen in patients with liver cirrhosis or hemochromatosis [96–99]. High iron concentration in the serum is essential for the bacteria to grow in the body. The genus *Vibrio* is categorized in the “halophilic” bacteria preferring to a high salt concentration for growth on plates. In contrast to *V. cholerae* and *V. parahaemolyticus* growing at the salt concentration of sea water (3–3.5%), *V. vulnificus* prefers to a lower salt concentration of the brackish (estuarine) water at the mouth of the river. *V. vulnificus* resides in the sea fish and oyster, particularly during the summertime. The bacteria proliferate in the gut of the sea creature when the temperature is high. Two transmission pathways of the pathogen are known: transenteric infection and traumatic skin infection. The former septicemic condition is often fatal, initiating a painful skin lesion on the arm or leg resembling honeybee bite. Gangrenous changes of the extremity progress rapidly.



**Figure 33.** Fulminant streptococcal infection (streptococcal myonecrosis) (Giemsa, H&E and Gram). Numerous chained cocci are demonstrated in the cultured blood. Vessels are thrombosed, and the striated muscle fibers show coagulation necrosis. Colonies of Gram-positive cocci are scattered in the ischemic tissue.



Gas formation is not associated. The traumatic infection of *V. vulnificus* is caused by an accidental trauma of the hand or fingers during cooking raw fish (preparing sashimi) or injuring the foot on the rocky seacoast. The prognosis is better than the former. The incidence of infection of the halophilic pathogen nicknamed “flesh-eating bacteria” is high in Japan.

Microscopically, perivascular cuffing of Gram-negative bacteria, showing a coccoid change, is noted in the involved ischemic/necrotic skin and soft tissue, while the cellular reaction is minimal (**Figure 34**).


### 10.3 *Aeromonas hydrophila* infection

Lethal gangrene of the extremities or face is also caused by *Aeromonas hydrophila* in patients under an immunocompromised condition, with diabetes mellitus or on hemodialysis, as a form of opportunistic infection [100–104]. The bacteria invade the skin via a minor trauma. **Figure 35** illustrates gross features of lethal gangrene of the right upper arm caused by *A. hydrophila*. Vesicles are formed on the necrotic skin. *A. hydrophila* belongs to the family *Vibrio* and widely distributes in fresh water and soil. *A. hydrophila* can grow at low temperature to cause food poisoning (watery or bloody diarrhea) due to production of heat-labile enterotoxins. An outbreak of *A. hydrophila* wound infection has also been reported among the participants for mud football games in Australia [105]. There were many infected scratches and pustules distributed over the bodies.

Microscopically, the lesion shows clusters of Gram-negative rods around necrotic subcutaneous tissue. Cellular reaction is poor. Gas formation may be associated. In the case as shown in **Figure 36**, necrotizing foci of infection were disseminated in the rectum, epididymis, prostate, liver, and kidneys.

## 11. Fournier’s gangrene

Fournier’s gangrene is a special form of fulminant cellulitis (fatal gangrene) involving the male scrotum and perineum [106–109]. The necrotizing change rapidly progresses to the surrounding soft tissue, eventually resulting in septicemia.



**Figure 34.**

*Vibrio vulnificus* infection in a cirrhotic male patient (H&E and Giemsa). In a biopsy specimen sampled in an emergency suite, perivascular cuffing by infected microbes is observed around small vessels and sweat glands (arrowhead) in the deep dermis through subcutis. Coccoid transformation is recognized in H&E and Giemsa stained preparations. Inflammatory reaction is sparse. Gram stain showed negativity.



IntechOpen

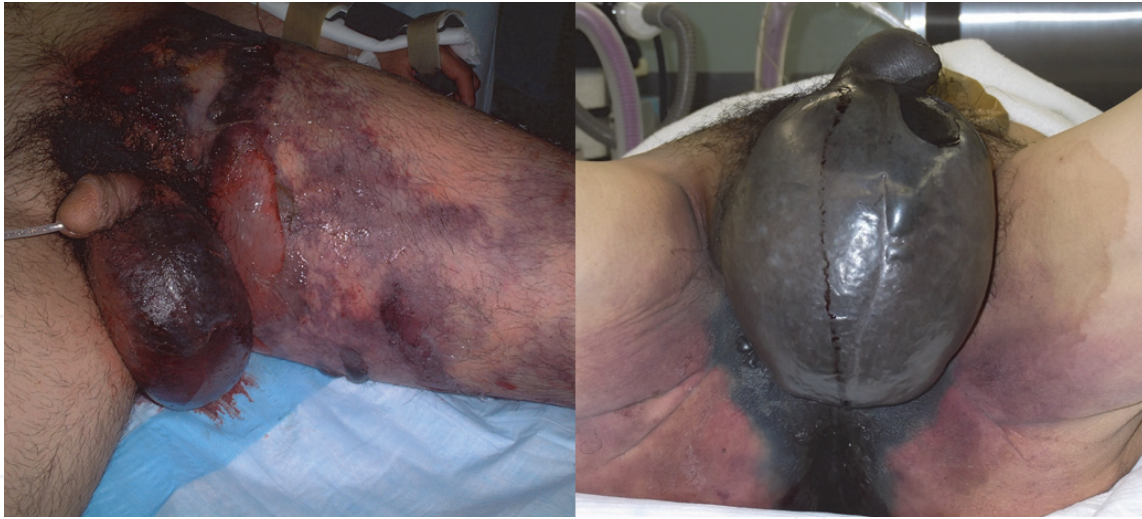**Figure 35.** *Aeromonas hydrophila* infection in a diabetic male patient aged 50's (gross appearance). Lethal gangrene is observed on the right upper arm. Vesicular skin change is evident. Autopsy confirmed that septicemia caused multiorgan abscess formation (see **Figure 36**).



**Figure 36.** *Aeromonas hydrophila* infection (H&E). Septic and necrotic/hemorrhagic lesions are seen in the rectal submucosa (left) and epididymis (right). Septic embolism is noted in the rectum, while Gram-negative rods are clustered around the dilated and thrombosed vascular structure in the epididymis, where inflammatory reaction is sparse.

The prognosis is poor. The scrotum is markedly swollen and becomes reddish-black in color (**Figure 37**). The penis is either involved or spared. The physiological lack of subcutaneous fat tissue in the scrotum and penis accelerates the bacterial spread. Gas production and malodor may be associated. It belongs to non-clostridial gas gangrene when gas production is noted. The preferred age ranges from 50 to 80 years. Male patients of Fournier's gangrene often have a history of diabetes mellitus. Immunocompromised condition also accelerates the disease. Perianal abscess should be a risk factor of the disease. Masturbation-related minor penile skin injury may cause the disease in younger age [110].

Microscopically, massive necrosis of the skin tissue is evident. Mixed bacterial infection, including *Streptococcus* and anaerobic bacteria, is often proven. When streptococci are isolated, it is categorized in fulminant streptococcal infection (**Figure 38**). Secondary surface infection of *Trichosporon* spp. (an opportunistic fungal pathogen) may occur.



**Figure 37.**

*Fournier's gangrene (gross findings of two male cases). Massive hemorrhagic necrosis started from the scrotum and extended to the left hip and leg (left). Marked black swelling of the scrotum is serious, and necrotizing change extends toward the perianal region (right). The rapidly progressive gangrene caused death in both patients. The penis is spared in the left case, but massively involved in the right case.*



**Figure 38.**

*Fournier's gangrene (gross, H&E, Gram and immunostain). Debridement specimen discloses massive transmural necrosis of the scrotal tissue. Gas bubbles are scattered in the heavily infected necrotic tissue. Gram-positive cocci are immunoreactive for streptococcal antigens. This case represents fulminant streptococcal infection with gas formation (non-clostridial gas gangrene).*

As illustrated in **Figure 39**, fulminant necrotizing inflammation involved the lower part of the rectum in a female patient suffering from myelodysplastic syndrome. Emergency surgery disclosed transmural gangrenous necrosis of the rectal wall with massive mixed bacterial infection, including *E. coli*. Occasionally, Fournier's gangrene has been complicated with rectal cancer [111, 112].

## 12. Necrotizing fasciitis

Necrotizing fasciitis represents clinically severe pyogenic infection (cellulitis) of the skin and underlying soft tissue [113–117]. Deep, painful, and intractable ulceration subacutely progresses predominantly on the extremities (**Figure 40**). Minor trauma may provide the entry for pathogens. The condition uncommonly follows

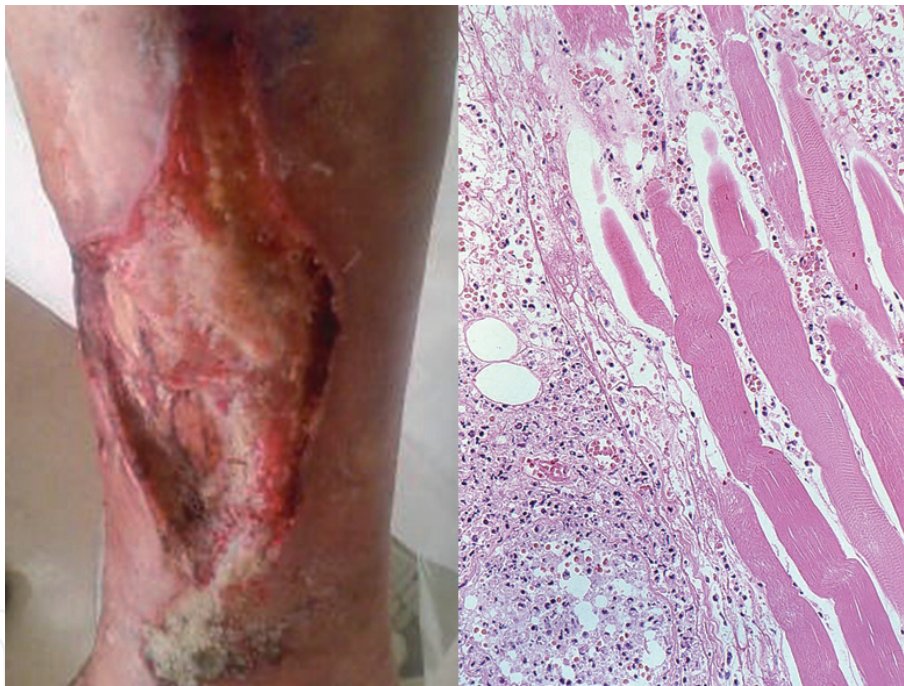




IntechOpen

**Figure 39.**

*Lethal Fournier's gangrene of the rectum (gross, H&E and immunostain). Transmural necrotic and gangrenous inflammation is seen in the lower part of the rectum in a female patient aged 60's suffering from myelodysplastic syndrome. Gram-negative rods are immunoreactive for E. coli-related lipopolysaccharide.*



**Figure 40.**

*Necrotizing fasciitis (gross and H&E). Deep and painful ulceration is caused by local and invasive bacterial infection. This aged male diabetic case had a history of arterial replacement therapy for atherosclerosis obliterans. In order to relieve pain and to avoid septicemic spread of infection, amputation surgery was performed. Necrotizing inflammation extends to the striated muscle layer.*

surgical procedures. Diabetes mellitus, immunosuppression, alcoholism, drug abuse, atherosclerosis-related ischemia, and malnutrition may be prodromal to this troublesome condition. It may be seen in healthy persons [118]. Necrotizing fasciitis is categorized into two types: type I (polymicrobial infection) and type II (monobacterial infection).

In **Figure 41**, necrotizing fasciitis seen in a poorly controlled diabetic male patient is presented. In the wintertime, a fan heater gave the patient a severe burn on his sole, because he did not feel pain sensation due to diabetic peripheral neuropathy. The doctor-shy patient did not visit a hospital for 1 week, and this allowed the lesion far progressed. Severe atherosclerosis had provoked dry gangrene in his



IntechOpen

**Figure 41.**

Localized severe burn on the sole of a diabetic male caused by a fan heater, resulting in necrotizing fasciitis (gross appearance). Because of diabetic neuropathy, deep ulcers occurred on the senseless foot. Dry gangrene on the first and second toes (arrowheads) indicates the association of diabetes-related atherosclerosis obliterans. The importance of foot care in diabetic patients should be emphasized.

toes. Diabetes-related neutrophilic dysfunction provided him with the vulnerability to infection. Polymicrobial (type I) necrotizing fasciitis resulted in septicemia. Emergency amputation saved his life. The importance of foot care for patients with diabetes mellitus should be emphasized.

Infrequently, necrotizing fasciitis is caused by *Pseudomonas aeruginosa* [119, 120]. Reportedly, the mortality rate of this type II lesion is 30%, and the infection often happens in the immunocompromised patients. Clinicians should consider empiric pseudomonal antibiotic coverage for preventing the progression of necrotizing limb infection.

An 18-year-old female patient had suffered from anorexia nervosa for 6 years. She happened to develop phlegmonous inflammation on her left lower leg, rapidly progressing to multifocal ulceration and gangrene. In 3 days, she underwent surgical amputation. *Pseudomonas aeruginosa* was cultured from blood and the leg lesion of necrotizing fasciitis. Immunohistochemical identification of the pseudomonal microbe was achieved by using a commercial monoclonal antibody. Representative features are illustrated in **Figure 42**.

Classic pathogens of cellulitis represent group A  $\beta$ -hemolytic *Streptococcus* and less frequently *Staphylococcus aureus*, but a diverse range of microorganisms, including *Pseudomonas aeruginosa* (as described above), cause cellulitis. Erythematous nodular lesions formed on the leg of neutropenic or leukemic patients were caused by *Stenotrophomonas maltophilia* [121]. Facial cellulitis may result from *Haemophilus influenzae* infection [122].

### 13. Fulminant coccal infection without gangrene of the extremities

Gram-positive cocci occasionally provoke fulminant, lethal systemic infection without gangrene of the extremities. The pathophysiology resembles that of flesh-eating bacteria infection, accompanying pronounced hypercytokinemia and poor cellular reactions. Streptococcal, pneumococcal, staphylococcal, and enterococcal etiologies are described below.





IntechOpen

**Figure 42.**

*Pseudomonas*-related necrotizing fasciitis in a young lady suffering from anorexia nervosa (gross, H&E and immunostain). Her leg with massive necrotic/gangrenous lesions was amputated (left, after sampling of histological specimens). Massive bacterial growth provoked little inflammatory reaction. The bacteria are immunoreactive for *Pseudomonas aeruginosa* antigen detected by a monoclonal antibody (the courtesy by Dr. Takashi Tsuchida, a pathologist in Hamamatsu Medical University Hospital, Hamamatsu, Japan).

### 13.1 Fulminant streptococcal infection without gangrene of the extremities

Fulminant infection of group A  $\beta$ -hemolytic *Streptococcus* (*Streptococcus pyogenes*) is typically featured by progressive gangrene in the soft tissue of the extremities, as described above in the Section 10.1. Streptococcal toxic shock syndrome provokes an aggressive lethal condition without predisposing diseases [123, 124]. It should be of note that fulminant group A streptococcal infection is also encountered in cases without gangrenous lesions of the extremities [125]. Streptococcal infection in the internal organs may cause the fatal disease.

We experienced five cases of fulminant streptococcal infection without gangrene of the extremities (**Table 1**). Four of five cases were young and immunocompetent, and encountered at forensic autopsy. Infectious foci were seen in internal organs such as the tonsil, bronchus, puerperal endometrium, and urinary bladder. The clinical course was very short ranging from 2 to 4 days. Infective and hemorrhagic cystitis with systemic streptococcal dissemination was encountered in an aged female patient with a history of cerebral infarction and femoral neck fracture (**Figure 43**). Necrotizing endometritis in a puerperal lady was the cause of streptococcal toxic shock-like syndrome, as illustrated in **Figure 44**. It can be categorized in so-called puerperal fever. Pregnancy-associated lethal infection should be of particular notice [126]. Group A *Streptococcus* infection was proven by microbial culture in two cases, and immunoreactivities of streptococcal antigens and Strep A were shown on the Gram-positive cocci in all five cases. Strep A is a carbohydrate antigen specific for group A *Streptococcus* [127].

There are two different pathological mechanisms in fulminant streptococcal infection without gangrene of the extremities [125]. One form with overwhelming bacterial growth is characterized by secondary systemic bacterial dissemination accompanying bacterial emboli with poor neutrophilic reaction. Bacterial embolism in the adrenal gland provokes bilateral adrenal hemorrhage (acute adrenocortical insufficiency), being categorized in Waterhouse-Friderichsen syndrome [128] (**Figure 45**). Another form without bacterial embolism was featured by bacterial

Case	Age/ sex	Clinical course	PD	Primary lesion	BE	MC	Autopsy findings
1	86 F	3 days	+	Hemorrhagic cystitis	+	ND	Bilateral renal cortical necrosis, bilateral adrenal hemorrhage, and DIC
2	30 M	2 days	–	Acute tonsillitis	+	–	Bilateral renal cortical necrosis, bilateral adrenal hemorrhage, and DIC (microthrombosis)
3	38 F	4 days	–	Necrotizing endometritis (Puerperal fever)	–	+*	Hemophagocytic syndrome, bilateral renal cortical necrosis, leukostasis, DIC (microthrombosis), myocardial ischemia, and liver congestion
4	24 F	3 days	+	Necrotizing bronchitis	– <sup>a</sup>	ND	Hemophagocytic syndrome, acute renal tubular necrosis, DIC, myocardial ischemia, pulmonary edema, and tonsillar hyperplasia
5	35 M	3 days	–	Necrotizing bronchitis	–	+	Hemophagocytic syndrome, acute renal tubular necrosis, DIC, myocardial ischemia, liver congestion, and pulmonary edema

PD—preexisting disease (case 1: cerebral infarct and femoral neck fracture; case 4: Graves' disease), BE—bacterial embolus formation in distant organs and tissues, and MC—microbial culture (ND: not done).  
\*Negative in the blood but positive from the uterine cervix.  
<sup>a</sup>Aspiration of coccal colonies into the alveolar space seen.

**Table 1.**

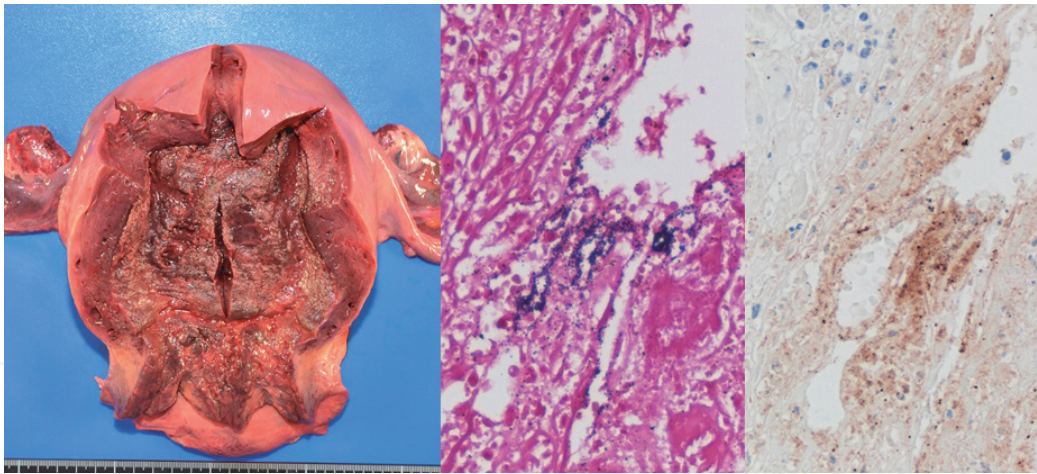
Summary of five autopsy cases of fulminant streptococcal infection without gangrene of the extremities [125].

**Figure 43.**

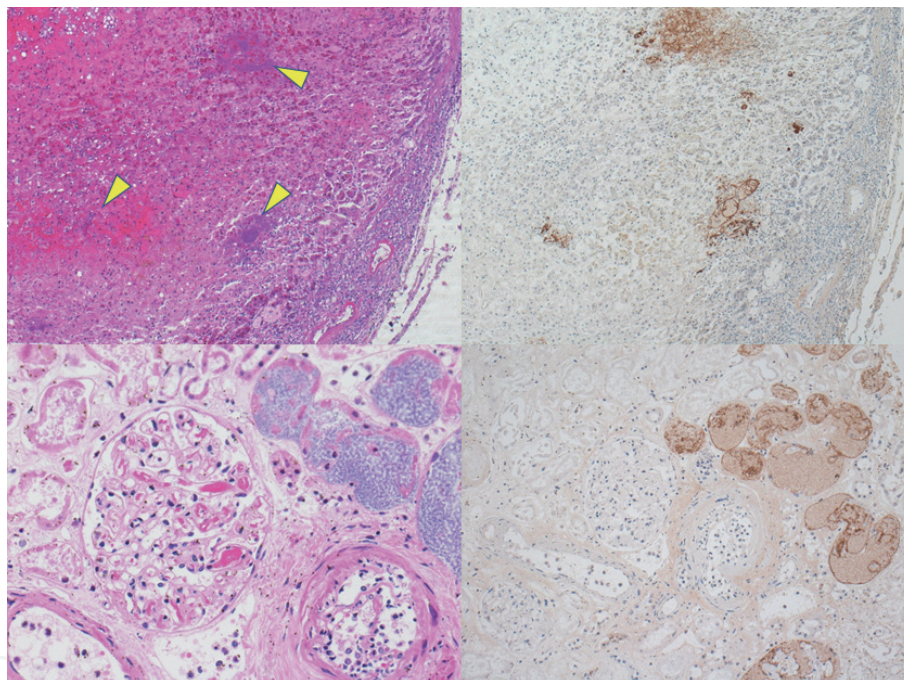
Fulminant streptococcal infection with hemorrhagic cystitis in an 86-year-old female patient (gross, H&E and immunostain). Massive hemorrhagic cystitis is evident. The cocci infected in the eroded bladder wall are immunoreactive for streptococcal antigens.

toxin-induced hemophagocytosis by activated macrophages, reflecting a hypercytokinemic state [129] (**Figure 46**). Hypercytokinemia and disseminated intravascular coagulation (DIC) are common phenomena in both forms, and bilateral renal cortical necrosis may be observed as an extreme manifestation of DIC [130]. Hematopoiesis in the bone marrow appear to be normal, but neutrophilic reactions are limited in the primary and disseminated infective foci. Supposedly, neutrophilic functions are acutely suppressed through two different mechanisms during the process of the fulminant disease. The disease is categorized in streptococcal toxic shock-like syndrome mediated by streptococcal superantigens [94, 95].





**Figure 44.** Fulminant streptococcal infection with necrotizing endometritis in a 38-year-old female patient (gross, Gram, immunostain). The eroded postpartum endometrium 4 days after delivery is colonized by Gram-positive cocci with positive immunoreactivity for Strep A, a carbohydrate antigen of group A Streptococcus. Neutrophilic reaction is limited in the endometrium. This condition is categorized as puerperal fever.



**Figure 45.** Fulminant streptococcal infection showing septic embolism, Waterhouse-Friderichsen syndrome, and bilateral renal cortical necrosis in the case demonstrated in **Figure 43** (adrenal and kidneys; H&E and immunostain). The adrenal glands show massive hemorrhagic necrosis. Septic streptococcal emboli (arrowheads) are seen in capillary vessels of the adrenal. The kidneys show bilateral cortical necrosis with marked fibrin thrombosis in the glomeruli and streptococcal colonization in the renal tubules (streptococcal antigens-positive).

Physicians should keep the possibility of fulminant streptococcal infection in mind, particularly when examining the patient manifesting progressive shock symptoms even without gangrene of the extremities. Autopsy prosecutors (diagnostic and forensic pathologists) must realize the difficulty in making an autopsy diagnosis, particularly when bacterial embolism is not identified under a microscope. The knowledge of these types of fulminant syndrome and the appropriate microscopic recognition of hemophagocytosis in the bone marrow, liver, and spleen are critically important for the autopsy prosecutors. When the association of the hypercytokinemic state was not suspected clinically and microscopically, one can hardly reach the correct autopsy diagnosis.



IntechOpen

**Figure 46.**

*Fulminant streptococcal infection without septic embolism caused by erosive bronchitis (bronchus: Gram, bone marrow and kidney: H&E). Local infection of Gram-positive cocci on the bronchus provoked hypercytokinemia and disseminated intravascular coagulation. Activated hemophagocytic macrophages (arrowheads) are distributed in the bone marrow. The kidney shows acute tubular necrosis.*

### 13.2 Fulminant pneumococcal infection

*Streptococcus pneumoniae* (so-called *Pneumococcus*), a capsule-forming Gram-positive coccus, is a leading cause of community-acquired pneumonia. Fulminant pneumococcal infection is a life-threatening disease, resulting in DIC and multiorgan failure [131, 132]. “Purpura fulminans” represents an extreme skin manifestation of DIC and Waterhouse-Friderichsen syndrome (caused by bilateral adrenal hemorrhage). The disease is often seen in splenectomized or immunosuppressed patients [133–135], while it is also observed in healthy patients without a history of splenectomy [136].

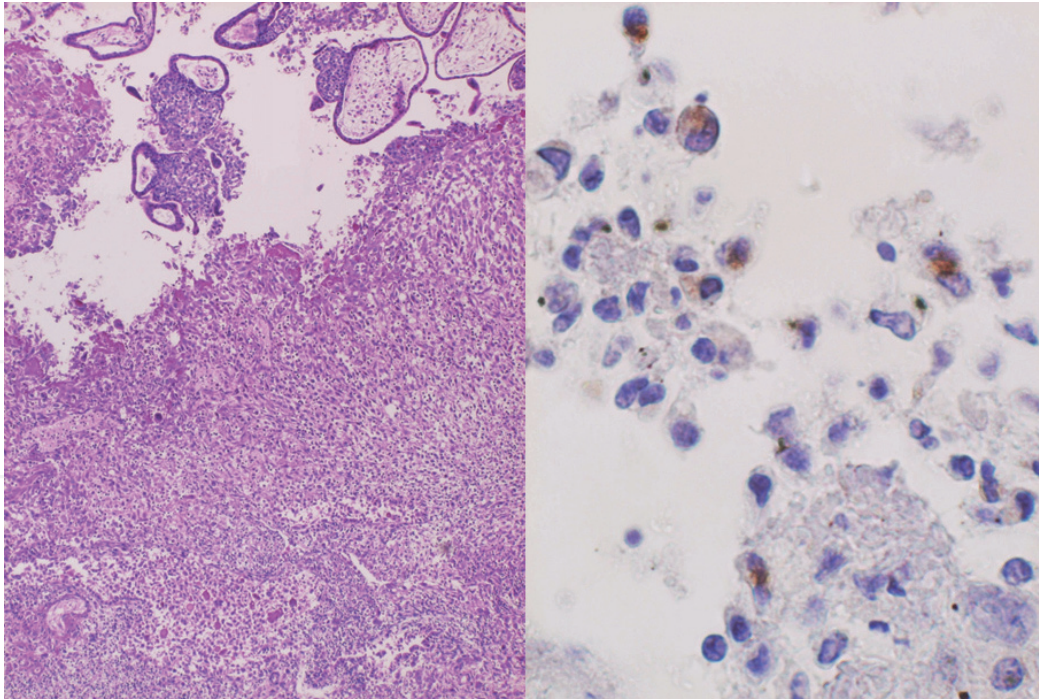
A pregnant woman aged 20’s manifested high fever and systemic skin rash. She had a history of splenectomy 10 years earlier. The total clinical course was as short as 2 days: septic shock provoked DIC and generalized petechiae. The disease represented puerperal fever. At autopsy, the uterus contained a dead fetus. The placenta contained small abscesses with infection of Gram-positive cocci with immunoreactivity of pneumococcal antigens (**Figure 47**). In the blood,  $\alpha$ -hemolytic *Streptococcus* was isolated. Cytokine storm-related hemophagocytosis was observed in the bone marrow and spleen. Neither gangrene of the extremity nor pneumonia was associated. The final diagnosis was fulminant pneumococcal infection as a form of overwhelming postsplenectomy infection.

Another case (a 60-year-old male patient) of fulminant pneumococcal infection is displayed in **Figure 48**. Total clinical course was 3 days. The small-sized spleen was observed. Neither limb gangrene nor pneumonia was observed. The entry of *S. pneumoniae* was unclear. The glomeruli showed bacterial embolism by capsule-forming Gram-positive cocci immunohistochemically expressing pneumolysin (a pneumococcal hemolytic exotoxin). The capsule formation is visualized with the colloidal iron method that stains the acidic substances blue.

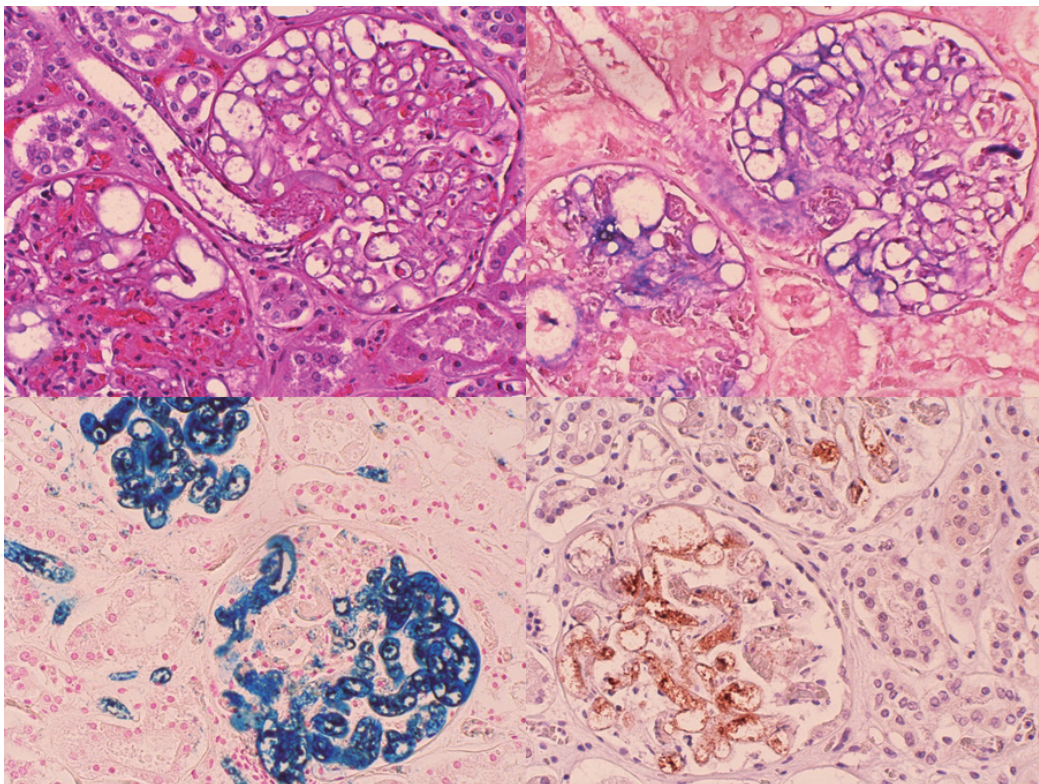
### 13.3 Fulminant staphylococcal infection

Community-acquired methicillin-resistant *Staphylococcus aureus* (CA-MRSA) often infects the skin and soft tissue of healthy young people. Severe invasive CA-MRSA infections include necrotizing pneumonia, necrotizing fasciitis, “purpura





**Figure 47.** Fulminant pneumococcal infection (H&E and immunostain). In this young lady with a history of splenectomy, the placenta was the entry of Gram-positive cocci. The bacteria with immunoreactivity of pneumococcal antigens are identified in the cytoplasm of neutrophils in a small abscess among placental villi.



**Figure 48.** Fulminant pneumococcal infection (H&E, Gram, colloidal iron and immunostain). Systemic spread of capsule-forming Gram-positive cocci drastically killed the patient. The glomeruli show septic embolism by cocci with colloidal iron-positivity (stained blue) and pneumolysin immunoreactivity (stained brown).

fulminans” (Waterhouse-Friderichsen syndrome) and disseminated infection with septic emboli [137–139]. The severe life-threatening infection may be caused by CA-MRSA, bearing the staphylococcal cassette chromosome mec gene type IV and



expressing Panton-Valentine leucocidin, an exotoxin lethal to leukocytes [140]. CA-MRSA has emerged as an important pathogen in the community worldwide.

A 70-year-old man suffering from hepatitis virus C-related liver cirrhosis complained of fever and sudden abdominal pain. He soon became septicemic and skin eruptions appeared. Blood microbial culture identified CA-MRSA. The patient died of septic shock 5 days after onset. Autopsy revealed massive septic emboli of Gram-positive cocci in systemic organs and tissues (**Figure 49**). Disseminated intravascular coagulation was associated. Hypercytokinemia activated hemophagocytosis by macrophages. No gangrene of the extremities was observed. Bacterial entry was unclear. The pathophysiological process resembled that of staphylococcal toxic shock syndrome: the bacteria secrete toxic shock syndrome toxin-1 to activate V $\beta$ 2-positive T-lymphocytes secreting cytokines [141].


Another male inpatient aged 60's suffering from liver cirrhosis received endoscopic ligation therapy for esophageal varices. The next day, he manifested high fever and hematemesis. He died of DIC and septic shock in 2 days. The entry of hospital-acquired MRSA (HA-MRSA) was the esophagus, and disseminated septic emboli provoked bilateral adrenal hemorrhage (Waterhouse-Friderichsen syndrome) and hemophagocytosis. **Figure 50** demonstrates glomerular septic emboli of MRSA and massive adrenal hemorrhage.

### 13.4 Fulminant enterococcal infection

Enterococci may rarely cause a fulminant form of systemic infection [142–144]. Enterococcal gangrenous inflammation in the bile duct was already described in the Section 8.3. Opportunistic, necrotizing, and lethal enterococcal enteritis may be encountered in immunocompromised patients. A diabetic male patient aged 80's with acute thrombosis of the superior mesenteric artery is presented. In the surgical specimen, the transmurally necrotic small bowel wall was heavily colonized by Gram-positive and enterococcal antigens-positive cocci (**Figure 51**), and *Enterococcus faecalis* was identified by microbial culture. Formation of capsules (biofilm), rich in acidic substances, was evident with colloidal iron stain. Septic dissemination of enterococci followed to kill the patient.



**Figure 49.** Fulminant CA-MRSA infection (lung and heart: H&E). Septic emboli of Gram-positive cocci are pronounced in the pulmonary artery branches. Microabscess is formed in the heart muscles.



IntechOpen

**Figure 50.**  
*Fulminant HA-MRSA infection (kidney: H&E, Gram, immunostain for staphylococcal antigen and PBP2'; and adrenal: H&E). Septic emboli in the glomerulus represent Gram-positive cocci with positivity for staphylococcal antigens and penicillin-binding protein 2' (PBP2'), immunohistochemically confirming MRSA septicemia (see also **Figure 10**). Marked adrenal hemorrhage (right panel) indicated an extreme form of DIC or Waterhouse-Friderichsen syndrome.*



**Figure 51.**  
*Fulminant enterococcal infection (H&E, colloidal iron, and immunostain). Enterococcal necrotizing enteritis followed acute thrombosis of superior mesenteric artery in a diabetic male patient aged 80's. In the surgical specimen, the transmurally necrotic small bowel wall is heavily colonized by Gram-positive cocci with colloidal iron-stained thick acidic capsules. Enterococcal antigens are proven. Microbial culture identified Enterococcus faecalis. Septic systemic dissemination killed the patient.*

## 14. Gangrenous inflammation associated with uncontrolled diabetes mellitus

As abovementioned repeatedly, diabetes mellitus predisposes gangrenous inflammation, particularly when the disease is poorly controlled. Here, three special disease situations as severe complications of diabetes mellitus are described.

### 14.1 Malignant otitis externa

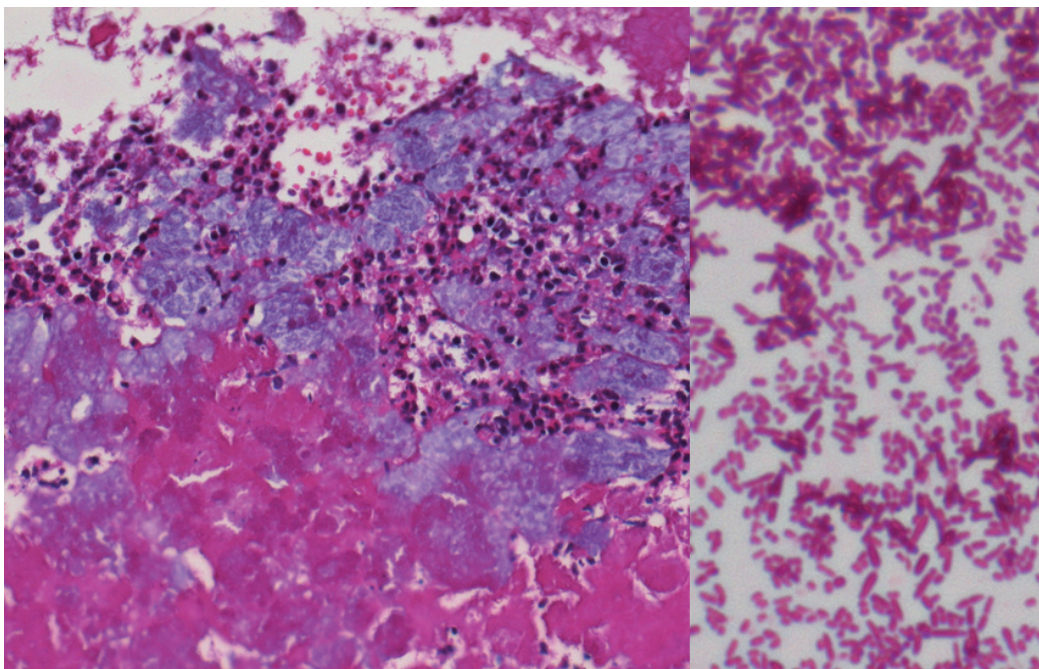
The external ear canal guards against infection by producing a protective layer of cerumen that creates an acidic and lysozyme-rich environment. Malignant otitis externa is a type of life-threatening infection in the aged and poorly controlled

diabetic patients. Those immunocompromised patients who suffer from acquired immunodeficiency syndrome, undergo chemotherapy, and take immunosuppressant medications such as glucocorticoids may also be vulnerable to this serious disease [145–149]. Once infection becomes established in the external meatus of the susceptible patient, the bacteria invade the underlying structures of the soft tissue and destroy the temporal bone, and finally resulting in septicemia. Malignant otitis externa should be suspected if tenderness, erythema, and/or edema of the external ear and adjacent tissues are noted on physical examination. *Pseudomonas aeruginosa* is the inciting organism in the vast majority of cases. Features of biofilm infection by Gram-negative rods are characteristic. The biopsy histology is illustrated in **Figure 52**. Much less frequently it is caused by *Staphylococcus aureus* and group A  $\beta$ -hemolytic *Streptococcus*. Fungal etiology is also known, and *Aspergillus* and *Candida* can be the causative microbes. When untreated, the mortality rate is around 50%.

## 14.2 Mucormycosis

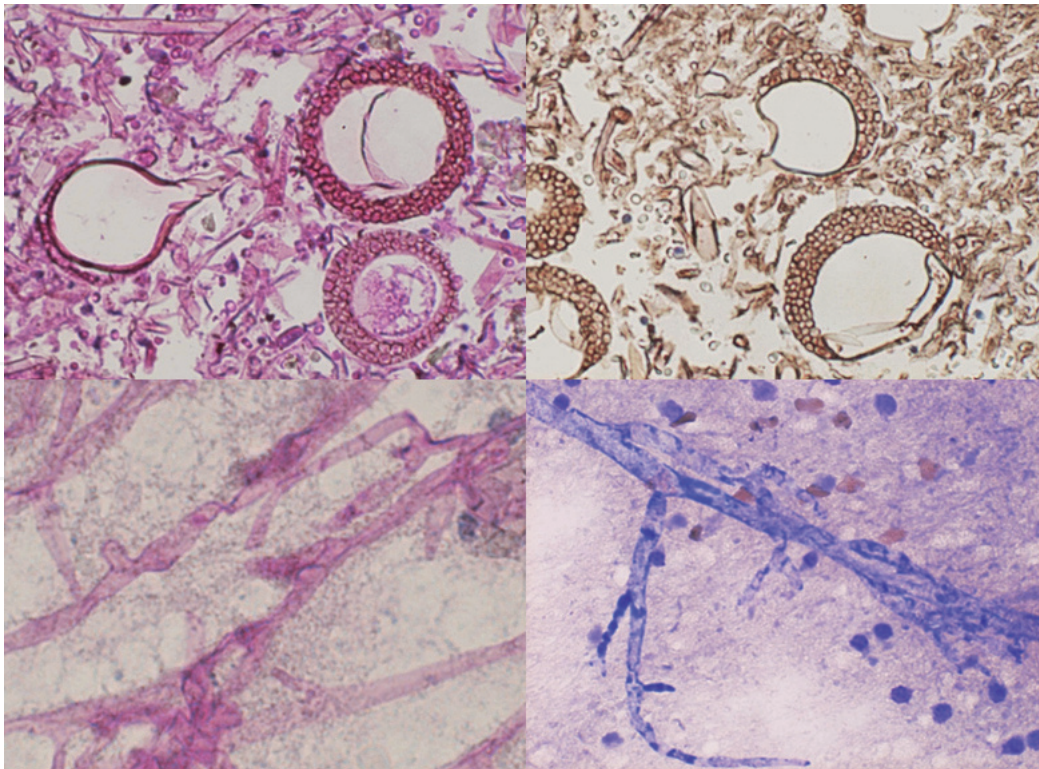
Mucormycosis (zygomycosis) is infection by the class *Zygomycetes*, mainly *Mucor ramosissimus*, *Rhizomucor pusillus* and *Rhizopus oryzae*. Sixteen species of *Zygomycetes* infect the human. *Zygomycetes* (mucoral fungi) are common molds growing in a moist environment. Fungi commonly have chitin as structural polysaccharide, but *Zygomycetes* synthesize chitosan, a deacetylated homopolymer of chitin. Hence, serum  $\beta$ -D-glucan, a laboratory marker of fungal infection, is negative in case of mucormycosis [150].

The main sites of localized mucormycosis are the lung and paranasal cavity. Formation of conidiophores is rarely encountered in case of paranasal cavity infection. The gross features of systemic mucormycosis represent hemorrhagic infarction of the involved tissues and organs [151]. Microscopically, faintly basophilic and wide hyphae, showing the lack of septum formation and wide angle of lamification, are seen in the mycotic thrombus. Stamp smear preparations (**Figure 53**) reveal typical microscopic morphology of mucormycosis. Infection of *Zygomycetes* is microscopically featured by angioinvasiveness and weak reactivity with Grocott



**Figure 52.** Malignant otitis externa (H&E and Gram stain on smear preparation). In this lethal diabetic case (a female patient aged 40's) accompanying pseudomonal septicemia, Gram-negative rods densely colonize the necrotic debris in necrotizing petrositis. Myxoid matrix of the colony indicates biofilm infection. Gram-negative rods are demonstrated in the smear preparation.





**Figure 53.** *Mucormycosis. Formation of conidiophores in the paranasal cavity and stamp cytology preparation of cerebral mucormycosis in a pediatric acute leukemia case. Aerated growth condition within the cavity is essential for conidiophore formation (H&E and immunostain for Rhizomucor antigen). Non-septating hyphae show variable thickness. Wide angle of lamification is distinct from Aspergillus hyphae (PAS and Giemsa, the courtesy by Dr. Suzuko Moritani, a pathologist at Shiga Medical University Hospital, Otsu, Japan).*

staining, as illustrated in **Figure 54**. However, some lesions of mucormycosis reveal clear basophilia with strong Grocott reactivity (refer to **Figure 57**, displaying neonatal intestinal mucormycosis).

Cutaneous mucormycosis is infrequently encountered as skin manifestation of systemic mucormycosis [152, 153]. A rare lethal variant is craniofacial



IntechOpen

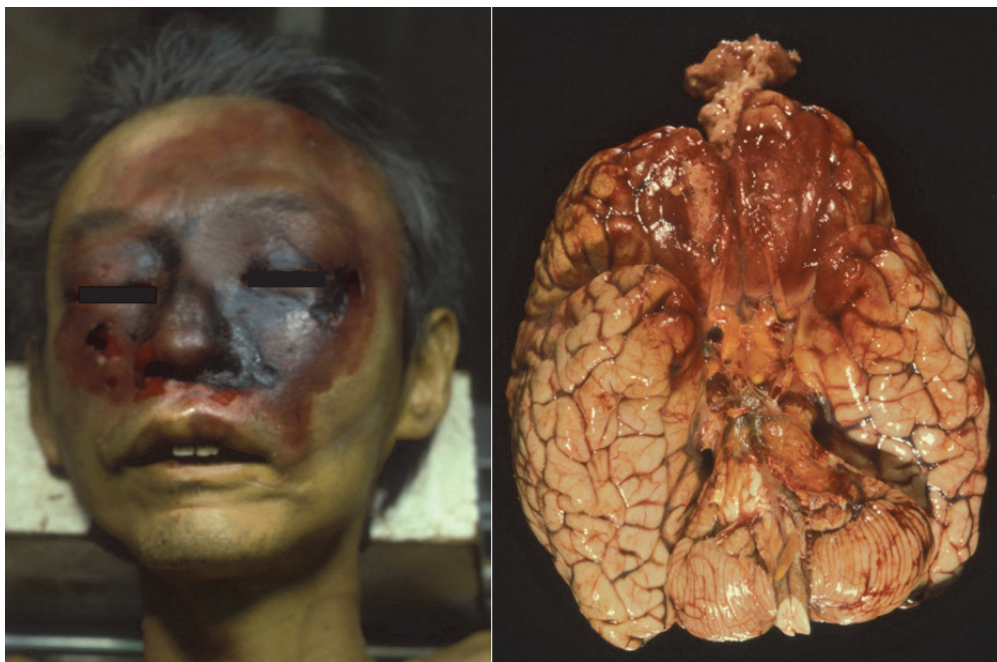**Figure 54.** *Angioinvasive mucormycosis (H&E, Grocott, and immunostain). Zygomycetes frequently shows angioinvasion, resulting in hemorrhagic infarction of the organ and tissue. Weak reactivity with H&E and Grocott stain is characteristic of this opportunistic fungus, as arrowheads indicate. The hyphae are clearly immunoreactive with anti-Rhizomucor monoclonal antibody, which is cross-reactive with Zygomycetes but not with Aspergillus or Candida.*

(rhinocerebral) mucormycosis, which is encountered as a complication of poorly controlled diabetes mellitus [154, 155]. Angioinvasive colonization of *Zygomycetes* aggressively progresses from the paranasal cavity to the overlying facial skin and to the lower part of the frontal lobe of the brain (**Figure 55**).

### 14.3 *Clostridium butyricum*-induced necrotizing enteritis

*Clostridium butyricum* is a spore-forming, Gram-positive obligate anaerobic rod with a rugby ball-shaped configuration [156]. It frequently forms spores even in the *in vivo* state, a feature quite different from *C. perfringens*. A male patient aged 30's with severe uncontrolled diabetes mellitus suddenly suffered from mesenteric arterial thrombosis. The surgically resected small bowel accompanied pneumatosis cystoides intestinalis (gas formation in the intestinal wall). Computed tomography scan demonstrated gas embolism filling the portal vein branches in the liver. Microscopically, gas-filled spaces were formed in the submucosa of the small bowel. Spore-forming Gram-positive large rods were discerned in the necrotic gut wall (**Figure 56**). Capsule formation by the spore-forming rods was proven with colloidal iron stain. Microbial culture of the blood identified *C. butyricum*. In contrast to gas gangrene caused by *C. perfringens*, the prognosis of the patient with *C. butyricum*-induced gas gangrene is not so poor. In fact, this patient was alive for years after surgery [157].

Neonatal necrotizing enterocolitis occurs in premature babies. The most likely cause of the disease is infection of *C. butyricum* [158–160]. Symptoms caused by small bowel necrosis include poor feeding, bloating, decreased activity, blood in the stool, or vomiting of bile. Poor blood flow results in ischemic necrosis of the bowel wall. Pneumatosis cystoides intestinalis and perforation with pneumoperitoneum and peritonitis are often associated. Surgery is required in those who have free air in the abdominal cavity. Breastfeeding may prevent the disease. Probiotic studies have reported that peroral administration of *C. butyricum* improves or even prevents clinical manifestation of pseudomembranous colitis due to *C. difficile* infection and hemorrhagic colitis caused by enterohemorrhagic *Escherichia coli* (O-157, H7)



**Figure 55.**

Lethal mucormycosis of rhinocerebral type in a poorly controlled diabetic male patient aged 60's (gross appearance). Angioinvasive mycosis resulted in hemorrhagic necrosis of the face and anteroinferior part of the brain. Infection had been extended from the paranasal cavity.





IntechOpen

**Figure 56.**

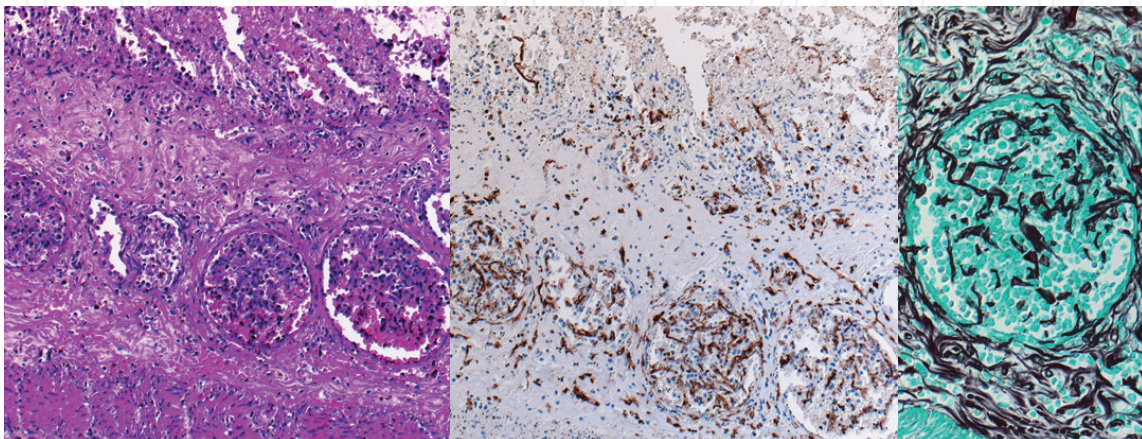
*C. butyricum*-induced gas gangrene (necrotizing enteritis) (H&E and Gram). The small bowel was surgically removed for mesenteric arterial thrombosis in a male patient aged 30's with severe diabetes mellitus. Gas-filled spaces are formed in the submucosa. Spore-forming, Gram-positive, rugby ball-shaped large rods are identified seen in the necrotic gut wall.

infection [161, 162]. Neonatal intestinal mucormycosis, clinically resembling neonatal necrotizing enterocolitis, is fetal and challenging to make an appropriate diagnosis [163, 164]. Risk factors include premature birth, malnutrition, and asphyxia. The entry of the organism is thought to be the oropharynx or nares.

**Figure 57** demonstrates the representative microscopic features of lethal ileal mucormycosis seen in a premature baby.

## 15. Anthrax and *Bacillus cereus* infection

Anthrax is a zoonotic infection of a large-sized Gram-positive bacillus, *Bacillus anthracis* [165–168]. Formation of spores and capsules is closely related to the pathogenicity of the microbe. Three clinical forms are known, involving the skin, lungs, and intestines. The latter two are often lethal. Skin anthrax, predominantly involving the arm, is an occupation-related infection of veterinarians and those who



**Figure 57.**

Neonatal intestinal mucormycosis (H&E, immunostain and Grocott). The premature baby was treated for neonatal necrotizing enterocolitis. Autopsy disclosed necrotic ileal wall with massive transmural infection of *Mucor* fungi. Vascular involvement (mycotic embolism) is evident by both immunostaining with a monoclonal antibody against *Rhizomucor* antigen and Grocott silver. Strong Grocott reactivity is noted in this case.

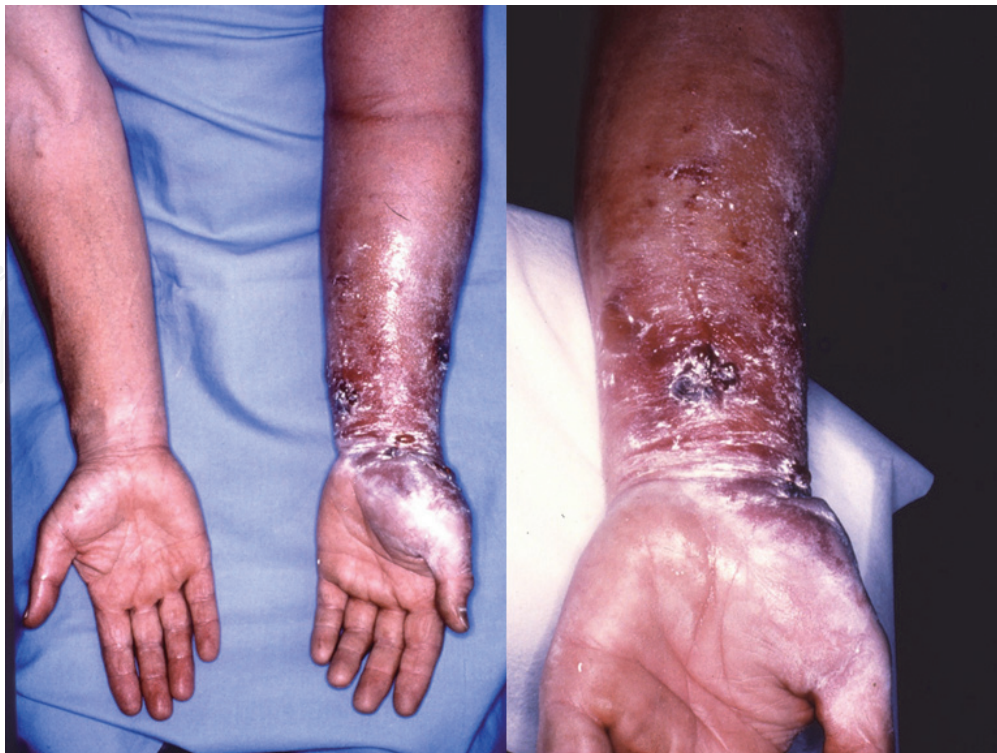

treat animal hair, skin, or carcass. The latent period is within 4 days. The skin lesion is necrotic and ulcerated to form hemorrhagic crust (eschar or black necrosis) (**Figure 58**). Characteristically, the ulcer is painless. Gram-positive rods are easily found in the exudate. *B. anthracis* is the best-known bioterrorist, because the spores are tolerant to dry conditions for a long period of time, and inhalation of the spored microorganisms provokes lethal necrotizing pneumonia. Ulcer-forming skin infection is also caused by other *Bacillus* species, such as *B. megaterium* and *B. pumilus* [169].

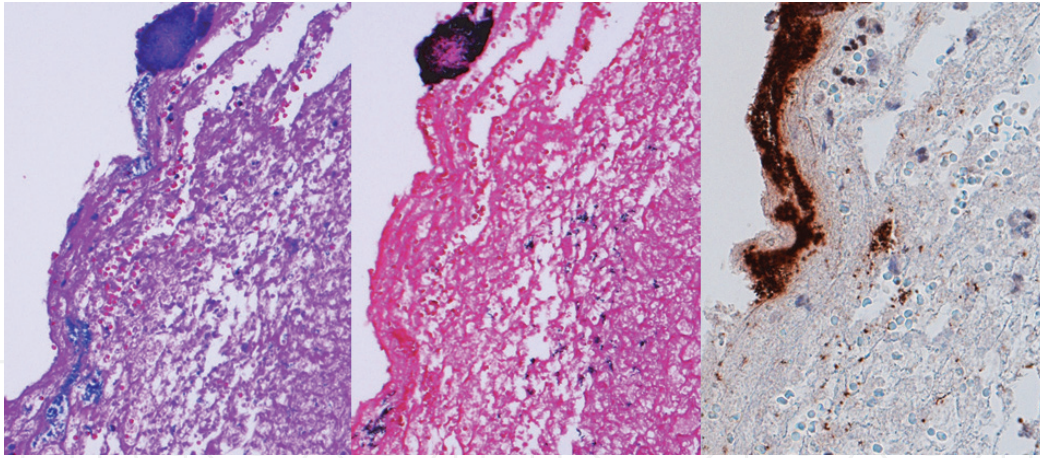
*Bacillus cereus* is associated mainly with food poisoning, but it may cause potentially fatal non-gastrointestinal infection. The pathogenicity of *B. cereus* is related to the production of tissue-destructive exoenzymes common to *B. anthracis*. *B. cereus* produces a potent  $\beta$ -lactamase, conferring marked resistance to  $\beta$ -lactam antibiotics. Clinically, anthrax-like progressive pneumonia, fulminant sepsis, and devastating central nervous system infections may be seen in immunocompromised individuals, intravenous drug abusers, and neonates. It also occurs in immunocompetent individuals [170]. The primary cutaneous/soft tissue infection of *B. cereus*, mimicking necrotizing fasciitis or non-clostridial gas gangrene induced subsequent to trauma, has been documented [171, 172].

**Figure 59** demonstrates primary necrotizing infection of *B. cereus* in the soft tissue of the hip, as a form of necrotizing fasciitis. Gas formation was not associated in this case. Trauma-related soft tissue gangrene, caused by a spore-forming Gram-positive bacillus, *B. cereus*, led this diabetic adult patient to death. Gram-positive rods heavily colonized the necrohemorrhagic muscle tissue.

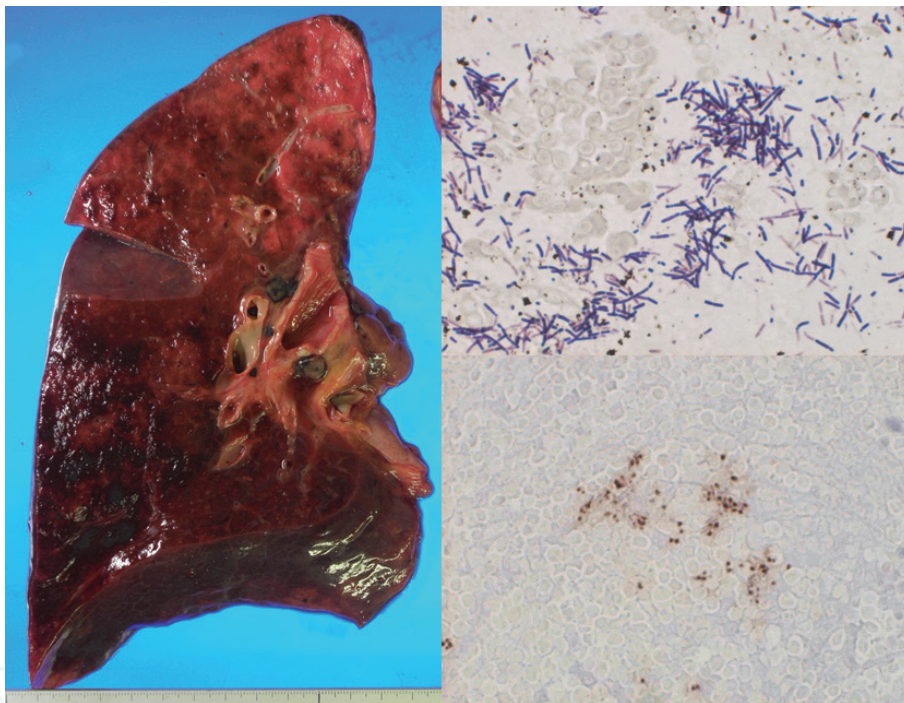
A 68-year-old housewife received intermittent chemotherapy against lymphoplasmacytic leukemia for 13 years. Her blood contained numbers of indolent small-sized leukemic cells. She happened to take curdled milk, and next day she complained of dyspnea and consciousness disturbance. She expired soon. The



**Figure 58.** Cutaneous anthrax (gross appearance). Occupation-related infection in a Japanese veterinarian is shown. The lesion of cutaneous anthrax on the left forearm is necrotic and ulcerated to form hemorrhagic crust (eschar). The courtesy by Dr. Keiko Oka, a dermatologist at Tokyo Hospital of Health Insurance Association of Nippon Express, Tokyo, Japan.



**Figure 59.** *Bacillus cereus*-induced necrotizing fasciitis (H&E, Gram and immunostain). Trauma-related lethal soft tissue gangrene is formed on the hip of the diabetic patient. Gram-positive rods colonize the necrohemorrhagic soft tissue. Immunostaining for *Bacillus cereus* antigens is strongly positive (the courtesy of Dr. Etsuko Nakamura, a pathologist at Toyohashi Medical Center, Toyohashi, Japan).



**Figure 60.** Lethal *Bacillus cereus* pneumonia in a female patient with indolent leukemia (gross, Gram and immunostain). Severe necrotizing hemorrhagic pneumonia was caused by incidental aspiration of sweet-curdled milk. Gram-positive rods grow in the necrotic lesion. The antiserum against *B. cereus* labels spores in the rods.

growth of *B. cereus* in fluid milk had provoked sweet curdling [173]. Autopsy disclosed massive hemorrhagic and necrotizing pneumonia caused by *B. cereus* in the right lower lobe. Spore-forming Gram-positive rods were identified in the lesion (**Figure 60**). *B. cereus* antiserum clearly labeled spores in the rod-shaped bacteria. It is highly likely that aspiration of the curdled milk resulted in lethal *B. cereus* pneumonia.

## 16. Conclusive remarks

The author reviewed pathological aspects of a variety of gangrenous lesions. The causative pathogens are commonly anaerobic. Often times, the lesions are clinically



severe and fulminant, and often encountered at autopsy. The exact morphological recognition of the respective lesions is essential for the pathologists to make an appropriate histopathologic diagnosis. Immunohistochemical approach is useful for identifying the pathogenic microorganisms. The author sincerely hopes that the present chapter may contribute to brushing up of the knowledge of the lesions with relatively low frequency but with high clinical implications.

## **Disclosure**

There were no funding sources for reporting the present chapter. The author has no conflict of interest for reviewing the present chapter.

## **Author details**

Yutaka Tsutsumi  
Diagnostic Pathology Clinic, Pathos Tsutsumi, Nagoya, Japan

\*Address all correspondence to: pathos223@kind.ocn.ne.jp

## **IntechOpen**

© 2020 The Author(s). Licensee IntechOpen. This chapter is distributed under the terms of the Creative Commons Attribution License (<http://creativecommons.org/licenses/by/3.0>), which permits unrestricted use, distribution, and reproduction in any medium, provided the original work is properly cited. 



## References

- [1] Tsutsumi Y. Application of the immunoperoxidase method for histopathological diagnosis of infectious diseases. *Acta Histochemica et Cytochemica*. 1994;27:547-560
- [2] Tsutsumi Y. Pathology of Skin Infections. New York: Nova Biomedical; 2013. p. 394. Available from: [https://www.pathos223.com/pathology/bookintroduction/pathology\\_of\\_skininfections/](https://www.pathos223.com/pathology/bookintroduction/pathology_of_skininfections/)
- [3] Fujii M, Mizutani Y, Sakuma T, et al. *Corynebacterium kroppenstedtii* in granulomatous mastitis: Analysis of formalin-fixed, paraffin-embedded biopsy specimens by immunostaining using low-specificity bacterial antisera and real-time polymerase chain reaction. *Pathology International*. 2018; 68:409-418
- [4] Tsutsumi Y. Low-Specificity and High-Sensitivity Immunostaining for Demonstrating Pathogens in Formalin-Fixed, Paraffin-Embedded Sections. London, UK: IntechOpen; 2019. pp. 1-46. DOI: 10.5772/intechopen.85055. Available from: <https://www.intechopen.com/books/immunohistochemistry-the-ageless-biotechnology/low-specificity-and-high-sensitivity-immunostaining-for-demonstrating-pathogens-in-formalin-fixed-pa>
- [5] Tsutsumi Y. Pathology of Infectious Diseases. Nagoya, Japan: Pathos Tsutsumi; 2003. Available from: <https://pathos223.com/en/>
- [6] Dafiewhare OE, Agwu E, Ekanem P, et al. A Review of Clinical Manifestations of Gangrene in Western Uganda. London, UK: IntechOpen; 2013: 1-14. DOI: 10.5772/55862. Available from: <https://www.intechopen.com/books/gangrene-management-new-advancements-and-current-trends/a-review-of-clinical-manifestations-of-gangrene-in-western-uganda>
- [7] Jacob J, Gionfriddo RJ. Gangrene. Symptoms, diagnosis and treatment. *BMJ Best Practice*. 2018. Available from: <https://bestpractice.bmj.com/topics/en-us/1015>
- [8] Al WA. Autoamputation of diabetic toe with dry gangrene: A myth or a fact? *Diabetes, Metabolism Syndrome and Obesity: Targets and Therapy*. 2018;11: 255-264. DOI: 10.2147/DMSO.S164199
- [9] Anaya DA, Bulger EM, Kwon YS, et al. Predicting death in necrotizing soft tissue infections: A clinical score. *Surgical Infections*. 2009;10:517-522
- [10] Hakkarainen TW, Kopari NM, Pham TN, Evans HL. Necrotising soft tissue infections: Review and current concepts in treatment, systems of care, and outcomes. *Current Problems in Surgery*. 2014;51:344-362
- [11] McGovern T, Wright IS. A vascular disease. *American Heart Journal*. 1941; 22:583-606
- [12] Cribier B, Djeridi N, Peltre B, Grosshans E. A histologic and immunohistochemical study of chilblains. *Journal of the American Academy of Dermatology*. 2001;45: 924-929
- [13] Boada A, Bielsa I, Fernández-Figueras MT, Ferrándiz C. Perniosis: Clinical and histopathological analysis. *The American Journal of Dermatopathology*. 2010;32:19-23
- [14] Nixon J, Cranny G, Bond S. Pathology, diagnosis, and classification of pressure ulcers: Comparing clinical and imaging techniques. *Wound Repair and Regeneration*. 2005;13:365-372
- [15] Livesley NJ, Chow AW. Infected pressure ulcers in elderly individuals. *Clinical Infectious Diseases*. 2002;35: 1390-1396

- [16] Heym B, Rimareix F, Lortat-Jacob A, et al. Bacteriological investigation of infected pressure ulcers in spinal cord-injured patients and impact on antibiotic therapy. *Spinal Cord*. 2004; **42**:230-234
- [17] Kitagawa A, Sanada H, Nakatani T, et al. Histological examination of pressure ulcer tissue in terminally ill cancer patients. *Japan Journal of Nursing Science*. 2004; **1**:35-46
- [18] Shibuya H, Terashi H, Kurata S, et al. Gas gangrene following sacral pressure sores. *The Journal of Dermatology*. 1994; **21**:518-523
- [19] Pirett CCNS, Braga IA, Ribas RM, et al. Pressure ulcer colonized by MRSA as a reservoir and risk for MRSA bacteremia in patients at a Brazilian university hospital. *Wounds*. 2012; **24**: 67-75
- [20] NPUAP. Pressure ulcers in America: Prevalence, incidence, and implications for the future. An executive summary of the National Pressure Ulcer Advisory Panel. *Advances in Skin & Wound Care*. 2001; **14**:208-215
- [21] Shimomura R, Tsutsumi Y. Histochemical identification of methicillin-resistant *Staphylococcus aureus*: Contribution to preventing nosocomial infection. *Seminars in Diagnostic Pathology*. 2007; **24**:217-226
- [22] Darke SG, King AM, Slack WK. Gas gangrene and related infection: Classification, clinical features and aetiology, management and mortality. A report of 88 cases. *The British Journal of Surgery*. 1977; **64**:104-112
- [23] McArthur HL, Dalal BI, Kollmannsberger C. Intravascular hemolysis as a complication of *Clostridium perfringens* sepsis. *Journal of Clinical Oncology*. 2006; **24**:2387-2388
- [24] Stevens DL, Aldape MJ, Bryant AE. Life-threatening clostridial infections. *Anaerobe*. 2012; **18**:254-259
- [25] Sushma M, Vidyadhar TVV, Mohanraj R, Babu M. A review on gas gangrene and its management. *PharmaTutor*. 2014; **2**:65-74
- [26] Valentine EG. Nontraumatic gas gangrene. *Annals of Emergency Medicine*. 1997; **30**:109-111
- [27] Sasaki T, Nanjo H, Takahashi M, Sugiyama T, Ono I, Masuda H. Non-traumatic gas gangrene in the abdomen: Report of six autopsy cases. *Journal of Gastroenterology*. 2000; **35**:382-390
- [28] Birgisson H, Stefánsson T, Andresdóttir A, Möller PH. Emphysematous pancreatitis. *The European Journal of Surgery*. 2001; **167**: 918-920
- [29] Ikegami T, Kido A, Shimokawa H, Ishida T. Primary gas gangrene of the pancreas: Report of a case. *Surgery Today*. 2004; **34**:80-81
- [30] Stockinger ZT, Corsetti RL. Pneumoperitoneum from gas gangrene of the pancreas: Three unusual findings in a single case. *Journal of Gastrointestinal Surgery*. 2004; **8**: 489-492
- [31] Nanjappa S, Shah S, Pabbathi S. *Clostridium septicum* gas gangrene in colon cancer: Importance of early diagnosis. *Case Reports in Infectious Diseases*. 2015; **2015**:694247
- [32] Griffin AS, Crawford MD, Gupta RT. Massive gas gangrene secondary to occult colon carcinoma. *Radiology Case Reports*. 2016; **11**:67-69
- [33] Miller C, Florman S, Kim-Schluger L, et al. Fulminant and fatal gas gangrene of the stomach in a healthy live liver donor. *Liver Transplantation*. 2004; **10**:1315-1319
- [34] Srivastava I, Aldape MJ, Bryant AE, Stevens DL. Spontaneous *C. septicum* gas gangrene: A literature review.

Journal of Clinical Microbiology. 2017; **48**:165-171

[35] Dempsey A. Serious infection associated with induced abortion in the United States. *Clinical Obstetrics and Gynecology*. 2012;**55**:888-892

[36] Bessman AN, Wagner W. Nonclostridial gas gangrene. Report of 48 cases and review of the literature. *JAMA*. 1975;**233**:958-963

[37] Hubens G, Carly B, De Boeck H, Vansteenland H, Wylock P. "Spontaneous" non clostridial gas gangrene: Case report and review of the literature. *Acta Chirurgica Belgica*. 1989; **89**:25-28

[38] Weisenfeld LS, Luzzi A, Picciotti J. Nonclostridial gas gangrene. *The Journal of Foot Surgery*. 1990;**29**:141-146

[39] Jain AKC, Viswanath S. Non-clostridial gas gangrene in diabetic lower limbs with peripheral vascular disease. *OA Case Reports*. 2013;**2**(9):83

[40] Takazawa K, Otsuka H, Nakawaga Y, Inokuchi S. Clinical features of non-clostridial gas gangrene and risk factors for in-hospital mortality. *The Tokai Journal of Experimental and Clinical Medicine*. 2015;**40**:124-129

[41] Shigemoto R, Anno T, Kawasaki F, et al. Non-clostridial gas gangrene in a patient with poorly controlled type 2 diabetes mellitus on hemodialysis. *Acta Diabetologica*. 2018;**55**:99-101

[42] Li CM, Chen PL, Ho YR. Non-clostridial gas gangrene caused by *Klebsiella pneumoniae*: A case report. *Scandinavian Journal of Infectious Diseases*. 2001;**33**:629-630

[43] Overcamp M, Pfohl M, Klier D, et al. Spontaneous gas-forming myonecrosis caused by group B streptococci and peptostreptococci. *The Clinical Investigator*. 1992;**70**:441-443

[44] Carr NJ. The pathology of acute appendicitis. *Annals of Diagnostic Pathology*. 2000;**4**:46-58

[45] Bhangu A, Søreide K, Di Saverio S, Assarsson JH, Drake FT. Acute appendicitis: Modern understanding of pathogenesis, diagnosis, and management. *Lancet*. 2015;**386**:1278-1287

[46] Nordin AB, Diefenbach K, Sales SP, Christensen J, Besner GE, Kenney BD. Gangrenous appendicitis: no longer complicated. *Journal of Pediatric Surgery*. 2019;**54**:718-722

[47] Marne C, Pallarés R, Martín R, Sitges-Serra A. Gangrenous cholecystitis and acute cholangitis associated with anaerobic bacteria in bile. *European Journal of Clinical Microbiology*. 1986;**5**:35-39

[48] Ganapathi AM, Speicher PJ, Englum BR, Perez A, Tyler DS, Zani S. Gangrenous cholecystitis: A contemporary review. *The Journal of Surgical Research*. 2015;**197**:18-24

[49] Önder A, Kapan M, Ülger BV, Oğuz A, Türkoğlu A, Uslukaya Ö. Gangrenous cholecystitis: Mortality and risk factors. *International Surgery*. 2015; **100**:254-260

[50] Liao CY, Tsai CC, Kuo WH, et al. Emphysematous cholecystitis presenting as gas-forming liver abscess and pneumoperitoneum in a dialysis patient: A case report and review of the literature. *BMC Nephrology*. 2016;**17**:23. DOI: 10.1186/s12882-016-0237-3

[51] Lee J. Diagnosis and management of acute cholangitis. *Nature Reviews. Gastroenterology & Hepatology*. 2009; **6**:533-541

[52] Zimmer V, Lammert F. Acute bacterial cholangitis. *Viszeralmedizin*. 2015;**31**:166-172

[53] Weber A, Huber W. Spectrum of pathogens in acute cholangitis in



patients with and without biliary endoprosthesis. *The Journal of Infection*. 2013;**67**:111-121

[54] Nomura T, Shirai Y, Hatakeyama K. *Enterococcal bactibilia* in patients with malignant biliary obstruction. *Digestive Diseases and Sciences*. 2000;**45**: 2183-2186

[55] Phillips LG, Rao KVS. Gangrene of the lung. *The Journal of Thoracic and Cardiovascular Surgery*. 1989;**97**: 114-118

[56] Chen CH, Huang WC, Chen TY, Hung TT, Liu HC, Chen CH. Massive necrotizing pneumonia with pulmonary gangrene. *The Annals of Thoracic Surgery*. 2009;**87**:310-311

[57] Chatha N, Fortin D, Bosma KJ. Management of necrotizing pneumonia and pulmonary gangrene: A case series and review of the literature. *Canadian Respiratory Journal*. 2014;**21**:239-245

[58] Nayeemuddin M, Wiseman O, Turner A. Emphysematous pyelonephritis. *Nature Reviews. Urology*. 2005;**2**:108-112

[59] Mahesan T, Reddy UD, Chetwood A, et al. Emphysematous pyelonephritis: A review of a rare condition. *Current Bladder Dysfunction Reports*. 2015;**10**:207-211

[60] Irfaan AM, Shaikh NA, Jamshaid A, Qureshi AH. Emphysematous pyelonephritis: A single center review. *Pakistan Journal of Medical Sciences*. 2020;**36**:S83-S86

[61] Kawaguchi Y, Mori H, Izumi Y, Ito M. Renal papillary necrosis with diabetes and urinary tract infection. *Internal Medicine*. 2018;**57**(22):3343. DOI: 10.2169/internalmedicine.0858-18

[62] Kernt M, Kampik A. Endophthalmitis: Pathogenesis, clinical presentation, management, and

perspectives. *Clinical Ophthalmology*. 2010;**4**:121-135

[63] Durand ML. Endophthalmitis. *Clinical Microbiology and Infection*. 2013;**19**:227-234

[64] Aulakh S, Nair AG, Gandhi R, et al. Orbital cellulitis with endogenous panophthalmitis caused by methicillin-sensitive *Staphylococcus aureus* in pregnancy. *Japanese Journal of Infectious Diseases*. 2017;**70**:314-316

[65] Ferrer C, Alio J, Rodriguez A, Andreu M, Colom F. Endophthalmitis caused by *Fusarium* proliferation. *Journal of Clinical Microbiology*. 2005; **43**:5372-5375

[66] Al-Jundi W, AliShebl A. Emphysematous gastritis: Case report and literature review. *International Journal of Surgery*. 2008;**6**:e63-e66

[67] López-Maroto DG-L, Cuéllar ER, García CN, Pozuelo AM, Herrero EF. Emphysematous esophagitis with gastric perforation. *Revista Española de Enfermedades Digestivas*. 2019;**111**: 884-886

[68] Chou YH, Hsu HL, Lee JC, Lin BR, Liu KL. Emphysematous colitis of ascending colon with portal venous air caused by diffuse large B-cell lymphoma. *Journal of Clinical Oncology*. 2010;**28**:e496-e497

[69] Amano M, Shimizu T. Emphysematous cystitis: A review of the literature. *Internal Medicine*. 2014; **53**:79-82

[70] Tariq T, Farishta M, Rizvi A, et al. A case of concomitant emphysematous cystitis and *Clostridium difficile* colitis with pneumoperitoneum. *Cureus*. 2018; **10**:e2897

[71] Liao W-C, Chou J-W. Emphysematous pyelonephritis, ureteritis and cystitis in a diabetic

patient. QJM: An International Journal of Medicine. 2010;**103**:893-894

[72] Chen S, Rahim S, Datta SN. A rare case of emphysematous urethritis. Urology & Nephrology Open Access Journal. 2016;**2**(3):1-4

[73] Vijayan P. Gangrene of the penis in a diabetic male with multiple amputations and follow up. Indian Journal of Urology. 2009;**25**:123-125

[74] Mathur A, Manish A, Maletha M, Luthra NB. Emphysematous epididymo-orchitis: A rare entity. Indian Journal of Urology. 2011;**27**:399-400

[75] Lau HW, Yu CH, Yu SM, Lee LF. Emphysematous epididymo-orchitis: An uncommon but life-threatening cause of scrotal pain. Hong Kong Medical Journal. 2018;**24**:426.e1-426.e2

[76] Chua YJ, Meharry S, Harding S, Stewart CJ. Endometrial pneumatosis (emphysematous endometritis). International Journal of Gynecological Pathology. 2014;**33**:511-514

[77] Lima-Silva J, Vieira-Baptista P, Cavaco-Gomes J, Maia T, Beires J. Emphysematous vaginitis. Journal of Lower Genital Tract Disease. 2015;**19**: e43-e44

[78] Agrawal S, Jayant K, Agarwal R. Breast gangrene: A rare source of severe sepsis. BMJ Case Reports. 2014;**2014**: bcr2013203467

[79] Luey C, Tooley D, Briggs S. Emphysematous osteomyelitis: A case report and review of the literature. International Journal of Infectious Diseases. 2012;**16**:e216-e220

[80] Smith-Singares E, Boachie JA, Iglesias IM, Jaffe L, Goldkind A, Jeng EI. *Fusobacterium* emphysematous pyomyositis with necrotizing fasciitis of the leg presenting as compartment syndrome: A case report. Journal of

Medical Case Reports. 2017;**11**:332. DOI: 10.1186/s13256-017-1493-y

[81] Urgiles S, Matos-Casano H, Win KZ, et al. Emphysematous aortitis due to *Clostridium septicum* in an 89-year-old female with ileus. Case Reports in Infectious Diseases. 2019;**2019**:1094837

[82] Ye R, Yang J, Hong H, et al. Descending necrotizing mediastinitis caused by *Streptococcus constellatus* in an immunocompetent patient: Case report and review of the literature. BMC Pulmonary Medicine 2020;**20**:43. DOI: 10.1186/s12890-020-1068-3

[83] Kim CJ, Yi JE, Kim Y, Choi HJ. Emphysematous endocarditis caused by AmpC beta-lactamase-producing *Escherichia coli*: A case report. Medicine (Baltimore). 2018;**97**(6):e9620

[84] American Academy of Periodontology. Consensus report: Necrotizing periodontal diseases. Annals of Periodontology. 1999;**4**(1):78

[85] Corbet EF. Diagnosis of acute periodontal lesions. Periodontology. 2000/2004;**34**:204-216

[86] Paster BJ, Falkler WA Jr, Enwonwu CO, et al. Prevalent bacterial species and novel phylotypes in advanced Noma lesions. Journal of Clinical Microbiology. 2002;**40**: 2187-2191

[87] Enwonwu CO. Noma: The ulcer of extreme poverty. The New England Journal of Medicine. 2006;**354**:221-224

[88] Parikh TB, Nanavati RN, Udani RH. Noma neonatorum. Indian Journal of Pediatrics. 2006;**73**:439-440

[89] Cunningham MW. Pathogenesis of group A streptococcal infections. Clinical Microbiology Reviews. 2000;**13**: 470-511

[90] Fox KL, Born MW, Cohen MA. Fulminant infection and toxic shock



syndrome caused by *Streptococcus pyogenes*. The Journal of Emergency Medicine. 2002;22:357-366

[91] Overkamp D, Pfohl M, Klier R, Domres B, Schmülling R-M. Spontaneous gas-forming bacterial myonecrosis caused by group B streptococci and peptostreptococci. The Clinical Investigator. 1992;70:441-443

[92] Humar D, Datta V, Bast DJ, et al. Streptolysin S and necrotising infections produced by group G streptococcus. Lancet. 2002;359:124-129

[93] Bryant AE, Bayer CR, Huntington JD, et al. Group a streptococcal myonecrosis: Increased vimentin expression after skeletal-muscle injury mediates the binding of *Streptococcus pyogenes*. The Journal of Infectious Diseases. 2006;193:1685-1689

[94] Spaulding AR, Salgado-Pabón W, Kohler PL, Horswill AR, Leung DY, Schlievert PM. Staphylococcal and streptococcal superantigen exotoxins. Clinical Microbiology Reviews. 2013;26:422-447

[95] Lin L, Xu L, Lv W, et al. An NLRP3 inflammasome-triggered cytokine storm contributes to streptococcal toxic shock-like syndrome (STSLs). PLoS Pathogens. 2019;15(6):e1007795

[96] Chen Y, Satoh T, Tokunaga O. *Vibrio vulnificus* infection in patients with liver disease: Report of five autopsy cases. Virchows Archiv. 2002;441:88-92

[97] Chiang SR, Chuang YC. *Vibrio vulnificus* infection: Clinical manifestations, pathogenesis, and antimicrobial therapy. Journal of Microbiology, Immunology, and Infection. 2003;36:81-88

[98] Inoue Y, Ono T, Matsui T, et al. Epidemiological survey of *Vibrio vulnificus* infection in Japan between

1999 and 2003. The Journal of Dermatology. 2008;35:129-139

[99] Jones MK, Oliver JD. *Vibrio vulnificus*: Disease and pathogenesis. Infection and Immunity. 2009;77:1723-1733

[100] Vukmir RB. *Aeromonas hydrophila*: Myofascial necrosis and sepsis. Intensive Care Medicine. 1992;18:172-174

[101] Grant A, Hoddinott C. *Aeromonas hydrophila* infection of a scalp laceration (with synergistic gas gangrene). Archives of Emergency Medicine. 1993;10:232-234

[102] Lin SH, Shieh SD, Lin YF, et al. Fatal *Aeromonas hydrophila* bacteremia in a hemodialysis patient treated with deferoxamine. American Journal of Kidney Diseases. 1996;27:733-735

[103] Furuu A, Yoshizuka N, Abe K, et al. *Aeromonas hydrophila* necrotizing fasciitis and gas gangrene in a diabetic patient on haemodialysis. Nephrology, Dialysis, Transplantation. 1997;12:1730-1734

[104] van der Burg BL B, Bronkhorst MW, Pahlplatz PV. *Aeromonas hydrophila* necrotizing fasciitis. A case report. The Journal of Bone and Joint Surgery. American Volume. 2006;8:1357-1360

[105] Vally H, Whittle A, Cameron S, et al. Outbreak of *Aeromonas hydrophila* wound infections associated with mud football. Clinical Infectious Diseases. 2004;38:1084-1089

[106] Lamerton AJ. Fournier's gangrene: Non-clostridial gas gangrene of the perineum and diabetes mellitus. Journal of the Royal Society of Medicine. 1986;79:212-215

[107] Eke N. Fournier's gangrene: A review of 1726 cases. The British Journal of Surgery. 2000;87:718-728

- [108] Thwaini A, Khan A, Malik A, et al. Fournier's gangrene and its emergency management. *Postgraduate Medical Journal*. 2006;**82**:516-519
- [109] Erol B, Tuncel A, Hanci V, et al. Fournier's gangrene: Overview of prognostic factors and definition of new prognostic parameter. *Urology*. 2010;**75**: 1193-1198
- [110] Heiner JD, Eng KD, Bialowas TA, et al. Fournier's gangrene due to masturbation in an otherwise healthy male. *Case Reports in Emergency Medicine*. 2012;**2012** Article ID 154025
- [111] Bruketa T, Majerovic M, Augustin G. Rectal cancer and Fournier's gangrene. Current knowledge and therapeutic options. *World Journal of Gastroenterology*. 2015;**21**:9002-9020
- [112] Yoshino Y, Funahashi K, Okada R, et al. Severe Fournier's gangrene in a patient with rectal cancer: Case report and literature review. *World Journal of Surgical Oncology*. 2016;**14**:234. DOI: 10.1186/s12957-016-0989-z
- [113] Kotrappa KS, Bansal RS, Amin NM. Necrotizing fasciitis. *American Family Physician*. 1996;**53**:1691-1697
- [114] Shimizu T, Tokuda Y. Necrotizing fasciitis. *Internal Medicine*. 2010;**49**: 1051-1057
- [115] Machado NO. Necrotizing fasciitis: The importance of early diagnosis, prompt surgical debridement and adjuvant therapy. *North American Journal of Medical Sciences*. 2011;**3**: 107-118
- [116] Schwartz RA. *Dermatologic Manifestations of Necrotizing Fasciitis*. New York, NY, USA: Medscape; 2011. Available from: <http://emedicine.medscape.com/article/1054438-overview>
- [117] Lancerotto L, Tocco I, Salmaso R, et al. Necrotizing fasciitis. Classification, diagnosis, and management. *Journal of Trauma and Acute Care Surgery*. 2012; **72**:560-566
- [118] Mahoning County Public Health. Necrotizing fasciitis: A rare disease, especially for the healthy. Youngstown, OH, USA; 2012. Available from: <https://www.mahoninghealth.org/health/necrotizing-fasciitis-a-rare-disease-especially-for-the-healthy/>
- [119] Akamine M, Miyagi K, Uchihara T, et al. Necrotizing fasciitis caused by *Pseudomonas aeruginosa*. *Internal Medicine*. 2008;**47**:553-556
- [120] Reisman JS, Weinberg A, Ponte C, et al. Monomicrobial *Pseudomonas* necrotizing fasciitis: A case of infection by two strains and a review of 37 cases in the literature. *Scandinavian Journal of Infectious Diseases*. 2012;**44**:216-221
- [121] Stens O, Wardi G, Kinney M, Shin S, Papamatheakis D. *Stenotrophomonas maltophilia* necrotizing soft tissue infection in an immunocompromised patient. *Case Reports in Critical Care*. 2018;**2018**: 1475730
- [122] Arnold CJ, Garrigues G, St Geme JW 3rd, Sexton DJ. Necrotizing fasciitis caused by *Haemophilus influenzae* serotype f. *Journal of Clinical Microbiology*. 2014;**52**:3471-3474
- [123] Stevens DL. Streptococcal toxic-shock syndrome: Spectrum of disease, pathogenesis, and new concepts in treatment. *Emerging Infectious Diseases*. 1995;**1**:69-78
- [124] Tajiri T, Tate G, Miura K, et al. Sudden death caused by fulminant bacterial infection: Background and pathogenesis of Japanese adult cases. *Internal Medicine*. 2008;**47**:1499-1504
- [125] Kato S, Yanazaki M, Hayashi K, Satoh F, Isobe I, Tsutsumi Y. Fulminant group A streptococcal infection without

- gangrene in the extremities: Analysis of five autopsy cases. *Pathology International*. 2018;**68**:419-424
- [126] Ooe K, Udagawa H. A new type of fulminant group A streptococcal infection in obstetric patients: Report of two cases. *Human Pathology*. 1997;**28**: 509-512
- [127] Onouchi T, Mizutani Y, Shiogama K, et al. Application of an enzyme-labeled antigen method for visualizing plasma cells producing antibodies against Strep A, a carbohydrate antigen, of *Streptococcus pyogenes* in recurrent tonsillitis. *Microbiology and Immunology*. 2015;**59**: 13-27
- [128] Tormos LM, Schandl CA. The significance of adrenal hemorrhage: Undiagnosed Waterhouse-Friderichsen syndrome, a case series. *Journal of Forensic Sciences*. 2013;**58**:1071-1074
- [129] Fujiwara F, Hibi S, Imashuku S. Hypercytokinemia in hemophagocytic syndrome. *The American Journal of Pediatric Hematology/Oncology*. 1993; **15**:92-98
- [130] Fukusato T. Clinicopathological studies of renal cortical necrosis, with special reference to its pathogenesis. *The Japanese Journal of Nephrology*. 1984;**26**:1461-1478
- [131] Naito R, Miyazaki T, Kajino K, et al. Fulminant pneumococcal infection. *BMJ Case Reports*. 2014;**2014**:bcr201420 5907
- [132] Yu VL, Chiou CC, Feldman C, et al. An international prospective study of pneumococcal bacteremia: Correlation with in vitro resistance, antibiotics administration, and clinical outcome. *Clinical Infectious Diseases*. 2003;**37**: 230-237
- [133] Waghorn DJ, Mayon-White RT. A study of 42 episodes of overwhelming post-splenectomy infection: Is current guideline for asplenic individuals being followed? *The Journal of Infection*. 1997; **35**:289-294
- [134] Hale AJ, LaSalvia M, Kirby JE, Kimball A, Baden R. Fatal purpura fulminans and Waterhouse-Friderichsen syndrome from fulminant *Streptococcus pneumoniae* sepsis in an asplenic young adult. *IDCases*. 2016;**6**:1-4
- [135] Theilacker C, Ludewig K, Serr A, et al. Overwhelming postsplenectomy infection: A prospective multicenter cohort study. *Clinical Infectious Diseases*. 2016;**62**:871-878
- [136] Murph RC, Matulis WS, Hernandez JE. Rapidly fatal pneumococcal sepsis in a healthy adult. *Clinical Infectious Diseases*. 1996;**22**: 375-376
- [137] Bukhari E, Al-Otaibi FE. Severe community-acquired infection caused by methicillin-resistant *Staphylococcus aureus* in Saudi Arabian children. *Saudi Medical Journal*. 2009;**30**:1595-1600
- [138] Bukharie HA. Increasing threat of community-acquired methicillin-resistant *Staphylococcus aureus*. *The American Journal of the Medical Sciences*. 2010;**340**:378-381
- [139] Holden R, Yankaskas J. Fulminant community-acquired MRSA infection in a previously healthy young adult. *American Journal of Respiratory and Critical Care Medicine*. 2020;**201**:A1805
- [140] Vandenesch F, Naimi T, Enright MC, et al. Community-acquired methicillin-resistant *Staphylococcus aureus* carrying Panton-Valentine leukocidin genes: Worldwide emergence. *Emerging Infectious Diseases*. 2003;**9**:978-984
- [141] McCormick JK, Tripp TJ, Llera AS, et al. Functional analysis of the TCR binding domain of toxic shock syndrome toxin-1 predicts further diversity in MHC class II/superantigen/



TCR ternary complexes. *Journal of Immunology*. 2003;**171**:1385-1392

[142] Linden P. Can enterococcal infections initiate sepsis syndrome? *Current Infectious Disease Reports*. 2003;**5**:372-378

[143] Gilmore MS, Clewell DB, Ike Y, Shankar N. *Enterococci: From Commensals to Leading Causes of Drug Resistant Infection*. Boston: Massachusetts Eye and Ear Infirmary; 2014. p. NBK190424

[144] Pericás JM, Zboromyrska Y, Cervera C, et al. Enterococcal endocarditis revisited. *Future Microbiology*. 2015;**10**:1215-1240

[145] Amorosa L, Modugno GC, Pirodda A. Malignant external otitis: Review and personal experience. *Acta Oto-Laryngologica. Supplementum*. 1996;**521**:3-16

[146] Franco-Vidal V, Blanchet H, Bebear C, et al. Necrotizing external otitis: A report of 46 cases. *Otology & Neurotology*. 2007;**28**:771-773

[147] Soudry E, Joshua BZ, Sulkes J, et al. Characteristics and prognosis of malignant external otitis with facial paralysis. *Archives of Otolaryngology – Head & Neck Surgery*. 2007;**133**:1002-1004

[148] Ling SS, Sader C. Fungal malignant otitis externa treated with hyperbaric oxygen. *International Journal of Infectious Diseases*. 2008;**12**:550-552

[149] Illing E, Olaleye O. Malignant otitis externa: A review of aetiology, presentation, investigations and current management strategies. *WebmedCentral Otorhinolaryngology*. 2011;**2**(3):WMC001725

[150] Rinaldi MG. Zygomycosis. *Infectious Disease Clinics of North America*. 1989;**3**:19-41

[151] Roden MM, Zaoutis TE, Buchanan WL, et al. Epidemiology and outcome of mucormycosis: A review of 929 reported cases. *Clinical Infectious Diseases*. 2005;**41**:634-653

[152] Song KR, Wong MS, Yeung C. Primary cutaneous zygomycosis in an immunodeficient infant: A case report and review of the literature. *Annals of Plastic Surgery*. 2008;**60**:433-436

[153] Skiada A, Petrikos G. Cutaneous zygomycosis. *Clinical Microbiology and Infection*. 2009;**15**(Suppl 5):41-45

[154] Margo CE, Linden C, Strickland-Marmol LB, et al. Rhinocerebral mucormycosis with perineural spread. *Ophthalmic Plastic and Reconstructive Surgery*. 2007;**23**:326-327

[155] Teixeira CA, Medeiros PB, Leushner P, Almeida F. Rhinocerebral mucormycosis: Literature review apropos of a rare entity. *BML Case Reports*. 2013;**2013**:bcr2012008552

[156] Cassir N, Benamar S, La Scola B. *Clostridium butyricum*: From beneficial to a new emerging pathogen. *Clinical Microbiology and Infection*. 2016;**22**:37-45

[157] Tsutsumi Y. *Clostridium butyricum*-Induced Gas Gangrene Accompanying Pneumatosis Cystoides Intestinalis. *Pathology of Infectious Diseases*. Nagoya, Japan: Pathos Tsutsumi; 2003. Available from: <https://pathos223.com/en/case/case011.htm>

[158] Sturm R, Stanek JL, Stauffer LR, et al. Neonatal necrotizing enterocolitis associated with penicillin-resistant, toxigenic *Clostridium butyricum*. *Pediatrics*. 1980;**66**:928-931

[159] Brook I. Clostridial infection in children. *Journal of Medical Microbiology*. 1995;**42**:78-82

[160] Rich BS, Dolgin SE. Necrotizing enterocolitis. *Pediatrics in Review*. 2017;**38**:552-559

- [161] Seki H, Shiohara M, Matsumura T, et al. Prevention of antibiotic-associated diarrhea in children by *Clostridium butyricum* MIYAIRI. *Pediatrics International*. 2003;**45**:86-90
- [162] Dahiya DK, Malik R, Dangi AR, et al. Chapter 44. New-generation probiotics. In: Faintuch J, Faintuch S, editors. *Microbiome and Metabolome in Diagnosis, Therapy, and Other Strategic Applications*. Cambridge, MA, USA: Academic Press; 2019. pp. 417-424. DOI: 10.1016/B978-0-12-815249-2.00044-0
- [163] Patra S, Vij M, Chirla DK, Kumar N, Samal SC. Unsuspected invasive neonatal gastrointestinal mucormycosis: A clinicopathological study of six cases from a tertiary care hospital. *Journal of Indian Association of Pediatric Surgeons*. 2012;**17**:153-156
- [164] Vallabhaneni S, Mody RK. Gastrointestinal mucormycosis in neonates: A review. *Current Fungal Infection Reports*. 2015;**9**:269-274
- [165] Dixon TC, Meselson M, Guillemin J, et al. Anthrax. *The New England Journal of Medicine*. 1999;**341**: 815-826
- [166] Tutrone WD, Scheinfeld NS, Weinberg JM. Cutaneous anthrax: A concise review. *Cutis*. 2002;**69**:27-33
- [167] Tena D, Martinez-Torres JA, Perez-Pomata MT, et al. Cutaneous infection due to *Bacillus pumilus*: Report of 3 cases. *Clinical Infectious Diseases*. 2007;**44**:e40-e42
- [168] Doganay M, Metan G, Alp E. A review of cutaneous anthrax and its outcome. *Journal of Infection and Public Health*. 2010;**3**:98-105
- [169] Duncan KO, Smoth TL. Primary cutaneous infection with *Bacillus megaterium* mimicking cutaneous anthrax. *Journal of the American Academy of Dermatology*. 2011;**65**:e60-e61
- [170] Ishida R, Ueda K, Kitano T, et al. Fatal community-acquired *Bacillus cereus* pneumonia in an immunocompetent adult man: A case report. *BMC Infectious Diseases*. 2019;**19**:197
- [171] Darbar A, Harris IA, Gosbell IB. Necrotizing infection due to *Bacillus cereus* mimicking gas gangrene following penetrating trauma. *Journal of Orthopaedic Trauma*. 2005;**19**:353-355
- [172] Bottone EJ. *Bacillus cereus*, a volatile human pathogen. *Clinical Microbiology Reviews*. 2010;**23**:382-398
- [173] Overcast WW, Atmaram K. The role of *Bacillus cereus* in sweet curdling of fluid milk. *Journal of Milk and Food Technology*. 1974;**37**:233-236