

Usher syndrome: clinical features, molecular genetics and advancing therapeutics

Maria Toms , Waheeda Pagarkar and Mariya Moosajee 

Ther Adv Ophthalmol

2020, Vol. 12: 1–19

DOI: 10.1177/
2515841420952194

© The Author(s), 2020.

Abstract: Usher syndrome has three subtypes, each being clinically and genetically heterogeneous characterised by sensorineural hearing loss and retinitis pigmentosa (RP), with or without vestibular dysfunction. It is the most common cause of deaf–blindness worldwide with a prevalence of between 4 and 17 in 100 000. To date, 10 causative genes have been identified for Usher syndrome, with *MYO7A* accounting for >50% of type 1 and *USH2A* contributing to approximately 80% of type 2 Usher syndrome. Variants in these genes can also cause non-syndromic RP and deafness. Genotype–phenotype correlations have been described for several of the Usher genes. Hearing loss is managed with hearing aids and cochlear implants, which has made a significant improvement in quality of life for patients. While there is currently no available approved treatment for the RP, various therapeutic strategies are in development or in clinical trials for Usher syndrome, including gene replacement, gene editing, antisense oligonucleotides and small molecule drugs.

Keywords: gene therapy, inherited retinal disease, inner ear, photoreceptor, retina, retinitis pigmentosa, sensorineural hearing loss, sensory hair cell, Usher syndrome

Received: 18 May 2020; revised manuscript accepted: 27 July 2020.

Introduction

Usher syndrome encompasses a group of inherited disorders characterised by dual sensory impairment of the auditory and visual systems, with a variable presentation of vestibular dysfunction in a proportion of cases. It is the most common cause of combined sight and hearing loss, accounting for more than half of deaf–blindness cases.^{1,2} It has an estimated prevalence of between 4 and 17 in 100 000 people worldwide.^{2,3} Furthermore, it has been estimated to represent 5% of all congenital deafness and 18% of all retinitis pigmentosa (RP) cases.^{2,4} Usher syndrome is both clinically and genetically heterogeneous and is divided into three distinct clinical subtypes, associated with a number of genetic loci. The Usher genes encode a variety of proteins that are expressed in the inner ear and retina where they perform essential functions in sensory hair cell development and function, and photoreceptor maintenance. While many promising treatments

are under investigation, there is no approved treatment for this disease to date.

Clinical characteristics

Usher syndrome involves a combination of bilateral sensorineural hearing loss with progressive retinal degeneration in the form of RP. It is categorised into three major clinical subtypes according to severity and onset of hearing loss and whether vestibular dysfunction is present⁵ (Table 1). However, there is clinical variability within each Usher subtype, with overlapping and atypical presentations described.

Usher syndrome type 1 (Usher 1) is the most severe subtype in which patients exhibit severe to profound bilateral congenital sensorineural hearing loss (Figure 1), most frequently non-progressive, with vestibular areflexia. It accounts for approximately 25–44% of all Usher syndrome cases.¹¹

Correspondence to:

Mariya Moosajee
Development, Ageing and
Disease, UCL Institute
of Ophthalmology, 11–43
Bath Street, London EC1V
9EL, UK.

The Francis Crick Institute,
London, UK

Great Ormond Street
Hospital for Children NHS
Foundation Trust, London,
UK

Moorfields Eye Hospital
NHS Foundation Trust,
London, UK
m.moosajee@ucl.ac.uk

Maria Toms
UCL Institute of
Ophthalmology, London,
UK; The Francis Crick
Institute, London, UK

Waheeda Pagarkar
Great Ormond Street
Hospital for Children
NHS Foundation Trust,
London, UK; University
College London Hospitals
NHS Foundation Trust,
London, UK

Table 1. Clinical features and genes associated with Usher syndrome types 1, 2 and 3.

Usher subtype	Causative genes	Sensorineural hearing loss	Retinitis pigmentosa	Vestibular function
Usher 1	<i>MYO7A, USH1C, CDH23, PCDH15, USH1G, CIB2</i>	Congenital, severe to profound	Prepubertal onset; average age of diagnosis in second decade; legal blindness in fourth decade	Vestibular hypofunction; motor development may be delayed; infants typically do not walk before 18 months of age
Usher 2	<i>USH2A, ADGRV1, WHRN</i>	Congenital, moderate to severe; high frequencies most affected	Onset in second decade; average age of diagnosis in third decade; legal blindness in sixth decade.	Normal vestibular function
Usher 3	<i>CLRN1</i>	Post-lingual onset, progressive, variable	Variable onset, typically in second decade	Variable; vestibular abnormalities in ~50% of patients, usually mild

Source: Data included from previous studies.⁶⁻¹⁰

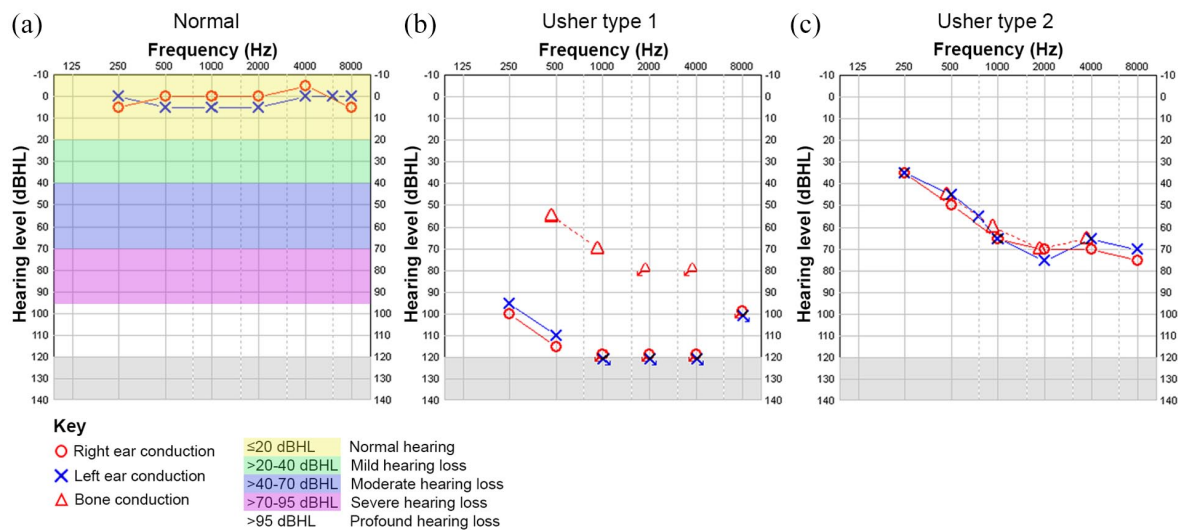


Figure 1. Audiograms of Usher syndrome type 1 and 2 patients. (a) Normal audiogram from a non-Usher individual. (b) Audiogram of a typical patient with Usher syndrome type 1 due to *MYO7A* mutation (homozygous c.4254del p.Asp1419fs) showing bilateral severe to profound sensorineural hearing loss (hearing loss in audiogram >95 dBHL). (c) Typical high frequency mild to severe sloping audiogram of an Usher syndrome type 2 patient (hearing loss in audiogram is 35–75 dBHL).

Infants are detected through the newborn hearing screen (Figure 2), and where not undertaken/available, the diagnosis is often suspected in infancy. Vestibular areflexia is reflected in delayed motor development and children usually do not walk independently before the age of 18 months. When older, they compensate for their vestibular areflexia using vision, until the onset of RP,

although they often have higher accidental falls and difficulty in performing activities, which require balance, for example, riding a bicycle. Due to the profound nature of deafness, children with Usher 1 derive limited or no benefit from hearing aids and most patients with Usher 1 would be sign language users if the hearing loss is not treated effectively. Timely use of cochlear

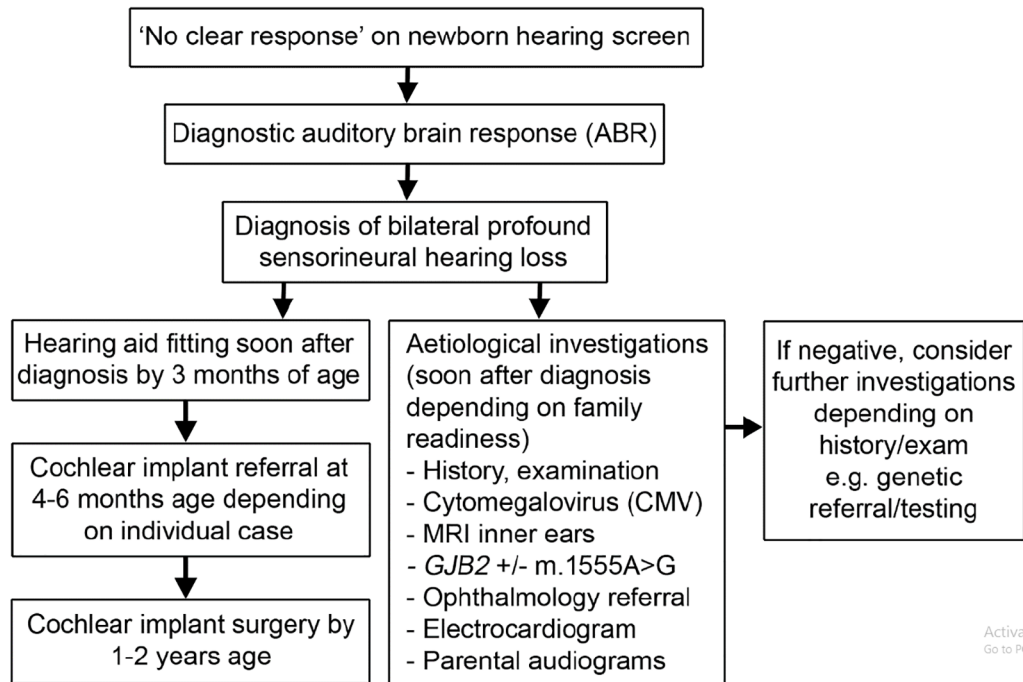


Figure 2. Flowchart for investigation and treatment of bilateral profound sensorineural hearing loss. Source: Adapted from the British Association of Audiological Physicians (BAAP) guidelines.¹²

implants can achieve oral communication and open set speech perception. An earlier age of implantation is correlated with improved outcome.^{13,14} The standard approach is to offer bilateral cochlear implants to Usher 1 patients within the first 2 years of life.

Usher syndrome type 2 (Usher 2) is the most common form of the disorder, representing over half of all cases.¹¹ The sensorineural hearing loss is typically described as sloping, mild to moderate in the low frequencies and severe to profound in the high frequencies (Figure 1).¹⁵ Hearing loss is congenital and infants are detected through the newborn hearing screen, however, if unavailable detection can be overlooked till the end of the first decade of life due to the high frequency configuration and degree of hearing loss.⁶ Although thought to be non-progressive, there is evidence to indicate progression of hearing loss over the years, particularly in Usher type 2A.^{16–18} Children derive benefit from conventional hearing aids and often have close to normal speech acquisition. However, with progression of hearing loss, cochlear implants are indicated. Up to 10% of Usher type 2A patients had cochlear implants (mean age: 59 years),¹⁹ which increased speech intelligibility, quality of life and communication, with similar outcomes to a control

group of adults with post-lingual hearing loss. Vestibular function is intact in Usher 2 patients and reflected in normal motor milestones. However, one study found vestibular abnormalities in four out of five genetically confirmed Usher 2 patients.²⁰ Episodes of vertigo were reported by patients although clinical balance was normal, and the authors suggested that subclinical changes in the vestibular system should be looked for.

Usher syndrome type 3 (Usher 3) is rare in most populations, accounting for approximately 2–4% of all cases, although it is particularly prevalent in Finland²¹ and among Ashkenazi Jewish people.²² The audiovestibular features are the most variable of the Usher subtypes. Hearing loss is of post-lingual onset and usually detected in the first decade of life, although onset can be delayed until adult life. It is typically of a progressive nature, with audiograms showing high frequencies more affected or a U-shaped configuration. Vestibular abnormalities are present in approximately half of patients, although most report a normal age of independent walking.⁷ Hearing aids are of benefit early in the course of disease, but cochlear implants may be required with progressive hearing loss. Improved hearing and subjective benefit were demonstrated in Usher 3 patients with implants

(mean age at implantation: 41 years) comparable with that observed in implanted patients without visual impairment.²³

In all types of Usher syndrome, audiological findings are detected/present prior to ophthalmological signs and symptoms. Children and adults with Usher syndrome do not have dysmorphism, and the disorder is commonly mistaken for a non-syndromic isolated sensorineural hearing loss. They will often have the initial aetiologic investigations for hearing loss, which include cytomegalovirus (CMV) testing and magnetic resonance imaging (MRI) scan, genetic testing for *GJB2* and mitochondrial m.1555A > G mutations and electrocardiography (ECG) in some patients, which is expected to be normal.^{12,24} Initial investigations for bilateral sensorineural hearing loss also include ophthalmological assessment, which in the early years can be normal depending on the Usher subtype. Diagnosis of Usher 1 should be suspected in any infant with bilateral profound sensorineural hearing loss and delayed motor milestones, even if the initial ophthalmology screen is normal. Usher 2 should be considered in patients with typical sloping configuration of hearing loss. Diagnosis of Usher 2 or 3 is made after visual symptoms or signs are detected through routine examination or electroretinography (ERG). A meta-analysis of next-generation sequencing (NGS) data in the United States indicates that 7.5% of patients with seemingly 'isolated deafness' have mutations in the Usher genes and may be at high risk of developing RP.²⁵ With the availability of NGS, Usher genes are included in the 'deafness' and 'retinal' gene panels to help with early genetic diagnosis.

Audiological rehabilitation in all forms of Usher syndrome is started soon after diagnosis by fitting of bilateral hearing aids. Hearing aid fitting in patients with Usher syndrome may need special considerations, especially with visual impairment.¹⁹ The onset of RP has a significant impact on communication, as patients will have difficulty in lip reading and understanding gesture and sign, and on balance as visual compensation is compromised. Patients with Usher syndrome and bilateral vestibular areflexia should be advised about the risk of disorientation and potential drowning with underwater swimming, due to poor availability of visual and proprioceptive inputs.^{26,27}

RP develops in all three Usher subtypes but with variable onset; Usher 1 is most commonly

pre-adolescent, with Usher 2 within the first two decades of life, and Usher 3 patients typically being post-pubertal.^{8,28} Visual prognosis also differs between the clinical types; Usher 1 patients generally show a more severe visual decline with age, reaching legal blindness on average 15 years earlier than patients with Usher 2.^{6,9} Typically, the first presenting symptom is night blindness (nyctalopia) with progressive visual field loss beginning in the mid-periphery caused by rod photoreceptor degeneration. It eventually progresses to involve cone photoreceptors, resulting in central and colour vision loss. Patients are often registered severely sight impaired but there can be significant intra- and interfamilial phenotypic variability. Fundus features include variable amounts of bone spicule pigmentation, retinal pigment epithelium (RPE) atrophy or depigmentation, retinal arteriolar attenuation and optic disc pallor (Figures 3(a) and 4(a)). A significant proportion of Usher patients may also develop cataracts and/or cystoid macular oedema.²⁹

Retinal imaging using fundus autofluorescence shows a ring of hyperautofluorescence in the macula (Figures 3(b) and 4(b)), and spectral domain optical coherence tomography (SD-OCT) reveals loss of the outer retinal structure (Figures 3(c) and 4(c)), sparing the fovea until late in disease ± cystoid macular oedema. A prospective study using optical coherence tomography angiography (OCTA) of patients with *MYO7A* and *USH2A* mutations showed reduced vessel density in the retinal circulation with changes in the superficial capillary plexus (SCP) and deep capillary plexus (DCP) in all patients compared with healthy age-matched controls.³⁰ However, peripheral defects were detected in the choriocapillaris (CC) earlier and more severely in *MYO7A* patients compared with the *USH2A* group. It was suggested that this is because the *MYO7A* protein (myosin VIIa) is mainly expressed in the RPE, thus affecting the CC directly. In the same study, patients were tested for macular sensitivity (MS) using micropertometry with the Macular Integrity Assessment, and this detected decreased mesopic mean MS in all patients, especially in the periphery. Patients with *MYO7A* mutations had a slightly lower mean MS than patients with *USH2A* mutations; however, the differences were found not to be statistically significant ($p = 0.66$). Static and dynamic perimetry detects mid-peripheral visual field loss with progression to residual small central islands, with a small temporal peripheral field preservation in the most advanced stages of the disease. ERG

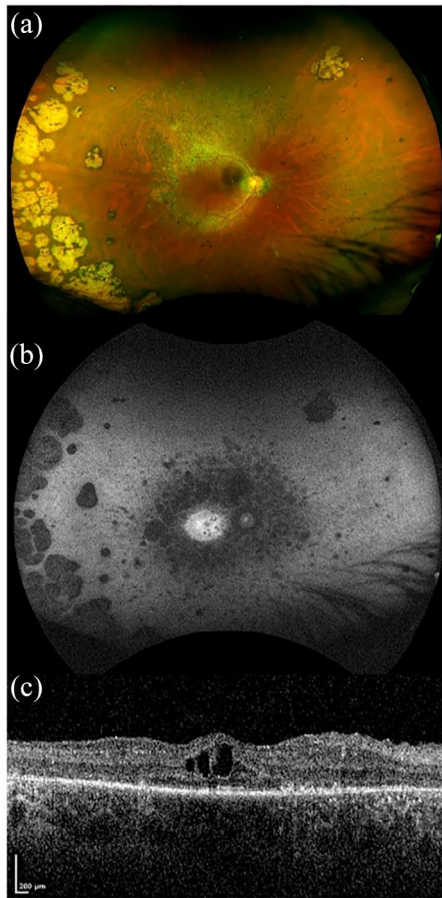


Figure 3. Retinal imaging of a patient with *MYO7A*-related Usher syndrome type 1. Images taken from a 34-year-old male with homozygous nonsense variants in *MYO7A*; c.2914C > T, p.(Arg972*). Best corrected LogMAR visual acuity was 0.24 in the right eye and 0.28 in the left eye. (a) Widefield colour imaging of the right fundus showing patchy RPE atrophy along the arcades with bone spicule pigmentation in the mid-periphery and peripapillary atrophy with arteriolar attenuation. In the temporal periphery, extensive chorioretinal atrophic patches are noted in this patient. (b) Widefield autofluorescence imaging of the right fundus showing dense hypoautofluorescence corresponding to RPE atrophy around the arcades extending into the mid-periphery. A ring of hyperautofluorescence is seen at the macula with speckled loss centrally. (c) Spectral-domain optical coherence tomography (SD-OCT) of the right eye showing loss of retinal lamination, cystoid macular oedema with intraretinal cystic changes and extensive loss of the ellipsoid zone.

measurement can show reduction and delay of amplitudes in the early stages of the disease, and is a useful test to perform in an infant born with profound deafness to determine the likelihood of underlying Usher 1, even before visual

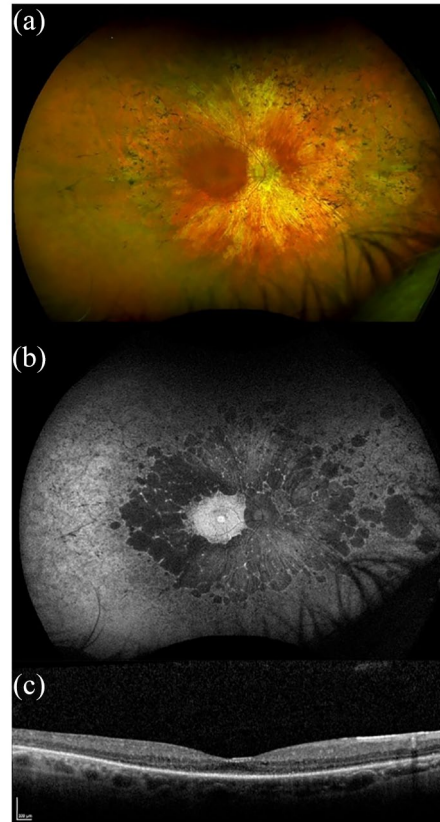


Figure 4. Retinal imaging of a patient with *USH2A*-related Usher syndrome type 2. Images taken from a 58-year-old male with compound heterozygous variants in *USH2A*; c.2299delG, p.(Glu767Serfs*21) and c.100C > T, p.(Arg34*). Best corrected LogMAR visual acuity was 0.50 in the right eye and 0.30 in the left eye. (a) Widefield colour imaging of the right fundus showing scattered bone spicule pigmentation in the mid-periphery and areas of depigmentation with RPE atrophy. Preserved retinal island at the macula, arteriolar attenuation and a waxy pale disc. (b) Widefield autofluorescence imaging of the right fundus showing hyperfluorescence signal at the fovea with dense scalloped hypoautofluorescence around the macula, arcades and extending past the mid-periphery corresponding with RPE atrophy. (c) Spectral-domain optical coherence tomography (SD-OCT) of the right eye showing retinal thinning and a small residual ellipsoid zone.

dysfunction is otherwise noted. Later, the full-field ERG is often non-recordable.

Dual sensory clinics are now being established to improve the clinical pathways and experience of children with hearing and sight impairment. These clinics will provide access to the relevant multidisciplinary in one visit, hence reducing stress and the burden associated with numerous,

separate medical appointments. Children with Usher syndrome have been reported to develop mental and behavioural disorders, including autism, conduct disorder, schizophrenia and learning difficulty. This could be multifactorial, due to sensory deprivation, stress, difficulty in diagnosis and a possible unproven genetic association.^{31,32} Dual sensory clinics will promote faster accurate diagnosis through more extensive genetic testing and detection of visual symptoms and mental health issues at an earlier stage.

Genetics of Usher syndrome

Usher genes

All Usher syndrome types are inherited in an autosomal recessive manner. To date, at least 10 causative genes have been identified for the disease, which include six Usher 1 genes, three Usher 2 genes and one Usher 3 gene. Historically, traditional Sanger sequencing of all Usher gene exons was found to provide a genetic diagnosis for more than 80% of Usher families,^{33,34} but this is time-consuming and costly, particularly for large patient cohorts. Microarray-based testing provided ~33% detection for Usher patients but can only screen for known mutations.^{35,36} NGS, including whole exome and genome sequencing, is now the method of choice with high efficiency offering the advantage of detecting a range of known and novel mutations, including large genomic DNA rearrangements. Targeted exome gene panel testing can reach diagnostic rates of around 70–80% in Usher families.^{29,37–39}

Currently, there are nine loci (USH1B–J) known to be involved in Usher 1. The genes identified for six of these loci are as follows: *MYO7A* (USH1B),⁴⁰ *USH1C* (USH1C),^{41,42} *CDH23* (USH1D),⁴³ *PCDH15* (USH1F),⁴⁴ *USH1G* (USH1G),⁴⁵ and *CIB2* (USH1J).⁴⁶ Of these genes, *MYO7A* is the most frequent cause of Usher 1, accounting for more than half of cases.³⁴ The USH1E, USH1H and USH1K loci have been mapped to chromosomes 21q21, 15q22–23 and 10p11.21–q21.1, respectively,^{47–49} but the genes are yet to be identified. It is worth noting that *CIB2* bi-allelic loss of function variants has been reported in patients with non-syndromic recessive hearing loss (DFNB48) but with no retinal symptoms.⁵⁰

Three genes underlying Usher 2 have been identified as *USH2A* (USH2A),⁵¹ *ADGRV1* (USH2C)⁵² and *WHRN* (USH2D).⁵³ *USH2A* mutations are the most common cause of Usher syndrome,

accounting for around 80% of Usher 2 cases.³⁴ In addition, *PDZ domain-containing 7* (*PDZD7*) has been reported to act as a disease modifier and contributor to a digenic form of Usher 2.⁵⁴

CLRN1 (or *USH3A*) is the only gene currently confirmed to cause Usher 3,^{55,56} with two prevalent mutations, p.(Tyr176*) and p.*Asn48Lys), accounting for most cases in Finnish and Ashkenazi Jewish patients, respectively.^{22,57} A homozygous missense variant in *histidyl-tRNA synthetase* (*HARS*) has also been reported in two patients with a phenotype compatible with Usher 3 (sometimes referred to as USH3B).⁵⁸

The Usher genes encode a number of structurally and functionally distinct proteins; these include an actin-binding motor protein (myosin VIIA, USH1B⁴⁰), scaffolding proteins (harmonin, USH1C;^{41,42} sans, USH1G;⁴⁵ whirlin, USH2D⁵³), cell adhesion/transmembrane proteins (cadherin 23, USH1D;⁴³ protocadherin 15, USH1F;⁴⁴ usherin, USH2A;^{51,59} clarin-1, USH3A⁵⁶), an adhesion G-coupled receptor (*ADGRV1*, USH2C⁵²) and a calcium- and integrin-binding protein (*CIB2*, USH1J⁴⁶). Most are expressed as multiple splice and protein variants in a range of tissues,^{59–64} but all of the Usher proteins are present in the inner ear and retina where most have been found to interact and form complexes that localise to subcellular locations in the ciliated sensory neurons, that is, inner ear hair cells and retinal photoreceptors.^{65,66} Myosin VIIA is also an essential RPE protein,^{67–69} and evidence suggests that clarin-1 is restricted to the retinal Müller glia.⁷⁰ Various studies have indicated the involvement of Usher proteins in a range of processes, including cohesion, mechanotransduction, synaptic maturation, and protein and organelle transport.

Genotype–phenotype correlations

The Usher genes show vast clinical heterogeneity and different mutations in most Usher genes have been linked to non-syndromic cases of autosomal recessive RP, or autosomal dominant or recessive sensorineural hearing loss (annotated as DFNA or DFNB).^{46,53,71–80} These include mutations in *MYO7A*, which have been associated with dominant and recessive non-syndromic hearing loss (DFNA11 [OMIM #601317] and DFNB2 [OMIM #600060], respectively).^{81,82} It has been suggested that mutations that allow some residual motor protein function, for example, in-frame deletion c.5146_5148delGAG p.(Glu1716del),

cause the milder non-syndromic phenotypes, whereas mutations associated with Usher 1, for example, c.1309G > A p.(Asp437Asn), have a more severe effect on protein function.⁸³ A separate study of 33 *USH1B* patients proposed that null *MYO7A* alleles, that is, those with stop mutations within the motor domain coding region such as c.999T > C p.(Tyr333*), may cause milder visual dysfunction than missense variants owing to a lack of mutant protein contributing to disease pathology.¹⁰ Significant correlations have not been reported in other patient populations with *MYO7A* mutations.⁸⁴ Mutations of *MYO7A* reported to cause DFN2 are comparable with those causing Usher 1, leading to question whether this phenotype results from missed RP or whether there may be modifying factors which influence the phenotype.⁸⁵ *MYO7A* mutations have also been reported to cause a phenotype of unilateral auditory neuropathy in a Chinese family with Usher 1⁸⁶ and an Usher 2 phenotype,⁸⁷ expanding its phenotypic spectrum.

Among the other Usher 1 genes, there is evidence of a genotype–phenotype correlation in both *CDH23* and *PCDH15*; missense variants are primarily associated with non-syndromic deafness (DFNB12 [OMIM #601386] or DFNB23 [OMIM #609533]) or more subtle RP symptoms, whereas frameshift, nonsense and splice site mutations cause Usher 1.^{72,74,88–90} However, missense mutations in *CDH23* can also cause milder or ‘atypical’ Usher 1, and genotype–phenotype correlations are not always predictable.⁸⁸ Pathogenic *USH1C* variants, including a leaky splice site mutation IVS12 + 5G > C,⁷³ have also been shown to cause recessive non-syndromic hearing loss (DFNB18 [OMIM #602092]), which has been proposed to be related to the less deleterious effect of the variants being located within alternatively spliced exons.^{73,91} A family with non-syndromic sensorineural hearing loss caused by compound heterozygous missense and frameshift mutations in *USH1G* has been described;⁷⁸ missense mutations in *USH1G* that are expected to result in residual protein function have been reported in Usher 1 families, thus expanding the phenotypic heterogeneity of Usher 1G disease.

USH2A has a diverse mutation spectrum, which includes nonsense, frameshift, missense and splice-affecting mutations, as well as deletions and duplications. The most common mutation found in *USH2A* is a single base pair (bp) deletion in exon

13, c.2299delG p.(Glu767Serfs*21),^{34,92} which has been shown to be associated with exon splicing.⁹³ This variant is predicted to produce a severely truncated protein and/or be subject to nonsense-mediated decay; however, transcript analysis showed that it caused skipping of exon 13 or exons 12 and 13.⁹³ Mutations of *USH2A* are associated with up to 23% of non-syndromic RP cases,⁹⁴ and specific mutant alleles are more frequent among such patients and families, the most common being missense variant c.2276G > T p.(Cys759Phe).^{95,96} Unusually, one patient with compound heterozygous *USH2A* mutations, c.1036A > C p.(Asn346His) and c.13316C > T p.(Thr4439Ile), was reported to have non-syndromic hearing loss, while their sibling harboured the same mutations and was diagnosed with typical Usher 2.⁹⁷

Several *USH2A* phenotype-genotype studies have been carried out to date. A survey conducted by Lenassi and colleagues of patients with *USH2A*-associated RP reported several ‘retinal disease-specific’ alleles that were rarely found in Usher 2 families, mostly missense variants that were likely to be less deleterious, while the Usher-associated variants mostly included those that were predicted to produce no viable protein (e.g. those causing premature truncation).⁹⁶ They proposed an allelic hierarchy model in which the presence of at least one retinal disease-specific allele in a patient with *USH2A*-related retinopathy resulted in the preservation of hearing. While this has not been supported by subsequent studies,^{6,98,99} the same analysis on a different cohort¹⁰⁰ combined with two large external cohorts^{98,101} found that the allelic hierarchy model was valid in 86% of individuals with non-syndromic *USH2A*-RP.¹⁰⁰ In addition, it has been reported that Usher 2 patients with one copy of the p.(Cys759Phe) allele showed a later onset of RP and milder hearing loss compared with the general Usher 2 population,⁶ and the presence of the p.(Cys759Phe) variant in a homozygous state or in combination with other *USH2A* missense mutations has been associated with isolated RP or RP with late onset hearing loss.⁹⁹ In contrast, the p.(Glu767Serfs*21) variant results in a more rapid deterioration and severe hearing threshold, heralding the need for careful audiological monitoring and consideration of cochlear implants.¹⁰⁰ In general, severe hearing impairment has been associated with truncating variants in *USH2A*.^{6,99,101,102} Further investigations into *USH2A* genotype–phenotype correlations have reported that the presence of two truncating mutations, or two missense

variants in the N-terminal laminin domain of the gene, were associated with Usher 2 patients and not those with non-syndromic RP,^{98,103} and the presence of at least one truncating mutation was related to earlier visual decline regardless of the phenotype.^{98,99}

WHRN is an additional Usher gene that causes non-syndromic deafness, which is related to the mutation location affecting the two predominantly expressed variants (long and short): N-terminal mutations that affect the long isoform are found in *USH2D* patients,^{53,104} whereas mutations in the C-terminal region manifest as *DFNB31*.^{105,106}

Development of therapies

Preclinical studies

While there is currently no available cure, there are numerous therapeutic strategies under development for Usher-related RP and other inherited retinal diseases (IRDs): these include gene replacement, gene editing, nonsense suppression and antisense oligonucleotide (ASO)-based approaches (Table 2). The eye is an attractive organ for therapeutic applications due to its accessibility and immune privilege, while the natural history of the disease with preserved cone photoreceptors at the fovea until a later stage provides an ideal window for intervention. Most therapeutic studies for Usher syndrome have been performed using patient-derived cells (typically fibroblasts) or mutant mice, of which there are many, with at least one existing for each causative gene.^{65,66} Most Usher mice display sensorineural hearing loss and vestibular phenotype reminiscent of their human counterparts, with only a limited number showing progressive retinal degeneration. Despite this, they have still aided in the assessment of potential treatments.

Gene replacement is an approach that has been shown to be effective in several Usher mouse models: adeno-associated virus (AAV) vectors have been used in *Myo7a*,^{107–110} *Whrn*¹³¹ and *Chn1*,¹³⁴ knockout mice via subretinal injection to restore expression of the wild-type Usher gene that was defective in each model. Dual overlapping AAV vectors have also been tested for *MYO7A* delivery as a potentially safer alternative for large genes with promising results, although they were not found to be

as efficient.^{108,109,111} Alternatively, delivery of functional *MYO7A* to the *USH1B* mouse model retina via lentiviral-based vectors with larger carrying capacities (9 versus 4.7 kb for single AAV) proved successful,^{112,113} although it harbours the risk of insertional mutagenesis. Among the other Usher models, gene delivery using AAV vectors has also produced significant improvements in auditory and vestibular hair cell function in mouse models of *USH1C*,¹¹⁴ *USH1G*,¹²⁴ *USH2D*,¹³² and *USH3*.^{135–137} This was achieved by viral injection into the inner ear through the round window membrane^{114,124,135–137} or posterior semicircular canal¹³² in postnatal neonatal mice.

The mouse inner ear is immature at birth and continues to mature postnatally. The acquisition of hearing (measured by the onset of startle response) occurs 12 days postnatally in mice, providing a window of opportunity for effective intervention with gene therapy.¹⁴⁵ Comparatively, hearing in humans is fully mature at birth (onset of startle response at 19 weeks gestation). The hearing loss in Usher 1 is established at birth and it is not clear whether the hair cells in the human inner ear are a viable therapeutic target. In order to be effective, human intervention should be considered within the foetal stage, before establishment of hearing (at ~18 weeks of gestation).¹⁴⁵ Hence, where therapeutic response in mice is successful when given soon after birth, it is questionable whether the same effect will be seen in patients with postnatal treatment. Overall, further studies in non-human primates will be useful in addressing some of these issues.⁶⁶

One alternative approach to gene replacement is gene editing, which involves cutting around genetic mutations through the use of nuclease enzymes and correcting the DNA error by homologous recombination with a DNA template containing the wild-type sequence.¹⁴⁶ This can be used to correct point mutations, small indels and splice site mutations, and is suitable for any gene size. Early investigations into the use of this strategy for Usher-directed treatment employed the use of two zinc finger nucleases to correct an *USH1C* point mutation (c.91C > T p.[Arg31*]) and induce full-length harmonin expression in cultured cells.¹¹⁵ In recent years, the CRISPR/Cas9 system has become highly popular for gene editing due to its efficiency and ease of use. This technique has been used for successful *in vitro* mutation repair in *USH2A* patient fibroblasts

Table 2. Treatment approaches for Usher syndrome.

Gene	Treatment type	Method	Model(s) tested	Clinical trials	References
Usher 1					
<i>MYO7A</i>	Gene replacement	Subretinal injection of AAV vectors	<i>Myo7a</i> ^{-/-} mice		Previous studies ¹⁰⁷⁻¹¹⁰
		Subretinal injection of dual AAV vectors	<i>Myo7a</i> ^{-/-} mice		Lopes and colleagues, ¹⁰⁸ Trapani and colleagues, ¹⁰⁹ Colella and colleagues ¹¹¹
		Subretinal injection of lentiviral vectors	<i>Myo7a</i> ^{-/-} mice	NCT01505062, NCT02065011	Hashimoto and colleagues, ¹¹² Zalocchi and colleagues ¹¹³
<i>USH1C</i>	Gene replacement	Round window membrane injection of AAV vectors	<i>Ush1c</i> knock-in (c.216G > A) mouse		Pan and colleagues ¹¹⁴
	Gene editing	Transfection of zinc finger nucleases and HDR template plasmid	HEK293 cell line transfected with <i>Ush1c</i> c.91C > T p.(Arg31*)		Overlack and colleagues ¹¹⁵
	Nonsense suppression	Incubation with NB30, NB54 and PTC124	HEK293 cell line and mouse retinas transfected with <i>Ush1c</i> c.91C > T p.(Arg31*),		Goldmann and colleagues ^{116,117}
	ASO	Peritoneal injection or transuterine injection into the amniotic cavity or inner ear of ASOs designed to correct defective pre-mRNA splicing	<i>Ush1c</i> knock-in (c.216G > A) mice		Previous studies ¹¹⁸⁻¹²⁰
<i>PCDH15</i>	Nonsense suppression	Incubation with gentamicin, paromomycin, NB30, NB54	COS-7 cell line transfected with mutant <i>PCDH15</i> constructs		Nudelman and colleagues ¹²¹⁻¹²³
<i>USH1G</i>	Gene replacement	Round window membrane injection of AAV vectors	<i>Ush1g</i> ^{-/-} mice		Emptoz and colleagues ¹²⁴
Usher 2					
<i>USH2A</i>	Gene editing	Transfection of CRISPR/Cas9 components and HDR template	Patient fibroblasts and iPSCs with compound heterozygous <i>USH2A</i> c.2299delG p.(Glu767Serfs*21) and c.2276G > T p.(Cys759Phe) or homozygous p.(Glu767Serfs*21)		Fuster-Garcia and colleagues, ¹²⁵ Sanjurjo-Soriano and colleagues ¹²⁶
	Nonsense suppression	Incubation with PTC124	HEK293 cell line transfected with <i>USH2A</i> c.11864G > A p.(Trp3955*). Patient fibroblasts with <i>USH2A</i> c.9424G > T p.(Gly3142*)		Neuhaus and colleagues, ¹²⁷ Samanta and colleagues ¹²⁸
	ASO	Transfection with ASOs designed to correct defective pre-mRNA splicing	Patient fibroblasts with <i>USH2A</i> c.7595-2144A > G and minigene splice assay		Slijkerman and colleagues ¹²⁹
		Treatment with ASO (QR-421a) designed to induce skipping of <i>USH2A</i> exon 13	Patient iPSC-derived retinal organoids with <i>USH2A</i> p.(Glu767Serfs*21), <i>ush2a</i> ^{rmc1} zebrafish, wild-type macaque, wild-type mice	NCT03780257	ProQR Therapeutics ¹³⁰
<i>USH2D</i>	Gene replacement	Subretinal injection of AAV vectors	<i>Whirlin</i> ^{-/-} mice		Zou and colleagues ¹³¹

(Continued)

Table 2. (Continued)

Gene	Treatment type	Method	Model(s) tested	Clinical trials	References
		Round window membrane injection or posterior semicircular canal injection of AAV vectors	<i>Whirler</i> mice		Isgrig and colleagues, ¹³² Yasuda and colleagues ¹³³
Usher 3					
<i>CLRN1</i>	Gene replacement	Subretinal or intravitreal injection of AAV vectors	Wild-type mice		Dinculescu and colleagues ¹³⁴
		Round window membrane injection of AAV vectors	<i>Clrn</i> ^{-/-} (KO-TgAC1)		Previous studies ^{135–137}
		Round window membrane injection of AAV vectors	<i>Clrn</i> ^{1ex4-/-} , <i>Clrn</i> ^{1ex4fl/fl} <i>Myo15</i> ^{-/-} <i>Cre</i> ^{+/-} mice		Dulon and colleagues ¹³⁶
		Round window membrane injection of AAV vectors	<i>Clrn</i> ^{-/-} mice, wild-type rats and macaque		Isgrig and colleagues ¹³²
	Small molecule drug	Peritoneal injection of BioFocus 844, identified as stabilising CLRN1 ^{N48K} protein	<i>Clrn</i> ^{1N48K/N48K}		Alagramam and colleagues ¹³⁸
Non-gene-specific					
	Cell transplant	Subretinal injection of human neural progenitor cells	<i>Ush2a</i> ^{-/-} mice		Lu and colleagues ¹³⁹
		Intravitreal implantation of encapsulated cells expressing CNTF	Rodent models of retinal disease	NCT00447980, NCT01530659	Previous studies ^{140–143}
		Retrobulbar, subtenons, intravitreal, subretinal, intra-optic nerve and intravenous injections of BMSC		NCT01920867, NCT03011541	Weiss and colleagues ¹⁴⁴
AAV, adeno-associated virus; ASO, antisense oligonucleotides; BMSC, bone marrow-derived stem cells; CNTF, ciliary neurotrophic factor; HDR, homology-directed repair; HEK, human embryonic kidney; iPSC, induced pluripotent stem cell.					

harbouring homozygous p.(Glu767Serfs*21) mutations,¹²⁵ as well as patient-derived induced pluripotent stem cells (iPSCs) either homozygous for *USH2A* p.(Glu767Serfs*21) mutations or compound heterozygous for p.(Glu767Serfs*21) and p.(Cys759Phe).¹²⁶ However, the efficiency of mutation correction was only 2.5% in fibroblasts¹²⁵ and up to 3% in iPSCs,¹²⁶ although the second study reported an 80% editing efficiency in the small number of homozygous *USH2A* clones that survived. Encouragingly, neither study reported off-target effects, which are unwanted mutations induced at DNA locations that show homology to the guide sequence. CRISPR/Cas9-based editing shows huge promise for the treatment of IRDs caused by a range of mutations; however, ensuring the absence of off-target effects and a high level of editing efficiency in retinal cells will be essential for future investigations.

Small molecule-based methods for treatment of Usher syndrome have included the use of translational read-through-inducing drugs (TRIDs), which bind to the translational machinery and are able to induce insertion of an amino acid at the site of premature stop codons, allowing read-through of nonsense mutations. These small molecule drugs include ataluren (PTC124) and designer aminoglycosides (NB compounds such as NB54). Several TRIDs have been used to suppress Usher 1-associated *PCDH15* and *USH1C* nonsense mutations *in vitro*, in cell cultures and in retinal explants.^{116,117,121–123} Furthermore, *in vivo* administration of NB54 and PTC124 was able to restore expression of full-length harmonin in mouse retinas transfected with *Ush1c* reporter constructs.¹¹⁷ For Usher 2 investigation, PTC124 was administered to a human embryonic kidney (HEK) cell model expressing a cDNA fragment of *USH2A* containing the c.11864G > A p.(Trp3955*)

mutation and showed a substantial increase in *USH2A* expression compared with the control.¹²⁷ Further studies demonstrated PTC124 efficacy in restoring *USH2A* protein expression and primary ciliogenesis capability in *USH2A* patient-derived fibroblasts with the c.9424G > T p.(Gly3142*) mutation.¹²⁸ Overall, TRIDs show promise as a safe and effective strategy to treat a range of Usher-related nonsense mutations; however, these particular variants cause ~16% of *USH2A*-related RP and 13% of all IRD cases.¹²⁸

An additional small molecule that has been of interest for Usher syndrome treatment, known as BioFocus 844 (BF844), was identified through cell-based high throughput screening as capable for stabilising the defective Clarin-1 protein produced by the common *CLRN1* missense variant p.(Asn48Lys).¹³⁸ BF844 was shown to protect against progressive hearing loss when administered intraperitoneally to an Usher 3 knock-in mouse model.

A further therapeutic option is the use of ASOs, which are short synthetic modified nucleic acids that bind RNA through complementary base pairing. They can be designed to bind pre-mRNA at splice enhancer or silencer target sites, preventing or stimulating binding of the spliceosome thereby modulating pre-mRNA splicing. ASOs have been used to rescue both the hearing and vestibular defects in *Ush1c* knock-in mice, which possess a cryptic splice site mutation that results in truncated harmonin protein.^{118–120} Initially, peritoneal injection of ASOs in neonatal mice was shown to partially correct defective pre-mRNA splicing of mutant *Ush1c* transcripts; the same group delivered ASOs to *Ush1c* knock-in foetal mice *in utero* via transuterine injection into the amniotic cavity and observed partial correction of vestibular function and hearing in the mice postnatally,¹¹⁹ while most recently transuterine injection directly into the developing inner ear produced more substantial improvements in both hearing and vestibular function that sustained into adulthood.¹²⁰ ASOs have also been used to correct a splicing defect caused by a deep intronic mutation in the *USH2A* gene (c.7595-2144A > G) which leads to insertion of a pseudoexon (PE40), in both patient-derived fibroblasts and a minigene splice assay.¹²⁹

Overall, there are a number of promising therapeutic strategies in the development for the Usher subtypes. The use of patient-derived retinal

organoids, which have already been generated for Usher syndrome caused by *USH2A* mutations,^{147,148} will further aid in the testing of novel treatments by providing the opportunity to demonstrate therapeutic potential in retinal-specific cells *in vitro*.

Identifying outcomes

Although several treatment strategies are already under development for Usher syndrome and other IRDs, identifying metrics that display detectable changes within relatively short time periods (e.g. 1–2 years) in otherwise slowly progressive conditions will aid the assessment of therapeutic efficacy in clinical trials. This is especially important when the treatments are administered systemically, such as orally, and the untreated eye cannot be used as a control. As the hearing loss is congenital and relatively stable throughout the lifetime of Usher patients (aside from Usher 3), a number of natural history studies have focussed on the progress of the retinal disease in Usher patients; these have included longitudinal assessment of patients with *MYO7A*^{9,10,84,149} and *USH2A*^{9,98,150–152} mutations using various clinical functional and structural measures, including visual acuity, perimetry, ERG, fundus autofluorescence and OCT-derived measurements.

For Usher 2, longitudinal data from a cohort of patients carrying the common *USH2A* c.2299delG mutation were studied and rod perimetry across the visual field was highlighted as a potential clinical measure for timely investigations, predicted to show detectable change within 1.4 years.¹⁵⁰ Ellipsoid zone (EZ) line width, which is the inner/outer segment boundary measured from OCT scans, was an effective surrogate measure of central visual loss and was predicted to show a detectable decrease in 2.3 years. A recent investigation into an Usher 2 patient population carrying a range of *USH2A* variants used retrospective longitudinal data to identify suitable clinical outcome metrics.¹⁵¹ Both EZ line and hyperautofluorescent outer retinal ring area showed significant reductions within the follow-up period (2–5 years); however, there was considerable variability in the population. Visual acuity was not found to be a suitable measurement due to its slow decline, consistent with previous work.¹⁵⁰ Furthermore, measuring retinal thickness from OCT images was confounded by the presence of macular oedema.

Data from ongoing longitudinal natural history studies, such as the ‘Rate of Progression in *USH2A*-related Retinal Degeneration’ (RUSH2A, NCT03146078) and the ‘Multicentre Longitudinal, Observational Natural History Study to Evaluate Disease Progression in Subjects With Usher Syndrome Type 1B’ (NCT03814499), in addition to the use of artificial intelligence-based methods will further aid in identifying suitable outcome metrics for clinical trials for Usher syndrome. This will likely be tailored to the mechanism (gain of function or slowing of disease progression) and target of treatment, that is, retina-wide or central retina. If gain of function is anticipated, trials could be relatively short (between 12 and 18 months) to arrive at an estimate of potential longevity.

Clinical trials

Owing to the success of preclinical investigations, there are several completed and ongoing clinical trials for patients with Usher-related RP. For Usher-specific gene therapy, the first clinical trial evaluated subretinal injection of a recombinant equine infectious anaemia virus (EIAV)-based lentiviral vector for delivery of *MYO7A* cDNA (UshStat) for treating patients with *MYO7A*-related Usher 1 (NCT01505062).¹¹³ However, this phase I/IIA trial has been terminated by the sponsor Sanofi due to review of clinical development plans and priorities. A second trial is ongoing to assess long-term safety of patients who received UshStat (NCT02065011). A further clinical trial is being prepared using dual hybrid AAV vectors to deliver *MYO7A* to the retina of *USH1B* patients (<https://cordis.europa.eu/project/id/754848/it>).^{109,153} Considering the Food and Drug Administration and European Medicines Agency approval of Spark Therapeutics Luxturna gene therapy for patients with *RPE65*-related retinal disease, gene replacement therapy has become a more likely future option for the treatment of several Usher subtypes. However, such therapies are likely to be highly costly, and conventional viral methods are not appropriate for very large genes like *USH2A* (cDNA length >15 kb).

For ASO-based treatments, there is currently a trial sponsored by ProQR for an ASO candidate (QR-421a), which has been designed to exclude the whole exon 13 in the *USH2A* mature mRNA transcript; this has been shown preclinically to result in restoration of functional usherin protein.¹³⁰ Considering that two of the most

common pathogenic *USH2A* mutations occur in exon 13,^{34,92,96} if successful this treatment would be suitable for a large proportion of patients with *USH2A*-related Usher 2 and RP. The phase I/II clinical trial is currently ongoing for intravitreal injection of QR-421a in patients with *USH2A* exon 13 variants (NCT03780257).

In addition to Usher gene-specific clinical trials, subretinal implantation of capsules containing human NT-501 cells that release ciliary neurotrophic factor (CNTF) has been trialled in patients with choroideremia and RP, including some with Usher 2 and Usher 3 (NCT00447980, NCT01530659).^{140,141} CNTF has been found to prolong photoreceptor survival in mouse and rat models of retinal degeneration.^{142,143} Viral delivery of rod-derived cone viability factor (RdCVF) is also under investigation for the treatment of RP; RdCVF is a factor naturally secreted by rods to protect cone photoreceptors,¹⁵⁴ and has been found to promote photoreceptor survival in mouse models of RP after viral-mediated expression in the retina.¹⁵⁵ If such strategies are effective in humans, this could be suitable for the significant number of IRD patients without a confirmed molecular diagnosis.

When choosing the method of treatment for Usher syndrome and other IRDs, the stage of disease will be an important consideration. The strategies already described are likely to be only effective at a stage where retinal photoreceptors are still intact. At the advanced stages of retinal degeneration, cell replacement therapies¹⁵⁶ or retinal prosthesis¹⁵⁷ may be the most feasible options. Advances in embryonic stem cell and iPSC technology make cell transplantation an ever-likely option for patients with late-stage retinal disease.¹⁵⁶ Bone marrow-derived stem cells (BMSC) have been trialled in five ungenotyped patients with varying subtypes of Usher syndrome as part of the Stem Cell Ophthalmology Treatment Study (SCOTS; NCT01920867 and NCT03011541).¹⁴⁴ Each Usher patient received autologous BMSC through either retrobulbar, subtenons, intravitreal, subretinal or intra-optic nerve injections into both eyes, followed by intravenous injections. The average pre-treatment logarithm of the minimum angle of resolution (LogMAR) acuity was 0.635, and the average postoperative change was a gain of 0.18 LogMAR. In the murine retina, it has been found that endogenous BMSC migrate and fuse with Müller glia cells after damage has been inflicted.¹⁵⁸ The

resulting hybrids were found to contribute to the replacement of damaged neurons, demonstrating the regenerative potential of BMSC in the mammalian retina.

Although there are no ongoing clinical trials for the Usher-specific hearing loss, there was a clinical trial for a recombinant adenovirus 5 (Ad5) vector containing the human atonal transcription factor (*ATOH1*) cDNA for administration via intra-labyrinthine infusion in patients with severe to profound sensorineural hearing loss (NCT02132130). The results are yet to be published. The successful preclinical work with several Usher mouse mutants makes gene therapy a promising future option; however, as discussed, these studies have involved treatment administration in prenatal or neonatal mice when the inner ear is still developing, and the use of similar therapies in children or adults with Usher syndrome may not be able to achieve reversal of the congenital inner ear defects.

Conclusion

Usher syndrome is a disorder with vast clinical and genetic heterogeneity, typically resulting in significant dual sensory loss causing great impact on patient quality of life. More than ever, the prospect of an available treatment for at least some Usher subtypes looks promising. However, there are still obstacles to overcome in developing safe treatments that work for each gene size and mutation. In addition to the many gene- and mutation-specific treatments under investigation, finding universal treatments that use common mechanisms for the treatment of RP should be a priority for the many patients that remain without a molecular diagnosis. Further patient analysis is necessary to determine better genotype–phenotype correlations for each clinical subtype to predict prognosis; this will inform genetic counselling, preimplantation diagnosis and the choice of best outcomes for each treatment trial.

Conflict of interest statement


The authors declared no potential conflicts of interest with respect to the research, authorship, and/or publication of this article.

Funding

The authors disclosed receipt of the following financial support for the research, authorship, and/or publication of this article: Research was funded by the Wellcome Trust (205174/Z/16/Z),

Retina UK, and the National Institute for Health Research (NIHR) Biomedical Research Centre at Moorfields Eye Hospital NHS Foundation Trust and UCL Institute of Ophthalmology.

ORCID iDs

Maria Toms  <https://orcid.org/0000-0002-0405-9208>

Mariya Moosajee  <https://orcid.org/0000-0003-1688-5360>

References

1. Vernon M. Usher's syndrome – deafness and progressive blindness. *J Chronic Dis* 1969; 22: 133–151.
2. Boughman JA, Vernon M and Shaver KA. Usher syndrome – definition and estimate of prevalence from two high-risk populations. *J Chronic Dis* 1983; 36: 595–603.
3. Kimberling WJ, Hildebrand MS, Shearer AE, *et al.* Frequency of Usher syndrome in two pediatric populations: implications for genetic screening of deaf and hard of hearing children. *Genet Med* 2010; 12: 512–516.
4. Marazita ML, Ploughman LM, Rawlings B, *et al.* Genetic epidemiologic studies of early-onset deafness in the United States school-age population. *Am J Med Genet* 1993; 46: 486–491.
5. Cohen M, Bitner-Glindzicz M and Luxon L. The changing face of Usher syndrome: clinical implications. *Int J Audiol* 2007; 46: 82–93.
6. Blanco-Kelly F, Jaijo T, Aller E, *et al.* Clinical aspects of Usher syndrome and the USH2A gene in a cohort of 433 patients. *JAMA Ophthalmol* 2015; 133: 157–164.
7. Sadeghi M, Cohn ES, Kimberling WJ, *et al.* Audiological and vestibular features in affected subjects with USH3: a genotype/phenotype correlation. *Int J Audiol* 2005; 44: 307–316.
8. El-Amraoui A and Petit C. The retinal phenotype of Usher syndrome: pathophysiological insights from animal models. *C R Biol* 2014; 337: 167–177.
9. Testa F, Melillo P, Bonnet C, *et al.* Clinical presentation and disease course of Usher syndrome because of mutations in MYO7A or USH2A. *Retina* 2017; 37: 1581–1590.
10. Jacobson SG, Cideciyan AV, Gibbs D, *et al.* Retinal disease course in Usher syndrome 1B due to MYO7A mutations. *Invest Ophthalmol Vis Sci* 2011; 52: 7924–7936.

11. Reiners J, Nagel-Wolfrum K, Juergens K, *et al.* Molecular basis of human Usher syndrome: deciphering the meshes of the Usher protein network provides insights into the pathomechanisms of the Usher disease. *Exp Eye Res* 2006; 83: 97–119.
12. Guidelines for aetiological investigation into severe to profound bilateral permanent childhood hearing impairment: produced by the British Association of Audiovestibular Physicians (BAAP). *Hear Balance Commun* 2016; 14: 135–145.
13. Pennings RJ, Damen GW, Snik AF, *et al.* Audiologic performance and benefit of cochlear implantation in Usher syndrome type I. *Laryngoscope* 2006; 116: 717–722.
14. Jatana KR, Thomas D, Weber L, *et al.* Usher syndrome: characteristics and outcomes of pediatric cochlear implant recipients. *Otol Neurotol* 2013; 34: 484–489.
15. Abadie C, Blanchet C, Baux D, *et al.* Audiological findings in 100 USH2 patients. *Clin Genet* 2012; 82: 433–438.
16. Reisser CF, Kimberling WJ and Otterstedde CR. Hearing loss in Usher syndrome type II is nonprogressive. *Ann Otol Rhinol Laryngol* 2002; 111: 1108–1111.
17. Pennings RJ, Huygen PL and Cremers WR. Hearing impairment in Usher syndrome type II. *Ann Otol Rhinol Laryngol* 2003; 112: 825.
18. Sadeghi M, Cohn ES, Kelly WJ, *et al.* Audiological findings in Usher syndrome types IIa and II (non-IIa). *Int J Audiol* 2004; 43: 136–143.
19. Hartel BP, van Nierop JWI, Huinck WJ, *et al.* Cochlear implantation in patients with Usher syndrome type IIa increases performance and quality of life. *Otol Neurotol* 2017; 38: e120–e127.
20. Magliulo G, Iannella G, Gagliardi S, *et al.* Usher's syndrome type II: a comparative study of genetic mutations and vestibular system evaluation. *Otolaryngol Head Neck Surg* 2017; 157: 853–860.
21. Pakarinen L, Karjalainen S, Simola KO, *et al.* Usher's syndrome type 3 in Finland. *Laryngoscope* 1995; 105: 613–617.
22. Ness SL, Ben-Yosef T, Bar-Lev A, *et al.* Genetic homogeneity and phenotypic variability among Ashkenazi Jews with Usher syndrome type III. *J Med Genet* 2003; 40: 767–772.
23. Pietola L, Aarnisalo AA, Abdel-Rahman A, *et al.* Speech recognition and communication outcomes with cochlear implantation in Usher syndrome type 3. *Otol Neurotol* 2012; 33: 38–41.
24. Guidelines for aetiological investigation into mild to moderate bilateral permanent childhood hearing impairment: produced by the British Association of Audiovestibular Physicians (BAAP). *Hear Balance Commun* 2016; 14: 125–134.
25. Jouret G, Poirsier C, Spodenkiewicz M, *et al.* Genetics of Usher syndrome: new insights from a meta-analysis. *Otol Neurotol* 2019; 40: 121–129.
26. Wilson C, Kennedy V, Stephens D, *et al.* Swimming after meningitis. *J R Soc Med* 2004; 97: 76–77.
27. Han BI, Song HS and Kim JS. Vestibular rehabilitation therapy: review of indications, mechanisms, and key exercises. *J Clin Neurol* 2011; 7: 184–196.
28. Millan JM, Aller E, Jaijo T, *et al.* An update on the genetics of Usher syndrome. *J Ophthalmol* 2011; 2011: 417217.
29. Dad S, Rendtorff ND, Tranebjærg L, *et al.* Usher syndrome in Denmark: mutation spectrum and some clinical observations. *Mol Genet Genomic Med* 2016; 4: 527–539.
30. Hagag AM, Mitsios A, Gill JS, *et al.* Characterisation of microvascular abnormalities using OCT angiography in patients with biallelic variants in USH2A and MYO7A. *Br J Ophthalmol* 2020; 104: 480–486.
31. Dammeyer J. Children with Usher syndrome: mental and behavioral disorders. *Behav Brain Funct* 2012; 8: 16.
32. Domanico D, Fragiotta S, Cutini A, *et al.* Psychosis, mood and behavioral disorders in Usher syndrome: review of the literature. *Med Hypothesis Discov Innov Ophthalmol* 2015; 4: 50–55.
33. Bonnet C, Grati M, Marlin S, *et al.* Complete exon sequencing of all known Usher syndrome genes greatly improves molecular diagnosis. *Orphanet J Rare Dis* 2011; 6: 21.
34. Le Quesne Stabej P, Saihan Z, Rangesh N, *et al.* Comprehensive sequence analysis of nine Usher syndrome genes in the UK National Collaborative Usher Study. *J Med Genet* 2012; 49: 27–36.
35. Jaijo T, Aller E, García-García G, *et al.* Microarray-based mutation analysis of 183 Spanish families with Usher syndrome. *Invest Ophthalmol Vis Sci* 2010; 51: 1311–1317.
36. Vozzi D, Aaspöllu A, Athanasakis E, *et al.* Molecular epidemiology of Usher syndrome in Italy. *Mol Vis* 2011; 17: 1662–1668.
37. Aparisi MJ, Aller E, Fuster-García C, *et al.* Targeted next generation sequencing for

- molecular diagnosis of Usher syndrome. *Orphanet J Rare Dis* 2014; 9: 168.
38. Krawitz PM, Schiska D, Krüger U, *et al.* Screening for single nucleotide variants, small indels and exon deletions with a next-generation sequencing based gene panel approach for Usher syndrome. *Mol Genet Genomic Med* 2014; 2: 393–401.
 39. Jiang L, Liang X, Li Y, *et al.* Comprehensive molecular diagnosis of 67 Chinese Usher syndrome probands: high rate of ethnicity specific mutations in Chinese USH patients. *Orphanet J Rare Dis* 2015; 10: 110.
 40. Weil D, Blanchard S, Kaplan J, *et al.* Defective myosin VIIA gene responsible for Usher syndrome type 1B. *Nature* 1995; 374: 60–61.
 41. Verpy E, Leibovici M, Zwaenepoel I, *et al.* A defect in harmonin, a PDZ domain-containing protein expressed in the inner ear sensory hair cells, underlies Usher syndrome type 1C. *Nat Genet* 2000; 26: 51–55.
 42. Bitner-Glindzicz M, Lindley KJ, Rutland P, *et al.* A recessive contiguous gene deletion causing infantile hyperinsulinism, enteropathy and deafness identifies the Usher type 1C gene. *Nat Genet* 2000; 26: 56–60.
 43. Bolz H, von Brederlow B, Ramirez A, *et al.* Mutation of CDH23, encoding a new member of the cadherin gene family, causes Usher syndrome type 1D. *Nat Genet* 2001; 27: 108–112.
 44. Ahmed ZM, Riazuddin S, Bernstein SL, *et al.* Mutations of the protocadherin gene PCDH15 cause Usher syndrome type 1F. *Am J Hum Genet* 2001; 69: 25–34.
 45. Weil D, El-Amraoui A, Masmoudi S, *et al.* Usher syndrome type I G (USH1G) is caused by mutations in the gene encoding SANS, a protein that associates with the USH1C protein, harmonin. *Hum Mol Genet* 2003; 12: 463–471.
 46. Riazuddin S, Belyantseva IA, Giese APJ, *et al.* Alterations of the CIB2 calcium- and integrin-binding protein cause Usher syndrome type 1J and nonsyndromic deafness DFNB48. *Nat Genet* 2012; 44: 1265–1271.
 47. Chaib H, Kaplan J, Gerber S, *et al.* A newly identified locus for Usher syndrome type I, USH1E, maps to chromosome 21q21. *Hum Mol Genet* 1997; 6: 27–31.
 48. Ahmed ZM, Riazuddin S, Khan SN, *et al.* USH1H, a novel locus for type I Usher syndrome, maps to chromosome 15q22-23. *Clin Genet* 2009; 75: 86–91.
 49. Jaworek TJ, Bhatti R, Latief N, *et al.* USH1K, a novel locus for type I Usher syndrome, maps to chromosome 10p11.21-q21.1. *J Hum Genet* 2012; 57: 633–637.
 50. Booth KT, Kahrizi K, Babanejad M, *et al.* Variants in CIB2 cause DFNB48 and not USH1J. *Clin Genet* 2018; 93: 812–821.
 51. Eudy JD, Weston MD, Yao SF, *et al.* Mutation of a gene encoding a protein with extracellular matrix motifs in Usher syndrome type IIa. *Science* 1998; 280: 1753–1757.
 52. Weston MD, Luijendijk MWJ, Humphrey KD, *et al.* Mutations in the VLGRI gene implicate G-protein signaling in the pathogenesis of Usher syndrome type II. *Am J Hum Genet* 2004; 74: 357–366.
 53. Ebermann I, Scholl HPN, Charbel Issa P, *et al.* A novel gene for Usher syndrome type 2: mutations in the long isoform of whirlin are associated with retinitis pigmentosa and sensorineural hearing loss. *Hum Genet* 2007; 121: 203–211.
 54. Ebermann I, Phillips JB, Liebau MC, *et al.* PDZD7 is a modifier of retinal disease and a contributor to digenic Usher syndrome. *J Clin Invest* 2010; 120: 1812–1823.
 55. Joensuu T, Hamalainen R, Yuan B, *et al.* Mutations in a novel gene with transmembrane domains underlie Usher syndrome type 3. *Am J Hum Genet* 2001; 69: 673–684.
 56. Adato A, Vreugde S, Joensuu T, *et al.* USH3A transcripts encode clarin-1, a four-transmembrane-domain protein with a possible role in sensory synapses. *Eur J Hum Genet* 2002; 10: 339–350.
 57. Fields RR, Zhou GM, Huang DL, *et al.* Usher syndrome type III: revised genomic structure of the USH3 gene and identification of novel mutations. *Am J Hum Genet* 2002; 71: 607–617.
 58. Puffenberger EG, Jinks RN, Sougnez C, *et al.* Genetic mapping and exome sequencing identify variants associated with five novel diseases. *PLoS ONE* 2012; 7: e28936.
 59. van Wijk E, Pennings RJ, te Brinke H, *et al.* Identification of 51 novel exons of the Usher syndrome type 2A (USH2A) gene that encode multiple conserved functional domains and that are mutated in patients with Usher syndrome type II. *Am J Hum Genet* 2004; 74: 738–744.
 60. Wolfrum U, Liu XR, Schmitt A, *et al.* Myosin VIIa as a common component of cilia and microvilli. *Cell Motil Cytoskeleton* 1998; 40: 261–271.
 61. Scanlan MJ, Williamson B, Jungbluth A, *et al.* Isoforms of the human PDZ-73 protein exhibit differential tissue expression. *Biochim Biophys Acta* 1999; 1445: 39–52.

62. Overlack N, Maerker T, Latz M, *et al.* SANS (USH1G) expression in developing and mature mammalian retina. *Vision Res* 2008; 48: 400–412.
63. Vastinsalo H, Jalkanen R, Dinculescu A, *et al.* Alternative splice variants of the USH3A gene clarin 1 (CLRN1). *Eur J Hum Genet* 2011; 19: 30–35.
64. Bhattacharya G, Miller C, Kimberling WJ, *et al.* Localization and expression of usherin: a novel basement membrane protein defective in people with Usher's syndrome-type IIa. *Hear Res* 2002; 163: 1–11.
65. Toms M, Bitner-Glindzicz M, Webster A, *et al.* Usher syndrome: a review of the clinical phenotype, genes and therapeutic strategies. *Expert Rev Ophthalmol* 2015; 10: 241–256.
66. Géléoc GGS and El-Amraoui A. Disease mechanisms and gene therapy for Usher syndrome. *Hear Res* 2020; 394: 107932.
67. Liu XR, Ondek B and Williams DS. Mutant myosin VIIa causes defective melanosome distribution in the RPE of shaker-1 mice. *Nat Genet* 1998; 19: 117–118.
68. Gibbs D, Kitamoto J and Williams DS. Abnormal phagocytosis by retinal pigmented epithelium that lacks myosin VIIa, the Usher syndrome 1B protein. *Proc Natl Acad Sci USA* 2003; 100: 6481–6486.
69. Lopes VS, Gibbs D, Libby RT, *et al.* The Usher 1B protein, MYO7A, is required for normal localization and function of the visual retinoid cycle enzyme, RPE65. *Hum Mol Genet* 2011; 20: 2560–2570.
70. Xu L, Bolch SN, Santiago CP, *et al.* Clarin-1 expression in adult mouse and human retina highlights a role of Müller glia in Usher syndrome. *J Pathol* 2020; 250: 195–204.
71. Liu XZ, Hope C, Walsh J, *et al.* Mutations in the myosin VIIA gene cause a wide phenotypic spectrum, including atypical Usher syndrome. *Am J Hum Genet* 1998; 63: 909–912.
72. Ahmed ZM, Riazuddin S, Ahmad J, *et al.* PCDH15 is expressed in the neurosensory epithelium of the eye and ear and mutant alleles are responsible for both USH1F and DFNB23. *Hum Mol Genet* 2003; 12: 3215–3223.
73. Ahmed ZM, Smith TN, Riazuddin S, *et al.* Nonsyndromic recessive deafness DFNB18 and Usher syndrome type IC are allelic mutations of USH1C. *Hum Genet* 2002; 110: 527–531.
74. Schultz JM, Bhatti R, Madeo AC, *et al.* Allelic hierarchy of CDH23 mutations causing non-syndromic deafness DFNB12 or Usher syndrome USH1D in compound heterozygotes. *J Med Genet* 2011; 48: 767–775.
75. Rivolta C, Berson EL and Dryja TP. Paternal uniparental heterodisomy with partial isodisomy of chromosome 1 in a patient with retinitis pigmentosa mutation in without hearing loss and a missense the Usher syndrome type II gene USH2A. *Arch Ophthalmol* 2002; 120: 1566–1571.
76. Nakayama J, Fu YH, Clark AM, *et al.* A nonsense mutation of the MASS1 gene in a family with febrile and afebrile seizures. *Ann Neurol* 2002; 52: 654–657.
77. Schneider E, Maerker T, Daser A, *et al.* Homozygous disruption of PDZD7 by reciprocal translocation in a consanguineous family: a new member of the Usher syndrome protein interactome causing congenital hearing impairment. *Hum Mol Genet* 2009; 18: 655–666.
78. Oonk AMM, van Huet RA, Leijendeckers JM, *et al.* Nonsyndromic hearing loss caused by USH1G mutations: widening the USH1G disease spectrum. *Ear Hear* 2015; 36: 205–211.
79. Yang T, Wei X, Chai Y, *et al.* Genetic etiology study of the non-syndromic deafness in Chinese Hans by targeted next-generation sequencing. *Orphanet J Rare Dis* 2013; 8: 85.
80. Khan MI, Kersten FF, Azam M, *et al.* CLRN1 mutations cause nonsyndromic retinitis pigmentosa. *Ophthalmology* 2011; 118: 1444–1448.
81. Liu XZ, Walsh J, Mburu P, *et al.* Mutations in the myosin VIIA gene cause non-syndromic recessive deafness. *Nat Genet* 1997; 16: 188–190.
82. Weil D, Kussel P, Blanchard S, *et al.* The autosomal recessive isolated deafness, DFNB2, and the Usher 1B syndrome are allelic defects of the myosin-VIIA gene. *Nat Genet* 1997; 16: 191–193.
83. Riazuddin S, Nazli S, Ahmed ZM, *et al.* Mutation spectrum of MYO7A and evaluation of a novel nonsyndromic deafness DFNB2 allele with residual function. *Hum Mutat* 2008; 29: 502–511.
84. Lenassi E, Saihan Z, Cipriani V, *et al.* Natural history and retinal structure in patients with Usher syndrome type 1 owing to MYO7A mutation. *Ophthalmology* 2014; 121: 580–587.
85. Astuto LM, Kelley PM, Askew JW, *et al.* Searching for evidence of DFNB2. *Am J Med Genet* 2002; 109: 291–297.
86. Xia H, Hu P, Yuan L, *et al.* A homozygous MYO7A mutation associated to Usher syndrome and unilateral auditory neuropathy spectrum disorder. *Mol Med Rep* 2017; 16: 4241–4246.
87. Rong W, Chen X, Zhao K, *et al.* Novel and recurrent MYO7A mutations in Usher syndrome type 1 and type 2. *PLoS ONE* 2014; 9: e97808.
88. Astuto LM, Bork JM, Weston MD, *et al.* CDH23 mutation and phenotype heterogeneity: a profile

- of 107 diverse families with Usher syndrome and nonsyndromic deafness. *Am J Hum Genet* 2002; 71: 262–275.
89. Bork JM, Peters LM, Riazuddin S, *et al.* Usher syndrome 1D and nonsyndromic autosomal recessive deafness DFNB12 are caused by allelic mutations of the novel cadherin-like gene CDH23. *Am J Hum Genet* 2001; 68: 26–37.
 90. Doucette L, Merner ND, Cooke S, *et al.* Profound, prelingual nonsyndromic deafness maps to chromosome 10q21 and is caused by a novel missense mutation in the Usher syndrome type IF gene PCDH15. *Eur J Hum Genet* 2009; 17: 554–564.
 91. Ouyang XM, Xia XJ, Verpy E, *et al.* Mutations in the alternatively spliced exons of USH1C cause non-syndromic recessive deafness. *Hum Genet* 2002; 111: 26–30.
 92. Dreyer B, Tranebjaerg L, Brox V, *et al.* A common ancestral origin of the frequent and widespread 2299delG USH2A mutation. *Am J Hum Genet* 2001; 69: 228–234.
 93. Lenassi E, Saihan Z, Bitner-Glindzicz M, *et al.* The effect of the common c.2299delG mutation in USH2A on RNA splicing. *Exp Eye Res* 2014; 122: 9–12.
 94. McGee TL, Seyedahmadi BJ, Sweeney MO, *et al.* Novel mutations in the long isoform of the USH2A gene in patients with Usher syndrome type II or non-syndromic retinitis pigmentosa. *J Med Genet* 2010; 47: 499–506.
 95. Rivolta C, Sweklo EA, Berson EL, *et al.* Missense mutation in the USH2A gene: association with recessive retinitis pigmentosa without hearing loss. *Am J Hum Genet* 2000; 66: 1975–1978.
 96. Lenassi E, Vincent A, Li Z, *et al.* A detailed clinical and molecular survey of subjects with nonsyndromic USH2A retinopathy reveals an allelic hierarchy of disease-causing variants. *Eur J Hum Genet* 2015; 23: 1318–1327.
 97. Lenassi E, Robson AG, Luxon LM, *et al.* Clinical heterogeneity in a family with mutations in USH2A. *JAMA Ophthalmol* 2015; 133: 352–355.
 98. Pierrache LH, Hartel BP, van Wijk E, *et al.* Visual prognosis in USH2A-associated retinitis pigmentosa is worse for patients with Usher syndrome type IIa than for those with nonsyndromic retinitis pigmentosa. *Ophthalmology* 2016; 123: 1151–1160.
 99. Pérez-Carro R, Blanco-Kelly F, Galbis-Martínez L, *et al.* Unravelling the pathogenic role and genotype-phenotype correlation of the USH2A p.(Cys759Phe) variant among Spanish families. *PLoS ONE* 2018; 13: e0199048.
 100. Molina-Ramírez LP, Lenassi E, Ellingford JM, *et al.* Establishing genotype-phenotype correlation in USH2A-related disorders to personalize audiological surveillance and rehabilitation. *Otol Neurotol* 2020; 41: 431–437.
 101. Hartel BP, Lofgren M, Huygen PL, *et al.* A combination of two truncating mutations in USH2A causes more severe and progressive hearing impairment in Usher syndrome type IIa. *Hear Res* 2016; 339: 60–68.
 102. Lee SY, Joo K, Oh J, *et al.* Severe or profound sensorineural hearing loss caused by novel USH2A variants in Korea: potential genotype-phenotype correlation. *Clin Exp Otorhinolaryngol* 2020; 13: 113–122.
 103. Gao FJ, Wang DD, Chen F, *et al.* Prevalence and genetic-phenotypic characteristics of patients with USH2A mutations in a large cohort of Chinese patients with inherited retinal disease. *Br J Ophthalmol*. Epub ahead of print 18 March 2020. DOI: 10.1136/bjophthalmol-2020-315878.
 104. Audo I, Bujakowska K, Mohand-Said S, *et al.* A novel DFNB31 mutation associated with Usher type 2 syndrome showing variable degrees of auditory loss in a consanguineous Portuguese family. *Mol Vis* 2011; 17: 1598–1606.
 105. Mburu P, Mustapha M, Varela A, *et al.* Defects in whirlin, a PDZ domain molecule involved in stereocilia elongation, cause deafness in the whirler mouse and families with DFNB31. *Nat Genet* 2003; 34: 421–428.
 106. Tlili A, Charfedine I, Lahmar I, *et al.* Identification of a novel frameshift mutation in the DFNB31/WHRN gene in a Tunisian consanguineous family with hereditary non-syndromic recessive hearing loss. *Hum Mutat* 2005; 25: 503–503.
 107. Colella P, Sommella A, Marrocco E, *et al.* Myosin7a deficiency results in reduced retinal activity which is improved by gene therapy. *PLoS ONE* 2013; 8: e72027.
 108. Lopes VS, Boye SE, Louie CM, *et al.* Retinal gene therapy with a large MYO7A cDNA using adeno-associated virus. *Gene Ther* 2013; 20: 824–833.
 109. Trapani I, Colella P, Sommella A, *et al.* Effective delivery of large genes to the retina by dual AAV vectors. *EMBO Mol Med* 2014; 6: 194–211.
 110. Dyka FM, Boye SL, Chiodo VA, *et al.* Dual adeno-associated virus vectors result in efficient in vitro and in vivo expression of an oversized gene, MYO7A. *Hum Gene Ther Methods* 2014; 25: 166–177.

111. Colella P, Trapani I, Cesi G, *et al.* Efficient gene delivery to the cone-enriched pig retina by dual AAV vectors. *Gene Ther* 2014; 21: 450–456.
112. Hashimoto T, Gibbs D, Lillo C, *et al.* Lentiviral gene replacement therapy of retinas in a mouse model for Usher syndrome type 1B. *Gene Ther* 2007; 14: 584–594.
113. Zallocchi M, Binley K, Lad Y, *et al.* EIAV-based retinal gene therapy in the shaker1 mouse model for Usher syndrome type 1B: development of UshStat. *PLoS ONE* 2014; 9: e94272.
114. Pan B, Askew C, Galvin A, *et al.* Gene therapy restores auditory and vestibular function in a mouse model of Usher syndrome type 1c. *Nat Biotechnol* 2017; 35: 264–272.
115. Overlack N, Goldmann T, Wolfrum U, *et al.* Gene repair of an Usher syndrome causing mutation by zinc-finger nuclease mediated homologous recombination. *Invest Ophthalmol Vis Sci* 2012; 53: 4140–4146.
116. Goldmann T, Rebibo-Sabbah A, Overlack N, *et al.* Beneficial read-through of a USH1C nonsense mutation by designed aminoglycoside NB30 in the retina. *Invest Ophthalmol Vis Sci* 2010; 51: 6671–6680.
117. Goldmann T, Overlack N, Moeller F, *et al.* A comparative evaluation of NB30, NB54 and PTC124 in translational read-through efficacy for treatment of an USH1C nonsense mutation. *EMBO Mol Med* 2012; 4: 1186–1199.
118. Lentz JJ, Jodelka FM, Hinrich AJ, *et al.* Rescue of hearing and vestibular function by antisense oligonucleotides in a mouse model of human deafness. *Nat Med* 2013; 19: 345–350.
119. Depreux FF, Wang L, Jiang H, *et al.* Antisense oligonucleotides delivered to the amniotic cavity in utero modulate gene expression in the postnatal mouse. *Nucleic Acids Res* 2016; 44: 9519–9529.
120. Wang L, Kempton JB, Jiang H, *et al.* Fetal antisense oligonucleotide therapy for congenital deafness and vestibular dysfunction. *Nucleic Acids Res* 2020; 48: 5065–5080.
121. Rebibo-Sabbah A, Nudelman I, Ahmed ZM, *et al.* In vitro and ex vivo suppression by aminoglycosides of PCDH15 nonsense mutations underlying type 1 Usher syndrome. *Hum Genet* 2007; 122: 373–381.
122. Nudelman I, Rebibo-Sabbah A, Cherniavsky M, *et al.* Development of novel aminoglycoside (NB54) with reduced toxicity and enhanced suppression of disease-causing premature stop mutations. *J Med Chem* 2009; 52: 2836–2845.
123. Nudelman I, Glikin D, Smolkin B, *et al.* Repairing faulty genes by aminoglycosides: development of new derivatives of geneticin (G418) with enhanced suppression of disease-causing nonsense mutations. *Bioorg Med Chem* 2010; 18: 3735–3746.
124. Emptoz A, Michel V, Lelli A, *et al.* Local gene therapy durably restores vestibular function in a mouse model of Usher syndrome type 1G. *Proc Natl Acad Sci USA* 2017; 114: 9695–9700.
125. Fuster-Garcia C, Garcia-Garcia G, Gonzalez-Romero E, *et al.* USH2A gene editing using the CRISPR system. *Mol Ther Nucleic Acids* 2017; 8: 529–541.
126. Sanjurjo-Soriano C, Erkilic N, Baux D, *et al.* Genome editing in patient iPSCs corrects the most prevalent USH2A mutations and reveals intriguing mutant mRNA expression profiles. *Mol Ther Methods Clin Dev* 2020; 17: 156–173.
127. Neuhaus C, Eisenberger T, Decker C, *et al.* Next-generation sequencing reveals the mutational landscape of clinically diagnosed Usher syndrome: copy number variations, phenocopies, a predominant target for translational read-through, and PEX26 mutated in Heimler syndrome. *Mol Genet Genomic Med* 2017; 5: 531–552.
128. Samanta A, Stingl K, Kohl S, *et al.* Ataluren for the treatment of Usher syndrome 2A caused by nonsense mutations. *Int J Mol Sci* 2019; 20: 6274.
129. Slijkerman RW, Vache C, Dona M, *et al.* Antisense oligonucleotide-based splice correction for USH2A-associated retinal degeneration caused by a frequent deep-intronic mutation. *Mol Ther Nucleic Acids* 2016; 5: e381.
130. ProQR Therapeutics. QR-421a, an antisense oligonucleotide, for the treatment of retinitis pigmentosa due to USH2A exon 13 mutations, <https://www.proqr.com/ush01se18x/> (2018, accessed April 2020).
131. Zou J, Luo L, Shen Z, *et al.* Whirlin replacement restores the formation of the USH2 protein complex in whirlin knockout photoreceptors. *Invest Ophthalmol Vis Sci* 2011; 52: 2343–2351.
132. Isgrig K, Shteamer JW, Belyantseva IA, *et al.* Gene therapy restores balance and auditory functions in a mouse model of Usher syndrome. *Mol Ther* 2017; 25: 780–791.
133. Yasuda SP, Seki Y, Suzuki S, *et al.* c.753A>G genome editing of a Cdh23(ahl) allele delays age-related hearing loss and degeneration of cochlear hair cells in C57BL/6J mice. *Hear Res* 2020; 389: 107926.
134. Dinculescu A, Stupay RM, Deng WT, *et al.* AAV-mediated clarin-1 expression in the mouse

- retina: implications for USH3A gene therapy. *PLoS ONE* 2016; 11: e0148874.
135. Geng R, Omar A, Gopal SR, *et al.* Modeling and preventing progressive hearing loss in Usher syndrome III. *Sci Rep* 2017; 7: 13480.
 136. Dulon D, Papal S, Patni P, *et al.* Clarin-1 gene transfer rescues auditory synaptopathy in model of Usher syndrome. *J Clin Invest* 2018; 128: 3382–3401.
 137. György B, Meijer EJ, Ivanchenko MV, *et al.* Gene transfer with AAV9-PHP.B rescues hearing in a mouse model of Usher syndrome 3A and transduces hair cells in a non-human primate. *Mol Ther Methods Clin Dev* 2019; 13: 1–13.
 138. Alagramam KN, Gopal SR, Geng R, *et al.* A small molecule mitigates hearing loss in a mouse model of Usher syndrome III. *Nat Chem Biol* 2016; 12: 444–451.
 139. Lu B, Wang S, Francis PJ, *et al.* Cell transplantation to arrest early changes in an ush2a animal model. *Invest Ophthalmol Vis Sci* 2010; 51: 2269–2276.
 140. Talcott KE, Ratnam K, Sundquist SM, *et al.* Longitudinal study of cone photoreceptors during retinal degeneration and in response to ciliary neurotrophic factor treatment. *Invest Ophthalmol Vis Sci* 2011; 52: 2219–2226.
 141. Birch DG, Weleber RG, Duncan JL, *et al.* Randomized trial of ciliary neurotrophic factor delivered by encapsulated cell intraocular implants for retinitis pigmentosa. *Am J Ophthalmol* 2013; 156: 283–292.
 142. LaVail MM, Unoki K, Yasumura D, *et al.* Multiple growth factors, cytokines, and neurotrophins rescue photoreceptors from the damaging effects of constant light. *Proc Natl Acad Sci USA* 1992; 89: 11249–11253.
 143. LaVail MM, Yasumura D, Matthes MT, *et al.* Protection of mouse photoreceptors by survival factors in retinal degenerations. *Invest Ophthalmol Vis Sci* 1998; 39: 592–602.
 144. Weiss JN and Levy S. Stem Cell Ophthalmology Treatment Study (SCOTS): bone marrow derived stem cells in the treatment of Usher syndrome. *Stem Cell Invest* 2019; 6: 31.
 145. Hastings ML and Brigande JV. Fetal gene therapy and pharmacotherapy to treat congenital hearing loss and vestibular dysfunction. *Hear Res* 2020; 394: 107931.
 146. Li M, Suzuki K, Kim NY, *et al.* A cut above the rest: targeted genome editing technologies in human pluripotent stem cells. *J Biol Chem* 2014; 289: 4594–4599.
 147. Tucker BA, Mullins RF, Streb LM, *et al.* Patient-specific iPSC-derived photoreceptor precursor cells as a means to investigate retinitis pigmentosa. *eLife* 2013; 2: e00824.
 148. Guo Y, Wang P, Ma JH, *et al.* Modeling retinitis pigmentosa: retinal organoids generated from the iPSCs of a patient with the USH2A mutation show early developmental abnormalities. *Front Cell Neurosci* 2019; 13: 361.
 149. Sumaroka A, Matsui R, Cideciyan AV, *et al.* Outer retinal changes including the ellipsoid zone band in Usher syndrome 1B due to MYO7A mutations. *Invest Ophthalmol Vis Sci* 2016; 57: 253–261.
 150. Calzetti G, Levy RA, Cideciyan AV, *et al.* Efficacy outcome measures for clinical trials of USH2A caused by the common c.2299delG mutation. *Am J Ophthalmol* 2018; 193: 114–129.
 151. Toms M, Dubis AM, de Vrieze E, *et al.* Clinical and preclinical therapeutic outcome metrics for USH2A-related disease. *Hum Mol Genet* 2020; 29: 1882–1899.
 152. Sandberg MA, Rosner B, Weigel-DiFranco C, *et al.* Disease course in patients with autosomal recessive retinitis pigmentosa due to the USH2A gene. *Invest Ophthalmol Vis Sci* 2008; 49: 5532–5539.
 153. Trapani I. Adeno-associated viral vectors as a tool for large gene delivery to the retina. *Genes* 2019; 10: 287.
 154. Lévillard T, Mohand-Saïd S, Lorentz O, *et al.* Identification and characterization of rod-derived cone viability factor. *Nat Genet* 2004; 36: 755–759.
 155. Byrne LC, Dalkara D, Luna G, *et al.* Viral-mediated RdCVF and RdCVFL expression protects cone and rod photoreceptors in retinal degeneration. *J Clin Invest* 2015; 125: 105–116.
 156. Terrell D and Comander J. Current stem-cell approaches for the treatment of inherited retinal degenerations. *Semin Ophthalmol* 2019; 34: 287–292.
 157. Nadal J and Iglesias M. Long-term visual outcomes and rehabilitation in Usher syndrome type II after retinal implant Argus II. *BMC Ophthalmol* 2018; 18: 205.
 158. Pesaresi M, Bonilla-Pons SA, Simonte G, *et al.* Endogenous mobilization of bone-marrow cells into the murine retina induces fusion-mediated reprogramming of Müller glia cells. *EBioMedicine* 2018; 30: 38–51.