

1807400835

ROYAL FREE THESIS 1991

ULTRASOUND IN THE DIAGNOSIS OF CARPAL TUNNEL SYNDROME.

PETER JOHN ALEXANDER MOLITOR

THESIS SUBMITTED FOR
THE DEGREE OF MASTER OF SURGERY
IN THE UNIVERSITY OF LONDON

1991

UNIVERSITY OF CAMBRIDGE
ORTHOPAEDIC RESEARCH UNIT
ADDENBROOKE'S HOSPITAL
CAMBRIDGE.

ProQuest Number: U049411

All rights reserved

INFORMATION TO ALL USERS

The quality of this reproduction is dependent upon the quality of the copy submitted.

In the unlikely event that the author did not send a complete manuscript and there are missing pages, these will be noted. Also, if material had to be removed, a note will indicate the deletion.



ProQuest U049411

Published by ProQuest LLC (2017). Copyright of the Dissertation is held by the Author.

All rights reserved.

This work is protected against unauthorized copying under Title 17, United States Code
Microform Edition © ProQuest LLC.

ProQuest LLC.
789 East Eisenhower Parkway
P.O. Box 1346
Ann Arbor, MI 48106 – 1346

ABSTRACT.

Carpal tunnel syndrome is a common condition; patients' symptoms can be rapidly relieved by a simple surgical procedure. The diagnosis is often obvious in the presence of a typical history and physical signs. In doubtful cases the surgeon utilises electromyography to confirm the diagnosis. This test, however, is time-consuming and may be unpleasant for the patient.

A new test is described using therapeutic ultrasound which is applied to the patient's wrist for a few seconds. A positive response occurs when the patient experiences paraesthesiae or discomfort in the hand in the median nerve distribution.

Following a pilot study on 19 patients the test has been further evaluated on a series of 82 patients by comparison with EMG studies.

The performance of the ultrasound therapy unit used in the experiments was first fully investigated by measurement of output power and frequency.

Animal experiments were conducted to determine the effect of ultrasound on peripheral nerve using the rat sciatic nerve as an animal model. A needle thermistor and hydrophone were used to measure skin temperature and ultrasound intensity during insonation (i.e. exposure of tissue to ultrasound) via a water bag which was used to ensure efficient acoustic coupling. Specimens of sciatic nerve from the insonated rats were examined under the

electron microscope. In addition teased specimens of sciatic nerve were prepared and axon counts performed on thin sections.

The laboratory work revealed no damage in nerves exposed to normal levels of ultrasound but in the maximal exposure group some focal remyelination was seen

The final results of the clinical assessment of the ultrasound test showed a 74% correlation with EMG studies although the latter must remain the investigation of choice. The ultrasound test would seem to have a place as a reasonably accurate, non-invasive screening procedure which can be performed in the clinic with a minimum amount of apparatus.

CONTENTS

Abstract	1
Contents	3
Acknowledgements	10
Statement of originality	12
CHAPTER 1. - THE CARPAL TUNNEL SYNDROME	13
1.1 History of the diagnosis of carpal tunnel syndrome	13
1.2 Anatomy of the carpal tunnel	28
1.3 Anatomical anomalies	38
1.4 Clinical picture and pathogenesis of carpal tunnel syndrome	40
1.5 Surgical management of carpal tunnel syndrome	48
CHAPTER 2. - NERVE CONDUCTION STUDIES	68
CHAPTER 3. - THEORY OF ULTRASOUND	72
3.1 Fundamentals of ultrasound	72
3.2 Dosage of ultrasound	81
3.3 Interaction of ultrasound with tissue	88
CHAPTER 4. - EVALUATION OF THE ULTRASOUND UNIT	94
4.1 Introduction	94
4.2 Measurement of frequency	95
4.3 Measurement of duty cycle	96
4.4 Measurement of power output	96
4.5 Discussion	105

CHAPTER 5. - EXPERIMENT TO DETERMINE SKIN TEMPERATURE AND ULTRASOUND INTENSITY DURING INSONATION OF THE RAT SCIATIC NERVE	107
5.1 Introduction	107
5.2 Materials and methods	108
5.3 Results	109
5.4 Discussion	115
CHAPTER 6. - THE STRUCTURAL EFFECT OF ULTRASOUND ON PERIPHERAL NERVE	116
6.1 Introduction	116
6.2 Materials and methods	118
6.3 Results	122
6.4 Discussion	145
CHAPTER 7. - ULTRASOUND DIAGNOSIS OF CARPAL TUNNEL SYNDROME	148
7.1 Introduction	148
7.2 Patients and methods	148
7.3 Results	150
7.4 Discussion	153
CHAPTER 8	156
8.1 Discussion	156
8.2 Contribution to knowledge	161
8.3 Further work	162
8.4 Summary	163
REFERENCES	165

APPENDICES

i. - A DIAGNOSTIC TEST FOR CARPAL TUNNEL SYNDROME USING ULTRASOUND - PILOT STUDY	183
---	-----

i.1 Introduction	183
i.2 Patients and methods	183
i.3 Results	184
i.4 Discussion	185
ii. - ACUTE CARPAL TUNNEL SYNDROME IN HAEMOPHILIA - A CASE REPORT	186
ii.1 Introduction	186
ii.2 Case report	186
ii.3 Discussion	189
iii. - PREPARATION OF TISSUE FOR ELECTRON MICROSCOPY	192
iii.1 Introduction	192
iii.2 Methods	198
iii.3 Thin sections	200
iii.4 Ultra-thin sections	200
iv. RESULTS	202
iv. - table 1. Ultrasound assessment of carpal tunnel syndrome	202
iv. - table 2. Controls	206
v. - STATISTICAL ANALYSIS - CALCULATIONS	207

TABLES AND ILLUSTRATIONS

CHAPTER 1.

Fig. 1.1 Sir James Paget 1865	14
Fig. 1.2 Sir James Learmonth 1933	18
Fig. 1.3 Bony margins of the carpal tunnel	30
Fig. 1.4 Section of the carpal tunnel	30
Fig.1.5 Regular branching of the median nerve	32
Fig.1.6 Subligamentous and transligamentous course of	

the median nerve	34
Fig.1.7 Accessory branches of the median nerve at the distal carpal tunnel	35
Fig.1.8 High division of the median nerve	35
Fig.1.9 Accessory branches of the median nerve proximal to the carpal tunnel	36
Fig.1.10 Lateral view of the hand of a patient with carpal tunnel syndrome showing thenar wasting and wasting of the first dorsal interosseous muscle	37
Fig.1.11 Pressure relations between components of the median nerve in the carpal tunnel	45
Fig.1.12 Skin incisions for carpal tunnel decompression	52-54
 CHAPTER 2	
Fig. 2.1 Typical EMG equipment	71
 CHAPTER 3	
Fig. 3.1 Ultrasound waves	74
Fig. 3.2 Ultrasound waveform parameters	74
Fig. 3.3 Ultrasound transducer	77
Fig. 3.4 Ultrasound beam profile	77
Fig. 3.5 Intensity peaks in ultrasound beam	79
Fig. 3.6 Diagram of apparatus used to plot ultrasound intensity peaks	80
Table 3.7 Absorption coefficients of various materials	83
Table 3.8 Half-value depth of various materials	84
Table 3.9 Specific acoustic impedance of various materials	85

CHAPTER 4

Fig. 4.1 Principle of ultrasound therapy unit	95
Fig. 4.2 Measurement of power output using a needle hydrophone	96
Fig. 4.3 Graph - ultrasound calibration with a needle hydrophone	98
Fig. 4.4 Graph - ultrasound calibration with a Bio-Tek Wattmeter	101
Fig. 4.5 Graph - ultrasound calibration after repair of Sonopuls	103
Fig. 4.6 Graph - repeat ultrasound calibrations with Medisonics Wattmeter	105
Fig. 4.7 Sonopuls 434 ultrasound therapy unit	106
Table 4.1 Calibration with needle hydrophone	98
Table 4.ii Calibration with Bio-Tek Wattmeter	100
Table 4.iii Calibration with Medisonics Wattmeter	102
Table 4.iv Repeat calibrations with Medisonics	104

CHAPTER 5

Fig. 5.1 Experiment to determine temperature rise and ultrasound intensity during insonation via a water bag	108
Table 5.2 Rise in skin temperature - results	109
Fig. 5.3 Graph - rise in skin temperature	109
Fig. 5.4 Section of skin burn - H. & E.	113
Fig. 5.5 Frozen section of skin burn - Oil Red O	114

CHAPTER 6

Fig. 6.1 Perfusion apparatus	120
------------------------------	-----

Fig. 6.2 Semi-thin section of normal sciatic nerve x 100 - 1% Toluidine blue in borax	123
Fig. 6.3 Semi-thin section of specimen R5 (maximum ultrasound) showing focal re-myelination and degeneration x 100 - 1% Toluidine blue in borax	124
Fig. 6.4 Section of fibrous mass from R5 - H.& E.	125

ELECTRON MICROGRAPHS

Fig. 6.5 Normal sciatic nerve showing myelinated and un- myelinated fibres x 3000	127
Fig. 6.6 Myelinated axon with Schwann cell nucleus x 4,400	128
Fig. 6.7 Myelinated axon, Schwann cell and un-myelinated fibres x 7,100	129
Fig. 6.8 Myelin lamellae x 21,000	130
Fig. 6.9 Myelinated axon sectioned at level of node of Ranvier x 10,400	131
Fig. 6.10 Myelinated axon sectioned at level of incisure of Schmidt Lanterman x 4,400	132
Fig. 6.11 Myelinated fibre and adjacent capillary wall x 4,400	133
Fig. 6.12 Myelinated fibre and adjacent perineurium showing collagen fibrils in transverse and longitudinal section x 7,100	134
Fig. 6.13 Un-myelinated fibres enclosed by a basal lamina of a Schwann cell x 8,300	135
Fig. 6.14 Remnants of basal lamina - noted in both insonated and control sections x 8,300	136
Fig. 6.15 Mast cell x 4,400	137

Fig. 6.16 Section of specimen R5 showing focal re-myelination, damage to the perineurium and fibrous reaction outside the nerve x 6,700	138
Fig. 6.17 Section of fibrous swelling associated with specimen R5 showing fibroblasts and numerous collagen fibrils x 3,000	139
Fig. 6.18 Re-myelinating and degenerate axons from specimen R5 x 8,300	140
Fig. 6.19 Single re-myelinating axon from specimen R5 x 8,300	141
Fig.6.20 Teased axon showing node of Ranvier x 400	143
Fig.6.21 Teased axon showing incisure of Schmidt Lanterman x 400	144

CHAPTER 7

Fig. 7.1 Using Sonopuls 434 ultrasound unit to detect carpal tunnel syndrome	149
Table 7.2 Summary of results	151

APPENDIX 2

Fig. ii.1 Acute carpal tunnel syndrome in a haemophiliac - palmar bruising and swelling at the wrist	188
--	-----

APPENDIX 3

Fig. iii.1 Transmission electron microscope	193
---	-----

APPENDIX 4

Table iv.1 Ultrasound assessment of carpal tunnel syndrome	202
Table iv.2 Ultrasound assessment of carpal tunnel syndrome - controls	206

ACKNOWLEDGEMENTS.

I wish to express my gratitude to Mr. Neil Rushton for allowing me to conduct my research in the University of Cambridge Orthopaedic Research Unit and for providing constant advice and encouragement.

I would like to thank Professor G. Bentley for his valued comments and guidance in supervising this thesis.

I am grateful to the East Anglian Health Authority for funding my research.

My colleagues in the University of Cambridge Orthopaedic Research Unit were a willing source of help and advice.

Thanks to Mr. D.J.Waters of Nomeq Ltd., Redditch, Worcestershire for the loan of the Sonopuls ultrasound therapy unit and to Mr. A. French of Medisonics U.K. Ltd., for the loan of a Medisonics Wattmeter.

My thanks go to the following (listed in alphabetical order) whose assistance is greatly appreciated:-

Dr. K. Bradshaw, E.M.G. Dept., Addenbrooke's Hospital.

Dr. B.J. Burchell, University of Cambridge.

Dr. A. Davenport, Dept. of Clinical Pharmacology, Addenbrooke's Hospital.

Mr. D.J.Dandy, Addenbrooke's Hospital.

Miss B. Disbrey, Histopathology Dept, Addenbrooke's Hospital.

Dr. F. Duck, Medical Physics Dept., Royal United Counties Hospital, Bath.

Dr. P.P. Dendy, Medical Physics Dept., Addenbrooke's Hospital.

Dr. Mary Dyson, Anatomy Dept., Guy's Hospital, London.

Mr. Graham Gatward, Electron Microscopy Dept., Addenbrooke's Hospital.

Dr. Audrey M. Glauert, Strangeways Research Laboratory, Cambridge.

Dr. Jean Jacobs, Institute of Neurology, Queen Square, London.

Dr. J. Jenner, Addenbrooke's Hospital, Cambridge.

Dr. R. King, Dept. of Neurological Science, Royal Free Hospital, London.

Dr. T.G. Leighton, Cavendish Laboratories, University of Cambridge.

Mr. M.J.W. Pickworth, Medical Physics Dept., Addenbrooke's Hospital.

Mrs. Beryl Smith, Central Biological Services, University of Cambridge.

Dr. N.E. Williams, Addenbrooke's Hospital, Cambridge.

The patients who kindly collaborated in the clinical study.

Finally my thanks go to my family for their patience and encouragement during the preparation of this thesis.

STATEMENT OF ORIGINALITY.

I have based this work on the hypothesis that therapeutic ultrasound can be used to diagnose carpal tunnel syndrome. The ultrasound tests in the small pilot study were performed by physiotherapists but in the larger series described in this thesis I personally examined the patients and performed the ultrasound tests. The calibration experiments were performed with assistance from Mr. M.J.W. Pickworth of the medical physics department at Addenbrooke's Hospital and Dr. T.G. Leighton of the Cavendish Laboratories, University of Cambridge.

For the animal studies I constructed the perfusion apparatus, prepared the fixatives and performed the perfusions myself. I also prepared the teased specimens and performed the axon counts. The frozen sections of skin were prepared by the Histology Department, Addenbrooke's Hospital and the H. and E. sections were processed during routine work in the Orthopaedic Research Unit, Addenbrooke's Hospital.

The cutting of ultra-thin sections of the delicate nerve preparations to sufficiently high standards requires considerable expertise and practice and so I entrusted this part of the specimen preparation to Mr. Graham Gatward of the Electron Microscopy Department of Addenbrooke's Hospital. Subsequent examination of specimens under the electron microscope was all performed personally.

CHAPTER 1.

THE CARPAL TUNNEL SYNDROME.

1.1 A HISTORY OF THE DIAGNOSIS OF CARPAL TUNNEL SYNDROME

Carpal tunnel syndrome is one of the commonest entrapment neuropathies and the classic symptoms and signs are well recognised. The condition was first described by Sir James Paget (1865) Fig.1.1 who wrote about a compression irritation syndrome of the median nerve at the wrist. He described a specimen in the pathology museum of St. Bartholomew's Hospital, London which consisted of a hand which had been surgically amputated. A cord had been drawn very tightly around the man's wrist seven years before the amputation. Paget wrote - "The median nerve where it passes under the annular ligament is enlarged with adhesions to all the adjacent tissues and induration of both it and them - it is probable that the median and other nerves suffered injury, for he had constant pain in the hand after the accident, impairment of the touch, contraction of the fingers and constantly repeated ulcers on the back of the hand."

Paget also reported a case from Guy's hospital:-

The patient had a Colles' fracture which had healed with excessive callus, causing compression of the median



Fig.1.1 Sir James Paget 1865

(Reproduced by kind permission of the Wellcome Museum
for the History of Medicine - London).

nerve. He had ulceration of the thumb, index and middle fingers which resisted "various treatments" and was cured only "by so binding the wrist that the parts of the palmar aspect being relaxed the pressure on the nerve was removed."

Subsequent reports of patients with symptoms and signs in the distribution of the median nerve in the hand did not, however, localise the lesion to the carpal tunnel. A series of cases from Massachusetts General Hospital was reported by Sir James Putnam (1880), a Boston neurologist. He noted that these cases had symptoms which are now regarded as typical of carpal tunnel syndrome i.e. pain and paraesthesiae in the median nerve distribution of the hands, often worse at night. Most of the 37 cases were female with an average age of 35. However, by 1950 there were only twelve reported cases of operative decompression of the carpal tunnel (Pfeffer et al 1988). The low incidence of surgical intervention was due to a lack of accurate diagnosis of the carpal tunnel syndrome. Early reports concentrated on either sensory or motor symptoms of median nerve compression, assuming a separate disease process. Treatment at this stage involved varied remedies such as galvanism, phosphorous, amyl nitrite, potassium bromide and cannabis indica - more commonly known nowadays as marijuana!

In a review of "The Symptomatology, Diagnosis and Surgical Treatment of Cervical Ribs", Keen (1907) cites

a personal communication from Mr Percy Sargent and Dr Farquhar Buzzard who describe a 49 year old woman with symptoms and signs typical of carpal tunnel syndrome. Radiographs revealed bilateral cervical ribs but at operation there was no evidence of brachial plexus compression by the cervical rib. Postoperative recovery was very slow.

James Ramsey Hunt (1909) noted an apparently isolated weakness and atrophy of the thenar muscles and attributed it to compression of the motor branch of the median nerve in the carpal tunnel secondary to occupational over-use. In a subsequent paper (Hunt 1911), he noted that the patients at times experienced paresthesia in the fingers.

Kinnier Wilson (1913) and Sargent (1921) were both proponents of the cervical rib theory as a cause of paraesthesiae and weakness in the median nerve distribution of the hand. They both advocated excision of the rib to effect a cure. Sargent, however, recognised that thenar atrophy often did not resolve after rib resection.

In the same year as Kinnier Wilson's review of the cervical rib, Marie and Foix (1913) reported the post mortem findings of an 80 year old female with bilateral thenar wasting. They observed both gross and microscopic changes of the compressed median nerve beneath the transverse carpal ligament. The recognition that the transverse carpal ligament played a key role in the

pathogenesis of median nerve compression was prophetic for its time. Unfortunately this work was overlooked for three decades, and in the first half of the twentieth century cervical rib compression of the brachial plexus was the commonest diagnosis used to account for median nerve symptoms in the hand.

The medical profession, however, became dissatisfied with the results of rib excision and sought explanations as to why motor and sensory symptoms occurred in patients without cervical ribs.

It was recognised that wrist trauma could be associated with compression of the median nerve in the carpal tunnel, the earliest report being that of Paget (1854). The next significant reports were by Watson-Jones (1929) who described median nerve neuropathy following carpal dislocation and Abbott and Saunders (1933) who published a series of cases of chronic median nerve compression following distal forearm fractures. They described variable thenar wasting and paraesthesiae in the median nerve distribution occurring at about two months post fracture.

One of the earliest carpal tunnel decompressions was reported in 1933 by Sir James Learmonth (Fig.1.2). He described a 71 year old woman with post traumatic arthritis of the wrist and anaesthesia over the tips of the index and middle fingers. On exploring the wrist he noted compression of the nerve between the anterior annular ligament and arthritic outgrowths from the carpal




Fig.1.2 Sir James Learmonth 1933

(Reproduced by kind permission of the Royal College of Surgeons of Edinburgh).

bones. Two weeks post operatively sensibility returned in the fingers. Zabriskie (1935) and Wartenberg (1939) questioned the theory of isolated thenar motor branch compression, pointing out that the paraesthesiae experienced by patients was often ignored.

By 1940 few advocates of this diagnosis remained.

It was not until 1938 that spontaneous compression of the median nerve at the wrist was recognised. Moersch (1938) described a syndrome with thenar atrophy and sensory changes. He pointed out the dangers of confusing this syndrome with cervical or brachial plexus lesions. Zachary (1945) reviewed the literature on the subject of thenar palsy and concluded that there was a definite "syndrome" consisting of thenar atrophy and sensory changes. He maintained that there were good grounds for suspecting a lesion of the main trunk of the median nerve, possibly in the carpal tunnel.

The next year Cannon and Love (1946) published a series of nine patients who underwent carpal tunnel decompression, three having spontaneous onset of symptoms. One case had previously undergone surgery for scalenus anticus syndrome without success and so, like Moersch (1938), they warned of the dangers of confusing carpal tunnel syndrome with brachial plexus lesions. Despite many reports and reviews in the literature to date no one had emphasised the importance of spontaneous compression of the median nerve as a distinct clinical entity. The landmark paper in the history of the

diagnosis of carpal tunnel syndrome was that of Brain, Wright and Wilkinson (1947).

Brain and Wilkinson were neurologists whilst Wright was a surgeon. They described in detail the clinical signs, diagnosis and pathology of spontaneous median nerve compression in the carpal tunnel of six women. The classical clinical picture was noted of "initial burning and tingling sensations in the median nerve distribution of the hand". When discomfort was severe it would waken patients at night. There was also weakness of abductor brevis and opponens pollicis accompanied by thenar wasting. Impairment of manipulation of small objects was also a feature. Examination revealed decreased appreciation of pin-prick, light touch and tactile discrimination over the fingers innervated by the median nerve. All cases were treated surgically with immediate relief of the symptoms of pain and paresthesia. At operation, compression of the median nerve was confirmed in the carpal tunnel with oedema of a short segment of nerve proximal to the ligament.

The authors emphasised that sensory abnormalities were important in the diagnosis of carpal tunnel syndrome and warned of potential confusion with "costoclavicular syndrome". They quoted Sargent's 65 cases of cervical rib (Sargent 1921) in 60% of which no objective sensory changes were found.

The next significant papers were written by Phalen in 1950 when he described three patients treated by carpal

tunnel decompression, once more warning that care should be taken to rule out a more proximal lesion. Phalen advised percussion over the carpal tunnel as a diagnostic aid. i.e. Tinel's Test. However, in his original paper Tinel (1915) describes percussion of divided nerves as a prognostic sign of regeneration. Phalen (1951) described a further diagnostic test, the wrist flexion test, later to be known as Phalen's Sign. Two years later Kremer, Gilliat, Golding and Wilson (1953) discussed acroparesthesia, or paresthesia of the extremities, in carpal tunnel syndrome and concluded that the symptoms were due to ischaemia of the median nerve at the site of compression in the carpal tunnel. A second paper by Gilliat and Wilson (1953) goes on to describe a pneumatic tourniquet test for the carpal tunnel syndrome based on the chance finding that patients with acroparesthesia experienced worsening of their symptoms when a pneumatic tourniquet was inflated on the arm above the elbow. Thirty five patients with suspected carpal tunnel syndrome were tested. Within one minute of inflation of a cuff around the arm above the elbow, 13 patients experienced paraesthesiae in the median nerve distribution of the hand. In all cases this test was negative after carpal tunnel decompression. The test was later criticised by Phalen (1966) who pointed out that normal subjects experience paraesthesiae when a cuff is inflated around the arm. At

that time the only methods of diagnosing carpal tunnel syndrome were history and clinical examination. It was not until 1956 that nerve conduction studies were first used as an aid to diagnosis. Although electrophysiological techniques were well established it was only after the second world war that they achieved widespread use in clinical diagnosis.

Their use in the diagnosis of carpal tunnel syndrome was first described by Simpson (1956). As the pathological basis of the condition was assumed to be local ischaemia of the median nerve, Simpson looked for phenomena known to be present in experimental ischaemia of short lengths of nerve. These were :-

- 1) diminished conduction velocity of a nerve impulse through the ischaemic segment.
- 2) repetitive firing of motor nerve fibres after a single electrical stimulus.

(Kugelberg (1946) Kugelberg and Cobb (1951).)

He demonstrated slowed conduction velocity in 11 out of 15 cases of carpal tunnel syndrome and repetitive firing after single shock stimulation in 7 cases.

Further work was carried out on nerve conduction studies, (Thomas, Lambert, Kalman and Cseuz (1967) and Buchthal and Rosenfalk (1971)) so that electromyography is now the main confirmatory test for carpal tunnel syndrome.

Around this time Phalen (1966 and 1968) reviewed his experience over 17 years of the diagnosis and treatment

of carpal tunnel syndrome. He concluded that "the diagnosis of carpal tunnel syndrome is made on the basis of a positive wrist flexion test, (Phalen's sign), the presence of Tinel's sign over the median nerve at the wrist and the restriction of all sensory findings to the median nerve distribution in the hand - these are the three most reliable findings and usually two of these findings are present in every patient with carpal tunnel syndrome." In addition some degree of atrophy of the thenar muscles will be present in half the patients. He concedes that electrodiagnostic methods may be helpful in doubtful cases.

As the main symptom of carpal tunnel syndrome is sensory disturbance several studies have been made of sensibility testing.

Gelberman, Szabo, Williamson, and Dimick (1983) assessed twelve volunteer subjects after exerting controlled external pressure on the carpal tunnel. Four sensory tests were used:-

1. Two point discrimination.
2. Moving two point discrimination.
3. Semmes - Weinstein monofilaments.
4. Vibration.

Threshold tests (i.e. vibration and monofilaments) consistently reflected gradual decreases in nerve function both subjectively and on electrical testing. Two point discrimination remained normal until conduction had nearly ceased.

Spindler and Dellon (1982) compared detailed sensibility testing with nerve conduction in patients with carpal tunnel syndrome. In 74 hands tested, nerve conduction studies were abnormal in 81% and sensory examination was abnormal in 66%. In the least severely affected group nerve conduction was abnormal in 80% whereas sensory examination was abnormal in only 10%

Another clinical sign was described by Pryse-Phillips (1984).

In a group of 212 patients referred for electromyography he asked what they did with their hands when the symptoms were at their worst. A positive "flick" sign was a sudden movement of the hands and wrist (in response to his question) as if shaking a clinical thermometer.

One hundred and ninety seven cases were positive (93%) and E.M.G. was abnormal in 93%.

Gutman, Gutierrez and Riggs (1986) were unable to reproduce these results and out of 56 patients only 14 (25%) had a positive flick test.

There have been few applications of new technology to the diagnosis of carpal tunnel syndrome.

A novel approach was used by Herrick, Herrick, Purohit and Smith (1986). They employed liquid crystal thermography i.e. a temperature sensitive crystal in sheet form which is laid on the wrist and changes colour in response to temperature changes. The method is, however, rather crude and out of 35 cases only 9 had

positive thermograms and positive E.M.G.s. In a later study Herrick and Herrick (1987) used liquid crystal and electronic thermography with much better results.

Comparing the results with electromyography, thermography showed 97% specificity and 100% sensitivity for the diagnosis of carpal tunnel syndrome. However the test must be performed by a technician trained in the technique to give consistent results.

Computerised Axial Tomography (CAT Scan) has been used to look at changes in carpal tunnel syndrome. John and his colleagues (1983) studied two cadavers, two controls and twenty patients suffering with carpal tunnel syndrome (confirmed by EMG or surgery). The following changes were noted :-

1. thickening of the transverse carpal ligament with a resultant decrease in tunnel volume.
2. synovial sheath hypertrophy causing an increase in the tunnel contents by thickened synovium around the tendons.
3. recurrent fibrosis after surgery.

Bleecker, Bohlman, Moreland and Tipton (1985), examined 14 male electricians with C.A.T. Seven had symptoms of carpal tunnel syndrome with associated EMG changes.

These cases had reduced carpal canal size (1.4-2.0 cm²) Although these findings shed some light on the pathology of the condition they do not make C.A.T. scanning of the wrist a practical aid to diagnosis.

Magnetic Resonance Imaging (MRI) has also been used to

investigate carpal tunnel syndrome. Middleton, Kneeland and Kelluran (1987) first studied normal anatomy with MRI imaging of eighteen wrists from nine normal controls and comparing the results with cryosections of cadaver wrists. They found that the borders of the carpal tunnel could be well defined and the median nerve was seen as an ovoid structure of moderate signal intensity, easily distinguished from the flexor tendons. The wrists of ten patients with carpal tunnel syndrome were then examined. Segmental and diffuse swelling of the median nerve was noted in six cases, distortion of the nerve in one and thickening of the tendon sheaths in one.

It would therefore seem that MRI can accurately and reliably detect pathological changes in patients with carpal tunnel syndrome.

Clinical examination remains the mainstay of diagnosis of carpal tunnel syndrome and the various diagnostic tests have been the subject of several critical reviews. Tinel's sign was evaluated by Gelmers (1979) and he concluded that it was of no diagnostic value.

Heller, Ring, Costeff and Solzi (1986) compared Phalen's and Tinel's test with EMG and again concluded that the signs were not reliable. A further, more detailed evaluation of clinical tests was carried out by Golding, Rose and Selvarajah (1986). They compared the five commonly used clinical tests for the diagnosis of carpal tunnel syndrome with electromyography. The tests were:-

1. demonstration of hypoalgesia in the median nerve distribution of the hand
2. thenar wasting
3. Phalen's test
4. Tinel's test
5. tourniquet test

After clinical evaluation electromyography was performed. The conclusion was that no clinical sign was useful and they believe that the only way to make the diagnosis is by careful evaluation of the symptoms rather than signs. Confirmation of the condition should be made by nerve conduction studies wherever possible.

In conclusion, over the last century much has been written on the diagnosis of carpal tunnel syndrome. To date the most reliable methods of diagnosis are the taking of a careful history and confirming clinical suspicions with nerve conduction studies.

1.2 ANATOMY OF THE CARPAL TUNNEL.

In order to understand the mechanisms involved in the pathogenesis of carpal tunnel syndrome and to treat the condition surgically it is important to have a knowledge of the anatomy of the region. Anomalies will be discussed at the end of the chapter.

The palmar surface of the carpus is a deep concavity, the palmar groove bounded on its medial and lateral borders by bony projections. The medial border is formed by the pisiform and the hook of the hamate. The pisiform lies in the medial part of the proximal border of the muscular hypothenar eminence which forms the medial part of the palm. The projecting lateral border of the carpal groove is formed by the tubercle of the scaphoid and the tubercle of the trapezium. A strong fibrous retinaculum, the transverse carpal ligament, converts the osseous groove into a tunnel. Its attachments are the pisiform and hook of hamate medially and the scaphoid tubercle and crest of trapezium (and sometimes the radial styloid) laterally. Through the carpal tunnel pass the following structures:-

- 1) Flexor pollicis longus tendon
- 2) Flexor digitorum superficialis tendons
- 3) Flexor digitorum profundus tendons
- 4) Common synovial sheath
- 5) median nerve and its artery.

The radial part of the transverse carpal ligament splits

into superficial and deep layers to provide a fibro-osseous tunnel for the tendon of flexor carpi radialis. In saggital section the transverse carpal ligament is fusiform in shape being thickest in the area volar to the distal two thirds of the capitate and the most proximal part of the base of the third metacarpal. At this point the ligament is 2mm. thick whereas proximal and distal to this point it thins out to about 1mm thick. (Robbins 1963)

Robbins (1963) studied the course of the median nerve and its anatomical relations in the carpal tunnels of seven cadaveric wrists by taking serial sections. He noted the following points:-

- 1) the cross sectional area of the carpal tunnel decreases from its entrance to a point between 2 and 2.5 cms. distally. It then increases in area to give a canal with a slightly narrowed waist.
- 2) at its narrowest point the canal is rigidly bounded on three sides by carpal bones and roofed by a thickened transverse carpal ligament.
- 3) all the structures are crowded in the canal.
- 4) in six of the seven specimens the median nerve was flattened and directly beneath the tight ligament.
- 5) projecting into the floor of the canal proximally is

Fig.1.3 THE BONY MARGINS OF THE CARPAL TUNNEL.

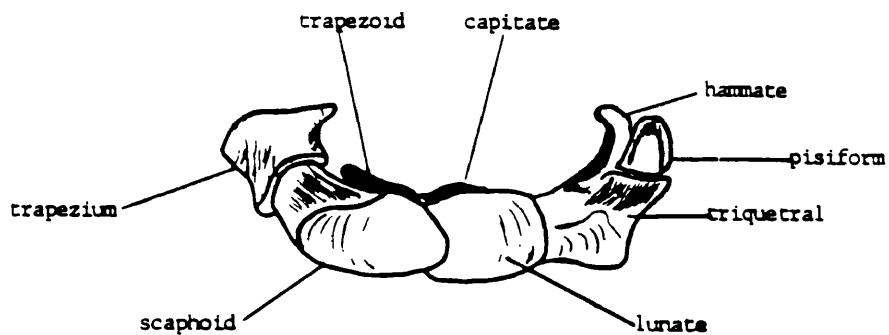
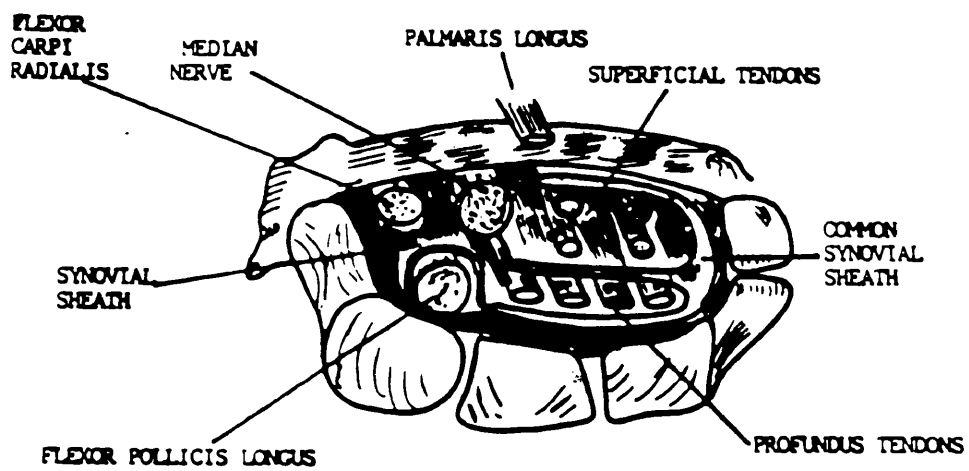


Fig.1.4 TRANSVERSE SECTION OF THE LEFT CARPAL TUNNEL.



the anterior part of the lunate and distally the capitate and trapezoid.

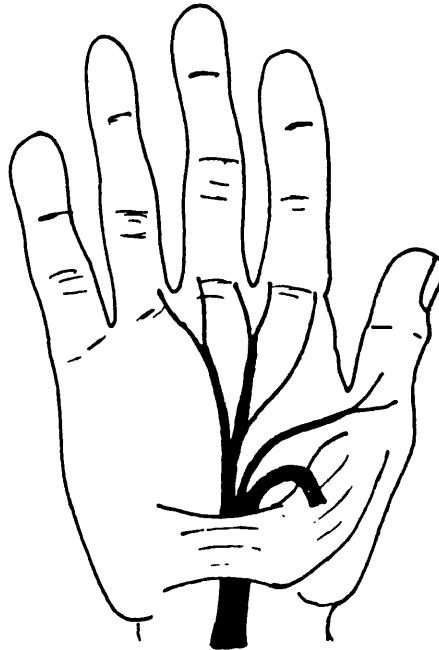
6) the volume of the canal decreases significantly in palmar flexion and extension.

THE MEDIAN NERVE

The most important and vulnerable structure within the carpal canal is the median nerve. This nerve is derived from C6, C7, C8 and T1 nerve roots, the main trunk being formed by the union of two heads from the outer and inner cords of the brachial plexus. At the wrist, just proximal to the flexor retinaculum, the median nerve gives off a palmar cutaneous branch which supplies more than half the thenar side of the palm. Division of this branch during carpal tunnel decompression can result in the formation of a troublesome neuroma (see operative treatment). Within the carpal tunnel the median nerve divides to enter the hand as a lateral and medial branch. The lateral muscular branch supplies the thenar muscles :- abductor brevis, flexor brevis and opponens pollicis, after curving round the distal border of the flexor retinaculum. This lateral branch then terminates as three palmar digital branches, two to the thumb and one to the index finger. The latter also supplies the first lumbrical. The medial branch gives off two palmar digital nerves for adjacent sides of second and third clefts.

Fig.1.5 REGULAR BRANCHING OF THE MEDIAN NERVE.

(Extraligamentous)



The branch to the second cleft also supplies the second lumbrical. The digital branches supply the nail beds and flexor skin of the radial three and a half digits.

The median nerve is a peripheral nerve with sensory, motor and sympathetic fibres surrounded by three consecutive tissue coats which provide protection from externally applied forces. This is of particular importance in the carpal tunnel. Loose areolar connective tissue separates fasciculi and provides a major cushion against compression. The perineurium is a dense sheet of fibrous tissue which invests each fasciculus. It consists of a multilayered network of collagen and elastic fibres. Its elasticity protects

individual fibres during stretching and acts as a diffusion barrier to maintain the intrafascicular pressure. The connective tissue within the fasciculus, the endoneurium, forms a thin membranous tube around each fibre.

ANOMALIES OF THE MEDIAN NERVE AT THE WRIST.

The anatomical variations of the median nerve in the carpal tunnel were studied by Lanz (1972). He bases his conclusions on analysis of 246 hands explored at operation and on the data of other published reports. In his personal series Lanz found 29 variations in the course of the median nerve and he classified the variations into four groups:-

I. Variations of the course of the thenar branch.

extraligamentous 46%

subligamentous 31%

transligamentous 23%

II. Accessory branches at the distal carpal tunnel.

III. High division of the median nerve.

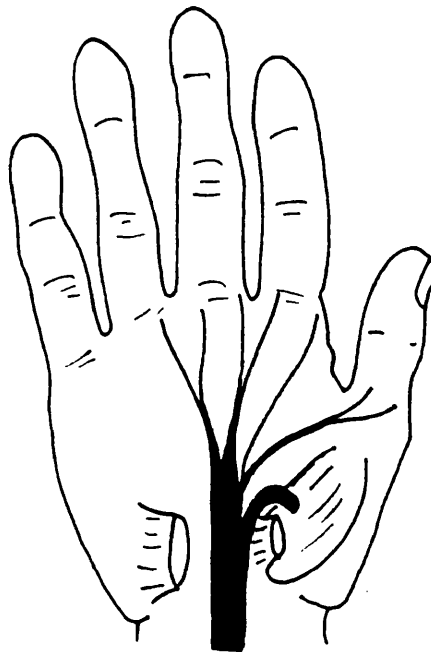
IV. Accessory branches proximal to the carpal tunnel.

The transligamentous course of the thenar branch is of particular clinical importance as the branch may be compressed within the ligament.

Fig.1.6 SUBLIGAMENTOUS (S.) AND TRANSLIGAMENTOUS (T.)

COURSE OF THE MEDIAN NERVE.

S.



T.

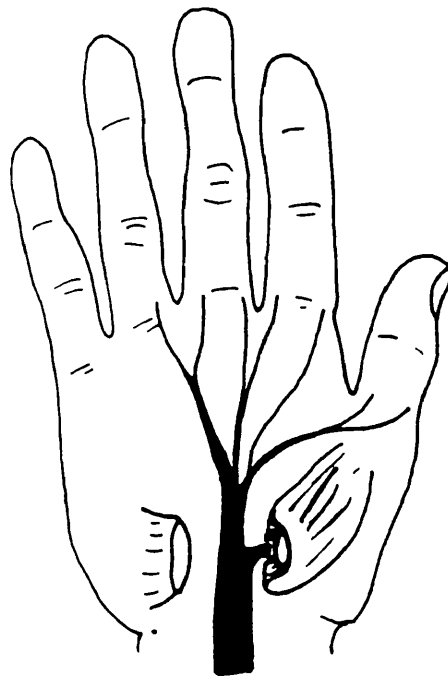


Fig.1.7 ACCESSORY BRANCHES OF THE MEDIAN NERVE AT THE DISTAL CARPAL TUNNEL.

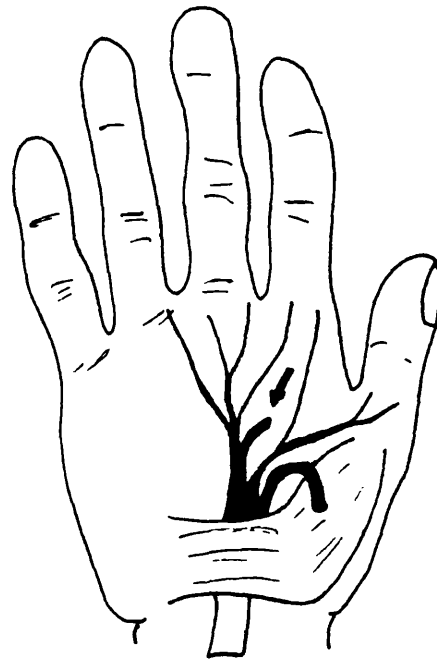


Fig.1.8 HIGH DIVISION OF THE MEDIAN NERVE.

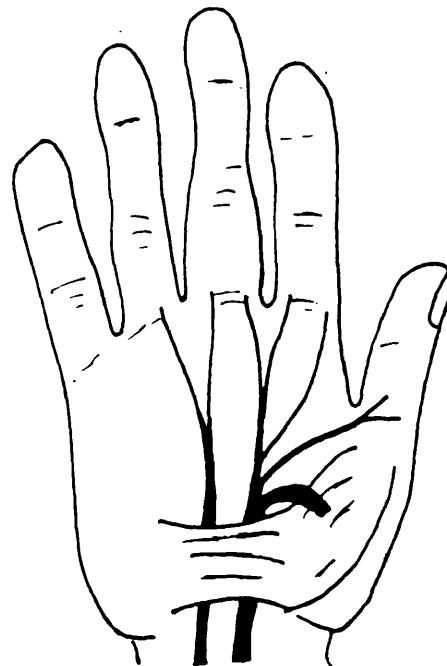
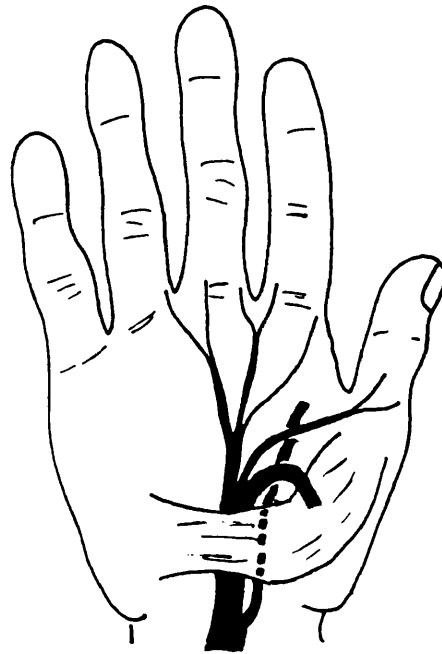


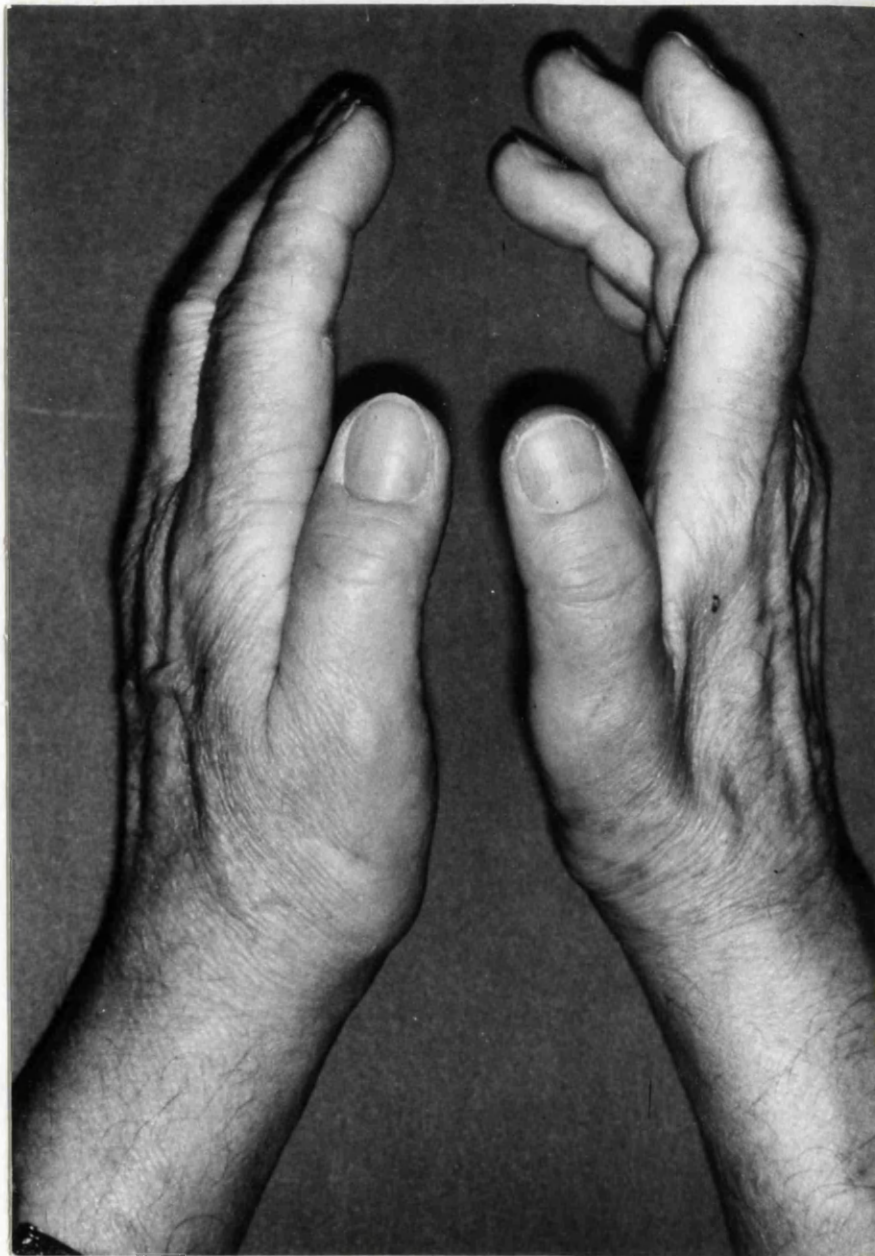Fig1.9 ACCESSORY BRANCHES PROXIMAL TO THE CARPAL TUNNEL.



In rare cases the terminal part of the thenar branch of the median nerve may give a branch to the first dorsal interosseous muscle and may be the sole or part nerve supply of this muscle. (Gray's Anatomy 1980).

Such a case, from the clinical part of this thesis, is illustrated in Fig.1.10. This shows the hands of a 72 year old female with wasting of both the thenar eminence and the first dorsal interosseous muscle on the right. This patient had typical symptoms and signs of carpal tunnel syndrome and also a positive ultrasound test. (See Chapter 7). The diagnosis was confirmed by electromyography which also showed normal conduction in the ulnar nerve.

Fig.1.10 Lateral view of the hands from a patient with right carpal tunnel syndrome showing thenar wasting and wasting of the first dorsal interosseous muscle.



1.3 ANATOMICAL ANOMALIES

There are, on reviewing the literature, relatively few reports of anatomical anomalies causing carpal tunnel syndrome. They can be grouped into those causing an increase in the contents of the carpal canal and those causing a decrease in the size of the tunnel. In the former group aberrant muscle is the main abnormality. Tanzer (1959) in his anatomical study of the carpal tunnel reported one case where abnormal muscle bellies of flexor digitorum sublimis extended almost completely through the canal. In two other cases he describes "an additional muscle at the wrist arising from the antebrachial fascia just proximal to the carpal ligament and extending obliquely to the ulnar side of the hand, to insert deep to the palmaris brevis in the substance of abductor digiti quinti.

An anomalous muscle arising from flexor digitorum sublimis and presenting as carpal tunnel syndrome was reported by Hutton, Kernohan and Birch (1981).

Abnormalities of the lumbrical muscles are well documented and in a case report by Nather and Pho (1981) a literature review revealed five other cases causing carpal tunnel syndrome.

A patent median artery has been reported by Lavey and Pearl (1981) as a cause of median nerve compression at the wrist.

In the second group of congenital anomalies i.e.

reduction of canal size, carpal stenosis has been well described by Dekel, Papaioannou, Rushworth and Coates (1980) who used computerised axial tomography to measure canal size. They concluded that carpal stenosis is an inherited condition which pre-disposes to the development of carpal tunnel syndrome in later life. Hypoplasia of the scaphoid is a very rare cause of median nerve compression but such a case was reported by Radford and Matthewson (1987) who describe a 15 year old boy with carpal tunnel syndrome and hypoplasia of the scaphoid associated with spondylo-epiphiseal dysplasia tarda.

In summary, the normal and abnormal anatomy of the carpal tunnel has been discussed. Anatomical anomalies consist of abnormal muscle, carpal stenosis or the very rare scaphoid hypoplasia. The other causes of carpal tunnel syndrome will be covered in the following section.

1.4 CLINICAL PICTURE AND PATHOGENESIS OF CARPAL TUNNEL SYNDROME

Having outlined the history of the diagnosis of carpal tunnel syndrome it can be seen that the condition is now a well recognised clinical entity which can be summarised as follows:-

A classical case presents with progressive symptoms. An accurate history, as emphasised previously, is perhaps the most important factor in establishing the diagnosis. The group of patients most commonly affected are middle aged females with an initial complaint of paresthesia in the long finger which then extends to the remainder of the median nerve distribution in the hand. Numbness and pain aggravated by prolonged exertion then develops. Frequently the patient is awakened at night with pain in the hand which is relieved by shaking, massaging or hanging the hand out of bed. Discomfort commonly radiates up the forearm. Clinical signs are less valuable in aiding diagnosis and may be very vague in the early stages. In an established case the main objective findings are :-

1. Tenderness on applying direct pressure to the carpal tunnel.
2. Positive Tinel's sign on percussing the carpal tunnel.
3. Positive Phalen's or wrist flexion test.
4. Sensory deficit limited to the median nerve distribution in the hand.

5. Positive tourniquet test (Gilliat and Wilson 1953)
6. Abductor pollicis brevis weakness which may go on to thenar atrophy.
7. Increase in motor and sensory latency of the median nerve at the wrist.

The differential diagnosis of carpal tunnel syndrome includes conditions which may affect the median nerve at several points. Some of these conditions are :-

1. Cervical disc protrusion.
2. Syringomyelia.
3. Cervical rib syndrome.
4. Scalenus anticus syndrome.
5. Ligament of Struthers. *
6. Neuropathies e.g. vitamin deficiencies.

*The Ligament of Struthers is associated with persistence of the lower head of coracobrachialis muscle which in turn is associated with a supratrochlear spur on the antero-medial aspect of the lower humerus. It is connected by a fibrous band (the ligament of Struthers) to the medial epicondyle. Attached to the band are part of the origin of pronator teres and the insertion of the abnormally low fibres of coracobrachialis. Beneath the ligament pass the median nerve and or brachial artery. Pressure on the former may cause a median nerve palsy differentiated from carpal tunnel syndrome by weakness of the forearm flexors and decreased sensibility over the thenar eminence.

PATHOGENESIS

The discrepancy between the volume of the contents of the carpal tunnel and the capacity of the unyielding canal can cause sporadic or persistent compression of the median nerve producing the carpal tunnel syndrome. Although in many cases the mechanisms are understood there are a number of systemic conditions in which the pathogenesis is not clear.

Entin (1968) groups the various aetiological factors as follows:-

A. Reduction of the capacity of the bony canal

1. Tightness of the flexor retinaculum. This is difficult to establish but does occur in productive inflammatory processes such as rheumatoid arthritis and may occur in myxoedema.

2. Encroachment on the canal by callus associated with wrist fractures.

3. Compression of the contents of the canal with extremes of motion of the wrist in either flexion or extension.

4. Acromegaly - attributed to bony changes.

5. Others.

B. Excessive volume of the contents

1. Inflammatory and degenerative conditions:

a. non-specific tenosynovitis

b. rheumatoid

c. gout

- d. synovial ganglia
 - e. amyloid disease
 - f. others
2. Post - traumatic.
- a. osteophytes
 - b. scar formation associated with tendon injury.
 - c. others
3. Neoplastic lesions.
- a. benign tumours
 - b. malignant tumours
4. Others.
- a. myxoedema (infiltration of fibrous tissue may affect the bulk of the flexor tendons)
 - b. haematoma secondary to clotting disorder such as haemophilia (see appendix ii).

C. Conditions associated with median nerve compression.

this group of varied systemic conditions may be associated with carpal tunnel syndrome but the mechanisms are not fully established in all cases.

1. Conditions associated with increase or redistribution of fat and or oedema.
- a. obesity
 - b. pregnancy
 - c. menopause
 - d. myxoedema
 - e. others
2. Neuropathies which render the nerves more

susceptible to compression.

- a. diabetes
- b. multiple myeloma
- c. amyloid
- d. others.

All the above factors have one end result which is the exertion of pressure on the median nerve. Gelberman et al (1981) made a study of the pressures within the carpal canal. They found a significant elevation of the mean pressure in patients with carpal tunnel syndrome. This pressure increased further with the wrist in flexion. Surgical release of the transverse carpal ligament brought about an immediate and sustained reduction in pressure.

Sunderland (1976) considers the consequences of increased pressure on the median nerve in the carpal canal and in particular the structural changes which occur. He favours a vascular mechanism for the resulting nerve lesions.

The funiculi in the median nerve are well separated by large amounts of epineural packing and resist considerable amounts of pressure. The elastic perineurium resists and maintains the intrafunicular pressure. Nutrient vessels, vasa nervorum, take an oblique course as they pass through the perineurium thus introducing a valve mechanism. Within the carpal tunnel there are at least five inter-related pressure systems.

- | | |
|---|-------|
| 1. pressure in nutrient artery in the perineurium | P^A |
| 2. intra-funicular pressure | P^F |
| 3. pressure in veins draining funiculi | P^V |
| 4. capillary pressure in funiculi | P^C |
| 5. carpal canal pressure | P^T |

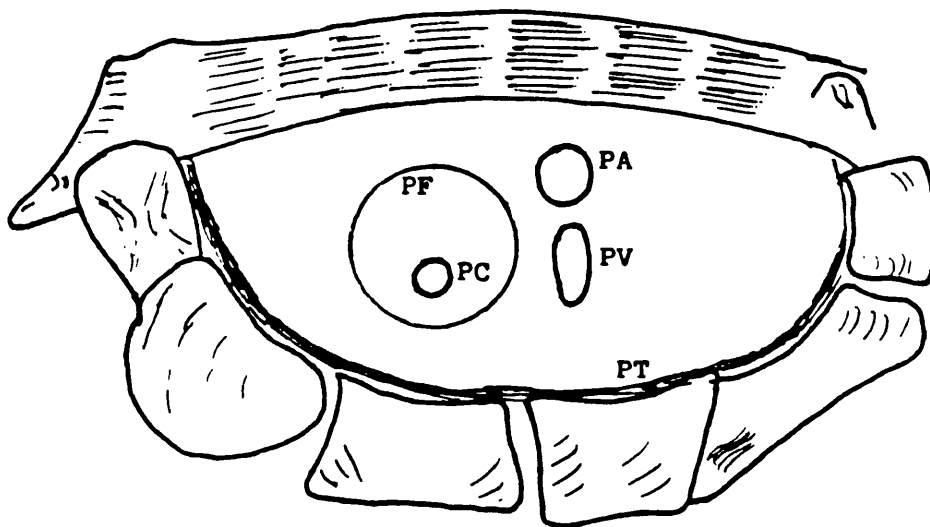


Fig. 1.11 PRESSURE RELATIONS BETWEEN THE COMPONENTS OF THE MEDIAN NERVE IN THE CARPAL TUNNEL - AFTER SUNDERLAND (1976).

The arteriolar pressure (P^A) must be higher than the pressure within the carpal tunnel (P^T) to maintain adequate intra-funicular circulation. Should the pressure (P^T) rise the epineurium would protect the funiculi in the early stages - except in cases of acute pressure increase such as would occur with traumatic dislocation of the lunate. Where the pressure increase is gradual the venous channels are the first to suffer, resulting in hyperaemia and circulatory slowing in the epineural and intra-funicular tissues. These changes eventually lead to pathological changes in the median nerve:-

1. impairment of the nutrition of funiculi leading to hyper-excitability; spontaneous fibre activity gives rise to pain (Melzack and Wall 1965).
2. hypoxia damages the capillary endothelium leading to protein leakage and oedema. Intrafunicular oedema is responsible for the enlargement of the nerve at the margins of the retinaculum.
3. long-standing pressure leads to more permanent changes in the nerve. Fibroblasts proliferate in the protein exudate and increasing numbers of nerve fibres become destroyed and fibrosed.

It would seem that these mechanisms adequately explain the lesion in chronic compression of the median nerve. Gilliat (1974) presents the counter-argument for a direct mechanical mechanism of nerve damage as a continuous sequence of changes with increasing

compression on the nerve. Initially there is a bulbous para - nodal swelling leading to superficial demyelination and finally telescoping of the nodal region with Wallerian degeneration of the nerve fibres. Sunderland (1976) however, convincingly discounts these theories.

The preceding sections have attempted to give a detailed patho - physiological description of carpal tunnel syndrome together with an account of the relevant anatomy.

1.5 SURGICAL MANAGEMENT OF CARPAL TUNNEL SYNDROME

Decompression of the median nerve at the wrist is a common surgical procedure, generally regarded as a simple minor operation. However, unless performed carefully with due consideration for the possible hazards, the complications of surgery may well cause disability worse than the original complaint.

Approximately 60% of cases of carpal tunnel syndrome are managed conservatively, the indications being:-

1. mild symptoms in the absence of abnormal motor signs.
2. in pregnancy where the compression is expected to subside post-partum.
3. in cases of acute or sub-acute tissue inflammation e.g. after Colles' fracture.
4. where the syndrome is precipitated by unusual manual labour.

Gelberman, Aronson and Weisman (1980), reviewed fifty hands in patients with carpal tunnel syndrome who had been managed conservatively with splints or steroid injection. They concluded that patients with mild symptoms, normal sensibility and normal thenar muscle function with a 1-2 ms. prolongation of motor or sensory latency responded well to conservative measures.

Patients with severe symptoms of over a year's duration associated with thenar atrophy and distal sensory or

motor latency of over 6ms. responded poorly to conservative management and showed a high relapse rate. Therefore about 40% of cases will come to surgical management.

Not all of these cases will have pre-operative nerve conduction studies and indeed the literature is not in agreement as to the usefulness of this investigation. Harris et al (1979) feel that nerve conduction studies provide valuable prognostic information but admit that the classic symptoms of the syndrome may be present in the presence of a normal EMG, particularly in the rheumatoid patient. Phalen (1972) felt that there was no place for nerve conduction studies.

It is, however, important in the doubtful case to confirm the diagnosis by EMG studies whenever possible.

ANAESTHESIA

Carpal tunnel decompression is a short procedure and the method of anaesthesia must be tailored accordingly.

A general anaesthetic is indicated when the patient is very anxious or requests this method and there are no medical contra-indications. In other cases regional anaesthesia, of which there are several techniques available, is used.

Supra-clavicular or brachial plexus blocks have the disadvantage of uncertain anaesthesia (not all dermatomes are included in some cases) and they can take some time to become effective. There is also a risk of

pneumothorax.

Bier's block gives good regional anaesthesia but the operative field is usually rather oedematous. Regional anaesthesia with bupivacaine has been shown to cause some impairment of cerebral function for several hours post-operatively. (Kortilla, Hakkinen and Linnoila 1975).

Nerve block can also be complicated by neuritis and so it is probably best to avoid this method in patients dependant on fine hand movements for their work.

Local anaesthetic block at the wrist by infiltration of 2% Lignocaine has the advantage of good, safe anaesthesia with virtually no side effects, allowing Day Surgery management of patients with early post-operative discharge. The technique can be performed rapidly and the only disadvantages are some discomfort from the pneumatic tourniquet and a rather boggy operative field. The lignocaine is injected subcutaneously in a "T" shaped fashion across the distal wrist crease and the line of the skin incision but not into the carpal tunnel itself. Whichever method is used a good pneumatic tourniquet around the upper arm is essential.

SURGICAL ANATOMY

One of the most important stages of carpal tunnel decompression is the siting of the skin incision. This must be made with due consideration of the underlying anatomy and its possible variants. The two most

vulnerable structures (apart from the median nerve itself) are the recurrent motor branch and the palmar cutaneous branch of the median nerve. Division of the latter can lead to the formation of a painful neuroma. A review of some of the major surgical texts has shown a marked variation in the recommended position of the skin incision. A brief summary of these is listed below:-

CAMPBELL'S OPERATIVE ORTHOPAEDICS Ed. A.H. Crenshaw,
7th Edn. Vol.I 1987.

Curved incision ulnar to and parallel to the thenar crease - avoiding the palmar branch of the median nerve between palmaris longus and flexor carpi radialis.

(Fig.1.12A.)

SURGERY OF THE MUSCULOSKELETAL SYSTEM. Ed. C McCollister
Evarts. Vol.I 1983.

An incision on the line that bisects the projection of the ring ray should overly the junction of the median and ulnar nerve territories in most instances.(Fig.1.12B.)

OPERATIVE HAND SURGERY Ed. David P.Green 1982

At the base of the palm the incision should be ulnar to the axis of the ring finger. Dissection should be on the ulnar side of the nerve. (Fig. 1.12C.)

Advise incision on ulnar or radial side of palm as shown in Fig.1.12D. The ligament is divided under direct vision and a strip of retinaculum is excised.

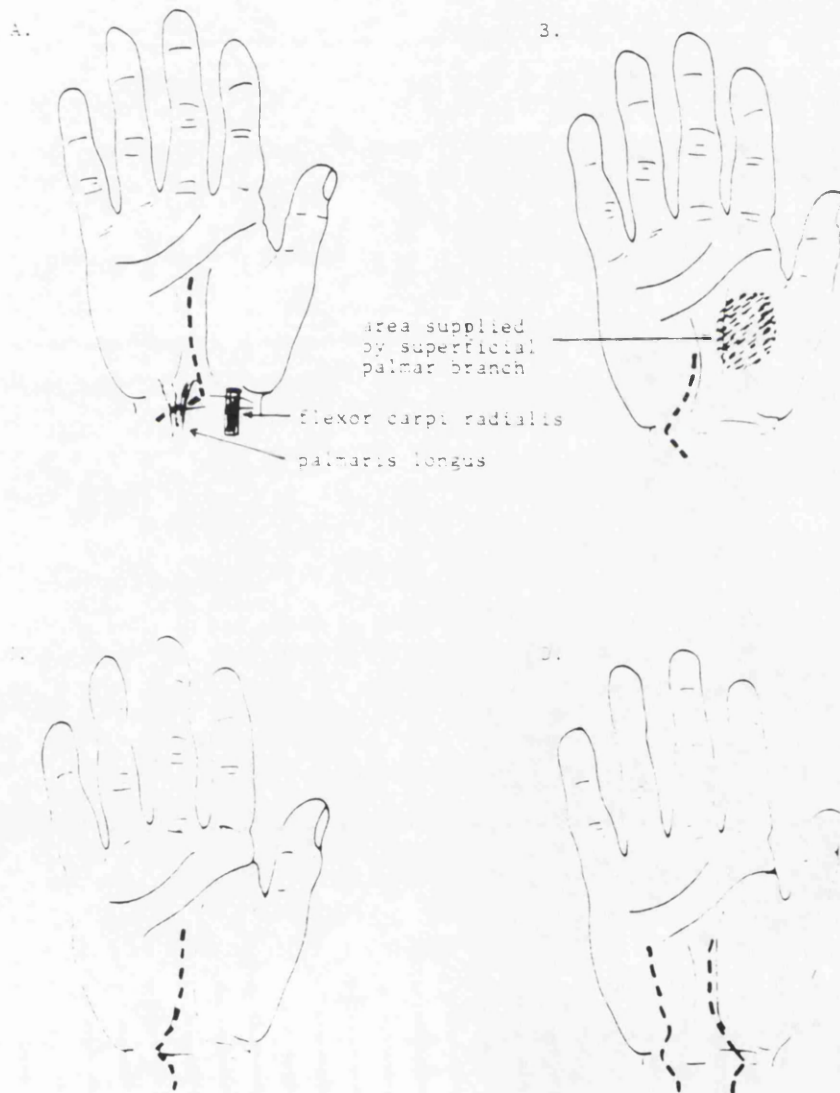


Fig.1.12 SKIN INCISIONS FOR CARPAL TUNNEL DECOMPRESSION

ROB AND SMITH'S OPERATIVE SURGERY - THE HAND Ed. Guy
Pulvertaft. 3rd. Edn. 1977.

A 4-5 cm. incision commencing in the thenar crease just proximal to the level of the superficial palmar arch and crossing the wrist crease to make a slight medial curve. (Fig.1.12E.)

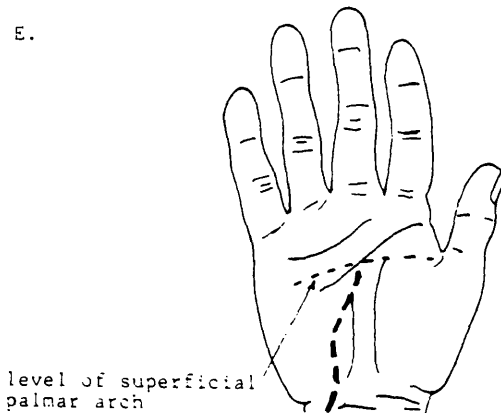


Fig.1.12 Cont.

It can be seen that even in this limited survey, there is a marked variation in the positioning of the skin incision.

Taleisnik (1973) made an anatomical study of the palmar cutaneous branch of the median nerve and the approach to the carpal tunnel by dissecting twelve cadaver hands. He concluded that to avoid injury to the nerve a curved longitudinal incision should be made, localised to the ulnar side of the axis of the ring finger ray. The incision should extend through skin, subcutaneous tissue and the flexor retinaculum. Elevation of a radial flap,

keeping all three tissue layers intact, further protects the cutaneous branch. The motor branch of the median nerve should also be avoided during carpal tunnel decompression by keeping the incision to the ulnar side of the thenar crease.

The anatomical variations of the median nerve in the carpal tunnel have been outlined in Chapter 1.2.

TECHNIQUE OF CARPAL TUNNEL DECOMPRESSION.

The patient must be suitably prepared for surgery and an appropriate anaesthetic is administered. A good pneumatic tourniquet is applied after elevation of the limb for several minutes. The arm and hand is prepared and draped and placed on an arm board with a small rolled-up towel or kidney dish placed beneath the wrist. A lead hand is used to keep the digits extended. The author favours a longitudinal skin incision in line with the ring finger extending from just proximal to the level of the superficial palmar arch to the distal wrist crease. (Fig.1.12F).

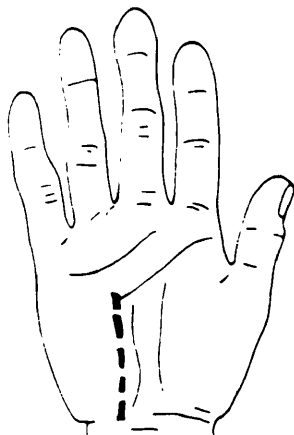


Fig.1.12 Cont.

Subcutaneous fat is retracted with small rake retractors, the superficial palmar fascia is divided and once the flexor retinaculum is seen a small longitudinal incision is made and a McDonald's dissector is gently introduced beneath the ligament. This structure is then divided distally and proximally, under direct vision, using the dissector to protect the nerve. The nerve and carpal tunnel are inspected for any other pathology and any bleeding points are coagulated with bi-polar diathermy. The wound is closed with interrupted 4-0 nylon skin sutures and a gauze, wool and crepe dressing is carefully applied. The tourniquet is then released and the limb is elevated for about thirty minutes post-operatively.

The patient is instructed to reduce the dressing at twenty four hours and to mobilise the hand gently. Sutures are removed at two weeks.

OTHER SURGICAL PROCEDURES.

1. EXTERNAL NEUROLYSIS. - This is indicated if the median nerve is adherent to the deep surface of the flexor retinaculum or adjacent tendons or if the nerve is constricted by fascia. The nerve trunk is carefully separated from surrounding scar tissue by simple dissection starting in normal tissue above or below the scarred area. Branches such as the motor and palmar cutaneous should be identified and carefully preserved as they can easily be damaged in the dissection.

Sunderland (1978) advocates the use of a nerve stimulator during dissection for the following reasons. If an evoked potential can be detected distally before dissection it infers that immature regenerating axons have reached the periphery and spontaneous recovery is likely. These immature axons are sensitive to mechanical deformation during surgery. Intact branches from the proximal nerve are often buried in scar tissue and repeated stimulation during surgery will facilitate their detection.

It is important to avoid grasping the median nerve itself. The flexor tendons should be retracted to allow inspection of the floor of the carpal tunnel. The blood supply to the nerve trunk should be preserved and haemostasis secured with bi-polar diathermy to avoid re-formation of scar tissue. Dissection of the recurrent thenar motor branch is not recommended by Lamb and Kuczynski (1981) and Conolly (1984) as they feel that it may be damaged in the process.

Synovectomy may be indicated if there is gross hypertrophy e.g. in rheumatoid arthritis.

Some advocate the instillation of steroids into the wound to prevent recurrence. How effective is external neurolysis? Brown (1970) reviewed 272 upper extremity nerve injuries, mostly combat related, over a three year period and concluded that external neurolysis was a rewarding procedure. Out of 24 procedures in the median nerve in the forearm 85% showed some return of function

and 15% showed no recovery. Sunderland (1978) points out that when a nerve in continuity is freed from scar tissue recovery is naturally attributed to surgery. However, recovery with or without surgery is a random process determined by factors such as rate of axon advance, distance over which axons regenerate and order in which structures are re-innervated. It is therefore impossible to conclude that improvements following neurolysis are due to surgery and not normal regenerative processes that would in any event have resulted in recovery.

2. INTERNAL NEUROLYSIS. This is a delicate microsurgical procedure and the indications for this technique are-

- i. motor and or sensory loss caused by interruption of nerve conduction e.g. palsy of abductor pollicis brevis.
- ii. constant pain and loss of sensibility.
- iii. operative findings of:-

- a) hour glass constriction of the median nerve.
- b) gross thickening of the epineurium.
- c) palpable induration.
- d) obliteration of the median artery.
- e) true neuroma in continuity of the median nerve.

However, there is some debate in the literature as to the value of this delicate procedure.

Curtiss and Eversman (1973) first popularised the

technique and claimed improved results in patients with constant sensory loss, thenar atrophy or both. Out of 96 operations less than 10% of cases had a poor result.

Lowry and Follender (1988) carried out a randomised double blind controlled study of 50 patients with severe carpal tunnel syndrome. (Thenar atrophy and or fixed sensory deficit.)

Twenty five cases had a standard carpal tunnel decompression and twenty five had interfascicular neurolysis in addition. No significant difference was found between the groups and the majority of cases in both groups showed an improvement in their clinical condition. It would therefore seem that there is little to be gained from this time consuming and demanding procedure.

3. RECONSTRUCTION OF THE FLEXOR RETINACULUM. This structure has four functions:-

- a. maintains the transverse carpal arch.
- b. supports the carpus.
- c. protects the median nerve.
- d. acts as a pulley for the flexor tendons.

Although the flexor retinaculum heals by the formation of fibrous tissue following carpal tunnel decompression some surgeons advocate reconstruction of this structure. This may be achieved by developing fascial flaps with a distal base on one side and a proximal base on the other. These are then sutured side by side across the

tunnel. The result is a new ligament approximately 2cms. wide with an adequate clearance for the contents of the carpal canal. (Kilgore and Graham 1977). In a review of 186 operative cases of carpal tunnel release MacDonald and Lichtman (1978) reported two cases of bowstringing of the flexor tendons (an incidence of 1.08%). The ligament was reconstructed using a free palmaris longus tendon graft. In practical terms the functional consequence of division of the flexor retinaculum is a slight impairment of power grip to loss of the transverse palmar arch. Patients should be warned about this weakness but they very rarely notice any deficit.

OPPONENSPLASTY.

In severe carpal tunnel syndrome with thenar wasting there may be no recovery in motor function following decompression. The resultant loss of opposition can be a significant disability. Opposition is a complex of two motions:-

- i. rotation of the thumb into pronation so that the pulp surfaces of the thumb and index finger face one another.
- ii. abduction or lifting of the thumb away from the palm of the hand (palmar abduction). The Royle-Thompson opponensplasty is the most frequently used procedure using the tendon of flexor digitorum superficialis of the ring or middle finger as a motor unit. Royle did not use a pulley and simply passed the motor unit up the

sheath of flexor pollicis longus. Thompson (1942) modified the operation by constructing a pulley from the distal end of the transverse carpal ligament. The distal attachment of the tendon is via a small drill hole in the neck of the first metacarpal and a slip is attached to extensor hood over the proximal phalanx. Swan neck deformities may occur after removal of flexor digitorum superficialis from the ring finger.

A much simpler procedure was described by Camitz (1929) using palmaris longus as the motor unit. The tendon is transferred to that of abductor pollicis brevis, the extra length required being provided by a strip of palmar fascia. Although there are several other methods of opponensplasty these two are the most widely used.

COMPLICATIONS OF CARPAL TUNNEL DECOMPRESSION

An awareness of possible complications of carpal tunnel surgery is essential to reduce morbidity from this deceptively simple procedure.

1. INTRA-OPERATIVE.

a. iatrogenic injury to the median nerve trunk, palmar branch, recurrent thenar branch or digital branches.

b. inadequate carpal tunnel decompression from incomplete division of the flexor retinaculum.

These problems can be avoided by careful surgical technique and ensuring that the ligament is divided under direct vision with due consideration of the anatomy of the region and its variants.

2. POST-OPERATIVE.

a. Early.

- Haematoma: use bipolar diathermy to coagulate bleeding points and elevate the limb post-operatively, the use of a drain is debatable.

- Oedema: caused by lack of early mobilisation or dressings which are too tight.

- Wound infection: avoid by strict aseptic technique.

- Wound dehiscence: careful suture technique with apposition of wound edges should obviate this problem. Splintage of the wrist for up to two weeks is employed by American surgeons.

- Bowstringing of flexor tendons this complication is mentioned by Blair (1988) and MacDonald and Lichtman (1978). It is said to be avoided by splinting the wrist for ten to fourteen days.

b. LATE COMPLICATIONS.

- Weakness of grip: this is very common and patients should be warned against this before surgery.

- Stiffness of fingers, wrist and shoulder: should be avoided by encouraging appropriate post-operative exercises.

- Scar hypertrophy and contracture: some patients are pre-disposed to develop hypertrophic and keloid scars. Contractures are usually caused by incisions which cross skin creases at right angles.

- Recurrent carpal tunnel syndrome: results from fibrosis around the median nerve or hyperplasia of

synovium. The former may be caused by excessive dissection around the median nerve. Steroid instilled into the wound at operation may help to avoid the problem but should not be used as a routine.

- Reflex Sympathetic Dystrophy. (RSD). - an abnormal reaction to injury characterised by pain, swelling, stiffness, vasomotor changes and osteoporosis of the bone of the affected part.

REFLEX SYMPATHETIC DYSTROPHY.

Causalgia was first described by Mitchell in 1864 as "intractable burning pain" following an injury to a peripheral nerve. He studied mainly gunshot wounds which were frequently associated with arterial injuries.

Homans (1960) described the syndrome of "minor causalgia" - a spontaneous burning pain following trauma to the upper extremity. He suggested that reflex arterial spasm due to vascular injury was the cause of the condition.

This syndrome has several descriptions including :- dysaesthesia, shoulder-hand syndrome, Sudeck's Atrophy, Algodystrophy and chronic traumatic oedema. The most frequently used term is Reflex Sympathetic Dystrophy (RSD).

The disorder has the same incidence in adult men and women and is now increasingly recognised in children (Lightman et al 1987). As mentioned earlier RSD is an

abnormal reaction to injury characterised by pain, swelling, stiffness, vasomotor changes, skin atrophy and osteoporosis of the bone in the affected region. There are three main factors which are believed to be important in the development of RSD:-

1. a painful lesion (trauma operative procedures, thrombophlebitis, osteomyelitis, septic arthritis.)
2. a predisposition to develop the disorder.
3. an abnormal sympathetic reflex. Schutzer and Gossling (1984) support the theory that RSD is associated with an abnormal vasomotor response to injury mediated by the sympathetic nervous system.

Drucker et al (1959) describe three stages of the disease:-

I. ACUTE. Pain either immediate or within a few weeks of injury - a constant aching or burning pain which is disproportionate to the injury. Oedema, increased hair and nail growth, hypothermia and hyperhidrosis may be present. Radiographic changes occur at one to two months.

II. DYSTROPHIC. By three months the oedematous tissue becomes indurated and the skin is cool, pale and occasionally cyanotic. The nails are brittle. Pain is continuous and radiographs reveal diffuse osteoporosis.

III. ATROPHIC. The pain spreads proximally and is associated with irreversible tissue changes. The skin and fingertips are wasted and fixed joint contractures are common. Radiographs show marked bone

demineralisation and ankylosis.

The condition is best treated early - well before stage III. Diagnosis is usually clinical by the recognition of the combination of pain which is out of proportion to the initial injury, swelling and stiffness accompanied by changes in skin colouration. Radiographs show soft tissue swelling and osteoporosis after about a month with a characteristic peri-articular distribution. Subtle subperiosteal resorption simulates changes of primary hyperparathyroidism. Surface erosion of subchondral and juxta-articular bone produce a picture resembling erosive arthropathy (Fahr and Sauser 1988). Isotope bone scans show increased uptake around the joints in most cases (Kosin et al 1981).

Liquid crystal thermography is also useful as an aid to diagnosis as it shows a "glove and stocking" alteration in the thermal pattern (Lightman et al 1987).

Treatment is directed at the aetiological factors and depends on the severity and degree of functional incapacity of the patient. Early recognition and therapy is the key to success. Gentle mobilisation is encouraged and a programme of physiotherapy is commenced to include heat, ice packs and deep friction massage. Splints should be used to prevent contractures. Effective pain relief is important. Simple analgesics may be used and trigger points should be injected with a long acting local anaesthetic. (bupivacaine 0.5%). Transcutaneous electrical nerve stimulation (TENS) may be of benefit in

some cases. Drug treatment, apart from analgesics, may include the use of corticosteroids, sympatholytic drugs such as the α -blocking agent phenoxybenzamine or the anti-epileptic drug carbamazepine (Tegretol). As there is a strong psychological component to the condition of RSD some advocate the use of anti-depressants.

When the above measures do not appear to be effective sympathetic blockade should be considered, the rationale being the interruption of the abnormal reflex mediated by the central nervous system. A stellate ganglion block is generally performed using 0.25% bupivacaine hydrochloride. A technically successful block is manifested by the appearance of a profound Horner's syndrome, rapid relief of pain and a cool, dry hand. Gentle physiotherapy should be commenced to increase the range of joint movement. Current practice is to limit the number of blocks to three or four and then to consider surgery if the patient has demonstrated a clinical response albeit short lived. However, Long (1980) has shown that surgical sympathectomy in RSD has only a limited success with less than 50% of patients obtaining permanent relief of their symptoms.

- Painful scar.

This is a common complication reported in a review of complications of carpal tunnel decompression by Das and Brown (1976) and Cseuz et al (1966). Discomfort lasting more than six months post-operatively requires further

treatment and Das and Brown (1976) found that injection of bupivacaine and steroid into the scar was beneficial. An increased risk of post-operative complications was noted by Nissenbaum (1980) in patients with carpal tunnel syndrome and co-existent Dupuytren's disease. These patients had an increased incidence of recurrent Dupuytren's and reflex sympathetic dystrophy.

The main points to be made from the above account are:-

Langloh and Linscheid (1972) state that incomplete division of the flexor retinaculum is the commonest cause of failure of carpal tunnel decompression.

Weakness of grip is also a very common complication and Garstman et al (1986) advise that all manual workers should be warned about this problem.

In a review of long term results of operation for carpal tunnel syndrome Cseuz et al (1966) found that in many cases the scar was sensitive for years after surgery. Taleisnik (1973) emphasises the importance of avoiding the palmar cutaneous branch of the median nerve in siting the skin incision to avoid a troublesome neuroma. Bowstringing of flexor tendons is an uncommon complication. Reflex sympathetic dystrophy is perhaps underestimated as a complication and the surgeon should always be aware of this potential problem.

It can be seen that a procedure which is usually regarded as simple and straightforward carries with it

the risk of significant morbidity. Careful attention to the position of the skin incision and surgical technique will avoid many of the potential hazards.

CHAPTER 2

PERIPHERAL NERVE CONDUCTION STUDIES

The carpal tunnel syndrome was the first of the entrapment neuropathies to be studied by nerve conduction velocity methods (Simpson 1956) and this technique is to date the only method of confirming the diagnosis.

Motor conduction is measured by stimulating the median nerve at the wrist and recording evoked potentials from the thenar muscles either with surface electrodes or with a concentric needle. Normal latency at the wrist is 2-4 m.secs. and a latency greater than 4.5 m.secs. is suggestive of median nerve compression in the carpal tunnel. The thenar compound muscle action potential is also reduced. This may be associated with some slowing of the motor conduction velocity in the forearm with fibrillation potentials in the abductor pollicis brevis muscle. More proximal slowing of nerve conduction may also be associated with compression at the pronator teres muscle. (see page 41).

In some cases there may be anomalous innervation of the thenar muscles from the ulnar nerve. An abnormal communication between the median and ulnar nerves in the upper forearm - the Martin Gruber Anastomosis - occurs in 15% of people (Mannerfelt 1966). When present there will be a higher amplitude of response on elbow

stimulation than on wrist stimulation.

Early or mild compression of the median nerve in the carpal tunnel may not be associated with conduction abnormalities but more than 90% of symptomatic patients have localised slowing of conduction in sensory fibres. Thomas, Lambert and Cseuz (1967), Buchthal and Rosenfalck (1971.) This sensory latency through the carpal tunnel is measured by stimulating the digital nerve of the index finger whilst recording at the wrist and is the most sensitive method of confirming an abnormality. The values recorded are compared with the latency in ulnar sensory fibres over the same distance to exclude a more generalised neuropathy. The opposite wrist cannot be used as a reliable control as patients with unilateral symptoms often have bilateral abnormalities on conduction studies. Bendler, Greenspan, Yu and Erdman (1977) found in a series of 440 electrodiagnostic records that 269 (61%) had bilateral involvement but only 28% complained of unilateral symptoms.

Despite the diagnostic features of nerve conduction studies, normal results may be found in patients with classical symptoms and signs of carpal tunnel syndrome. These patients, however, are often relieved of their symptoms following surgical treatment.

Grunberg (1983) reviewed 33 patients who despite normal E.M.G. results had a carpal tunnel decompression performed on clinical grounds, and concluded that E.M.G.

was not a very sensitive indicator of carpal tunnel syndrome with an 8% incidence of false negative results. A comparison was made between nerve conduction studies and operative treatment of carpal tunnel syndrome by Harris, Tanner, Goldstein and Petee (1979). They noted that patients with motor abnormalities had a more favourable result than those with only sensory abnormalities. It was also found that the duration of the symptoms pre-operatively did not significantly influence the results of surgery. (This contradicts Phalen (1979) who maintained that prolonged symptoms constitute a bad prognostic sign). They pointed out that the classic symptoms of the syndrome in patients can be present in the presence of normal nerve conduction studies and that this was particularly true in rheumatoid patients. Another comparative study of nerve conduction tests was carried out by Spindler and Dellon (1982) who investigated 43 patients with a classical history of carpal tunnel syndrome, both by conduction studies and sensibility testing i.e. vibration and two point discrimination perception tests. They found some patients with classic carpal tunnel syndrome and normal conduction studies. Also some had significant abnormality in one test whilst the other test was normal. The conclusion was that conduction studies are more sensitive in confirming the diagnosis but a combination with sensibility tests gives an even more sensitive test.

It would seem that as nerve conduction studies are only 90% accurate in confirming the diagnosis of carpal tunnel syndrome and that other tests of median nerve dysfunction in the hand serve to augment the diagnosis, there is scope for another technique to clarify the clinical picture.

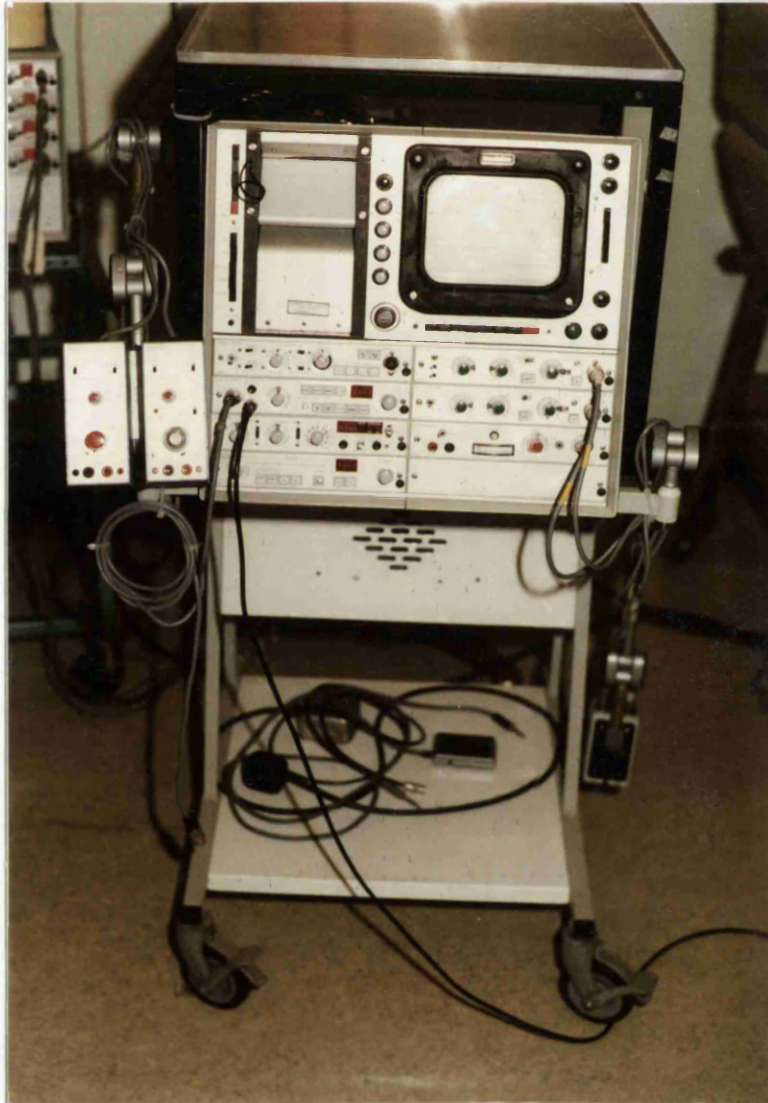


Fig. 2.1 TYPICAL EMG EQUIPMENT.

CHAPTER 3

THEORY OF ULTRASOUND

3.1 FUNDAMENTALS OF ULTRASOUND.

Ultrasound can be defined as a form of wave motion, similar in nature to audible sound but at a higher frequency and therefore not detectable by the human ear. The audible frequency range extends from about 20 Hz to 20,000 Hz but the upper limit decreases with advancing age. In clinical practice the frequencies of ultrasound used are between 1 and 3 MHz.

The energy of ultrasound is transmitted by the vibration of the molecules of the medium through which the wave is travelling. i.e. gas, solid or liquid.

Ultrasound is generated by the use of the piezo-electric effect. If pressure is applied to a crystal such as quartz, electric charges develop on the outer surface of the material. This effect is reversible so that if an alternating current is applied to a crystal it will undergo changes in shape at the same frequency as the alternating electric field. This will cause the crystal to vibrate and the vibration will be transmitted to the molecules of the medium to which the crystal is applied. In ultrasound therapy units the crystal used is a polycrystalline material lead zirconate titanate (PZT). This material has the advantage that only a small voltage is required to induce the acoustic energy and it

is also less sensitive to mechanical shocks. A basic ultrasound therapy unit consists of a high frequency oscillator which acts via an amplifier on the crystal in the treatment head. The resonant frequency of the crystal is partly determined by the thickness of the piezo - electric material (PZT) and this will affect the frequency of the ultrasound generated. Because of this the ultrasound generator and treatment head must be carefully adjusted to produce the correct output. (Hoogland 1986).

In order to understand the basics of ultrasound some terms will now be defined:-

WAVELENGTH

The distance in which a wave motion repeats itself. The ultrasound wave is longitudinal in nature i.e. direction of propagation is the same as the direction of oscillation and causes compression and expansion of the medium through which it travels at half a wavelength's distance. (figs. 3.1 and 3.2).

FREQUENCY

The number of times a complete wave motion occurs in one second.

i.e. cycles per second or HERZ (Hz) (fig. 3.2).

AMPLITUDE

A term used to describe the magnitude of disturbance in a wave. (Fig. 3.2).

Fig. 3.1 Ultrasound waves - a vibrating crystal (PZT) generates waves of pressure and rarefaction. Molecules are displaced backward and forward along the line of travel.

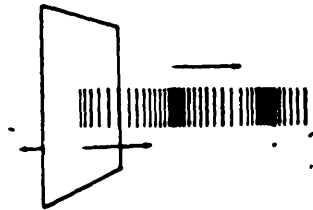
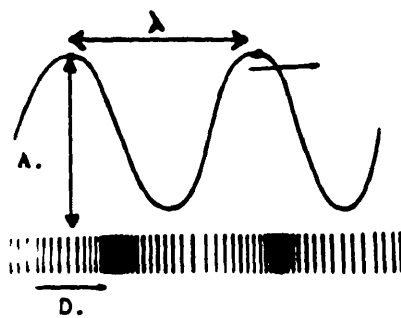


Fig. 3.2 = wavelength i.e. one cycle
A = amplitude
D = direction of propagation



An ultrasonic wave can either be described in terms of the movement of the particles of the medium through which it travels. (Amplitude expressed in units of distance cms. or m.) or in terms of the pressure variation found along the path of the wave. (Amplitude expressed in units of pressure Newtons / metre²)

INTENSITY

As ultrasound passes through a medium the component particles of the medium begin to vibrate at the frequency of the propagated waveform and therefore acquire kinetic energy. Intensity is a measure of this energy and is defined as the amount of energy crossing unit area in unit time. The SI units for intensity are watts per metre² but it is convention in medical ultrasound to express intensity in watts / cm.²

SPACE AVERAGED INTENSITY

The intensity of the ultrasound beam averaged over a specific area - usually the transducer face.

TIME AVERAGED INTENSITY

Important only for pulsed treatment i.e. it is clear that half as much energy will be delivered to the tissue if the ultrasound is pulsed 1:1.

POWER

Total energy in the ultrasound beam measured in watts.

EFFECTIVE RADIATING AREA

The ERA is important in determining intensity. As the piezo-electric transducer does not vibrate uniformly the ERA is always smaller than the geometric area of the treatment head. ERA should therefore always be measured and specified. (fig.3.3).

Properties of the Ultrasound Beam.

There are two distinct areas in the ultrasound beam (fig. 3.4)

- the near field or Fresnel zone.
- the distant field or Fraunhofer zone.

Each have specific characteristics:-

Fresnel Zone

- interference phenomena in the ultrasound beam which may lead to marked variation in intensity.
- absence of divergence, in fact there is slight convergence of the ultrasound beam.

Fraunhofer Zone

- near absence of interference phenomena resulting in a near uniform sound beam with gradually decreasing intensity as distance from the transducer increases.
- the ultrasound beam has a larger diameter.
- a wider spread of the sound energy due to both the divergence and the fact that the intensity distribution perpendicular to the longitudinal axis of the sound beam becomes increasingly bell shaped.

The length of the near field depends upon the diameter

of the treatment head and the wavelength of the ultrasound. A head of 1 cm.^2 diameter will have a near field of about 2 cms. at 1 MHz.

Fig. 3.3 Ultrasound treatment head showing geometric area (A) and effective radiating area (ERA).

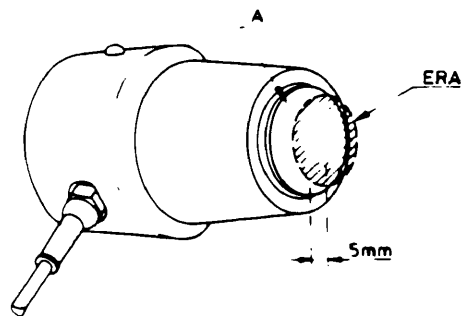
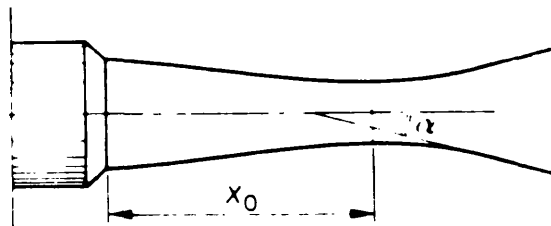


Fig. 3.4 Ultrasound beam profile.

x_0 - near field or Fresnel Zone.

α - angle of divergence of beam.



At 3 MHz. the near field is three times as long because the wavelength is proportionally shorter. Therapeutic effects of ultrasound occur mainly in the near field. Interference phenomena occur in this part of the beam resulting in it being non-homogeneous and intensity peaks of 5-10 times higher than the set value may occur. This behaviour of the sound beam is defined as the Beam Non Uniformity Ratio (BNR) Fig. 3.5.

In theory the BNR cannot be smaller than 4 i.e. one should always allow for intensity peaks of at least four times the set value. This is the one reason why the treatment head should always be kept in motion during use to avoid localised intensity peaks. (Hoogland 1986).

The graphic representation of ultrasound intensity peaks (Fig.3.5) is produced using a calibrated hydrophone immersed in a water bath which is constructed to avoid reflections of the ultrasound beam. Fig.3.6 shows the principle of the apparatus. The hydrophone a is mounted on tracks b and c which enable it to be positioned in the vertical plane d By rotating the treatment head e the third dimension can be obtained and therefore the whole ultrasound beam can be scanned.

Fig. 3.5 Diagram of intensity peaks in the ultrasound beam of large and small treatment heads at 1MHz. and 3MHz showing beam non - uniformity.

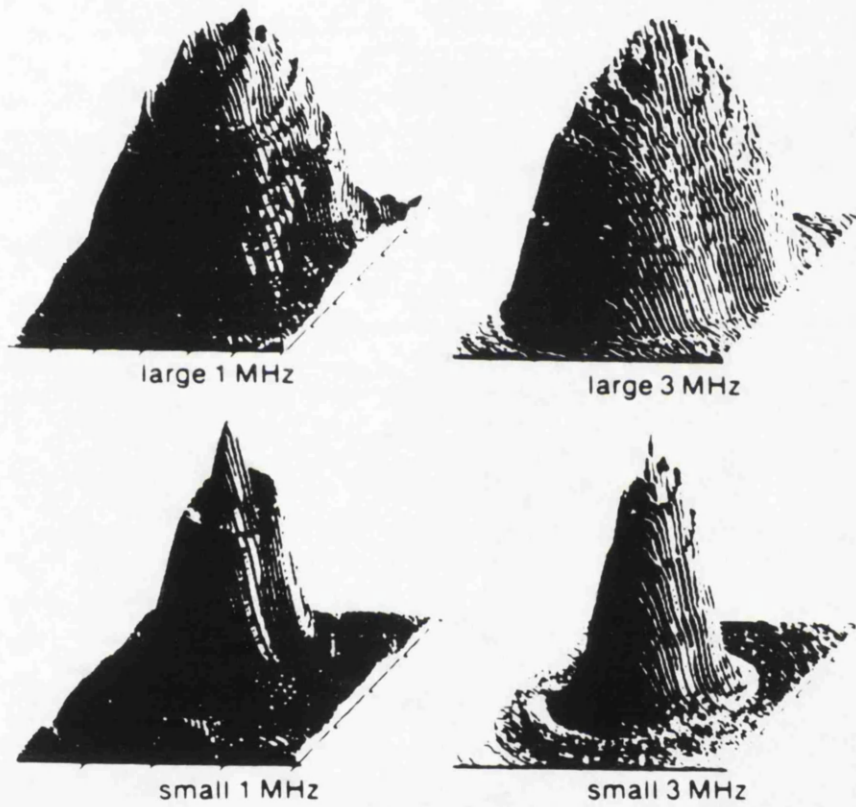
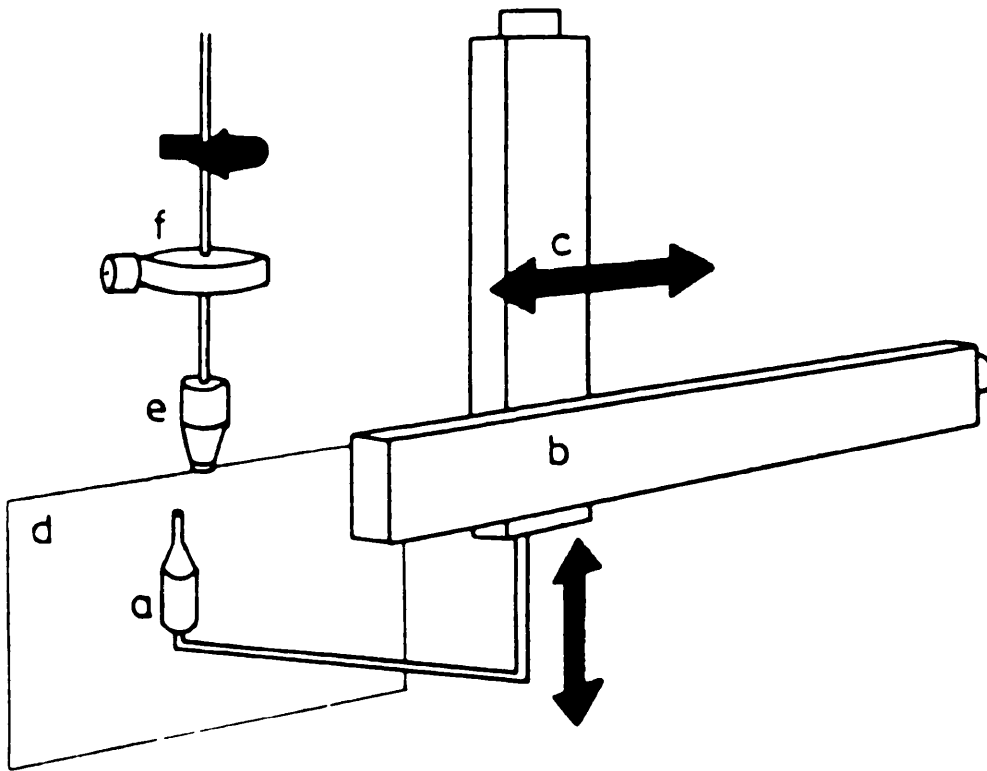


Fig.3.6 Diagrammatic representation of apparatus used to plot ultrasound intensity peaks.

- a - hydrophone
- b - horizontal track
- c - vertical track
- d - vertical plane
- e - ultrasound transducer
- f - axis for rotation



3.2 DOSAGE OF ULTRASOUND.

In clinical and experimental work it is important to quantify and standardise the amount or dose of ultrasound which is delivered to the tissues. Although exposure to ultrasound has been compared to exposure to ionising radiation there are important differences.

When a photon of ionising radiation such as an x-ray or gamma ray passes through a tissue it loses some or all of its energy. This causes electrons within the tissue to be set into motion and in turn cause numerous biochemical effects which manifest themselves as radiation damage. The amount of damage produced is proportional to the number and velocity of these moving electrons which in turn is proportional to the total amount of energy deposited within the tissue. A single short exposure to photons having the same energy at high intensity produces the same effect as numerous long exposures at a low intensity.

The major difference in the dosage of ultrasound is that the energy of the ultrasound wave which is absorbed by a tissue does not, according to current knowledge, generate destructive charged species. Instead the energy appears as heat. Therefore, there does not appear to be a cumulative effect from numerous exposures to low intensities of ultrasound. There is, however, a marked correlation between the magnitude of any observed biological effect and the rate at which the ultrasound is applied to the tissue.

The dose of ultrasound can therefore be defined as the product of intensity and duration of exposure (Williams 1983). The frequency of ultrasound affects the penetration of ultrasound and so influences the biological effects. Absorption of ultrasound energy varies in a linear fashion between 1 and 10mHZ. (most therapeutic devices operate at 1 and 3 mHZ). The absorption coefficient is used to indicate the absorption of ultrasound energy by various media. (see table 3.7) A more practical way of expressing absorption is the half value depth i.e. the distance in the direction of the sound beam in which the intensity in the medium decreases by half its original value. This value can be calculated as follows:-

$$D_{1/2} = \frac{0.69}{A}$$

A

where

$D_{1/2}$ = half value depth

A = absorption coefficient

some examples are shown in table 3.8

There are further complicating factors in the way in which a beam of ultrasound reacts with the medium through which it passes (Hoogland 1986).

Table 3.7 ABSORPTION COEFFICIENT AT 1 AND 3 MHZ.

MEDIUM.	ABSORPTION COEFFICIENT @		
	1 MHZ	3 MHZ	
Blood	0.028	0.084	
Blood-vessel	0.4	1.2	
Bone	3.22		
Skin	0.62	1.86	
Cartilage	1.16	3.48	
Air (20°C)	2.76	8.28	
Muscle	0.76	2.28	*1
	0.28	0.84	*2
Fat	0.14	0.42	
Water (20°C)	0.0006	0.0018	
Nerve	0.2	0.6	

*1 sound beam perpendicular to muscle fibres

*2 sound beam parallel to muscle fibres

(from Ultrasound Therapy - Enraf Nonius, Holland.)

Table 3.8 HALF-VALUE DEPTH (D_{1/2}) OF VARIOUS MATERIALS

	1MHZ.	3MHZ.
Bone	2.1 mm	---
Skin	11.1 mm	4 mm
Cartilage	6 mm	2 mm
Air	2.5 mm	0.8 mm
Muscle	9 mm	3 mm *1
	24.6 mm	8 mm *2
Fat	50 mm	16.5 mm
Water	11500 mm	3833.3 mm

*1 sound beam perpendicular to muscle fibres

*2 sound beam parallel to muscle fibres

DEFINITION:- the "half value depth" is the distance in the direction of the sound beam in which the intensity in a certain medium decreases by half.

(from Ultrasound Therapy - Enraf Nonius, Holland).

ACOUSTIC IMPEDANCE (Z)

This property of a material determines the ratio of reflected to refracted waves of an ultrasound beam. It is defined as the product of the density (D) of the medium and the velocity (C) of sound within the medium.

$$Z = D \times C$$

Some examples of specific acoustic impedance of various media are :-

Table 3.9

MEDIUM.	Z (Kg./m ² S)	
Aluminium	13.8	.10 ⁶
Blood	1.6	.10 ⁶
Bone	6.3	.10 ⁶
Blood-vessel	1.7	.10 ⁶
Gel	~ 1.8	.10 ⁶
Skin	~ 1.6	.10 ⁶
Air	0.0004	.10 ⁶
Muscle	1.6	.10 ⁶
Fat	1.4	.10 ⁶
Water (20°C)	1.5	.10 ⁶

(from Williams A.R. 1983, Ultrasound -Biological Effects and Potential Hazards, Academic Press, London.)

REFLECTION AND REFRACTION.

Reflection occurs at boundaries between different tissues or media. The amount of reflected energy depends upon the specific acoustic impedance of various media.

$$R = \frac{\{Z_1 - Z_2\}^2}{\{Z_1 + Z_2\}^2} \times 100\%$$

where R = amount of reflected energy

Z = acoustic impedance

When the difference between acoustic impedance of the two media becomes smaller, so the reflection decreases. In the body significant reflection occurs for transition between muscle tissue and bone R = 30%.

REFRACTION.

When an ultrasound beam is incident on a surface at an angle other than 90° refraction occurs, just as it does when light passes through glass or water.

SCATTER.

Ultrasound is scattered within the body due to:-

1. divergence in the far field (Fraunhofer zone).
2. refraction.

Scatter can lead to effects outside the source beam.

INTERFERENCE.

This occurs due to two phenomena:-

1. interference in the near field (fresnel zone) which can cause a four fold increase in ultrasound intensity.
2. interference as a result of reflection where incident and reflected beams overlap. At this point the two waveforms may cause constructive or destructive interference.

There have been several detailed surveys of ultrasound therapeutic devices and these have shown disturbing discrepancies between stated and measured outputs intensities. Allen and Battye (1978) made recommendations regarding the important parameters in assessing ultrasound units. They made the point that in practice it is not the intensity which is important but the total power output.

Using the guidelines of the International Electrotechnical commission (I.E.C.) they found discrepancies of 30% between their radiation balance reading and the stated output of the therapy instruments. The I.E.C. recommends limits of departure from expected output values of acoustic power up to 20% for low levels and 15% for high levels (above half scale output). They also noted that acoustic power of most instruments tended to decrease when the unit was left on for long periods. This could be as large as 20% of the initial output after ten minutes. A more recent study by

Lloyd and Evans (1988) employed a radiation force balance based on a design by Anson and Chivers (1982) in order to measure total output power. Beam profiles were measured using a hydrophone driven by a computer controlled stepper motor. Out of 43 machines tested only 44% were considered satisfactory i.e. had an acceptable beam profile and space and time averaged intensities within 30% of the indicated level over the range from 0.25 to 2W/cm². (Hoogland 1986).

3.3 INTERACTION OF ULTRASOUND WITH TISSUES.

Tissue is compressed and expanded at the same frequency as the ultrasound acting upon it with fairly large pressure changes as a result. At 1 W/cm² and 1 MHz. the pressure variation is approximately 1.7 bar. Energy contained within the ultrasound beam decreases with the distance travelled through the medium i.e. the beam is attenuated. As energy cannot be destroyed but is converted from one form to another the interaction of ultrasound and tissue with resultant attenuation gives rise to a number of physical effects which may in turn lead to biological changes.

1. **Mechanical.** compression and expansion in the tissues has an effect called micro - massage which can change the volume of body cells in the order of 0.02% Permeability of cell membranes is also altered with an

improvement in the exchange of metabolic products. These effects are of great therapeutic importance and are the basis of ultrasound treatment.

2. Thermal. Micromassage also leads to the generation of frictional heat as the result of the absorption of mechanical energy. When the tissue temperature can be maintained at between 40°C - 45°C for at least five minutes several desirable effects occur. There is a temporary increase in the extensibility of collagenous structures such as tendons, ligaments and joint capsules with a resultant decrease in joint stiffness. pain and muscle spasm. Tissues with a high protein content (muscle and tendon) absorb energy more readily than tissues with a high fat content. Structures which can be heated preferentially include periosteum, superficial cortical bone, joint menisci fibrotic muscle, tendon sheaths and major nerve roots. (Dyson 1987).

3. Cavitation. Under the appropriate conditions ultrasound acting on liquids may lead to the formation of tiny bubbles. (10^{-6} m. in diameter). These conditions are:- 1. a suitable nucleus e.g. a small particle, surface irregularity or a micro-bubble.

2. dissolved gas in the tissue.

3. appropriate amplitude of ultrasound -
>80mW/cm².

ter Haar and Daniels (1981) demonstrated ultrasonically induced cavitation in vivo using a pulse echo ultrasonic imaging technique which has been used to study bubble formation after decompression from raised ambient pressures in deep sea divers.

Ultrasound may drive these bubbles to oscillate either in a stable fashion, increasing and decreasing in volume - stable cavitation - or to oscillate in a violent fashion before collapsing - collapse or transient cavitation. This phenomena may cause local damage as very high temperatures and pressures develop at the position of the collapsing bubble. Both types of cavitation give rise to localised liquid flow around the vibrating bubble known as streaming and this may be beneficial. (Dyson 1987).

4. Standing Waves. If part of an ultrasound wave passes through tissues is reflected from an interface between two materials with differing acoustic properties (e.g. soft tissue and air) and if the incident wave and reflected wave become superimposed so that peaks of maximum intensity or pressure form at fixed positions at half a wavelength apart - standing waves will form. This can cause local arrest of local blood vessel movement and cause endothelial damage leading to clot formation (Dyson 1974).

By a consideration of the above factors it can be seen that there are possible adverse effects from the use of

therapeutic ultrasound. High intensities can cause marked mechanical peak loading of tissues and possible damage. Cavitation when unstable can also lead to tissue damage. Stasis of blood cells, endothelial damage and subsequent thrombosis can occur as a result of standing waves.

5. Sonoluminescence. Recent work carried out by Pickworth et al (1988), has demonstrated this phenomenon when unstable cavitation is induced by insonation of water with ultrasound at therapeutic levels. Sonoluminescence is the light emitted when unstable or collapse cavitation occurs in a liquid - a condition when potential biological damage may occur. During unstable cavitation induced by ultrasound bubbles formed within a liquid expand and contract adiabatically. During the compression phase of the ultrasound cycle the temperature of the gas trapped in the bubble is raised to several thousand degrees Kelvin and this is associated with the release of free radicals. These two factors are potentially capable of causing tissue damage.

Pickworth et al (1988) used a standard therapeutic ultrasound unit to insonate a tank of water and demonstrate sonoluminescence. They found that the effect was more marked with pulsed regimes which contradicts current recommendations on the use of ultrasound in clinical practice.

As the basis of this thesis involves the exposure of subcutaneous nerves to ultrasound what is the effect of ultrasound on nerves?

An extensive literature search has revealed that there is relatively little current knowledge regarding adverse effects of ultrasound on peripheral nerves. Histological changes have been found in the sciatic nerves of neonatal rats (3 - 5 Days) following exposure to an ultrasound medical imaging system (Ellisman, Palmer and Andre 1987). Under the electron microscope changes were noted in the myelin sheath at the paranodal region. The levels of ultrasound in this study were not comparable with therapeutic levels and the nerve was not fully mature. Also the technique for fixation of the tissue did not involve perfusion making artefacts more likely. The work carried out as part of this thesis on the rat sciatic nerve attempts to overcome these problems.

Other work has concentrated on the effect of ultrasound on nerve conduction. Conclusions are variable i.e. conduction can be increased or decreased. Farmer (1968), Zankel (1966), Currier, Greathouse and Swift (1978).

Various mechanisms have been implicated in these conduction changes. Madsen and Gersten (1981) postulate that changes in membrane permeability to sodium ions are responsible.

Halle, Scoville, Greathouse (1981) investigated the

variables of thermal and mechanical energy by comparing the effect of ultrasound with infra-red treatment on sensory nerve conduction velocity. Temperature changes were held constant during both treatments and the study failed to show any significant difference in changes of conduction velocity, concluding that heat was responsible for the effects.

Comparing ultrasound with other radiations it has been remarked that while public exposure to medical ultrasound approaches that to ionising radiation - the research effort which has been directed towards the bio - effects of ultrasound has been only a very small fraction of that expended on the effects of ionising radiation.

CHAPTER 4.

EVALUATION OF SONOPULS ULTRASOUND UNIT.

4.1 Introduction.

Reviews of the performance of ultrasound therapy units have shown marked discrepancies between the stated output and the measured output. (Allen and Battye 1978, Repacholi and Benwell 1978, Ros, Sourkes and Sanderman 1984 and Lloyd and Evans 1988).

From these surveys it is evident that measured output should be within 20 - 30% of the expected output.

The Sonopuls 434 device used for the experiments in this thesis was therefore assessed by various methods and the results are set out below.

The instrument consists of a high frequency oscillator connected to a piezo-electric crystal in the treatment head via a driver amplifier. The resonant frequency of the crystal is partly determined by the thickness of the piezo-electric material lead zirconate titanate (PZT). This infers that in normal circumstances the treatment head and ultrasound generator must be matched. i.e. the head cannot be used with another generator without calibration being performed. The Sonopuls 434 incorporates a micro - computer and a feedback circuit to allow interchange of treatment heads.(see fig. 4:1)

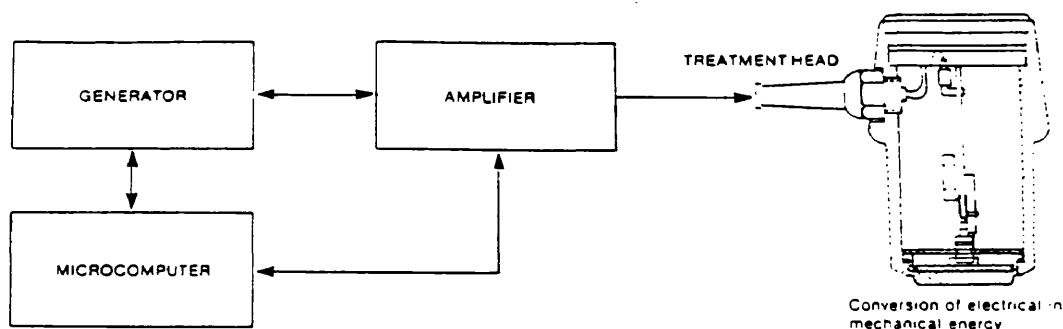


Fig. 4:1 PRINCIPLE OF ULTRASOUND THERAPY UNIT.

This circuitry also monitors the contact between transducer and treatment surface so that when this contact is broken the ultrasound output is interrupted thereby preventing heat dissipation in the treatment head.

The following parameters were measured to assess performance:-

4.2 - MEASUREMENT OF FREQUENCY.

A simple inductive coil was used to pick up radiation from the transducer which was directed at a dummy treatment area in the form of a bag of saline. The coil, approximately 8cms diameter. of insulated wire was connected to a wide range digital frequency meter which measured 999.33 KHZ. The stated frequency of the

treatment head was 1MHZ +/- 0.01%

4.3 MEASUREMENT OF DUTY CYCLE.

With the Sonopuls set to "pulsed" mode with a duty cycle of 2:8 the inductive coil arrangement used in the preceding test was used to couple the unit to an oscilloscope.

Pulses were seen at the rate of one on for every four off thus confirming the setting of 2:8.

4.4 MEASUREMENT OF POWER OUTPUT.

A needle hydrophone was used for the first measurement of temporal spatial average output using the arrangement shown below.

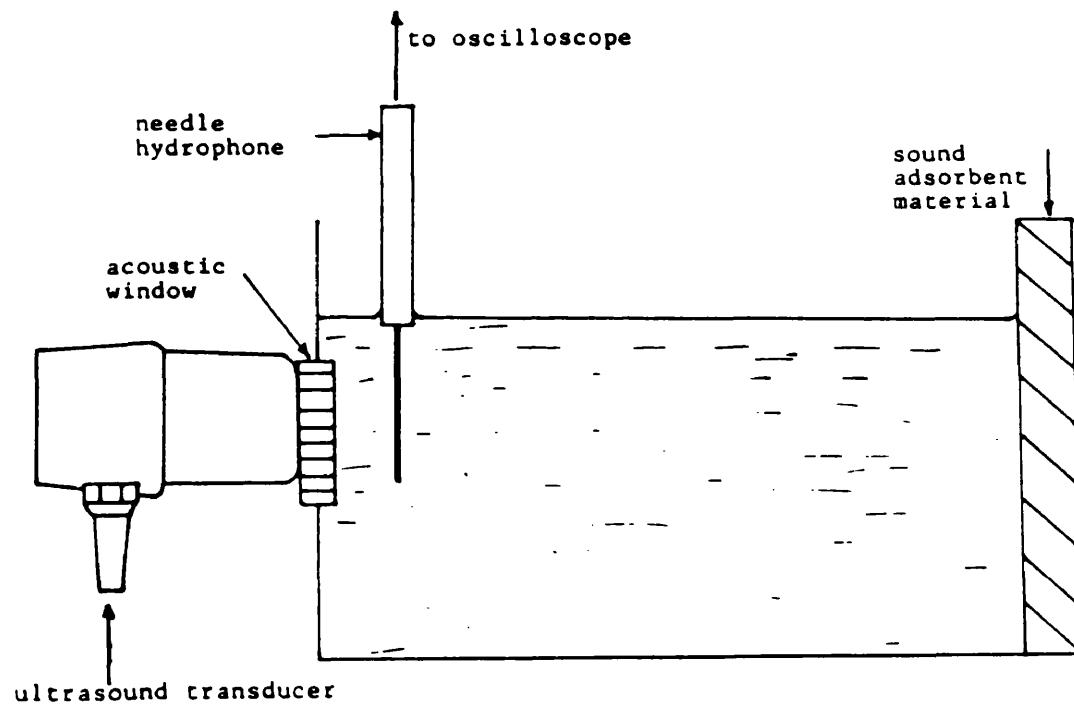


Fig. 4.2 MEASUREMENT OF POWER OUTPUT USING A NEEDLE HYDROPHONE.

The ultrasound transducer was coupled to a water tank via a polythene "window". Carpet was used at the opposite end of the tank to absorb ultrasound and prevent reflected power affecting the readings. A Dapco NP10-13 needle hydrophone was used and this had been cross calibrated against a secondary standard (membrane hydrophone) traceable to the National Physics Laboratory (NPL).

The hydrophone was positioned at the spatial/temporal peak maximum for the treatment head used (ERA = 0.8cm²). Output from the device was measured by coupling it to an oscilloscope.

The calibration factor for the hydrophone was 2.25 KPa/Mv.

Calculation of power output was as follows:-

$$I = \frac{P^2}{2 \times Z} \quad \text{where} \quad \begin{array}{l} I = \text{intensity watts/cm.}^2 \\ P = \text{pressure KPa} \\ Z = \text{acoustic impedance} \end{array}$$

$$Z = D \times C \quad \text{where} \quad \begin{array}{l} D = \text{density of water} \\ \quad = 1000\text{Kg./M}^2 \\ C = \text{speed of ultrasound} \\ \quad \text{in water} \\ \quad = 1480\text{M/sec.} \end{array}$$

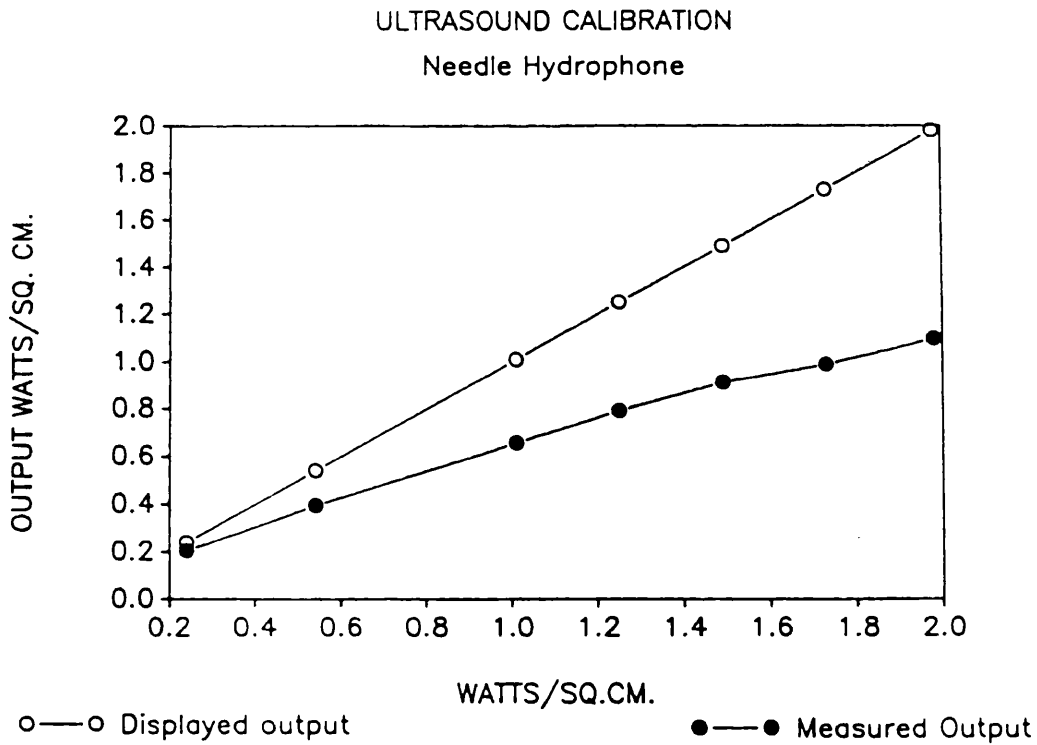
(See Table 4.i)

Table 4.i

CALIBRATION WITH NEEDLE HYDROPHONE.

SONO. O/P W/CM. 2	HYDRO.O/P mV.	= K.PASC.	ACTUAL O/P W/CM. 2
0.24	34.5	77.63	0.204
0.54	48.0	108.00	0.394
1.01	62.0	139.50	0.657
1.25	68.0	153.00	0.791
1.49	73.0	164.25	0.911
1.73	76.0	171.00	0.988
1.98	80.0	180.00	1.095

Fig. 4.3



It can be seen from the graph drawn from these results (fig. 4.3) that there was a significant difference between the expected and actual output and at an expected output of 1.98 watts/cm.² the error is 45% which is not acceptable.

A second calibration was carried out using a commercial power meter (Bio-Tek Wattmeter UW -11 serial no. 0266) which again had been cross calibrated against an NPL standard.

De - gassed water which had been boiled for thirty minutes and allowed to cool to room temperature was used as a coupling medium.

The wattmeter had been calibrated at a frequency of 1.09 MHZ. against an NPL tethered float ultrasound measuring device.

Total power measured from float = 1.75 watts.

" " " " Bio-Tek = 2.0 watts.

Therefore correction factor = $1.75/2$
= 0.88

Sonopuls output = Watts/cm²

ERA = 0.88 cm²

Correction factor = $0.88/0.8$
= 1.1

Two sets of readings were taken from the wattmeter to give identical results and these are recorded below together with the corrected outputs.

Table 4.ii

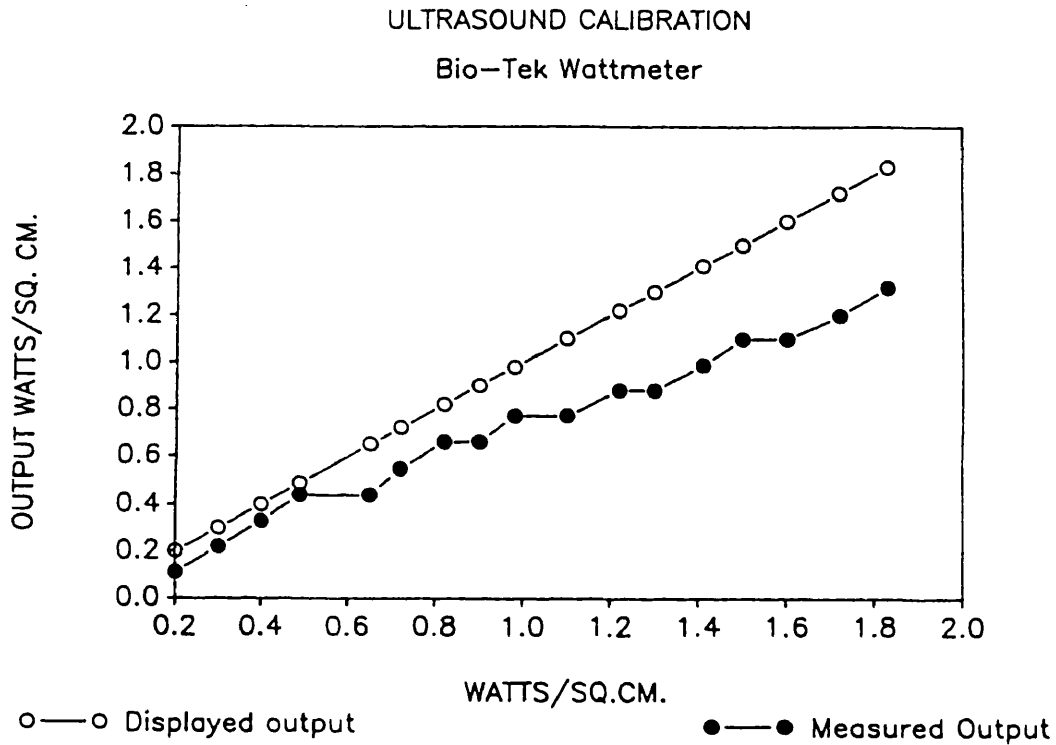
CALIBRATION WITH BIO-TEK WATTMETER.

SONOPULS O/P	MEASURED O/P	CORRECTED O/P
0.20	0.1	0.11
0.30	0.2	0.22
0.40	0.3	0.33
0.49	0.4	0.44
0.65	0.4	0.44
0.72	0.5	0.55
0.82	0.6	0.66
0.90	0.6	0.66
0.98	0.7	0.77
1.10	0.7	0.77
1.22	0.8	0.88
1.30	0.8	0.88
1.41	0.9	0.99
1.50	1.0	1.10
1.60	1.0	1.10
1.72	1.1	1.20
1.83	1.2	1.32

units = watts/cm²

The results are again represented graphically (Fig. 4.4) and show a similar curve to that obtained with the needle hydrophone.

Fig. 4.4



The Sonopuls was therefore checked by Nomeq Ltd. and it was found that the quiescent current of the output stage was incorrect and this was adjusted to its correct value. A post adjustment calibration was

performed using a Medisonics wattmeter and the results are recorded below:-

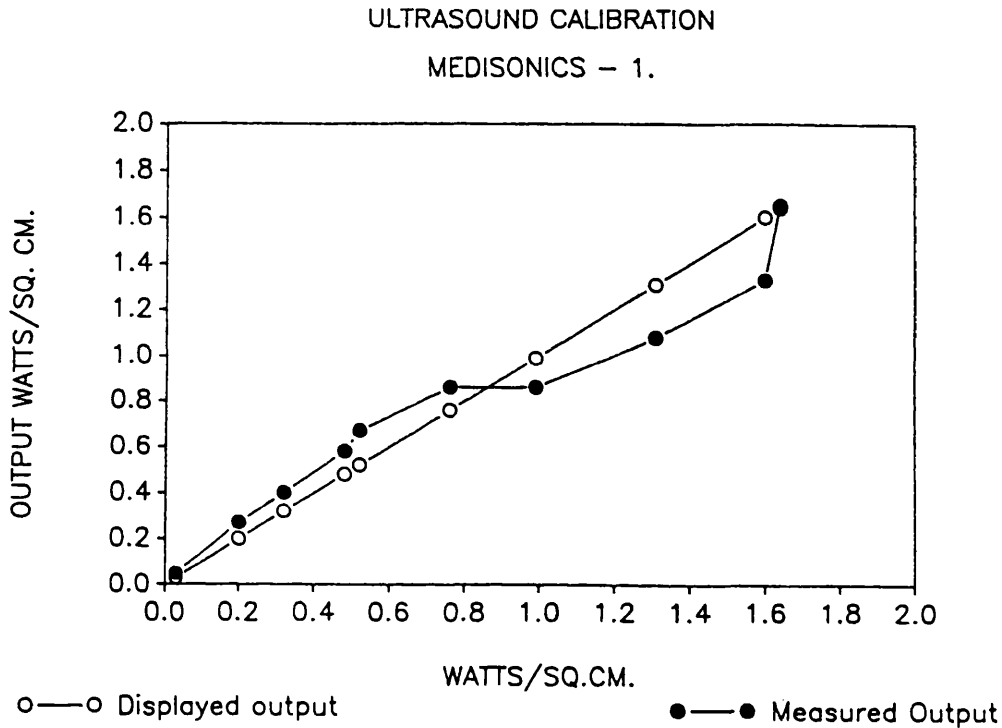
Table 4.iii

CALIBRATION WITH MEDISONICS WATTMETER

SONOPULS W.	MEDISONICS W.
0.03	0.05
0.20	0.27
0.32	0.40
0.48	0.58
0.52	0.67
0.76	0.86
0.99	0.86
1.31	1.08
1.60	1.33
1.64	1.65

The repeat calibration with the Medisonics wattmeter showed a good correlation between expected and measured output and confirmed that the re-alignment of the Sonopuls output stage had corrected the error detected in the first measurement. The results are represented graphically:-

Fig. 4.5



Two further calibrations were performed using the Medisonics wattmeter and showed consistent performance. (see table 4.iv. and Fig. 4.6)

Unfortunately the Medisonics wattmeter was only capable of measuring total power up to 2.0 watts/cm.² (temporal spatial average power) but as most error occurs at lower power levels it was thought that this gave a good index of performance.

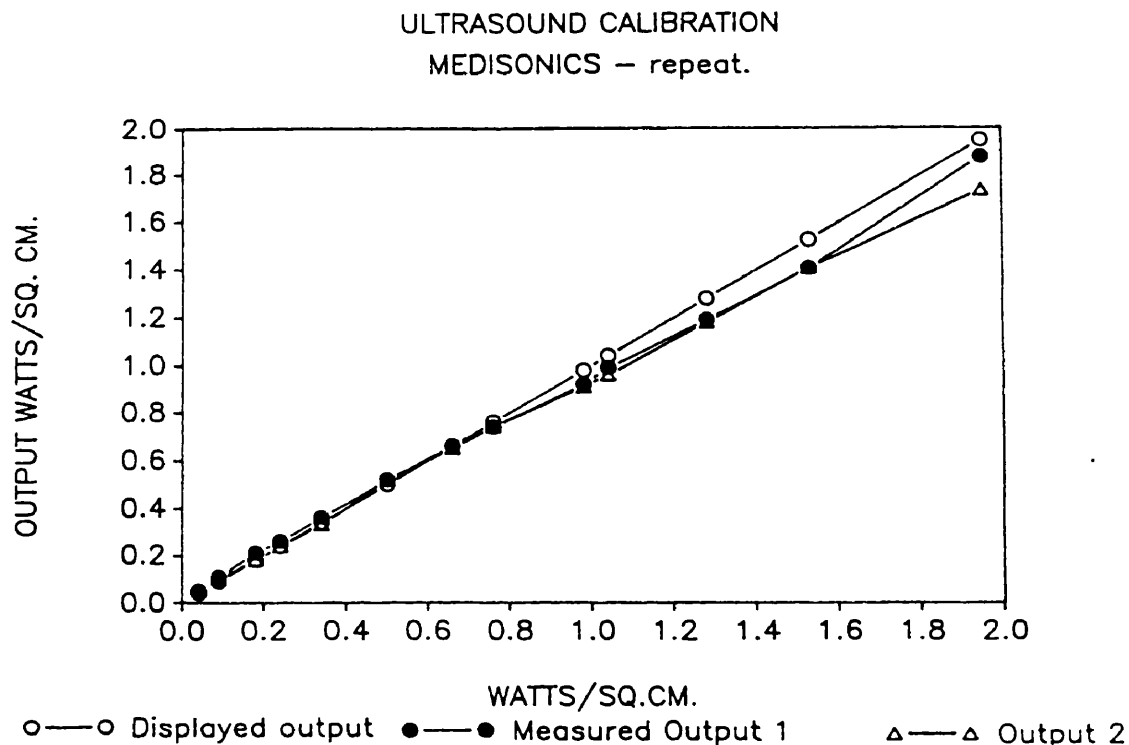
Table 4.iv

REPEAT CALIBRATIONS WITH MEDISONICS WATTMETER.

0.8 CM² TRANSDUCER

SONO. W/CM2	= WATTS	MEDISONICS 1	MEDISONICS 2
0.04	0.05	0.05	0.05
0.09	0.07	0.11	0.10
0.18	0.14	0.21	0.18
0.24	0.19	0.26	0.24
0.34	0.27	0.36	0.33
0.50	0.40	0.52	0.52
0.66	0.53	0.66	0.65
0.76	0.61	0.74	0.74
0.98	0.78	0.92	0.91
1.04	0.83	0.99	0.96
1.28	1.02	1.19	1.18
1.53	1.22	1.41	1.41
1.95	1.56	1.88	1.74

Fig. 4.6



4.5 DISCUSSION.

There were limitations to all the methods of ultrasound measurement used but the alternative was a calibration at the National Physics Laboratory which is an extremely costly exercise and outside the financial confines of this project. However, it was felt that by using several different methods of measurement (which seemed to compare with each other reasonably well) a good compromise was reached.

In the light of these tests it was felt that the Sonopuls 434 ultrasound unit had an adequate performance and was operating within the accepted degree of error for such devices.



Fig. 4.7 SONOPULS 434 ULTRASOUND THERAPY UNIT.

CHAPTER 5

EXPERIMENT TO DETERMINE SKIN TEMPERATURE AND ULTRASOUND INTENSITY DURING INSONATION OF THE RAT SCIATIC NERVE VIA A WATER BAG.

5.1 Introduction.

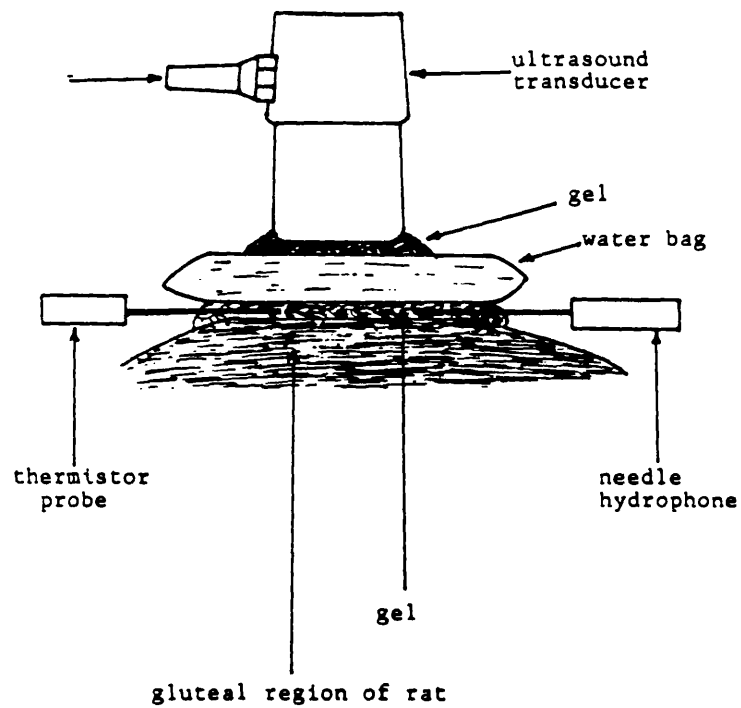
In order to subject the rat sciatic nerve to maximal doses of ultrasound it was found necessary to insonate via a water bag to avoid direct thermal effects on the skin surface. These come about due to inefficient coupling between the 5cm.² treatment head and the uneven surface of the rat's gluteal area leading to a marked temperature rise of the transducer.

To overcome this problem a 250ml. saline infusion bag was drained of its contents and the saline was replaced with de-gassed water.

Gel was then placed on the transducer and treatment side of the bag. see fig. 5.1

Theoretically there should be minimal attenuation of the ultrasound beam by this arrangement and so this was confirmed experimentally. Also a direct thermal effect of ultrasound was excluded by measuring the skin temperature during a ten minute insonation at 2.0 watts/cm. continuous output.

Fig. 5.1



5.2 Materials and Methods.

The rat was first anaesthetised with intraperitoneal pentobarbitone 35mg./kg.

Skin temperature was monitored with an Edale Thermistor Thermometer (Edale Instruments, Toft, Cambridge.)

The needle thermistor was placed on the skin surface next to a Dapco needle hydrophone connected to a Tektronix 453 oscilloscope.

Using the arrangement in fig. 5.1 the treatment head was held stationary for ten minutes with the Sonopuls set to maximum continuous output at 1MHZ. The results were as follows:-

5.3 Results.

SKIN TEMPERATURE.

ambient temperature 20 °C.

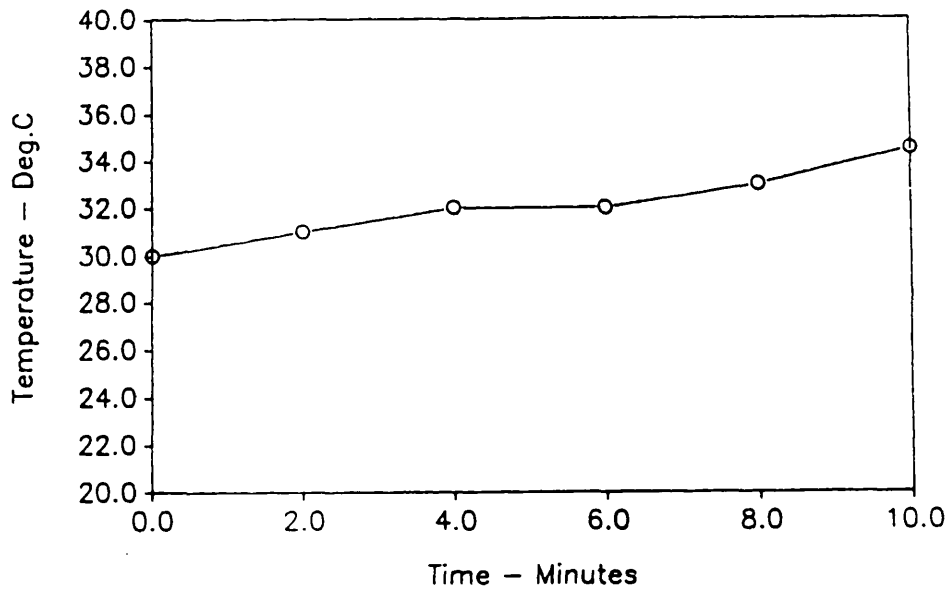
Table 5.2

TIME (MINS)	TEMPERATURE
0	30
2	31
4	32
6	32
8	33
10	34.5

At the end of insonation the temperature of the water bag was 27°C.

Fig. 5.3

ULTRASOUND AND SKIN TEMPERATURE
2.0 watts/sq.cm. (cont) for 10 mins



ULTRASOUND INTENSITY AT SKIN LEVEL

The Dapco needle hydrophone was placed in the gel between water bag and skin of the rat's gluteal region and was connected to the oscilloscope which was calibrated to 50 mV / cm.

During the experiment it was noted that the output from the hydrophone varied as the ultrasound transducer was hand held and minor movements caused considerable fluctuation in signal.

The peak to peak level of the sine wave displayed on the oscilloscope varied between 1 and 4.5cms.

Therefore the variation in amplitude was 0.5 - 2.25 cms.

From calibration of the oscilloscope 1.0 cm = 50mV
Amplitude of signal detected by the hydrophone was 25 - 112.5 mV

The hydrophone had been calibrated using a membrane hydrophone as a secondary standard (traceable to the National Physics Laboratory) 2.25 KPa / mV.

Therefore pressure varied between 56.25 KPa and 253KPa.
= 0.056 MPa - 0.253 MPa since 1000KPa = 1.0 MPa.

This is equivalent to 0.66 - 2.53 Atmospheres
since 1.0 Atmosphere = 100 KPa.

INTENSITY

$$I = P^2 / 2(D \times C)$$

P = pressure

= X KPA

where X = 56.25 or 253

X KPa = X x 10Pa

D = density of water

= 10^3 Kg. M^{-3}

C = speed of sound in
water

= 1480 M/S^{-1}

Z = D x C (Z = acoustic impedance of water = 2.96)

$$I = (X \times 10^3)^2 / 2.96 \times 10^6$$

$$= X^2 \times 10^6 / 2.96 \times 10^6$$

$$= X^2 / 2.96 \text{ W/M}^2$$

or:-

$$I = X^2 / 2.96 \times 10^4 \text{ W / CM}^2$$

To calculate intensity of ultrasound at skin surface :-

A). where $X = 56.25$ KPa

$$I = 56.25^2 / 2.96 \times 10^4$$
$$= 3164.0624 / 2.96 \times 10^4$$

$$I = 0.107 \text{ W / CM}^2$$

B). where $X = 253$ KPA

$$I = 253^2 / 2.96 \times 10^4$$
$$= 64009 / 2.96 \times 10^4$$

$$I = 2.162 \text{ W / CM}^2$$

The Sonopuls read-out varied between 2.00 and 2.20 W / CM^2 during the experiment and this reflected minor movements of the hand held transducer.

Following this treatment a superficial burn appeared on the rat's hindquarter - not corresponding to the area of the treatment head but measuring about 5 x 10 mm. This did not seem to cause any discomfort and there was no evidence of motor impairment.

A section of this skin was therefore taken and stained with haematoxylin and eosin. This has all the features of a burn with inflammatory cells and fibroblastic reaction. Several vacuoles were noted in the sub-epidermal area which were thought to be due to fat.

(Fig. 5.4)

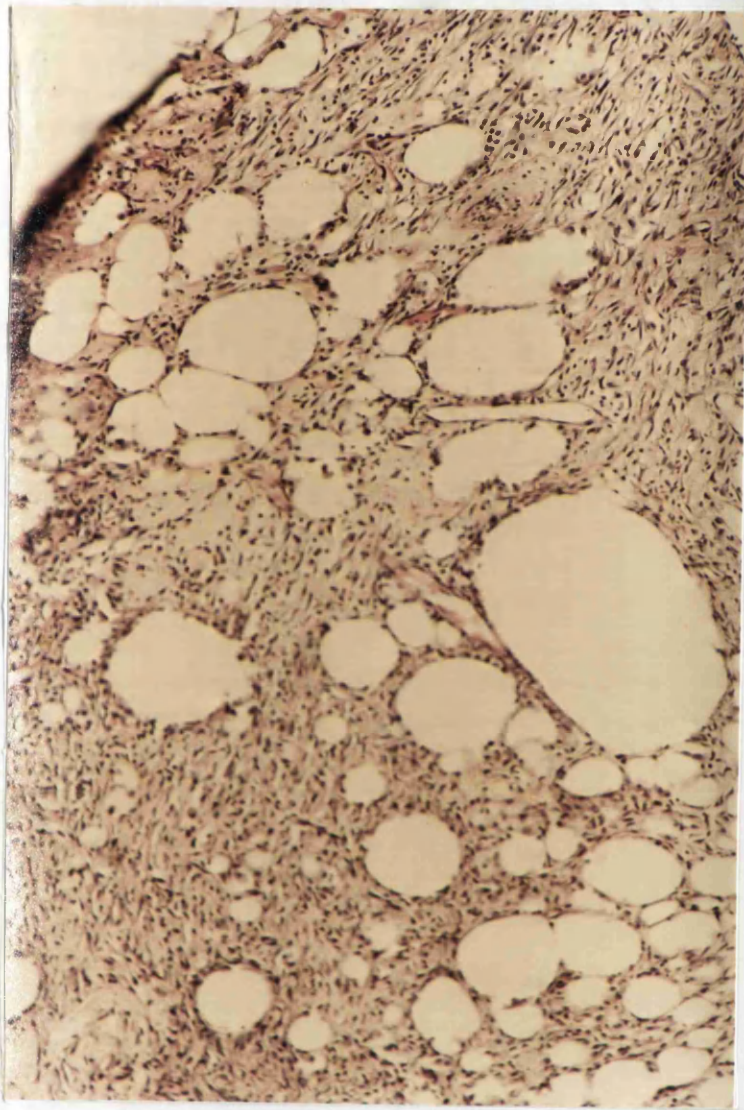


Fig. 5.4 Section of skin burn. - H.& E. x100

Frozen sections were therefore performed on a subsequent specimen by the histology department of Addenbrooke's Hospital. (Fig. 5.5) These confirmed that the spaces were indeed due to fat.

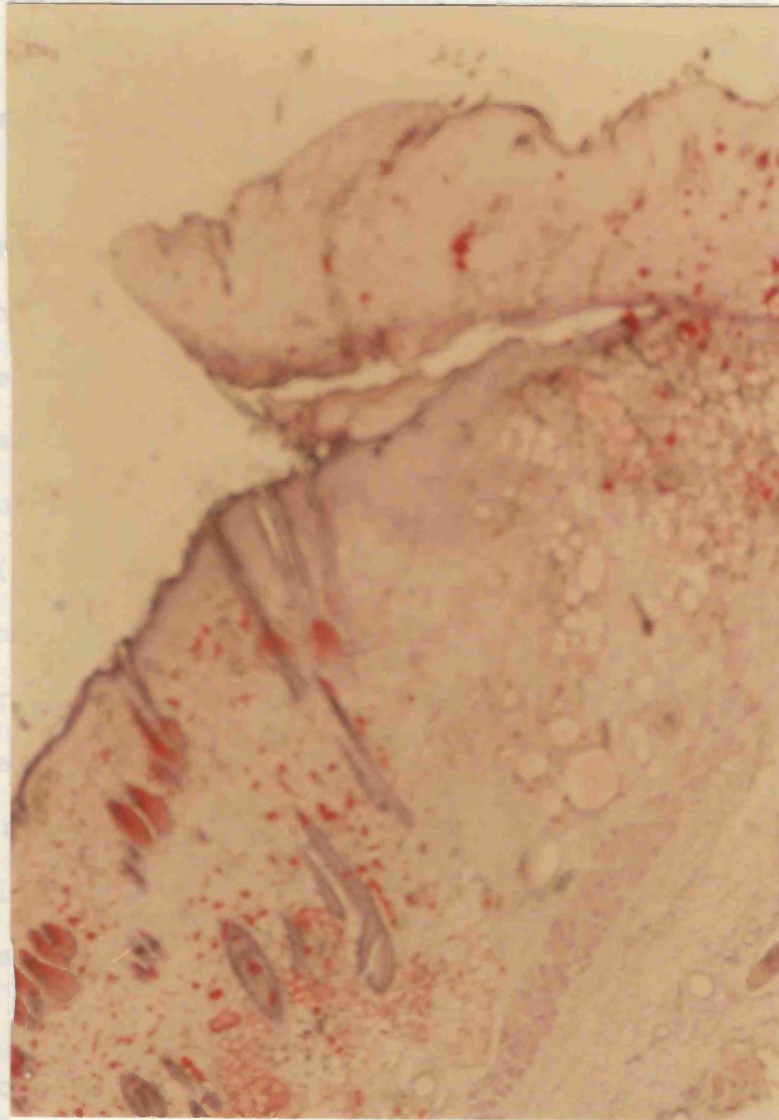


Fig. 5.5 Frozen section of skin burn.- Oil Red O x100

5.4 Discussion.

The temperature rise at the skin surface during this experiment was negligible and there was very little attenuation of the ultrasound beam by the water bag.

It is thought that the burn produced on the rat's hindquarter was due to dissipation of ultrasound energy in the tissue. As the "burn" seemed to overly the bony prominence of the pelvis it is possible that thermal damage occurred due to reflection of ultrasound leading to constructive interference with the incident beam.

This would lead to a localised intensity peak but one would expect a corresponding temperature rise. Increased capillary blood flow in the skin will help to dissipate heat but Dyson et al (1974) have shown that standing waves (produced by a stationary transducer) can impede or even arrest capillary blood flow. This would counteract the cooling effect but again one would expect a corresponding temperature rise.

Another possibility is that unstable cavitation was occurring. This is associated with highly localised increases in temperature and pressure which leads to tissue damage. Other workers (ter Haar et al 1979) have demonstrated highly localised tissue damage with electron microscopy and have attributed it to cavitation.

This experiment has reinforced the advice that in clinical practice it is extremely important to ensure efficient coupling of the transducer which must be kept in motion during treatment.

THE STRUCTURAL EFFECTS OF ULTRASOUND ON PERIPHERAL NERVE.

6.1 INTRODUCTION.

As the basis of this thesis advocates the use of therapeutic ultrasound for a new indication i.e. the diagnosis of carpal tunnel syndrome, which involves concentrating ultrasound over a subcutaneous peripheral nerve, it is important to demonstrate that there will be no adverse effects on the nerve.

There has been very little work carried out in this field to date. Changes in nerve conduction velocity, both increased and decreased rates, have been demonstrated by Madsen and Gersten (1961) and Farmer (1968). This effect may be thermal but Dyson (1987) postulates that alteration of cell membrane permeability to ions, sodium in particular, may be responsible. Early experimental work studying the structural changes in nerves following exposure to ultrasound involved very high, non-therapeutic doses and the results cannot be compared with the clinical situation (Baltes, Herrick and Strobel 1954).

More recent work has investigated the effect of diagnostic ultrasound on nerve. Ellisman, Palmer and André (1987) claimed that diagnostic ultrasound may disrupt myelination. They used neo-natal rats in their

study which showed irregularities in the myelin at the node of Ranvier when longitudinal sections were examined under the electron microscope. One must question the significance of the subtle changes demonstrated in immature myelin in nerve which had been prepared by immersion fixation. (See theory of electron microscopy appendix iii.).

To investigate further the effect of therapeutic ultrasound on nervous tissue an animal model was used in the form of the sciatic nerve of the laboratory rat. This nerve is easily accessible as it emerges from the sciatic foramen and is of reasonable size to handle. The nerve was exposed to maximal levels of ultrasound in order to determine what type of damage would be produced. A second experiment was carried out, exposing the nerve to doses of ultrasound comparable to that in the diagnostic test. Sections of the nerve were then examined under the light microscope looking for evidence of damage - de-myelination in particular. Further examination was carried out under the electron microscope to assess any subtle structural damage. Finally the fascicles were teased apart from each specimen and a small sample of fibres examined under the light microscope as a further check for de-myelination.

6.2 MATERIALS AND METHODS.

Adult female Wistar rats were used weighing between 250 and 300 gms. Three rats in each group were treated as follows:-

The right gluteal area was insonated using a couplant gel and a moving treatment head (except group 2).

The left sciatic nerve was used as control.

GROUP 1. 0.5 minute ultrasound 2.0 W/CM^2 continuous.
1 MHz., 0.8 CM^2 transducer.

R1	L1
R2	L2
R3	L3

GROUP 2. 10 minutes ultrasound 2.0 W/CM^2 continuous
1 MHz., 5.0 CM^2 transducer (stationary)
using a water bag and gel as couplant.
(Fig. 5.1)

R4	L4
R5	L5
R6	L6

The dose of ultrasound in group 1. approximates to that used in the diagnostic test whereas in group 2 maximal levels were used. The rats were first anaesthetised with intra-peritoneal pentobarbitone 35 mg/kg. The right gluteal area was then shaved and the sciatic nerve was insonated using couplant gel. A water bag was used for

the maximal levels to avoid direct heat from the transducer. (see chapter 5). The rats were then allowed to recover and observed for any adverse effects, particularly motor or sensory impairment of the hind limb. At fourteen days post insonation the rats were again anaesthetised to allow perfusion fixation of the nerves. Using a midline incision, a laparotomy was performed and the viscera were displaced to allow access to the abdominal aorta. This was carefully cleared and two 3.0 silk ties were passed around it, the proximal tie being just distal to the renal arteries. A 22g. intravenous canula was then inserted in a caudal direction via a small incision in the aorta, having first tied it off proximally. Heparin 250 IU in 2cm³ of normal saline was then injected prior to connecting the perfusion apparatus. (see fig. 6.1) This consisted of two glass bottles connected to a manometer and pressurised by a sphygmomanometer bulb. One bottle contained normal saline and the other primary fixative which consisted of 2% paraformaldehyde, 3% gluteraldehyde and 1 mM. calcium chloride in 0.1M cacodylate buffer at pH 7.3.

Prior to commencing perfusion the vena cava was divided and then the hind limbs were perfused with 100 cm³ normal saline at a pressure of 100mm.Hg. The perfusate was then changed to primary fixative at which stage a terminal dose of pentobarbitone was administered to the rat. At least 150 cm³ of fixative was perfused.

The sciatic nerve was then carefully dissected out on each side and placed in primary fixative overnight.

After immersion in osmium 2-3 cm. segment of nerve was also processed for teasing as follows:-

Following a wash in 0.1M cacodylate buffer the nerve was

immersed

65% and

The spec

dissecti

good axo

level th

The exc

dried in

For deta

microsc

rior to

stained

under th

and to

Axon de

etcher

consist

The image of the axons was projected on a screen of a projected microscope.

The axons were counted by touching each one with a pen-

like transducer which is connected to the computer.

Graph paper placed on the screen facilitated counting.




Fig. 6.1 Perfusion apparatus.

The tissue was processed for electron microscopy according to the schedule on page 198.

After immersion in osmium a 1cm. segment of nerve was also processed for teasing as follows:-

Following a wash in 0.1M cacodylate buffer the nerve was immersed in 45% glycerol at 45°C for 24 hours, then in 66% and finally 100% glycerol.

The specimens were then carefully teased under a dissecting microscope using fine needles. At least ten good axons were isolated in each sample, showing at least three nodes each.

The excess glycerol was then removed and the slides dried in alcohol prior to application of cover slips. For details of preparation of material for electron microscopy see appendix iii.

Prior to electron microscopy semi-thin sections were stained with 1% toluidine blue in borax and examined under the light microscope to confirm adequate fixation and to assess gross structural changes.

Axon counts were performed on these sections using a Reichert Jung MOP 3 computerised counter. This device consists of a magnetic "screen" onto which is projected the image of the slide from a projection microscope.

The axons were counted by touching each one with a pen-like transducer which is connected to the computer.

Graph paper placed on the screen facilitated counting.

6.3 RESULTS.

1. SEMI-THIN SECTIONS.

These were examined to assess gross evidence of structural damage to the nerve. The sections were also used as a quality control for fixation prior to electron microscopy. Contrary to expectations no evidence of nerve damage was noted in these specimens except for number R5 which deserves special mention.

As mentioned previously (p.112) rats treated at the maximum level of ultrasound developed a burn over the hind quarter. In the case of R5 there was a marked fibrous reaction resulting in the production of a hard mass about 10mm. in diameter arising from the back of the pelvis . This mass was impinging on the sciatic nerve which had to be carefully dissected clear.

Examination of the semi-thin section of this nerve revealed evidence of focal re-myelination indicating axon damage adjacent to this fibrous mass. Fig. 6.5

A section of the mass was cut and stained with haematoxylin and eosin. Fig. 6.6

This shows quite a marked fibrous reaction and this is also evident on the electron micrographs of this specimen. It is well documented that ultrasound stimulates fibroblasts (Dyson 1987) and it is probable that this fibrous reaction was in response to local periosteal inflammation caused by the ultrasound.

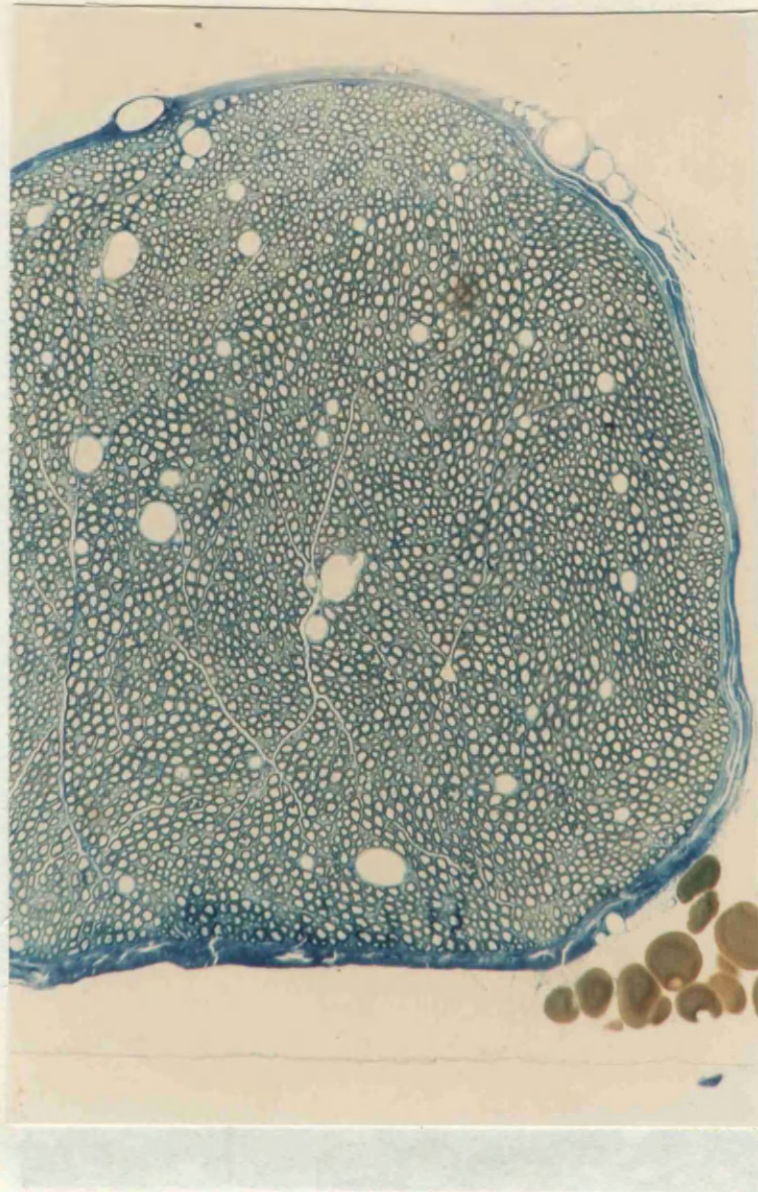


Fig.6.2 Semi-thin section of normal sciatic nerve
X100 - 1% Toluidine blue in borax.

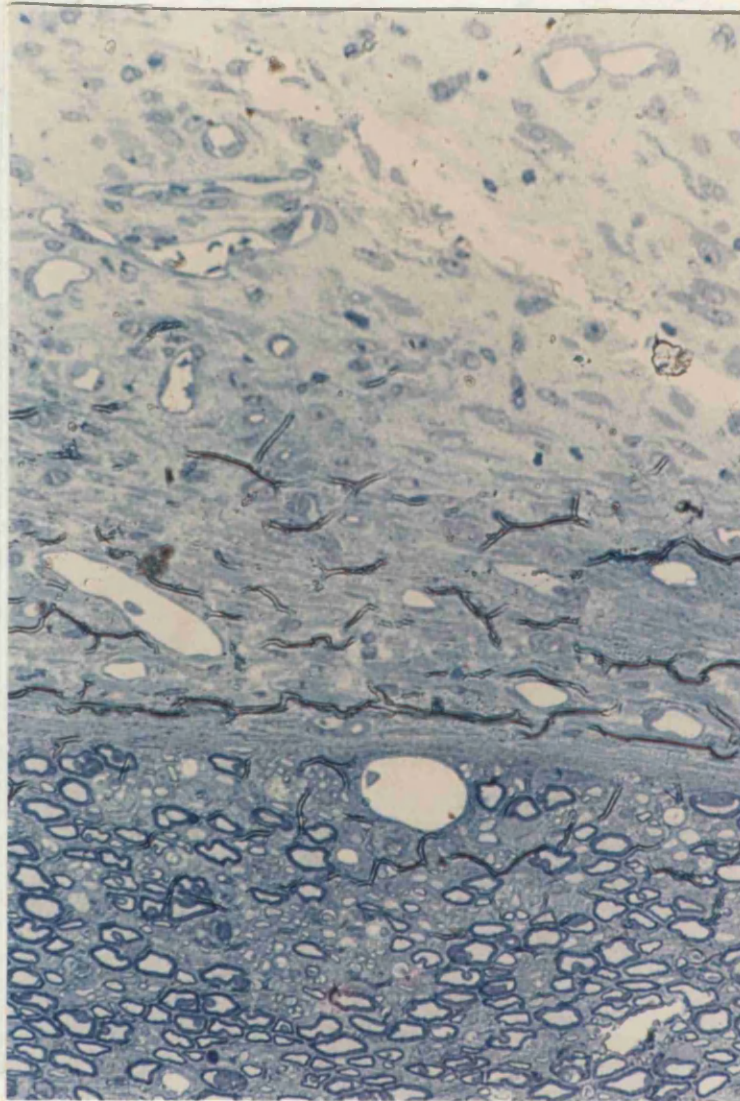
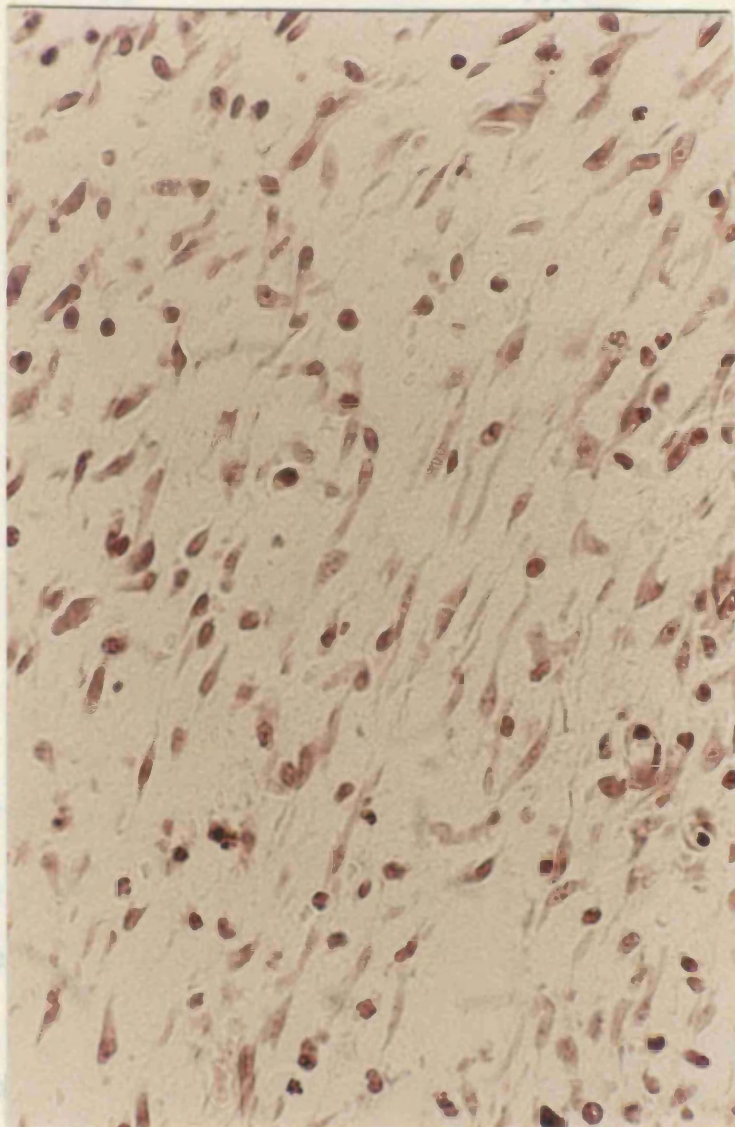


Fig.6.3 Semi-thin section of specimen R5 (maximum ultrasound) showing focal remyelination and degeneration. x100. 1% Toluidine blue in borax.



These r
procedu
showed
the str

rio
est. This
between

2. ELECTRON MICROSCOPE

Ultra-thin sections from each nerve were examined carefully using a Phillips TM 410 transmission electron microscope.

Fig. 6.4 Section of fibrous mass from R5 - x250 stained with H. & E.

Electron micrographs of these specimens are shown on the following pages and mostly exhibit normal structure. Included are examples of the main features seen under

3. AXON COUNTS

SECTION.	COUNT.
R1	3886
L1	3831
R2	3505
L2	3503
R3	3978
L3	3892
R4	3857
L4	3846
R5	3964
L5	3945
R6	3802
L6	3849

These results were analysed using a nonparametric procedure in the form of the Mann-Whitney U-Test. This showed that there was no statistical difference between the axon counts ($p = 0.05$).

2. ELECTRON MICROSCOPY.

Ultra-thin sections from each nerve were examined carefully using a Phillips EM 410 transmission electron microscope.

Electron micrographs from these specimens are shown on the following pages and mostly exhibit normal structure. Included are examples of the main features seen under

the electron microscope when examining peripheral nerve. The abnormal electron micrographs are described fully in the discussion.

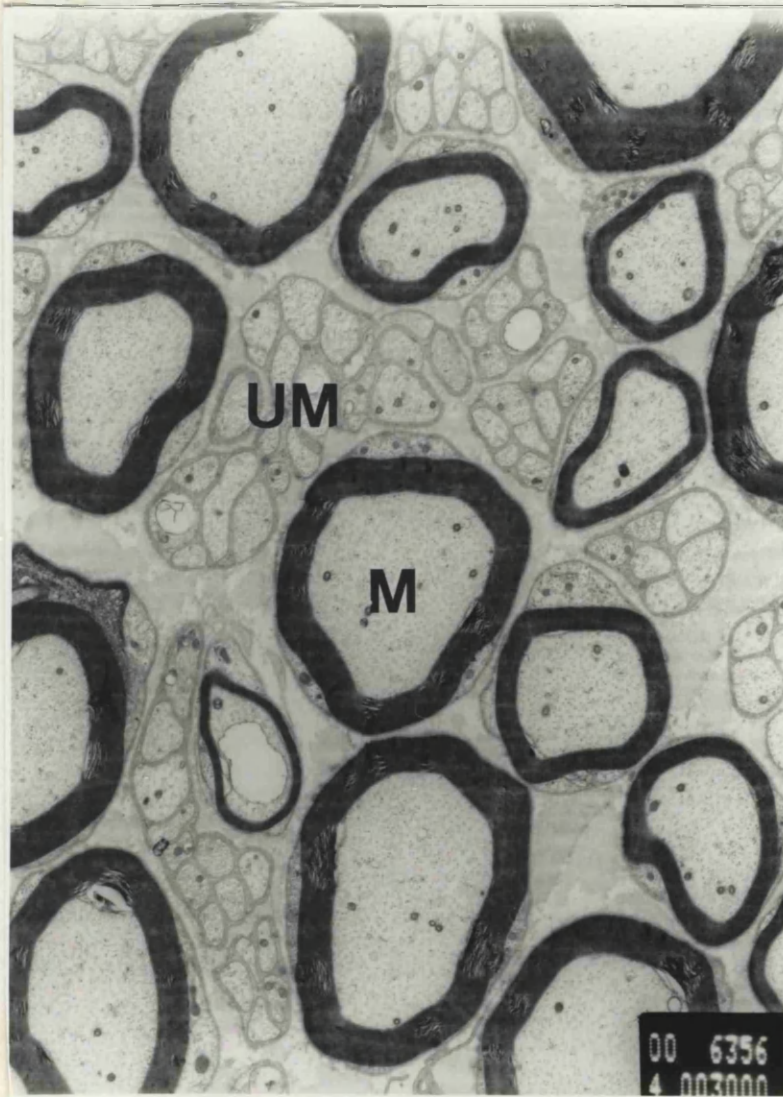


Fig. 6.5 Normal sciatic nerve showing myelinated (M) and un-myelinated fibres (UM). x 3000.

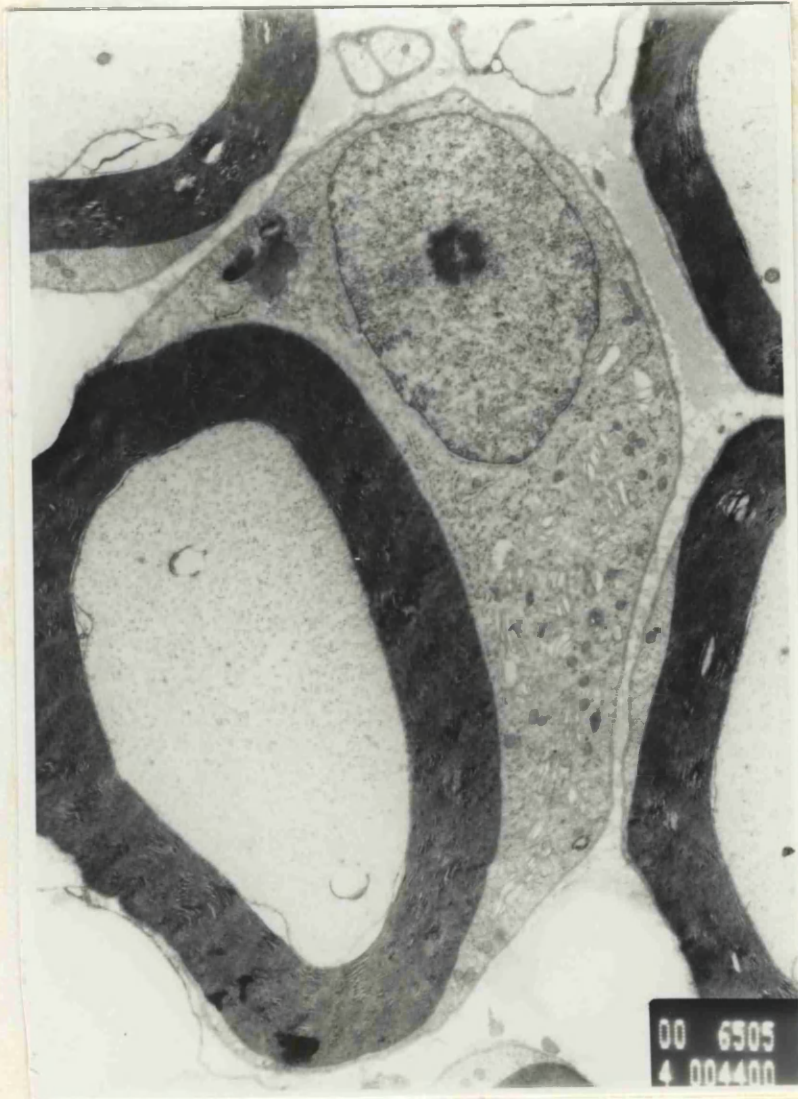

Fig. 6.6 Myelinated axon and Schwann cell with adjacent
unmyelinated axon. x 7,100.

Fig. 6.6 Myelinated axon with Schwann cell and nucleus.

x 4,400.

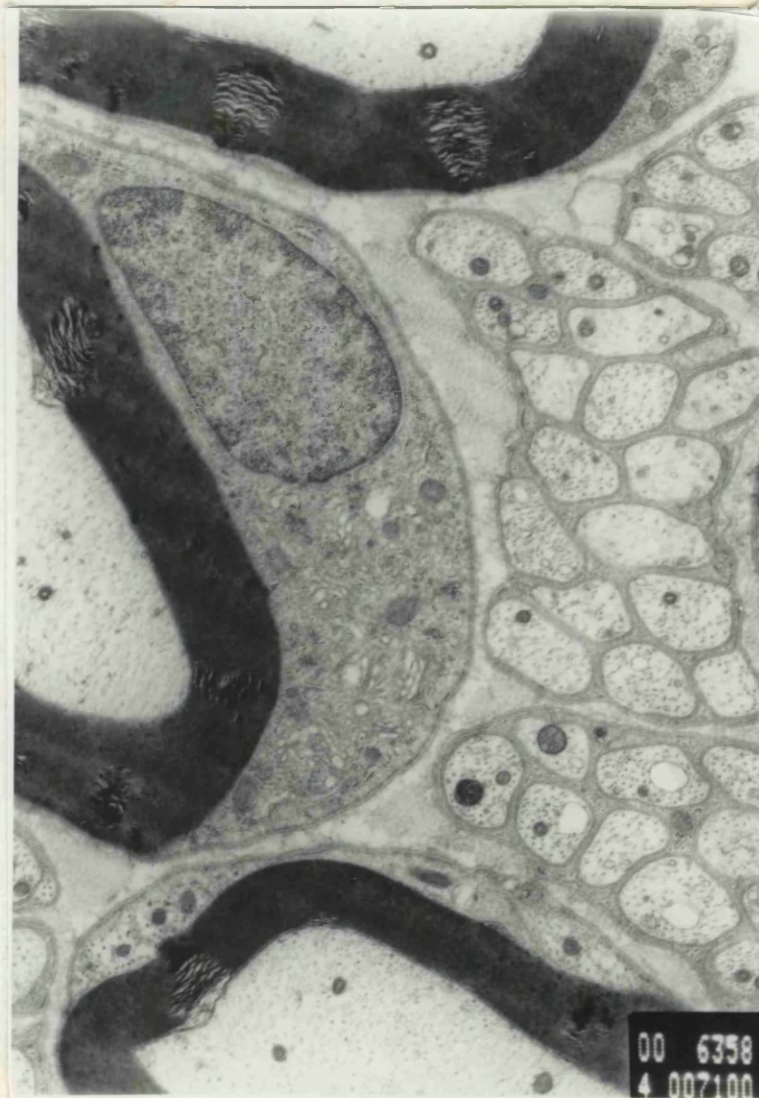


Fig. 6.7 Myelinated axon and Schwann cell with adjacent un-myelinated fibres. x 7,100.

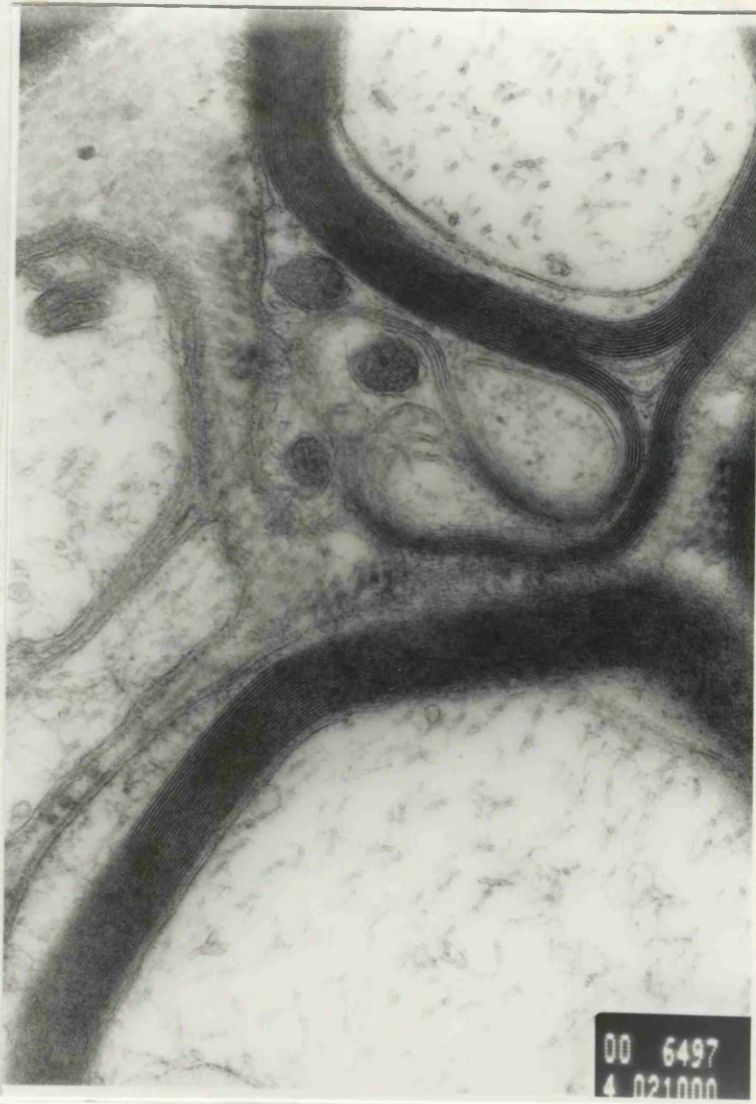

Fig. 6.8 Myelin lamellae. x 21,000.

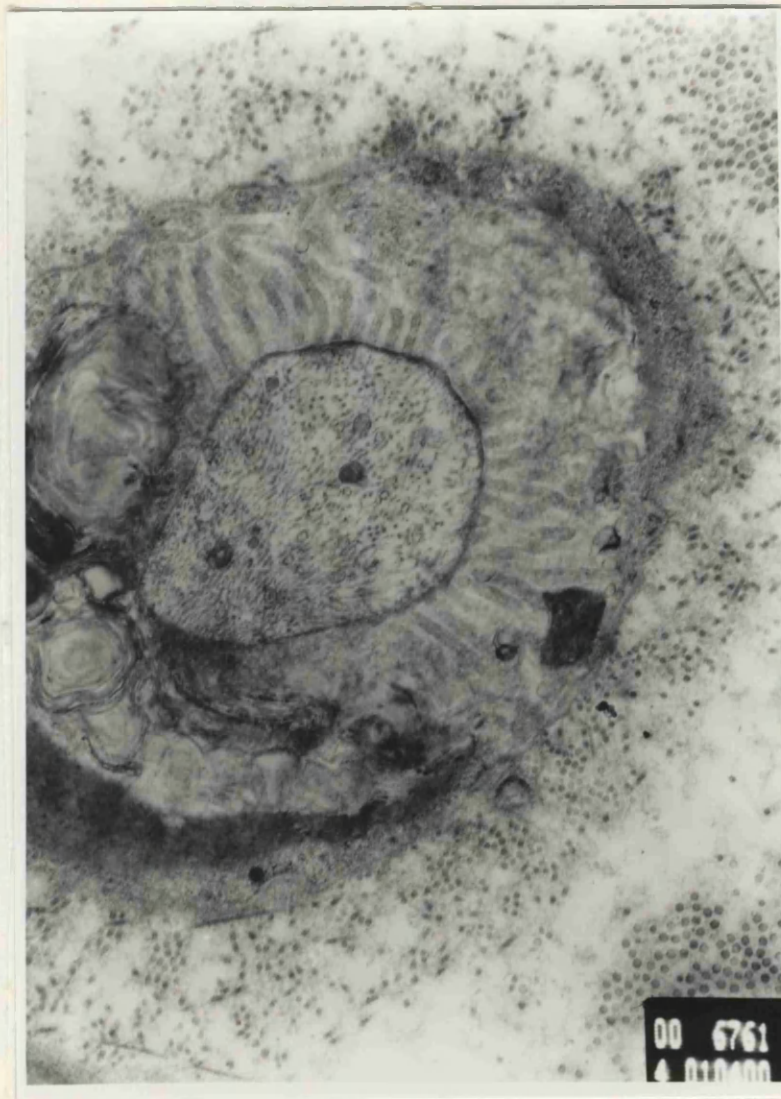

Fig. 6.9 Myelinated axon sectioned at the level of a node of Ranvier. x 10,400.

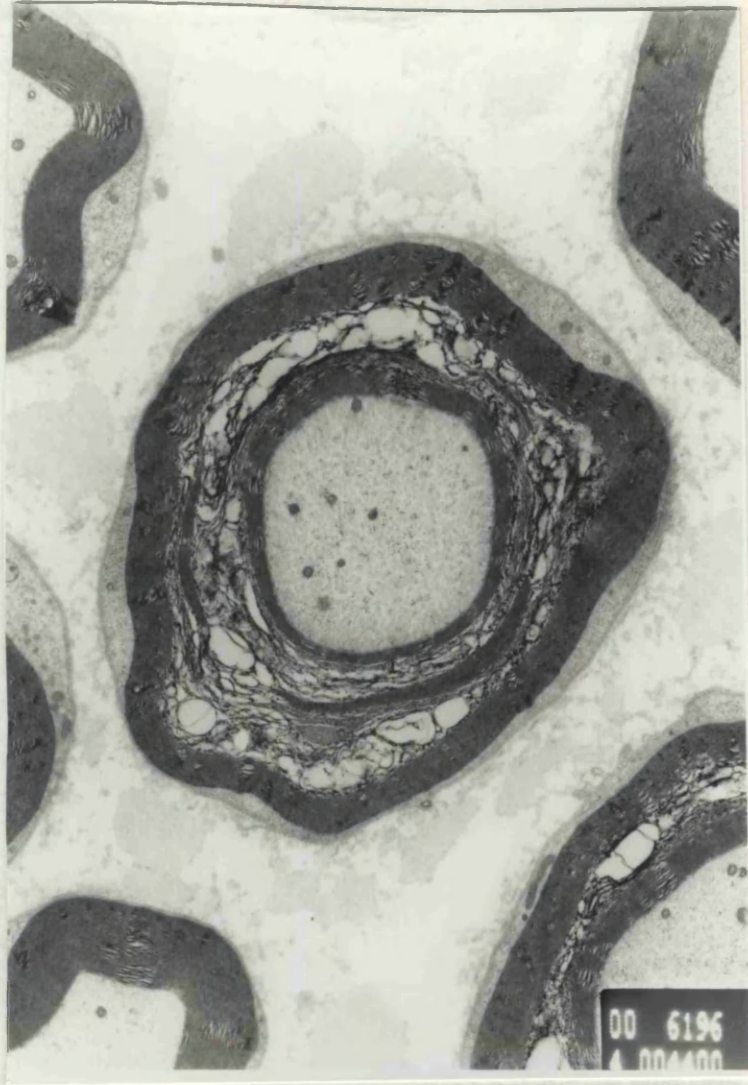

Fig. 6.10 Myelinated axon sectioned at the level of an incisure of Schmidt-Lanterman. x 4,400.

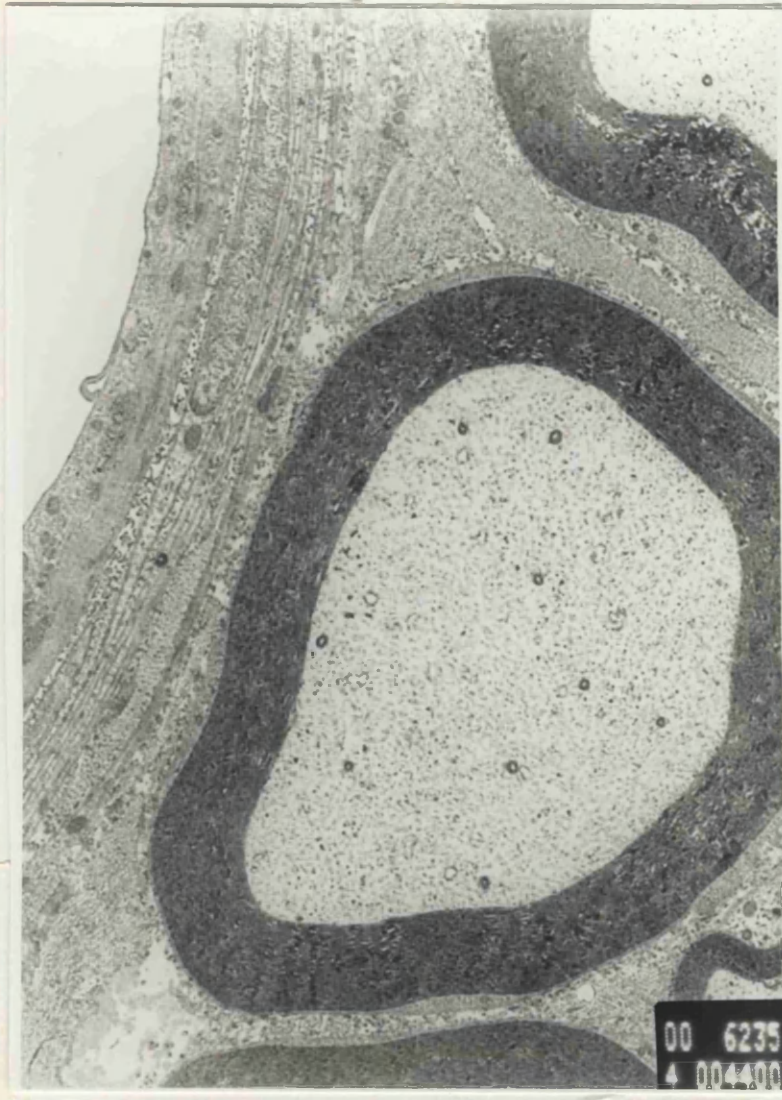

Fig. 6.11 Myelinated fibre and adjacent capillary
showing cell wall. x 4,400.
x 7,120.

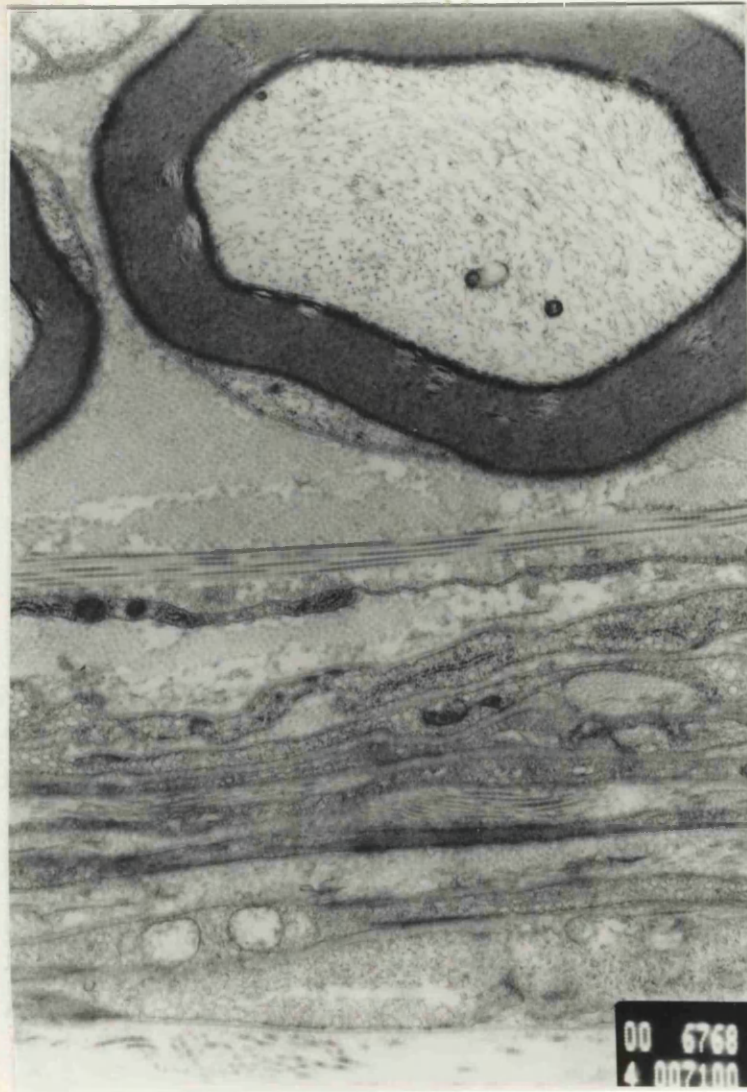

Fig. 6.12 Myelinated fibre and adjacent perineurium showing collagen in longitudinal and transverse section. x 7,100.

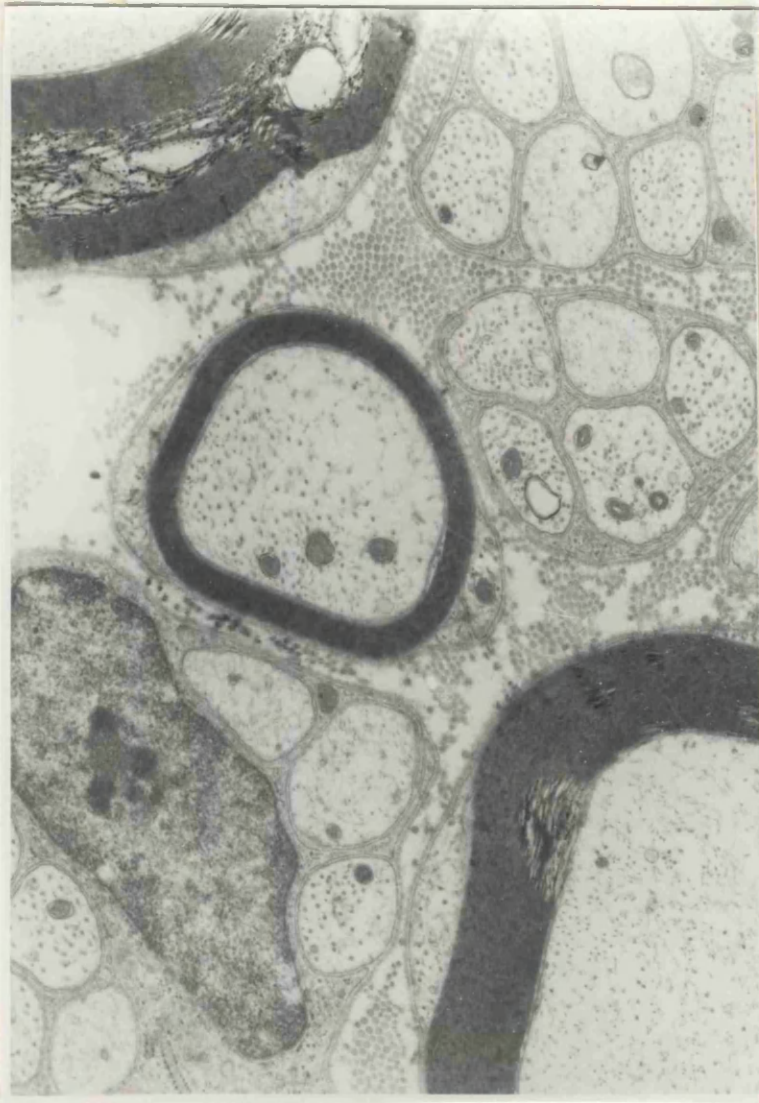

Fig. 6.13 Unmyelinated fibres enclosed by basal lamina of Schwann cell. (bottom left) x 8,300.

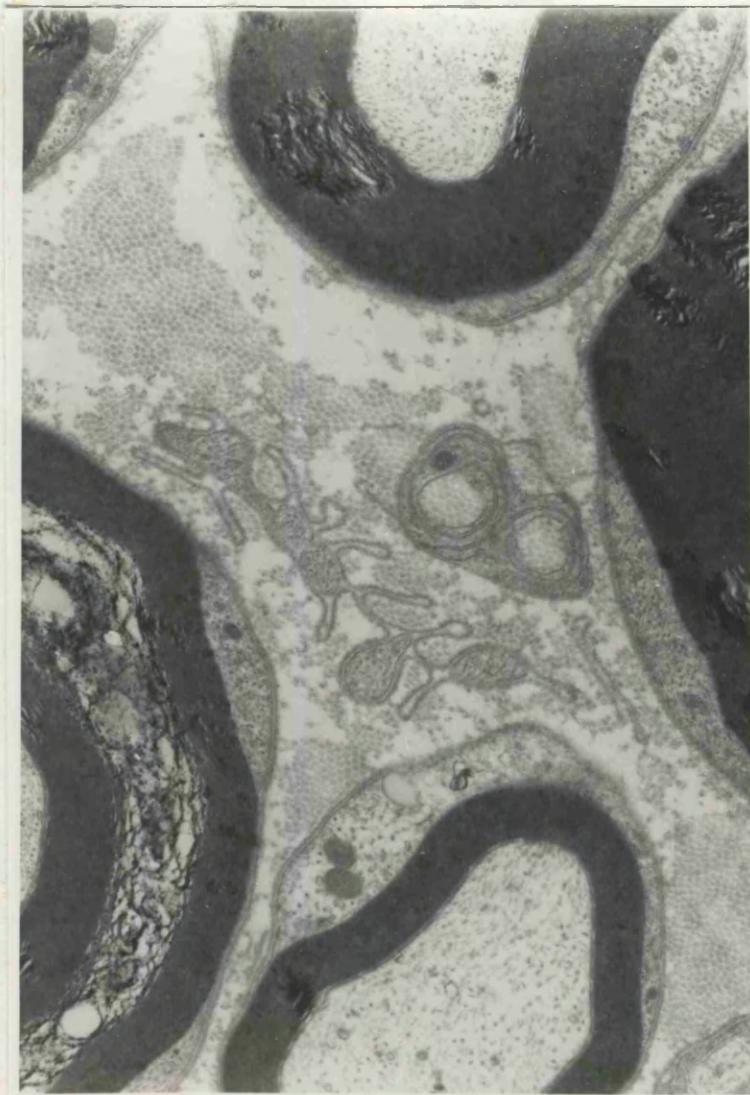

Fig. 6.14 Remnants of basal lamina - these were noted
in both insonated and control specimens.
x 8,300

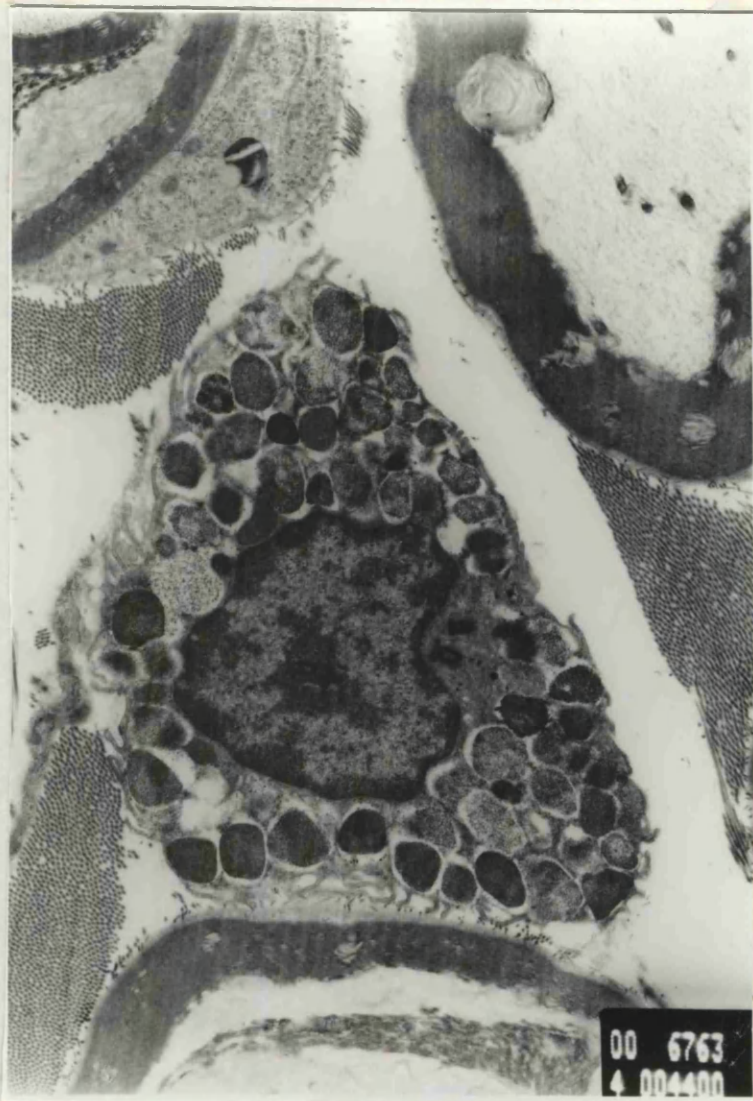

Fig. 6.15 Mast cell. x 4,400. focal re-
myelination. damage to perineurium and fibrous reaction
outside the nerve. x 2,400.

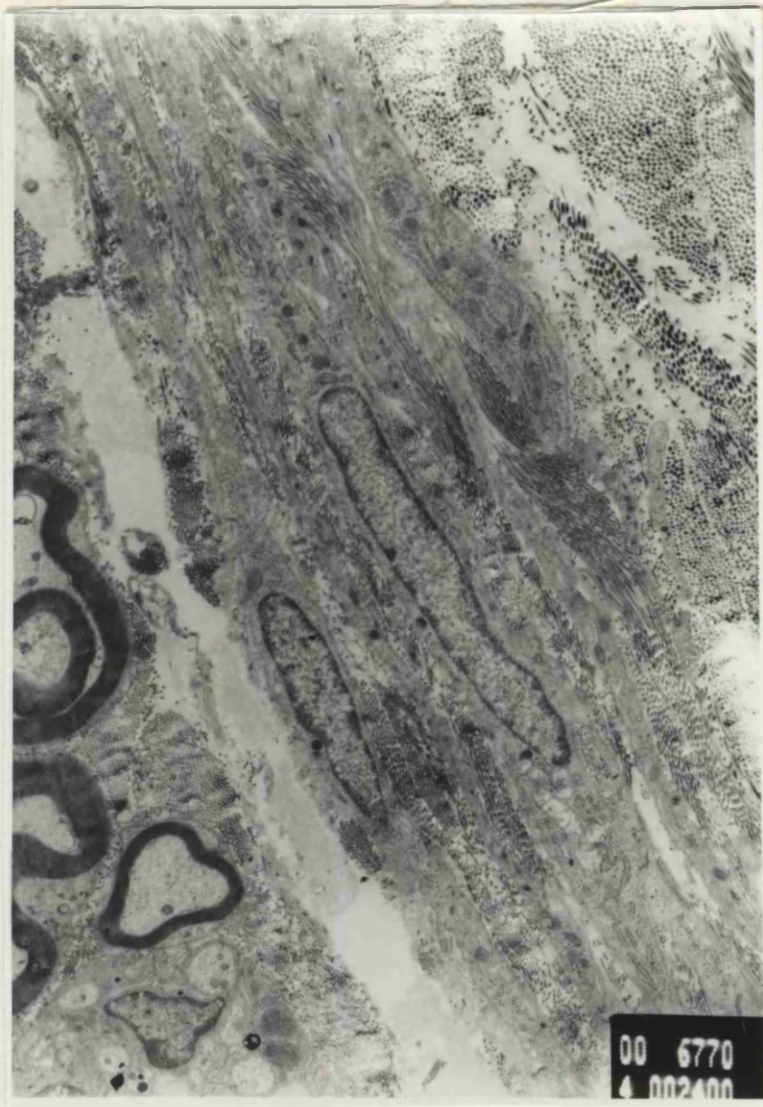


Fig. 6.16 Section of specimen R5 showing focal remyelination, damage to perineurium and fibrous reaction outside the nerve. x 2,400.

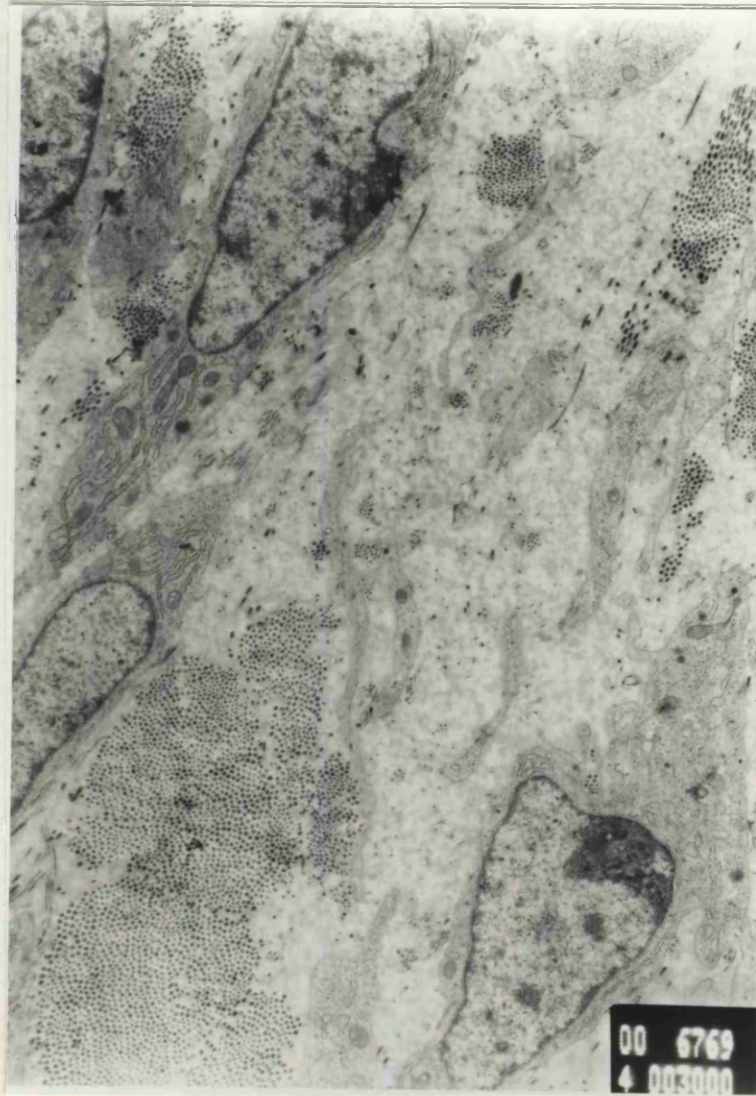


Fig. 6.17 Section of fibrous swelling associated with R5 showing fibroblasts and numerous collagen fibrils.
x 3,000

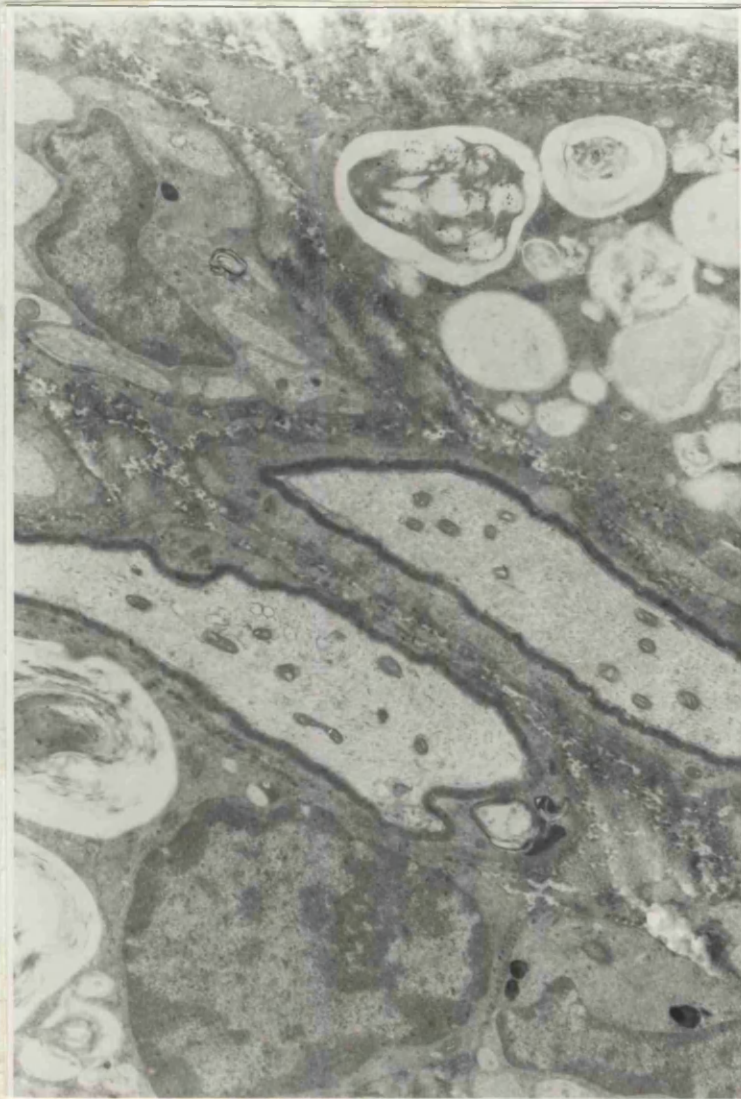
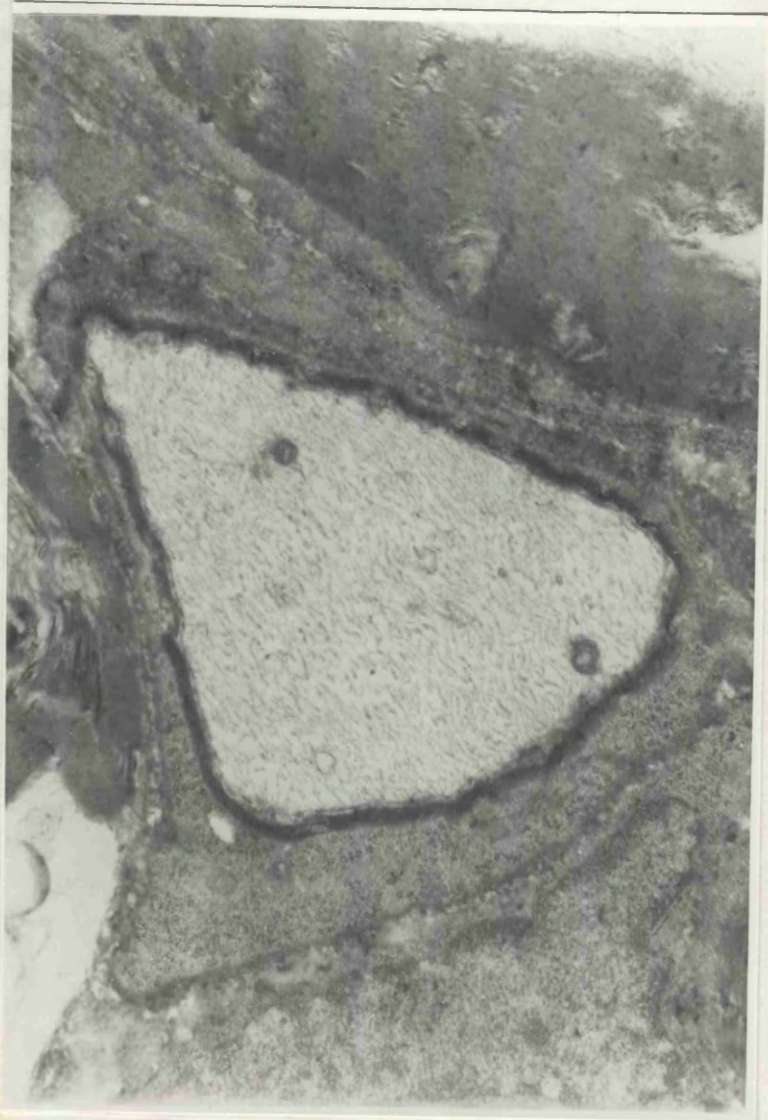

Fig. 6.18 Remyelinating axons and macrophages from specimen R5 x 5,000.

3. TRANSVERSE SPECIMENS.

There was no evidence of demyelination on the specimens by examination of both individual axons and bundles of

fibers
the
and
str
fibr
form
betw
cyto
met
adja



on
Renvier
matter
is now
as which
cell
signals for
and

Fig. 6.19 Single remyelinating axon from specimen R5.
x 8,300.

3. TEASED SPECIMENS.

There was no evidence of de-myelination on the specimens by examination of both individual axons and bundles of fibres. Examples of these preparations are shown on the following pages. There is a normal node of Ranvier and also an incisure of Schmidt-Lanterman. This latter structure was once thought to be an artefact but is now known to consist of closely packed myelin lamellae which form a funnel shaped zone of cytoplasm spiralling between the internal and external layers of schwann cell cytoplasm. They probably provide conduction channels for metabolites into the depths of the myelin sheath and adjacent axon.

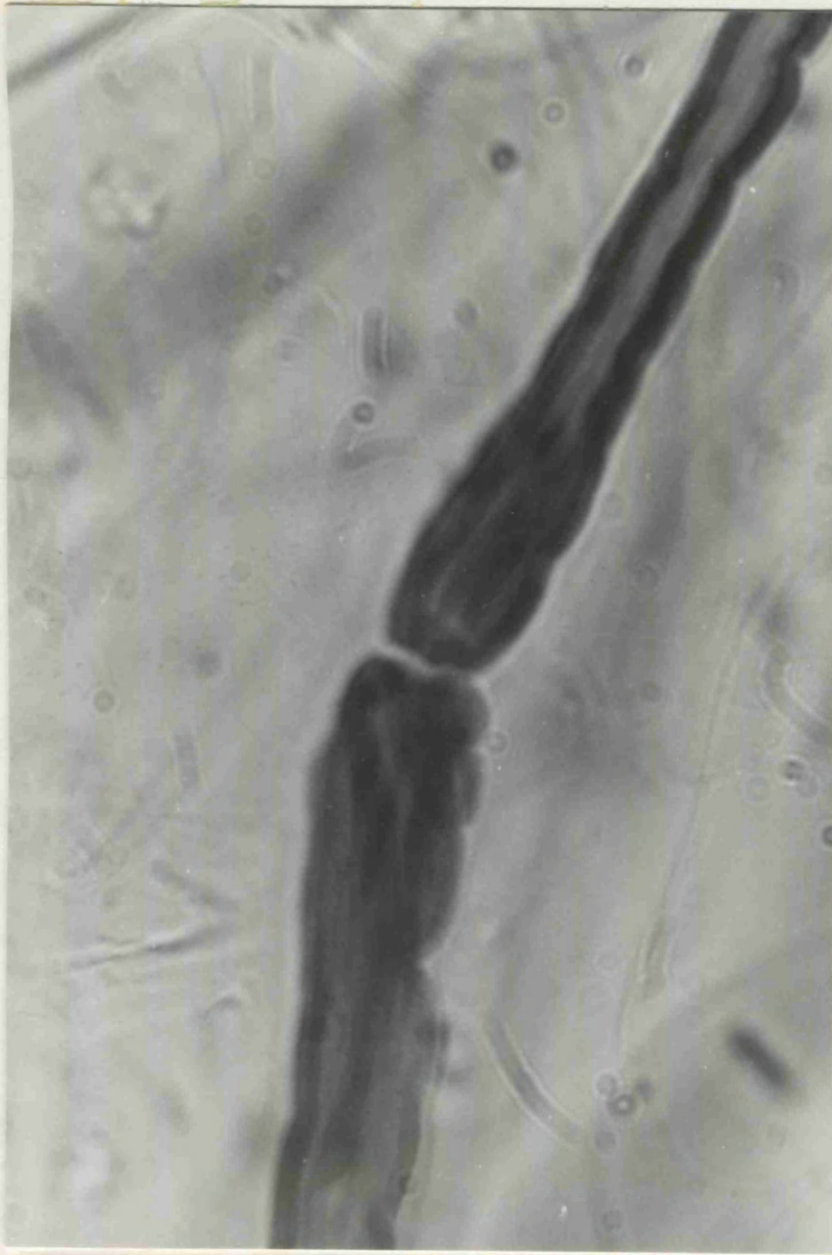

Fig 6.20 Teased axon showing node of Ranvier - x400

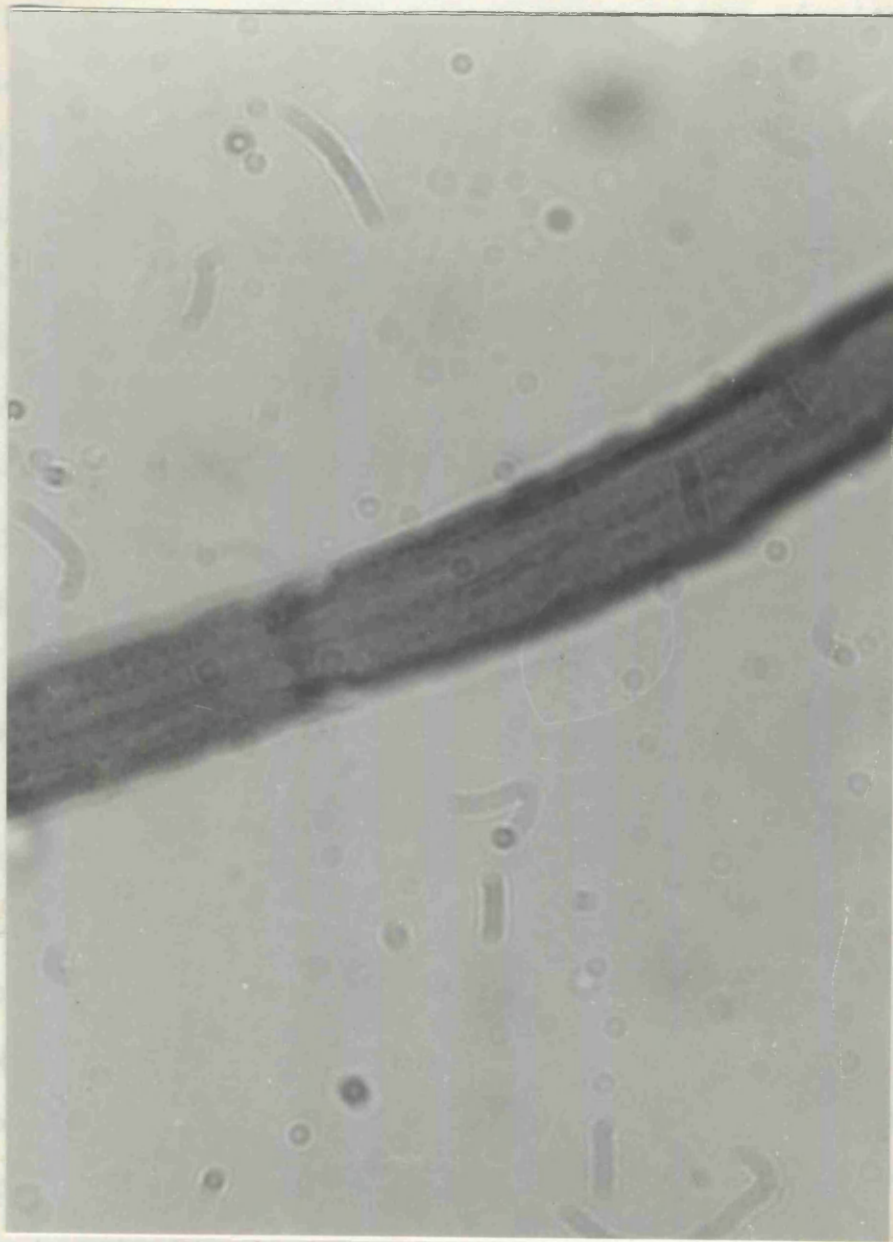

Fig.6.21 Teased axon showing incisure of Schmidt

Lanterman - x 400.

6.4 DISCUSSION.

The aim of this experiment has been to see if ultrasound causes damage to peripheral nerve under the conditions used in the diagnostic test for carpal tunnel syndrome. To see what type of damage would occur all the rules of ultrasound treatment were broken by using maximum levels of ultrasound for a prolonged period with a stationary treatment head. Evidence of any such damage would then be looked for in nerves exposed to levels of ultrasound as in the diagnostic test. In practice the duration of exposure in this test is only about five seconds but for the purpose of this experiment exposure was for 30 seconds.

The nerves were examined at two weeks as by this time evidence of structural damage would be seen. Sections were examined under the light microscope but no evidence of structural damage could be found except in specimen R5 which showed some evidence of peripheral nerve damage. The sections were then examined under the electron microscope in order to detect more subtle structural changes such as those reported by Ellisman, Palmer and André (1987) but again no changes of significance were found. As a further check for possible de-myelination sections of nerve were teased, samples being taken from different segments of the nerve. At least ten fibres from each nerve were examined under the light microscope and once more there was no evidence of myelin damage. After discussion with the Department of

Neurological Science at the Royal Free Hospital, London it was decided that more extensive teasing of at least 100 fibres from each nerve as advocated by Dyck et al (1984) was not justified in view of the failure to find any significant changes by light or electron microscopy. The axon counts showed no significant difference in the counts between experiment and control nerves ($P = 0.05$) and no demyelinated or thinly remyelinated fibres were seen.

These findings support the contention that there is no myelin damage occurring as a result of exposure to ultrasound, neither was there any evidence of axonal loss.

It became clear that interpretation of the electron micrographs would be extremely difficult without the experience gained by looking at very large numbers of specimens. Normal variants and artefacts posed a particular problem.

The situation was clarified by examination of the specimens in collaboration with Dr. Jean Jacobs at the Institute of Neurology, Queen Square, London.

Having reviewed the electron micrographs, several grids were examined again under the electron microscope.

There appeared to be no gross changes in any of the specimens apart from R5. Again the changes in the sub-perineural area adjacent to the fibrous reaction were seen with remyelination and demyelination of axons focally in this area. A possible explanation for this

is that a local high ultrasound intensity, produced by either constructive interference or cavitation, had produced a perineurial window. This concept was described by Spencer et al (1975). They produced local damage in the perineurium of the rat peroneal nerve by surgical means and then observed the subsequent localised axonal demyelination and remyelination. They found that remyelination was prominent at around twelve days.

This work has served to show that the use of ultrasound over a subcutaneous nerve under the conditions advocated for the diagnostic test for carpal tunnel syndrome, is unlikely to cause any structural damage. It also contradicts the advice given in ultrasound therapy manuals (e.g. Hoogland 1986) that peripheral nerve is extremely sensitive to ultrasound. The only convincing evidence of damage was produced under extreme conditions and probably occurred at a point of cavitation or constructive interference between an incident and reflected ultrasound beam. This would only apply when ultrasound is used incorrectly i.e. with a stationary treatment head.

CHAPTER 7.

ULTRASOUND DIAGNOSIS OF CARPAL TUNNEL SYNDROME A REPEAT ASSESSMENT.

7.1 INTRODUCTION.

The hypothesis upon which this work is based is that therapeutic ultrasound can be used to diagnose carpal tunnel syndrome. A pilot study reported in appendix i. showed a 98% correlation between E.M.G. and the ultrasound test but the series only considered nineteen cases.

A second study has therefore been undertaken to see if the previous results could be repeated and also to confirm the findings of other workers that Tinel's and Phalen's test are of little value in the diagnosis of carpal tunnel syndrome.

(Gelmers 1979, Heller et al 1986, Golding et al 1986).

7.2 Patients and Methods

Patients referred for E.M.G. diagnosis of carpal tunnel syndrome were subjected to testing with a therapeutic ultrasound unit, having first obtained informed consent. In addition both Tinel's and Phalen's tests were performed in the standard manner.

Ultrasound was administered using a Sonopuls 434 device with a 0.8cm^2 treatment head at a frequency of 1MHZ. and an amplitude of 2.0 W/CM^2 .

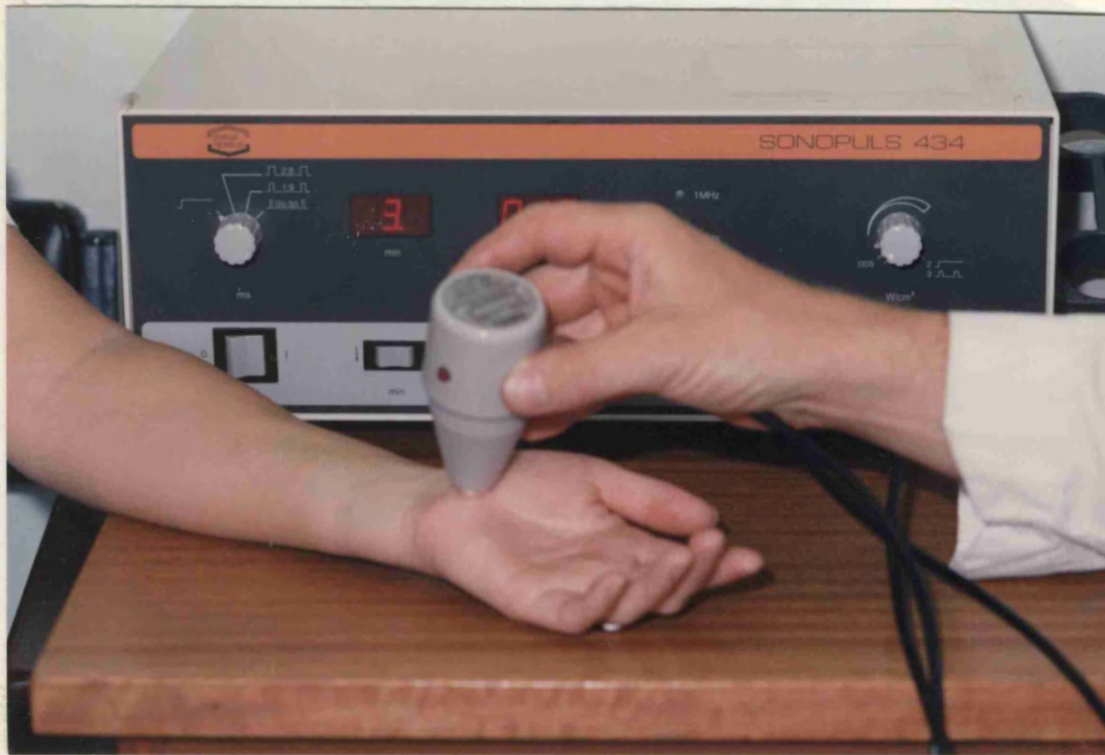

Fig. 7.1 Using a Sonopuls 434 ultrasound unit to detect carpal tunnel syndrome.

As before a couplant gel was applied to the patients wrist and the ultrasound transducer was passed slowly along the wrist in line with the ring finger. To eliminate observer bias patients were asked to describe what they experienced, if anything, and the tests were performed prior to the EMG. A positive response to the ultrasound test was regarded as the sensation of paraesthesiae or pain.

E.M.G.s were performed in a standard manner and the criteria used for a positive diagnosis of median nerve compression at the wrist were:-

1. Distal Motor Latency > 4 secs.
2. Antidromic Sensory volley < 15u volts.
3. Distal Latency, Wrist - Index <3.2 secs.
4. gross asymmetry between left and right wrists.

In addition to the above a group of 25 control subjects (50 wrists) were selected at random from a routine fracture clinic. (see appendix 4. - table 6.) These controls were not subjected to EMG studies.

7.3 RESULTS.

No. cases	=	82
(i.e. No. wrists	=	164)
Male = 26	Female =	56
Average age	=	52
Range		21 - 81
Clinically bilateral	=	33
E.M.G. bilateral	=	17

The results of each test are summarised in table 7.2. It has been assumed that a positive E.M.G. is equivalent to a definite diagnosis of carpal tunnel syndrome. This will be expanded upon in the discussion.

Table 7.2

SUMMARY OF RESULTS.

	TEST	+ EMG	- EMG	TOTAL
ULTRASOUND	+	33	17	50
	-	26	88	114
TINEL	+	16	15	31
	-	43	90	133
PHALEN	+	26	25	51
	-	33	80	113
CLINICAL	+	55	60	115
	-	4	45	49

+ EMG = CARPAL TUNNEL SYNDROME

All tests were performed immediately prior to the EMG.

The data from this study was discussed with a statistician, Dr. Brendan Burchell - University of Cambridge, who advised analysis using a 2 X 2 contingency table which is set out below :-

	EMG +	EMG -	
TEST +	a.	b.	a. + b.
TEST -	c.	d.	c. + d.
	a. + c.	b. + d.	

Using such a table one can work out an expected value for each variable i.e. what one would expect to occur by pure chance and then using the Chi ² test calculating the probability of the results occurring by chance. A

Using the above formulae the following results were obtained:-

TINEL'S TEST: $\chi^2 = 4.33$ P = 0.03
 $\delta = 0.16$

PHALEN'S TEST: $\chi^2 = 7.95$ P = 0.005
 $\delta = 0.22$

ULTRASOUND TEST: $\chi^2 = 28$ P = < 0.001
 $\delta = 0.41$

7.4 DISCUSSION.

Cases selected for this study had all been referred for EMG with a diagnosis of "? carpal tunnel syndrome". This facilitated the efficient collection of data to make a reasonably large series but had the disadvantage that the sources of referral were varied with no fixed criteria for the diagnosis of carpal tunnel syndrome. Most had typical presentations but some referrals were vague with clinical information such as "numb hands - ? CTS." As a consequence of this the number of negative EMG'S is relatively high. It was felt important to retain this negative data as it is equally valid to show that the ultrasound test is accurate in confirming a positive and a negative diagnosis of carpal tunnel

syndrome. Analysis of data from this survey proved difficult in that several variables are being compared with a standard result (EMG), which in itself is not 100% accurate. Grunberg (1983) found an 8% false negative rate in a series of carpal tunnel decompressions performed despite normal electromyography.

The question under consideration in this survey is how accurate are the various methods of diagnosing carpal tunnel syndrome? Results have been compared with EMG studies which for the purpose of this survey is taken as 100% accurate. In fact EMG detects pathological changes in nerve conduction where impairment is due to damage such as demyelination. Presumably the false negatives reported by Grunberg are early cases of carpal tunnel syndrome before nerve damage has occurred.

Both the Chi^2 tests and the Phi tests show that the ultrasound test is significantly more accurate than the Tinel and Phalen tests. If one considers how often the ultrasound test makes the correct diagnosis, i.e. positive with positive EMG and negative with negative EMG there is a 74% correlation. In the case of Tinel's test this is 64% and in Phalen's 60%.

There still remains some doubt about those cases which were EMG negative but ultrasound positive - is ultrasound detecting some EMG false negative cases? To investigate this further it will be necessary to review these cases retrospectively to see if their

symptoms resolved or if definitive treatment such as steroid injection or surgery was needed.

The results of this work do not show the high correlation found with EMG in the initial pilot study (90%) but nevertheless a 74% correlation makes the test useful as a rapid screening procedure in doubtful cases of carpal tunnel syndrome. There are two important differences in this series:-

Firstly cases in the pilot study were selected with a positive EMG and a positive diagnosis of carpal tunnel syndrome. Secondly the second series is much larger.

CHAPTER 8.

8.1 DISCUSSION.

The aim of this work has been to evaluate a diagnostic test for carpal tunnel syndrome which the author devised whilst working at Northampton General Hospital. A large number of carpal tunnel decompressions were performed and many cases were referred for E.M.G. confirmation of the diagnosis prior to surgery.

There was sometimes a considerable delay in receiving the results of this test due to a heavy demand on the E.M.G. department. There was a place for a more rapid confirmatory test which preferably could be performed in the out-patient clinic. With this in mind it was postulated that ultrasound could be used as a diagnostic aid, working rather like a sophisticated Tinel's test. Having gained the approval of the ethical committee this simple test was performed on nineteen patients who had already had the diagnosis of carpal tunnel syndrome confirmed by electromyography. The results showed a 90% correlation with electromyography but the study can be criticised as the series is small (19 patients) and only patients with positive EMG's were tested. EMG's were not performed on the control group as it was not possible to add an extra nineteen patients to an already overloaded EMG department. The study, however, served as

a pilot study prior to the more extensive investigation at Addenbrooke's hospital, Cambridge where the author investigated the use of ultrasound in this novel manner in greater detail. From discussions with physiotherapy colleagues and reading the literature it became clear that the performance of therapeutic ultrasound devices was less than ideal in many cases. At the outset of this project the Sonopuls 434 unit which was used for all the experiments was thoroughly assessed.

An initial calibration test, made with the help of the Medical Physics Department at Addenbrooke's hospital, revealed that the output of the unit was some 45% less than the stated output. This was found to be due to an incorrectly adjusted driver amplifier and once adjusted the unit was shown to be operating satisfactorily.

This calibration exercise highlights the need to check the output of therapeutic ultrasound units regularly with a device which will actually measure the intensity of ultrasound emitted from the treatment head.

It is postulated that the different results from the second clinical study were partially due to the fact that the ultrasound unit used in the pilot study, a Therasonic 1030, was giving a much higher output than that stated on the output meter although it has not been possible to confirm this.

The marked reaction produced in the rats' skin during maximum exposure to ultrasound shows the danger of incorrect treatment methods. It is instructive to note

that the skin reaction occurred at a skin temperature of 35°C and so must have been due to an isolated peak of ultrasound intensity due to incident and reflected beams or to localised cavitation. Recommendations on the use of ultrasound therapy devices advise the operator to avoid subcutaneous peripheral nerves. The test gained ethical committee approval as the exposure of the median nerve to ultrasound during the procedure amounts to a few seconds only. The dose of ultrasound applied to a tissue is time and amplitude related and so adverse effects under such conditions of use would be highly unlikely.

Nevertheless it was felt important to investigate fully the effect of ultrasound on peripheral nerve.

There are several reports in the literature on the effects of ultrasound on the conduction velocity of peripheral nerve, (see Chapter 3.3), but little has been reported on structural damage of nerve exposed to ultrasound at therapeutic levels. An experiment was therefore devised to add to the knowledge on this subject.

Electron microscopy was used as the "state of the art" method of detecting subtle structural changes in tissue. It became evident whilst preparing specimens for microscopy that peripheral nerve is extremely demanding in its requirements for good fixation and that artefact in preparation can easily be interpreted as pathology.

Much time was spent in perfecting a suitable method of tissue preparation. Following maximal exposure to ultrasound semi-thin sections of nerve were examined under the light microscope and it was expected that there would be evidence of significant de-myelination. None was found and so electron microscopy was performed and again no significant changes were found. A limited number of teased fibres were examined under the light microscope and once more no de-myelination was demonstrated. (See discussion in Chapter 6.)

Therefore, contrary to popular belief it proved difficult to produce evidence of damage in nerves subjected to maximum levels of ultrasound. In fact only one section (R5) showed significant damage in the form of focal remyelination and degeneration with a localised reaction outside the perineurium. This can be explained by the Perineurial Window Theory (see Chapter 6.4).

It could be argued that the ultrasound "missed" the relatively small sciatic nerve of the rat which is only about 2mm. in diameter but using a 5 cm.² treatment head it is extremely unlikely that three nerves in consecutive experiments were lying in a low intensity area of ultrasound. It was expected to see more widespread damage to the myelin sheath with evidence of de-myelination and degeneration.

This work has shown that at therapeutic levels ultrasound is unlikely to damage subcutaneous peripheral nerve and that there is in fact a large margin of safety

in that maximum levels did not seem to produce gross damage. There was no evidence of damage under the conditions of the diagnostic ultrasound test. The study can be criticised in that the minimum number of rats were used to gain meaningful results (six) and an obvious field of further research would be to increase the number of rats tested and also to examine the nerves at several time intervals post insonation.

The repeat assessment of the ultrasound test did not show such a good correlation with EMG as the original study but nevertheless when compared with the "Gold Standard" of EMG the results of the test proved to be statistically significant with a P value of less than 0.001 (1° of freedom). The Phi test showed the ultrasound test to be more significant than either Tinel's or Phalen's tests confirming the impression formed in the review of the history of the diagnosis of carpal tunnel syndrome. (see Chapter 1.1).

There remains an area of doubt in the tests where ultrasound was positive but the EMG was negative. In these cases it is possible that the ultrasound was giving the correct diagnosis and the EMG was giving false negative results. Grunberg (1983) claimed an 8% false negative rate for EMG by operating on symptomatic patients who had negative EMG'S. The degree of compression of the median nerve cannot be measured at operation although the surgeon often reports in the notes - "very tight ligament". It is possible that in

some cases surgery may have a placebo effect.

In the light of this work it is felt that in the presence of a convincing history, a positive ultrasound test should help to confirm the diagnosis and a 74% correlation with EMG makes the test useful as an additional rapid, non-invasive procedure which can be used by the surgeon in out-patients. There is also the important factor that the test causes minimal discomfort (if any) and inconvenience to the patient.

8.2 CONTRIBUTION TO KNOWLEDGE.

A new method is proposed for the diagnosis of carpal tunnel syndrome and following a pilot study, which gave good results in comparing this test with EMG, this method was tested on a much larger group of patients. The results of these tests when compared with EMG were not show such a high correlation as the pilot study but nevertheless they were statistically significant. ($P = < 0.001$ 1° of freedom). It is therefore suggested that the ultrasound test has a place in the diagnosis of carpal tunnel syndrome as a screening technique in doubtful cases.

There has been very little work to date carried out on the effects of ultrasound on the structure of peripheral nerve. Ellisman, Palmer and André (1987) claimed that diagnostic ultrasound may disrupt myelination. This work has shown that despite high levels of therapeutic

ultrasound minimal structural damage occurs with only focal remyelination in one case (R5) subjected to maximal ultrasound. During treatment under correct conditions with a moving transducer no damage was detected. Examination of specimens under the light and electron microscope and axon counts on sections of each nerve confirmed that there was no significant damage.

8.3 FURTHER WORK.

The clinical studies could be extended to follow up those cases with a negative EMG but a positive ultrasound test to see what proportion, if any, came to surgery.

It would be instructive to select out patients for the ultrasound test in which a confident diagnosis of carpal tunnel syndrome had been made and confirmed by electromyography. Such a series could provide valuable information, particularly if operative outcome was recorded.

The test could also be applied to other entrapment neuropathies and also to regenerating nerves as it was in this context that Tinel described his sign.

As current knowledge on the effect of ultrasound on peripheral nerve is scanty there is scope for further research in this field examining a larger number of samples and at different time intervals post insonation.

Another aspect for investigation would be the effect of pulsed ultrasound as Pickworth et al (1988) have shown that unstable cavitation is more likely (and hence tissue damage) during this mode of treatment. Unstable cavitation as demonstrated in vitro by the phenomena of sonoluminescence has not yet been demonstrated in vivo. Plans are under way to investigate this further in conjunction with the medical physics department at Addenbrooke's Hospital.

8.4 SUMMARY.

This thesis has investigated the proposal that therapeutic ultrasound can be used to diagnose carpal tunnel syndrome by irritating the compressed median nerve and causing the patient to experience paraesthesiae or discomfort in the median nerve distribution.

In the opening chapters an account has been given of the history of the diagnosis of carpal tunnel syndrome and the anatomy of the carpal tunnel outlined. The clinical picture and pathogenesis of the condition has been described in detail followed by an outline of its surgical management. There is a brief account of electromyography which currently is the only method of confirming the diagnosis. As this work is based upon the use of therapeutic ultrasound the fundamental principles of ultrasound have been described together

with an explanation of dosage and interaction with tissue. The experimental work was preceded by an assessment of the ultrasound unit which was used throughout the project.

As the test involved a novel use of ultrasound on a subcutaneous peripheral nerve, an animal model in the form of the sciatic nerve of the laboratory rat was employed and exposed to normal and maximal levels of ultrasound. The nerve was then examined under both the light and electron microscope to detect any structural damage which may be caused by ultrasound.

An account is included of a pilot study of the proposed diagnostic test compared with EMG. The initial results in twenty cases were very encouraging. This study was then continued with a larger series of 82 patients and although the results were not as good as the initial survey they were statistically significant.

This new test has shown potential as a diagnostic aid for carpal tunnel syndrome but it is concluded that electromyography remains the investigation of choice.

REFERENCES.

Abbott L.C. and Saunders J.B. del M. (1933) Surg. Gynae. Obs., 57, 507.

Injuries of the median nerve in fractures of the lower end of the radius.

Adamson J.E., Sprouji S.J., Horton C.E. and Mladick R.A. (1971)

Plast. Recon. Surg., 47, 332.

The acute carpal tunnel syndrome.

Allen K.C.R. and Battye C.K. (1977) DHSS Scientific and Technical Branch Report 16/17.

Evaluation of four ultrasonic therapy units.

Anson L.W. and Chivers R.C. (1982) J. Med. Eng. Tech., 6, 150.

A rugged strain gauge ultrasound therapeutic exposiometer.

Bedford A.F., Glasgow M.M., and Wilson J.N. (1982) Injury 14, 180.

Ultrasonic assessment of fractures and its use in the diagnosis of scaphoid fracture.

Baldes E.J., Herrick J.F. and Strobel C.F. (1954) Am. J. Phys. Med., 33, 21. Biologic effects of ultrasound.

- Bendler E.M., Greenspan B., Yu J. and Erdman W.J. (1977)
Arch. Phys. Med. Rehab., 58, 362.
The bilaterality of carpal tunnel syndrome.
- Blair S.J. (1988) Orth. Clin. North Am. 19, 125.
Avoiding complications of surgery for nerve compression syndromes.
- Bleecker M.L., Bohlman M., Moreland R. and Tipton A. (1985) Neurology, 35, 1599.
Carpal tunnel syndrome. Role of canal size.
- Brain W.R., Wright A.D. and Wilkinson M. (1947) Lancet, 1, 277,
Spontaneous compression of both median nerves in the carpal tunnel.
- Brown P.W. (1970) Clin. Orthop., 68, 14.
The time factor in surgery of upper extremity peripheral nerve injuries.
- Buchthal F. and Rosenfalk A. (1971) J. Neurol. Neurosurg. Psych., 34, 243.
Sensory conduction from digit to palm and palm to wrist in carpal tunnel syndrome.
- Camitz H. (1929) Acta. Chir. Scand., 65, 77.
Über die be handlung der oppositionslämung.

Cannon B.W. and Love J.G. (1946) *Surgery*, 20, 210.

Tardy median palsy: Median neuritis; Median thenar neuritis amenable to surgery.

Case D.B. (1967) *B. J. Clin. Pract.*, 21, 254.

An acute carpal tunnel syndrome in a haemophiliac.

Conolly W.B. (1984) *A Colour Atlas of Treatment of Carpal Tunnel Syndrome*. Wolfe Medical, London.

Currier D.P., Greathouse D. and Swift T. (1978) *Arch. Phys. Med. Rehab.*, 59, 181.

Sensory nerve conduction, effect of ultrasound.

Cseuz K.A., Thomas J.E. and Lambert E.H. (1966) *Mayo clin. Proc.*, 41, 232.

Long term results of operation for carpal tunnel syndrome.

Curtiss R.M. and Eversman W.W. (1973) *J.B.J.S.* 55A, 733.
Internal neurolysis as an adjunct to the treatment of carpal tunnel syndrome.

Das S.K. and Brown H.G. (1976) *Hand*, 8, 243.

In search of complications in carpal tunnel decompression.

Dekel S., Papaioannou T., Rushworth G. and Coates R.
(1980) B.M.J. 280, 1297. Iodipathic carpal tunnel
syndrome caused by carpal stenosis.

Drucker W.R., Hubay C.A., Holden W.D. et al. (1959)
Am.J.Surg., 97,454. Pathogenesis of post traumatic
sympathetic dystrophy.

Dyck P.J, Thomas P.K., Lambert E.H. and Bunge R.(1984)
Peripheral Neuropathy. 2nd. Ed., Vol. I., Saunders,
Philadelphia.

Dyson M., Pond J., Woodward B. and Broadbent J. (1974)
Ult. Med. Biol., 1, 133.
The production of blood vessel stasis and endothelial
damage in the blood vessel of chick embryos treated with
ultrasound in a stationary wave field.

Dyson M. (1987) Physiotherapy, 73, 116.
Mechanisms involved in therapeutic ultrasound.

Ehrman L., Lechner K., Mamoli B., Novotny C. and Kos K.
(1981) J. Neurol., 225, 175

Ellisman M.H., Palmer D.E. and André M.P. (1987) Exp.
Neurol., 98, 78.
Diagnostic levels of ultrasound may disrupt myelination.

Entin M.A. (1968) Surg. Clin. N. Am., 48, 1097.

Carpal tunnel syndrome and its variants.

Fahr L.M. and Sauser D.D. (1988) Orth. Clin. N. Am., 19,
27. Imaging of peripheral nerve lesions.

Farmer W.C. (1968) Phys. Ther., 48, 1233.

Effects of ultrasound on conduction of motor axons.

Ford D.J. and Ali M.S. (1986) J.B.J.S., 68B, 758.

Acute carpal tunnel syndrome - complications of delayed
compression.

Garstman G., Kovach J., Crouch C. et al. (1986) J. Hand
Surg., 11, 372.

Carpal arch alteration following carpal tunnel release.

Gelberman R.H., Aronson D. and Weisman M.H. (1980)
J.B.J.S., 62A, 1181. Carpal tunnel syndrome.

Gelberman R.H., Hergenroeder P.T., Hargens A.R.,

Lundborg G.N. and Akeson W.H. (1981) J.B.J.S., 63A, 380.

The carpal tunnel syndrome; a study of carpal canal
pressures.

Gelberman R.H., Szabo R.M., Williamson R.V. and Dimick
M.P. (1983) J.B.J.S., 65A, 632.

Sensibility testing in peripheral nerve compression
syndromes; an experimental study in humans.

Gelmers H.J. (1979) Acta. Neurochir.(Wien), , 225.

The significance of Tinel's sign in the diagnosis of carpal tunnel syndrome.

Gilliat R.W. and Wilson T.G. (1953) Lancet, 2, 596.

A pneumatic tourniquet test in the carpal tunnel syndrome.

Gilliat R.W., Ochoa J., Rudge P. et al. (1974) Trans Am. Neurol. Assoc., 99, 71.

The cause of nerve damage in acute compression.

Glauert A.M. (1984) Practical Methods in Electron Microscopy., North Holland, Amsterdam.

Golding D.N., Rose D.M. and Selvarajah K. (1986) Br. J. Rheum. 4, 388.

Clinical tests for carpal tunnel syndrome - an evaluation.

Gray's Anatomy (1980) 36th Ed., 1099. Eds. Williams P.L. & Warwick R., Churchill Livingstone, Edinburgh.

Grunberg A.B. (1983) J. Hand Surg., 8, 348.

Carpal tunnel decompression despite normal electromyography.

Gutman L., Gutierrez A., and Riggs J.E. (1986) J. Neurol. Neurosurg. Psych., 49, 220.

The Flick sign in carpal tunnel syndrome.(letter).

Halle J.S, Scoville C.R. and Graethouse D.G. (1981) Phys. Ther., 61, 345. Ultrasound's effect on the conduction latency of the superficial radial nerve in man.

Harris C.M., Tanner E., Goldstein M.N., and Pettee D.S. (1979) J.B.J.S., 61A, 93.

The surgical treatment of carpal tunnel syndrome correlated with pre-operative nerve conduction studies.

Heller L., Ring H., Costeff H. and Solzi P. (1986) Eur. Neurol., 25, 40. Evaluation of Tinel's and Phalen's signs in the diagnosis of carpal tunnel syndrome.

Herrick R.T. and Herrick S. (1987) J. Hand Surg., 12, 931. Thermography in the detection of carpal tunnel syndrome and other compressive neuropathies.

Herrick R.T., Herrick S., Purohit R. and Smith L. (1986) Postgrad. Med., March, 78. Liquid crystal thermography in the detection of carpal tunnel syndrome.

Homans J. (1960) N. Eng. J. Med., 222, 870.

Minor causalgia. A hyperesthetic neurovascular syndrome.

Hoogland R. (1986) *Ultrasound Therapy*, Enraf Nonius, Holland.

Hunt J.R. (1909) *Trans. Am. Neurol. Assoc.* 35, 184
Occupation neuritis of the thenar branch of the median nerve: a well defined type of atrophy of the hand.

Hunt J.R. (1911) *Am. J. Med. Sci.* 141, 224.
The thenar and hypothenar types of neural atrophy of the hand.

Hutton P., Kernohan J. and Birch R. (1981) *Hand*, 13, 85.
An anomalous flexor digitorum superficialis indicis muscle presenting as carpal tunnel syndrome.

John V., Nau H.E., Nasher H.C., Reinhardt V. and Venjakob K. (1983) *Am. J. Neuro. Radiol.* 4, 770.
C.T. of carpal tunnel syndrome.

Karnovsky M.J. (1965) *J. Cell Biol.*, 27, 137.
A formaldehyde-glutaraldehyde fixative of high osmolality for use in electron microscopy.

Keen W.W. (1907) *Am. J. Med. Sci.*, 133, 193.
The symptomatology, diagnosis and surgical treatment of cervical rib.

Kilgore E.S. and Graham W.P. (1977) The Hand - Surgical and Non Surgical Treatment. Lea and Febiger, Philadelphia.

Kinnier Wilson S.A. (1913) Proc. Roy. Soc. Med., 6, 133.
Some points on the symptomatology of cervical ribs with especial reference to muscular wasting.

Kortilla K., Hakkinen S. and Linnoila M. (1975) Acta. Anaesth. Scand., 19, 384.

Side effects and skills related to driving after intramuscular administration of bupivacaine and etidocaine.

Kosin F., Soin J.S., Ryan L.M. et al. (1981) Radiology, 138, 437.

Bone scintillation in the reflex sympathetic dystrophy syndrome.

Kremer M., Gilliat R.W., Golding J.S.R. and Wilson T.G. (1953) Lancet 2, 590.

Acroparaesthesia in the carpal tunnel syndrome.

Kugelberg E. (1946) Brain, 69, 310.

"Injury activity" and trigger zones in human nerves.

Kugelberg E. and Cobb W.A. (1951) J. Neurol. Neurosurg. Psych., 14, 88. Repetitive discharges in human motor nerve fibres during the post ischaemic state.

Lamb D.W. and Kuczynski K. (1981) The Practice of Hand Surgery. 400, Blackwell, Oxford.

Lancourt J.E., Gilbert M.S. and Posner M.A. (1977) J.B.J.S., 59A, 451.
Management of bleeding and associated complications of haemophilia in the hand and forearm.

Langloh N. and Linscheid R.L. (1972) Clin. Orth., 83, 41.
Recurrent and unrelieved carpal tunnel syndrome.

Langford L.A. and Coggeshall R.E. (1980) Anat. Rec., 197, 297.
The use of potassium ferricyanide in neural fixation.

Lanz V. (1972) J. Hand Surg., 2, 44.
Anatomical variations of the median nerve in the carpal tunnel.

Lavey E.B. and Pearl R.M. (1981) Annals Plast. Surg. 7, 236.
Patent median artery as a cause of carpal tunnel syndrome.

Learmonth J.R. (1933) Surg. Clin. N. Am., 13, 905.

The principles of decompression in treatment of certain diseases of peripheral nerves.

Lightman H.I., Pochaczewsky R., Aprin H. and Iiowite N. (1987) J. Paeds., III, 551.

Thermography in childhood reflex sympathetic dystrophy.

Lloyd J.J. and Evans J.A. (1988) Physiotherapy, 2, 56.

A calibration survey of physiotherapy ultrasound equipment in North Wales.

Long D.M. (1980) Neurosurgery, 6,317.

Surgical treatment of chronic pain.

Lowry W.E. and Follender A.B. (1988) Clin. Orth. 227, 251.

Inter-fascicular neurolysis in severe carpal tunnel syndrome - a prospective randomised double blind controlled study.

MacDonald R.I., Lichtman D.M. (1978) J. Hand Surg., 3,70.

Complications of surgical release for carpal tunnel syndrome.

Madsen P.W. and Gersten J.W. (1961) Arch. Phys. Med. Rehab., 42, 645.

Effects of ultrasound on conduction velocity of peripheral nerves.

Mannerfelt L. (1966) Acta. Orthop. Scand. (Suppl.) 87,1. Studies on the hand in ulnar nerve paralysis. A clinical-experimental investigation in normal and anomalous innervation.

Marie P. and Foix C. (1913) Revue Neurology (Paris), 26, 647.

Atrophie isolée de l'éminence thénar d'origine névritique. Rôle du ligament annulaire antérieur du carpe dans la pathogénie de la lésion.

Melzack R. and Wall P.D. (1965) Science, 150, 971.

Pain mechanisms - a new theory.

Middleton W.D., Kneeland J.B., Kelluran G.M. et al. (1987) Am. J. R., 148, 307.

MR imaging of the carpal tunnel: Normal anatomy and preliminary findings in the carpal tunnel syndrome.

Mitchell S.W., Morehouse G.R., and Keen W.W. (1864) Gunshot Wounds and Other Injuries of the Nerves., J.P. Lippincott, Philadelphia.

Moersch F.P. (1938) Proc. Staff Meetings Mayo Clin.,
220. Median thenar neuritis.

Molitor P.J.A. (1988) J. Hand Surg., 13, 40.

A diagnostic test for carpal tunnel syndrome using
ultrasound.

Monheim M.S. and Gribble J.J. (1984) J. Hand Surg., 9A,
580. Carpal tunnel syndrome in haemophilia.

Nather A. and Pho R.W. (1981) Hand 13, 87.

Carpal tunnel syndrome produced by an organising
haematoma within the anomalous second lumbrical muscle.

Nissenbaum M. (1980) J. Hand Surg., 5, 544.

Treatment considerations and carpal tunnel syndrome with
co-existent Dupuytren's disease.

Paget J. (1865) Lectures on surgical pathology. 3rd. ed.
p.50. Lindsay and Blakiston, Philadelphia.

Pfeffer G.B., Gelberman R.H., Boyes J.H., Rydevik.

(1988) J. Hand Surg., 13B,28.

The history of carpal tunnel syndrome.

Phalen G.S., Gardner W.J. and La Londe A.A. (1950)
J.B.J.S., 32A, 109.

Neuropathy of the median nerve due to compression
beneath the transverse carpal ligament.

Phalen G.S. (1951) J.A.M.A., 145, 1128.

Spontaneous compression of the median nerve at the wrist.

Phalen G.S. (1966) J.B.J.S., 48A, 211.

The carpal tunnel syndrome. Seventeen years experience in diagnosis and treatment in 634 hands.

Phalen G.S. (1968) Cleve. Clin. Q., 35,1.

The diagnosis of carpal tunnel syndrome.

Phalen G.S. (1970) J.A.M.A., 212, 1365.

Reflections on 21 years experience with the carpal tunnel syndrome.

Phalen G.S. (1972) Clin. Orth., 83, 29.

The carpal tunnel syndrome - clinical evaluation of 598 hands.

Pickworth M.J.W., Dendy P.P, Leighton T.G. and Walton A.J. (1988) Phys. Med Biol., 33, 1249.

Studies of the cavitation effects of clinical ultrasound by sonoluminescence - threshold for sonoluminescence from a therapeutic ultrasound machine and the effect of temperature and duty cycle.

Pryse - Phillips W.E. (1984) J. Neurol. Neurosurg. Psych., 47, 870.

Validation of a diagnostic sign in carpal tunnel syndrome.

Putnam J.J.(1880) Archives of Medicine (New York),4,147.
A series of cases of paresthesiae mainly of the hand, of periodical recurrence and possibly of vasomotor origin.

Radford P.J. and Matthewson M.H. (1987) J. Hand Surg., 12B, 236.

Hypoplastic scaphoid - an unusual cause of carpal tunnel syndrome.

Repacholi M.H. and Benwell D.A. (1978) Health Phys., 36, 679. Using surveys of ultrasound therapy devices to draft performance standards.

Robbins H. (1963) J.B.J.S., 45A, 953.

Anatomical study of the median nerve in carpal tunnel syndrome.

Ros R.N., Sourkes A.M. and Sanderman J.M. (1984) Health Phys., 47, 595.

Survey of ultrasound therapy devices in Manitoba.

Royle N.D. (1938) J.A.M.A., 111, 612. An operation for paralysis of the intrinsic muscles of the thumb.

Sabatini D.D., Bensch K. and Barnett R.J. (1963) J. Cell Biol., 17, 19. Cytochemistry and electron microscopy. The preservation of cellular ultrastructure and enzyme activity by aldehyde fixation.

Sargent P. (1921) Brain, 44, 95. Lesions of the brachial plexus associated with rudimentary ribs.

Schutzer S.F. and Gossling H.R. (1966) J.B.J.S., 66A, 625. The treatment of reflex sympathetic dystrophy syndrome.

Simpson J.A. (1956) J. Neurol. Neurosurg. Psych., 19, 275. Electrical signs in the diagnosis of carpal tunnel and related syndromes.

Spencer P.S., Weinberg H.J., Raine C.S. and Prineas J.W. (1975) Brain Research 96, 323-329. The perineurial window - a new model of focal demyelination and remyelination.

Spindler H.A. and Dellon A.L. (1982) J. Hand Surg., 7, 260. Nerve conduction studies and sensibility testing in carpal tunnel syndrome.

Sunderland S. (1976) J. Neurol. Neurosurg. Psych., 39, 615. The nerve lesion in the carpal tunnel syndrome.

Sunderland S. (1978) Nerves and Nerve Injuries. 2nd. Ed., Churchill Livingstone, Edinburgh.

Taleisnik J. (1973) J.B.J.S. 55A, 1212.

The palmar cutaneous branch of the median nerve and the approach to the carpal tunnel - an anatomical study.

Tanzer R.C. (1959) J.B.J.S., 41A, 626. The carpal tunnel syndrome - a clinical and anatomical study.

ter Haar G.R., Daniels S. (1981) Phys. Med. Biol. 26,1145.

Evidence for ultrasonically induced cavitation in vivo.

ter Haar G.R., Dyson M. and Smith S. (1979) Ult. Med. Biol. 5,167. Ultrastructural changes in the mouse uterus brought about by irradiation at therapeutic intensities in standing wave fields.

Thomas J.E., Lambert E.H., Kalman A. and Cseuz A. (1967) Arch. Neurol., 16, 635.

Electrodiagnostic aspects of carpal tunnel syndrome.

Thompson T.C. (1942) J.B.J.S., 24, 632.

Modified operation for opponens paralysis.

Tinel J. (1915) *La Presse Médicale*, 23, 388.

Le signe du fourmillement dans les lésions des nerfs périphériques.

Wartenberg R. (1939) *Arch. Neurol. Psych.*, 42, 373.

Partial thenar atrophy.

Williams A.R. (1983) *Ultrasound - Biological Effects and Potential Hazards*. Academic Press, London.

Watson-Jones R. (1929) *Proc. R. Soc. Med.* 22, 1071.

Carpal semilunar dislocations and other wrist dislocations with associated nerve lesions.

Zabriske E.G., Hare C.C., and Masselink R.J. (1935) *Bulletin of Neurol. Inst. of N.Y.*, 4, 207.

Hypertrophic arthritis of cervical vertebrae with thenar muscular atrophy occurring in three sisters.

Zachary R.B. (1945) *Surg. Gynae. Obs.*, 81, 213.

Thenar palsy due to compression of the median nerve in the carpal tunnel.

Zankel H.T. (1966) *Arch. Phys. Med. Rehab.*, 47, 787.

Effect of physical agents on motor conduction velocity of the ulnar nerve.

APPENDIX 1.

A DIAGNOSTIC TEST FOR CARPAL TUNNEL SYNDROME USING ULTRASOUND

i.1 Introduction.

The hypothesis upon which this work is based is that therapeutic ultrasound can be used to reproduce the symptoms of carpal tunnel syndrome by irritating the compressed median nerve in the carpal tunnel. A pilot study was therefore designed to test this hypothesis.

i.2 Patients and Methods.

Patients entered into the study had been referred for E.M.G. studies for the diagnosis of carpal tunnel syndrome. The results were reported as:-

1. Normal.
2. Suggestive of mild compression of the median nerve in the carpal tunnel.
3. Suggestive of moderate compression.
4. Suggestive of severe compression.

Each patient then had both wrists tested with an Electromedical Supplies Therasonic 1030 Ultrasound unit using a 5 cm² treatment head. Tests were performed on both wrists at a continuous output of 1 MHZ and amplitudes of:-

1.0 W/cm² 1,5 W/cm² 2.0 W/cm²

Ultrasonic coupling medium was applied to both wrists and the probe passed from the proximal wrist crease a distance of 5cms. distally in line with the ring finger in a slow movement. The patient's response was recorded as :-

- A. Nothing
- B. Warmth only
- C. Paraesthesiae - distribution noted.
- D. Discomfort / pain
- E. Other

Each test took approximately five minutes and was performed by a physiotherapist, after informed consent had been obtained.

i.3 Results

19 patients were tested and of these 17 had a positive ultrasound test i.e. they experienced paraesthesiae, discomfort or pain over the carpal tunnel or median nerve distribution.

In two cases, pain was felt in the other wrist although that had a normal E.M.G.

12 patients had a positive E.M.G. result in both wrists, of which 11 had positive ultrasound tests in both wrists. Seven patients had bilateral symptoms.

In addition a group of normal controls was tested, having excluded conditions such as rheumatoid arthritis,

pregnancy or peripheral neuropathy. The age range was 23 - 79 years (mean 49). Of the control group of 16 wrists, only one patient felt discomfort at an intensity of 1.5 W/cm² in one wrist. One felt pain in both wrists at an intensity of 2.0 W/cm².

1.4 Discussion.

The results of this preliminary survey show a good correlation between E.M.G. and ultrasound and it is hoped that the technique may be used to augment nerve conduction studies. The study can be criticised for the small number of patients in the series and the fact that the control group did not have EMG's performed. However, it is suggested that the technique of ultrasound diagnosis described is a rapid non - invasive method which is more acceptable to patients than electromyography. Patients involved in the study experienced discomfort no worse than their carpal tunnel symptoms and several commented that they felt the test was less stressful than E.M.G. Molitor (1988).

APPENDIX 2.

ACUTE CARPAL TUNNEL SYNDROME IN HAEMOPHILIA.

ii.1 Introduction.

Acute median nerve compression at the wrist differs from the classical carpal tunnel syndrome in its aetiology and presentation.

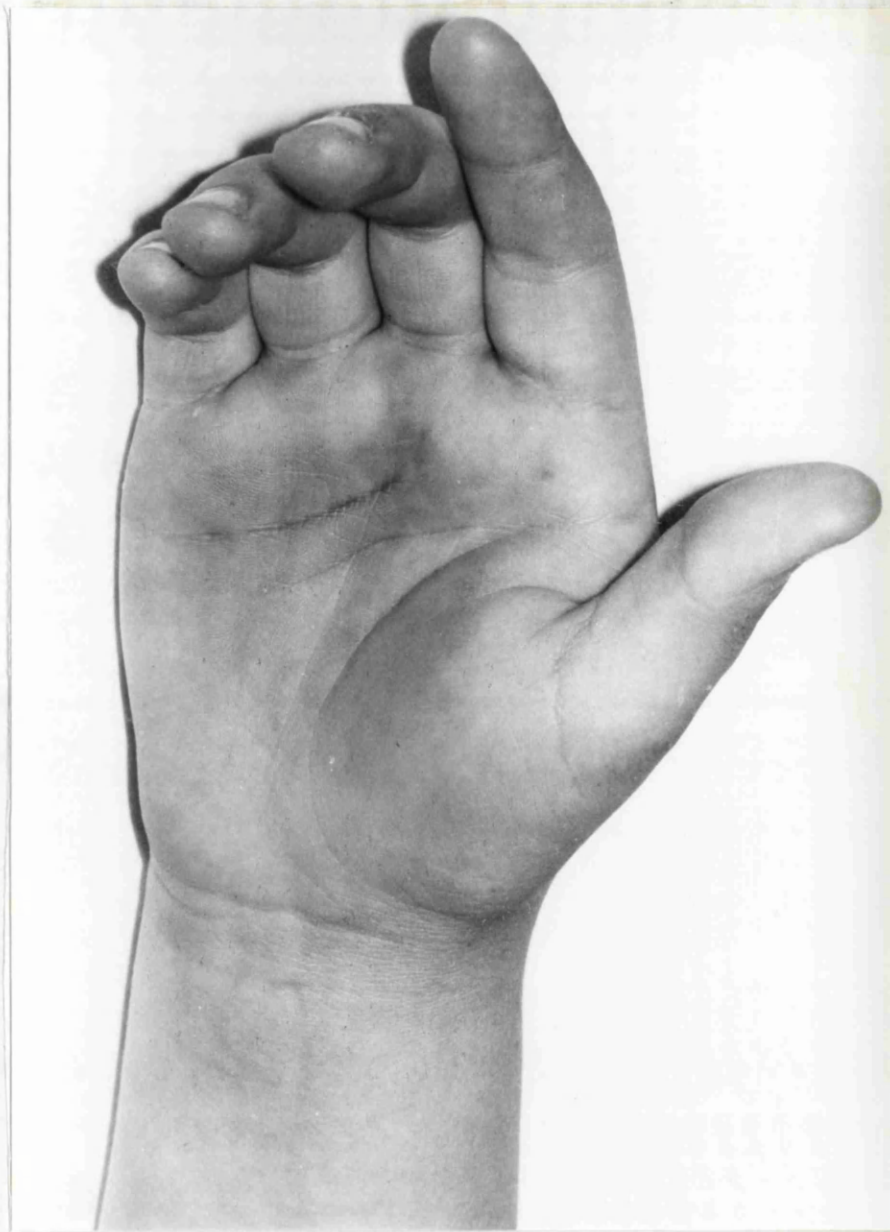
There is a rare association with haemophilia and a case is reported in this paper. A review of the literature over the past twenty years revealed only nine cases. It is suggested that management of these cases should be conservative in the first instance with factor VIII replacement continued for three to five days. Surgical decompression is indicated if symptoms fail to resolve in the first twenty four hours.

A case is reported of a thirteen year old haemophiliac who presented with an acute carpal tunnel syndrome.

ii.2 Case report.

A thirteen year old 60kg. boy with severe haemophilia A (factor VIII < 1%) was admitted with a history of spontaneous onset of pain and swelling in the right hand. The symptoms had started five days previously and suspecting a bleed he had treated himself with 500IU of high purity heat treated human factor VIII (Elstree). Over the next twelve hours there was some reduction in

the pain, but this then worsened over the next few days and became associated with paraesthesiae in the fingers. Despite these symptoms he did not give himself further factor VIII. On the day of admission the pain had become suddenly much worse. On examination there was obvious palmar bruising and swelling extending under the flexor retinaculum (see figure ii.1). All movements of the hand and wrist were painful and there were signs of median nerve compression with decreased sensibility in the median nerve distribution and a positive Tinel's sign. There was no forearm tenderness and both radial and ulnar pulses were present at the wrist. Full blood count revealed a normal platelet count, clotting studies showed a normal prothrombin time and the expected prolonged kaolin and partial thromboplastin time. He was treated with 2500IU of human factor VIII (see above). which raised his factor VIII level to 81% and his arm was elevated overnight. Twelve hours later there was marked improvement of all his symptoms. He was treated with further factor VIII over the next three days to keep the factor VIII levels between 25 and 50% and allowed to exercise the hand gently. One week later he had made a full recovery with no residual signs of median nerve compression.



**Fig. ii.1 Acute carpal tunnel syndrome in a haemophiliac
- palmar bruising and swelling at the wrist.**

ii.3 Discussion.

Carpal tunnel syndrome presenting in childhood and adolescence is in itself very uncommon. The association with haemophilia is a recognised rare complication and I have reviewed the literature over the last twenty years to find only nine reported cases. Of these two were below the age of eighteen, one in a sixteen year old following trauma to the wrist, (Adamson et al 1971) and one of spontaneous onset in a five year old. (Case 1967).

A review of peripheral nerve lesions in haemophiliacs (Ehrman et al 1981) revealed 36 lesions over a 27 year period in 234 haemophiliacs (15.4%). Of these femoral nerve involvement was the commonest due to haemorrhage into the iliopsoas muscle. There were only two cases of carpal tunnel syndrome in the series. A paper looking specifically at forearm and hand complications in 200 haemophiliacs over a seven year period again reported only two cases of carpal tunnel syndrome (Lancourt, Gilbert and Posner 1977).

Peripheral nerve lesions in haemophilia can be caused by several mechanisms. A haematoma can compress the median nerve as in the reported case or ischaemia can cause damage as a feature of Volkman's contracture. It is also possible that haemorrhage can occur into the nerve sheath and this was reported in a patient with evidence of median nerve compression at the wrist who failed to respond to conservative treatment (Monheim and Gribble

1984). In the haemophiliac presenting with pain and/or neurological impairment in the hand, the possibility of acute carpal tunnel syndrome should be considered. The diagnosis in this situation poses several problems. As stated earlier, the classic symptoms and signs of carpal tunnel syndrome are not always evident in the acute case. Pain around the wrist can be caused by haemarthrosis and an old haemarthrosis may cause functional impairment of intrinsic muscle function and forearm haemorrhage may cause more proximal median nerve compression.

It is agreed that in acute median nerve compression associated with wrist trauma and uncomplicated by a bleeding diathesis, urgent surgical decompression is indicated (Ford and Ali 1986).

The literature was not in agreement on the management of the haemophiliac. Of the papers reviewed six cases were treated conservatively and three surgically. All made a full recovery apart from one case with an 80% recovery in the conservative group. This patient had factor VIII inhibitors and therefore could not receive replacement therapy. It would seem therefore, that conservative management is to be recommended in the first instance. Factor VIII levels should be raised to 25-50% by replacement therapy and maintained for three to five days. The arm should be elevated until pain is relieved and normal sensibility returns. Gentle mobilisation may then be commenced. Should symptoms not be improved after

the first few hours of conservative management surgical decompression is required.

APPENDIX 3.

PREPARATION OF TISSUE FOR ELECTRON MICROSCOPY

iii.1 INTRODUCTION.

Transmission electron microscopy is a technique which enables detailed examination of biological specimens at very high magnification. The electron microscope is in effect a large vacuum tube with the facility for the introduction of specimens via an air lock.

A beam of electrons is produced in the electron gun by a heated tungsten filament, or cathode, maintained at a potential of between 20 - 120 KV. The beam is focused by an aperture in the bias shield which is held at a negative potential with respect to the cathode.

The anode (third electrode) is at ground potential and serves to accelerate the electron beam. The lenses in the system are magnetic but act in the same way as the optics of a light microscope. A condenser lens focuses the electron beam onto the specimen which is placed on a small grid between two halves of the objective lens.

This further focuses and magnifies the image which is projected onto a fluorescent screen.

Specimens for examination in the electron microscope must be ultra-thin i.e. no thicker than 100 nm., for optimum resolution, because of the limited penetration of the

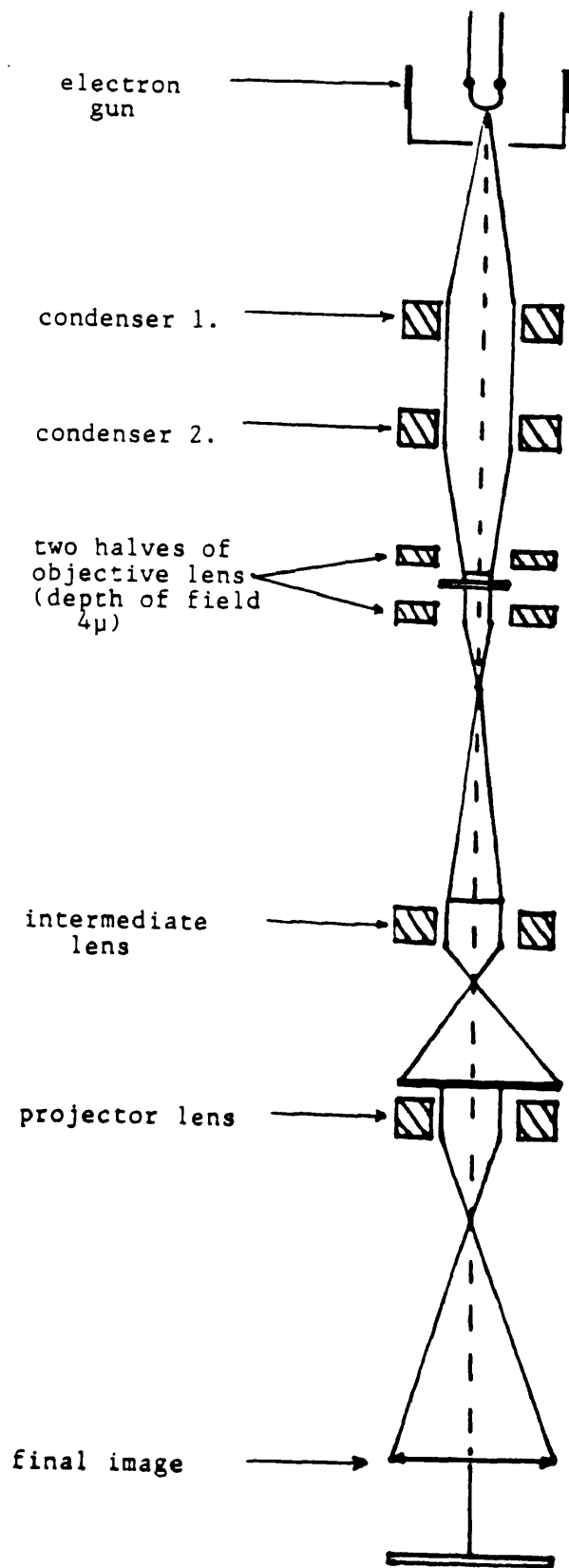


Fig. iii.1 Transmission Electron Microscope.

electron beam at conventional accelerating voltages of around 100KV.

The resolution of the transmission electron microscope is defined as the minimum distance between two objects such that they can be seen to be discrete. This is usually between 0.2 - 0.4 nm. Although structural detail below 2nm. does not appear to be preserved by current preparation methods, there is a wealth of detail in the 2 - 100 nm. range which gives valuable information on the micro-anatomy and pathology of tissues.

Preparation of specimens to survive the hostile environment of the electron microscope is an exacting process which follows several well defined steps including fixation, dehydration, embedding and sectioning.

The aim of fixation is to stop post-mortem changes and to preserve the structure of the tissue in as near life-like condition as possible. Good fixation is particularly important in the case of nervous tissue as it undergoes rapid degeneration post-mortem. It is also very susceptible to damage during dissection. Fixation by perfusion therefore gives ideal preparation for nerve.

The aim of fixation is to produce blocks which can be sectioned easily and which contain a specimen in which the fine structure is preserved in a state as near as possible to that of the living tissue. (Glauert 1975). Fixation can be regarded as "stabilising" cellular

organisation.

Ideally the fixative should match exactly the environment of the living tissue with respect to pH, ionic composition and osmolarity. Whereas pH and ionic composition can be controlled relatively easily, the osmolarity poses a problem as insufficient is known about the internal osmotic pressure of living cells. There is great debate amongst electron microscopists as to the importance of osmolarity. Primary fixatives, particularly paraformaldehyde, significantly alter the osmolarity of the final solution which may be modified by the addition of substances such as sucrose or polyvinylpyrrolidone.

The pH can be adjusted by the use of a suitable buffer of which phosphate buffer is the most physiological. There is the disadvantage that phosphate forms a precipitate with calcium ions and is prone to contamination with micro-organisms.

Cacodylate buffer is easy to prepare, is stable for long periods and does not form precipitates with calcium ions. A serious disadvantage is that cacodylate contains arsenic so that suitable precautions must be taken.

A third type of buffer is "Pipes" -

Piperazine - N - N¹ bis[2 - ethanesulphonic acid]

This a zwitterionic buffer which is non toxic and does not precipitate with calcium. A practical disadvantage is that it is poorly soluble. Buffers in addition to stabilising pH act as a vehicle for the primary

fixative.

The two most commonly used primary fixatives are the aldehydes glutaraldehyde and paraformaldehyde followed by a secondary fix in osmium tetroxide as recommended by Sabatini, Bensch and Barnett (1963) and Karnovsky (1965). Aldehydes act by cross linking proteins and stabilising nucleoproteins and carbohydrates.

Neither unsaturated fatty acids or phospholipid are fixed by aldehyde and these substances are removed from the specimen during dehydration. Therefore a secondary fix with osmium tetroxide is used to stain lipids. The heavy atomic nucleus of osmium becomes attached to the polar groups and thus makes these structures electron opaque.

Glutaraldehyde is a good cross-linking agent but has a slow penetration. Paraformaldehyde is not as effective at cross linking but penetrates tissue rapidly. A combination of the two aldehydes is therefore used.

Various substances are added to the basic fixative to enhance tissue preservation. Calcium ions prevent the formation of myelinic figures. These artefacts are produced when phospholipids, rendered soluble by glutaraldehyde, interact with osmium during the second fixation.

Potassium ferrocyanide is advocated by Langford and Coggeshall (1980) to enhance fixation of neural tissue. It can be seen that there are many variations on methods used for preparation of tissue for the electron

microscope.

Glauert (1984) advises the use of an established method in the first instance.

The first fixation schedule used consisted of:- 3% glutaraldehyde and 2% paraformaldehyde in PIPES buffer with the addition of sucrose to modify the osmolarity and calcium chloride. Potassium ferrocyanide was added to the osmium.

Considerable time was spent modifying this method but satisfactory fixation was not achieved.

Therefore a much simpler method was employed as used by the Institute of Neurology, Queen Square, London. The schedule is set out under methods.

Having fixed the specimen it must be dehydrated as embedding media are not soluble in water. This is removed by washing the specimens in ethanol in increasing concentrations. Finally an intermediate solvent such as acetone or propylene oxide is used which is freely miscible with the resin. The specimen is then infiltrated and embedded in a resin which will support the tissue during sectioning with the ultra-microtome and subsequent exposure in the electron microscope.

Resin consists of an epoxy resin, hardener and accelerator which when mixed in appropriate proportions and heated for 24hrs produce hard "blocks".

iii.2 METHODS.

0.2 Molar Cacodylate buffer.

- dissolve 21.4g. sodium cacodylate in 500cm³ water.
- adjust pH to 7.3 with molar HCl.
- fresh solution made each week.

10% Paraformaldehyde.

- add 25g. paraformaldehyde to 200cm.³ water
- heat to 60°C, stirring constantly
- add 10 molar NaOH dropwise until solution clears
- allow to cool and make up to 250cm³.

(The above should be carried out in a fume cupboard).

To make up the final fixative; 2% glutaraldehyde, 2% paraformaldehyde in 0.1 M cacodylate buffer the following quantities are used per 100cm.³ of fixative:-

10% Paraformaldehyde	20 cm. ³
25% Glutaraldehyde	12 cm. ³
0.2 M Cacodylate buffer	40 cm. ³
Distilled water	28 cm. ³
Calcium chloride dihydrate	50 mg.

This solution was used for perfusion fixation and the dissected nerve was the placed in primary fixative overnight.

Specimens were then rinsed in 0.1M cacodylate buffer and transferred to 1% osmium tetroxide for 2 - 4 hours.

The specimens were agitated throughout. After a further rinse in Cacodylate buffer the specimens were dehydrated in alcohol.

70% Ethanol	10 minutes
90% Ethanol	10 minutes
100% Ethanol	10 minutes
100% Ethanol	10 minutes
100% Ethanol	10 minutes

Specimens were then placed in 100% acetone prior to infiltration with TAAB resin which was prepared thus:-

TAAB Resin	27.5g.
DDSA	22.5g.
MNA	3.1g.

stir for 30 minutes.
add 1g. DMP 30
stir for 10 minutes.

Infiltration was carried out with constant mixing of the specimens.

Resin : Acetone	1 : 1	1 hour
Resin : Acetone	2 : 1	1 hour
100% Resin		overnight

Two to three changes of resin the next day prior to embedding and polymerisation at 60°C for 24 hrs.

Thin and ultra-thin sections were then cut using a Reichert Yung ultra-microtome and stained as follows:-

iii.3 THIN SECTIONS.

The thin section was placed on a microscope slide and covered with a few drops of 1% Toluidine blue in 1% borax.

The slide was then placed on a hot plate the edges of the stain became gold in colour - after a few seconds only.

The slide was then washed with distilled water, dried and a cover slip applied.

iii.4 ULTRA-THIN SECTIONS FOR ELECTRON MICROSCOPY.

- the specimen was placed on a copper grid and then placed in uranyl acetate for three minutes. (25% uranyl acetate in methanol; this solution must be protected from light as it is photosensitive).

- the grids were washed in methanol and dried on filter paper.

- stain with Reynold's lead citrate (see below *).

There is a risk of lead carbonate forming at this stage by reaction of the lead citrate from exhaled carbon dioxide.

Therefore it was important not to breathe over the solutions.

- two further washes in methanol and then dry on filter paper.

- the grids were then stored in petrie dishes until required.

* Reynold's lead citrate:-

1.33 g. lead citrate.

1.76g. sodium citrate

30 cm³ distilled water.

shake the above for one minute.

leave for 30 minutes - shaking occasionally.

add 8 cm³ 1M NaOH.

dilute to 50 cm (pH 12).

APPENDIX 4.

RESULTS

Table iv.1

ULTRASOUND ASSESSMENT OF CARPAL TUNNEL SYNDROME

NO:	AGE:	SEX:	CLIN:	TIN:	PHAL:	ULTS:	EMG:
1R	48	F	-	-	-	-	-
1L	48	F	+	-	-	-	-
2R	56	M	-	-	-	-	-
2L	56	M	+	-	+	-	-
3L	76	M	+	-	+	+	+
3R	76	M	+	-	+	+	+
4L	81	F	+	-	+	-	+
4R	81	F	+	-	+	-	+
5L	67	F	-	-	+	-	-
5R	67	F	+	-	+	-	+
6L	67	M	+	-	+	-	-
6R	67	M	+	-	+	-	+
7L	68	F	+	+	+	-	-
7R	68	F	-	-	-	-	-
8L	37	F	+	-	-	+	+
8R	37	F	+	-	-	+	-
9L	48	F	+	-	+	-	+
9R	48	F	+	-	-	+	+
10L	64	F	+	-	-	-	+
10R	64	F	-	-	-	-	+
11L	77	F	-	+	-	-	-
11R	77	F	+	+	-	+	+
12L	73	F	+	+	-	+	-
12R	73	F	+	+	-	-	-
13L	56	F	+	+	+	+	*
13R	56	F	+	+	+	+	+
14L	42	M	+	-	-	+	-
14R	42	M	+	-	-	+	-
15L	33	F	+	-	+	+	+
15R	33	F	+	-	+	+	+
16L	47	F	-	-	-	-	-
16R	47	F	+	+	+	-	-
17L	41	F	-	-	-	-	-
17R	41	F	+	-	+	+	+
18L	33	M	-	-	-	-	-
18R	33	M	+	-	-	-	-
19L	53	M	+	+	+	+	+
19R	53	M	+	-	-	-	-
20L	50	M	-	-	-	-	-
20R	50	M	+	-	-	-	-
21L	70	F	-	-	-	-	-
21R	70	F	+	-	+	-	+
22L	66	F	+	-	-	-	-

Table iv.1 cont.

NO:	AGE:	SEX:	CLIN:	TIN:	PHAL:	ULTS:	EMG:
22R	66	F	+	-	-	-	-
23L	38	F	+	-	-	-	-
23R	38	F	-	-	+	-	-
24L	52	F	-	-	-	-	-
24R	52	F	+	+	-	-	-
25L	23	F	-	-	-	-	-
25R	23	F	+	+	-	+	+
26L	32	F	+	-	+	-	-
26R	32	F	-	-	-	-	-
27L	21	M	+	-	-	-	-
27R	21	M	-	-	-	-	-
28L	51	F	+	+	+	-	+
28R	51	F	+	+	+	-	+
29L	66	F	+	-	-	-	-
29R	66	F	+	-	-	-	-
30L	81	F	+	-	-	+	+
30R	81	F	-	-	-	-	+
31L	41	F	+	+	+	+	+
31R	41	F	+	-	+	+	-
32L	79	F	+	-	-	+	+
32R	79	F	+	-	-	+	+
33L	38	F	-	-	-	-	-
33R	38	F	+	-	-	-	-
34L	54	F	+	-	-	-	+
34R	54	F	+	-	-	-	+
35L	52	F	+	-	-	-	-
35R	52	F	+	-	-	-	-
36L	56	F	+	-	-	+	-
36R	56	F	-	-	-	-	-
37L	52	M	+	-	-	-	-
37R	52	M	+	-	-	-	+
38L	50	M	+	-	-	-	+
38R	50	M	+	-	-	-	+
39L	60	F	+	-	-	+	+
39R	60	F	-	-	-	-	-
40L	48	M	-	-	-	-	-
40R	48	M	+	+	-	-	+
41L	46	F	+	-	-	+	-
41R	46	F	-	-	-	-	-
42L	52	F	+	+	-	+	+
42R	52	F	-	-	-	-	-
43L	35	F	-	-	-	-	-
43R	35	F	+	-	+	-	-
44L	53	M	+	-	-	-	+
44R	53	M	-	-	-	-	-
45L	44	F	+	+	+	+	-
45R	44	F	-	-	-	-	-
46L	55	F	+	-	+	-	-
46R	55	F	+	-	+	+	-
47L	48	F	+	+	-	+	+
47R	48	F	+	+	-	+	-
48L	44	F	+	+	+	-	-
48R	44	F	-	-	-	-	-

Table iv.1 cont.

NO:	AGE:	SEX:	CLIN:	TIN:	PHAL:	ULTS:	EMG:
49L	21	M	+	-	+	+	+
49R	21	M	+	-	-	+	+
50L	61	F	-	-	-	-	-
50R	61	F	+	+	+	+	+
51L	42	M	+	-	-	-	-
51R	42	M	+	-	-	-	-
52L	67	M	-	-	-	-	-
52R	67	M	+	-	-	-	+
53L	77	M	-	-	+	-	-
53R	77	M	+	-	+	-	+
54L	77	M	+	-	-	-	-
54R	77	M	+	-	-	-	-
55L	74	F	+	+	+	+	+
55R	74	F	-	-	-	-	-
56L	57	F	+	+	+	+	+
56R	57	F	-	-	-	-	-
57L	71	F	-	-	-	-	-
57R	71	F	+	+	-	+	+
58L	66	F	+	-	-	-	-
58R	66	F	-	-	-	-	-
59L	68	F	-	-	+	-	-
59R	68	F	+	-	+	+	+
60L	55	M	+	+	-	-	+
60R	55	M	-	-	-	-	+
61L	55	F	+	-	-	+	+
61R	55	F	-	-	-	-	-
62L	68	F	+	-	-	-	-
62R	68	F	+	-	-	-	-
63L	30	F	+	-	-	+	+
63R	30	F	+	-	-	+	+
64L	57	M	+	-	-	-	-
64R	57	M	-	-	-	-	-
65L	53	F	-	-	+	-	-
65R	53	F	+	-	+	-	-
66L	37	M	+	+	+	+	-
66R	37	M	-	-	-	-	-
67L	27	F	+	-	+	+	+
67R	27	F	-	-	-	-	-
68L	33	F	+	-	+	-	-
68R	33	F	+	-	+	-	-
69L	45	M	+	+	-	-	+
69R	45	M	-	-	-	-	+
70L	44	M	+	-	+	+	+
70R	44	M	+	-	+	+	+
71L	58	F	-	-	-	-	-
71R	58	F	+	-	-	-	+
72L	63	M	+	-	-	-	-
72R	63	M	+	-	-	-	-
73L	39	F	-	-	-	-	-
73R	39	F	+	+	-	-	-
74L	38	M	-	-	-	-	-

Table iv.1 cont.

NO:	AGE:	SEX:	CLIN:	TIN:	PHAL:	ULTS:	EMG:
74R	38	M	+	+	+	+	-
75L	77	F	+	+	-	-	-
75R	77	F	-	-	-	-	-
76L	53	F	+	-	-	-	+
76R	53	F	-	-	-	-	-
77L	55	M	+	-	+	+	-
77R	55	M	-	-	-	-	-
78L	36	F	+	+	+	+	*
78R	36	F	-	-	-	-	-
79L	46	F	+	-	-	+	-
79R	46	F	+	-	-	+	-
80L	35	F	+	-	-	-	-
80R	35	F	+	-	-	-	-
81L	35	M	+	-	-	+	+
81R	35	M	+	-	+	+	+
82L	40	F	-	-	+	-	-
82R	40	F	+	-	+	-	-

COMMENTS.

10L,10R. severe denervation

13L minimum changes

19R minimum symptoms

55R RCTD

69L severe

69R mild

78L no EMG.

Table iv.2

ULTRASOUND ASSESSMENT OF CARPAL TUNNEL SYNDROME

CONTROLS.

NO:	AGE:	SEX:	R:	L:	DIAGNOSIS:
1	16	M	-	-	# HUMERUS
2	42	M	-	-	# TIB. & FIB.
3	64	M	-	-	
4	67	F	-	-	# RAD. & ULNA
5	77	F	-	-	
6	43	M	-	-	# TIB. & FIB.
7	39	M	-	-	# SCAPHOID
8	76	F	-	-	# HUMERUS
9	59	F	-	-	
10	78	M	-	-	
11	74	M	-	-	T.H.R.
12	53	F	-	-	C.M.C. O.A.
13	32	F	-	-	
14	37	F	-	-	# TOE
15	43	F	-	-	
16	57	M	-	-	
17	19	F	-	-	
18	46	M	-	-	# ANKLES
19	20	F	-	-	
20	41	F	-	-	
21	51	F	-	-	
22	27	F	-	-	
23	27	F	-	-	
24	36	F	+	-	**
25	29	M	-	-	

** on further questioning had steroid injection to carpal tunnel in the past and currently had mild symptoms.

MALES	10
FEMALES	15
AVERAGE AGE	46
RANGE	16 - 78

APPENDIX 5.

STATISTICAL ANALYSIS - CALCULATIONS.

2 X 2 CONTINGENCY TABLES:-

1. ULTRASOUND.

a.	b.	
11%	19.5%	30.5%
18	32	a + b = 50
c.	d.	
25%	44.5%	69.5%
41	73	c + d = 114
36%	64%	
a + c = 59	b + d = 105	

from:- $Ea = \frac{(a+b)(a+c)}{N}$

$$Ea = \frac{50 \times 59}{164}$$

$$= 17.98$$

$$Eb = \frac{50 \times 105}{164}$$

$$= 32$$

$$Ec = \frac{59 \times 114}{164}$$

$$= 41$$

$$Ed = \frac{105 \times 114}{164}$$

$$= 73$$

$$\text{from:- } \chi^2 = \sum \frac{(O - E)^2}{E}$$

$$\chi^2 = \frac{15^2}{18} + \frac{15^2}{32} + \frac{15^2}{41} + \frac{15^2}{73}$$

$$\chi^2 = 28.$$

this gives a P value of < 0.001 (1° of freedom)

to calculate a Phi value:-

$$\begin{aligned} \phi &= \chi^2 / N \\ &= 28 / 164 \\ &= 0.41. \end{aligned}$$

2. TINEL.

a.	b.	a + b = 31
7%	12%	18.9%
11	20	
c.	d.	c + d = 133
29%	52%	81.1%
48	85	
a + c = 59	b + d = 105	
36%	64%	

$$Ea = \frac{31 \times 59}{164}$$

$$= 11.2$$

$$Eb = \frac{31 \times 105}{164}$$

$$= 19.8$$

$$E_c = \frac{59 \times 133}{164} \quad E_d = \frac{133 \times 105}{164}$$

$$= 47.9 \quad = 85.2$$

$$\chi^2 = 25/11 + 25/20 + 25/48 + 25/85$$

$$= 2.27 + 1.25 + 0.52 + 0.29$$

$$= 4.33$$

this gives a P value of 0.03 (1° of freedom)

to calculate the Phi value:-

$$\phi = 4.33 / 164$$

$$= 0.16.$$

3. PHALEN.

a.	b.
11%	19.9%
18	33
c.	d.
24.8%	44.1%
41	72

$$E_a = \frac{51 \times 59}{164} \quad E_b = \frac{51 \times 105}{164}$$

$$= 18 \quad = 33$$

$$E_c = \frac{59 \times 113}{164} \quad E_d = \frac{105 \times 113}{164}$$

$$= 41 \quad = 72$$

$$\begin{aligned}x^2 &= 64/18 + 64/33 + 64/41 + 64/72 \\ &= 3.56 + 1.94 + 1.56 + 0.89 \\ &= 7.95\end{aligned}$$

this gives a P value of 0.005 (1° of freedom)

to calculate the Phi value :-

$$\begin{aligned}\phi &= 7.95/164 \\ &= 0.22\end{aligned}$$
