



Subfoveal retinal detachment associated with dome-shaped macula in a 6 year-old child: Comparison with other case reports and systematic review of the literature regarding dome-shaped macula in children

M. Pilar Martin-Gutierrez^a, Michalis Georgiou^{a,b}, Michel Michaelides^{a,b,*}

^a Moorfields Eye Hospital, London, EC1 2PD, UK

^b UCL Institute of Ophthalmology, University College London, London, EC1V 9EL, UK

ARTICLE INFO

Keywords:

Dome-shaped macula
Subretinal detachment
Children
Adolescents
Optic disc pit
Posterior staphyloma
Subretinal fluid

ABSTRACT

Purpose: To describe the case of an asymptomatic 6-year-old girl, who was found to have bilateral dome-shaped macula, associated with left serous macular detachment and left optic disc pit, and no evidence of posterior staphyloma in either eye, and to review the literature regarding dome-shaped macula in children and compare our patient's findings with similar case reports.

Observations: Our patient presented with bilateral dome-shaped macula and several other accompanying features, already described in previous reports in children her age.

Conclusions and importance: Dome-shaped macula is a relatively new entity, which has been mainly described in highly myopic adults. Since its description, an increasing number of studies have been published to help characterise this condition and to elucidate its nature, causes, epidemiology and associated findings. Although the majority of the available data relate to adults, there are a number of studies that describe dome-shaped macula in children and adolescents. In this paper, we discuss the association of dome-shaped macula in children with posterior staphyloma, myopia, and suggest a possible developmental aetiology for this entity.

1. Introduction

Dome-shaped macula (DSM) was first described by Gaucher et al in 2008 as a convex elevation of the macula within a myopic staphyloma.¹ Since then, there has been an increasing number of studies describing DSM, mainly in adults with high myopia, but also in children and adolescents²⁻⁵; and both in patients with emmetropia and hypermetropia.⁶ Although Gaucher et al. defined the condition as a macular bulge within a myopic staphyloma, DSM has been frequently observed in the absence of a staphyloma.

A number of hypotheses have been proposed to explain the origin of DSM, such as low intraocular pressure resulting in collapse of the scleral wall,⁷ vitreomacular traction,⁷ resistance of the scleral wall to staphylomatous deformation,¹ thickened subfoveal choroid resulting in a CSR-like mechanism,¹ thickened subfoveal sclera,^{1,8} or asymmetrical enlargement of Bruch's membrane in the equatorial region, resulting in a "fold" at the posterior pole.⁴ Although it is generally accepted that the first two hypotheses may be inaccurate, as no evidence of low intraocular pressure or vitreomacular traction has been found in the studied

subjects, the exact origin of this condition has not yet been fully elucidated.

Caillaux et al.,⁹ proposed a classification of DSM based on the morphology of the dome as seen in OCT scans; (i) horizontal dome shape, when detected on vertical OCT scans; (ii) vertical dome shape, when detected on horizontal OCT scans; or (iii) round dome shape, when detected in both vertical and horizontal OCT scans. Most studies published so far found that the prevalence of horizontal shaped domes was the highest in adults,⁹⁻¹⁶ whereas vertical shaped domes were the least prevalent, or not found in some cohorts.^{17,18} Interestingly, studies conducted in children only found horizontal dome shapes in their cohorts.²⁻⁵

It is widely known that DSM can be complicated by subretinal detachment (SRD), pigmentary changes of the retinal pigment epithelium (RPE) and choroidal neovascularization, which can lead to decreased visual acuity or metamorphopsia. A wide range of therapies have been used to treat SRF associated with DSM, including oral eplerenone or acetazolamide, focal laser, intravitreal injections of triamcinolone and antiVEGF agents, or half-fluence/half dose

* Corresponding author. Moorfields Eye Hospital, London, EC1 2PD, UK.

E-mail address: michel.michaelides@ucl.ac.uk (M. Michaelides).

<https://doi.org/10.1016/j.ajoc.2020.100821>

Received 6 May 2020; Received in revised form 16 June 2020; Accepted 4 July 2020

Available online 8 July 2020

2451-9936/© 2020 Published by Elsevier Inc. This is an open access article under the CC BY-NC-ND license (<http://creativecommons.org/licenses/by-nc-nd/4.0/>).

photodynamic therapy (PDT); yet these have not been shown to be effective in achieving a significant anatomic or functional response.^{10,19}

Herein, we present the case of an asymptomatic 6-year-old girl, who was found to have bilateral dome-shaped macula, associated with left serous macular detachment and no evidence of posterior staphyloma in either eye.

2. Case report

A 6 year-old female, with a prior medical history of unbalanced translocation between the distal arm of chromosome 3 and the short arm

of chromosome 9, and associated developmental delay, was seen in the Paediatric Ophthalmology Department at Moorfields Eye Hospital for recurrent left sticky eye since birth. At the age of four (November 2017) a hypopigmented area in the macula of the left eye was noted on fundoscopy. Subsequent TORCH screening came back negative, and electrophysiological testing was normal, although these were not completely reliable due to relatively poor compliance. She was further referred to the Paediatric Retina clinic.

The patient was first seen in Paediatric Retina clinic in January 2020. The patient was then 6 years old, and her cycloplegic refraction was +2.00/-3.50 x 180 (spherical equivalent (SE) = +0.25 D) in the right

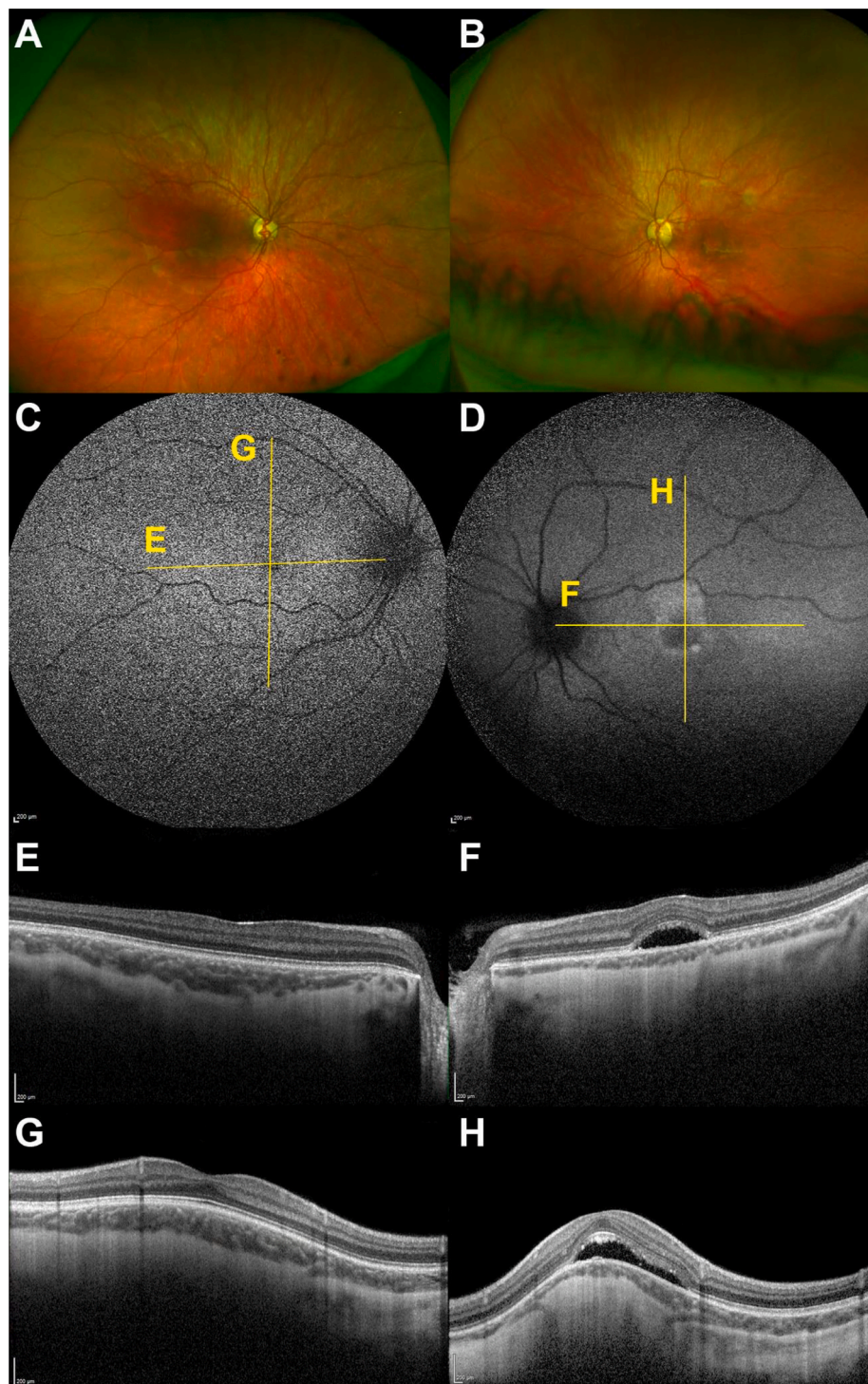


Fig. 1. Multimodal Imaging in Horizontal Dome-Shaped Macula.

Multimodal imaging of subfoveal retinal detachment associated with dome-shaped macula in a 6 year-old child. (A) and (B) colour fundus photographs of the right and left eye respectively, exhibiting a certain degree of tessellation. (B) Pigmentary changes are visible at the left macula, including the fovea. (C) and (D) Fundus autofluorescence (FAF) images of the right and left eye respectively. (C) FAF pattern was normal for the right eye, despite the low image quality. (D) Hyperautofluorescence is observed adjacent to the pigmentary changes in the left eye. The yellow lines on the FAF images (C–D) mark the location of the corresponding optical coherence tomography (OCT) line scans presented in (E–H). No foveal bulge was observed either in the right (E) or in the left eye (F) on the horizontal OCT scans. In the vertical scans: (G) a mild macular bulge is observed in the right eye (250 μm), and (H) a more prominent macular bulge in the left eye (446 μm). (F) and (H) The left eye presents a subfoveal serous detachment. The choroid is thicker in the right hyperopic eye (E and G), compared to the left eye (F and H). All OCT scans are to scale. (For interpretation of the references to colour in this figure legend, the reader is referred to the Web version of this article.)

eye, and $-1.50/-3.50 \times 180$ (SE = -3.25 D) in the left eye, and her visual acuity was 20/50 and 20/40, respectively. Slit-lamp examination identified normal anterior segments in both eyes. Dilated retinal examination did not show tilted optic discs or staphylomata in either eye (Fig. 1A and B), but revealed an area of pigmentary change at the left macula, including the fovea (Fig. 1B). Both retinas exhibited a certain degree of tessellation, especially supero-temporally.

55° autofluorescence imaging scans were unremarkable in the right eye (Fig. 1C), but revealed hyperautofluorescence adjacent to the pigmentary changes in the left eye (Fig. 1D), likely secondary to long standing subretinal fluid (SRF) in that area. Interestingly, the hyperfluorescent area did not extend inferiorly, as would be expected due to gravity, but was observed only superiorly.

Spectral domain optical coherence tomography (SD-OCT) scans (Spectralis, Heidelberg Engineering, Heidelberg, Germany) showed a mild macular bulge in the vertical scan (Fig. 1G), but not in the horizontal scan (Fig. 1E), in the right eye; and a more prominent macular bulge in the vertical scan (Fig. 1H), but not in the horizontal scan (Fig. 1F), in the left eye. The shape of the domes in our patient was, therefore, horizontal. According to the previously suggested definition of dome-shaped macula by Ellaban et al.,¹⁶ the diagnosis of a DSM was made based on the existence of a macular bulge greater than 50 μm from the apex of the bulge to a presumed line drawn from the RPE in the borders of the bulge.¹⁶ The macular bulges measured 250 μm and 446 μm , for the right and left eye respectively. The left eye was also associated with a subfoveal serous detachment (Fig. 1 F and H). SD-OCT scans appeared to show an increased thickness of the sclera in both eyes, although this could not be measured by ultrasonography or enhanced depth imaging due to poor patient co-operation. The choroid was thicker in the right, hyperopic eye, as shown on scans (Fig. 1E–H). Subfoveal choroidal thickness measured 219 μm in the right eye and 116 μm in the left eye.

On funduscopy a difference in the optic size was noted (Fig. 2A and B); the left optic nerve being larger. On detail OCT imaging an optic disc pit was observed in the left eye (Fig. C–D), without being related to the subfoveal serous detachment (Fig. D).

The patient was therefore diagnosed with bilateral DSM, more prominent in her left (myopic) eye, with associated SRF and RPE pigmentary alterations in this eye, as well as an optic disc pit. To the best of our knowledge, the patient was under no medication that might have precipitated the appearance of SRF (e.g. steroids). It was decided not to treat the SRF in her left eye due to the patient being asymptomatic and her left eye vision being similar to previous routine visits at her local hospital, and also because a number of different therapies applied to SRF associated with DSM have not been found to be beneficial in previous reports.

3. Discussion

The initial study describing DSM in adults identified moderate, posterior staphylomas, specifically type I and type II of Curtin's classification²⁰ in all cases, as per their fundoscopic characteristics.¹ They concluded that DSM within a myopic staphyloma is indeed a type of myopic posterior staphyloma. Other studies describe DSM in myopic eyes with staphyloma, although with different prevalence,^{1,6,12,16,17,21,22} and some suggest that the origin of DSM may be closely associated to staphyloma.^{12,13,16,18,21} There are other studies, on the contrary, which do not report the association of DSM with posterior staphyloma.^{3–5,8,12,22} The diagnosis of staphyloma is commonly based on funduscopy, colour images or OCT scans. However, the accuracy of these methods for diagnosing staphylomas remains controversial. For instance, conventional 50° fundus photos or OCT scans may not cover the entire staphyloma, as staphylomas may be wider than these scans. Other methods are perhaps more accurate but less accessible in clinic, such as ultrasound scans, ultra-wide OCT scans or MRI scans.²³ Given the different definitions of staphyloma and the different methods used to detect it, the diagnosis of staphyloma may not have been accurate or consistent in many of the aforementioned DSM studies. Interestingly, most of the aforementioned studies only used funduscopy and standard OCT or colour images.^{3,8–10,12–15,24,25} Therefore, the prevalence of DSM in conjunction with staphyloma found in these studies would likely be different if other imaging methods had been applied. In

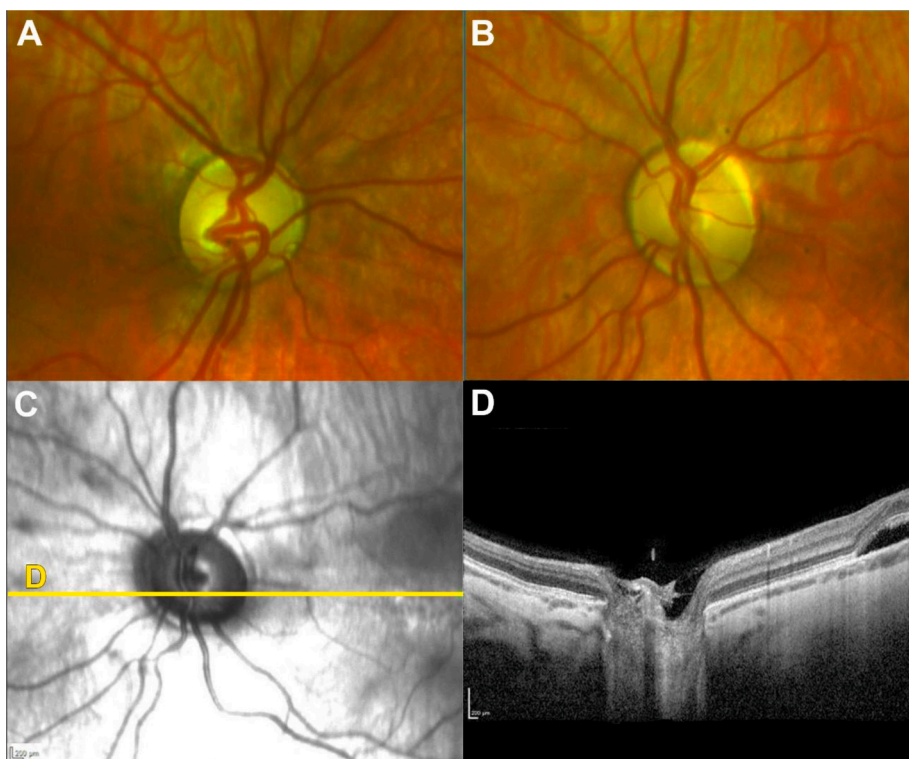


Fig. 2. Multimodal Optic Nerve Imaging.

(A) and (B) colour fundus photographs of the right and left optic nerves respectively. A difference in size is observed, with the left optic nerve being larger. (C) Near infrared image of the left optic nerve; the yellow line marks the location of the corresponding optical coherence tomography (OCT) line scan presented in (D). (D) Horizontal OCT scans over the optic nerve, shows findings compatible with an optic disc pit. The subfoveal serous detachment is present to the far left. (For interpretation of the references to colour in this figure legend, the reader is referred to the Web version of this article.)

addition, posterior elongation of the sclera secondary to pathologic myopia has been confused with posterior staphyloma in some OCT studies. Therefore, the lack of accurate diagnostic methods and axial elongation in myopic eyes may have been a significant confounding factor in previous studies evaluating prevalence of DSM and posterior staphyloma. In this study we have chosen Spaide's definition of staphyloma in pathologic myopia²⁶: an outpouching of the wall of the eye with a radius of the curvature that is less than the surrounding curvature of the wall of the eye, usually accompanied by localised thinning of the sclera and choroid.

It has also been suggested that DSM could be a staphyloma subtype.^{1,21} However, in a cohort of 105 patients with pathologic myopia studied with 3D MRI and wide-field fundus images, Ohno-Matsui proposed that DSM develops independently from staphylomas, and also earlier than staphylomas.²² In fact, staphylomas are known to develop in middle age,^{4,16,20} whereas DSM can be present very early in life.²⁻⁵ In keeping with this, it is of note that the DSM studies in children and adolescents²⁻⁵ do not report the existence of staphylomas. The absence of staphyloma in our patient may be readily explained by her age. The shape of the DSM in our patient was horizontal bilaterally, and therefore, only seen in the vertical OCT scan. This would be in line with the previously described DSM in children and adolescents.²⁻⁵ Although change of dome orientation has been described in longitudinal studies,¹⁰ further studies are needed to elucidate why horizontal domes occur more readily at a younger age, and which pathophysiological mechanism prompts this. Nevertheless, this finding may be due to the limited number of reported subjects.

In their study of 17 high myope patients under the age of 20 with macular elevations, Xu et al. suggested that the characteristics of the macular inward elevations found in children and adolescents may differ from the DSM found in adults, based on wider bases and smoother slopes of the domes. Therefore, they proposed that macular elevations in children and adolescents may be a different entity from the adult DSM, and referred to it as "ridge-shaped macula".⁴ It is possible, however, that these features may not represent a different entity, but a premature presentation of the same entity, which has been shown can vary over time. As no hyperopic shift has been noted in patients with DSM, we can assume that the bulge does not grow inward, but rather the thinned sclera surrounding the dome may deepen.^{10,16} Thus, it would not be unreasonable to suggest that wide, smooth slopes in young patients may steepen over the years, therefore slowly acquiring the characteristics of the DSM we usually see in adults. Our patient presented with a mild, smooth dome in her right, hyperopic eye, and with a more pronounced bulge in her left, myopic eye. This would be in keeping with more pronounced bulges seen in eyes with greater axial length due to scleral protrusion.

SRD is commonly associated with DSM. The origin of the fluid, however, remains poorly understood. It has been hypothesized that SRD can occur secondarily to (i) increased scleral thickness, which would obstruct the outflow of choroidal fluid⁸; (ii) increased subfoveal choroidal thickness, which would act as a CSR-like phenomenon,⁸ or (iii) RPE dysfunction.^{1,24} Also, abrupt changes in choroidal thickness may play a role in its pathophysiology.¹⁹ Subfoveal choroidal thickness (219µm OD, 116µm OS) was not evidently increased in our patient, especially in her left eye, which could be in line with this eye being myopic. Although we could not measure scleral thickness in clinic due to poor patient collaboration, the sclera appeared to be thickened on OCT scans, especially in the eye with SRF. Interestingly, our patient was found to have macular RPE changes in her left eye since November 2017. This finding would indicate the existence of chronic changes in the RPE due to long-standing marked macular bulge since, at least, the age of four. Chronic damage to the RPE may have affected the RPE pump function, thus resulting in the appearance of SRF in this eye. It seems, therefore, that the pathogenic mechanism resulting in SRF in our patient's left eye may be due to mainly RPE dysfunction, and possibly to increased scleral thickness, although this latter remains to be proven

with accurate measurement. The height of the macular bulge being greater than 350 µm has been associated with the presence of SRD,⁹ and also with RPE atrophy.¹⁰ The findings in our patient are in keeping with this data, as the greater bulge (>350 µm in her left eye), presented with SRD, as well as with RPE atrophy; whereas the milder bulge in her hyperopic, right eye (<350 µm), did not show any evidence of current SRD on OCT or previous SRD on autofluorescence imaging.

Some unique features of our case, in addition to the young age at presentation, are the FAF findings and her visual acuity. FAF imaging was unremarkable in the right eye, whereas the left eye showed evidence of long-standing subretinal fluid. It is noteworthy that the hyperfluorescent track in her left eye did not extend inferiorly, as expected due to gravity, but superiorly; a finding that is not readily explained. It is also remarkable that the visual acuity was better in the eye with DSM and SRD, as chronic SRD and RPE pigmentary changes have been generally associated with poorer visual acuity in the long term; however, this may relate to anisometropia and/or her young age. Optic disc pit is a rather rare finding in the general population, and in our case may further provide evidence of a developmental aetiology in DSM. To the best of our knowledge, there have been two other descriptions in the literature in children with similar findings at this early age. Xu et al. describe the case of a 4-year-old girl with high myopia (-12 D and 25.9 mm of axial length), who presented with a left mild horizontal macular bulge in the absence of posterior staphyloma. However, in contrast to our case, Xu's patient did not exhibit any SRD and our child was not highly myopic. Nevertheless, they suggest that these findings are commonly associated with diffuse chorioretinal atrophy and subsequently, with extremely thinned choroid. In keeping with this, OCT scans and colour images in our patient revealed diffuse chorioretinal atrophy, more prominent supero-temporally in both eyes, and thinned choroid predominantly in her left, myopic, eye.⁴ The second description also relates to a 4-year-old-girl, who was seen due to visual impairment and abnormal ophthalmological findings. Akhras et al. reported bilateral tilted discs, inferonasal crescents, inferonasal and macular atrophy of the RPE and situs inversus of the retinal vessels on funduscopy. No posterior staphyloma was found, and the child was said to have bilateral hypermetropia and astigmatism. However, no data concerning refraction was available. OCT scans revealed bilateral DSM and bilateral SRD, which resolved spontaneously over a period of three years. Despite progression of macular atrophy in this period, an improvement in visual acuity was observed. Akhras et al. concluded that this case represented bilateral congenital tilted optic disc and DSM combined with bilateral SRD.⁵ Our patient resembles Akhras's in that both presented with astigmatism, bilateral macular atrophy (possibly due to the bilateral macular bulge), chorioretinal thinning with no evidence of myopia (bilaterally in Akhras's patient and in the right eye only in our patient), and DSM associated with SRD.

4. Conclusion

Although there is an increasing amount of information regarding DSM, some of its aspects remain elusive. Association with posterior staphyloma, for instance, may have been biased in previous studies, according to the definition used by different authors. In this paper we suggest considering Spaide's definition of staphyloma, as it may be the clearest and most specific, thus avoiding confusion with axial elongation of the globe.

Studies regarding DSM in children revealed slightly different findings compared to DSM in adults, which may be explained by the short time of evolution of the lesions. It is interesting, however, that children did not exhibit posterior staphylomas, therefore suggesting these two entities might not be closely associated, but rather two different findings that can coexist in highly myopic eyes.

There seems to be a direct correlation between DSM and degree of myopia, as DSM tends to occur in more myopic patients. DSM has been widely considered an acquired feature, secondary to myopia, which

might evolve as myopia increases. Interestingly, we have found in our patient and in the literature myopic findings (more specifically, chorioretinal atrophy) in association with DSM in young patients who did not present with myopia at the time of the consultation. We have described in our discussion 3 patients, who at the age of 4 presented with retinal findings compatible with DSM; 2 of them not having being diagnosed with high myopia. Although there may be differences regarding refractive error among these patients, all of them presented with myopic fundus features and unilateral/bilateral DSM at a very early age. This observation may be explained by the following hypothesis: DSM may represent a congenital lesion, given the young age of these patients; and the myopic findings in these patients might imply a certain predisposition to myopia in eyes presenting with DSM. Also, the presence of an optic disc pit in our case may further support a developmental aetiology. There is little evidence so far to support this hypothesis, given the small number of patients presented in this paper. Therefore, we suggest that further prospective studies encompassing longer periods of young, non-myopic patients presenting with DSM and myopic fundi, would help clarify whether these patients develop myopia or high myopia over time.

Patient consent

Written consent to publish this case has not been obtained. This report does not contain any personal identifying information.

Funding

Supported by grants from the National Institute for Health Research Biomedical Research Centre at Moorfields Eye Hospital NHS Foundation Trust and UCL Institute of Ophthalmology, Onassis Foundation, Leventis Foundation, The Wellcome Trust (099173/Z/12/Z), Moorfields Eye Hospital Special Trustees, Moorfields Eye Charity, Retina UK, Fight for Sight UK, and the Foundation Fighting Blindness (USA).

Authorship

All authors attest that they meet the current ICMJE criteria for Authorship.

Declaration of competing interest

The following authors have no financial disclosures: MPMG, MG, MM.

Acknowledgements

None.

References

1. Gaucher D, Erginay A, Lecleire-Collet A, et al. Dome-shaped macula in eyes with myopic posterior staphyloma. *Am J Ophthalmol*. 2008 May;145(5):909–914.
2. Cebeci Z, Kir N. Bilateral dome-shaped macula with serous macular detachment in a child. *Case Rep. Ophthalmol. Med*. 2015;2015:1–4.
3. Shin E, Park K-A, Oh SY. Dome-shaped macula in children and adolescents. *Grzybowski A, ed. PLoS One*. 2020 Jan;15(1), e0227292.
4. Xu X, Fang Y, Jonas JB, et al. ridge-shaped macula in young myopic patients and its differentiation from typical dome-shaped macula in elderly myopic patients. *Retina*. 2018 Nov;1.
5. Akhras N, Letartre L. Foveal subretinal fluid in a pediatric patient's eyes with a congenital tilted optic disc and a dome-shaped macula. *Can J Ophthalmol*. 2019;54(6):e277–e280.
6. Errera M-H, Michaelides M, Keane PA, et al. The extended clinical phenotype of dome-shaped macula. *Graefes Arch Clin Exp Ophthalmol*. 2014 Mar;252(3):499–508.
7. Mehdizadeh M, Nowroozzadeh MH. Dome-shaped macula in eyes with myopic posterior staphyloma. *Am J Ophthalmol*. 2008 Sep;146(3):478. author reply 478–479.
8. Imamura Y, Iida T, Maruko I, Zweifel SA, Spaide RF. Enhanced depth imaging optical coherence tomography of the sclera in dome-shaped macula. *Am J Ophthalmol*. 2011 Feb;151(2):297–302.
9. Caillaux V, Gaucher D, Gualino V, Massin P, Tadayoni R, Gaudric A. Morphologic characterization of dome-shaped macula in myopic eyes with serous macular detachment. *Am J Ophthalmol*. 2013 Nov;156(5):958–967.
10. Soudier G, Gaudric A, Gualino V, et al. LONG-TERM evolution OF dome-shaped macula: increased macular bulge is associated with extended macular atrophy. *Retina*. 2016 May;36(5):944–952.
11. Dai F, Li S, Wang Y, et al. Correlation between posterior staphyloma and dome-shaped macula IN high myopic eyes: retina. 2019 Dec:1.
12. Lorenzo D, Arias L, Choudhry N, et al. DOME-SHAPED macula IN myopic eyes: twelve-month follow-up. *Retina*. 2017 Apr;37(4):680–686.
13. Zhao X, Ding X, Lyu C, et al. Observational study of clinical characteristics of dome-shaped macula in Chinese Han with high myopia at Zhongshan Ophthalmic Centre. *BMJ Open*. 2018 Dec;8(12), e021887.
14. Garcia-Ben A, Kamal-Salah R, García-Basterra I, Gonzalez Gómez A, Morillo Sanchez MJ, García-Campos JM. Two- and three-dimensional topographic analysis of pathologically myopic eyes with dome-shaped macula and inferior staphyloma by spectral domain optical coherence tomography. *Graefes Arch Clin Exp Ophthalmol*. 2017 May;255(5):903–912.
15. Soudier G, Gaudric A, Gualino V, et al. Macular choroidal thickness in myopic eyes with and without a dome-shaped macula: a case-control study. *Ophthalmologica*. 2016;236(3):148–153.
16. Ellabban AA, Tsujikawa A, Muraoka Y, et al. Dome-shaped macular configuration: longitudinal changes in the sclera and choroid by swept-source optical coherence tomography over two years. *Am J Ophthalmol*. 2014 Nov;158(5):1062–1070.
17. Ohsugi H, Ikuno Y, Oshima K, Yamauchi T, Tabuchi H. Morphologic characteristics of macular complications of a dome-shaped macula determined by swept-source optical coherence tomography. *Am J Ophthalmol*. 2014 Jul;158(1):162–170.
18. Liang I-C, Shimada N, Tanaka Y, et al. Comparison of clinical features in highly myopic eyes with and without a dome-shaped macula. *Ophthalmology*. 2015 Aug;122(8):1591–1600.
19. Tan ACS, Yzer S, Freund KB, Dansingani KK, Phasukkijwatana N, Sarraf D. Choroidal changes associated with serous macular detachment IN eyes with staphyloma, dome-shaped macula or tilted disk syndrome: retina. 2017 Aug;37(8):1544–1554.
20. Curtin BJ. The Posterior Staphyloma of Pathologic Myopia. *Trans Am Ophthalmol Soc*. 1977;75:67–86.
21. Byeon SH, Chu YK. Dome-shaped macula. *Am J Ophthalmol*. 2011 Jun;151(6):1101. author reply 1101–1102.
22. Ohno-Matsui K. Proposed classification of posterior staphylomas based on analyses of eye shape by three-dimensional magnetic resonance imaging and wide-field fundus imaging. *Ophthalmology*. 2014 Sep;121(9):1798–1809.
23. Ohno-Matsui K, Jonas JB. Posterior staphyloma in pathologic myopia. *Prog Retin Eye Res*. 2019;70:99–109.
24. Fajardo Sánchez J, Chau Ramos CE, Roca Fernández JA, Urcelay Segura JL. Estudio de las características clínicas, fundoscópicas, tomográficas y angiográficas de la mácula en domo según la altura de protrusión macular. *Arch Soc Esp Oftalmol*. 2017 Oct;92(10):458–463.
25. Soudier G, Gaudric A, Gualino V, et al. Serous retinal detachment in dome-shaped macula is associated with greater central choroidal blood flow measured by optical coherence tomography angiography. *Ophthalmologica*. 2020;243(2):129–135.
26. Spaide RF. Staphyloma: Part 1. In: Spade RF, Ohno-Matsui K, Yannuzzi LA, eds. *Pathologic Myopia*. New York, NY: Springer; 2014:167–176.