



Year: 2015

Root Canal Morphology and Configuration of 179 Maxillary First Molars by Means of Micro-computed Tomography: An Ex Vivo Study

Briseño-Marroquín, Benjamín; Paqué, Frank; Maier, Karolin; Willershausen, Brita; Wolf, Thomas Gerhard

Abstract: **INTRODUCTION** The objective of this study was to propose a root canal configuration description method and to investigate the root canal system morphology of the maxillary first molar by means of micro-computed tomographic imaging. **METHODS** The root canal configuration, foramina, and accessory canal frequency of 179 maxillary first molars were investigated by means of micro-computed tomographic imaging and 3-dimensional software imaging. The root canal configuration and main foramina number are described from coronal to apical with a 4-digit system. **RESULTS** The most frequent root canal configurations were 1-1-1/1 (45.8%), 2-2-2/2 (25.1%) and 2-2-1/1 (10.1%) in mesiobuccal roots and 1-1-1/1 in distobuccal (97.2%) and palatal (98.9%) roots. The first mesiobuccal (MB1) root canal had 1 accessory canal in 26.3% of the teeth, the distobuccal root canal had 12.3%, and the palatal root canal had 9.5%; in the second mesiobuccal root canal, there was rarely 1 accessory canal. There was 1 accessory canal in 26.3%, 12.3%, and 9.5% in the MB1, distobuccal, and palatal root canals, respectively. The MB1, distobuccal, and palatal root canals had 1 main foramen. The MB2 had 1 main foramen in 39.0% of the teeth and no main foramen in 61.0%. **CONCLUSIONS** The root canal configuration of maxillary first molars is quite diversified. Contrary to our expectations in this research, the mesiobuccal root has predominantly 1 root canal entrance and only 1 main foramen. Anatomic variations including connecting and accessory canals occur in any third of root.

DOI: 10.1016/j.joen.2015.09.007

Posted at the Zurich Open Repository and Archive, University of Zurich

ZORA URL: <http://doi.org/10.5167/uzh-121175>

Accepted Version



Originally published at:

Briseño-Marroquín, Benjamín; Paqué, Frank; Maier, Karolin; Willershausen, Brita; Wolf, Thomas Gerhard (2015). Root Canal Morphology and Configuration of 179 Maxillary First Molars by Means of Micro-computed Tomography: An Ex Vivo Study. *Journal of Endodontics*, 41(12):2008-2013. DOI: 10.1016/j.joen.2015.09.007

Root Canal Morphology and Configuration of 179 Maxillary First Molars by Means of Micro-Computed Tomography. An Ex Vivo-Study

Benjamín Briseño Marroquín DDS, MDS, PhD, Prof.*
Frank Paqué DDS, PhD**
Brita Willershausen DDS, PhD, Prof.*
Thomas Gerhard Wolf DDS, PhD*

*Department of Operative Dentistry
Johannes Gutenberg University Medical Center
Mainz, Germany

**Division of Preventive Dentistry, Periodontology, and Cariology
University of Zürich Center of Dental Medicine
Zürich, Switzerland

Corresponding author:
Thomas Gerhard Wolf
Poliklinik für Zahnerhaltung
Augustusplatz 2
55131 Mainz
Germany
e-mail: thomaswolf@uni-mainz.de
Tel: +496131173501 (office)
Fax +496131173406 (office)

Keywords

Maxillary first molar; micro-CT; morphology; root canal configuration; foramina

Acknowledgments

“The authors deny any conflicts of interest”

Abstract

Introduction

The objective of this study is to propose a root canal configuration description method and to investigate the root canal system morphology of the maxillary first molar by means of micro-CT (μ CT).

Materials and Methods

The root canal configuration, foramina and accessory canals frequency of 179 maxillary first molars, was investigated by means of μ CT and a 3D software imaging. The root canal configuration and main foramina number are described from coronal to apical with a four digit system.

Results

The most frequent root canal configurations were 1-1-1/1 (45.8%), 2-2-2/2 (25.1%) and 2-2-1/1 (10.1%) in mesiobuccal, 1-1-1/1 in the distobuccal (97.2%) and palatal (98.9%) roots. The MB1 had in 26.3%, DB in 12.3%, P in 9.5% and MB2 rarely one accessory canal. 26.3, 12.3, 9.5% in the MB1, distobuccal and palatal root canals had one accessory canal, respectively. The MB1, distobuccal and palatal root canals had one main foramen. The MB2 had in 39.0% one and in 61.0% none main foramen.

Conclusions

The root canal configuration of maxillary first molars is quite diversified. Contrary to our expectations in this research, the mesiobuccal root has predominantly one root canal entrance and only one main foramen. Anatomical variations, connecting and accessory canals occur in any third of a root.

Introduction

Knowledge of the complex three-dimensional root canal system and possible diversifications are an essential presupposition for a successful endodontic treatment (1-5). A detailed conceptual description; thus, understanding of the endodontic morphology will significantly reduce the demanding challenges during the access cavity preparation as well as during cleaning, shaping and filling procedures of the root canal system (6,7). Root canal anatomy has been described and controversially discussed in literature (3). Nowadays, micro-computed tomography (μ CT) combined together with a rendering software allows the imaging and three-dimensional analysis of tooth structures (5,8-12). High resolution μ CT not only provides a comprehensive analysis of the endodontic morphology, but it gives additional minute information of the root canal system complexity (4,8,13,14). Weine et al. (1) reported the first detailed morphological description of the maxillary first molar. A frequently employed root canal configuration description system was introduced by Vertucci (2). Yet, a considerable amount of teeth is difficult to precisely classify with these systems due to their anatomical complexity (12,15,16). The present study aims to describe the root canal system configuration and its relationship with the foramina of maxillary first molars and to propose a "universal" logic four digit code root canal configuration codification system through the evidence obtained.

Materials and Methods

Teeth selection

179 extracted human permanent maxillary first molars were obtained for reasons unrelated to the present study from dental clinics and dental practitioners and stored in 5.25% sodium hypochlorite. Out of a greater sample number, only teeth that could be clearly identified as maxillary first molars, according to their coronal and root anatomic-morphological appearance. Maxillary first and second molars were collected, screened and separated by view. Only teeth with three clear distinctly and mesiodistal crown diameter of 10.0 mm (± 0.2) were considered as maxillary first molars [Kraus et al., 1969]; otherwise they were excluded. The teeth obtained were from an Egyptian population (17) and their selection criteria were: complete development, no signs of root fracture, resorption, no radicular and coronal caries and that they had no endodontic treatment. The teeth were cleaned from any attached hard and soft tissues as well as calculus by means of an

ultrasonic scaler, placed for one hour in a 3% hydrogen peroxide ultrasonic bath and then stored in 70% alcohol according to their type and dental arch position. For further investigation of the teeth internal morphology (for research purposes not reported in this investigation), endodontic access cavities were prepared with a high-speed hand piece and a diamond round bur (801-014 / Komet, Lemgo, Germany). When required, ultrasonic tips were used to remove pulp stones. The pulp chambers were rinsed with 1% sodium hypochlorite (60 sec) and dried through suction.

Micro computed tomography (μ CT) - morphological analysis

The teeth were scanned at an isotropic resolution of 20 μ m in a desktop μ CT unit (μ CT 40; Scanco Medical, Brüttisellen, Switzerland) by means of a previously established method (9-11) at settings of 70 kV and 114 μ A resulting in 800 to 1200 slices per tooth.

To be able to differentiate the tooth structures, the images obtained were visualized through depiction in dummy colors in the 3D reconstructions of the μ CT scans using a specific software (VGStudio Max 2.2; Volumegraphics, Heidelberg, Germany). The structure of the teeth were color-coded by means of the rendering software. The pulp chamber and the root canal system were coded with red, the coronal enamel with white and the dentin with transparent-grey (Fig. 1).

The root canal configuration was described dividing the root into thirds. The first, second and third configuration digit provide the coronal, middle and apical third root canal number at the coronal limit of the respective third. The fourth digit is separated with a slash and indicates the main foramina number. Main foramina were defined as foramina, which emerged from the same canal at the apical terminus, and in which the measured diameter difference between the foramina was no less than 0.2 mm. The foramina diameter results are intended to be reported in a near future manuscript. Furthermore, the number of accessory and connecting root canals, as well as the number of apical accessory foramina observed under μ CT, were also recorded. A connecting canal was defined as the one that connects one root canal with the same one or another without merging into periapical tissue. The results are expressed through absolute and relative values according to the sample number.

Results

The root canal configuration proposal was established according to the results obtained and can be observed in Figs. 2-4. The root canal configuration is described with four digits. The first three digits reflect the root canal number at the coronal limit of the respective third of a root. The fourth digit is separated with a slash (instead of dash) and gives information about the number of main foramina present.

The root canal configuration description of the mesiobuccal, distobuccal and palatal roots is shown in Tab. 1. The most frequently observed root canal configuration in the mesiobuccal root (MB1 and MB2 root canals together) was 1-1-1/1 (45.8%), followed by 2-2-2/2 (25.1%) and 2-2-1/1 (10.1%). An additional 14 different root canal configurations were determined with less than 5% each in this root. Yet, all of these 14 root canal configurations together represent 17.3% of the total. A root canal configuration of 1-1-1/1 was most frequently observed in the distobuccal (97.2%) and palatal (98.9%) roots. The distobuccal and palatal roots showed four and two further root canal configurations.

The number and mean of accessory canals in the roots of the maxillary first molar, as well as the connecting canals from one to a different root canal, or as a "loop canal" within the same root canal are shown in Tab 2. The absence of accessory canals, as defined in this research, was the most frequent situation observed in all roots. The MB1 root canal had in 26.3% one and in 69.3% none accessory canal. The distobuccal and palatal root canals had in 12.3 and 9.5% one and in 2.8 and 2.2% two accessory canals, respectively.

The number of apical foramina observed, including main and accessory foramina, is shown in Tab 3. The MB1, distobuccal and palatal root canals had mostly one main foramen. The MB2 root canal had in 39.0% one and in 61.0% none main foramen (merged with the MB1 root canal). Also, only one main foramen was detected in a second distobuccal (0.6%) and palatal (1.1%) root canal. In 92.7% of the mesiobuccal roots examined, no accessory foramina were observed. The distobuccal root had only in 1.1% one accessory foramina.

Discussion

The aim of this study was to investigate the morphology of the maxillary first molar by means of μ CT-reconstruction and 3D-image-software system and to sustain a solid statistical analysis through a high number of samples. Different methods (1,2,15,18) have been used to achieve an adequate visualization of the root canal system. In vitro investigations have been enforced due to their superiority in comparison to the intrinsic limitations of in vivo investigations (4,19). Nevertheless, both, in vivo and in vitro research, can provide significant information to the clinician. μ CT has proven to be a relevant method (4,13,14,20) when compared with others such as root sectioning (1), microscopic examination (18) and even canal staining with tooth clearing (2) and is, in the mean time, considered to be the reference standard for laboratory morphological studies of the root canal system (4). The μ CT method is a non-invasive; thus, non-destructive method which allows an accurate morphological analysis of the root canal number and configurations (21).

The actual complexity and diversity of the root canal system can only be understood when root canal number and configuration, accessory and connecting canals, as well as main and accessory foramina are described. An accurate root canal configuration classification offers the clinician the possibility to easily describe and recognize the level of treatment complexity. Different configuration type classifications have been suggested in the literature (1,2,15,18); the classifications proposed by Weine et al. (1) and Vertucci (2) are probably the most widespread ones.

An exhaustive examination of the results obtained in this investigation (and further investigations not yet reported) led to a four digit description of the root canal configuration. Actually, the root canal configuration proposed in this study is similar to the one proposed by Vertucci (2). Regrettably, in our opinion, the configuration classification of Vertucci (2) was popularized with roman numerals, which does not allow to take advantage of the didactic benefits of the method. In this research each root was divided into thirds; thus, allowing for a detailed description of the root canal path from the coronal to the apical third. The fourth digit reveals the number of main foramina present and is separated with a slash (instead of an hyphen) for didactic purposes. The method describes the root canal number in the

coronal at the respective third limit. It could happen that the root canal splits right after this limit and the proposed configuration would give the perception that the information obtained could be wrong. Yet, the correct root canal(s) number will appear at the next apical level; in the case of the apical third it would appear as main foramina instead of root canal number. It would have been possible to divide the root canals in fourths in an effort to make a more accurate description of the root canal path. Yet, due to the large volume of teeth investigated (not only those included in this investigation), we were able to realize, that this possibility would be helpful only in a relative low amount of teeth. Thus, it was decided to work with thirds instead of fourths for the sake of didactic simplicity. The configuration description method, as proposed in this investigation, has not been, to the best of our knowledge, described in literature yet.

A wide range of configuration types, that cannot be described with the methods proposed by Weine et al. (1) and Vertucci (2) classification methods, have been described by different authors (15,16,22). In the present study, 17, 5 and 3 different configuration types in the mesiobuccal, distobuccal and palatal roots, respectively, were observed. The most frequently observed configurations in this research were 1-1-1/1 (45.8%), followed by 2-2-2/2 (25.1%) and 2-2-1/1 (10.1%). These results are similar, when compared with the respective restrictions, to the ones obtained by Vertucci (2) (type I; [1-1-1/1] 45%; type IV [2-2-2/2] 18% and type II [2-2-2/1, 2-2-1/1, 2-1-1/1] 37%) and Weine et al. (1) (type I [1-1-1/1] 48.5%, type III [2-2-2/2] 14.0% and type II [2-2-2/1, 2-2-1/1, 2-1-1/1] 37.5%).

The μ CT technology provides a non-invasive method, which allows for a complete and detailed visualization of the internal morphology; thus, configuration of the root canal system as well. It has been shown that not all of the root canal configurations that have been proposed with “classical” research methods can be validated when employing a μ CT as research methodology (4,8,23). The mesiobuccal root frequently showed only one root canal entrance (53.7%) and one main foramen (61%). Two entrances and two foramina were observed in 25.1%. These results are in contrast with those of Park et al. (4) in which they report one and two root canals in 28.3 and 65.2% cases, respectively. The root canal configuration frequency observed in this investigation is also in disagreement with the investigation reported by Weine et al. (1). These authors reported that the MB1 root canal

was present in 100% of the teeth examined and is consistent with our results. The MB2 root canal frequency is also similar to the results reported by Weine (1) (65.2%) and ours (46.5%). Yet, the presence of two root canals in 100% of the samples in the mesiobuccal root and with a relatively high frequency of two foramina (69%) (5), differs from our results. Two other μ CT studies reported the presence of two root canals in the mesiobuccal root with a 80% (13) and 90% (14) frequency. A literature review (3) of 34 in vivo and in vitro studies including 8399 maxillary first molars with different research methods reports an incidence of two canals in 60.5% in the mesiobuccal root and are not in agreement with our results. Yet, the presence of one canal in the distobuccal (98.3%) and palatal (99%) roots are similar to those obtained in this investigation (97.2 and 98.9%).

Verma and Love (14) were not able to observe a relationship between the number of main foramina and root canal configuration. The relatively high frequency of two main foramina in the mesiobuccal root observed in the present study (41%) is in agreement with other studies with 71.15% (17) and 65 % (14); whereas Grande et al. (24) detected in 40% three and more foramina. The inconsistencies of the comparison results are probably due to the different origin of the teeth, to the number of teeth investigated [179 against 13 (5), 20 (14) and 46 (2)] or to the research methodologies employed. The lack of age and gender in the present study, although not relevant in our opinion, however, should also be considered as a possibility to explain the discrepancies with other investigations.

Our results could also suggest that due to the relative high occurrence of two main foramina in the mesiobuccal root, the frequency of configurations 2-2-2/2, 1-1-1/2, 1-1-2/2 and 1-2-2/2 (Vertucci (2) type IV and V, respectively) may be higher in the Egyptian population (17). Yet, it would be difficult to sustain that this hypothesis is correct due to the high agreement, concerning the root canal configuration similarities in the distobuccal and palatal root canals, with other authors (15,25-28).

Five different types of root canal configuration were observed in the distobuccal root. These results are similar to those obtained by Sert and Bayirli (15), who observed 14 additional root canal configurations. However, Thomas et al. (29) and Wasti et al. (30) report a higher configuration variety. Similar to our results, the root canal configuration type of the palatal root has

been reported in the literature and with even lower variations from the 1-1-1/1 configuration (31,32) in the distobuccal root. In contrast, Wasti et al. (30) reported that 33.3% of the palatal roots of the maxillary first molars had a configuration type 1-2. These discrepancies could also be explained through the different type of ethnical samples origin and sample number.

Time before the presence of a second mesiobuccal root canal was confirmed (18), reports about the presence accessory canals could be found in the literature (33). The frequency of accessory canals found in the maxillary first molar, by means of a radiographic technique (34), was lower in all roots in comparison to the one reported by Pineda and Kuttler (18). In the present study accessory canals were observed in mesiobuccal root in (MB1 30.8%, MB2 5.6%), distobuccal 15.1% and palatal root 11.7% of the teeth. These findings are in contrast with the reported frequencies of more than 50% (35) or even close to 85% (2). The presence of connecting canals observed in the present study (2.9%) is in contrast to the 100% observed by Somma et al. (13) in 30 teeth of Italian origin investigated also by means of μ CT. These authors report isthmuses in 71% (10), which is also in contrast with the results of this investigation. While Al-Shalabi et al. (31) found no more than two and mostly only one accessory canal in the mesiobuccal root, in this investigation we were able to find up to five accessory root canals in the mesiobuccal root. The observed frequency of accessory canals in this research in the distobuccal and palatal roots are similar to those described in literature (15,31); yet, lower than those reported by Vertucci (2). The recognition of the presence of accessory canals and spaces, which cannot be mechanically cleaned and shaped, and because of the treatment limitations caused by the complex morphological characteristics of maxillary first molars, magnification and further development of root canal irrigants are highly recommended to compensate such endodontic surgical and non-surgical treatment pitfalls.

Conclusions

- The most frequent root canal configurations in the mesiobuccal root were 1-1-1/1 (45.8%), 2-2-2/2 (25.1%) 2-2-1/1 (10.1%)
- The most frequently observed root canal configuration in the distobuccal and palatal root was 1-1-1/1 (97.2% and 98.9%, respectively)

- Accessory canals in the MB1 and MB2 root canals were observed in 30.8 and 94.4% respectively and in the distobuccal and palatal root canals in 84.9 and 88.3%, respectively.
- Up to five accessory canals were observed in 30.8% of the MB1, up to three in 5.6% in the MB2, up to two in 15.1% in the distobuccal and in 11.7% in the palatal root canals. Connecting canals between the MB1 and MB2 root canals were observed in only 2.9% of the teeth examined.
- The MB1, distobuccal and the palatal root canal had only one main foramen in 100%; one main foramen was observed in 39.0% in the MB2 root canal. One accessory foramen was observed in 7.3% in the mesiobuccal root and 1.1% in the distobuccal root. No accessory foramen was observed in the palatal root.

References

1. Weine FS, Healey HJ, Gerstein H, Evanson L. Canal configuration in the mesiobuccal root of the maxillary first molar and its endodontic significance. *Oral Surg Oral Med Oral Pathol* 1969;28:419–25.
2. Vertucci FJ. Root canal anatomy of the human permanent teeth. *Oral Surg Oral Med Oral Pathol* 1984;58:589–99.
3. Cleghorn BM, Christie WH, Dong CCS. Root and root canal morphology of the human permanent maxillary first molar: a literature review. *J Endod* 2006;32:813–21.
4. Park J-W, Lee J-K, Ha B-H, Choi J-H, Perinpanayagam H. Three-dimensional analysis of maxillary first molar mesiobuccal root canal configuration and curvature using micro-computed tomography. *Oral Surg Oral Med Oral Pathol Oral Radiol Endod* 2009;108:437–42.
5. Domark JD, Hatton JF, Benison RP, Hildebolt CF. An ex vivo comparison of digital radiography and cone-beam and micro computed tomography in the detection of the number of canals in the mesiobuccal roots of maxillary molars. *J Endod* 2013;39:901–5.
6. Schilder H. Filling root canals in three dimensions. *Dent Clin North Am* 1967;11:723–44.
7. Schilder H. Cleaning and shaping the root canal. *Dent Clin North Am* 1974;18:269–96.
8. Plotino G, Grande NM, Pecci R, Bedini R, Pameijer CH, Somma F. Three-dimensional imaging using microcomputed tomography for studying tooth macromorphology. *J Am Dent Assoc* 2006;137:1555–61.
9. Paqué F, Ganahl D, Peters OA. Effects of root canal preparation on apical geometry assessed by micro-computed tomography. *J Endod* 2009;35:1056–9.
10. Peters OA, Boessler C, Paqué F. Root canal preparation with a novel nickel-titanium instrument evaluated with micro-computed tomography: canal surface preparation over time. *J Endod* 2010;36:1068–72.
11. Peters OA, Paqué F. Root canal preparation of maxillary molars with the self-adjusting file: a micro-computed tomography study. *J Endod* 2011;37:53–7.
12. Ahmad IA, Al-Jadaa A. Three root canals in the mesiobuccal root of maxillary molars: case reports and literature review. *J Endod* 2014;40:2087–94.
13. Somma F, Leoni D, Plotino G, Grande NM, Plasschaert A. Root canal morphology of the mesiobuccal root of maxillary first molars: a micro-computed tomographic analysis. *Int Endod J* 2009;42:165–74.
14. Verma P, Love RM. A Micro CT study of the mesiobuccal root canal morphology of the maxillary first molar tooth. *Int Endod J* 2011;44:210–7.
15. Sert S, Bayirli GS. Evaluation of the root canal configurations of the mandibular and maxillary permanent teeth by gender in the Turkish population. *J Endod* 2004;30:391–8.
16. Lee K-W, Kim Y, Perinpanayagam H, Lee J-K, Yoo Y-J, Lim S-M, Chang SW, Ha B-H, Zhu Q, Kum K-Y. Comparison of alternative image reformatting techniques in micro-computed tomography and tooth clearing for detailed canal morphology. *J Endod* 2014;40:417–22.
17. Marroquín BB, El-Sayed MAA, Willershausen-Zönnchen B. Morphology of the physiological foramen: I. Maxillary and mandibular molars. *J Endod* 2004;30:321–8.
18. Pineda F, Kuttler Y. Mesiodistal and buccolingual roentgenographic investigation of 7,275 root canals. *Oral Surg Oral Med Oral Pathol* 1972;33:101–10.
19. Jung I-Y, Seo M-A, Fouad AF, Spångberg LSW, Lee S-J, Kim H-J, Kum K-Y. Apical anatomy in mesial and mesiobuccal roots of permanent first molars. *J Endod* 2005;31:364–8.
20. Baratto Filho F, Zaitter S, Haragushiku GA, de Campos EA, Abuabara A, Correr GM. Analysis of the internal anatomy of maxillary first molars by using different methods. *J Endod* 2009;35:337–42.
21. Nielsen RB, Alyassin AM, Peters DD, Carnes DL, Lancaster J. Microcomputed tomography: an advanced system for detailed endodontic research. *J Endod* 1995;21:561–8.
22. Filpo-Perez C, Bramante CM, Villas-Boas MH, Húngaro Duarte MA, Versiani MA, Ordinola-Zapata R. Micro-computed tomographic analysis of the root canal morphology of the distal root of mandibular first molar. *J Endod* 2015;41:231–6.
23. Rhodes JS, Ford TR, Lynch JA, Liepins PJ, Curtis RV. Micro-computed tomography: a new tool for experimental endodontology. *Int Endod J* 1999;32:165–70.
24. Grande NM, Plotino G, Pecci R, Bedini R, Pameijer CH, Somma F. Micro-computerized tomographic analysis of radicular and canal morphology of premolars with long oval canals. *Oral Surg Oral Med Oral Pathol Oral Radiol Endod* 2008;106(3):e70–6.
25. Alavi AM, Opasanon A, Ng YL, Gulabivala K. Root and canal morphology of Thai maxillary molars. *Int Endod J* 2002;35:478–85.

26. Ng YL, Aung TH, Alavi A, Gulabivala K. Root and canal morphology of Burmese maxillary molars. *Int Endod J* 2001;34:620–30.
27. Rwenyonyi CM, Kutesa AM, Muwazi LM, Buwembo W. Root and canal morphology of maxillary first and second permanent molar teeth in a Ugandan population. *Int Endod J* 2007;40:679–83.
28. Weng X-L, Yu S-B, Zhao S-L, Wang H-G, Mu T, Tang R-Y, et al. Root canal morphology of permanent maxillary teeth in the Han nationality in Chinese Guanzhong area: a new modified root canal staining technique. *J Endod* 2009;35:651–6.
29. Thomas RP, Moule AJ, Bryant R. Root canal morphology of maxillary permanent first molar teeth at various ages. *Int Endod J* 1993;26:257–67.
30. Wasti F, Shearer AC, Wilson NH. Root canal systems of the mandibular and maxillary first permanent molar teeth of south Asian Pakistanis. *Int Endod J* 2001;34:263–6.
31. Shalabi al RM, Omer OE, Glennon J, Jennings M, Claffey NM. Root canal anatomy of maxillary first and second permanent molars. *Int Endod J* 2000;33:405–14.
32. Shahi S, Yavari HR, Rahimi S, Ahmadi A. Root canal configuration of maxillary first permanent molars in an Iranian population. *J Dent Res Dent Clin Dent Prospects*. 2007;1:1–5.
33. Barrett MT. The internal anatomy of teeth with special reference to the pulp and its branches. *Dent Cosmos* 1925;67:581–92.
34. Pineda F. Roentgenographic investigation of the mesiobuccal root of the maxillary first molar. *Oral Surg Oral Med Oral Pathol* 1973;36:253–60.
35. Kim Y, Lee S-J, Woo J. Morphology of maxillary first and second molars analyzed by cone-beam computed tomography in a Korean population: variations in the number of roots and canals and the incidence of fusion. *J Endod* 2012;38:1063–8.

Maxillary first molar / Root Canal Configuration			
Root	Configuration	Frequency	
		Absolute	Mean
MB (MB1 & MB2)	1-1-1/1	82	45.8
	2-2-2/2	45	25.1
	2-2-1/1	18	10.1
	2-1-1/1	7	3.9
	1-1-2/2	6	3.4
	1-1-1/2	4	2.2
	1-2-2/2	3	1.7
	3-3-2/2	3	1.7
	2-1-2/2	2	1.1
	2-2-1/2	2	1.1
	1-3-1/1	1	0.6
	2-1-1/2	1	0.6
	2-2-3/3	1	0.6
	3-2-3/2	1	0.6
	3-3-1/1	1	0.6
	3-3-2/3	1	0.6
	3-3-3/3	1	0.6
DB	1-1-1/1	174	97.2
	1-1-1/2	2	1.1
	1-1-2/1	1	0.6
	2-1-1/1	1	0.6
	2-2-1/1	1	0.6
P	1-1-1/1	177	98.9
	1-1-2/1	1	0.6
	2-2-1/1	1	0.6

Tab 1. Root canal configuration observed under μ CT of the maxillary first molar (n = 179). The mesiobuccal root depicts the results of the MB1 and MB2 root canals together. The configuration numbers from left to right describe the root canal path from the coronal, middle and apical thirds, respectively. The last number, separated with a slash, depicts the number of main foramina observed.

Canals	MB1		MB2		Connecting		DB		P	
	n	%	n	%	n	%	n	%	n	%
0	124	69.3	169	94.4	174	97.2	152	84.9	158	88.3
1	47	26.3	4	2.2	3	1.7	22	12.3	17	9.5
2	5	2.8	5	2.8	1	0.6	5	2.8	4	2.2
3	1	0.6	1	0.6						
4					1	0.6				
5	2	1.1								

Tab 2. Absolute number (n) and mean (%) of accessory and connecting canals observed under μ CT of the maxillary first molar (n =179).

F	MB1		MB2		MB-Acc		DB		DB2		DB-Acc		P		P2	
	n	%	n	%	n	%	n	%	n	%	n	%	n	%	n	%
0			109	61.0	166	92.7			178	99.4	177	98.9			177	98.9
1	179	100	70	39.0	13	7.3	179	100	1	0.6	2	1.1	179	100	2	1.1

Tab 3. Absolute number (n) and mean (%) of apical main and accessory (Acc) foramina observed under μ CT of the maxillary first molar (F = foramina; MB-Acc = accessory foramina in the mesiobuccal root; DB2 = second distobuccal root canal; P2 = second palatal root canal; n =179).

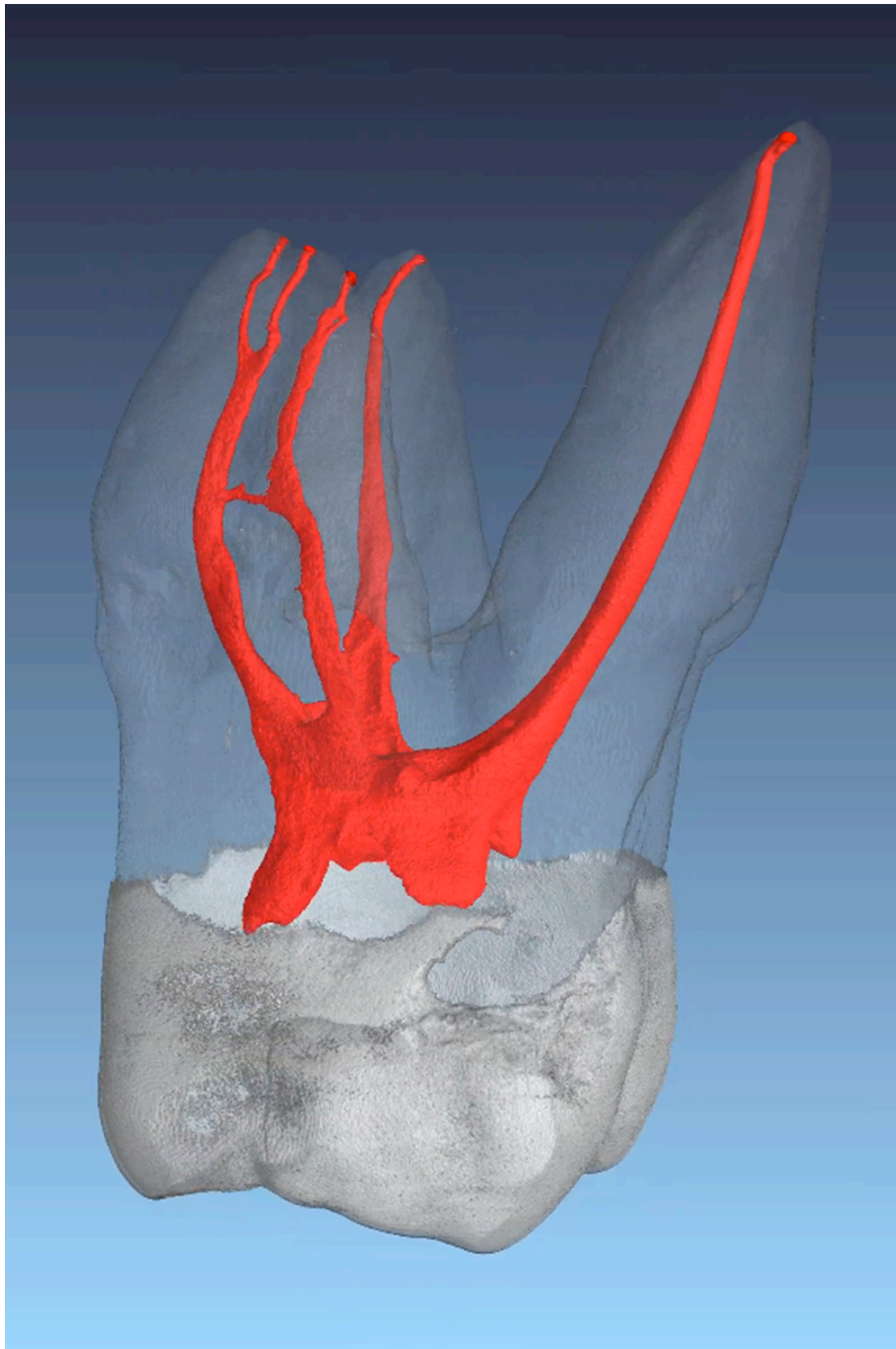


Fig. 1. μ CT of a maxillary first molar. The different dental structures (enamel, dentin and pulp) are easy to depict through the color code obtained through the employed software. The palatal and distobuccal root canals have, in this case, a 1-1-1/1 root canal configuration. The mesiobuccal root canal configuration is more complicated (MB1 = 1-1-1/2; MB2 1-1-1/1). A connecting canal between the MB1 and MB2 root canals can be observed.

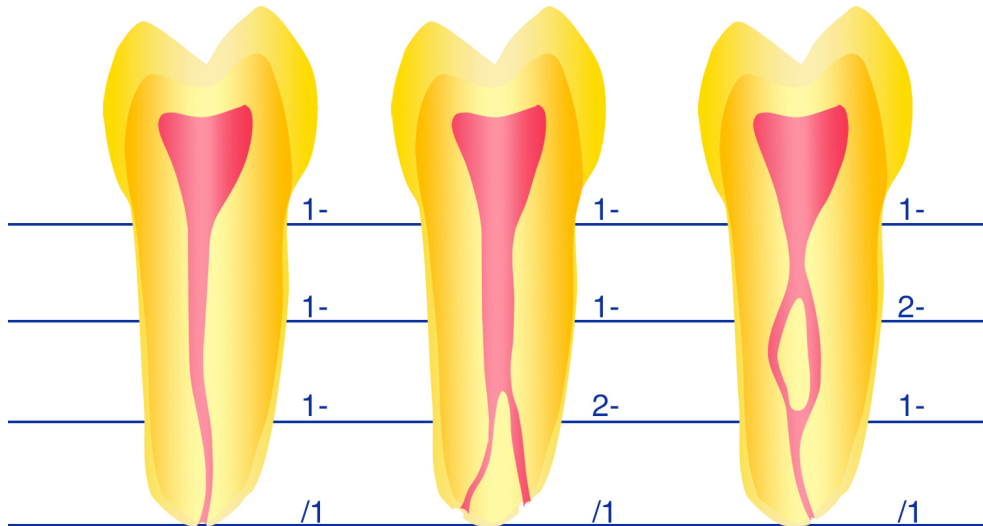


Fig. 2. Proposed morphological description of the root canal configuration of root canals starting with one root canal at the pulp chamber floor level. The digits describe the canal number at the coronal level of the respective third limit. The foramina number is separated with a slash to facilitate understanding of the digits meaning.

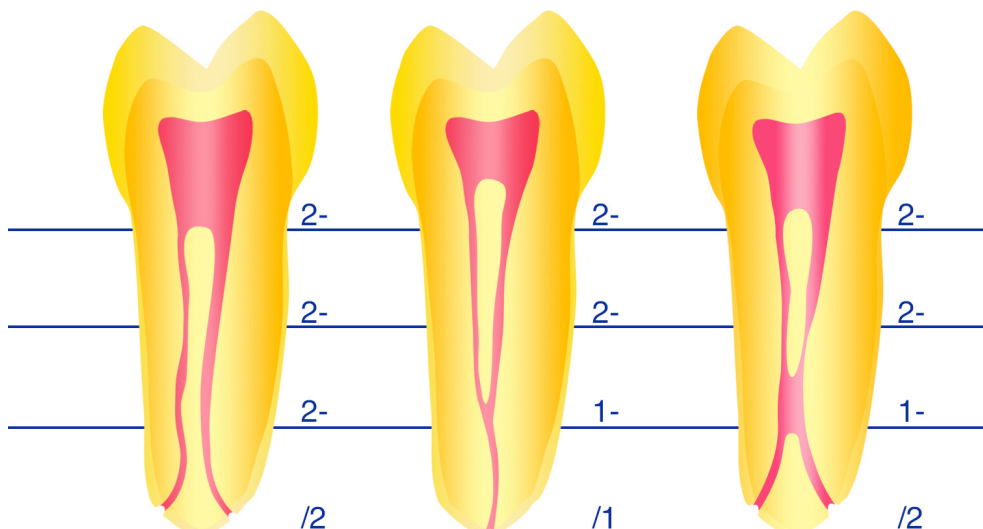


Fig. 3. Proposed morphological description of the root canal configuration of root canals starting with two root canals at the pulp chamber floor level. The digits describe the canal number at the coronal level of the respective third limit. The foramina number is separated with a slash to facilitate understanding of the digits meaning.

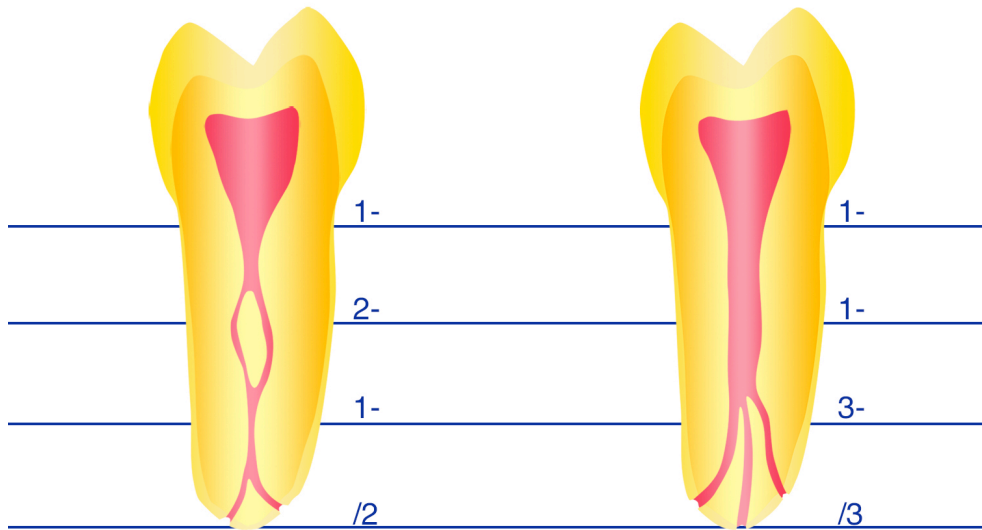


Fig. 4. Proposed morphological description of the root canal configuration. This figure describes the exemptions of the one and two root canals configurations. The digits describe the canal number at the coronal level of the respective third limit. The foramina number is separated with a slash to facilitate understanding of the digits meaning.