



Gardner, David S. and Welham, Simon J.M. and Dunford, Louise J. and McCulloch, Thomas A. and Hodi, Zsolt and Sleeman, Philippa and O'Sullivan, Saoirse and Devonald, Mark A.J. (2014) Remote conditioning or erythropoietin before surgery primes kidneys to clear ischemia-reperfusion-damaged cells: a renoprotective mechanism? *American Journal of Physiology - Renal Physiology*, 306 (8). F873-F884. ISSN 1931-857X

Access from the University of Nottingham repository:

<http://eprints.nottingham.ac.uk/28887/1/Gardner%20et%20al%202014.pdf>

Copyright and reuse:

The Nottingham ePrints service makes this work by researchers of the University of Nottingham available open access under the following conditions.

- Copyright and all moral rights to the version of the paper presented here belong to the individual author(s) and/or other copyright owners.
- To the extent reasonable and practicable the material made available in Nottingham ePrints has been checked for eligibility before being made available.
- Copies of full items can be used for personal research or study, educational, or not-for-profit purposes without prior permission or charge provided that the authors, title and full bibliographic details are credited, a hyperlink and/or URL is given for the original metadata page and the content is not changed in any way.
- Quotations or similar reproductions must be sufficiently acknowledged.

Please see our full end user licence at:

http://eprints.nottingham.ac.uk/end_user_agreement.pdf

A note on versions:

The version presented here may differ from the published version or from the version of record. If you wish to cite this item you are advised to consult the publisher's version. Please

see the repository url above for details on accessing the published version and note that access may require a subscription.

For more information, please contact eprints@nottingham.ac.uk

Remote conditioning or erythropoietin before surgery primes kidneys to clear ischemia-reperfusion-damaged cells: a renoprotective mechanism?

David S. Gardner,¹ Simon J. M. Welham,² Louise J. Dunford,^{1,5} Thomas A. McCulloch,⁴ Zsolt Hodi,⁴ Philippa Sleeman,¹ Saoirse O'Sullivan,⁶ and Mark A. J. Devonald^{3,5}

¹School of Veterinary Medicine and Science, University of Nottingham, Loughborough, United Kingdom; ²School of Biosciences, University of Nottingham, Loughborough, United Kingdom; ³School of Clinical Sciences, University of Nottingham, Nottingham University Hospitals NHS Trust, Nottingham, United Kingdom; ⁴Histopathology Unit, City Hospital, Nottingham, United Kingdom; ⁵Renal and Transplant Unit, City Hospital, Nottingham, United Kingdom; and ⁶School of Graduate Entry Medicine and Health, Royal Derby Hospital, Derby, United Kingdom

Submitted 31 October 2013; accepted in final form 10 February 2014

Gardner DS, Welham SJ, Dunford LJ, McCulloch TA, Hodi Z, Sleeman P, O'Sullivan SE, Devonald MA. Remote conditioning or erythropoietin before surgery primes kidneys to clear ischemia-reperfusion-damaged cells: a renoprotective mechanism? *Am J Physiol Renal Physiol* 306: F873–F884, 2014. First published February 12, 2014; doi:10.1152/ajprenal.00576.2013.—Acute kidney injury is common, serious with no specific treatment. Ischemia-reperfusion is a common cause of acute kidney injury (AKI). Clinical trials suggest that preoperative erythropoietin (EPO) or remote ischemic preconditioning may have a renoprotective effect. Using a porcine model of warm ischemia-reperfusion-induced AKI (40-min bilateral cross-clamping of renal arteries, 48-h reperfusion), we examined the renoprotective efficacy of EPO (1,000 iu/kg iv.) or remote ischemic preconditioning (3 cycles, 5-min inflation/deflation to 200 mmHg of a hindlimb sphygmomanometer cuff). Ischemia-reperfusion induced significant kidney injury at 24 and 48 h (χ^2 , 1 degree of freedom, >10 for 6/7 histopathological features). At 2 h, a panel of biomarkers including plasma creatinine, neutrophil gelatinase-associated lipocalin, and IL-1 β , and urinary albumin:creatinine could be used to predict histopathological injury. Ischemia-reperfusion increased cell proliferation and apoptosis in the renal cortex but, for pretreated groups, the apoptotic cells were predominantly intratubular rather than interstitial. At 48-h reperfusion, plasma IL-1 β and the number of subcapsular cells in G2-M arrest were reduced after preoperative EPO, but not after remote ischemic preconditioning. These data suggest an intrarenal mechanism acting within cortical cells that may underpin a renoprotective function for preoperative EPO and, to a limited extent, remote ischemic preconditioning. Despite equivocal longer-term outcomes in clinical studies investigating EPO as a renoprotective agent in AKI, optimal clinical dosing and administration have not been established. Our data suggest further clinical studies on the potential renoprotective effect of EPO and remote ischemic preconditioning are justified.

potentially preventable; AKI; kidney; RIPC; EPO; cell cycle

ACUTE KIDNEY INJURY (AKI) imposes a heavy burden on patients and on health services, being a common cause of in-hospital morbidity and mortality. Warm ischemia with reperfusion frequently results in AKI (2, 22). Despite being a potentially preventable condition, the incidence of AKI has remained unchanged for decades. A clearer understanding of the pathophysiology of AKI, including association with serum or urinary biomarkers at an early stage, is an important scientific and

clinical target (13) and enables targeted renoprotective interventions to be developed.

Human recombinant erythropoietin (EPO) is an established drug for the treatment of renal anemia. EPO has been demonstrated to be renoprotective in rodent models of ischemic (23, 27)-, sepsis (8)-, nephrotoxin (19)- or cold ischemia-reperfusion-induced (5) AKI. A pilot clinical study reported encouraging preliminary results (26). However, substantial clinical evidence for renoprotection by EPO is lacking (7, 9). In contrast, remote ischemic preconditioning (RIPC), in which short-term (1–5 min), nonlethal episodes (3–5 cycles) of limb ischemia remote to the organ of interest result in attenuated tissue injury during subsequent longer-term ischemia and reperfusion, has been reported to offer considerable protection against ischemia-reperfusion (IR)-induced organ damage. RIPC has been demonstrated in the heart (4, 11), brain (12), liver (1), and kidney (30), but negative results have also been reported (17). A randomized-controlled clinical trial to ascertain the effectiveness of RIPC for prevention of AKI is ongoing (10). In common with EPO, the effectiveness and potential mechanism of renoprotective action of RIPC have not been described in detail in a relevant, preclinical large-animal model.

In this study, we have first developed and optimized a porcine model of AKI. The pig has a number of advantages over other laboratory models that make it appropriate as a preclinical animal model for the study of renal disease. First, serial organ biopsies may be taken, allowing the time course of injury to be determined. Second, such serial within-animal sampling ensures less biological variation and thus fewer animals may be used to achieve satisfactory statistical power. Third, porcine kidneys are functionally and histologically similar to human kidneys, likely responding to ischemia-reperfusion-induced injury (IRI) in a similar fashion (16). Using our porcine model of AKI, we tested the renoprotective efficacy of preoperatively administered EPO or remote ischemic conditioning. Our primary outcome was histopathological assessment of the kidney at 24 h (by percutaneous biopsy) and at 48 h (after post mortem). Using an animal model allowed us to relate time-resolved histopathology to a secondary outcome, a serial analysis of potential AKI biomarkers in plasma [neutrophil gelatinase-associated lipocalin (NGAL), creatinine, urea, albumin, osmolality, IL-1 β] and urine (creatinine, urea, albumin, osmolality, electrolytes) (2). From the biobanked tissue samples after biopsy at 24 h or post mortem at 48 h, we investigated the renal cortical cell response to injury using

Address for reprint requests and other correspondence: D. Gardner, School of Veterinary Medicine and Science, Univ. of Nottingham, Sutton Bonington Campus, Loughborough LE12 5RD, UK (e-mail: david.gardner@nottingham.ac.uk).

immunohistofluorescence for markers of the cell cycle and apoptosis. Our data indicate that histopathological and physiological changes in early AKI do not appear to correlate well. However, a panel of early biomarkers provides evidence of developing AKI. Our data suggest that plasma creatinine, NGAL, and IL-1 β together with the urinary albumin-to-creatinine ratio (ACR) at 2 h provide early noninvasive evidence of developing AKI. We further show that the putative renoprotective value of EPO or RIPC pretreatment may relate to their influence on renal cortical cell handling of apoptotic cellular debris. Furthermore, in the short term, EPO but not RIPC elicited a significant reduction in plasma IL-1 β and reduced the number of p-H3^{ser10} G2-M-arrested cells in the outer cortex after IRI. This might be a mechanism by which EPO confers renoprotection in AKI.

METHODS

Animals. All procedures were performed in accordance with the UK Animals (Scientific Procedures) Act, (1986) and were approved by the local ethical review committee of the University of Nottingham. Thirty female pigs [58 \pm 4.6 kg (means \pm SD)] were anesthetized for general surgery [buprenorphine (0.05 mg/kg), ketamine (5 mg/kg), and detomidine (0.1 mg/kg)] with alfaxalone (0.7–2.4 mg/kg iv), dosed to effect for intubation. Anesthesia was maintained with isoflurane (1–2% in O₂) and ventilated using a tidal volume of 10–12 ml/kg. A venous catheter was inserted for supportive fluid delivery and vascular access. The depth of anesthesia and other parameters were monitored during surgery and were not different across treatment groups. A midline laparotomy was performed, and both the right and left kidneys were revealed for renal artery cross-clamping (40 min), after which clamps were removed and the incision site closed. A bladder catheter (12 Fr) was inserted for urine collection, and the pigs were recovered to a pen. One sham control pig developed malignant hyperthermia during anesthesia, was humanely euthanized without recovery, and was excluded from analysis. Postoperative

analgesia was maintained with buprenorphine every 8 h for the first 24 h and thereafter every 12–24 h, including tramadol (4 mg/kg im) as required.

Experimental design. Pigs were randomly assigned (sealed envelope) to either a sham control ($n = 12, n = 4/\text{group}$) or IR ($n = 18, n = 6/\text{group}$) group and to one of three treatment protocols: 1) intravenous (iv) pretreatment with 5 ml saline; 2) iv pretreatment with EPO at 1,000 iu/kg; or 3) pretreatment with RIPC, consisting of three cycles of 5-min inflation to 200 mmHg, followed by 5-min deflation of a sphygmomanometer cuff placed around a hind leg. Pretreatment was conducted 30 min before induction of renal IRI. Plasma and urine were sampled at intervals throughout the study and biobanked at -20°C for further analysis. A percutaneous right kidney biopsy was performed with ultrasound guidance at 24 h, and pigs were lightly sedated. An outline of the experimental design is given in Fig. 1.

Histopathology and immunohistofluorescence. At 48 h, all pigs were humanely euthanized by a lethal dose of barbiturate (200 mg/kg), and selected tissues were snap-frozen in LN₂ or fixed in 4% paraformaldehyde and subsequently preserved. Histopathology and immunohistofluorescence were conducted on 5- μm sections using standard laboratory protocols. Each section from all animals was assessed independently by two renal consultant histopathologists blinded to the sample ID. Antibodies against PCNA (ab29) and p-H3^{ser10} (ab5176) were purchased from Abcam (Cambridge, UK). Sequence specificity for the protein of interest was $>95\%$ in each case. Primary antibodies were used after heat-mediated antigen retrieval at a concentration of 1:1,000, with blocking by 10% neutral goat serum. Secondary antibodies were either Alexa Fluor 544 used at 1:300 or Texas Red Goat anti-mouse (Invitrogen) used at 1:100. To assess immune cell infiltration into kidney tissue, we used frozen sections (10 μm) to quantify staining with swine leucocyte antigen (SLA), which marks cells expressing the MHC class II (DR region; MCA2314, Serotec) at the cell surface, and in paraffin-embedded sections we used the anti-macrophage antibody MAC387 (ab22506, Abcam).

Blood and urine chemistry. Plasma and urine albumin (g/l), creatinine ($\mu\text{mol/l}$), and urea (mmol/l) were measured by autoanalyzer

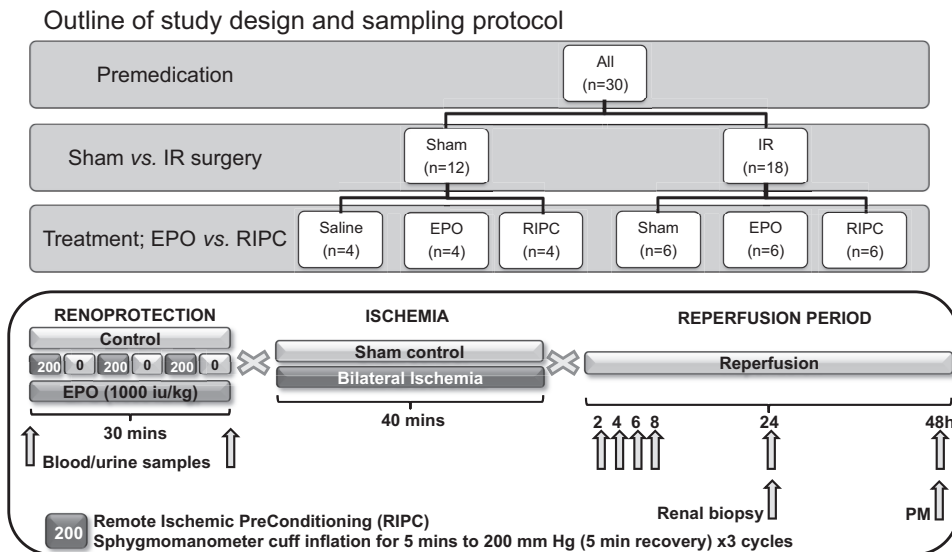


Fig. 1. Outline of study design. Pigs were randomly assigned (sealed envelope) to either a sham control ($n = 12, n = 4/\text{group}$) or ischemia-reperfusion (IR; $n = 18, n = 6/\text{group}$) group and to 1 of 3 treatment protocols: 1) intravenous (iv) pretreatment with 5 ml saline; 2) iv pretreatment with erythropoietin (EPO) at 1,000 iu/kg; or 3) pretreatment with remote ischemic preconditioning (RIPC), consisting of 3 \times cycles of 5-min inflation to 200 mmHg, followed by 5-min deflation of a sphygmomanometer cuff placed around a hind leg. Pretreatment was conducted 30 min before induction of renal IR injury. Plasma was obtained from serial blood samples (10 ml into K⁺-EDTA and heparinized tubes) taken from all animals before IR (-30 min, baseline), post-RIPC (-5 min), and postoperatively at 2, 4, 6, 8, 24, and 48 h. Urine was spot-sampled at baseline and postoperatively at 2, 4, 6, 8, 24, and 48 h. Each was biobanked at -20°C for further analysis. A percutaneous right kidney biopsy was performed with ultrasound guidance at 24 h, and pigs were lightly sedated. PM, post mortem.

(RX-Imola, Randox, Co. Antrim, Northern Ireland, UK) with typical interassay variation of <5%. Osmolality was measured by freezing point depression (Osmomat 030, Gonotech). Electrolytes (Na^+ and Cl^-) were determined by inductively coupled mass spectrometry (ICP-MS; XSeries II, Thermo Fisher) with intra-assay variability being <2%. Plasma NGAL was measured using a commercially available porcine-specific ELISA (Kit-044; Bioprote) following the kit instructions; intra- and interassay variation was <5%. An array of cytokines in plasma and kidney tissue lysates (IL-1 α , -1 β , -2, -4, -6, -10, -12, -18 and TNF- α) were measured using a porcine-specific Illuminex assay, in magnetic bead format (PCYTMAG-23K, Millipore).

Statistical analysis. Continuous data (e.g., plasma/urinary metabolites) were analyzed using analysis of variance with IR (yes/no) \times treatment (saline/EPO/RIPC) plus interactions as fixed effects and time (+0–48 h) as a within-animal repeated measure, where appropriate. Nonparametric data were \log_{10} transformed before analysis. Ordinal data (e.g., ATN injury score) were analyzed by regression, fitting Poisson (for categorical data) or binomial (yes/no) errors. Significance was accepted with χ^2 (degrees of freedom, 1) >3.84. To explore any relationship between fixed effects and AKI categories, logistical generalized estimating equations were used, adjusted for potential covariates (e.g. baseline plasma creatinine). $P \leq 0.050$ was accepted as indicating statistical significance. In addition, a multivariate linear discriminant analysis that captured <95% variation from all histopathological scores within treatment groups was used. The number of pigs allocated per group was based on a previous pilot study ($n = 5$ pigs) in which histopathological score variability between sham controls was minimal but was increased by IR. Hence, we randomized by sealed envelope $n = 4/\text{group}$ for controls and $n = 6/\text{group}$ for IR. Considering a 10% probability of detecting mild-moderate acute kidney injury in the sham control group but a 90% probability in the untreated IR group gives the study a power of 90% with significance (α) set at 0.05.

RESULTS

Histopathology of the kidney after IRI. Forty-minute ischemia in the pig was determined as the optimal duration for occlusion of the renal arteries to induce mild-moderate renal injury, as opposed to severe injury that fails to recapitulate the clinical picture (20). At 24 and 48 h after ischemia (by biopsy and post mortem, respectively), the kidneys had significant histopathological damage, which was not prevented by the putative renoprotective treatments (Figs. 2 and 3).

Blood and urine chemistry after IRI. We performed longitudinal analysis of metabolites and potential biomarkers in plasma and urine before and after renal IR. At baseline, plasma osmolality was 310 (307–313) mosmol/kgH₂O-mean [95% confidence interval (CI)] and remained unchanged regardless of IR or treatment. In contrast, plasma creatinine, urea ($P < 0.001$, both cases), and NGAL ($P = 0.056$) increased with IR (Fig. 4, A–C). EPO and RIPC treatment appeared to blunt the increase in NGAL with IR at 2 h, but not thereafter (Fig. 4B, b1–b3). The change in urine biochemistry after IRI marked a significant decline in kidney function with reduced urinary loss of creatinine, urea, sodium, and reduced osmolality (Fig. 5). However, ACR significantly increased, peaking as early as 2 h post-IRI (Fig. 5C).

Cell survival or cell death after IRI. At 24 h after IRI, there was a nonsignificant trend toward a greater number of terminal deoxynucleotidyl transferase (TdT)-mediated dUTP nick-end labeling (TUNEL) TUNEL⁺ cells in the IR group [control, 0.2 (0.0–1.6) vs. IR, 1.2 (0.5–6.2); $P = 0.07$ median interquartile

range (IQR)] that increased and became significant by 48 h [control, 0.3 (0.0–2.0) vs. IR, 40 (0.0–84.5); $P = 0.01$ median IQR]. Notably, at 24 (Fig. 6) and 48 h (Fig. 7), both EPO- and RIPC-pretreated IR groups exhibited a much greater proportion of apoptotic (TUNEL⁺) cells that were intratubular, colocalized with proteinaceous casts in the distal tubules, rather than randomly distributed throughout the cortex and outer medulla. This suggested that pretreatment with EPO and RIPC in the context of IRI may support an enhanced residual capacity of the kidney to shed apoptotic cellular debris and facilitate recovering tubular cells to proceed through the cell cycle, rather than become arrested at the second checkpoint before mitosis (G2-M) and become fibrotic, as has been shown in mice (28). Hence we used immunofluorescence to identify proliferative (PCNA⁺, captures cells in late G1 and S-phase during DNA synthesis) vs. nonproliferative (phospho-histone 3⁺ p-H3, captures cells stalled in the G2-M phase) cells. IR elicited a significant increase in PCNA⁺ve (Fig. 8A) and p-H3⁺ve cells (Fig. 8B). The area of PCNA⁺ve cells was similar between IR groups (Fig. 8C). While the number of p-H3⁺ve cells increased from the subcapsular to corticomedullary region (sequential field-of-view measurements from subcapsular to corticomedullary junction; Fig. 8D), we also found that the number of p-H3⁺ve cells was significantly less in the outer, but not inner, cortex of EPO-treated IR animals ($F_{pr} = 0.021$ for interaction; Fig. 8, E and F). Furthermore, while IR was marked by an early increase in plasma IL-1 β that peaked at 8-h reperfusion (no other cytokines were observed to increase significantly), in those animals that had received preoperative EPO, but not saline or RIPC, plasma IL-1 β had returned to baseline and was indistinguishable from sham controls by 24-h reperfusion (Fig. 9). Accordingly, the concentration of kidney tissue cytokines was not different in IR kidneys relative to sham controls at 48-h reperfusion (Table 1), and immune cell infiltration as marked by SLA (MHC-II) and macrophage (MAC387) staining was unremarkable and not different between groups at this time (data not shown).

DISCUSSION

Clinical context of AKI and renoprotective modalities. AKI is a huge clinical problem worldwide. In the United Kingdom, the Kidney Alliance has estimated that death rates from AKI exceed those from methicillin-resistant *Staphylococcus aureus* by 100-fold (AKI; between 62,000 and 210,000 vs MRSA; 364 in 2011; information at <http://www.worldkidneyday.co.uk/>) costing the NHS up to £789 million per year. AKI, unlike many other noncommunicable diseases, is preventable in many cases. It has been estimated that, through the delivery of optimal care, at least 12,000 lives and £130–£186 million could be saved. Nevertheless, over the last few decades treatment of AKI has been at best supportive. Hence investigation of potentially renoprotective therapies continues to receive much attention. To date, preoperative administration of EPO and RIPC are two putative renoprotective interventions that have been studied in animal models and clinical trials. In early rodent (8, 19, 23, 27), porcine (25) and clinical (26) studies, preoperative EPO administration showed promise for reducing aspects of AKI, but further clinical studies have subsequently proved disappointing (7, 9). In contrast, a number of

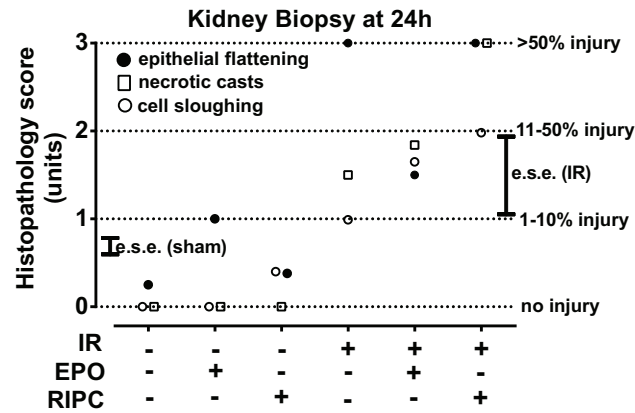
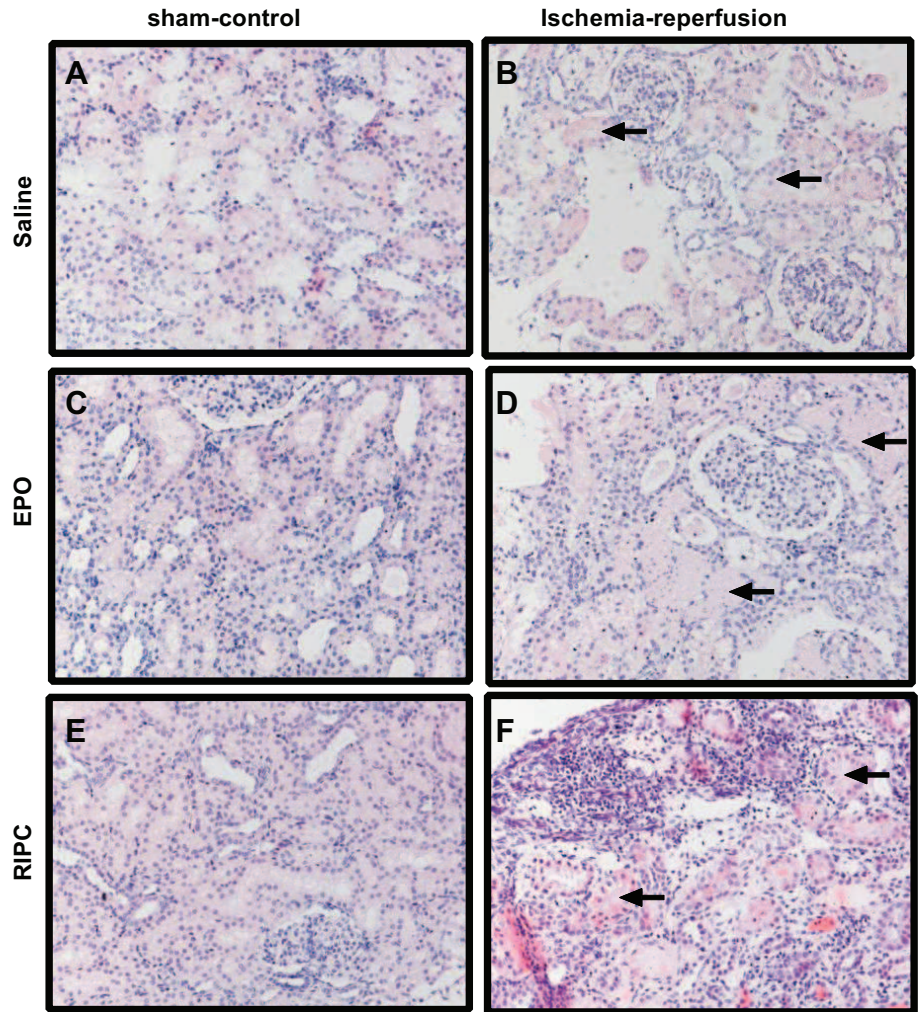


Fig. 2. Histological assessment of acute kidney injury in renal biopsies at 24 h indicates presence of significant injury. *Top*: 2 pathologists, independently and blinded to the provenance of sections, scored on a discrete scale (0, no injury; 1, 1–10%; 2, 11–50%, 3, >50%) 4 histopathological parameters: epithelial flattening, necrotic casts, cell sloughing, and interstitial infiltrate. Data are predicted mean scores [pooled estimated error for main effects (sham vs. IR) represented by e.s.e.] after ordinal regression analysis and adjustment for pathologist (there was no significant difference between pathologist for all scores). There was a significant main effect of IR on epithelial flattening [$\chi^2 = 9.88$ (1 degree of freedom; df), $P = 0.007$], necrotic casts [$\chi^2 = 44.6$ (1 df), $P < 0.001$], and cell sloughing [$\chi^2 = 14.7$ (1 df), $P = 0.002$]. The number of glomeruli in biopsies was sham, 12 ± 2 ; IR, 8 ± 2 (means \pm SE). *Bottom*: representative photomicrographs of 5- μ m paraffin-embedded sections of biopsies from each treatment group, stained with hematoxylin and eosin. Arrows indicate damaged tubules.



clinical studies have shown that, after RIPC before surgery, acute injury to organs (either heart, liver, brain, or kidney) was significantly reduced (3, 12, 14, 30), but negative results have also been reported (17, 29). With this background of contrasting laboratory and clinical studies, we developed the current large-animal pre-clinical model of moderate AKI and tested the effectiveness of EPO or RIPC pretreatment using a factorial design. With regard to both of these interventions, and the AKI field in general, the dataset is overwhelmingly derived from rodent models. Translation to clinical medicine has proved disappointing (20), a

phenomenon also observed in the field of inflammatory research (21). In contrast, the pig is an excellent animal model for renal research. It has similar relative organ mass, kidney anatomy and physiology, and is large enough to allow serial sampling of biofluids and organs. Acquisition of these data is not ethically possible in humans and practically very difficult in rodents. This is important, as organ biopsy remains the gold standard for diagnosis of renal injury, and our study in the pig allows for an interpretation of plasma and urinary biomarkers in the context of time-resolved histopathology.

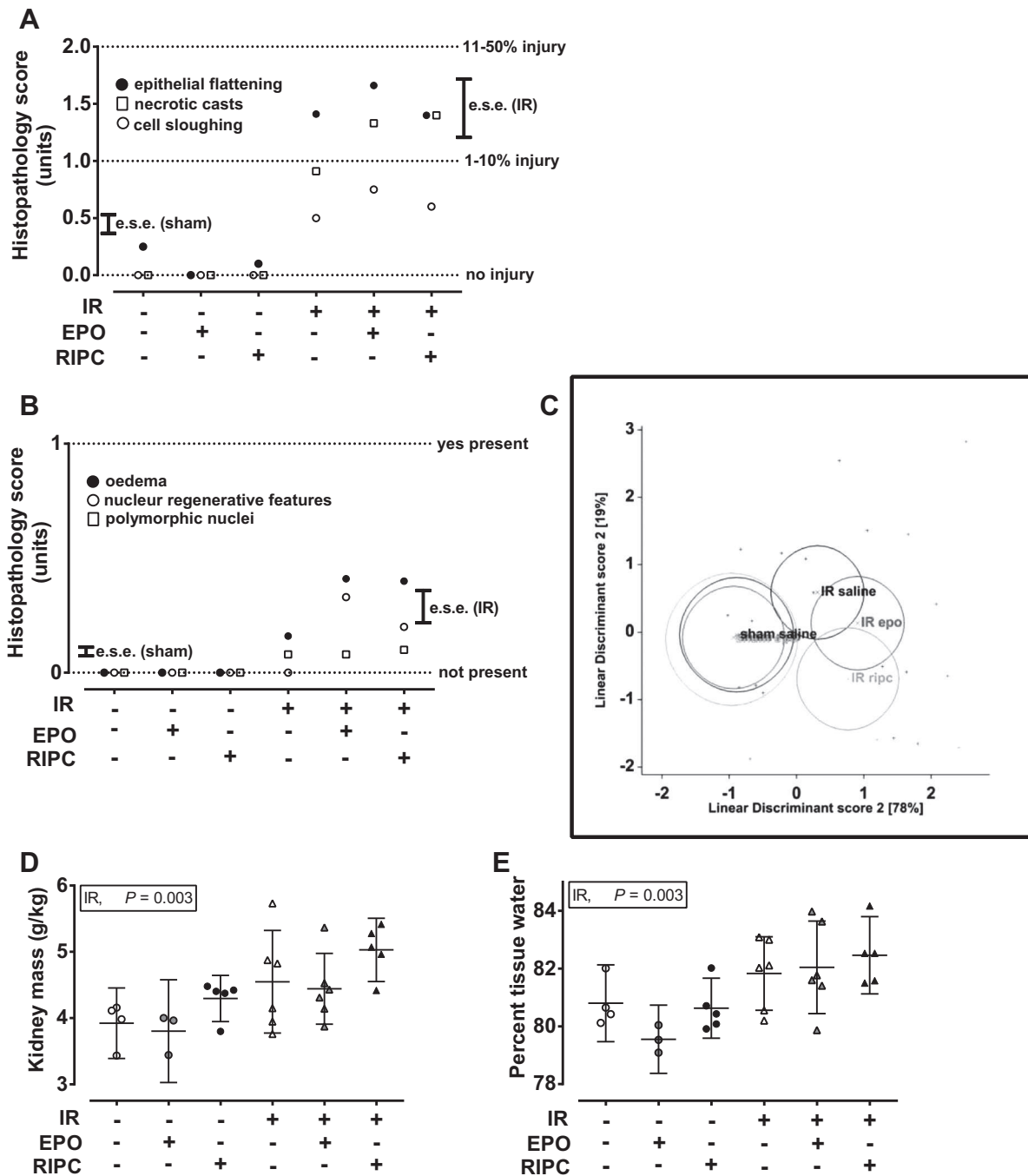


Fig. 3. Forty-minute ischemia with 48-h reperfusion induce significant renal histopathological injury. *A*: 2 pathologists, independently and blinded to the provenance of sections, scored on a discrete scale (0, no injury; 1, 1–10%; 2, 11–50%; 3, >50%) 4 histopathological parameters: epithelial flattening, necrotic casts, cell sloughing, and interstitial infiltrate and on a binomial scale (no = 0 or yes = 1) a further 3 histopathological parameters: the presence of edema, nuclear regenerative features, and/or polymorphic nuclei. Data are predicted mean scores [pooled SE for main effects (sham vs. IR) represented by e.s.e.] after ordinal regression analysis and adjustment for pathologist (there was no significant difference between pathologist for all scores). There was a significant main effect of IR on epithelial flattening [$\chi^2 = 34.1$ (1 df), $P < 0.001$], necrotic casts [$\chi^2 = 52.9$ (1 df), $P < 0.001$], cell sloughing [$\chi^2 = 51.1$ (1 df), $P < 0.001$] but no effect on interstitial infiltrate [$\chi^2 = 0.8$ (1 df), $P = 0.36$]. *B*: there was no evidence of edema, nuclear regenerative features, and polymorphs in sham controls (0/11 sections assessed), but each was increased with IR. *C*: combining all the assessed ordinal parameters (epithelial flattening, necrotic casts, cell sloughing, and interstitial infiltrate) into a multivariate discriminant analysis (accounting for 97% variation in score) indicated a significant effect of IR per se [$\chi^2 38.2$ (20 df), $P = 0.008$], as represented by the first dimension in the discriminant plot [means ($\pm 95\%$ C.I., i.e., confidence interval) represented by circles]. *D* and *E*: IR significantly increased relative kidney mass (per kg body wt), largely due to increased renal water retention or edema, confirming the histopathological assessment. Putative renoprotection by EPO or RIPC had no effect on histopathological injury. Data were analyzed as an IR (2 levels; yes/no) \times treatment (3 levels; saline/EPO/RIPC) factorial ANOVA with interaction (controls, $n = 11$: saline, $n = 4$; EPO, $n = 3$; RIPC, $n = 4$ vs IR, $n = 17$: IR-saline, $n = 6$; IR-EPO, $n = 6$; IR-RIPC, $n = 5$). Statistical significance was accepted at $P < 0.05$. Where appropriate for each group, horizontal lines are means with vertical lines, 95% C.I.

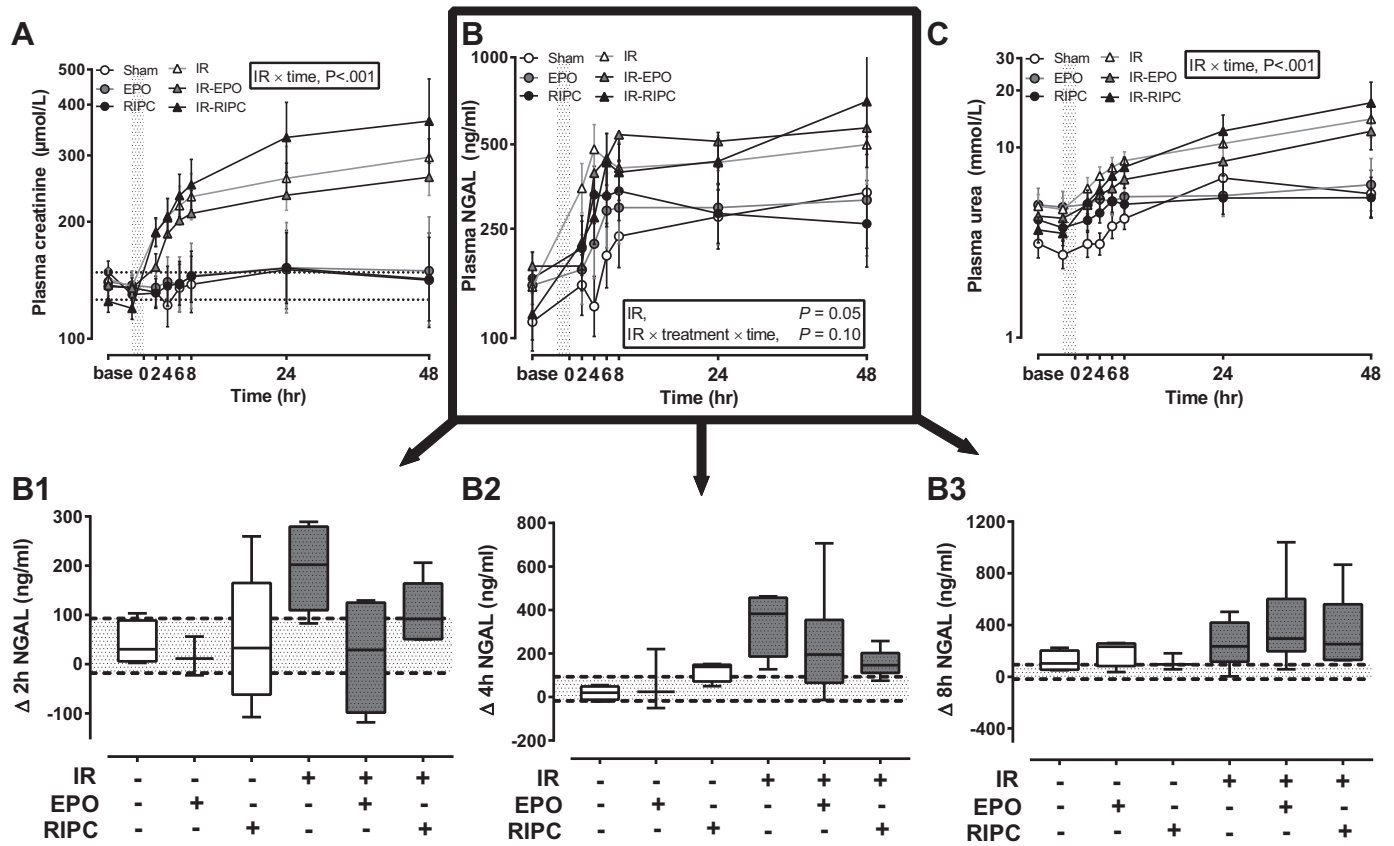


Fig. 4. Increment in plasma creatinine, urea, and neutrophil gelatinase-associated lipocalin (NGAL) mark significant renal injury, but for the first 2 h after IR plasma NGAL is blunted by EPO and RIPC. A–C: plasma was obtained from serial blood samples taken from all animals before IR (–30 min, “base” and –5 min, “0”) and subsequently at 2, 4, 6, 8, 24, and 48 h. Data were first log₁₀ transformed and analyzed as an IR (2 levels; yes/no) × treatment (3 levels; saline/EPO/RIPC) × time (7 levels, analyzed as a repeated measure) factorial ANOVA with interaction (controls, n = 11; saline, n = 4; EPO, n = 3; RIPC, n = 4 vs. IR, n = 17; IR-saline, n = 6; IR-EPO, n = 6; IR-RIPC, n = 5). Data are predicted mean logs ± SE from the model, presented on an antilog scale for clarity. B1–B3: boxplots are change (Δ) in plasma NGAL at 2, 4, or 8 h relative to baseline. Vertical shaded area represents the period of ischemia, and horizontal shaded area represents the baseline range (±95% C.I.) for plasma NGAL. Statistical significance was accepted at P < 0.05. Boxes are IQR (line at median), and whiskers are the 5–95% C.I. for group data.

A porcine model of AKI: prevention of histopathological damage by EPO or RIPC? We show that clamping both renal arteries of the pig for 40 min elicited moderate to severe histopathological injury by 24 h which lasted until at least 48-h reperfusion. It has been reported that a similar duration (average time, 37 min) of warm IR in humans undergoing partial nephrectomy for excision of a renal mass incurred little histopathological injury (16). However, injury was assessed at 5-min reperfusion in that study. Our new data in the pig would suggest that marked injury does develop after 40-min IR, and significant tubular damage is evident at 24 h. The predominant histopathological finding in our study was epithelial cell flattening with cell sloughing in proximal tubules together with the presence of necrotic casts in distal tubules. Edema and nuclear dedifferentiation were also notable responses. Renal edema was confirmed at post mortem by freeze drying kidney tissue. In this short-term study, neither EPO nor RIPC prevented any aspect of this intrarenal damage. While traditional biomarkers such as plasma creatinine marked injury throughout the study, alternative biomarkers such as ACR were resolving, being similar to baseline at 24 h despite significant histopathological injury at this time. This highlights the temporal discrepancies between biomarkers and tissue diagnosis and provides further

evidence of the importance of using more than one biomarker in clinical practice. Identification of an early decisive biomarker is important, and we show here for the first time that by using a combination of established (urinary ACR and plasma creatinine) and novel (plasma NGAL, IL-1β) biomarkers, a noninvasive prediction of AKI may be made as early as 2 h after reperfusion in this model.

Cellular response in the renal cortex to IRI in pigs. Renal IRI, at a cellular level, is characterized in vitro and in vivo (laboratory mammals) by apoptosis, necrosis, and immune cell infiltration (2, 22). This phenotype is virtually absent from control animals in the current study but prevalent (apoptosis) in the untreated (saline-infused) pig with AKI at 24 h, becoming significantly worse by 48-h reperfusion (Fig. 4). The mechanism of renoprotective action of EPO has been proposed to be antiapoptotic (15, 24). While we do not observe a treatment effect of EPO per se on the numbers of TUNEL⁺ cells, we do observe a distinctive distribution of apoptotic cells with IRI and after treatment with either EPO or RIPC, but not saline (see Figs. 6 and 7). They were clearly shed, together with other cell debris, into tubules and had coalesced in necrotic casts in distal tubules, rather than being spread throughout the tubular and interstitial cells of the renal cortex. This phenotype was

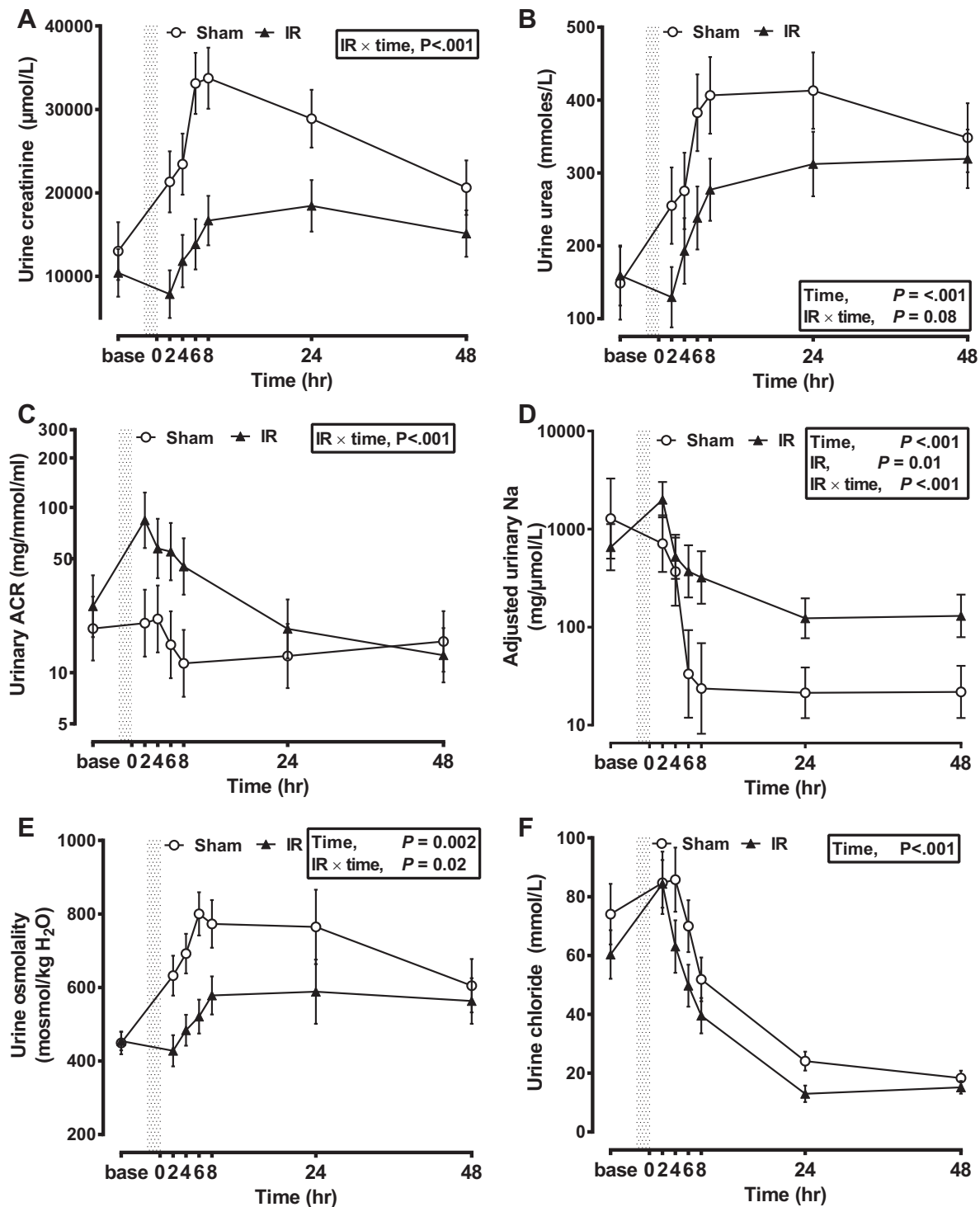


Fig. 5. Urine chemistry after IR-induced kidney injury. Urine was spot-sampled from a bladder catheter (Foley, 12F) before IR (-30 min, "base") and subsequently at 2, 4, 6, 8, 24, and 48 h after IR. Data [albumin-to-creatinine ratio (ACR), Na] were first \log_{10} transformed and analyzed as an IR (2 levels; yes/no) \times treatment (3 levels; saline/EPO/RIPC) \times time (7 levels, analyzed as a repeated measure) factorial ANOVA with interaction (controls, $n = 11$: saline, $n = 4$; EPO, $n = 3$; RIPC, $n = 4$ vs. IR, $n = 17$: IR-saline, $n = 6$; IR-EPO, $n = 6$; IR-RIPC, $n = 5$). Data are predicted means \pm SE from the model, presented on a linear or an antilog (ACR, Na) scale for clarity. In pigs with IR-induced kidney injury, urinary osmolality (E) and output of creatinine (A), urea (B), and Na (D) were significantly reduced for 24–48 h. Urinary loss of chloride reduced significantly after IR and was similar between all groups (F). The urinary ACR significantly increased after IR, peaking at 2 h and returning to near baseline by 24 h (C). Vertical shaded area represents the period of ischemia. Statistical significance was accepted at $P < 0.05$. There was no significant effect of renoprotective treatment on all measures of urine biochemistry after IR, hence only the main effect of sham vs. IR is presented.

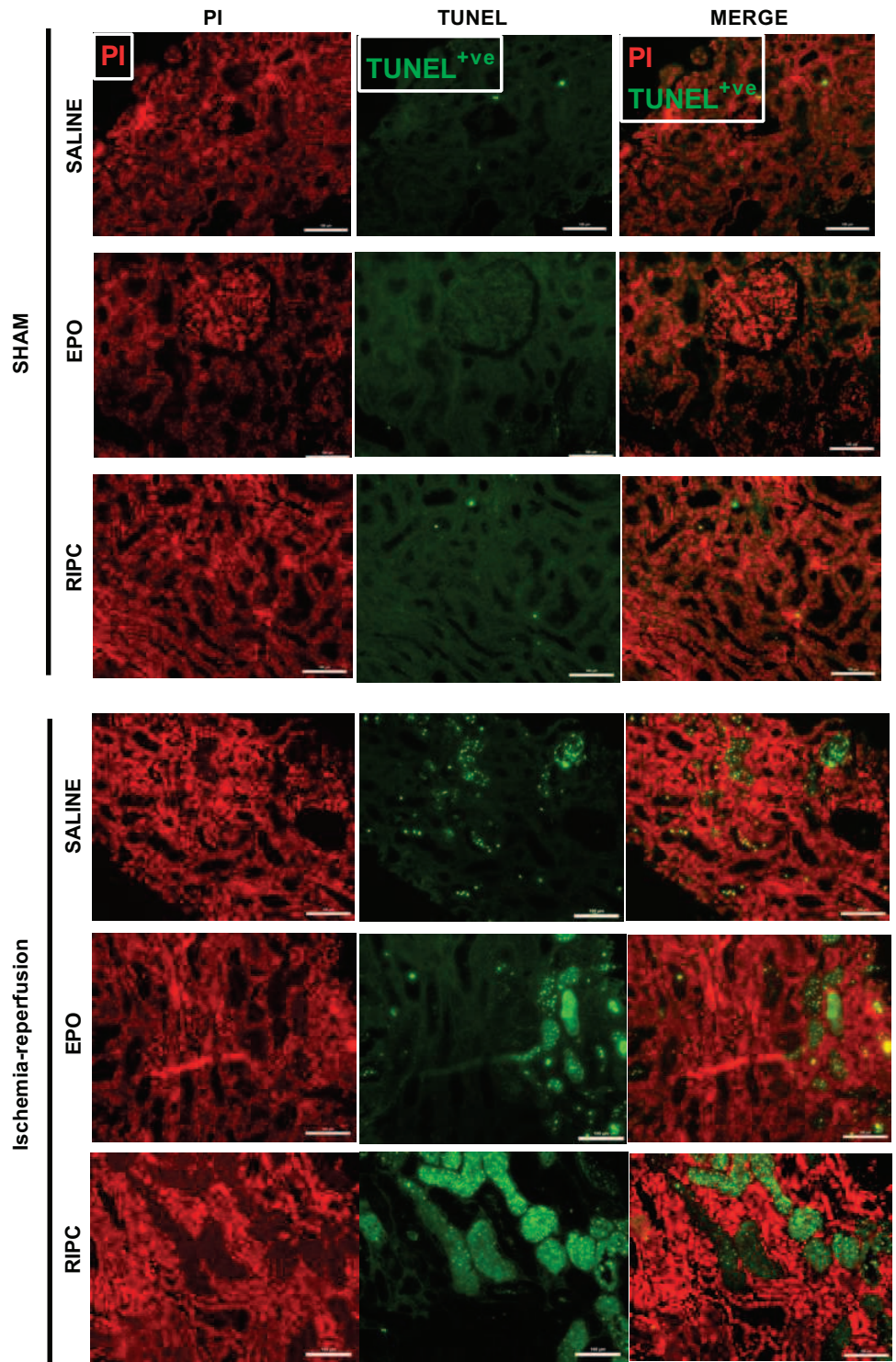


Fig. 6. Pretreatment with EPO or RIPC promotes shedding of terminal deoxynucleotidyl transferase(TdT)-mediated dUTP nick-end labeling (TUNEL)⁺ve apoptotic cells into tubules at 24-h post-IR. Data are representative microphotographs of renal biopsy tissue (right kidney; *n* = 3–5/group) sampled at 24-h reperfusion and taken from paraffin-embedded sections. Fluorescently labeled apoptotic nuclei (TUNEL cell-death detection kit, Roche) were visualized using an FITC filter on a Nikon Eclipse 80i microscope with a DS-Qi1Mc digital camera and contrasted against propidium iodide (PI) cells as a general nuclear marker. Immunohistofluorescent sections were visualized using EPO and RIPC.

observed in post mortem tissue at 48 h but also, importantly, in the renal biopsy at 24 h. This suggested to us that the mechanism of renoprotection offered by EPO or RIPC may involve the cell cycle. Rather than cells becoming stalled at the second checkpoint (G2-M) and progressing to fibrosis (28), EPO and RIPC were stimulating a prosurvival response that included a greater capacity of renal tubular cells to shed apoptotic and necrotic debris. Using immunofluorescence, we observed an increased propensity toward cell dedifferentiation and prolifer-

ation (marked by an increased number of PCNA⁺ve cells and validating the histopathological assessment) together with an increased number of cells stalled at G2-M after IRI in all groups. This effect became progressively greater from the subcapsular to corticomedullary region in the renal cortex. However, a consideration of the regional distribution of p-H3⁺ve cells in the group pretreated with EPO indicated successful rescue of cells from cell cycle stalling in the subcapsular (outer cortex) but not in deeper cortical regions (e.g.,

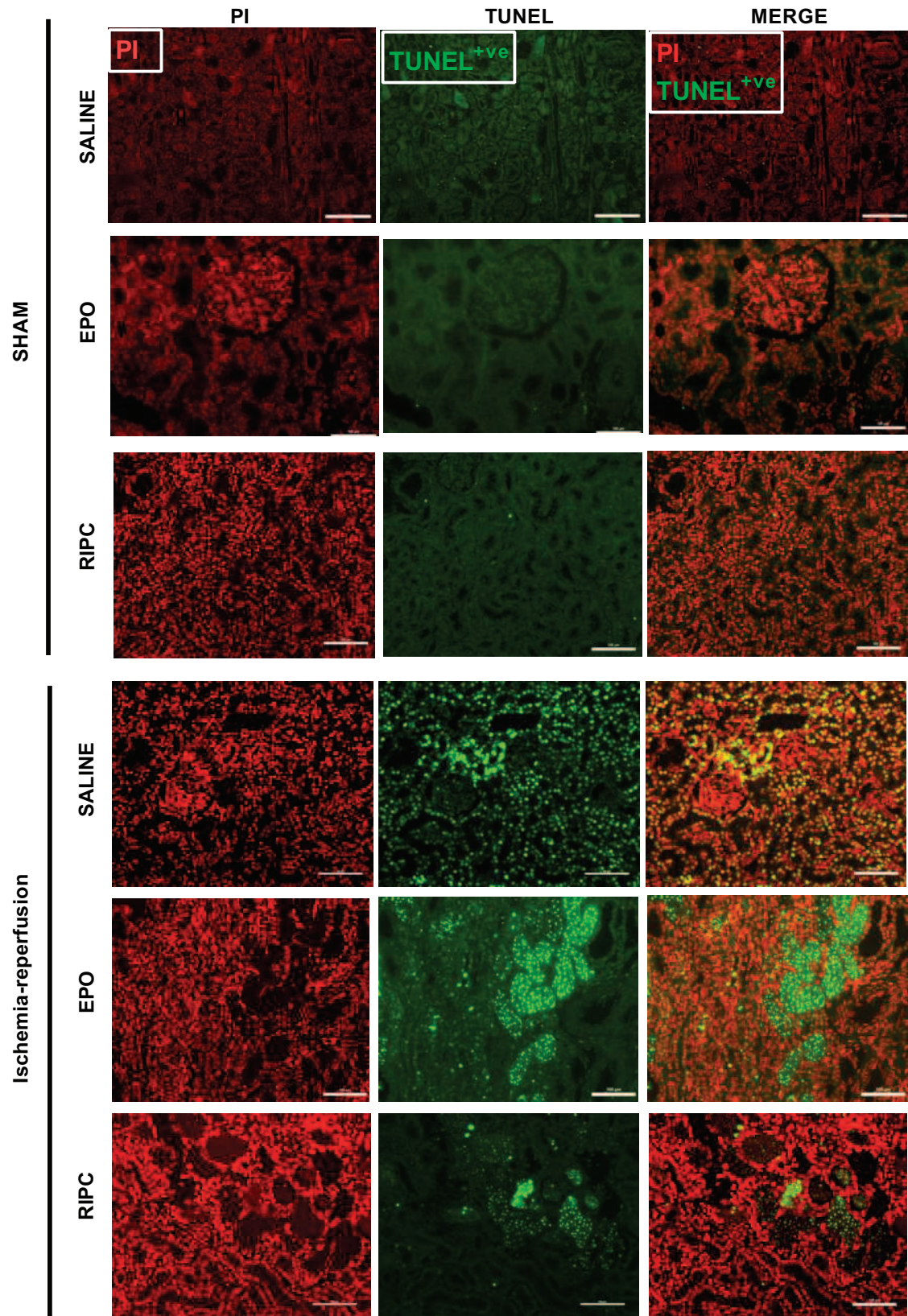
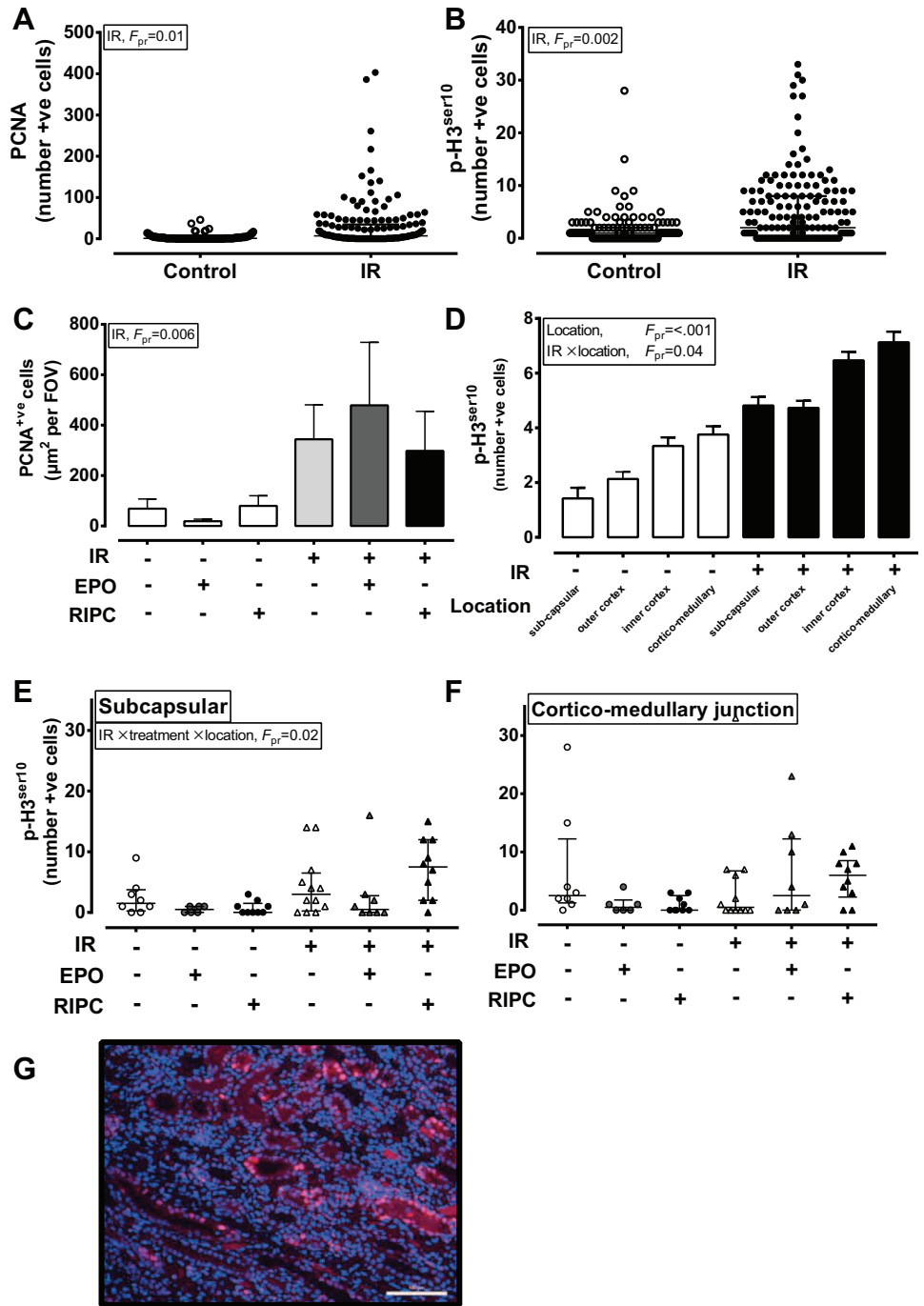


Fig. 7. Pretreatment with EPO or RIPC promotes shedding of TUNEL⁺ apoptotic cells into tubules at 48-h post-IR. Data are representative microphotographs of single kidney sections ($n = 3-5/\text{group}$) from paraffin-embedded tissue recovered at post mortem (48-h reperfusion). Fluorescently labeled apoptotic nuclei (TUNEL cell-death detection kit, Roche) were visualized using a FITC filter on a Nikon Eclipse 80i microscope with a DS-Qi1Mc digital camera and contrasted against propidium iodide (PI) cells as a general nuclear marker. Immunohistofluorescent sections were visualized using EPO and RIPC.

Fig. 8. Renal IRI increases the number of PCNA⁺ and p-H3^{ser10} cells, indicating an increase in proliferative activity at G1-S and G2-M, respectively, but EPO reduces the number of subcapsular cells in G2-M arrest. Data are from immunofluorescent analysis of single kidney sections per animal (*n* = 3–5/group) from paraffin-embedded tissue recovered at post mortem (48-h reperfusion). Sections were prepared for immunofluorescence by heat-mediated antigen retrieval and labeling with a porcine-specific primary antibody to proliferating cell nuclear antigen (PCNA) for proliferative cells and to phospho-histone 3 (p-H3^{ser10}) for nonproliferative cells stalled in G2-M. Sections were counterstained with DAPI. Specificity of the antibodies was confirmed by using appropriate negative controls (omitting the primary and using an IgG isotype). Positive cells were visualized using an FITC filter on a Nikon Eclipse 80i microscope with a DS-Qi1Mc digital camera. Data were first log₁₀ transformed and analyzed as IR (2 levels; yes/no) × treatment (3 levels; saline/EPO/RIPC) × location (5 levels representing separate fields-of-view from the subcapsular area to inner corticomedullary junction). Quantitative data (controls, *n* = 11; saline, *n* = 4; EPO, *n* = 3; RIPC, *n* = 4 vs. IR, *n* = 18; IR-saline, *n* = 6; IR-EPO, *n* = 6; IR-RIPC, *n* = 5) were analyzed using a generalized linear mixed model with the individual included as a random effect and errors fitted with a Poisson distribution. Data are observed counts of positive nuclei (A, C–F) or predicted means ± SE. from the model (B). In pigs with IR-induced kidney injury, the numbers of proliferative cells were increased (A and B) as were the numbers of cells stalled in G2-M (C and D); however, EPO pretreatment reduced the number of G2-M cells in the outer cortex. G: representative microphotograph of PCNA⁺ staining. Statistical significance was accepted at *P* < 0.05.



corticomedullary junction). The IL-1 family of cytokines, in particular, IL-1β, TGF-β, and IL-18, are proinflammatory upon activation and have been suggested to contribute to, and mark, renal IR-injury (2). Uromodulin/Tamm-Horsfall protein is produced from the thick ascending limb of the loop of Henle with renal damage that exposes the interstitium (as observed here) and exacerbates renal IL-1β production (6). In our large-animal model, we show for the first time that EPO, but not RIPC, blunted the IR-induced increase in plasma IL-1β. At 8-, 24-, and 48-h reperfusion, values for IL-1β in the IR-EPO group were at or near control levels, in contrast to in the IR and IR-RIPC groups which remained high. Thus pretreatment with

EPO, but not RIPC, appears to blunt some aspects of the early sterile inflammatory response that characterizes acute kidney injury and rescues outer cortical cells from becoming arrested in the cell cycle. However, serial jugular blood sampling is only able to show temporal changes to cytokines as reflected in organ spillover into the general circulation. This is likely a crude estimation of the postischemic, intraorgan inflammatory response in which waves of inflammatory activity engender different roles within the organ in a time-dependent fashion (2). The current data, limited to renal tissue samples at 24 and 48 h, are unlikely to suitably capture this response. Indeed, in our model at 48-h reperfusion, we observed no evidence

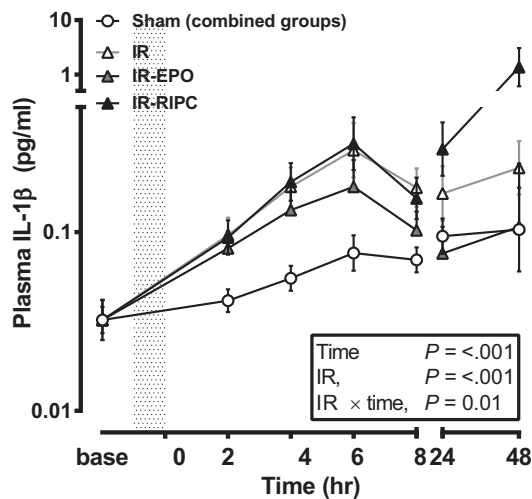


Fig. 9. Renal IR leads to significantly increased plasma IL-1 β that is blunted at 24 h after pretreatment with EPO. Plasma was obtained from serial blood samples taken from all animals before IR (-30 min, "base") and subsequently at 2, 4, 6, 8, 24, and 48 h. Data were first log₁₀ transformed and analyzed as an IR (2 levels; yes/no) \times treatment (3 levels; saline/EPO/RIPC) \times time (7 levels, analyzed as a repeated measure) factorial ANOVA with interaction (controls, $n = 11$; saline, $n = 4$; EPO, $n = 3$; RIPC, $n = 4$ vs. IR, $n = 17$; IR-saline, $n = 6$; IR-EPO, $n = 6$; IR-RIPC, $n = 5$). Data are predicted mean logs \pm SE from the model, presented on an antilog scale. Sham-control groups (saline/EPO/RIPC) were not different from each other and are presented combined for clarity. Vertical shaded area represents the period of ischemia. Statistical significance was accepted at $P < 0.05$.

for greater immune cell infiltration after IRI (analysis of kidney lysate cytokines, quantification of cells expressing MHC-II, abundance of tissue macrophages). Nevertheless, blunting of IL-1 β by EPO after IR is of interest and may

mitigate progression of AKI to chronic kidney disease in this group (2, 28).

In summary, we asked whether EPO or RIPC delivered preoperatively could protect against AKI. Clinical studies have shown efficacy for each intervention, to some extent, but the data are ambiguous and the mechanisms remain elusive. We optimized and characterized a preclinical animal model allowing us to investigate potential mechanisms through serial sampling of biofluids and renal histology, together with characterization of renal tissue responses. First, using this model, we identify the dissociation between renal physiology, as assessed through serial sampling of biofluids, and histopathology. For example, moderate to severe kidney injury was histologically evident at 24-h reperfusion despite resolving blood and urine chemistry. This could be an important consideration for the clinician interpreting noninvasive biomarkers. Our data suggest that a 2-h measurement of plasma creatinine, NGAL, IL-1 β , and urinary ACR would provide the earliest biomarker panel for predicting AKI. Furthermore, we have demonstrated EPO- and, to a lesser extent, RIPC-associated cellular effects, which could be potentially renoprotective. These data suggest that there is merit in investigating the putative renoprotective effect of EPO, and possibly RIPC, further. Despite equivocal outcomes in clinical studies investigating EPO as a renoprotective agent in AKI, optimal clinical dosing and administration of EPO have not been established and our data suggest that further clinical studies are justified.

ACKNOWLEDGMENTS

The authors are grateful for the help and support provided by the Bio Support Unit on the Sutton Bonington Campus to Jim Craigon for statistical advice on the manuscript and to Kate White MRCVS for advice with regard to the surgical plan for the studies.

Table 1. Kidney tissue cytokines in pigs exposed to control (sham surgery) or ischemia-reperfusion (IR) with 48-h reperfusion

Cytokine, pg·ml ⁻¹ ·mg protein ⁻¹	Group	Treatment			SED	P Value		
		saline	EPO	RIPC		G	Tr	G \times Tr
IFN- γ	Sham	0.41	2.55	2.56	2.04	0.13	0.54	0.45
	IR	2.16	0.45	2.66				
IL-1 α	Sham	0.012	0.012	0.011	0.002	0.83	0.93	0.93
	IR	0.012	0.012	0.012				
IL-1 β	Sham	0.063	0.062	0.054	0.036	0.20	0.75	0.79
	IR	0.067	0.095	0.100				
IL-2	Sham	0.221	0.259	0.192	0.066	0.40	0.57	0.28
	IR	0.227	0.132	0.204				
IL-4	Sham	0.412	0.461	0.366	0.150	0.74	0.59	0.46
	IR	0.461	0.267	0.409				
IL-6	Sham	0.004	0.007	0.005	0.003	0.18	0.67	0.83
	IR	0.007	0.008	0.009				
IL-8	Sham	0.069	0.075	0.057	0.016	0.44	0.99	0.37
	IR	0.055	0.053	0.066				
IL-10	Sham	0.022	0.026	0.023	0.006	0.30	0.67	0.46
	IR	0.023	0.015	0.021				
IL-12	Sham	0.014	0.015	0.014	0.003	0.40	0.63	0.49
	IR	0.013	0.010	0.015				
IL-18	Sham	0.816	0.830	0.876	0.226	0.64	0.28	0.54
	IR	0.972	0.692	1.077				
TNF- α	Sham	0.002	0.003	0.003	0.001	0.81	0.54	0.54
	IR	0.003	0.001	0.003				

Cytokines were analyzed (pg/ml) in kidney tissue lysates (RIPA buffer) by Luminex array (Millipore). Data are predicted means with standard error of the differences between means (SED.) used to represent the residual error. There were $n = 3$ –6 pigs/treatment group (29 pigs in total) analyzed in a 2 (sham, IR) \times 3 (saline, erythropoietin; EPO, remote ischemic preconditioning; RIPC) factorial design by ANOVA (Genstat v14). G, group; Tr, treatment; df, degrees of freedom. Protein (mg/ml) was determined in lysates by the Bradford method. Statistical significance was accepted at $P < 0.05$, with 95% confidence interval (CI) as ± 2.07 (df_{6,23}) \times SED.

GRANTS

This study was funded by the Faculty of Medicine, Schools of Veterinary Medicine and Science and Clinical Sciences, University of Nottingham, and Nottingham University Hospitals NHS Trust Charities, Renal and Transplant Unit, City Hospital, Nottingham.

DISCLOSURES

No conflicts of interest, financial or otherwise, are declared by the authors.

AUTHOR CONTRIBUTIONS

Author contributions: D.S.G., T.A.M., Z.H., and M.A.D. provided conception and design of research; D.S.G., S.J.W., L.J.D., T.A.M., Z.H., P.S., and S.O. performed experiments; D.S.G. analyzed data; D.S.G., S.J.W., and M.A.D. interpreted results of experiments; D.S.G. prepared figures; D.S.G. drafted manuscript; D.S.G., S.J.W., and M.A.D. edited and revised manuscript; D.S.G. and M.A.D. approved final version of manuscript.

REFERENCES

1. Abu-Amara M, Yang SY, Quaglia A, Rowley P, Fuller B, Seifalian A, Davidson B. Role of endothelial nitric oxide synthase in remote ischemic preconditioning of the mouse liver. *Liver Transpl* 17: 610–619, 2011.
2. Bonventre JV, Yang L. Cellular pathophysiology of ischemic acute kidney injury. *J Clin Invest* 121: 4210–4221, 2011.
3. Botker HE, Kharbanda R, Schmidt MR, Bottcher M, Kaltoft AK, Terkelsen CJ, Munk K, Andersen NH, Hansen TM, Trautner S, Lassen JF, Christiansen EH, Krusell LR, Kristensen SD, Thuesen L, Nielsen SS, Rehling M, Sorensen HT, Redington AN, Nielsen TT. Remote ischaemic conditioning before hospital admission, as a complement to angioplasty, and effect on myocardial salvage in patients with acute myocardial infarction: a randomised trial. *Lancet* 375: 727–734, 2010.
4. Byrne CJ, McCafferty K, Kieswich J, Harwood S, Andrikopoulos P, Raftery M, Thiemermann C, Yaqoob MM. Ischemic conditioning protects the uremic heart in a rodent model of myocardial infarction. *Circulation* 125: 1256–1265, 2012.
5. Cassis P, Gallon L, Benigni A, Mister M, Pezzotta A, Solini S, Gagliardini E, Cugini D, Abbate M, Aiello S, Rocchetta F, Scudeletti P, Perico N, Noris M, Remuzzi G. Erythropoietin, but not the correction of anemia alone, protects from chronic kidney allograft injury. *Kidney Int* 81: 903–918, 2012.
6. Darisipudi MN, Thomasova D, Mulay SR, Brech D, Noessner E, Liapis H, Anders HJ. Uromodulin triggers IL-1beta-dependent innate immunity via the NLRP3 inflammasome. *J Am Soc Nephrol* 23: 1783–1789, 2012.
7. de Seigneux S, Ponte B, Weiss L, Pugin J, Romand JA, Martin PY, Saudan P. Epoetin administered after cardiac surgery: effects on renal function and inflammation in a randomized controlled study. *BMC Nephrol* 13: 132, 2012.
8. de Souza AC, Volpini RA, Shimizu MH, Sanches TR, Camara NO, Semedo P, Rodrigues CE, Seguro AC, Andrade LC. Erythropoietin prevents sepsis-related acute kidney injury in rats by inhibiting nuclear factor- κ B and upregulating endothelial nitric oxide synthase. *Am J Physiol Renal Physiol* 302: F1045–F1054, 2012.
9. Hafer C, Becker T, Kielstein JT, Bahlmann E, Schwarz A, Grinzoff N, Drzymala D, Bonnard I, Richter N, Lehner F, Klempnauer J, Haller H, Traeder J, Fliser D. High-dose erythropoietin has no effect on short- or long-term graft function following deceased donor kidney transplantation. *Kidney Int* 81: 314–320, 2012.
10. Hausenloy D, Candilio L, Laing C, Kunst G, Pepper J, Kolvekar S, Evans R, Robertson S, Knight R, Ariti C, Clayton T, Yellon D, Investigators TET. Effect of remote ischemic preconditioning on clinical outcomes in patients undergoing coronary artery bypass graft surgery (ERICCA): rationale and study design of a multi-centre randomized double-blinded controlled clinical trial. *Clin Res Cardiol* 101: 339–348, 2012.
11. Heusch G, Musiolik J, Kottenberg E, Peters J, Jakob H, Thielmann M. STAT5 activation and cardioprotection by remote ischemic preconditioning in humans/novelty and significance. *Circ Res* 110: 111–115, 2012.
12. Jensen HA, Loukogeorgakis S, Yannopoulos F, Rimpilainen E, Petzold A, Tuominen H, Lepola P, Macallister RJ, Deanfield JE, Makela T, Alestalo K, Kiviluoma K, Anttila V, Tsang V, Juvonen T. Remote ischemic preconditioning protects the brain against injury after hypothermic circulatory arrest. *Circulation* 123: 714–721, 2011.
13. Koyner JL, Garg AX, Coca SG, Sint K, Thiessen-Philbrook H, Patel UD, Shlipak MG, Parikh CR, Consortium fT-A. Biomarkers predict progression of acute kidney injury after cardiac surgery. *J Am Soc Nephrol* 23: 905–914, 2012.
14. Loukogeorgakis SP, Williams R, Panagiotidou AT, Kolvekar SK, Donald A, Cole TJ, Yellon DM, Deanfield JE, MacAllister RJ. Transient limb ischemia induces remote preconditioning and remote postconditioning in humans by a K_{ATP} -channel dependent mechanism. *Circulation* 116: 1386–1395, 2007.
15. Moore E, Bellomo R. Erythropoietin (EPO) in acute kidney injury. *Ann Intensive Care* 1: 3, 2011.
16. Parekh DJ, Weinberg JM, Ercole B, Torkko KC, Hilton W, Bennett M, Devarajan P, Venkatachalam MA. Tolerance of the human kidney to isolated controlled ischemia. *J Am Soc Nephrol* 24: 506–517, 2013.
17. Rahman IA, Mascaro JG, Steeds RP, Frenneaux MP, Nightingale P, Gosling P, Townsend P, Townend JN, Green D, Bonser RS. Remote ischemic preconditioning in human coronary artery bypass surgery: from promise to disappointment? *Circulation* 122: S53–S59, 2010.
18. Rjiba-Touati K, Boussema IA, Belarbia A, Achour A, Bacha H. Protective effect of recombinant human erythropoietin against cisplatin-induced oxidative stress and nephrotoxicity in rat kidney. *Int J Toxicol* 30: 510–517, 2011.
19. Rosen S, Heyman SN. Difficulties in understanding human ‘acute tubular necrosis’: limited data and flawed animal models. *Kidney Int* 60: 1220–1224, 2001.
20. Seok J, Warren HS, Cuenca AG, Mindrinos MN, Baker HV, Xu W, Richards DR, McDonald-Smith GP, Gao H, Hennessy L, Finnerty CC, López CM, Honari S, Moore EE, Minei JP, Cuschieri J, Bankey PE, Johnson JL, Sperry J, Nathens AB, Billiar TR, West MA, Jeschke MG, Klein MB, Gamelli RL, Gibran NS, Brownstein BH, Miller-Graziano C, Calvano SE, Mason PH, Cobb JP, Rahme LG, Lowry SF, Maier RV, Moldawer LL, Herndon DN, Davis RW, Xiao W, Tompkins RG, Inflammation and Host Response to Injury, Large Scale Collaborative Research Program. Genomic responses in mouse models poorly mimic human inflammatory diseases. *Proc Natl Acad Sci USA* 110: 3507–3512, 2013.
21. Sharfuddin AA, Molitoris BA. Pathophysiology of ischemic acute kidney injury. *Nat Rev Nephrol* 7: 189–200, 2011.
22. Sharples EJ, Patel N, Brown P, Stewart K, Mota-Philippe H, Sheaff M, Kieswich J, Allen D, Harwood S, Raftery M, Thiemermann C, Yaqoob MM. Erythropoietin protects the kidney against the injury and dysfunction caused by ischemia-reperfusion. *J Am Soc Nephrol* 15: 2115–2124, 2004.
23. Siren AL, Fratelli M, Brines M, Goemans C, Casagrande S, Lewczuk P, Keenan S, Gleiter C, Pasquali C, Capobianco A, Mennini T, Heumann R, Cerami A, Ehrenreich H, Ghezzi P. Erythropoietin prevents neuronal apoptosis after cerebral ischemia and metabolic stress. *Proc Natl Acad Sci USA* 98: 4044–4049, 2001.
24. Solling C, Christensen AT, Krag S, Frokiaer J, Wogensen L, Krog J, Tonnesen EK. Erythropoietin administration is associated with short-term improvement in glomerular filtration rate after ischemia-reperfusion injury. *Acta Anaesthesiol Scand* 55: 185–195, 2011.
25. Song YR, Lee T, You SJ, Chin HJ, Chae DW, Lim C, Park KH, Han S, Kim JH, Na KY. Prevention of acute kidney injury by erythropoietin in patients undergoing coronary artery bypass grafting: a pilot study. *Am J Nephrol* 30: 253–260, 2009.
26. Vesey DA, Cheung C, Pat B, Endre Z, Gobe G, Johnson DW. Erythropoietin protects against ischaemic acute renal injury. *Nephrol Dial Transplant* 19: 348–355, 2004.
27. Yang L, Besschetnova TY, Brooks CR, Shah JV, Bonventre JV. Epithelial cell cycle arrest in G2/M mediates kidney fibrosis after injury. *Nat Med* 16: 535–543, 2010.
28. Young PJ, Dalley P, Garden A, Horrocks C, La Flamme A, Mahon B, Miller J, Pilcher J, Weatherall M, Williams J, Young W, Beasley R. A pilot study investigating the effects of remote ischemic preconditioning in high-risk cardiac surgery using a randomised controlled double-blind protocol. *Basic Res Cardiol* 107: 1–10, 2012.
29. Zimmerman RF, Ezeanuna PU, Kane JC, Cleland CD, Kempananjappa TJ, Lucas FL, Kramer RS. Ischemic preconditioning at a remote site prevents acute kidney injury in patients following cardiac surgery. *Kidney Int* 80: 861–867, 2011.