

Ashraf, Sadaf (2011) Contributions of inflammation and angiogenesis to structural damage and pain in osteoarthritis. PhD thesis, University of Nottingham.

Access from the University of Nottingham repository:

http://eprints.nottingham.ac.uk/11979/1/PDF_of_final_thesis_submitted.pdf

Copyright and reuse:

The Nottingham ePrints service makes this work by researchers of the University of Nottingham available open access under the following conditions.

- Copyright and all moral rights to the version of the paper presented here belong to the individual author(s) and/or other copyright owners.
- To the extent reasonable and practicable the material made available in Nottingham ePrints has been checked for eligibility before being made available.
- Copies of full items can be used for personal research or study, educational, or not-for-profit purposes without prior permission or charge provided that the authors, title and full bibliographic details are credited, a hyperlink and/or URL is given for the original metadata page and the content is not changed in any way.
- Quotations or similar reproductions must be sufficiently acknowledged.

Please see our full end user licence at:

http://eprints.nottingham.ac.uk/end_user_agreement.pdf

A note on versions:

The version presented here may differ from the published version or from the version of record. If you wish to cite this item you are advised to consult the publisher's version. Please see the repository url above for details on accessing the published version and note that access may require a subscription.

For more information, please contact eprints@nottingham.ac.uk



The University of
Nottingham

UNITED KINGDOM • CHINA • MALAYSIA

**Contributions of Inflammation and Angiogenesis
to Structural Damage and Pain in Osteoarthritis**

Sadaf Ashraf

Arthritis Research UK Pain Centre

Department of Academic Rheumatology

School of Clinical Sciences, Clinical Sciences Building

City Hospital, Nottingham, NG5 1PB

**Thesis submitted to the University of Nottingham for
the degree of Doctor of Philosophy**

July 2011

ABSTRACT

Background: Osteoarthritis (OA), one of the commonest joint diseases of unknown aetiology is a major source of pain and disability in the ageing population. Current therapeutic agents for OA focus on symptomatic relief. Patients often present to clinics with long established disease when the boundaries between ageing and pathology are indistinct. A greater understanding of early OA is thus required and may help achieve the goal of disease modification. OA is associated with chondropathy, synovitis, subchondral bone remodelling and osteophyte formation. Angiogenesis, the growth of new blood vessels from pre-existing ones may contribute to each of these features. Inflammation is increasingly recognised as an important feature of OA. Synovitis is detectable within the osteoarthritic joint both radiologically and histologically, evidenced by symptoms such as stiffness or pain, signs such as effusion and use of anti-inflammatory drugs for treatment of OA. Pain is the predominant symptom of OA, but little is known about the mechanism by which this pain arises.

Objectives: This thesis describes studies examining the contributions of angiogenesis to inflammation, structural damage and pain in OA.

Hypothesis: Inflammation and angiogenesis are co-dependent processes that can exacerbate and mediate structural damage and pain in OA.

Methods: In-vivo, in animal models and ex-vivo in human meniscal tissue, using immunohistochemistry, joint histology and pain behaviour testing, the effects of enhancing synovitis on angiogenesis, structural damage and pain in OA, and whether inhibiting either synovitis or angiogenesis could reduce this structural damage and pain were investigated.

Results: It is shown for the first time that blood vessel growth at the onset of resolving synovitis leads to its subsequent persistence. Exacerbating synovitis in the rat meniscal transection (MNX) model of OA enhanced synovial angiogenesis, total joint damage and pain behaviour. Following treatment with the anti-angiogenic compound, PPI-2458 [(1R)-1-carbamoyl-2-methyl]-carbamic acid-(3R, 3S, 5S, 6R)-5-methoxy-4-[(2R, 3R)-2-methyl-3-(3-methyl-but-2-enyl) oxiranyl]-1-oxaspiro (2*5) oct-6-yl ester], synovial angiogenesis, vascularisation of channels penetrating into the articular cartilage (osteocondral angiogenesis), synovitis, joint damage (mainly attenuation of osteophyte growth) and pain behaviour were all reduced. Anti-inflammatory drugs (dexamethasone and indomethacin) reduced synovitis, synovial angiogenesis and pain behaviour in the rat MNX model of OA. Treatment with dexamethasone reduced joint damage score by decreasing cartilage damage. Indomethacin however did not affect joint structure. Human meniscal tissue from knees with high chondropathy displayed increased degeneration of collagen bundles, increased vascular densities both in the synovium and at the fibrocartilage junction with a greater density of perivascular sensory nerve profiles in the outer region. Increased penetration of the synovial tissue towards the tip of the meniscus was noted in menisci from high chondropathy group compared to those from the low chondropathy group.

Conclusion: Data from animal studies indicates that conversion of acute inflammation to chronic inflammation may be due to the stimulation of angiogenesis. Furthermore, these data provide evidence that synovitis contributes to joint pathology and pain behaviour in the rat MNX model of OA and this may be partly due to the angiogenesis in the synovium and at the osteochondral junction. Data from human studies highlights that tibiofemoral chondropathy is associated with altered matrix structure, increased vascular penetration and increased sensory nerve densities in the medial meniscus. Angiogenesis and associated sensory nerves in the meniscus may therefore contribute to pain in knee OA.

Summary: These findings support the hypothesis that inflammation and angiogenesis are indeed co-dependent processes, exacerbating and mediating structural damage and pain in OA. Angiogenesis inhibition has the potential to reduce synovitis, joint damage and pain in OA.

ACKNOWLEDGEMENTS

I am heartily thankful to all those who have helped and inspired me during my doctoral study. It is a pleasure to thank my supervisors David A Walsh and Paul I Mapp for giving me the opportunity to do my PhD in the Department of Academic Rheumatology. This thesis would not have been possible without their guidance, helpful discussions and encouragement over the last three years both in the practical work and with the thesis write-up. I am particularly indebted to David as he was always available and willing to help me with my work. His perpetual energy and enthusiasm in research has motivated me and kept me going. David, you have been an inspiration to me! I owe a big thank you to Paul for getting me up to speed in the practical skills needed to complete this thesis and for being there to help out when required.

I would like to thank Dan for always making me smile with his unique sense of humour and for being patient with my never-ending and often daft, statistically-related questions! You have been great Dan! I would like to extend my thanks to Roger Hill, Deborah Wilson and the team at Kings Mill Hospital for the collection and preparation of human samples and for compiling the data for the repository database; to Ruth (AstraZeneca) for teaching the meniscal transection surgery (MNX model of OA); to Inma Rioja (GlaxoSmithKline) for providing the angiogenic compound PPI-2458; and all the staff at the BMSU (University of Nottingham) without which I could not have undertaken my research.

I am grateful to Rebecca, Maddie, Jeanne, Priyam and Helen for their friendship and support, without them my time within the department would not have been as enjoyable, so thank you guys for making my PhD years fun and memorable! Shaista, Asiya and Kirtiman, to each of you I owe a huge thank you for being there for me when I needed you guys and listening patiently to me when I was in my “PhD-moaning-mood”. I am truly blessed to have friends like you.

Lastly, but most importantly, I would like to thank my amazing family for all that they have done for me, not just for the last three years, but my entire life, this PhD would not have been possible without their love and support.

PUBLICATIONS

- Ashraf S, Mapp PI, Walsh DA. Contributions of angiogenesis to inflammation, joint damage and pain in a rat model of osteoarthritis. *Arthritis Rheum.* 2011; In Press.
- Ashraf S, Wibberly H, Mapp PI, Hill R, Wilson D, Walsh DA. Increased vascular penetration and nerve growth in the meniscus: a potential source of pain in osteoarthritis. *Ann Rheum Dis.* 2011; 70(3):523-9.
- Ashraf S, Mapp PI, Walsh DA. Angiogenesis and persistence of inflammation in a rat model of proliferative synovitis. *Arthritis Rheum.* 2010; 62(7):1890-8.
- Ashraf S, Walsh DA. Angiogenesis in osteoarthritis. *Curr Opin Rheumatol.* 2008; 20(5):573-80.

PRESENTATIONS

Poster:

- Ashraf S, Mapp PI, Walsh DA. Angiogenesis inhibition has the potential to reduce pain in the rat meniscal transection model of osteoarthritis. OARSI World Congress on Osteoarthritis, Brussels, Belgium, 2010. Abstract: Osteoarthritis and cartilage. Vol:18; Supplement 2.
- Ashraf S, Mapp PI, Walsh DA. Angiogenesis and persistence of inflammation in a rat model of proliferative synovitis. BSR & BHPR Rheumatology Annual Conference, Glasgow, Scotland, 2009. Abstract: Rheumatology. Vol:48; Supplement 1.
- Ashraf S, Mapp PI, Walsh DA. The effects of Fibroblast Growth Factor-2 on carrageenan-induced synovitis in the rat. Postgraduate research forum held by the University of Nottingham, 2008.

Oral:

- Ashraf S, Wibberly H, Mapp PI, Hill R, Wilson D, Walsh DA. Increased vascular penetration and nerve growth in the meniscus: a potential source of pain in osteoarthritis. OARSI World Congress on Osteoarthritis, Brussels, Belgium, 2010. Abstract: Osteoarthritis and Cartilage. Vol:18; Supplement 2.
- Ashraf S, Mapp PI, Walsh DA. Angiogenesis and persistence of inflammation in a rat model of proliferative synovitis. YSL Symposium-Networking Angiogenesis, University of Chester, 2009.

CONTENTS

Abstract	2
Acknowledgements	4
Publications	5
Presentations	6
Contents	7
List of Figures	12
List of Tables	14
Abbreviations	15
1 Introduction	18
1.1 The Synovial Joint	18
1.2 Innervation of the knee joint	22
1.3 Osteoarthritis	23
1.3.1 Aetiology	24
1.3.2 Signs, Symptoms and Characteristics	25
1.3.3 Pathophysiology	26
1.3.4 Diagnosis and Detection	29
1.3.5 Treatment	30
1.4 Pain and Osteoarthritis	32
1.4.1 Joint pathology contributing to pain in OA	33
1.4.2 Neuropeptides, Sensory Nerves and Inflammation	35
1.5 Angiogenesis and Osteoarthritis	37
1.5.1 Process of Angiogenesis	37
1.5.2 Factors regulating angiogenesis	39
1.5.3 Role of chondrocytes in angiogenesis	41
1.5.4 Involvement of angiogenesis in OA	42
1.5.5 Angiogenesis and Pain	43
1.5.6 PPI-2458, an inhibitor of angiogenesis	44
1.6 Inflammation and Osteoarthritis	47
1.6.1 Acute Inflammation	47
1.6.2 Chronic Inflammation	48
1.6.3 Inflammatory Process	48
1.6.4 Involvement of Inflammation in OA	50
1.6.5 Synovial Macrophages and Inflammation in OA	51
1.6.6 Anti-inflammatory Therapy	52
1.7 Inflammation, Angiogenesis, Structural damage and Pain in OA	53

1.8	Animal Models of Osteoarthritis	56
1.9	Summary	59
1.10	Hypothesis and Aims	60
2	Materials and Methods	61
2.1	Introduction	61
2.2	Animal Models	61
2.2.1	Anaesthesia	61
2.2.2	Euthanasia	62
2.2.3	Intra-articular injection into rat knee joints	62
2.2.4	Subcutaneous Injections	63
2.2.5	Oral Gavage	63
2.2.6	Meniscal Transection (MNX) Model of Osteoarthritis	63
2.3	Behavioural Testing	66
2.3.1	Pain Testing	66
2.3.2	Weights	67
2.4	Joint Swelling	67
2.5	Tissue Collection and Processing	68
2.5.1	Harvesting and Mounting Rat Synovia	68
2.5.2	Harvesting and Mounting Rat Tibiofemoral Joints	68
2.5.3	Human Menisci	70
2.5.4	Systemic Transcardiac Perfusion of Rat Tibiofemoral Joints	70
2.5.5	Blood Glucose Testing	71
2.6	Immunohistochemistry	71
2.6.1	Introduction	71
2.6.2	Principles Involved	71
2.6.3	Staining Procedures	73
2.7	Histological Stains	76
2.7.1	Haematoxylin and Eosin	76
2.7.2	Safranin-O and fast green	76
2.8	Image Analysis and Quantification	77
2.8.1	Synovia	77
2.8.2	Cartilage and Subchondral Bone	78
2.8.3	Human Menisci	79
2.9	Patient and Sample Selection for Human Menisci Study	81
2.9.1	Macroscopic Chondropathy Score of Tibiofemoral Joint	81
2.10	Statistical Analysis	86
2.11	Reagents	86

3	Role of angiogenesis in inflammation and pain in two rat models of synovitis	87
3.1	Introduction	87
3.2	Aims	89
3.3	Methods	90
3.3.1	Short term angiogenesis inhibition using PPI-2458 and 2% carrageenan induced synovitis	90
3.3.2	Intra-articular injection of FGF-2 and/or carrageenan	91
3.3.3	Dose response effects of PPI-2458 on angiogenesis (FGF-2)	94
3.3.4	PPI-2458 and intra-articular injection of FGF-2 and carrageenan	95
3.3.5	Tissue collection and preparation	96
3.4	Results	97
3.4.1	Synovial inflammation, angiogenesis and pain behaviour after intra-articular injection of 2% carrageenan and administration of the angiogenesis inhibitor PPI-2458	97
3.4.1.1	Inflammation	97
3.4.1.2	Angiogenesis	100
3.4.1.3	Pain Behaviour	101
3.4.1.4	Weights	102
3.4.2	Synovial angiogenesis and inflammation after intra-articular FGF-2 and/or carrageenan injection	104
3.4.3	FGF-2 induced synovial angiogenesis without inflammation	104
3.4.4	Carrageenan induced synovitis without angiogenesis	108
3.4.5	Combined effects of FGF-2 and carrageenan on synovial angiogenesis and inflammation	110
3.4.6	Dose-dependent inhibition of angiogenesis by PPI-2458	110
3.4.7	Synovial angiogenesis and inflammation after PPI-2458 administration early during FGF-2/carrageenan- induced synovitis	112
3.5	Summary of Results	114
3.6	Discussion	115
4.	Role of angiogenesis in inflammation, joint damage and pain in a rat model of knee osteoarthritis	119
4.1	Introduction	119
4.2	Aims	121
4.3	Methods	122
4.3.1	Injection of 2% carrageenan and MNX model of OA	122
4.3.2	Dexamethasone and Indomethacin	122
4.3.3	PPI-2458	122

4.4	Results	124
4.4.1	MNX model of OA	124
4.4.2	Effects of inhibiting inflammation on angiogenesis, joint damage and pain in the MNX model of OA	127
4.4.3	Effects of inhibiting angiogenesis on inflammation, joint damage and pain in MNX model of OA	133
4.4.4	Effects of enhancing synovitis using 2% carrageenan on angiogenesis, joint damage and pain in the MNX model of OA	137
4.4.5	Effects of inhibiting angiogenesis on synovitis, joint damage and pain in the combined MNX and 2% carrageenan model	137
4.5	Summary of results	152
4.6	Discussion	153
4.6.1	MNX model of OA	153
4.6.2	Inflammation and pain in OA	154
4.6.3	Angiogenesis and inflammation in OA	154
4.6.4	Effects of anti-inflammatory and anti-angiogenic treatments	155
5	Vascularisation and Innervation of human menisci	157
5.1	Introduction	157
5.2	Aims	158
5.3	Methods	158
5.4	Results	160
5.4.1	Meniscal Structure	160
5.4.2	Meniscal Vascularity	162
5.4.3	Sensory Innervation	164
5.5	Summary of results	166
5.6	Discussion	167
6	Overall Summary of Results	169
7	Conclusions and Future Directions	171
7.1	Angiogenesis and chronic inflammation	172
7.2	Angiogenesis, inflammation, structural damage and pain in osteoarthritis	173
7.3	Anti-inflammatory and anti-angiogenic treatments in osteoarthritis	175
7.4	Meniscus as a source of pain in human tibiofemoral osteoarthritis	176
7.5	Limitations of the current studies	178
7.6	Future directions	180
7.7	Concluding remarks	182
8	References	184
9	Appendices	210

9.1	Materials and Reagents	210
9.2	Antibody List	213
9.3	Buffers and solutions used for immunohistochemistry	215
9.4	Calculations	218
9.5	Consent Forms	219

LIST OF FIGURES

- Figure 1.1: Frontal view of the right knee joint.
- Figure 1.2: Illustration of the four layers and collagen distribution of the hyaline cartilage.
- Figure 1.3: Potential causative factors that may lead to initiation and progression of OA.
- Figure 1.4: Comparison of osteoarthritic and normal knee joint.
- Figure 1.5: Therapeutic approaches for OA.
- Figure 1.6: Process of angiogenesis.
- Figure 1.7: Structure of parent molecule fumagillin, TNP-470 and PPI-2458.
- Figure 2.1: Intra-articular injection into knee joint cavities.
- Figure 2.2: Meniscal transection surgery.
- Figure 2.3: Measuring pain behaviour.
- Figure 2.4: Knee joint swelling.
- Figure 2.5: Harvesting synovium.
- Figure 2.6: Harvesting knee joints.
- Figure 2.7: Indirect immunohistochemistry.
- Figure 2.8: Flow diagram highlighting the essential steps involved prior to staining procedures.
- Figure 2.9: Diagram illustrating the method of quantifying meniscal vascularisation and nerve growth.
- Figure 2.10: Severity of chondropathy determined macroscopically on post mortem samples of tibiofemoral joints.
- Figure 2.11: Samples selection criteria for human meniscal study.
- Figure 2.12: The spread of age and the associated macroscopic chondropathy scores.
- Figure 3.1: Experimental plan to investigate whether a short course of the angiogenesis inhibitor PPI-2458 curtails 2% carrageenan induced synovitis and pain behaviour.
- Figure 3.2: Experimental plan of how the doses of FGF-2 and/or carrageenan compounds were selected.
- Figure 3.3: Experimental plan to determine the time point after which synovial angiogenesis returns to levels similar to those in naïve controls.
- Figure 3.4: Experimental plan to elucidate the combined effects of FGF-2 and carrageenan.
- Figure 3.5: Experimental plan of how the dose-response effects of PPI-2458 on FGF-2 induced angiogenesis were analysed.
- Figure 3.6: Experimental plan of how the effects of PPI-2458 on intra-articular injection of FGF-2 and carrageenan were investigated.
- Figure 3.7: Histological evidence of synovial macrophage infiltration, angiogenesis and vascular density after 2% carrageenan injection and PPI-2458 administration.
- Figure 3.8: Inhibition of measures of inflammation after 2% carrageenan and PPI-2458 administrations.
- Figure 3.9: Inhibition of synovial angiogenesis after 2% carrageenan and PPI-2458 administration.

Figure 3.10: Time-course of the inhibition of knee joint pain after 2% carrageenan injection and PPI-2458 administration.

Figure 3.11: Time-course of the weight gain of animals.

Figure 3.12: Histological evidence of angiogenesis and macrophage infiltration after co-injection of FGF-2 and carrageenan.

Figure 3.13: Dose response effects of FGF-2 on synovial endothelial cell proliferation and macrophage infiltration.

Figure 3.14: Synovial EC proliferation after intra-articular injection of 6 picomoles of FGF-2.

Figure 3.15: Dose response effects of carrageenan on synovial macrophage infiltration and endothelial cell proliferation.

Figure 3.16: Persistent synovitis, after co-injection of FGF-2 and carrageenan.

Figure 3.17: Dose dependent reduction after PPI-2458 in FGF-2 induced synovial endothelial cell proliferation.

Figure 3.18: Inhibition of FGF-2 induced angiogenesis and resolution of synovitis after PPI-2458 administration.

Figure 4.1: Experimental plan investigating the effects of anti-inflammatory or anti-angiogenic drugs on synovitis, joint damage and pain behaviour in the MNX model of OA.

Figure 4.2: Histological changes of the medial tibial plateaux 35 days after meniscal transection surgery in the MNX model of OA.

Figure 4.3: Histological evidence of synovial angiogenesis, vascular density and macrophage infiltration in the MNX model of OA after anti-inflammatory or anti-angiogenic drugs.

Figure 4.4: Inhibition of measures of inflammation after meniscal transection surgery in indomethacin, dexamethasone and PPI-2458 treated animals.

Figure 4.5: Histological changes of the medial tibial plateaux 35 days post meniscal transection surgery.

Figure 4.6: Time-course of the inhibition of meniscal transection induced knee joint pain behaviour following anti-inflammatory and anti-angiogenic treatment.

Figure 4.7: Synovial angiogenesis and vascularisation of channels crossing the osteochondral junction in the medial tibial plateaux.

Figure 4.8: Weight gain and blood glucose levels following the administration of either anti-inflammatory or anti-angiogenic treatment.

Figure 4.9: Histological evidence of synovial macrophage infiltration after meniscal transection or SHAM surgery with intra-articular injection of 2% carrageenan and PPI-2458 treatment.

Figure 4.10: Histological evidence of synovial angiogenesis after meniscal transection or SHAM surgery with intra-articular injection of 2% carrageenan and PPI-2458 treatment.

Figure 4.11: Histological evidence of synovial vascular density after meniscal transection or SHAM surgery with intra-articular injection of 2% carrageenan and PPI-2458 treatment.

Figure 4.12: Inhibition of measures of inflammation after meniscal transection surgery and 2% carrageenan injection in PPI-2458 treated animals.

Figure 4.13: Synovial angiogenesis after meniscal transection surgery and 2% carrageenan injection in PPI-2458 treated animals.

Figure 4.14: Histological changes of the medial tibial plateaux in the MNX model of OA with 2% carrageenan and oral administration of PPI-2458.

Figure 4.15: Time-course of the inhibition of meniscal transection induced and carrageenan exacerbated knee joint pain following the administration of PPI-2458.

Figure 4.16: Weights of animals following the administration of anti-angiogenic compound PPI-2458.

Figure 5.1: Structure of human menisci.

Figure 5.2: Vascularity of human menisci.

Figure 5.3: Depth of vascular penetration along the midline of the menisci.

Figure 5.4: Calcitonin gene related peptide (CGRP)-immunoreactive (sensory) nerve profiles in the outer region of human menisci.

Figure 6.1: Relationship between inflammation, angiogenesis, innervation, structural damage and pain in OA.

LIST OF TABLES

Table 1: Weight gain of animals following treatment with angiogenesis inhibitor PPI-2458.

Table 2: Reduction in OA structural changes in the medial tibial plateaux following anti-inflammatory/anti-angiogenic treatment in the MNX model of OA.

Table 3: Exacerbation and/or reduction in OA structural changes in the medial tibial plateaux following intra-articular injection of 2% carrageenan into operated knee joints and/or anti-angiogenic treatment in the MNX model of OA.

Table 4: Exacerbation in OA structural changes in the medial tibial plateaux following intra-articular injection of 2% carrageenan in the MNX model of OA.

Table 5: Patient details and chondropathy scores.

ABBREVIATIONS

OA	Osteoarthritis
RA	Rheumatoid arthritis
MNX	Meniscal transection
PPI-2458	[(1R)-1-carbamoyl-2-methyl]-carbamic acid-(3R, 3S, 5S, 6R)-5-methoxy-4-[(2R, 3R)-2-methyl-3-(3-methyl-but-2-enyl) oxiranyl]-1-oxaspiro (2*5) oct-6-yl ester]
FGF	Fibroblast growth factor
FGFR	Fibroblast growth factor receptor
CGRP	Calcitonin gene related peptide
ECM	Extracellular matrix
GAG	Glycosaminoglycan
MMPs	Matrix metalloproteinases
ADAMTS	A-disintegrin and metalloproteinase with thrombospondin-like repeats
TIMPS	Tissue inhibitors of metalloproteinases
SLPI	Secretory leukocyte proteinase inhibitor
PAI	Plasminogen activator inhibitor
uPA	urokinase plasminogen activator (uPA)
tPA	Tissue plasminogen activator
EC	Endothelial cell
IL	Interleukin
TNF	Tumour necrosis factor
IFN	Interferons
MRI	Magnetic resonance imaging
NSAIDs	Non-steroidal anti-inflammatory drugs
COX	Cyclooxygenase
SADOA	Slow-acting drugs for osteoarthritis
DMOAD	Disease modifying osteoarthritis drugs
CNS	Central nervous system
NO	Nitric Oxide
VEGF	Vascular endothelial growth factor
BM	Basement membrane
PECAM	Platelet endothelial cell adhesion molecule
PDGF	Platelet derived growth factor
SMC	Smooth muscle cell
EDGF	Epidermal derived growth factor

GF	Growth factor
JNK	Jun N-terminal kinase
MAPK	Mitogen activated protein kinase
SAF	Serum amyloid A activating factor
HIF	Hypoxia inducible factor
TGF	Tumour growth factor
Ang	Angiopoietin
IFN	Interferon
BMP	Bone morphogenic protein
CAM	Chorio-allantoic membrane
BML	Bone marrow lesions
BME	Bone marrow oedema
Gd-DTPA	Gadolinium diethylenetriamine pentaacetic acid
MetAP	Methionine aminopeptidase
PG-PS	Peptidoglycan-polysaccharide
CIA	Collagen-induced arthritis
AA	Adjuvant arthritis
MIA	Monosodium-Iodoacetate
DC	Dendritic cells
NK	Natural killer
PG	Prostaglandins
COMP	Cartilage oligomeric protein
CRP	C-reactive protein
HA	Hyaluronic acid
LIF	Leukocyte inhibitory factor
ACLT	Anterior cruciate ligament transection
PM	Post mortem
O ₂	Oxygen
CO ₂	Carbon dioxide
BSA	Bovine serum albumin
MCL	Medial collateral ligament
CT	Connective tissue
OCT	Optimum cutting temperature
EDTA	Ethylenediaminetetraacetic acid
PBS	Phosphate buffered saline
PVP	Polyvinylpyrrolidene
ABC	Avidin-biotin complex

DAB	Diaminobenzidine
RT	Room temperature
PCNA	Proliferating cell nuclear antigen
DAPI	4'-6'-diamidino-2-phenylindole hydrochloride
GS	Griffonia simplicifolia
HEPES	N-[2-hydroxyethyl]piperazine-N'-[2-ethanesulfonic acid]; 4-[2-hydroxyethyl]piperazine-1-ethanesulfonic acid
HP β CD	2 hydroxy propyl β cyclodextrin
FCJ	Fibrocartilage junction
IR	Inner region
OR	Outer region
SEM	Standard error of mean
IQR	Inter quartile range
ANOVA	Analysis of variance
HUVECs	Human umbilical vein endothelial cells
FLS	Fibroblast like synoviocytes

1 INTRODUCTION

1.1 The Synovial Joint

A joint is an essential part of the human body, allowing for movement and providing mechanical support. It can be defined as an area of the body where bones link together. Diarthrodial joints, also known as synovial joints are the most common and the most moveable joints in the human body composed of several different tissues including the synovium, cartilage, bone, and menisci that all interact in a specified way to function relatively well over many years. The health of the joint deteriorates when these tissues are affected.

The knee joint is an example of a synovial (diarthrodial) joint, where the distal end of the femur, consisting of the medial and lateral femoral condyles, meets the proximal part of the tibia. These two bones form a hinge joint, with the patella bone or “knee cap” at the front. Joint capsule, menisci and the four main ligaments help to stabilize the joint, the medial and lateral collateral ligaments at either side of the knee hold the two adjoining bones in close proximity and serve to protect the joint against inward and outward forcing, the central anterior and posterior cruciate ligaments extend down from the lateral and medial condyles of the femur to the anterior and posterior intercondylar areas of the tibia respectively (Figure 1.1).

The knee joint contains two menisci, a medial and a lateral, located between the femoral condyles and the tibial plateaux. The anterior and posterior horns of the menisci are attached to the tibial plateaux by insertional ligaments. Menisci are crescentic shaped wedges of fibrocartilage. Human meniscal tissue consists of fibrochondrocytes suspended in an extra cellular matrix (ECM) of collagen, glycoproteins, proteoglycans and elastin (McDevitt et al., 1990; Gray 1999). Cells of the menisci are known as fibrochondrocytes owing to their chondrocytic appearance, yet ability to synthesise a fibrocartilage matrix (McDevitt et al., 1990). The body of the meniscus consists of principally type I collagen fibres running in a circumferential orientation. Less numerous fibres running in a radial orientation are thought to function to bind the circumferential fibres together (Messner et al., 1998). The collagen content of the meniscus consists of greater than 90% type I collagen with smaller proportions of types II, III, IV and V collagen (McDevitt et al., 1990). The menisci are known to have important roles in increased joint congruity, dispersal of weight, reduction of friction, shock absorption and proprioception (Seedhom et al., 1974; Assimakopoulos et al., 1992; Messner et al., 1998).

Chondroitin sulphate is the principal glycosaminoglycan (GAG) of meniscal proteoglycans with smaller proportions of dermatan sulphate, keratin sulphate and hyaluronic acid proteoglycans (Herwig et al., 1984; Nakano et al., 1997). The distributions of proteoglycans in the meniscus show regional variations reflecting the differences in loading across the tissue (Collier et al., 1995; Nakano et al., 1997; Messner et al., 1998).

The blood supply to the menisci mainly originates from the medial and lateral genicular arteries which give rise to a perimeniscal vascular plexus. The perimeniscal plexus is predominantly circumferential in organization and sends radial branches into the meniscus supplying only the outer portion of the meniscus, whilst the inner region is avascular. The extent of vascularisation is greater in the anterior and posterior horns compared to the meniscal body (Arnoczky et al., 1982; Danzig et al., 1983; Day et al., 1985). Myelinated and unmyelinated nerves are mostly found in the peripheral and middle thirds of the body of the meniscus, some of which are free nerves and others are associated with blood vessels. The inner third of the meniscal body is devoid of innervation. As with the vascularisation, nerve supply is greater in the anterior and posterior horns than in the body of the meniscus (Wilson et al., 1969; Day et al., 1985; Zimny et al., 1988; Mine et al., 2000).

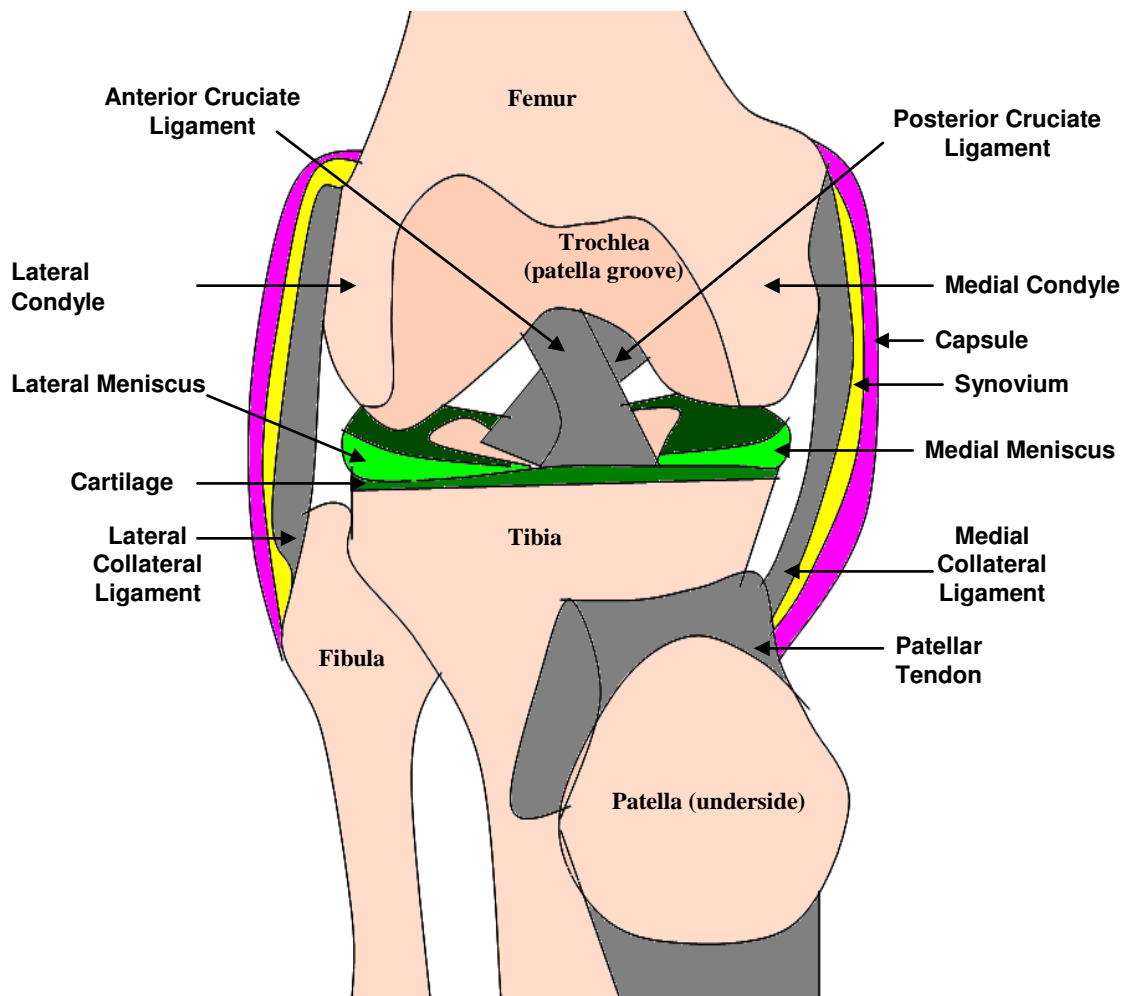


Figure 1.1: Frontal view of the right knee with quadriceps tendon cut and the patella reflected distally.

Synovial joints such as the knee are characterized by a fibrous capsule that surrounds the ends of the two bones, within which is the synovium. The synovium consists of two layers of cells; the outer intimal layer is largely fibroblast-like synoviocytes and the subintimal below this surface layer is largely macrophages. The synovial lining is approximately 2 to 3 cell thick and highly vascularised. However, during inflammation, local fibroblast proliferation as well as macrophage infiltration and recruitment to the synovium cause the lining to become up to 8 or more cell thick. This hypercellularity of the sub-intimal layer often contains perivascular lymphoid aggregates (Haywood et al., 2003). The superficial (shallow) layers of the synovium are highly vascular in order to satisfy the metabolic demands of both the synoviocytes (synovial cells) and avascular articular cartilage, whilst the deeper layers of the synovium are far less vascular. The synovial fluid secreted by the synovial lining into the joint space lubricates the joint and provides nutrients and transports cellular repair components to the chondrocytes in the cartilage and buffers the force between the two bones (Lorenz et al., 2006).

Normal joint surfaces are covered by a thin layer of hyaline articular cartilage, with subarticular calcified cartilage resting on subchondral bone, forming the gliding surface of the diarthrodial joints (Muir 1995). It provides a low-friction surface for the opposing bones with increased compressive force and is able to withstand a lifetime of load bearing and motion. Cartilage is made up of ECM, with around 1-5% of its volume comprising of chondrocytes but it is devoid of nerves and blood vessels. Chondrocytes ensure that the cartilage matrix is kept rich in collagen and proteoglycans (Bruckner et al., 1994) and are essential in maintaining a balance between synthesis and degradation of ECM components. The quality of ECM is critical for maintaining the functional properties of the cartilage (Poole et al., 1988). The remaining ECM is between 65-80% water based with type II collagen fibrils forming a macro fibular network arranged to withstand tensile, shear and compressive stresses thereby distributing static and dynamic joint loading and decreasing friction (Burr 2004). Collagen fibrils and the chondrocytes act to organize these macromolecules into a unique structure that depends on the depth of the cartilage (Imhof et al., 1997). The general orientation of the collagen fibrils defines the four main cartilage layers (Figure 1.2). Collagen orientation and water content differs in response to the pressure and shear force experienced by the cartilage (Imhof et al., 1997). Proteoglycans of the cartilage exert osmotic pressure to draw water into the cartilage which counteracts mechanical forces during movements that force water out (Imhof et al., 1997). This mass transport of fluid ensures that the whole body of cartilage is nourished and acts as a shock absorber against joint articulation and movement.

As the articular cartilage is avascular, its nourishment is supplied by the synovial fluid produced by synovial vasculature. Such vessels are fenestrated, allowing fluid and small molecules, including glucose to enter the synovial cavity and thus come into contact with the cartilage. Between the third layer and the calcified cartilage is the tidemark; a thin line that interlocks the two layers of cartilage and can often be

seen microscopically. In pathophysiological conditions such as OA, this is subjected to high stress leading to its duplication (Imhof et al., 1997).

Calcified cartilage (layer 4) is a highly specialized mineralized region of the articular cartilage. It is thought to provide attachment of the cartilage to the underlying bone, aid in transmitting and dissipating mechanical forces to the bone and prevent diffusion from the bone to radial layers of the cartilage (Oegema et al., 1997). The subchondral bone spaces contain vascular channels. These are small 10-30 μm diameter channels, often containing 1-2 blood vessels within them. These tend to grow up from the bone marrow towards the osteochondral junction and are enclosed in concentric layers of bone, forming a sheath. They can be open-ended, where the leading edge is covered by only a thin layer of endothelial cells, or close-ended, where the endothelial cells have been replaced by bone (Clark 1990). The function of these channels is yet to be fully understood. However, earlier studies have shown that such channels are in greater numbers under areas of greater weight bearing (Woods et al., 1970). The purpose of these channels have been proposed as a mechanism of getting blood-borne nutritional support to the articular cartilage and as a major part in the re-modelling of the subchondral bone that contributes to disease pathology (Clark 1990). Vascular channels have been shown to breach the osteochondral junction in ageing and arthritic disease. Here, penetration of the articular cartilage compromises the barrier of calcified cartilage between the bone and overlying cartilage. Subsequent invasion of blood vessels via these channels may contribute to cartilage changes in OA, such as cartilage calcification or endochondral ossification, and with it, cartilage thinning (Fenwick et al., 1999; Walsh et al., 2007).

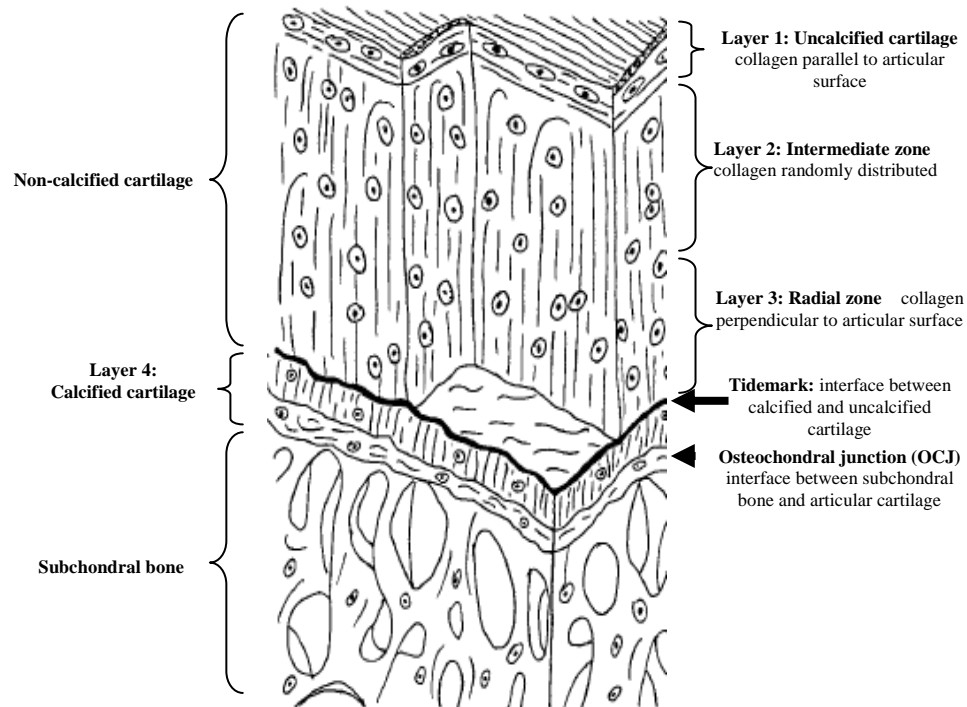


Figure 1.2: Illustration of the four layers and collagen distribution of the hyaline cartilage. (Adapted from Imhof et al., 1997).

1.2 Innervation of the knee joint

Knee joints are supplied with both primary nerves; branches of peripheral nerves passing adjacent to the joint and accessory nerves; branches of intra-muscular nerves crossing the joint capsule (Mapp 1995). The knee joint is richly innervated by sensory and sympathetic nerves. Sensory nerves detect and transmit mechanical information from the joint to the central nervous system (McDougall 2006) detecting pain. Structures such as the musculature, joint capsule, synovium, tendons, ligaments, menisci, periosteum and subchondral bone of the joint also have a rich nerve supply, whereas the articular hyaline cartilage is aneural (Hunter et al., 2008).

The nerves which serve the joint arise from several levels of the spinal cord and around 60% of such nerves are sensory nerves. There are four classes of such afferents, classified according to their activation threshold by mechanical stimulation. Large diameter (5 μm) myelinated nerve fibres encoding and transmitting proprioceptive signals that are either dynamic (movement sensations) or static (position sense) are mainly from groups I and II ($A\beta$) myelinated nerve fibres with a conduction velocity of 20-100 m/s. Small diameter (2-3 μm) myelinated nerve fibres which become a free nerve ending are group III ($A\delta$) fibres with a conduction velocity of < 20 m/s. They have a low mechanical threshold and so respond to passive joint movement. While the small diameter unmyelinated C fibres which carry nociceptive information belong to group IV having a conduction velocity of < 1 m/s, responding to extreme, noxious stimuli; indicating a noxious function. Proprioceptive $A\beta$ fibres of the joint terminate in the capsule, fat pad, ligaments, menisci and periosteum. Nociceptive $A\delta$ and C fibres innervate the capsule, ligaments, menisci, periosteum and mineralized bone especially areas of high mechanical load (Hunter et al., 2008). It is these fibres which are responsible for pain transmission in the joint (Heppelmann 1997), their main function being to detect noxious stimuli and transmit this information to the central nervous system from the joint.

1.3 Osteoarthritis

Arthritic disease is a significant health problem worldwide placing enormous burden on society (van Saase et al., 1989) due to its progressive and debilitating nature leading to chronic pain, disability, high morbidity and reduction in quality of life. OA is the commonest form of arthritis affecting the whole diarthrodial (synovial) joint. It is the biggest cause of joint pain in the elderly (Peat et al., 2001) and the main cause in the increase of joint replacement therapy (Dixon et al., 2004).

In 1986, the Subcommittee on Osteoarthritis of the American College of Rheumatology Diagnostics and Therapeutic Criteria Committee defined OA as “A heterogeneous group of conditions that lead to joint symptoms and signs which are associated with defective integrity of articular cartilage, in addition to related changes in the underlying bone at the joint margins” (Altman et al., 1986). In 1994, the World Health Organization Conference for Guidelines in Osteoarthritis Research, Diagnosis and Treatment updated the definition of OA to: “OA is a result of both mechanical and biological events that uncouple the normal balance between degradation and synthesis by articular cartilage chondrocytes and ECM, and subchondral bone. OA involves all tissues of the diarthrodial joint. Ultimately, OA is manifested by morphologic, biochemical and biomechanical changes. When clinically evident, OA is characterized by joint pain, tenderness, limitation of movement, crepitus, occasional effusion and variable degrees of inflammation” (Mollenhauer et al., 2002).

OA can be seen as a condition that results from a heterogeneous group of overlapping chronic and painful conditions affecting the synovial joints. No general definition of the disease is accepted as OA can be described in terms of the radiographic and histological changes seen in the joint as well as the symptoms, however structural changes and symptoms rarely correlate exactly. As a result some patients complaining of joint pain will hardly have any structural radiographic changes but on the other hand some patients with complete joint destruction will experience no joint pain. This makes the diagnosis of OA extremely challenging as it is based on a combination of these features.

OA is thus defined not as a single disease entity but rather a collection of disorders with different underlying pathophysiological mechanisms that have a similar final common pathway (Aigner et al., 2002). Numerous researchers are now compelled to regard OA as a "process" rather than a disease because it is observed in all those conditions that display an imbalance between mechanical stresses applied to the articular cartilage and its ability to withstand that stress (Slemenda et al., 1998), this leads to the loss of articular cartilage within the synovial joints causing joint damage.

1.3.1 Aetiology

The exact underlying cause of OA is unclear. Epidemiological studies, analysis of patterns of familial clustering and twin studies have all suggested that there is a definite genetic component (Valdes et al., 2006). There are also numerous interacting environmental and mechanical factors that contribute to the onset of OA. Perhaps the most obvious of these is age, since the incident of arthritis increases almost exponentially with age (Petersson 1996). Other factors including (but are not limited to), gender (being more common in women), joint instability and/or malalignment, malnutrition (Swoboda 2001), muscle weakness (Goldring et al., 2007), obesity (Felson 1990), occupation involving repetitive heavy joint use (Felson 1988) and trauma/joint injuries (Doherty et al., 1983) have all been implicated in the onset of OA. These risk factors may trigger biochemical and molecular pathways, leading to the progression of OA (Figure 1.3).

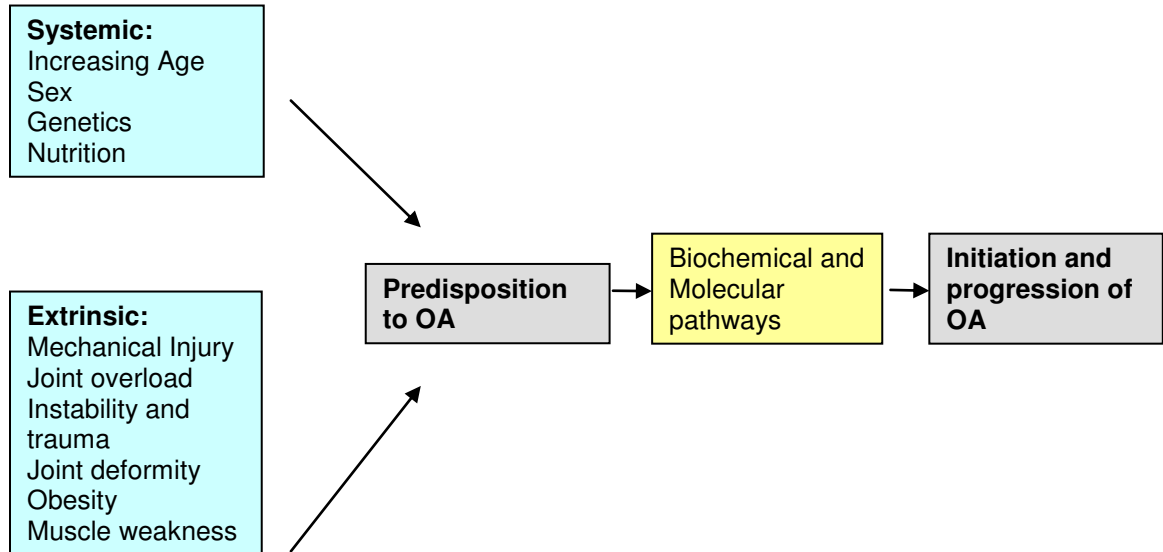


Figure 1.3: Potential causative factors that may lead to initiation and progression of OA. Systemic and extrinsic factors can result in altered biochemical and molecular pathways in the joint leading to structural damage.

1.3.2 Signs, Symptoms and Characteristics

OA mainly affects the large weight bearing joints such as knees, hip and lower spine, as well as the joints of hands and feet (Cushnaghan et al., 1991). OA can be classified as being primary/idiopathic (affecting previously healthy individuals over the age of 40 years) or secondary (develops in response to injury of the joint) in nature.

Since OA is not defined by a particular joint involvement pattern, clinical presentation is thus difficult to assess. OA is mostly not diagnosed until it has progressed to the later stages where more pronounced alteration in the joint lead to pain and radiographically detectable changes. Clinical symptoms of OA include (Hunter et al., 2008):

- Joint pain; intensity of which increases upon excessive joint movement and weight bearing but is relieved by rest except in advance form of the condition where OA can cause rest and night pain leading to loss of sleep, further exacerbating pain. This pain is often deep, aching and not well localized. It is usually of insidious onset and when pain persists, pain-related psychological distress is also evident.
- Stiffness; felt intermittently upon resuming activity after rest but with time it becomes permanent.
- Reduced function and joint movement.
- Joint instability, buckling or giving way.
- Crepitus (creaking of the joints with movement).
- Deformities, bony enlargement of the joint.
- Altered gait.
- Muscle atrophy or weakness.
- Joint effusion, swelling and inflammation, tenderness usually located over the joint.

Pain is the main symptom experienced as a result of the pathophysiology of OA and is shown to originate from several sources such as periosteum, subchondral bone, synovium, menisci, ligaments and muscles (Brandt et al., 1991). It is thought to be enhanced by inflammation and angiogenesis which are both interconnected. It has been postulated (Dieppe et al., 2005) that angiogenesis can lead to the innervation of normal articular insensate cartilage, thus being the source of pain. Vascularisation of non-calcified articular cartilage is a common feature in OA but the mechanisms driving it remain incompletely understood. Sensitisation of sensory nerves by inflammatory mediators can also cause pain and these sensitized nerves can therefore contribute to neurogenic inflammation and initiate new vessel growth.

Radiographically visible changes are narrowing of the joint space with osteophyte growth at joint margins and advancement of the subchondral bone (Goldring et al., 2007). Depletion of proteoglycans and collagen II have been found alongside fibrillation of the articular surface, fissures, thinning of the cartilage and tidemark duplication (Lorenz et al., 2006). Blood vessels cross the tidemark from the subchondral bone

into the avascular articular cartilage. Synovial inflammation is observed accompanied by thickening of the synovial lining, angiogenesis and synovial effusion, all leading to joint swelling.

1.3.3 Pathophysiology

In the osteoarthritic joint, gradual loss of articular cartilage is observed, where osteoarthritic cartilage loses its smooth appearance. Initial degenerative changes in the articular cartilage lead to cartilage softening, fibrillation, fissuring and diminished cartilage thickness. These changes become more pronounced with time, eventually exposing the underlying subchondral bone plate. Pathology in the articular cartilage is referred to as chondropathy (Figure 1.4). In the case of the knee joint, structural changes are more marked in the tibial cartilage, particularly in the medial compartment. Cartilage loss in OA results from the degradation of ECM by chondrocytes and activation of extracellular matrix metalloproteinases (MMPs). Additionally, metabolic activity of the chondrocytes is shifted towards a state where new matrix synthesis is outweighed by a breakdown of matrix constituents (Rousseau et al., 2007). Chondrocytes show a reduced expression of type II collagen, and aggrecan, the major cartilage proteoglycan. Upregulation of MMPs such as collagenases (MMP-1, -8 and -13), gelatinase (MMP-2) and stromelysin (MMP-3) is also apparent. These enzymes are synthesized by chondrocytes and released into the ECM where they are activated and cause degradation of collagen and proteoglycans (Murphy et al., 2005; Pardo et al., 2005; Cawston et al., 2006) but these are not dominant aggrecanase enzymes, and instead the major protease responsible are two members of the A-Disintegrin And Metalloproteinase with Thrombospondin-like Repeats (ADAMTS) family-ADAMTS-4 and ADAMTS-5 (Murphy et al., 2005). The activity of MMPs is controlled by tissue inhibitors of metalloproteinases (TIMPs). TIMP-1 is most effective in inhibiting MMP-1 and is the most highly expressed protease inhibitor in normal cartilage (Davidson et al., 2006). TIMP-3 is the only TIMP that can inhibit aggrecanases ADAMTS-4 and -5, and in addition is sequestered rather than released freely into the ECM, allowing for a precise control over its cellular localization, which is very useful in the carefully localized process of angiogenesis (Kashiwagi et al., 2001; Murphy et al., 2003). Disturbances in the regulation of MMPs and TIMPs increase cartilage degradation (Franses et al., 2010). Serine protease inhibitors, secretory leukocyte proteinase inhibitor (SLPI) and the plasminogen activator inhibitor (PAI)-1 are also responsible for cartilage matrix degradation. PAI-1 regulates the activation of of the serine protease plasmin via urokinase plasminogen activator (uPA) or tissue plasminogen activator (tPA), contributing to cartilage turnover by activating pro-MMPs (Cawston et al., 2006). SLP-1 inhibits many cartilage degrading proteases, and is implicated in reducing angiogenesis by inhibiting endothelial cell (EC) migration (Franses et al., 2010). Therefore a compromised articular matrix composition through an interplay of various promoters and inhibitors leads to abnormal matrix turnover and hence cartilage degradation.

Concomitant changes in bone are less well understood. OA is characterized by an increase in anabolic activity in the subchondral bone. Osteoblastic and Osteoclastic activities become unbalanced and increased

bone deposition results in subchondral bone sclerosis and formation of osteophytes. Osteophytes (new bone formation) appear at the joint margins, subchondral bone thickens, joint capsule enlarges, mild synovitis and effusion are also observed (Pelletier et al., 1995). It remains yet to be confirmed whether subchondral bone sclerosis is a cause of or consequence of cartilage loss in OA. The increased thickness and density of the subchondral bone and osteophyte formation may be a result of a disordered repair process to increase joint stability. Evidence suggests that sclerosis may be the initial pathological event in OA initiating subsequent cartilage loss through preventing the flow of nutrients from underlying subchondral bone to the cartilage (Hunter et al., 2003). Fragments of damaged joint cartilage detach and fall into the articular cavity as a result of fissuring and float in the synovial fluid causing the upregulation of inflammatory mediators like interleukin (IL)-1 and tumour necrosis factor (TNF)- α (Hedbom et al., 2002). This pathological process leads to compromised function of the cartilage to effectively distribute forces in the weight bearing joints (Maroudas 1976).

OA is largely thought of as a non-inflammatory disorder; however research has shown that inflammation is an integral component of OA progression contributing to the development of its symptoms (Bonnet et al., 2005). Inflammation may be caused by phagocytosis of shed cartilage fragments by synoviocytes. The inflamed synovium releases pro-inflammatory cytokines such as TNF- α and IL-1 and -6 (Smith et al., 1997). These cytokines can bind to chondrocyte receptors leading to further release of MMPs as well as inhibiting type II collagen production, hence enhancing cartilage degradation (Stannus et al., 2010).

Synovial and subchondral bone changes are now being regarded as essential in understanding the pathogenesis of progressive joint destruction, but whether events in cartilage precede those in bone and synovium or vice versa or they actually occur around the same time in cartilage, synovium and the subchondral bone are all topics of immense interest.

Meniscal degeneration is commonly seen in OA, where menisci appear torn, fissured, fragmented, macerated or completely destroyed (Bennett et al., 2002; Englund 2009). Proteoglycan loss, collagen alteration, degradation of the meniscal ECM, peri-meniscal synovitis, calcification and increased blood vessel growth not limited to the outer peripheral portion of the menisci (Burman et al., 1933; Herwig et al., 1984; Kapadia et al., 2000; Grainger et al., 2007; Sun et al., 2010) all contribute to meniscal degeneration and reduced meniscal tensile strength. The meniscus is less able to withstand loading and force transmission during normal movements of the joint, further leading to degenerative tears (Bhattacharyya et al., 2003) and exacerbating OA structural damage.

Degenerative tears occurring in OA are distinct from traumatic tears which usually occur in younger people as a result of a specific trauma to the joint in which the meniscus becomes trapped under excessive force between the femoral and tibial condyles (Englund 2009). Joint space narrowing as a result of OA displaces

the meniscus, exposing the underlying articular surfaces (Gale et al., 1999). The loss of normal functioning meniscus due to tears or displacement contribute to articular cartilage loss and further progression of OA (Hunter et al., 2006).

A strong association between meniscal degeneration, articular cartilage damage, subchondral bone changes, synovitis and joint space narrowing is reported in enhancing the experience of pain in OA (Gale et al., 1999; Hunter et al., 2006; Yusuf et al., 2010).

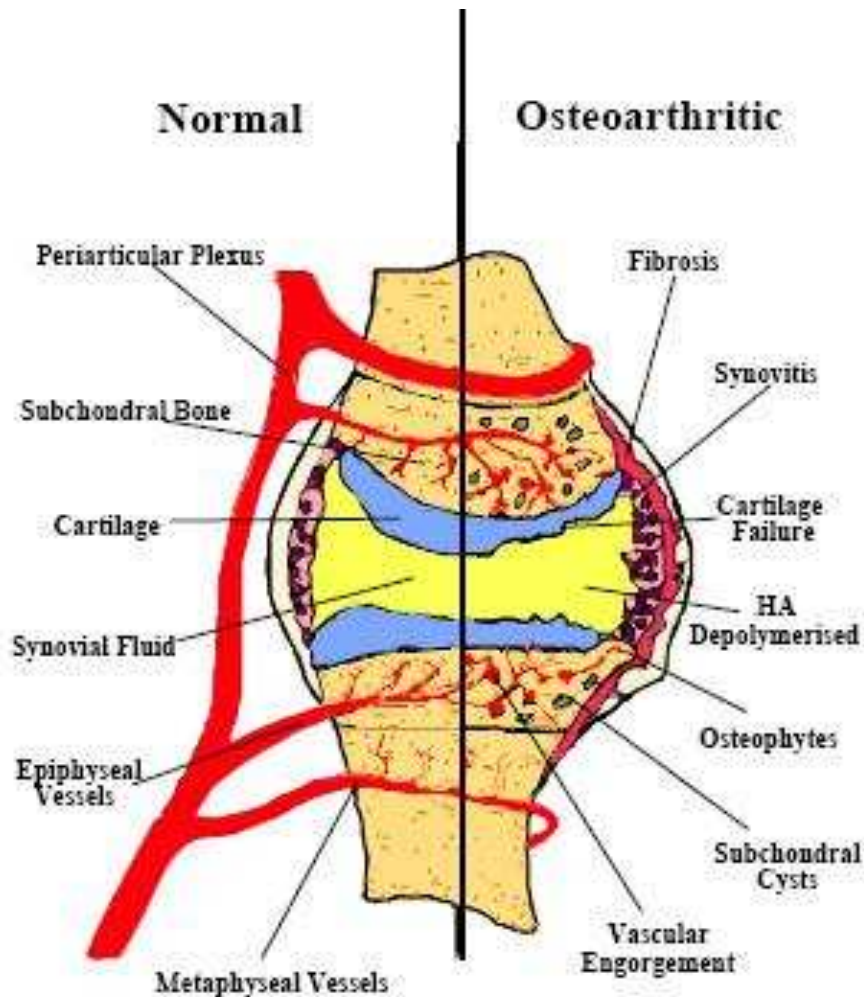


Figure 1.4: Comparison of osteoarthritic and normal joint. Changes occur in the cartilage (loss of proteoglycans, fibrillation/erosion), subchondral bone (osteophytosis, sclerosis, remodeling) and synovium (inflammation). (Smith et al., 2002).

1.3.4 Diagnosis and Detection

To a certain degree like other complex clinical syndromes, a poor correlation is observed between the clinical features (symptoms), underlying mechanisms (pathology) and imaging (radiological) of OA.

Standard radiography is insensitive to the earliest pathological features of OA, hence the absence of positive radiographic findings can not confirm the complete absence of symptomatic disease (Kellgren et al., 1957); radiographs have also been shown to not always complement the clinical presentation of pain (Spector et al., 1993). Conversely, on some occasions people may have indication of OA through X-ray changes but display mild physical symptoms. The advanced form of the disease is clearly visible on plain radiographs as narrowing of joint space, osteophytes and sometimes changes in the subchondral bone. Standard radiography, in general, provides a limited view of the disease process in subchondral bone (Ding et al., 2007).

Ultrasound can be used to measure synovial thickness and Doppler imaging can be used to reveal synovial blood flow and hence indirectly angiogenesis and synovitis, which encompass some of the early changes observed in OA. Magnetic Resonance Imaging (MRI) is now permitting serial assessment of subchondral bone, both in early and established OA as well as in normal joints. This whole-organ evaluation approach has demonstrated frequent abnormalities of cartilage, menisci, bone (bone marrow lesions and osteophytes), synovium and ligaments even when no radiographic changes are present in patients with OA (Conaghan et al., 2006) such as bone marrow lesions in early OA, which are not detectable with plain radiographs (Conaghan et al., 2004; Carrino et al., 2006).

Arthroscopy can reveal cartilage damage before changes in bone become evident however it is invasive so it is not a method of choice for diagnosis of OA. No reliable laboratory test for diagnostic purpose is available. Erythrocyte sedimentation rate and levels of C - reactive protein provide useful information about inflammation in some patients with OA but they correlate poorly with pathology of cartilage damage.

The 2009 European League Against Rheumatism (EULAR) recommendations for diagnosing knee OA state that when the following 3 symptoms and 3 signs are detected, it is sufficient to correctly diagnose 99% of knee OA (Altman 2010). The 3 symptoms are persistent knee pain, limited morning stiffness and reduced function, and the 3 signs are, crepitus, restricted movement and bony enlargement (Zhang et al., 2010). American College of Rheumatology (ACR) describe OA based on clinical examination of knee pain in addition to 3 of the following 6 criteria: > 50 years of age, < 30 minutes of morning stiffness, crepitus, bony tenderness, no enlargement, or an absence of palpable warmth (Altman et al., 1986). Sensitivity for these criteria is 95% with 69% specificity (Altman 2010).

Patients presenting in the clinics normally have severe OA so early detection and analysis of OA in patients need to be the prime research focus to fully understand the mechanisms in disease progression from start to finish.

1.3.5 Treatment

OA is not a curable disease. Mechanisms by which OA arises remain incompletely understood. At present therefore treatment is tailored according to risk factors, severity of pain, presence or absence of joint effusion and degree of osteoarthritic damage. Because no single therapy is adequate in OA, it comprises of both non-pharmacological and pharmacological therapies. Therapy focuses on alleviating the signs and symptoms of the disease especially pain and inflammation, to improve quality of life, mobility, walking and if possible, to slow the progression of OA (Altman 2010). Physical therapy and exercise are employed to improve stiffness by increasing movement and strengthening muscles that support the affected joints. Joint replacement surgery is the end result in those in whom conventional management has failed. Currently, analgesics (paracetamol, acetaminophen, opioids and capsaicin), anti-inflammatory agents with analgesic properties (non-selective non-steroidal anti-inflammatory drugs [NSAIDs], cyclooxygenase [COX]-2 inhibitors, topical NSAIDs and intra-articular corticosteroids), symptomatic-slow-acting drugs and anti-cytokine therapy are used to treat OA of the knee (Michael et al., 2010) (Figure 1.5). These drugs are not without their associated side effects. The specific risk factors associated with the use of classic NSAIDs are due to their mechanisms of action on prostaglandin secretion. These drugs act by inhibiting the secretion of prostaglandins through COX-1 and/or COX-2 inhibition. Specific COX-2 inhibitors have a selective anti-inflammatory effect but are still markedly nephrotoxic, whereas non-selective COX inhibitors also have renal side effects. Intra-articular glucocorticoid injections can markedly reduce joint effusions but are used with caution in diabetic patients who are already hyperglycaemic. Slow-acting drugs for osteoarthritis (SADOA) which can be further subdivided into either symptomatic-SADOA or disease modifying osteoarthritis drugs (DMOAD) include hyaluronic acid, D-glucosamine sulphate, chondroitin sulphate and diacerein (Michael et al., 2010). Their specific mechanisms of actions are yet to be elucidated but they range from curtailing inflammation to nociceptor blockade and targeting matrix destroying effects of cytokines. Antibodies against TNF- α or the use of anti-inflammatory cytokines such as IL-1, -10, -13 and TNF- β are also available (Michael et al., 2010).

Inflammation and Angiogenesis both contribute to the symptoms and pathology of OA, therefore further analysis of their role can lead to more effective therapies.

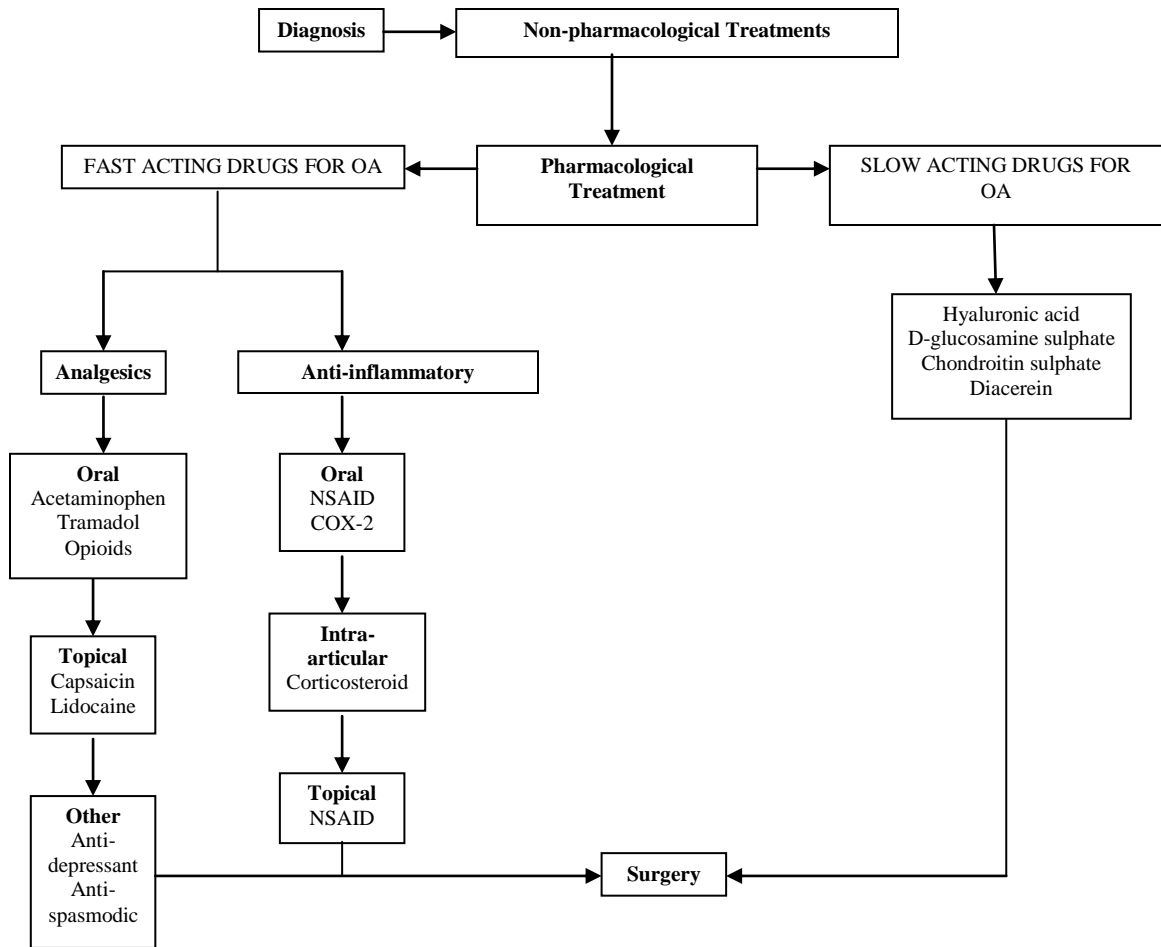


Figure 1.5: Therapeutic approach for OA. After the diagnosis of OA, a non-pharmacological approach is initiated. If that is not effective, then a pharmacological approach is adopted. Joint replacement surgery is the end result in those in whom conventional management has failed. COX (cyclooxygenase), NSAID (non steroidal anti-inflammatory drug) (Altman 2010).

1.4 Pain and Osteoarthritis

The sensation of pain alerts us to real or impending injury and triggers the appropriate protective responses in harmful situations. However, in some instances, pain can exceed its usefulness and can become chronic and debilitating. The theory of pain that has been carried over into the 20th Century was originally proposed by a scientific philosopher Descartes in the 17th Century, but in 1965 ideas about pain were revolutionized by Wall & Melzacks “Gate Control Theory” (Melzack et al., 1965). This theory states that the transmission of nerve impulses from afferent fibres (nociceptors) to the spinal cords dorsal horn is modulated by a spinal “gating” mechanism, which increase or decrease the flow of these afferent signals to higher processors i.e. the brain, depending on their activity. Essentially the theory highlighted the central nervous system as an essential component in pain processes (Melzack 1993). The current beliefs of pain are largely based on this “gate control theory” outlined over 40 years ago.

The tissues of healthy joints appear to have a relatively high threshold in order to prevent normal movements generating pain (Dieppe et al., 2005). Pain arising from damage to tissue that the nerves serve is known as inflammatory pain, whereas, neuropathic pain arises from changes in damaged nerve endings (Dickenson 2002). Pain, the predominant feature of OA, is one of the main reasons of patients seeking medical advice. The precise causes of this pain are not fully understood as the pain experienced in OA varies widely in nature, severity and location between patients, hence it is plausible to assume that the sources of pain also differ between patients (Creamer 2000).

It is the sensory neurons (nociceptors) that transmit the information that is portrayed as pain, of which the A δ -fibres transmit the sharp pain of an acute injury and the C-fibres produce the dull, aching pain of a deeper, more persistent injury and the burning quality of neuropathic pain (Julius et al., 2001; McCabe 2004). Afferent sensory nerves terminate at the dorsal horn in the spinal cord, here information from the periphery is interpreted and acted on through interaction with the central nervous system (CNS) (Schaible et al., 1993; Felson 2005; McDougall 2006). Nociceptors in the joint normally respond only to movement of the joint beyond its working limits, however following joint damage, physical changes (joint effusion, tissue oedema, and structural changes) in the joint, alongside the introduction of inflammatory mediators released into the damaged tissues, result in a reduction of the mechanical threshold for the activation of articular nociceptors. In this instance, manipulation and movement of the joint within its normal range is easily sufficient to activate them and cause allodynia (pain in response to a normally innocuous stimuli) and hyperalgesia (heightened pain intensity in response to a normally painful stimuli) (Schaible et al., 1985).

It has been reported that nociceptors in the joint do not always signal pain when stimulated by mechanical pressure, explaining why some patients with extensive radiographic changes of OA fail to report pain whilst others having normal radiographs experience pain (Hannan et al., 2000; Felson et al., 2001).

Inflammation has been strongly linked to hyperalgesia and persistent pain in OA (Hill et al., 2001; Hill et al., 2007). Another means by which pain may be generated in joints is via the stimulation of “silent nociceptors”. These sensory nerve fibres are quiescent in normal joints. However, following injury and/or inflammation these become activated and start to send nociceptive information to the CNS (Grigg et al., 1986; Schaible et al., 1988). Persistent pain (chronic inflammation) can alter both peripheral and central signaling mechanisms. Effectively, peripheral sensitization will, over a period of time lead to central sensitization alongside “Neural plasticity”, which may play a large role in the pain experienced during arthritis. Whereby, the normal neural circuits that feed in to the pain pathways can reconfigure in response to the stimulus they receive. Here, persistent pain transmission, as in chronic inflammation can lower the threshold of the A δ and C fibres from just detecting noxious stimuli, to detecting non-noxious stimuli, such as normal knee joint movements (McCabe 2004). Overall, nociceptors not only signal acute pain, but also contribute to persistent and pathological pain conditions that occur after injury or inflammation, wherein pain is produced by normally innocuous stimuli resulting from either the lowering of nociceptor activation thresholds (peripheral sensitization) and/or the increased responsiveness of spinal cord neurons that are responsible for pain transmission to the brain (central sensitization) (Coggeshall et al., 1983; Schaible et al., 1986; Dieppe et al., 2005).

1.4.1 Joint pathology contributing to pain in OA

The source and cause of osteoarthritic pain is still largely unknown but is believed to involve multiple interactive pathways, and could be caused by the structural damage occurring in the joint such as degradation of the articular cartilage, joint space narrowing, osteophyte formation, subchondral bone changes, meniscal changes and/or inflammation in the joint.

Articular cartilage is both avascular and aneural, incapable of directly generating pain. In contrast, nociceptors are found primarily in the tissues of subchondral bone, periosteum, ligaments, muscle, joint capsule, synovium and the menisci and may be implicated in the genesis of pain in OA (Felson 2005).

Synovial hyperplasia, fibrosis, thickening of synovial capsule, activated synoviocytes and in some cases lymphocytic infiltrate (B- and T-cells as well as plasma cells) are characteristic features of osteoarthritic synovium (Hunter et al., 2008). Synovium contributes to osteoarthritic pain as a result of irritation of sensory nerve endings within the synovium from osteophytes and synovial inflammation that is due in part to the release of prostaglandins, leukotrienes, proteinases, neuropeptides and cytokines (McDougall 2006). Using non-contrast MRI, inflamed infrapatellar fat pad, has also been implicated in the pathogenesis and hence a source of pain in OA (Fernandez-Madrid et al., 1995; Hill et al., 2007).

It has been shown that blood vessels grow up from the subchondral bone, breaching the tidemark and invading the normally aneural and avascular articular cartilage in OA (Suri et al., 2007). The route by

which they do this is usually within the vascular channels that extend up from the subchondral bone marrow spaces through the calcified cartilage and into the non-calcified articular cartilage (Clark 1990), which effectively provide a direct connection between the subchondral bone marrow spaces and articular cartilage. Such invasion has also been linked to the loss of proteoglycans from the cartilage providing less resistance to vascular invasion. Alongside the growth and invasion of new vessels, accompanying afferent fibres have also been observed, which may be attributed to some of the pain experienced in OA. Experiments have indicated that neovascularisation precedes nerve growth forming a pathway for innervations of the surrounding tissue (Gu et al., 1995). If this is the case at the osteochondral junction, neovascularisation in OA from underlying subchondral bone and the subsequent invasion of the overlying articular cartilage may also form a pathway in which these sensory nerves can grow. As well as the sensitization of joint nociceptors, both in the synovium and within the subchondral bone, such as those growing through vascular channels, there are other peripheral components in joint pain suffered in OA, including bone pain caused by rapid bone turnover and subchondral bone plate thinning (due to high osteoclast activity and an acidic pH), the ossification of chondrocytes to form osteophytes and the formation of osteophytes, attributing to joint space narrowing. Source of pain in OA has been attributed to bone pathologies such as subchondral bone sclerosis, microfractures, raised interosseous pressure and decreased blood flow leading to bone angina and stretching of periosteum by osteophyte formation (Arnoldi et al., 1975; Szébenyi et al., 2006; Hunter et al., 2008). Bone marrow lesions detected using MRI are also strongly associated with pain in OA (Felson et al., 2001).

However, the use of bone pathology as an explanation for pain in OA is limited since only a weak relationship exists between radiographic joint changes and the level of pain experienced. Patients suffering from joint pain may have periarticular syndromes; soft tissue lesions that are painful and often disabling e.g. Baker's cyst or Infrapatellar bursitis, caused by inflammatory mediators that build up in the soft tissue. The above mentioned studies on sources of pain in OA rely on correlation between particular tissue pathologies and presence of pain. From these studies it can not be confirmed whether a particular pathological process in OA is the cause of pain, it can only be deduced that the two are associated.

Another source of joint pain in OA may be directly due to the nerves themselves. Following joint injury, the nerves which re-innervate the healing tissue may show a disorganized and abnormal morphology, containing an over abundance of chemicals such as Substance P and CGRP (McDougall et al., 2000) indicating that injured joints could develop neuropathic pain post-trauma which has been successfully treated with the neuropathic pain analgesic gabapentin to relieve arthritis (Hanesch et al., 2003).

1.4.2 Neuropeptides, Sensory Nerves and Inflammation

Inflammation in OA, whether it is in the synovium or bone is a substantial contributor to joint pain. Neuronal activity in the pain pathway is ultimately responsible for the generation and exacerbation of joint pain. Release of inflammatory mediators such as bradykinin, prostaglandins, histamine, lactic acid, substance P, CGRP and vasoactive intestinal peptide into the joint sensitizes nociceptors to otherwise normal innocuous joint movements to elicit a painful response (Hunter et al., 2008). With time, in OA, inflammation and increased neuronal activity from the periphery can cause plasticity changes in the CNS. Second order neurons in the spinal cord increase their firing potential such that the transmission of pain information to the somatosensory cortex is enhanced. This central sensitization intensifies pain felt and can even lead to pain responses in other regions of the body remote from the inflamed joint (referred pain) (Hunter et al., 2008). As the disease progresses, more of these mediators accumulate in the affected joint, thereby stimulating a self-perpetuating cycle of pain generation.

Neuropeptides are a family of chemical mediators, stored and released from the terminals of autonomic nerves and slowly conducting joint afferents. Local axon reflexes are responsible for the peripheral release of neuropeptides from sensory nerves, leading to neurogenic inflammation (McDougall 2006). Numerous neuropeptides are localized in nociceptive afferent nerve fibres, including the thin un-myelinated A and C-fibres, both of which are found in the joints.

CGRP and substance P are both well known neuropeptides markers for primary afferent fibres. CGRP is a 37 amino acid peptide known to exist in two forms, alpha and beta, that activates intracellular adenylyl cyclase and protein kinase A through G protein-coupled receptors including the CGRP1 receptors (Bird et al., 2006). CGRP coexists with Substance P in small-diameter afferent fibers and are important mediators in the pathogenesis of arthritis (Chen et al., 2008). It has been reported that sensitization of sensory nerves lead to the untimely, abnormal and excessive release of neuropeptides in some areas and depletion in others, leading to neurogenic inflammation, causing vasodilatation, increased vascular permeability and plasma extravasation into the surrounding tissues, all of which are characteristic features of an acute inflammatory response (Garrett et al., 1992; Konttinen et al., 2006). Substance P has been shown to induce plasma extravasation into the joint and stimulate the function of various inflammatory cells whilst CGRP has been reported to both increase blood flow to the joint, and also potentiate the effects of Substance P (Mapp et al., 1996). Hyper-responsiveness of CGRP was blocked in acute synovitis following administration of a selective CGRP antagonist, indicating that CGRP plays an important role in the central neurotransmission of painful mechanosensory information arising from the knee (Neugebauer et al., 1996). CGRP is also referred to as a “bone neuropeptide” which has been shown to inhibit osteoclastic bone resorption and may be implicated in the bone remodelling seen in OA (Konttinen et al., 1996). The release of neuropeptides also has a powerful effect on cytokine production such as the interleukins which can further lead to the up regulation of these neuropeptides, hence potentiating the inflammatory effect as well

as pain behaviour (Kontinen et al., 2006). Taken together, previous literature indicates that sensory neuropeptides, of which CGRP and substance P are most well studied, contribute towards generating and promoting joint pain in OA.

1.5 Angiogenesis and Osteoarthritis

The complex process of angiogenesis is defined as the growth of new blood vessels from pre-existing vasculature (Risau 1997). Under normal conditions angiogenesis is tightly regulated by various activating and inhibitory factors. Angiogenesis is fundamental to many physiological events including embryogenesis, growth, wound healing and female reproductive system (Walsh 1999). Unregulated angiogenesis can result in numerous pathologies including chronic inflammation, tumour growth and metastasis, arthritis (Walsh et al., 2001), diabetic retinopathy, psoriasis, and juvenile haemangioma (Powell 1999).

1.5.1 Process of Angiogenesis

Angiogenesis is viewed as a multi-step process rather than just a single event (Bonnet et al., 2005) involving intensive interplay between cells, soluble factors, ECM components, activating and inhibiting factors (Liekens et al., 2001). These vary depending on the tissue involved, between different physiological and pathological conditions as well as during the different phases of a continuous disease process such as synovitis (Bonnet et al., 2005).

Angiogenesis is rapidly initiated upon receiving an activating signal, also known as the angiogenic stimulus. Hypoxia, ischemic conditions, diseased or injured tissues producing and releasing angiogenic promoters can all trigger angiogenesis. Vascular relaxation mediated by Nitric Oxide (NO) can enter ECs in the angiogenic cascade (Griffioen et al., 2000). Vascular endothelial growth factor (VEGF) has also been implicated in the initiation of angiogenesis. VEGF can induce vasodilation via endothelial NO production, increase EC permeability and prevent EC apoptosis (Brown et al., 1997) as well as inducing proteases and various receptors important during cellular invasion and tissue remodelling. It is abundantly released by hypoxic tumour cells, macrophages and various other cells of the immune system (Ziche et al., 1997). VEGF-receptor is upregulated under hypoxic and ischemic conditions, emphasising its role in the early phases of angiogenesis (Forsythe et al., 1996). Angiogenesis initiation however does not solely depend on VEGF production.

The first process to take place after receiving the angiogenic stimulus is the activation of ECs. This involves their detachment from the tight configuration with adjacent ECs by the alteration of vascular endothelial cadherin junctions that link them together (Bonnet et al., 2005), leading to increased vascular permeability. The underlying endothelial basement membrane (BM) is degraded by proteolytic enzymes such as MMPs and plasminogen activators, releasing matrix bound angiogenic factors (Pepper 2001) enabling the migration and proliferation of ECs into the stroma of neighbouring tissues.

Following the proteolytic degradation of the BM, ECs start to migrate through the degraded matrix into the surrounding areas. This migration is aided by a variety of cell surface associated integrins, allowing

specific cell matrix adhesions as they move through the ECM to reach the site of new vessel formation (Carmeliet 2000). ECs proliferate to provide adequate capillary perfusion to the target site, if for any reason proliferation is halted then the angiogenic response fails to progress beyond the initial stage of neovascularisation which is vascular sprouting.

Capillary tube formation and deposition of new BM are critical steps in the formation of new, fully functional capillaries and requires the re-establishment of the vascular endothelial cadherin and adherin junctions that were initially disrupted. This requires the tight cell-cell adhesions to form; platelet endothelial cell adhesion molecule-1 (PECAM-1) plays an important role in this. EC interactions with ECM and mesenchymal cells are an essential requirement for the formation of a stable vasculature. Hence when the capillary tube formation is completed and the BM is laid down, surrounding vessel layers composed of mural cells (Hirschi et al., 1997) need to be recruited. This is accomplished by the synthesis and secretion of growth factors like platelet derived growth factor (PDGF) which is a mitogen and chemoattractant for a variety of mesenchymal cells (Griffioen et al., 2000). Mural precursor cells then differentiate into pericytes and smooth muscle cells (SMC) through the cell-cell contact dependent process. Anastomoses are then created and blood flow is established leading to the development of vasoregulatory system and a fully functional microvasculature through the expression of vasoactive peptides and their receptors (Walsh 1999) whilst redundant vessels regress as a result of EC proliferation (Bonnet et al., 2005) (Figure 1.6).

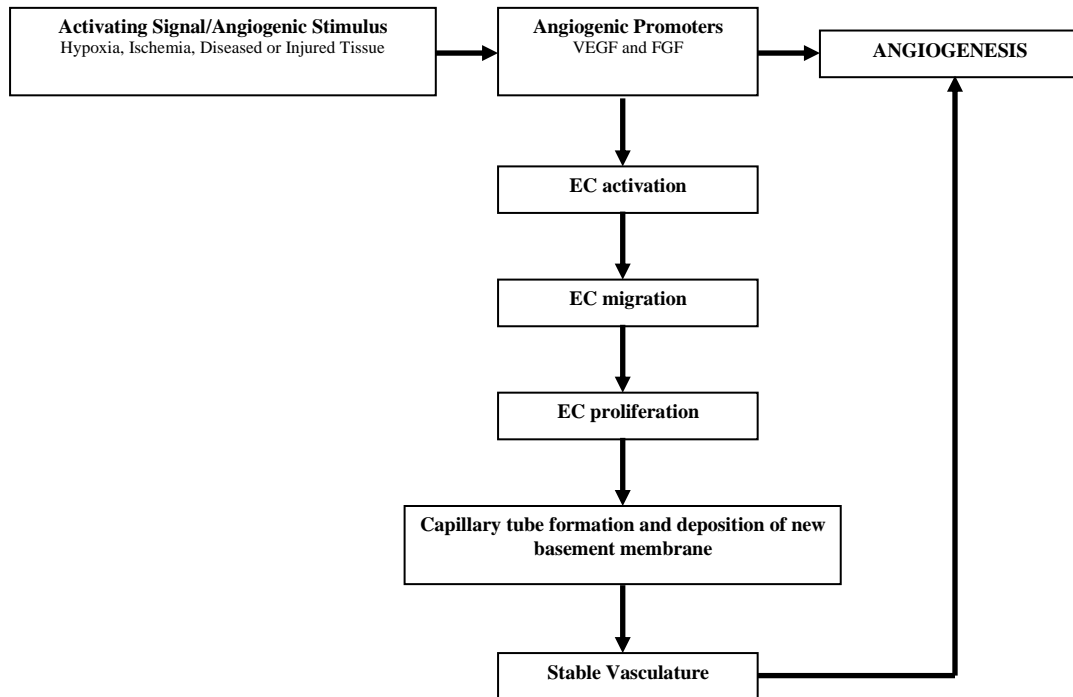


Figure 1.6: Process of angiogenesis. Activating signal/angiogenic stimulus leads to the release of angiogenic promoters including vascular endothelial growth factor (VEGF) and fibroblast growth factors (FGFs) which assist in the development of new blood vessels (angiogenesis).

1.5.2 Factors regulating Angiogenesis

Angiogenesis is regulated by numerous inducers and inhibitors produced by a large number of cells under various conditions. VEGF, FGF, epidermal-derived growth factor (EDGF), PDGF, angiopoietins as well as chemokines and cytokines are some of the well known pro-angiogenic factors (Walsh 1999; Liekens et al., 2001; Bonnet et al., 2005). Perhaps the most well described of these pro-angiogenic factors is VEGF (Klagsbrun et al., 1999). These regulatory mediators are either soluble, ECM or membrane bound growth factors (GF) or components of ECM itself.

VEGF family and the angiopoietins specifically act on ECs. VEGF is produced in response to certain growth factors, cytokines and in response to low tissue oxygen tension (Liekens et al., 2001). VEGF is a potent angiogenic factor which also regulates chondrocyte metabolism. It couples the invasion of blood vessels with hypertrophic cartilage remodelling and ossification in OA (Murata et al., 2008). VEGF can be expressed by osteoblasts, hypertrophic chondrocytes, and superficial articular chondrocytes in OA, as well as by macrophages and fibroblasts within the synovium (Enomoto et al., 2003). VEGF expression is upregulated in OA chondrocytes compared to normal controls (Gerber et al., 1999), although increased VEGF expression in OA articular cartilage is predominantly localised to the superficial zones rather than near sites of osteochondral angiogenesis (Pufe et al., 2005).

Inflammatory cytokines, hypoxia and mechanical stress each modify chondrocyte phenotype in OA (Pufe et al., 2004), including upregulated VEGF expression (Goldring 2001; Murata et al., 2008). IL1 induced VEGF production was dependent on Jun N-terminal kinase (JNK) but not p38 mitogen-activated protein kinase (MAPK) signalling pathways (Murata et al., 2006). The inflammation-responsive transcription factor Serum Amyloid A activating factor-1 (SAF-1) may regulate VEGF expression in chondrocytes during arthritis (Ray et al., 2007). Knock-down of endogenous SAF-1 inhibited IL-1 β and tumour growth factor (TGF)- β mediated induction of VEGF expression in chondrocytes.

Hypoxia upregulates VEGF expression in chondrocytes through the activation of hypoxia inducible factor (HIF)-1 α . HIF-1 α and VEGF display similar localisations in OA (Pfander et al., 2005). Increased VEGF expression in hypoxic chondrocytes was dependent on the p38 MAPK pathway, indicating that inflammation and hypoxia regulate VEGF expression in chondrocytes through distinct signalling pathways (Murata et al., 2006).

Upregulated VEGF expression in chondrocytes induced by mechanical overload/stress such as compression, shear, tension and strain may also be mediated by HIF-1 α activation (Tanaka et al., 2005). HIF-1 α expression also accompanied VEGF expression in overloaded bovine cartilage disks (Pufe et al., 2004). Inflammatory mediators may also contribute to the stimulation of chondrocytes by abnormal

mechanical stress (Loeser 2006) and synergy between inflammatory, hypoxic and mechanical pathways may be key to the predilection of diarthrodial joints to develop OA.

VEGF may facilitate the secretion of MMPs whilst reducing TIMP production, especially under hypoxic conditions (Pufe et al., 2004; Tanaka et al., 2005). The resistance of articular cartilage to vascular invasion, is in part due to the generation of anti-angiogenic factors, including TIMPs, by articular chondrocytes (Smith et al., 2003). VEGF's ability to shift the MMP:TIMP balance in favour of matrix degradation may contribute to the loss of angiogenesis inhibition observed in OA cartilage. Modulation of chondrocyte function, therefore, far from being a coincidental action of VEGF, may enhance its direct angiogenic effects on vascular ECs. This may well be desirable in the normal growth plate, but in OA, where the equilibrium is already shifted to cartilage degradation, such effects may exacerbate the disease process.

Angiopoietin (Ang)-1 and Ang-2 play key roles in blood vessel maintenance, growth and stabilisation (Carmeliet 2003). Once VEGF has triggered the formation of immature vessels (Polverini 2002) Ang-1 stabilises them by recruiting mesenchymal cells to the site and promoting their differentiation into vascular SMC (Horner et al., 2001). Ang-2 is a natural antagonist of Ang-1, competitively inhibiting the binding of Ang-1 to Tie-2 receptors (Kasama et al., 2007). In synovial fibroblasts, Ang-1 and Ang-2/Tie expression is modulated by hypoxia, VEGF and the proinflammatory cytokines IL-1 and TNF- α (Scott et al., 2005). Osteoblasts also are an important source of Ang-1. TNF- α and interferon- γ (IFN γ) co-stimulation reduces the secretion of Ang-1 from human osteoblasts which is mediated in-part by an NF κ B dependent pathway leading to the induction of NO synthesis (Jimi et al., 2005). Mice deficient in Ang-2 are unable to elicit an inflammatory response, perhaps suggesting an anti-inflammatory effect of Ang-1 (Fiedler et al., 2006). Again, complex interactions are emerging between angiogenesis, inflammation and bone formation.

TGF β -1, noted above to mediate osteophyte growth, has complex effects on angiogenesis. It inhibits EC growth, promotes BM reformation and stimulates SMC differentiation and recruitment (Carmeliet 2003). TGF β -1 therefore may be important in vascular maturation, an essential step in developing a stable neovascular bed. PDGF similarly can contribute to vascular maturation through proliferation of pericytes and vascular SMCs (Abramsson et al., 2003). TNF- α and TGF- β can exert their angiogenic effects by releasing factors from macrophages, ECs and tumour cells.

Fibroblast growth factor (FGF) is a family of growth regulatory proteins sharing 35% to 50% amino acid sequence identity that have potent mitogenic effects on various cells of mesodermal and ectodermal origin (Szebenyi et al., 1999). FGF signalling is transduced through the formation of a complex, of a growth factor, a proteoglycan and a high affinity fibroblast growth factor receptor (FGFR), which is a transmembrane tyrosine kinase receptor (McKeehan et al., 1998). Further research has shown that a combination of angiogenic factors such as VEGF or GF supplements containing FGF-1 can increase the

survival of both ECs and vascular network tremendously (Kwak et al., 1999). Cytokines, chemokines and angiogenic enzymes activate a wide array of target cells besides ECs. FGFs (mainly FGF1 and FGF-2) are the most well known molecules of this group inducing cell migration, proliferation and differentiation. Studies have shown that FGF-2 can induce tube formation in collagen gels and modulate integrin expressions, gap junctions and intercellular communications (Bussolino et al., 1996). FGFs are implicated in the progression of OA (Daouti et al., 2005). FGF-8 was shown to be produced by injured synovium and degradation of ECM was enhanced by FGF-8 (Uchii et al., 2008). FGF-8 may therefore be involved in cartilage damage and exacerbation of OA. FGF-2 has various physiological effects on bone and cartilage metabolism (Chuma et al., 2004), it is chondroprotective (Khan et al., 2010).

1.5.3. Role of Chondrocytes in Angiogenesis

The regulation of matrix turnover and angiogenesis also converge in articular cartilage. Normal mature non-calcified articular cartilage is devoid of blood vessels. Articular cartilage is normally hostile to vascular invasion, probably because of its matrix composition, and the generation of anti-angiogenic factors by articular chondrocytes (Smith et al., 2003). These include troponin-1 (Moses et al., 1999) and chondromodulin-1 (Shukunami et al., 2005) amongst others such as metalloprotease inhibitors. By contrast, chondrocytes may alternatively induce vascular invasion of articular cartilage. Indeed, this is a prerequisite for endochondral ossification. In physiological endochondral ossification during long bone growth, differentiated chondrocytes proceed stepwise to become hypertrophic chondrocytes, eventually undergoing apoptosis, leaving behind a cartilage matrix that is mineralised and replaced by new bone. Osteophyte formation at chondro-synovial junctions, and advancement of the subchondral bone into articular cartilage, both characteristic features of OA, each proceed through a process of endochondral ossification (Moskowitz et al., 1987).

Pharmacological inhibition of angiogenesis prevents endochondral ossification at the growth plate, leading to a widening of the cartilaginous growth plate in growing rodents. Similarly, angiogenesis inhibitors prevent new bone formation at the chondro-synovial junction in rodents subjected to experimental arthritis (Hashimoto et al., 2002). Angiogenesis may also contribute to osteophyte formation by facilitating inflammation. TGF- β 1 and bone morphogenic protein (BMP)-2, amongst the growth factors that are produced by macrophages (Bakker et al., 2001), contribute to osteophyte formation by enhancing chondro- and osteogenesis (Zoricic et al., 2003; van Lent et al., 2004). Blood vessels from the subchondral bone penetrate into the calcified articular cartilage, and grow into the non-calcified cartilage in OA. As vessels invade, new bone is formed as cuffs around the vascular channels, constituting an advancing wave of ossification into the osteoarthritic cartilage. Altering the balance between inhibition and stimulation of angiogenesis therefore has the potential to retard pathological new bone formation in OA.

Convergence of molecular pathways that regulate chondrocyte function, angiogenesis and inflammation emphasises their interdependence in OA pathogenesis, but compromises conclusions about the specific contribution made by blood vessel growth. This is amply illustrated by VEGF. Originally thought to be a specific modulator of EC function, albeit causing plasma extravasation as well as angiogenesis, VEGF is now known also to have important effects on articular chondrocytes. Evidence of efficacy of VEGF receptor inhibition in animal models of arthritis is consistent with, but does not prove, a contribution of angiogenesis to their aetiology.

1.5.4 Involvement of Angiogenesis in OA

During OA, a number of changes can be observed in the joints such as cartilage loss, osteophyte formation and synovitis, varying degrees of angiogenesis contributes to each of these features.

The vasculature of normal joints is highly organised, with the synovium being vascular in order to supply the avascular hyaline articular cartilage with oxygen and nutrients. Study using the chick embryo chorio-allantoic membrane (CAM) shows that osteoarthritic hyaline cartilage loses its ability to remain avascular when placed onto active chick CAM vasculature (Fenwick et al., 1999). It is thought that the actions of anti-angiogenic molecules synthesised and released by chondrocytes inhibit the vascularisation of the hyaline articular cartilage and prevent endochondral ossification (Haywood et al., 2001). Blood vessels penetrate the outer portion of the normal human meniscus, reaching as far as its middle third, with the innermost portion remaining avascular (Wilson et al., 1969; Day et al., 1985). This property of the cartilage ensures that its mechanical performance is maintained.

The ability of a joint to regulate its blood flow is diminished by the occurrence of synovitis and increased levels of synovial fluid volume associated with joint disease. Studies have indicated that angiogenesis is observed more profoundly near the synovial surface of patients with OA (Walsh et al., 2007). Angiogenesis is a key component of chronic inflammation, the two are closely linked, supported by in-vivo studies showing that synovitis is inhibited by agents that inhibit angiogenesis (Storgard et al., 1999). Inflammatory tissue is often hypoxic which leads to angiogenesis via the regulation of factors like VEGF and FGF-1 (Walsh et al., 2001). Inflammatory cells such as macrophages and mast cells (found in chronically inflamed OA synovium), can directly or indirectly produce angiogenic factors that can stimulate vessel growth in OA.

Invasion of blood vessels across osteochondral junctions is implicated in contributing towards articular cartilage changes in OA. Blood vessels invade into calcified cartilage from the underlying subchondral bone within fibrovascular channels (Bonnet et al., 2005; Suri et al., 2007). Angiogenesis has also been demonstrated in association with degeneration in the fibrocartilage of the intervertebral disc (Kauppila 1995). Angiogenesis is thought to facilitate the progression of OA by development of osteophytes,

endochondral ossification, advancing of subchondral plate and the remodelling of the joint (Brown et al., 1988). Subchondral bone has been identified as a potential source of pain in OA. Subchondral bone changes have long been recognised in early disease leading to speculation that these, rather than cartilage changes, may be of primary aetiological importance.

Bone marrow lesions (BML), initially described as bone marrow oedema (BME) were first identified in association with trauma and injury (Eustace et al., 2001). They are commonly defined as regions of abnormal MRI signals that histologically represent necrosis, fibrosis, bleeding and/or oedema (BME) (Zanetti et al., 2000). BML are characterised by MRI as hyperintense signalling regions on T2 weighted images consistent with increased water content, and exhibit increased signal after gadolinium diethylenetriamine pentaacetic acid (Gd-DTPA) injection, indicating increased vascularity (Hawighorst et al., 1999). At least some of these changes associated with BML have long been recognised by histopathologists as replacement of the normal subchondral marrow by fibrovascular granulation tissue. Angiogenesis is an important component of subchondral fibrovascular marrow replacement in both human and experimental OA (Mapp et al., 2008). This tissue is continuous with the vascular channels which breach the tide mark to invade the articular cartilage in OA. BML are positively associated with knee pain, increased cartilage defect score and OA progression as measured by joint space narrowing, suggesting an importance in both symptoms and structural damage in OA (Hunter et al., 2005; Hunter et al., 2006). Elucidating the contribution of angiogenesis to this potentially pivotal process in the development of symptoms and structural damage in OA raises hope of novel and targeted therapeutic approaches for the future as angiogenesis is an essential part of OA pathophysiology.

1.5.5 Angiogenesis and Pain

The contribution of angiogenesis to pain is still not fully understood. Although not of itself necessarily painful, angiogenesis, by enabling innervation of tissues, may be permissive, and may synergise with inflammation to exacerbate pain (Bonnet et al., 2005).

In OA blood vessels invade the calcified region of the otherwise avascular and aneural articular cartilage from the underlying subchondral bone and penetrate newly formed cartilage at the joint margin during osteophyte formation (Hashimoto et al., 2002). Vascular turnover is even more pronounced in the inflamed osteoarthritic synovium. Sensory nerves accompany this neovascularisation in all these structures (Walsh et al., 1996). These fine, unmyelinated, peptide-containing nerve terminals typically mediate a sustained burning pain commonly described by patients with OA (Wagstaff et al., 1985). Perivascular sensory nerves may contribute to pain in OA, originating in articular cartilage, periosteum, menisci, cruciate and collateral ligaments and in joints capsules (Suri et al., 2007). Subchondral angiogenesis and innervation may be particularly important where the protective layer of articular cartilage is lost, consistent with observed associations between the extent of cartilage loss determined arthroscopically and reported pain

severity. Compressive forces and hypoxia may activate growing perivascular nerves even before complete cartilage loss. Sensory innervation of osteophytes following angiogenesis may, in part, explain the association between radiologically graded osteophyte severity and reported pain in OA (Neame et al., 2003).

Unmyelinated sensory nerves can also amplify the inflammatory response by releasing vasoactive substances (neuropeptides) (Neugebauer et al., 1995), such as substance-P and CGRP. These peptides also can initiate angiogenesis, as can peptides from accompanying sympathetic nerves such as neuropeptide Y (Zukowska-Grojec 1998). Substance P and CGRP act on specific cell surface receptors localised on blood vessels thereby enhancing EC proliferation, migration and capillary tube formation in-vitro (Haegerstrand et al., 1990; Kahler et al., 1993) and angiogenesis in-vivo (Lee et al., 2003).

Substance P release during neurogenic inflammation enhances plasma extravasation and enables EC proliferation through neurokinin NK₁ receptors. In animal models of synovitis, substance P, either exogenously applied or released from an endogenous source, can stimulate synovial angiogenesis through NK₁ receptors during the early stages of synovitis, and selective NK₁ receptor antagonists can inhibit this angiogenesis (Seegers et al., 2003; Seegers et al., 2004). Endogenously released substance P can therefore contribute towards the early stages of angiogenesis in acute inflammation, and neuropeptides interact with other acute inflammogens such as bradykinin under these circumstances.

1.5.6 PPI-2458, an inhibitor of Angiogenesis

Angiogenesis inhibitors have currently been under continuous focus due to their immense potential as therapeutic agents. Increasing number of anti-angiogenic compounds (synthetically created; PPI-2458 and naturally occurring; angiostatin and endostatin) have been identified over the years with a specific focus on inhibiting an individual step of angiogenesis. As each step in the angiogenic cascade involves a great variety of enzymes, cytokines and receptors, numerous possible targets for therapeutic intervention are available. These compounds have targeted the inhibition of ECM remodelling, adhesion molecules, activated ECs, angiogenic mediators or their receptors and EC intracellular signalling (Liekens et al., 2001). Most of these have been studied in relation to their applicability in cancer therapy and chronic inflammatory conditions.

Development of novel therapies to manipulate angiogenesis offers a great approach to relieve the symptoms and severity of OA. These therapeutic agents need to specifically target the mechanism of harmful angiogenesis whilst causing minimal adverse effects. Therefore drugs that broadly inhibit inflammation or angiogenesis may have limited applicability in OA. Anti-angiogenic therapy for inflammatory diseases has numerous advantages. It suppresses blood vessel growth leading to reduced nutrient supply to the metabolically active cells present in the inflamed tissue. It blocks the entry route of

inflammatory cells into the tissues, inhibits EC activation, proliferation and vascular remodelling in chronically inflamed lesions thereby inhibiting the production of EC-derived soluble factors such as MMPs and cytokines. Application of anti-angiogenic strategies will also allow us to study in more detail the functional role of angiogenesis during inflammatory conditions thereby increasing our knowledge related to OA pathophysiology.

Methionine aminopeptidase (MetAP) are metalloenzymes required to remove N-terminal methionine residue from proteins at the initial phase of translation. The translation process on ribosomes is initiated with methionine, and the N-terminal methionine is usually removed before the newly synthesised protein is intracellularly transported. The removal of the N-terminal methionine residues, leads to the exposure of a glycine residue onto which myristic acid is attached covalently (myristylation). This process is required for the stability and correct functioning of numerous signalling molecules (Lowther et al., 2000). Two types of MetAP have been identified, MetAP-1 and MetAP-2. MetAP-2 is distinguished from MetAP-1 by the addition of a helical subdomain inserted into the C terminal. MetAP-2 is expressed in proliferating cells such as endothelium, at the site of neo-vascularisation or B cells in the germinal centres (Priest et al., 2009).

Fumagillin and structural analogs such as TNP-470 (previously known as AGM-1470) irreversibly inhibit MetAP-2 (an enzyme that selectively removes initiating N-terminal methionine residues from proteins during synthesis) (Griffith et al., 1997; Sin et al., 1997; Bernier et al., 2004). These molecules inhibit angiogenesis by blocking EC proliferation and migration (Ingber et al., 1990). Studies using in-vivo models of arthritis have shown that administration of TNP-470 before the onset of arthritis prevents disease (Peacock et al., 1992). Adverse neurotoxicity however has been reported with the use of TNP-470. Therefore less toxic MetAP-2 inhibitors are needed, of which, PPI-2458 is a strong candidate.

PPI-2458 [(1R)-1-carbamoyl-2-methyl]-carbamic acid-(3R, 3S, 5S, 6R)-5-methoxy-4-[(2R, 3R)-2-methyl-3-(3-methyl-but-2-enyl)oxiranyl]-1-oxaspiro(2*5)oct-6-yl ester], a orally active, novel fumagillin derivative that irreversibly forms covalent bonds with MetAP-2 and inhibits EC proliferation at the late G₁ phase of the cell cycle, a crucial step in angiogenesis (Bernier et al., 2005). PPI-2458 has shown not to have any direct effects on inflammatory cytokines and chemokines, but how MetAP-2-dependent proliferation is regulated in PPI-2458-sensitive cells is yet to be fully understood (Bernier et al., 2004; Brahn et al., 2009). However it is this direct angiogenic effect of PPI-2458 which distinguishes it from other agents used to treat arthritis whose actions are directed at the proinflammatory cytokine network. PPI-2458 has been shown to inhibit swelling in peptidoglycan-polysaccharide (PG-PS) induced arthritis (Bernier et al., 2004; Hannig et al., 2007) and to regress collagen-induced arthritis (CIA) in both rat and mice models (Bainbridge et al., 2007; Brahn et al., 2009), indicating that angiogenesis might be an important target in treatment of arthritis. PPI-2458 has fewer toxic side-effects compared with its parent

molecule TNP-470 (Figure 1.7). PPI-2458 is under development for the treatment of cancer, including B cell non-Hodgkin's lymphoma (phase 1) and arthritis (Cooper et al., 2006; Hannig et al., 2006; Priest et al., 2009).

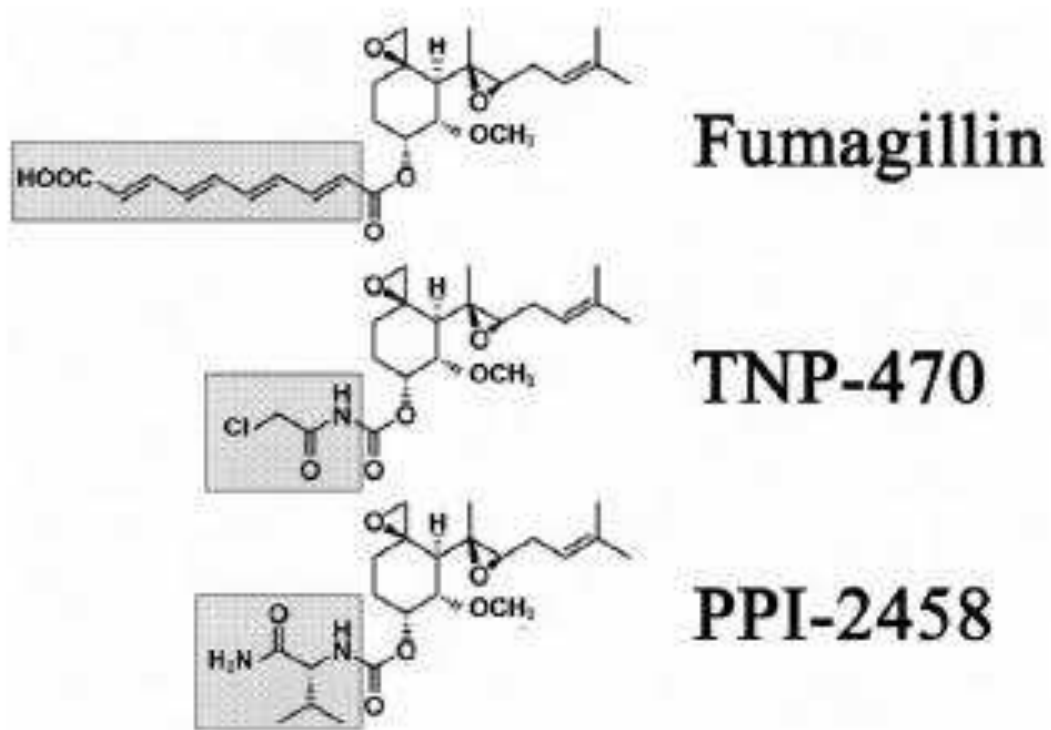


Figure 1.7: Structure of parent molecule, fumagillin and modification of side chains (box) for TNP-470 and PPI-2458 (Bernier et al., 2004; Brahn et al., 2009).

1.6 Inflammation and Osteoarthritis

Inflammation is a protective pattern of response controlling tissue damage occurring as a result of pathogenic, traumatic or toxic injury. The inflammatory process is governed by both pro- and anti-inflammatory molecules requiring distinct cell types and various factors which act in a co-ordinated manner to regulate cell chemotaxis, migration and proliferation leading to tissue repair (Benelli et al., 2006).

Under normal physiological conditions inflammation is tightly regulated to maintain homeostasis which is achieved by the actions of soluble proteins (cytokines and growth factors) acting between inflammatory cells, fibroblasts and vascular ECs within the affected site. When inflammation is not properly regulated the balance is shifted away from the initiation of the healing process and towards the occurrence of persisting inflammation (Charo et al., 2006). Thus the initiation and the control of inflammation are crucial elements. Inflammation can be classified as either acute or chronic.

1.6.1 Acute Inflammation

This is the initial response to cellular injury characterised by its sudden onset. The series of events involved in acute inflammation are coagulation, increased blood flow and vascular permeability at the affected site as a result of the dilatation of arterioles, capillaries and venules, oedema, localised pain, migration and accumulation of inflammatory cells and the formation of granulation tissues, all contributing to tissue repair. Hence the classical symptoms observed in inflammation are redness, swelling, heat and pain which occur within minutes of tissue trauma (Dallegrì et al., 1997).

The initial step in acute inflammation is to contain the blood flow and repair the damaged blood vessels. This is done by activating the blood clotting system which eventually leads to the release of inflammatory mediators that control the vascular response, causing changes in permeability, blood flow and adhesiveness.

Movement of cells and tissues is important in diluting toxic factors at the sites of trauma/infection and also to allow the influence of proteins which promote anti-bacterial activity.

ECs are an active part of the inflammatory response. They expose adhesion molecules on their surface after receiving stimulatory signals from pro-inflammatory cytokines and aid the movement of leukocytes (neutrophils) in the inflamed tissue. This is an essential mechanism for the destruction of microbial agents and removal of tissue debris by phagocytosis, representing a key step in the resolution of inflammation (Wahl et al., 1996).

Following clearance of the pathogens it is necessary to suppress the inflammatory response (infectious stimulus is eliminated and acute inflammatory response fades) and enhance tissue repair. If an acute response fails to resolve the cellular injury, it leads to chronic inflammation.

1.6.2 Chronic Inflammation

Chronic inflammation results from a persisting irritant that fails to be eliminated during the acute inflammatory response. It can also be caused by autoimmune response to self antigens or due to an innately chronic irritant of low intensity which does not evoke a significant acute inflammatory reaction. In this process the continuous inflammation and attempted tissue healing by repair occur simultaneously rather than consecutively.

It is characterised by the recruitment of a large number of macrophages which lead to a less pronounced exudative response and increased inflammatory cellular recruitment and proliferation compared to the acute inflammatory response. Different profiles of the inflammatory mediators and GFs are released depending on the nature of the pathogens encountered, giving rise to different morphological patterns of chronic inflammation. Systemic effects however are more pronounced and contribute towards clinical consequences.

Chronic inflammatory conditions have been found to mediate numerous diseases including psoriasis, diabetes, atherosclerosis, Alzheimer's, rheumatoid arthritis (RA), OA, ocular disorders, Crohn's disease and cancer (Costa et al., 2007).

1.6.3 Inflammatory Process

When blood vessels are damaged during tissue trauma, clotting enables the containment of blood flow. Platelets release coagulation factors (essential in haemostasis) and leukocyte recruitment factors (facilitate the rapid influx of leukocytes and GFs to the affected site) so that the healing process can commence, a part of this healing process is inflammation.

Inflammation includes a complex network of chemical signals and cell interactions that instruct and maintain the host response against tissue damage. These include allergic, cytotoxic antibody mediated, immune complex mediated and delayed hypersensitivity responses. Usually immune complexes eliminate antigens without producing any detectable inflammation (governed by a balance between pro-inflammatory and anti-inflammatory factors) but if the inciting agent is too difficult to remove, it will produce amplified effects.

The cells that are initially activated during this process are leukocytes, neutrophils and eosinophils (Charo et al., 2004). Leukocytes are normally restricted to the centre of the blood vessels but as a result of

inflammation they interact with the vascular endothelium. Once in damaged tissues, leukocytes proceed to remove the injurious agents and initiate tissue repair. Changes in the adhesion molecules on ECs and leukocytes enable a large number of circulating leukocytes and neutrophils to be further recruited. Neutrophils are the earliest phagocytic cells to be recruited, they engulf and destroy debris, dead and dying tissues, they are able to phagocytose many pathogens. As inflammation progresses even monocytes contribute towards its actions.

Monocytes migrate to the inflamed areas guided by chemotactic signals (Philip et al., 2004) where they differentiate into dendritic cells (DC) and macrophages. Macrophages in turn provide GFs (PDGF, FGF, TGF β) and cytokines that engage numerous responses in distinct cell types including ECs, epithelial cells and cells of mesenchymal origin at the inflamed region (Costa et al., 2007). Macrophages and mast cells release cytokines that result in tissue remodelling and recruitment of additional leukocytes. They help lymphocytes to proliferate, further enabling cytokine production and orchestration of tissue repair through their release of fibroblast recruitment, growth and matrix inducing molecules.

DCs then capture antigens, mature and eventually migrate to lymph nodes stimulating adaptive immune cells. DCs are further activated by natural killer (NK) cells which interlink innate and adaptive immunity, in response to this, B cells, CD4⁺T cells and CD8⁺T cells are attracted to a specific antigen and clonally expanded to elicit a large immune response (de Visser et al., 2006) thereby eliminating the pathogen. This result in the increased vascular permeability, blood flow and vascular adhesiveness observed during inflammation.

Mast cells are also involved in the early steps of the inflammatory process, they release cytokines, histamine, proteases and eicosanoids (Coussens et al., 2002) which also mediate vasodilatation and fluid extravasation promoting endothelial adhesion and further recruitment of inflammatory cells (Nathan 2002).

Eosinophils are not normally associated with inflammation; they are not as sufficient as neutrophils in phagocytosis. Eosinophils are mainly involved in the destruction of organisms that are too large to be phagocytosed efficiently.

Pro-inflammatory cytokines and chemokines including interleukins, TNF- α and IFNs are also released by several cell types at the inflamed sites, they bind and activate G-protein coupled receptors on immune cells (Charo et al., 2004; Charo et al., 2006) stimulating signalling transduction cascades within the cells, inducing changes in cell morphology and migration.

Hence the immunological mediated elimination of foreign material is the result of antigen recognition by specific mechanisms (antibodies) or non-specific mechanisms (phagocytes). This activates an

amplification cascade, producing pro-inflammatory substances resulting in altered blood flow, increased vascular permeability, augmenting the adherence of circulating leukocytes to vascular endothelium, promoting the migration of leukocytes into tissues and stimulating the leukocytes to destroy the inciting agent.

1.6.4 Involvement of Inflammation in OA

Inflammation is increasingly thought to enhance structural severity in OA, whether it is the bio-chemical changes within the cartilage and the release of the cartilage breakdown products in the synovial fluid (Attur et al., 2002) or the subchondral bone changes. Acute flares are proposed to occur on the background of chronic synovitis or in non-inflamed joints leading to elimination of the irritant followed by resolution to the original state (Bonnet et al., 2005).

In osteoarthritic synovium, the inflammatory changes that are observed include synovial hypertrophy and hyperplasia with the sublining tissue being infiltrated with a mixed population of inflammatory cells (Pelletier et al., 2001). Synovitis contributes towards dysregulation of chondrocyte function in remodelling the cartilage ECM (Loeser 2006). Chondrocytes obtained from patients with OA have been shown to produce pro-inflammatory mediators and are thought to act in the cartilage in an autocrine or paracrine manner to promote a catabolic state which leads to a progressive cartilage damage in OA (Attur et al., 1998).

Various researchers have implicated T cells in producing pro-inflammatory cytokines and MMPs within the inflamed synovial membranes (McInnes et al., 2000) as well as increased mononuclear cell infiltrates and over expression of mediators of inflammation in early OA (Benito et al., 2005).

Considerable amounts of evidence involving in-vitro and in-vivo studies support the view that a link exists between increased levels of catabolic enzymes and inflammatory mediators in OA synovial fluid and joint tissue (Goldring et al., 2007).

Mechanical forces in OA may also produce metabolic changes that result in cytokine production by the synovium (Abramson 2004). Persisting mechanical stress results in inflammation, as cartilage is not vascularised or innervated, joint swelling or pain may not be observed, but a host of mediators normally seen in inflammatory arthritis are produced and act in a paracrine and autocrine manner to endow the chondrocytes with a catabolic phenotype. Prostaglandins (PG) are one of the key mediators of inflammation; these mediators can be produced by synovial cells and the chondrocytes themselves.

A number of biological markers are believed to be associated with synovitis in OA, such as cartilage oligomeric protein (COMP), serum level of C reactive protein (CRP) and hyaluronic acid (HA). COMP is

found in the articular cartilage during increased levels of synovitis. CRP is predictive of radiographic progression of long term knee OA whereas HA levels have shown to increase in OA (Thonar et al., 1995). These markers are elevated in OA, indicating the presence of subclinical inflammation in the absence of acute inflammatory flares. Excessive production of cytokines and GF by the inflamed synovium and activated chondrocytes functionally alter the synovium, cartilage and subchondral bone (Pelletier et al., 2001). They appear to be first produced by the synovial lining and then they diffuse into the cartilage through the synovial fluid. Here they act in an autocrine/paracrine fashion (Goldring et al., 2007) activating chondrocytes that in turn display enhanced and co-ordinated expression of proteases and their catabolic factors such as NO and pro-inflammatory cytokines that are further responsible for cartilage destruction, chondrocyte apoptosis and other structural changes associated with the disease process (Pelletier et al., 2001).

Pro-inflammatory cytokines contribute towards cartilage destruction (Shalom-Barak et al., 1998; Olee et al., 1999; Goldring et al., 2007). Studies in animal models have shown that cartilage destruction is mainly driven by the actions of IL1 whereas TNF α is involved in the onset of arthritis (Goldring et al., 2004). Human articular chondrocytes when stimulated by IL1 increase the expression of MMP but inhibit the biosynthesis of cartilage PG and collagens (Tetlow et al., 2001). Chronic synovitis is also associated with the changes in the synthesis and release of neurotransmitters and modulators (Bonnet et al., 2005).

In the inflamed synovium fibroblasts and blood vessels proliferate, macrophages are recruited and there is an increased cellular apoptosis. Inflammatory mediators stimulate sensory nerves causing pain in the joint. Fine unmyelinated sensory nerves containing neuropeptides like substance P and CGRP have been localised in the joint. Inflammation exacerbates cartilage degradation in OA (Bonnet et al., 2005). Under normal circumstances, if damaged matrix proteins were removed, the proteolytic process would be turned off and chondrocytes would work to replace the lost matrix, however in OA this phase of matrix remodelling is insufficient or defective. Abnormal mechanical forces stimulate the chondrocytes to produce a host of inflammatory mediators many of which are normally produced by macrophages during response to injury and infection increasing the catabolic activity of the chondrocytes, resulting in the release of proteolytic enzymes including aggrecanase and MMPs that cause the destruction of the cartilage matrix (Lisignoli et al., 1999). Fundamental events resulting in the destruction of articular cartilage in OA arises from the imbalance between the anabolic and catabolic pathways (Hedbom et al., 2002). Increased catabolism of cartilage ECM is the main pathologic process leading to the degeneration of articular cartilage in OA (Tetlow et al., 2001).

1.6.5 Synovial Macrophages and Inflammation in OA

Activated synovial macrophages are important mediators of synovitis and promoting OA pathology. Clinically, patients with OA have a variable degree of synovitis. Synovial inflammation has been

implicated in many of the signs and symptoms of OA including joint swelling and effusion (Pelletier et al., 2001). Inflammation is likely to contribute to disease progression because a strong association between biological markers of inflammation such as C-reactive protein and cartilage oligomeric matrix protein with structural damage in OA exists (Clark et al., 1999; Sowers et al., 2002). Histologically OA synovium shows hyperplasia, with increased lining cells, and mixed inflammatory infiltrate mainly consisting of macrophages (Farahat et al., 1993; Benito et al., 2005). In-vitro studies have indicated that macrophages drive the production of several pro-inflammatory cytokines (IL-1, IL-6, IL-8, TNF- α) and MMPs (Bondeson et al., 2006). As well as being involved in synovial inflammation, TNF- α and IL-1 can activate chondrocytes and synovial fibroblasts, stimulate their own production, induce synovial cells and chondrocytes to produce IL-6, IL-8 and leukocyte inhibitory factor (LIF) and stimulate protease and prostaglandin production (Goldring et al., 2007; Bondeson et al., 2010). In-vivo studies where synovial lining macrophages were depleted have shown that, macrophage depletion was linked to fibrosis and osteophyte formation (van der Kraan et al., 1990; Blom et al., 2004; van Lent et al., 2004). Therefore, synovial macrophages exhibit an activated phenotype in OA. Anti-macrophage strategies to reduce OA seem to be an attractive avenue to explore, but if such strategies need to be feasible, they need to act locally in the synovium only, because macrophages are key players in protecting tissues against infectious diseases and such strategies can also inhibit the “wanted” positive effects of macrophages.

1.6.6 Anti-inflammatory Therapy

Targeting inflammation is an attractive possibility in OA. It has the potential to retard disease progression and relieve symptoms of pain and stiffness. Currently available NSAIDs are the most commonly used treatment in OA, reducing the symptoms observed in OA without halting disease progression. The selective COX-2 inhibitors exhibit analgesic and anti-inflammatory effects equivalent or even superior to conventional NSAIDs. Indomethacin is the most well studied conventional NSAID. Intra-articular injections of corticosteroids (dexamethasone) provide an easy and cost effective pain relief strategy with minimal risk. Hence newer DMOADs which specifically target the pathophysiological processes in OA offer better disease management. Inhibiting proinflammatory cytokines which play a pivotal role in OA progression is an attractive possibility (Pelletier et al., 2001). Clinical studies using anti-TNF antibody infliximab (Magnano et al., 2007; Fioravanti et al., 2009) and anakinra (recombinant IL-1Ra) (Chevalier et al., 2005; Goupille et al., 2007) showed significant symptomatic relief in patients with OA. Steroidal and non-steroidal anti-inflammatory drugs are however not without their side-effects. Their long-term use is associated with diverse effects such as peptic ulcers, myopathy, oedema, hyperkalemia, hypernatremia and hypertension. The greatest therapeutic finding will be targeting those inflammatory processes that are disease specific because drugs that broadly inhibit such important biological processes can have detrimental side-effects.

1.7 Inflammation, Angiogenesis, Structural damage and Pain in Osteoarthritis

Chronic inflammation and angiogenesis are two interlinked processes where angiogenesis can occur in the absence of inflammation but chronic inflammation however always accompanies angiogenesis (Bonnet et al., 2005). It is thought that angiogenesis does not initiate inflammation but rather perpetuates or potentiates it by supplying nutrients and oxygen to the cells present in the inflamed synovium (Costa et al., 2007), and also the increase in vascular density, macrophage infiltration and VEGF expression within the synovium regulate the extent of EC proliferation. Thereby highlighting that neovascularisation could be largely driven by synovitis.

Angiogenesis itself can be stimulated directly or indirectly by inflammatory mediators, it is closely associated with chronic synovitis. A considerable body of evidence suggests that this co-dependence involves the augmentation of cellular infiltration and proliferation as well as the overlapping roles of regulatory growth factors and cytokines (Jackson et al., 1997).

Macrophages are abundantly present in chronically inflamed osteoarthritic synovium producing inflammatory mediators and increasing the production of growth factors enabling new blood vessel formation. Hypoxia is viewed as a common stimulus for both angiogenesis and inflammation (Murdoch et al., 2005). It occurs when tissue proliferation outstrips blood vessel growth, inducing macrophages and monocytes to release a large quantity of angiogenic factors (including VEGF and FGF2) which can induce blood vessel growth (Nathan 2002). Normally vascular synovium provides the avascular cartilage with nutrients and oxygen. In OA the association between EC proliferation and new vessel formation leads to an increase in EC surface area creating an enormous capacity for the production of cytokines, adhesion molecules and other inflammatory stimuli (Jackson et al., 1997). It is proposed that VEGF and FGF-2 may also be produced by lymphocytes and neutrophils in the early induction of angiogenesis (Bonnet et al., 2005) however their exact involvement is still under investigation. Many inflammatory mediators are also angiogenic (Form et al., 1983). These findings are mainly based on research carried out using Cornea and Chicken CAM Assays.

The interplay between chronic inflammation and angiogenesis is accomplished by the activation of iNOS which leads to NO production from inflammatory cells (macrophages) and endothelium, thereby stimulating vessel dilatation and permeability to macromolecules facilitating oedema formation and immune cell extravasation (Morbideilli et al., 1996). Adhesion of immune cells to endothelium is a crucial step in activating neighboring EC to attract blood derived inflammatory cells. Adhesion molecules such as E-selectin are highly expressed by new vessels and facilitate inflammatory cell infiltration (Cid et al., 2000). Inflammatory mediators produced by immune cells can target fibroblasts and ECs to release angiogenic factors and can themselves release angiogenic factors (VEGF and FGF-2) (Ziche et al., 1997).

Inflammatory response on the other hand can be maintained by new vessels transporting inflammatory cells, nutrients and oxygen to the site of inflammation.

Recent findings show that angiogenesis and inflammation rely on cross talk between NF κ B and Ang-Tie 2 signaling pathways (Pacifico et al., 2006). Ang-2 has both an angiogenic role and is also involved in upregulating pro-inflammatory cells (Fiedler et al., 2006).

It has also been postulated that neuropeptides such as substance-P and CGRP enhance EC proliferation, migration and capillary tube formation in-vitro and angiogenesis in-vivo (Bonnet et al., 2005), it has been revealed that endogenously released Substance P contributes to early stages of angiogenesis in capsaicin and carrageenan induced synovitis (Walsh et al., 1998).

Hence inflammatory cells that are abundant in the inflamed OA synovium can induce angiogenesis directly by producing angiogenic factors and/or by secreting cytokines that indirectly stimulate ECs and fibroblasts to release angiogenic factors, which in turn contribute to neovascularisation and inflammation by inducing immune cell mobilization. Expression of angiogenic factors is further enhanced by the hypoxic conditions that are evident in OA.

Angiogenesis and inflammation are important processes in OA pathophysiology, both are interlinked; evidence in the literature has demonstrated that they are upheld by the same stimuli. We need to further understand their cross-talk and intricate interplay to develop effective therapies.

Even-though it is not fully understood as to how angiogenesis contributes to pain in OA, it is however recognized that it may synergise with inflammation to exacerbate pain (Bonnet et al., 2005). In OA blood vessels invade the calcified region of the otherwise avascular and aneural articular cartilage from the underlying subchondral bone, breaching the tidemark and penetrating newly formed cartilage at the joint margins during osteophyte formation (Hashimoto et al., 2002). Sensory nerves have been shown to accompany neovascularisation occurring in OA (Walsh et al., 1996) and are implicated in mediating the sustained burning pain sensation described by patients suffering with OA (Wagstaff et al., 1985). Pain in OA can originate from periosteum, subchondral bone, synovium, ligaments and muscles (Suri et al., 2007). A current study shows that perivascular localisation of nerve; sensory and sympathetic, in articular cartilage contributes to tibiofemoral pain in OA (Suri et al., 2007). Implying that vascularisation is the driving force behind innervation. Compressive forces and hypoxia are also thought to stimulate these new nerves to release neuropeptides in a temporally and spatially regulated manner, contributing towards persistent pain and structural damage in OA.

Unmyelinated sensory nerves can also amplify the inflammatory response by releasing vasoactive substances (neuropeptides) (Neugebauer et al., 1995), such as substance-P and CGRP. These peptides can also initiate angiogenesis, as can peptides (neuropeptide Y) from accompanying sympathetic nerves (Zukowska-Grojec 1998).

Substance P and CGRP are thought to act on specific cell surface receptors localised on blood vessels thereby enhancing EC proliferation, migration and capillary tube formation in-vitro (Haegerstrand et al., 1990; Kahler et al., 1993) and angiogenesis in-vivo (Lee et al., 2003).

Substance P release during neurogenic inflammation enhances plasma extravasation through the interaction with neurokinin NK₁ class G protein coupled receptor and enables EC proliferation. Fairly recent studies (Seegers et al., 2003; Seegers et al., 2004) using in-vivo models of synovitis highlighted that substance P either exogenously applied or released from an endogenous source can stimulate synovial angiogenesis through an action on NK₁ and bradykinin B₂ receptors during the early stages of synovitis, selective NK₁ and bradykinin B₂ receptor antagonists can inhibit this angiogenesis. Hence, inflammation, angiogenesis and accompanied nerve growth can all enhance the structural damage seen in OA.

1.8 Animal models of Osteoarthritis

A major problem encountered in OA research is that the disease is not presented in clinics and diagnosed until it has progressed to its advanced stages when pronounced alterations in the joint have led to radiographically detectable changes and severe pain. Pain is the main symptom that brings patients suffering from OA to clinics. Studying the early mechanisms of OA in humans is extremely difficult partially due to the low sensitivity of the diagnostic tools used and the low availability of the diseased tissue (Ameye et al., 2006). As a result, the underlying biochemical and molecular processes leading to the macroscopically and histologically visible alterations are still not completely understood. In-order to overcome this, a number of animal models of OA have been developed (Pond et al., 1973; Little et al., 1996) that exhibit changes similar to those observed in human OA, however no animal model fully mimics the normal pathogenesis of OA in humans. Thus controversy surrounds the issue regarding relating the data obtained from such animal models to human situations. Never-the-less the advantages of these models are that as well as knowing the time-point and causative of the joint damage, healthy cartilage can also be obtained from the same subject (Lorenz et al., 2006). Hence animal models complement human investigations to study in detail pathogenic hypotheses and therapeutic strategies.

There are numerous classical animal models of OA involving a number of animal species, rabbits, dogs, sheep and rodent (rats and mice) models of OA which were first developed in the late 1970s (Schwartz et al., 1979). Most recently cats and guinea pigs have also been used as research tools. OA in these animals can occur spontaneously with aging (Wilhelmi et al., 1976) but it can also be induced surgically to produce mechanical joint instability. Other chemical and enzymatic methods are also employed to induce OA, whereas more recently genetically modified; transgenic or knockout animals have come under the limelight too (Goldring et al., 2007).

Spontaneous/naturally occurring models of OA (Dunkin-Hartley guinea pig, STR/ort and STR/1N mouse strains) are more like human OA with slower onset and progression. Osteoarthritic pathology (synovitis, chondropathy, osteophytosis, subchondral bone changes and pain) is seen in these animals by 6 months (Bendele et al., 1989; Blaney Davidson et al., 2006). Like human OA, these models are not very sensitive when identifying the initiating events but they however are viewed as effective screening models despite being time consuming.

Chemically induced models of OA, where induction of OA is achieved by injection of a noxious substance cause joint pathology through inhibition of chondrocyte metabolism (papain and monosodium-iodoacetate [MIA]) and damage to ligaments and tendons (collagenase) (van der Kraan et al., 1990; Fernihough et al., 2004). The MIA model has emerged as a good model to study osteoarthritic pain and the effects of analgesic drugs because it is reproducible and mimics pathological changes and experience of pain as seen in human OA. Intra-articular injection of MIA produces progressive joint degeneration through inhibition

of glycolysis and subsequent chondrocyte death that develops over several weeks. Similar to human OA, joint pathology is characterised by chondrocyte necrosis resulting in decreased thickness of the articular cartilage and fibrillation of the cartilage surface, exposure of the underlying subchondral bone, swelling and reduction in bone mineral content and density (Kobayashi et al., 2003). However, since iodoacetate is a metabolic poison, chondrocyte cell death in the model is extensive, unlike that observed in human OA.

Genetically modified animals (knock out or transgenic mice) are a major tool to investigate genetic predispositions/contributions to OA. They are well defined and allow insight into mechanisms of tissue formation and maintenance, matrix assembly, signalling proteins and molecular interactions in OA but their usefulness for the study of the pathophysiology of OA is debateable (Saamanen et al., 2000; Ameye et al., 2006; Dinser 2008). The genetic approach allows important insights into the multitude of factors affecting the pathogenesis of OA. However each model describes a distinct molecular entity making it difficult to study the effects of different treatment approaches. Longer time is needed for OA to develop in genetic models compared to surgical and enzymatic models that are faster and consistent but they are considered to be more relevant to the traumatic than classical forms of degenerative OA.

Surgical models (structural alteration to the tendons muscles or ligaments) of mechanical instability represent the chronic traumatic form of OA. Initially, experiments employed models in which OA was induced in the temporomandibular joint but with time these models were developed to involve other synovial joints, including the knee (Schwartz 1987). Mechanical instability can be induced using various surgical methods such as: Anterior Cruciate Ligament Transection (ACLT) and meniscectomy. ACLT was first used in dogs and the partial menisci resection model in rabbits (Bendele 2001) since then both of these procedures have been widely used in other species like mice, guinea pig, rats, and cats.

Substantial research has been conducted by numerous researchers on these animal models to fully understand the various aspects of OA. Some of the research has focused on the relationship between symptoms (pain) and bone morphology in OA (Bove et al., 2006; Vermeirsch et al., 2007), analysis of gene expression changes in animal models and their relevance in early human OA (Appleton et al., 2007; Dell'accio et al., 2008). Recently, it was shown that using a combination of ligament transection and meniscectomy in knees of mice, varying degrees of OA (mild, moderate, severe) with direction of instability (anterior versus medial) could be created (Kamekura et al., 2005). The researchers successfully showed the development of OA and osteophyte formation up to 8 weeks post surgery using a rapid, cheap and applicable model. To elucidate the understanding of the metabolism of cartilage and bone, knees of two rat models were subjected to ACLT and/or medial menisci resection (Hayami et al., 2006), results obtained from this study highlight the role for bone remodelling in OA pathogenesis. Research carried out using the rat and rabbit meniscal transection models (Mapp et al., 2008) has further clarified the role of osteochondral and synovial angiogenesis in human OA.

The above mentioned research collectively illustrates the popularity of these two methods of surgical intervention amongst scientists to induce OA in animal models. The disadvantage of the surgical models is that only knee damage can be studied and also use of smaller animals like mice is technically demanding.

Currently no consensus exists on the most relevant animal model of OA. However the diversity of animal models available provide a wealth of valuable information on joint biology and OA pathology, having said that each model has various advantages and disadvantages associated with its use.

The rate of disease progression between species of the same model has been seen to increase as size and lifespan of the animal is reduced, development of OA in different species thus varies. It has been reported that in animal models like dogs, cats and sheep their large size and the lack of availability of biochemical reagents to study the molecular dynamics in affected joints has reduced the usefulness of these models in evaluating potential disease modifying agents (Goldring et al., 2007). It takes 1 year for significant cartilage loss and osteophyte formation to be apparent in ACLT dogs and at least 3 years to display alteration to advanced OA (Lorenz et al., 2006) compared to rats and rabbits. Moderate OA has been observed in rabbits as early as 10 days after ACLT, severe OA developed by 2-4 months post surgery (Pfander et al., 1999), the follow-up however proves to be problematic because of the long time needed. Smaller animal like rats, mice and guinea pigs thus enable low cost studies to be carried out due to their small size and shorter time frame of OA development. As a result our current understanding of the metabolism of cartilage and bone in the larger models is limited.

Animals also display different patterns of joint loading, being quadrupeds as opposed to bipeds, joints are smaller and the cartilage in animals is thinner in contrast to humans, enabling only a small quantity of cartilage to be analysed. Therefore differences between animal models make comparison between various studies difficult; this in turn makes the extrapolation of animal data to humans slightly problematic. It is therefore essential to further conduct comparative studies to address the issue of whether it is possible to find a suitable single animal model or if the development and comprehensive characterisation of pre-clinical animal models is more feasible to further enhance our understanding on OA pathology and intervention mechanisms. It has been postulated that for future studies comparing the effects of structure modifying drugs on different animal models can perhaps clarify the response of these models to therapy, suitability as preclinical models (fast or slow disease progression models, species of choice etc.) and the relevance to human OA (Ameye et al., 2006). Overall animal studies have never-the-less provided new insights into OA pathogenesis despite their limitations.

1.9 Summary

OA is the commonest joint disease but is of unknown aetiology (Walsh 2004). It is the major cause of pain and disability in the ageing population (Walsh et al., 2007). Current therapeutic agents focus on symptomatic relief because pharmacological interventions that halt disease progression are not available (Daouti et al., 2005), and, although the clinical course of OA is highly variable, it too often progresses to total joint replacement surgery (Dixon et al., 2004). A greater understanding of early OA may help achieve the goal of disease modification.

OA is associated with articular cartilage loss, synovitis, fibrosis, subchondral bone remodelling and osteophyte formation. Angiogenesis, the growth of new blood vessels from old, may contribute to each of these features (Bonnet et al., 2005). Angiogenesis is highly regulated under normal conditions (Risau 1997) by various activating and inhibiting factors (Otrock et al., 2007), and is fundamental to many physiological events including embryogenesis, growth, wound healing and female reproductive cycle (Walsh 1999).

Pain, the main symptom of OA can originate from several sources (Dieppe et al., 2005). Hypoxia, compressive forces and inflammation have all been implicated in sensitising sensory nerves that grow alongside blood vessels in articular cartilage and osteophytes (Wagstaff et al., 1985). These sensitised nerves may reciprocally contribute to neurogenic inflammation and initiate new vessel growth.

Angiogenesis may therefore contribute both to the symptoms and pathology of OA, and further analysis of its role should lead to more effective therapies.

1.10 Hypothesis and Aims

The overall aim of this thesis was to investigate the role of angiogenesis and inflammation in structural damage and pain in osteoarthritis. It was hypothesised that:

- Angiogenesis during the early phase of synovitis could be a key factor in determining its persistence, and, where this is the case, treatment with the angiogenesis inhibitor (PPI-2458) could resolve this persistent synovitis.
- Anti-inflammatory (dexamethasone, indomethacin) and anti-angiogenic (PPI-2458) drugs could reduce structural damage and pain in the rat meniscal transection (MNX) model of OA by targeting synovitis and synovial and osteochondral angiogenesis.
- Increased angiogenesis in the human meniscus could be associated with increased sensory nerve growth leading to pain in OA.

2 **MATERIALS AND METHODS**

2.1 **Introduction**

This chapter outlines the general methods employed in this thesis. The source of human and animal tissues is described. All in-vivo animal experiments were carried out in accordance with UK Home Office regulations and were performed on either male Lewis or Wistar rats (Charles River, Margate, Kent, UK) weighing between 250-280 or 150-180 gm respectively. Pilot dose- and time-ranging experiments were carried out on sample animals in accordance with good practice and the 3 Rs: reduction, refinement and replacement. All procedures involving the use of human tissues were approved by Nottingham Research Ethics Committee (08/H0403/132), the tissues were obtained post mortem (PM) from patients following consent from next of kin (Walsh et al., 2003). A sample of PM consent form, buffer recipes, reagents and materials used and details of primary and secondary antibodies are all listed in the appendix (Section 8).

2.2 **Animal Models**

2.2.1 **Anaesthesia**

General inhalant anaesthesia was administered via an anaesthetic machine on rats undergoing recovery experiments as recommended in schedule 2A of the Animals Scientific Procedures Act 1986 (ASPA) (Gotoh et al., 2004). Isoflurane an inhaled anaesthetic is a volatile compound, delivered using oxygen (O₂) as the carrier. When isoflurane is allowed to vaporise, the inspired vapour has specific effects on the CNS. Anaesthesia is achieved when there is a gradual increase in concentration of isoflurane in the CNS and it reaches the same levels as that in the lungs. Isoflurane is less soluble in blood so induction of, and recovery from anaesthesia is more rapid. The fall in blood pressure observed with the use of isoflurane is primarily due to vasodilation rather than myocardial depression, making isoflurane the agent of choice for the induction of anaesthesia (Eger 1984). Each animal was placed in a transparent, acrylic induction chamber, the top was sealed and O₂ flow rate was turned on to 2 L/min. Isoflurane vaporiser was set at 3% concentration and the scavenger system was activated. Once the animal was anaesthetised, judged by lack of movement and reflexes and monitoring the rate and depth of breathing, it was removed from the chamber and anaesthesia was further maintained via a facemask. As soon as anaesthesia was achieved, the inspired concentration (3%) was reduced to a maintenance concentration of 2% isoflurane in O₂ (Gotoh et al., 2004). This gave precise control on the amount of anaesthetic agent given and hence the depth of anaesthesia. Elimination of the agent by the lungs meant more rapid recovery from procedures, which is vital in regaining normal physiology, to control post-operative hypothermia and fluid or electrolyte imbalance. When the procedure was completed, the anaesthetic machine was turned off and the animal was monitored until it regained consciousness before being returned to its cage.

2.2.2 Euthanasia

Each animal was killed by asphyxiation in carbon dioxide (CO₂) as recommended in schedule 1 (appropriate methods of humane killing) of the Animals Scientific Procedures Act 1986 (ASPA). Each animal was placed in an empty, acrylic chamber with a transparent lid, which was not sealed or clamped down in order to allow air to escape from around the rim. Flow of CO₂ was turned on to 2 L/min, gradually introducing 100% CO₂ to result in the replacement of 20% of the chamber volume per minute (Hewett et al., 1993). Exposure to a rising concentration of CO₂ caused unconsciousness due to a direct narcotic effect of CO₂ and eventual death from hypoxia. After 6 minutes the flow of CO₂ was turned off, the chamber was inverted to tip out all the residual CO₂ which is heavier than air and would otherwise have sunk to the bottom of the chamber (Smith et al., 1997). If this is not done and the next animal is put into the chamber when the concentration of CO₂ is already high, the animal will exhibit respiratory distress (Danneman et al., 1997). Death was confirmed by placing a spatula firmly across the back of the neck of each animal and taking a firm grasp of the tail of the animal and pulling sharply to dislocate the neck.

2.2.3 Intra-articular injections into rat knee joint cavities

Each animal was anaesthetised with isoflurane (2% in O₂) (section 2.2.1). The skin over the joint was shaved and swabbed with 70% ethanol. Injections of a total volume of 100 µl were given into the knee joints of approximately 200g animals using a 27-gauge 12.7-mm needle inserted through the suprapatellar ligament whilst the joint was held in 90° flexion (Mapp et al., 1996; Walsh et al., 1998; Seegers et al., 2003). Sequential injections (2 injections; each 100µl in volume) were given in a similar manner. A delay of 30 minutes between injections allowed the solution to disperse, after which the carrageenan injection was administered. Carrageenan was dissolved in sterile 0.9% normal saline (pH 7.4). FGF-2 was prepared in 10 mM Tris (pH 7.6) containing 0.1% bovine serum albumin (BSA). Naïve rats were used as controls (Figure 2.1).

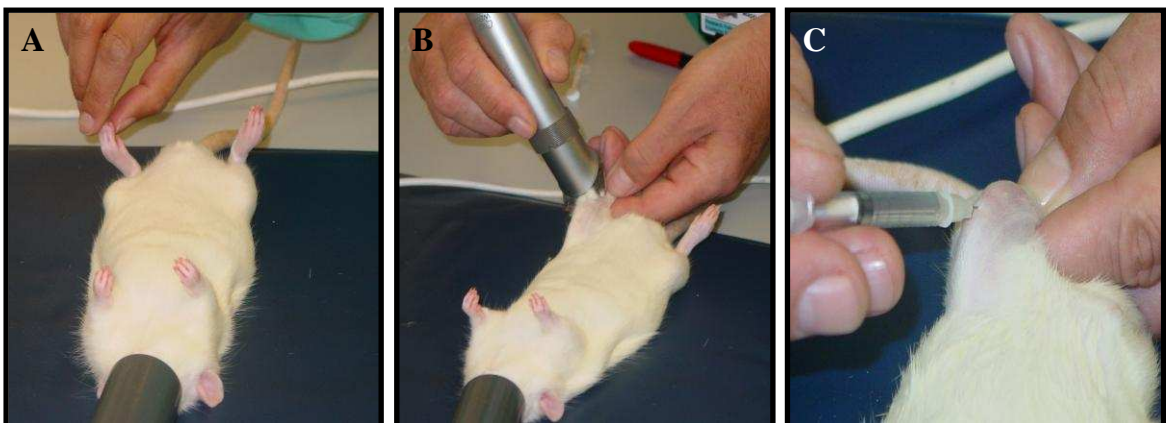


Figure 2.1: Intra-articular injection into knee joint cavities. Animals were anaesthetised judged by lack of movement and reflexes and monitoring the rate and depth of breathing (A) (section 2.2.1). The skin over the joint was shaved and swabbed with 70% ethanol (B). Injections were given using a 27-gauge 12.7-mm needle inserted through the suprapatellar ligament whilst the joint was held in 90° flexion (C)

2.2.4 Subcutaneous injections

Prior to meniscal transection surgery (section 2.2.6), each animal was anaesthetised (section 2.2.1) and given subcutaneous injection of Ceporex™ (0.005ml/100gm; Schering-Plough Animal Health, Middlesex, UK), an antibiotic, followed by a single dose of Rimadyl™ (0.01ml/100gm; Pfizer Ltd, Kent, UK) to reduce post-operative pain. This was done by lifting a fold of the skin using the thumb and first two fingers of one hand in the lower left or right quadrant of the abdomen. There are no vital organs in this area. The needle was then passed through the skin at the base of the fold parallel to the body, to avoid penetrating deeper tissues.

2.2.5 Oral gavage

Gavage or stomach tubes are used to instil liquids directly into the stomach of animals. They are stainless steel needles with a protective rounded tip to prevent any internal damage to the animal during oral dosing. The animal was restrained with its neck extended, so that the head was well controlled and the forelimbs immobilised (Wolfensohn et al., 2003). Care was taken to avoid excessive tight grip on the animal which would otherwise induce a panic response. Distance between the oral cavity and the end of the xyphoid process was measured on outside of the animal with the needle to ensure that the needle to be used was of appropriate size and at the same time giving an idea of how far to insert the needle when dosing. Inappropriate sized needles could cause internal damage to the animal as well as resulting in the drug being delivered to site other than the stomach. The needle attached to a 1ml syringe containing the appropriate drug in a 500 µl volume was passed gently down the oesophagus. To achieve correct positioning, the needle was used as a lever to move the animal's head slightly upwards and back approximating a straight line. Positioning the tube to either the right or the left of the animal's mouth facilitated the passage of the needle into the oesophagus with ease. Care was taken not to force the needle down as this could damage the oesophagus, or put the needle into the trachea. When the contents of the syringe were injected into the oesophagus, the needle was gently removed and the animal returned to its cage and observed for any signs of distress, such as gasping and frothing at the mouth or nose. Resistance to insertion of the needle, or a struggling animal indicated a problem. The procedure was stopped and carefully restarted.

2.2.6 Meniscal transection (MNX) model of Osteoarthritis

Animal models have been developed which resemble various aspects of the osteoarthritic human knee whilst being amenable to potential pharmacological manipulation (Ameye et al., 2006). MNX model of OA in the rat displays changes within the articular cartilage, osteophyte formation and angiogenesis, both within the synovium and at the osteochondral junction, which resembles human tibiofemoral OA (Mapp et al., 2008). It has a mild to moderate severity, sufficient to enable the exploration of factors which may either exacerbate or relieve OA.

OA was induced on day 0 by medial meniscal transection as described previously (Janusz et al., 2002; Mapp et al., 2008). Briefly, prior to surgery, each animal was anaesthetized (section 2.2.1) and given subcutaneous injections (section 2.2.4). The left leg was closely shaved and surgically prepared with Vetasept Povidone-Iodine scrub (Animalcare Ltd, Dunnington, York) to provide a sterile area to operate on. The scrub was applied from the middle of the clipped area towards the outside to prevent any dirt being dragged from the fur at the edge on to the skin where the incision was to be made. The animal was then appropriately positioned over a heat blanket to keep it warm during surgery. A sterile op-cover (Kruuse Ltd, Sherburn in Elmet, North Yorkshire) was placed over the leg to be operated on, covering all but the surgical field, reducing the risk of sterile items coming into contact with non-sterile areas close to the surgical field. All instruments were sterilized prior to surgery. A large section of the skin over the knee joint was grasped using straight forceps (InterFocus Ltd, Linton, Cambridge, **11370-40**). The skin was cut on the medial side of the knee joint with a single cut just underneath the joint cavity using straight iris scissors (InterFocus Ltd, Linton, Cambridge, **14558-11**). The white shadow of medial collateral ligament (MCL) was seen at this point buried under the muscle layers. Hemorrhage from the skin edge was arrested by applying firm pressure from a sterile swab. Connective tissue (CT) was grasped with straight forceps and cauterized using small vessel cauteriser (InterFocus Ltd, Linton, Cambridge, **18000-00**) edged in a straight line from one corner of the cut to the other. The muscle layers were then held before being cauterized in a similar manner as that of the CT to expose the MCL. To prevent excess blood loss from the surgical site, hemorrhage was arrested by cauterizing the bleeding vessel during the course of surgery. This minimized post-operative swelling, surgical shock and risk to the animal. The MCL was grasped with micro-forceps with teeth (InterFocus Ltd, Linton, Cambridge, **11084-07**). Using the straight spring scissors (InterFocus Ltd, Linton, Cambridge, **15000-00**) held flat to the joint, the MCL was cut and part removed (3mm) to uncover the meniscus. The procedure was stopped at this point and the wound sutured if SHAM surgery was being performed. Otherwise the procedure was continued and the meniscus was freed from its surrounding tissues by making two cuts either end of the meniscus at the top and two cuts at the bottom using straight spring scissors. The ankle of the animal was twisted gently to clearly visualize the joint space and the meniscus was grasped using straight forceps before being cut through the full thickness at its narrowest point using straight spring scissors. The meniscus separated in to two parts. Care was taken to ensure that the underlying articular cartilage did not suffer any forced damage whilst the meniscus was being cut during the surgery. The safety of the underlying articular cartilage was ensured in several ways, by twisting the ankle of the animal to create a space between the meniscus and the two bone ends. This enabled the free meniscus to be grasped easily by the forceps and to be pulled up slightly without touching the two bone ends before the cut was made. Also, after the meniscus was cut, the two bone ends were inspected thoroughly under the microscope to ensure no damage was sustained. The site was flushed with saline and dabbed using sterile swabs to remove excess blood. To stop tissues from drying out during surgery, they were dabbed at regular intervals with sterile swabs soaked in saline. Instruments were re-sterilised between animals using Novasapa Cold Steriliser (Pfizer Animal Health, Walton Oaks, Surrey).

Sutures were placed using micro needle holder with cutter (InterFocus Ltd, Linton, Cambridge, **12075-14**) and suture tying forceps (InterFocus Ltd, Linton, Cambridge, **18025-10**) to pass curved needles through tissues and to tie knots after suturing. The CT layer was closed with interrupted stitches using Ethicon coated vicryl 8/0 sutures. The skin was closed using subcutaneous continuous stitches with Ethicon coated vicryl 4/0 sutures to appose the tissue margins and allow healing (Figure 2.2).

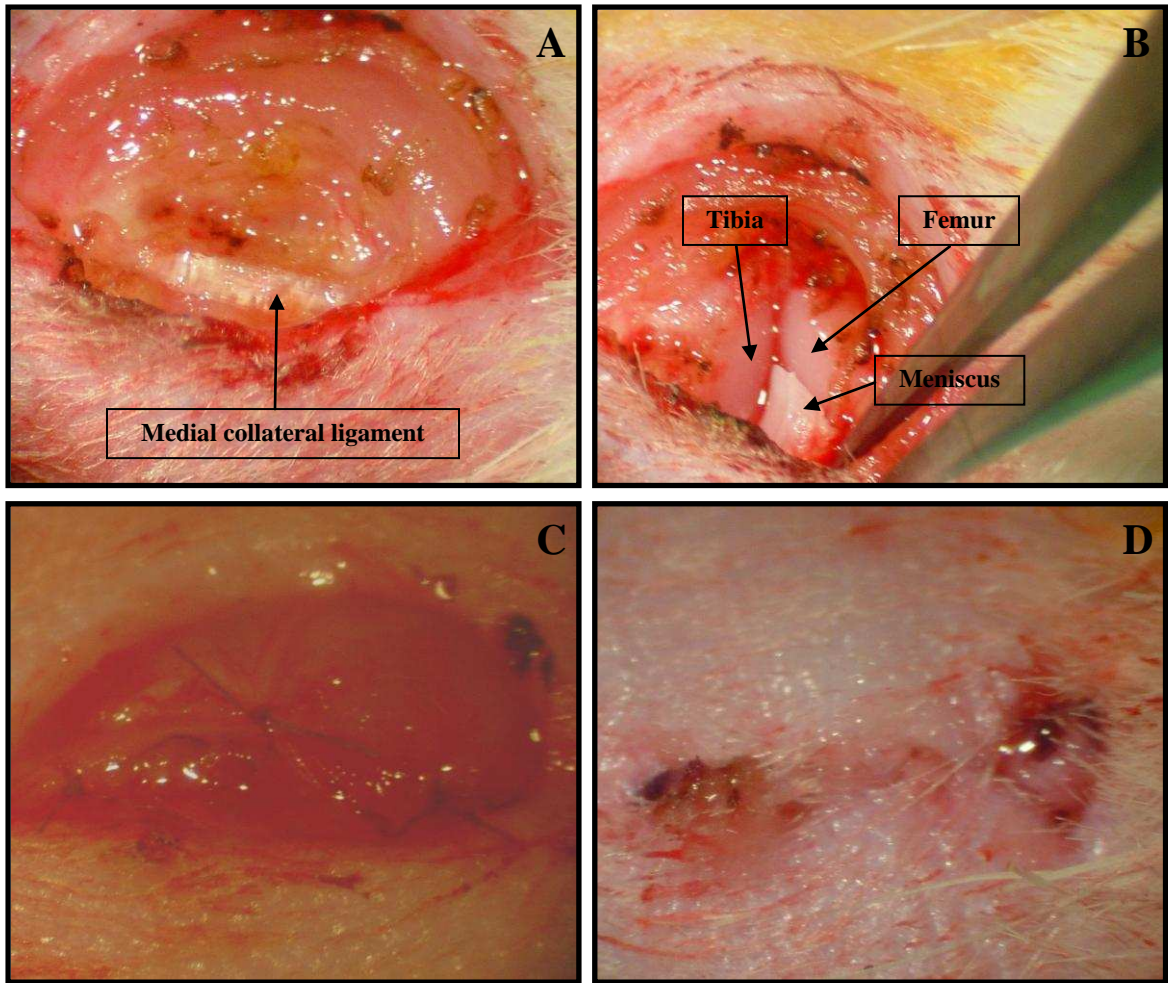


Figure 2.2: Meniscal transection surgery. Medial collateral ligament was exposed (A) and partly removed to access the meniscus. The meniscus was cut through the full thickness at its narrowest point (B). The connective tissue layer was closed first (C) followed by the skin (D).

2.3 Behavioural Testing

2.3.1 Pain Behaviour

Knee joint pain can be measured indirectly as weight-bearing asymmetry (Neugebauer et al., 2007). This method is used in the clinical setting to assess pain in the arthritic patients. Most commonly, the weight bearing asymmetry is measured between the two hind limbs as the force exerted by each limb on a transducer pad over a given period of time. Weight borne by each hind limb is expressed as the percentage difference of weight distribution (force) between each hind limb (Bove et al., 2003; Mapp et al., 2010). A significant shift of weight from the ipsilateral (operated) to the contralateral (control) limb (a weight-bearing deficit) is taken as a pain measure.

A Perspex tube instead of a Perspex box was used to house the animals in order to carry out the pain behaviour testing because animals seemed calmer and stayed relatively still in the tube compared to when they were in the box, enabling consecutive readings to be obtained. However when the animals were housed in the Perspex box, they tended to move around a lot and appeared more stressed. Animals were able to climb out of the Perspex box via the removable lid. This interfered with obtaining consecutive readings. Animals were first habituated in the Perspex tube/Incapacitance Meter prior to when the actual pain behaviour measurements were supposed to be taken. This enabled the animals to get used to their surroundings, reducing stress levels. Stressed animals could grossly interfere with true pain behaviour measurements. Pain behaviour was measured at set time-points using the Incapacitance Meter (Linton Instruments, Norfolk, UK). Each animal was placed in the Perspex tube, such that each paw rested on a separate transducer pad that recorded the animal's weight distribution over a period of 3 seconds. An average of 5 separate readings was taken for each data point (Figure 2.3).

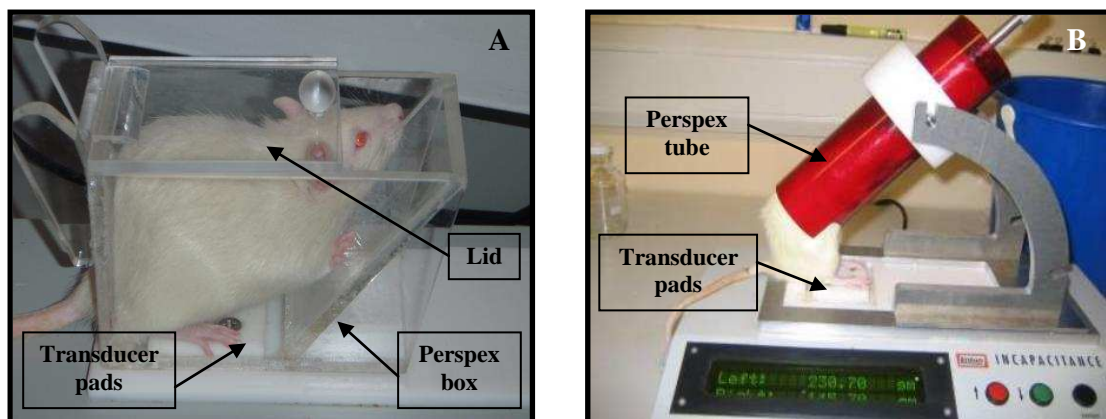


Figure 2.3: Measuring pain behaviour. Incapacitance meter having Perspex box (A) or Perspex tube (B) to house the animals. Animals were placed on the incapitance meter such that each hind paw rested on a separate transducer pad of the incapitance meter. Over a period of 3 seconds, the amount of weight the animal was placing on each of its hind limb was measured in grams.

2.3.2 Weights

Weight of each animal was measured at set time-points throughout the experiments to ensure that the surgical procedures and the drugs being used were not having detrimental side-effects.

2.4 Joint Swelling

Joint swelling was measured at set time-points with a digital electronic caliper (Miyutoyo UK Ltd., Andover, UK) as asymmetry in knee diameters (millimeters) between ipsilateral (operated) and contralateral (control) knee joints (Figure 2.4).

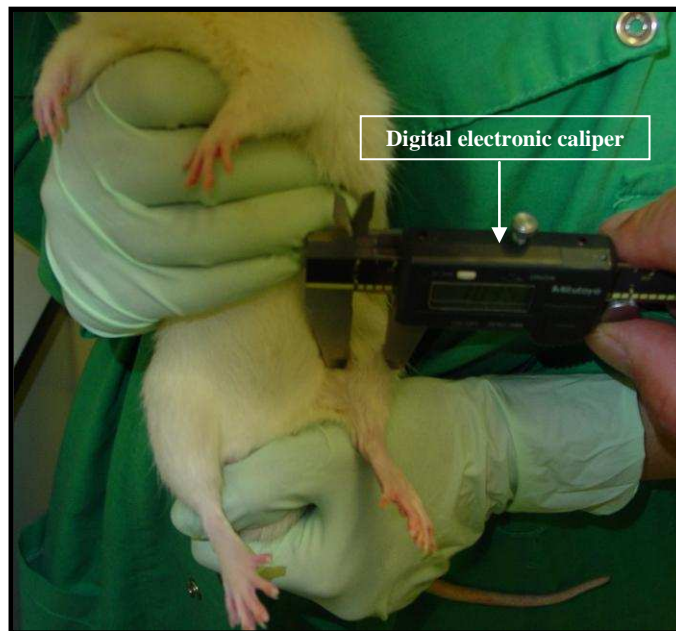


Figure 2.4: Knee joint swelling. Each animal was held by an assistant and the knee joint diameter was measured using a digital electronic calliper.

2.5 Tissue Collection and Processing

2.5.1 Harvesting and mounting rat synovia

Animals were killed by asphyxiation in CO₂ (section 2.2.2). For each animal, skin was removed, synovia with patellae from right and left knees were dissected free from bone (Figure 2.5) and immediately embedded perpendicularly side on in Tissue Tek Optimum Cutting Temperature (OCT®) mounting medium (Raymond Lamb, Eastbourne, UK) onto cork blocks before being snap frozen in melting isopentane and stored at -80°C until use.

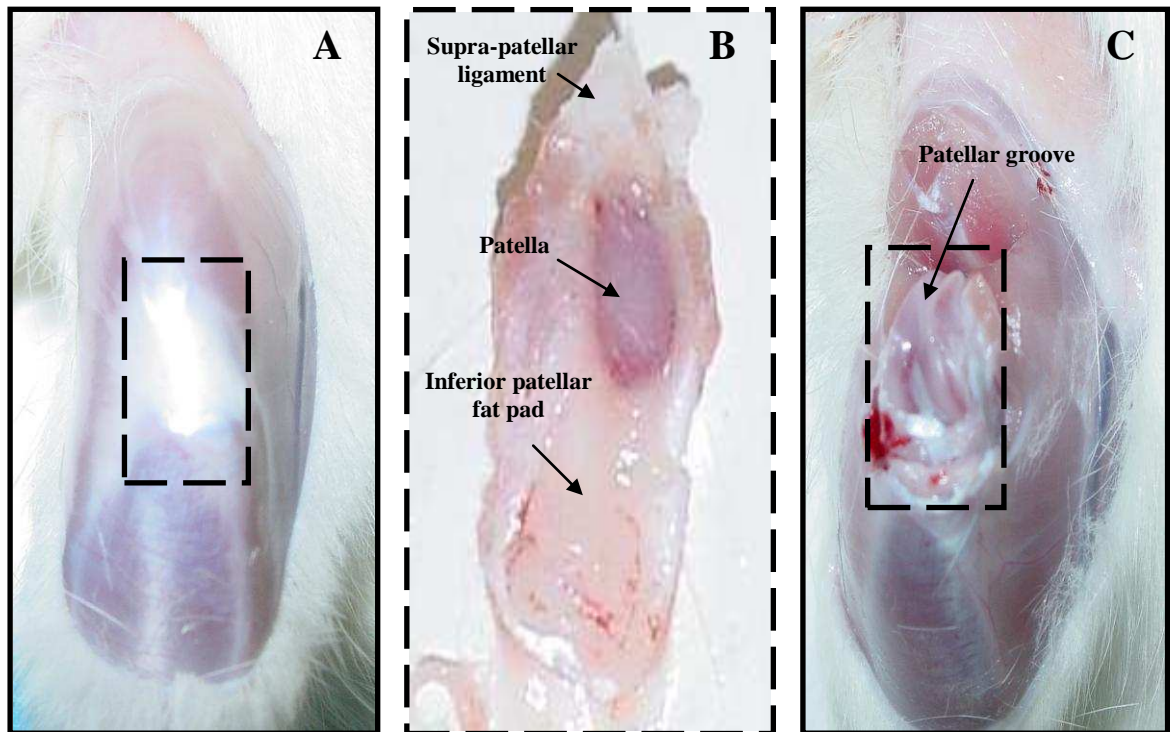


Figure 2.5: Harvesting synovium. **A**, knee joint of an animal with the skin removed. **B**, synovium with patella dissected free from bone. **C**, exposed underlying patella groove with the synovium and patella removed.

2.5.2 Harvesting and mounting rat tibiofemoral joints

Tibiofemoral joints were isolated by cutting mid-femur and tibia using bone cutters and excess skeletal muscle was removed. The joints were preserved in either neutral buffered formalin (containing 4% formaldehyde) for 48 h at room temperature or Zamboni's fixative solution (2% [w/v] paraformaldehyde, 15% [v/v] picric acid in phosphate buffer, pH 7.3) overnight at 4°C (Stefanini et al., 1967). The sections were continuously agitated on a roller-mixer throughout the fixing process and subsequently decalcified.

Decalcification is the process by which heavily mineralised tissues are softened to enable thin sections to be obtained for histological purposes, carried out by treatment with reagents which react with calcium. There are two major types of such reagents; acids (formic acid) to form soluble calcium salts and chelating agents (ethylenediaminetetraacetic acid [EDTA]) to take up calcium ions. Formic acid was used to rapidly decalcify the tibiofemoral joints to be used for histological stains (section 2.7) in order to analyse the structure of the joint. EDTA decalcification was used because it was a less harsh and slower method of decalcification compared to formic acid having little to no effect on the stainability of the tissue, enabling immunohistochemistry detection of delicate structures such as nerves.

Formalin-fixed tibiofemoral joints were decalcified in 10% formic acid in neutral buffered formalin (containing 4% formaldehyde), changed every other day, for 10 days at room temperature. Decalcification was confirmed by radiography (22kV 16sec). Coronal sections (Figure 2.6) of trimmed joint tissues were then cut and processed by standard histological techniques and mounted in paraffin wax blocks for sectioning. Briefly, the sections were secured (flat side down) in labelled plastic cassettes. The cassettes were placed in the Shandon Pathcentre enclosed tissue processor (Shandon ThermoScientific, Leicestershire, UK) at King's Mill Hospital by an experienced laboratory technician (Roger Hill) to undergo a series of dehydration and clearing steps. The sections were impregnated with molten wax for the final embedding stage of setting the sections in blocks of paraffin wax. For this, metal moulds were placed on a hot-plate and molten wax was dispensed into them from a Tissue Tek® embedding centre (model TEC5 EME2; Sakura Finetek Europe, The Netherlands). Tibiofemoral joint sections were then placed flat side down into the centre of the mould using warm forceps and transferred briefly to a cold-plate to allow the wax to slightly solidify at the bottom of the mould. At the same time the section was pressed down to enable an even flat tissue surface to be achieved with the wax. Labelled plastic cassettes were then placed on top of the mould, pressed down and more wax poured on top to evenly fill the cassettes. Moulds were then placed on the cold-plate for rapid cooling of the wax. Once the wax set, the wax blocks were removed from the metal moulds, excess wax trimmed from the cassettes and the wax blocks were stored at room temperature until required for microtomy (Figure 2.6).

Zamboni-fixed tibiofemoral joints were transferred to 15% [w/v] sucrose in phosphate buffered saline (PBS/Sucrose) solution at 4 °C for 5 days. The PBS/Sucrose solution was changed daily until the yellow appearance of the solution was cleared. Once cleared, the PBS/Sucrose was replaced with decalcification fluid (10% EDTA in 10mM Tris buffer with 7.5% [w/v] polyvinylpyrrolidene [PVP], pH 6.95). The joints were decalcified for approximately 5 weeks at 4°C. The decalcification fluid was changed every other day. Radiography (22kV 16secs) was used to detect the extent of decalcification of the tibiofemoral joints. When the joints were fully decalcified, coronal sections of trimmed joints (Figure 2.6 A) were cut and transferred to PBS/Sucrose solution for 5 days at 4°C through to 1:1 mixture of PBS/Sucrose and OCT® embedding matrix into 100% OCT for a further 7 days at 4 °C. The sections were continuously agitated on

a roller-mixer throughout this process before being mounted onto cork blocks and then snap frozen in melting isopentane on liquid nitrogen and stored at -80 °C.

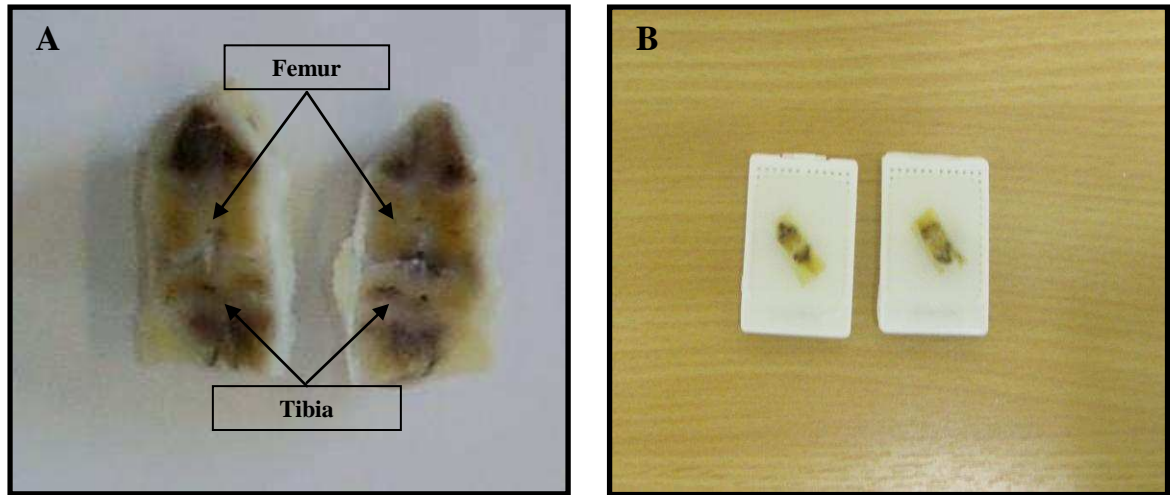


Figure 2.6: Harvesting knee joints. **A**, an example of a knee joint split in half from which coronal sections were taken. **B**, sections of knee joints embedded in paraffin wax blocks.

2.5.3 Human menisci

All menisci samples were processed on site at King's Mill Hospital by an experienced laboratory technician (Roger Hill) following standardised procedures. Coronal slices (2 mm thick) from the midline of medial menisci were fixed in neutral buffered formalin (containing 4% formaldehyde) for 48 h at room temperature and wax embedded, or were fixed in Zamboni's solution (2% [w/v] paraformaldehyde, 15% [v/v] picric acid in phosphate buffer, pH 7.3) (Stefanini et al., 1967) overnight at 4 °C. Samples fixed in Zamboni's solution were transferred to 15% [w/v] PBS/Sucrose solution at 4 °C for 5 days and then through 1:1 mixture of PBS/Sucrose and OCT® embedding matrix into 100% OCT for a further 7 days at 4 °C before being mounted onto cork blocks and then snap frozen in melting isopentane and stored at -80 °C.

2.5.4 Systemic transcardiac perfusion fixation of rat tibiofemoral joints

Each animal was sedated 15 min prior to the procedure with intraperitoneal injection of 0.5ml sodium pentobarbital (Euthatal), given in the lower left or right quadrant of the abdomen as there are no vital organs in this area. The quadrants are demarcated by the midline and a line perpendicular to it passing through the umbilicus. The needle was angled at 45° and passed smoothly through the skin. When both the corneal and hind paw withdrawal reflexes were absent, the animal was restrained on a perfusion tray and the rib cage was cut to expose the heart.

A small incision was made in the left ventricle and a cannula was passed through it into the ascending aorta. A small incision was made in the right atrium to allow drainage of returning blood and fluid from

the systemic circulation. PBS (500 ml) was pumped through the cannula to wash out any remaining traces of blood in the animal. Zamboni's fixative (500 ml) was then pumped through the animal to fix the tibiofemoral knee joints (Hukkanen et al., 1992). Tibiofemoral joints were isolated by cutting mid-femur and tibia and preserved in Zamboni's fixative solution, ready for the decalcification process (section 2.5.2).

2.5.5 Blood Glucose Testing

OneTouch® Ultra® Blood Glucose Meter and Test Strips (LifeScan Inc. High Wycombe, UK) were used to test blood glucose levels 35 days after meniscal transection surgery (section 2.2.6). Briefly, at the time of harvesting rat tibiofemoral knee joints (section 2.5.2) the code matched test strip was inserted into the associated meter. Drops of blood were applied to the top edge of the test strip until the confirmation window was full. The results were displayed on the meter in a range of 1.1 – 33.3 mmol/L. Normal blood glucose level was taken as 4 – 7 mmol/L.

2.6 Immunohistochemistry

2.6.1 Introduction

Immunohistochemistry is a process used to localise specific molecules (antigens) in tissue sections or cell preparations by the use of antibodies (Immunoglobulins) (Coons et al., 1950) for microscopical evaluation. These antibodies are coupled to a variety of labels such as enzymes, fluorescence molecules, isotopes and colloidal gold that can be visualised relatively easily. Immunohistochemistry is readily used in research and in clinics as a diagnostic tool. In addition to antibodies, other types of proteins and carbohydrates such as lectins can be used to detect specific molecules in tissue sections or cell preparations, using essentially the same method.

2.6.2 Principles involved

Tissues are first collected and processed (section 2.5) before thin sections are cut and stained with labelled antibodies. This is needed not only to preserve the tissue architecture but also to prevent deterioration of antigens being investigated and at the same time processing the tissue so that sections can be cut for light microscopy. This processing step also fixes the antigens, preventing their leakage into the microenvironment and into the solutions used during the processing and staining procedures. Sections are cut from either fixed tissue samples embedded in paraffin wax or unfixed frozen samples which are followed by a fixation step using acetone. Paraffin wax embedded tissues display superior quality of the morphology of cells and tissues, the antigenic determinants are however relatively poorly preserved and sometimes difficult to detect. As a result, either antigen retrieval methods are used to overcome this difficulty or unfixed frozen tissue samples are used. The basic principles of immunohistochemistry staining are the incubation of tissue sections with primary antibodies directed to antigens of interest, binding of these antibodies to tissue antigens and detection of the attached antibodies. The primary

antibodies are either directly conjugated to a tag or unlabelled (indirect method). In the indirect method, unlabelled primary antibodies bind to antigens. Labelled biotinylated secondary antibodies (raised against the IgG of the animal species in which the primary antibodies are raised) react with the primary antibodies. The specific antigen-antibody interactions can be visualised using the avidin-biotin complex (ABC) method (Guesdon et al., 1979; Hsu et al., 1981). The biotin vitamin on the secondary antibody binds with high affinity to the glycoprotein avidin. Four biotin vitamins can bind with high affinity to one avidin glycoprotein, amplifying the antigen-antibody signal (Figure 2.7). Biotin is labelled with either peroxidase (Nakane et al., 1966) or alkaline phosphatase (Mason et al., 1978) enzyme markers. These are easily developed by incubation with a substrate, either diaminobenzidine (DAB) substrate to give a brown coloured stain or Fast Red substrate to give a red stain respectively that can easily be visualised. The DAB stain can be enhanced using glucose oxidase/nickel, producing a deep purple/black colour (Shu et al., 1988).

Indirect immunohistochemistry with ABC method is more frequently used as it has several advantages. Firstly, it allows for considerably higher sensitivity, to antigens which are present in low amounts without increasing background staining. This is also important where the cost of primary antibodies is significant. The high affinity of avidin and biotin ensures the user of the rapid formation and stability of the complex. Moreover, it is possible to localise more than one antigen with two or more primary antibodies in the same tissue by using separate enzyme markers or substrates.

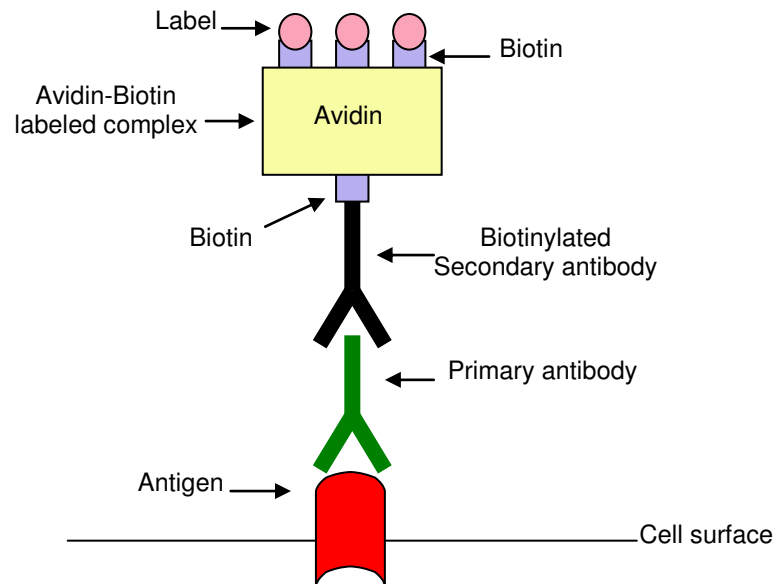


Figure 2.7: Indirect immunohistochemistry. Primary antibody binds to the specific antigen of interest on the cell surface. A biotinylated secondary antibody binds the unlabelled primary antibody and is detected with the performed avidin-biotin complexes (avidin biotin complex, ABC method). Four biotin vitamins can bind with high affinity to one avidin glycoprotein, amplifying the antigen-antibody signal that is easily developed and visualised.

2.6.3 Staining procedures

For detection of CGRP positive nerves, Zamboni's fixed tissues were used (Stefanini et al., 1967). Unfixed fresh frozen tissues were used for all other studies. Details of primary and secondary antibodies used in these studies are listed in the appendix. For staining of nerves, 15µm thick tissues sections were cut to facilitate morphological identification of these fine delicate structures. For all other staining, tissue sections were cut 5 µm thick. Rat synovial tissue sections and human meniscal tissue sections from each OCT block were cut using a motorised cryostat, mounted on slides, and briefly air dried. Coronal sections from paraffin wax blocks taken from the midpoint of the rat knee joint as identified by the presence of cruciate ligament insertions and sections from human menisci were cut in a Reichert-Jung rotary microtome were. Preparations were mounted in Distyrene, Plasticizer and Xylene (DePeX™) except those to detect ECs which were mounted in PBS/glycerol (3:1). Figure 2.8 highlights the essential steps required prior to carrying out the staining procedures.

Sections of unfixed tissues were then fixed in acetone for 10 minutes at 4°C and washed twice in 0.01 M PBS, pH 7.4, each wash lasted 5 minutes. Whereas sections from paraffin wax blocks were dewaxed in xylene and rehydrated from 100% ethanol, through to 70% ethanol and then into distilled water, before being washed in PBS. Each step was performed twice and lasted 5 minutes. To completely abolish the chances of false positive reactions occurring in frozen tissues, endogenous peroxidase activity was blocked by incubating the tissue sections for 30 minutes at room temperature (RT) in absolute methanol containing 0.33% hydrogen peroxide (Streefkerk 1972) and then washed twice for 5 minutes in 0.01 M PBS.

Primary antibodies diluted in 0.01M PBS with 5% BSA and 3.3% normal serum from the species in which the secondary antibody was raised were then applied and the tissue sections were incubated in a humid chamber either for 1 hour at RT, or overnight at 4°C and subsequently washed twice in 0.01 M PBS. Sections were then incubated in biotinylated secondary antibody diluted in 0.01 M PBS with 5% BSA and 3.3% normal serum for 45 minutes at RT. Sections were washed twice for 5 minutes in 0.01 M PBS and then incubated with avidin biotin complex (ABC) for 30 minutes at RT.

ABC was prepared and left standing at RT for 30 minutes before use. 100 µl of solution B was added to 5 ml PBS and mixed by shaking, followed by the addition of 100 µl solution A and immediate mixing. After incubation with ABC, sections were washed twice for 5 minutes in PBS and incubated for a further 5 minutes in 0.1M sodium acetate buffer, pH 4.6 before being developed with the chromogen. Deposition of chromogen during development was monitored by direct visualisation under light microscopy using a ×4 objective lens and reaction terminated by immersion in 0.01M PBS.

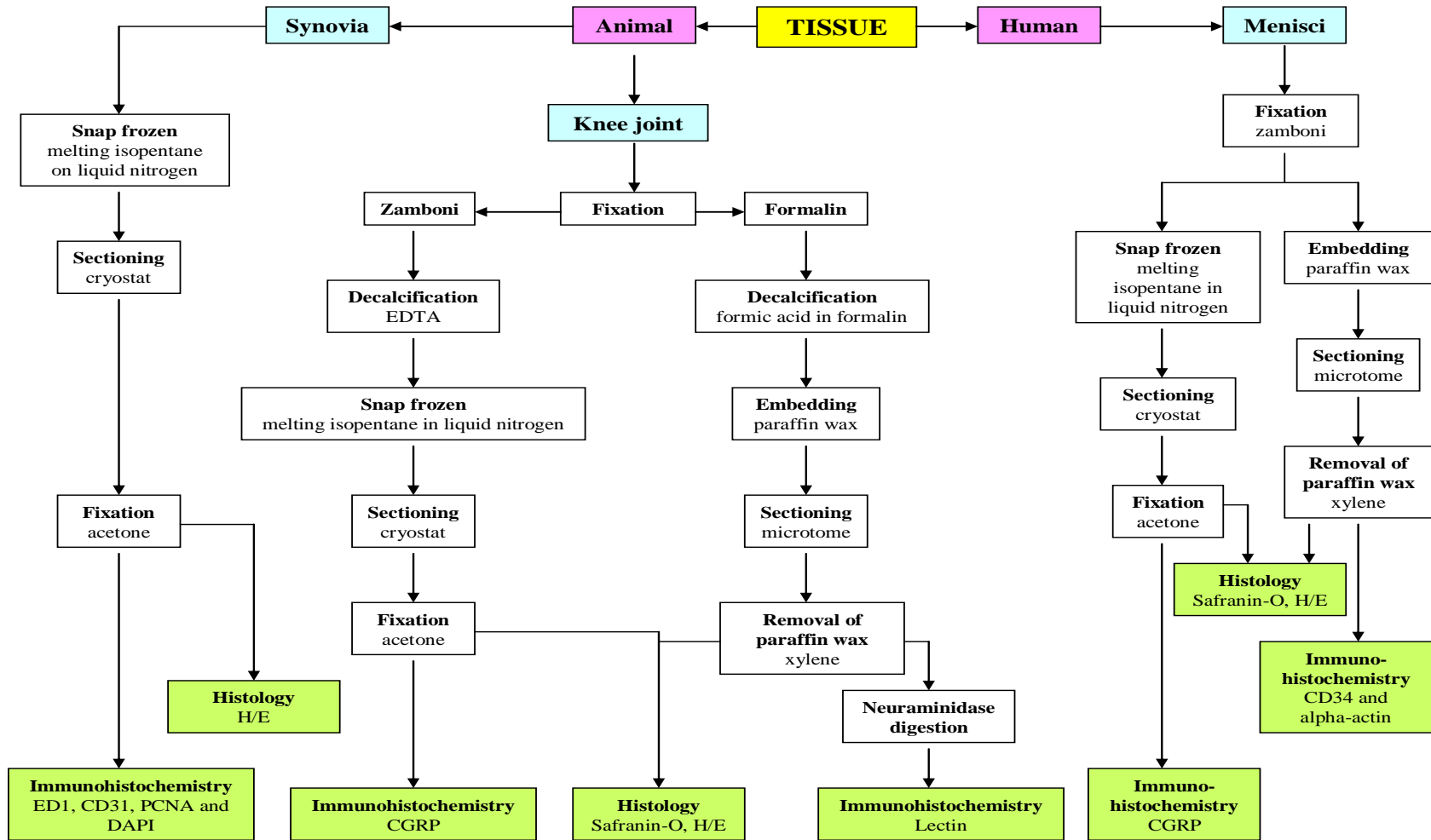


Figure 2.8: Flow diagram highlighting the essential steps involved prior to staining procedures.

Tissue sections immunostained by the peroxidase-conjugated ABC complex method were visualised with DAB using the glucose oxidase/nickel-enhanced method (Shu et al., 1988) before being either directly dehydrated in graded alcohols and mounted in DePeX™ or first counterstained with Mayers Haematoxylin and differentiated in 1% acid alcohol before dehydration and mounting.

Glucose oxidase/nickel enhancement of the ABC-peroxidase method was employed for demonstration of neuronal structures (Shu et al., 1988). It comprised of dissolving 25 mg of DAB in 25 ml of distilled water immediately before use and mixed with 25 ml of 0.2 M sodium acetate buffer, pH 6.0, containing 1.25 g di-ammonium nickel (II) sulphate.6H₂O, 20 mg ammonium chloride and 100 mg β-D-glucose. Glucose oxidase (0.25 ml of 0.2% in distilled water) was added with stirring and applied to sections in an incubation chamber.

Tissues sections stained by the ABC-alkaline phosphatase method were developed using Sigma-Aldrich Fast Red (Poole, UK) and mounted in PBS/glycerol (3:1). To prevent drying of sections following mounting, coverslips were sealed with nail varnish.

For multiple sequential staining, to identify CD31-positive cells and proliferating cell nuclear antigen (PCNA)-immunoreactive CD31-positive cells (to identify ECs and proliferating ECs, respectively) in the synovia as two separate measures of the extent of angiogenesis, sections were first immunostained by the peroxidase-conjugated ABC complex method for PCNA (Waseem et al., 1990) and then by the ABC-alkaline phosphatase method using a monoclonal antibody directed against CD31 for endothelium (Male et al., 1995). Nuclei were counterstained with fluorescent DNA ligand, 4'-6'-diamidino-2-phenylindole hydrochloride (DAPI) in a humid chamber at RT in the dark for 10 minutes (Sanna et al., 1992). Sections were then mounted in PBS/glycerol and coverslips sealed using nail varnish. Staining procedures were similar to those previously described (Walsh et al., 1998).

Macrophage infiltration was identified by immunoreactivity for the monoclonal antibody clone ED1 (Dijkstra et al., 1985) in the synovia. Nerves were immunolocalised using antibody to CGRP. Vascular endothelium was localised using antibody to alpha actin (Kennedy et al., 2010), all labelled with avidin-biotin complex and visualised by nickel-enhanced DAB method (Shu et al., 1988) before being mounted in DePeX.

Lectin immunohistochemistry was performed to identify ECs using Griffonia simplicifolia (GS-1) as previously described (Orgad et al., 1984; Alroy et al., 1987) on paraffin wax embedded tissue sections. After de-waxing and rehydration, sections were incubated in neuraminidase for 3 hours in a humid chamber at 37°C to cleave surface sialic acids. The sections were then washed twice for 5 minutes in N-[2-hydroxyethyl]piperazine-N'-[2-ethanesulfonic acid]; 4-[2-hydroxyethyl]piperazine-1-ethanesulfonic acid

(HEPES) buffer, pH 7.5 and incubated with lectin GS-1 in HEPES buffer overnight at 4°C in a moist chamber. The lectin was detected using anti-lectin followed by biotinylated antibodies with phosphatase-labeled ABC visualised using Fast Red™.

2.7 Histological Stains

2.7.1 Haematoxylin and eosin

Haematoxylin and eosin stains were used to analyse tissue architecture. The basic dye component, haematoxylin, having high affinity for acidic structures such as nucleic acid, stained the cell nuclei blue/black, whilst eosin, an acid dye, having high affinity for basic structures, stained cell cytoplasm and most connective tissue fibres in various shades and intensities of pink, orange and red (King et al., 1986).

Frozen tissue sections (5 µm thick) were washed twice for 5 minutes in distilled water. Whereas paraffin wax embedded tissue sections (5 µm thick) were first dewaxed in xylene and then rehydrated in graded ethanol before being washed in distilled water twice for 5 minutes. Nuclear staining was then achieved by immersing the sections in Mayer's haematoxylin for 10 minutes, rinsing in running tap water to differentiate the staining, dipping the sections in 1% acid alcohol solution for 10 seconds and back into tap water for further 3 minutes before being immersed in 1% eosin for 1 minute to stain all other tissue structures varying degree of red. Staining was then differentiated with running tap water and the sections were dehydrated through graded ethanol into xylene and mounted in DePeX and covered with cover-slips.

2.7.2 Safranin O and fast green

Safranin O and fast green staining technique is most commonly used for studying bone and cartilage (McIlwraith et al., 1981; Bulstra et al., 1993). The un-calcified cartilage stains red because of its high proteoglycan content, calcified cartilage stains a lighter pink shade and subchondral bone stains blue/green (Rosenberg 1971). Safranin O and fast green staining technique was used to analyse the cartilage in rat knee joints and human menisci.

Frozen tissue sections (5 µm thick) were washed twice for 5 minutes in distilled water. Whereas paraffin wax embedded tissue sections (5 µm thick) were first dewaxed in xylene and then rehydrated in graded ethanol to distilled water twice for 5 minutes. Sections were then immersed for 2 minutes in Weigert's haematoxylin, rinsed for 1 minute in running tap water, submerged in acid alcohol solution for 20 seconds and rinsed again in tap water for further 3 minutes. Sections were subsequently immersed in Fast Green for 5 minutes, dipped for 1 second in acetic acid and immersed in Safranin O for 5 minutes, followed by differentiation of the staining in running tap water and dehydration with graded ethanol to xylene before being mounted in DePeX and covered with cover-slips.

2.8 Image analysis and Quantification

All image analysis and quantification was carried out whilst being blinded to the experimental details, using a Zeiss Axioscop-50 microscope (Carl Zeiss Ltd, Welwyn Garden City, UK). Images were captured using a 3-CCD video camera module (model KY-F55B; JVC, Japan) and analysed using KS300 image analysis software (Imaging Associates Ltd., Thame, UK).

2.8.1 Synovia

Using a $\times 20$ objective lens, data was obtained from four fields of view on each synovial section that displayed the highest densities of either CD31-positive blood vessels, or PCNA-positive endothelial nuclei, or ED1-positive macrophages.

To quantify vascular density and proliferating ECs in the synovium, the synovial region to be analysed was first chosen according to morphology. An image was captured using a 3-CCD video camera for analysis with KS300 image analysis software. Colour transmitted light images and fluorescence images of DAPI-positive nuclei were captured and converted automatically to monochrome images. Frame surrounding the synovium was delineated and measured. The image was thresholded according to hue to include all CD31-positive blood vessels. The vessels were interactively selected from a mask created to include only endothelium, and their combined areas measured. PCNA-positive nuclei, falling within the endothelium were counted by interactively selecting each of them. The fluorescent image of the DAPI-positive nuclei was overlaid by the endothelial mask automatically and the DAPI-positive nuclei were then counted interactively. To quantify macrophage infiltration, colour transmitted light image of ED1-positive synovial region was captured and converted automatically to monochrome image. A frame surrounding the synovium was delineated and measured. The image was thresholded according to hue to include all ED1-positive nuclei and their combined areas measured. These procedures were similar to those previously described (Seegers et al., 2003). Non-specific staining was excluded from the measurements by rejecting objects not fitting the morphological criteria of the structures (macrophages, blood vessels, nerves) being quantified. EC proliferating index was defined as the percentage of EC nuclei positive for PCNA. Vascular density and macrophage fractional area was defined as the percentage of synovial area that was positive for CD31 and ED1 respectively.

2.8.2 Cartilage and Subchondral Bone

The entire medial tibial plateaux of the mid-coronal sections stained with Safranin-O were used to assess chondropathy and osteophytosis through a $\times 10$ objective lens under transmitted light. Chondropathy and osteophytosis were evaluated using the system of Janusz et al., as previously described (Janusz et al., 2002). Briefly, in this method cartilage damage was scored on a scale of 0 to 5 as follows:

- 0 = Cartilage of normal appearance
- 1 = Minimal fibrillation in superficial zone only
- 2 = Mild, extends into the upper middle zone
- 3 = Moderate, well into the middle zone
- 4 = Marked, into the deep zone but not to the tidemark
- 5 = Severe, full thickness degeneration to the tidemark

The extent of medial tibial plateau involved in the damage was also taken into account. It was estimated as the proportion of the section of medial tibial plateau that was involved, 1/3, 2/3 or 3/3. The cartilage damage score was then multiplied by 1, 2 or 3 respectively to give an overall chondropathy score.

Osteophytes were scored depending on their size on a scale of 0 to 3 using an eyepiece graticule as follows:

- 0 = No osteophyte present
- 1 = Mild, $< 40 \mu\text{m}$
- 2 = Moderate, 40 to 160 μm
- 3 = Severe $> 160 \mu\text{m}$.

Total joint damage score was calculated as the sum of the chondropathy and osteophyte scores.

Integrity of the osteochondral junction was measured as either the number of channels present in the articular cartilage of a Safranin-O stained section of the medial tibial plateau using a $\times 20$ objective lens or the number of channels present per centimeter length of the medial tibial plateau. Channels were accepted as being in the cartilage if they had either entered into the cartilage or were fully touching it. To measure the length of the medial tibial plateau, an image was captured using a 3-CCD video camera for analysis with KS300 image analysis software. Colour transmitted light image of the medial tibial plateau was captured and converted automatically to monochrome image. The length was delineated using a line and measured. Osteochondral vascular density was determined by counting the number of channels containing Griffonia simplicifolia (GS-1) lectin labelled blood vessels crossing the osteochondral junction in a section across the medial tibial plateau.

2.8.3 Human Menisci

Meniscal degeneration was defined according to the modified Copenhaver classification based on change in appearance of collagen bundles (Copenhaver W 1978; Ishihara G 2009) using the following criteria:

Grade 0 = Homogeneous eosinophilic staining. Collagen bundles closely set with normal chondrocytes.

Grade 1 = Mild cleft formation of collagen bundles with irregular eosinophilic staining and reduction in the chondrocytes.

Grade 2 = Severe cleft and cyst formation of collagen bundles accompanied with hypocellular regions.

Appearance of collagen bundles was analysed separately within the outer and inner regions of the meniscus.

Vascularity using alpha actin staining was measured as percentage of tissue section area that was occupied by actin positive blood vessels ($\leq 150 \mu\text{m}$ diameter). Vascular densities were measured, using a $\times 4$ objective lens within each of 8 consecutive fields along the entire transverse midline from the inner tip towards the periphery, in all fields along the sagittal fibrocartilage junction between the inner and outer meniscal regions and within the synovium (Figure 2.9). Each field was 1.4 mm long and had an area of 1.68 mm^2 .

Numbers of CGRP positive nerve profiles that were associated with blood vessels in the outer region of the meniscus were counted at $\times 40$ objective lens in 6 fields of view that displayed the highest vascular densities with associated nerve profiles. Each field of view comprised an area of $16800 \mu\text{m}^2$. CGRP positive nerves were counted as associated with blood vessels if they were within $25 \mu\text{m}$ of the nearest vessel profile.

Synovial in-growth towards the tip of the meniscus was measured as the length (millimeter) of the synovium attached to the inner region of the meniscus (Figure 2.9). To measure the length, an image was captured using a 3-CCD video camera for analysis with KS300 image analysis software. Colour transmitted light image of the synovium attached to the inner region was captured and converted automatically to monochrome image. The length was delineated using a line and measured.

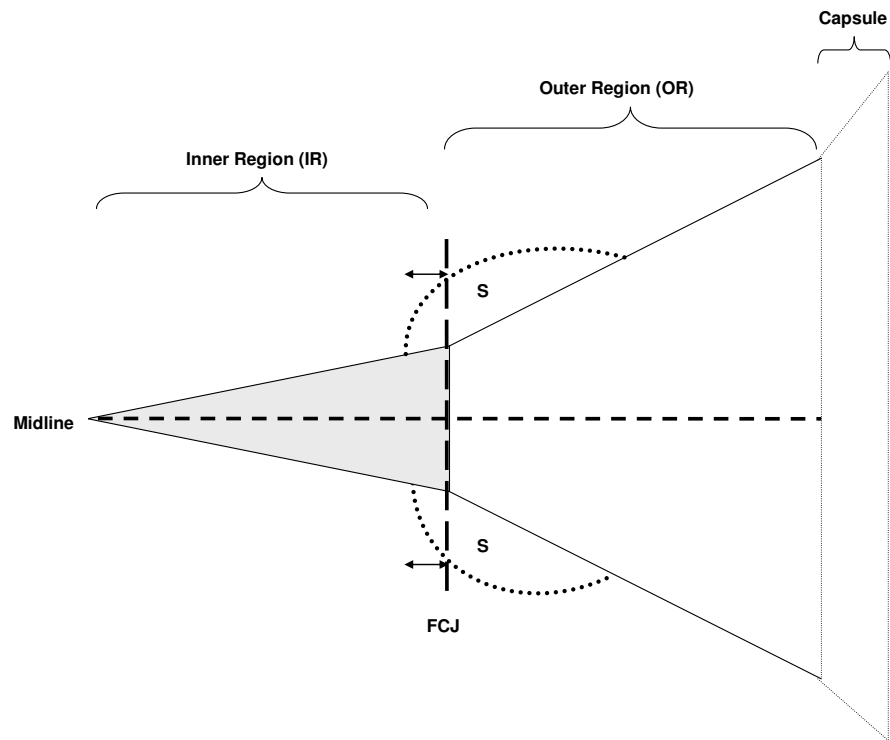


Figure 2.9: Diagram illustrating the method of quantifying meniscal vascularisation and nerve growth. Blood vessels were analysed (1) sequentially and within each consecutive field along the outer region of the entire fibrocartilage junction [(FCJ), vertical dashed line] separating the outer from the inner region, (2) along the entire midline (horizontal dashed line) of the meniscus, and (3) in the synovium (S) adjacent to the FCJ. Nerve profiles associated with blood vessels were analysed in the outer region (OR) of the menisci. The extent of synovial in-growth (arrows) towards the meniscal tip was measured in the inner region (IR).

2.9 Patient and sample selection for human menisci study

All procedures were approved by Nottingham Research Ethics Committee 1 (08/H0403/132). Knees were collected PM from patients following consent from next-of-kin (person identified by the patient or those accompanying the patient where the patient was incapacitated) (Walsh et al., 2003). The Academic Rheumatology joint tissue repository containing 288 PM cases was screened for cases displaying either high or low macroscopic chondropathy scores in the tibiofemoral joint as a measure of the presence and degree of OA (Walsh et al., 2009). Identification of meniscal nerves required special fixation of tissues, available for a subgroup of 52 repository cases. Cases did not have rheumatoid arthritis or other inflammatory joint diseases as determined by case notes review and interview with bereaved relatives.

2.9.1 Macroscopic chondropathy score of tibiofemoral joint

The extent and severity of loss of articular cartilage integrity for the medial and lateral femoral condyles and tibial plateaux were determined for each case by a single assessor, Roger Hill, at Kings Mill Hospital immediately following tissue harvesting (Walsh et al., 2009). Tibial and femoral plateaux were photographed from a fixed distance of 23 cm using a Kaiser RS 2 XA camera stand, under standard illumination with a Sony DSC-s85 CyberShot digital camera fitted with a Carl Zeiss lens at $\times 4$ zoom (Carl Zeiss Ltd., Welwyn Garden City, UK). Severity of chondropathy was analysed on the photographs and graded 0 to 4 as follows:

Grade 0 = Normal, smooth, unbroken surface, homogeneous white to off-white colour.

Grade 1 = Swelling and softening, a light brown homogeneous colouration.

Grade 2 = Superficial fibrillation, lightly broken surface, white to off-white/light brown in colour.

Grade 3 = Deep fibrillation, coarsely broken cartilage surface, dark brown, grey or red in colour.

Grade 4 = Subchondral bone exposure, stippled white and dark brown/red in colour.

The percentage of area of each articular surface that displayed each grade was estimated by delineating freehand on standardised diagrams of each articular surface the extent of each grade of surface change (Figure 2.10).

Chondropathy scores were calculated using the formula (Dougados et al., 1994; Walsh et al., 2009): $\text{Score} = (\text{Grade } 1 \times 0.14) + (\text{Grade } 2 \times 0.34) + (\text{Grade } 3 \times 0.65) + \text{Grade } 4$.

The scores (possible range 0 to 100) from each articular surface were summed to give a total score (possible range 0 to 400) for the joint, with 0 indicating no evidence of chondropathy. Forty cases (20 per group) were then selected for study of meniscal vascularity and 16 cases (8 per group) for the study of meniscal innervation, based on the following criteria:

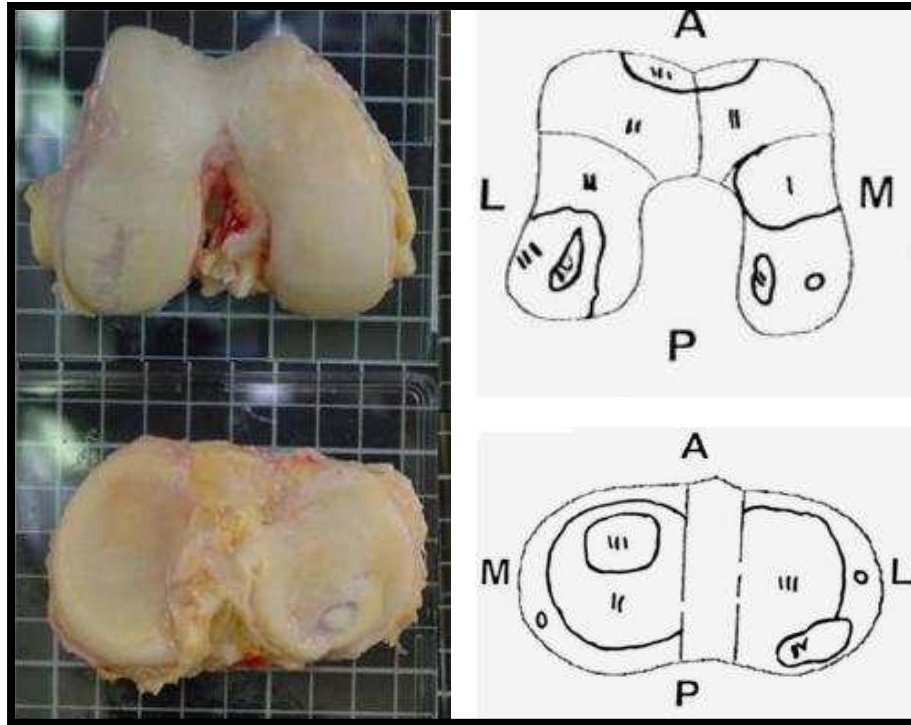
High chondropathy group

Knees were included on the basis of highest total joint chondropathy score plus, to maximise the likelihood of including cases with tibiofemoral OA, the presence of at least some grade 3 or 4 chondropathy in the medial compartment.

Low chondropathy group

Knees were included on the basis of lowest total joint chondropathy score plus, in order to minimise the risk of including cases with medial compartment OA, the absence of grade 3 or grade 4 chondropathy in either the medial or lateral compartment.

Only medial menisci were examined for this study. Patient criteria for choosing the samples are given in Figure 2.11. Figure 2.12 shows the spread of age and the associated macroscopic chondropathy scores of 200 consecutive PM cases within the repository from which the samples were selected.



Grade	Tibial plateaux		Femoral condyles	
	Lateral	Medial	Medial	Lateral
I	15	—	—	80
II	15	—	—	20
III	30	55	30	—
IV	—	45	40	—

Figure 2.10: Severity of chondropathy determined macroscopically on post mortem samples of tibiofemoral joints. Digital photographs of femoral condyles and tibial plateaux are shown with their respective schematic diagrams, highlighting the extent of each grade of surface appearance. Table of the estimated percentage of joint surface attributed to each grade is also shown (Walsh et al., 2009). A = anterior, P = posterior, L = lateral and M = medial.

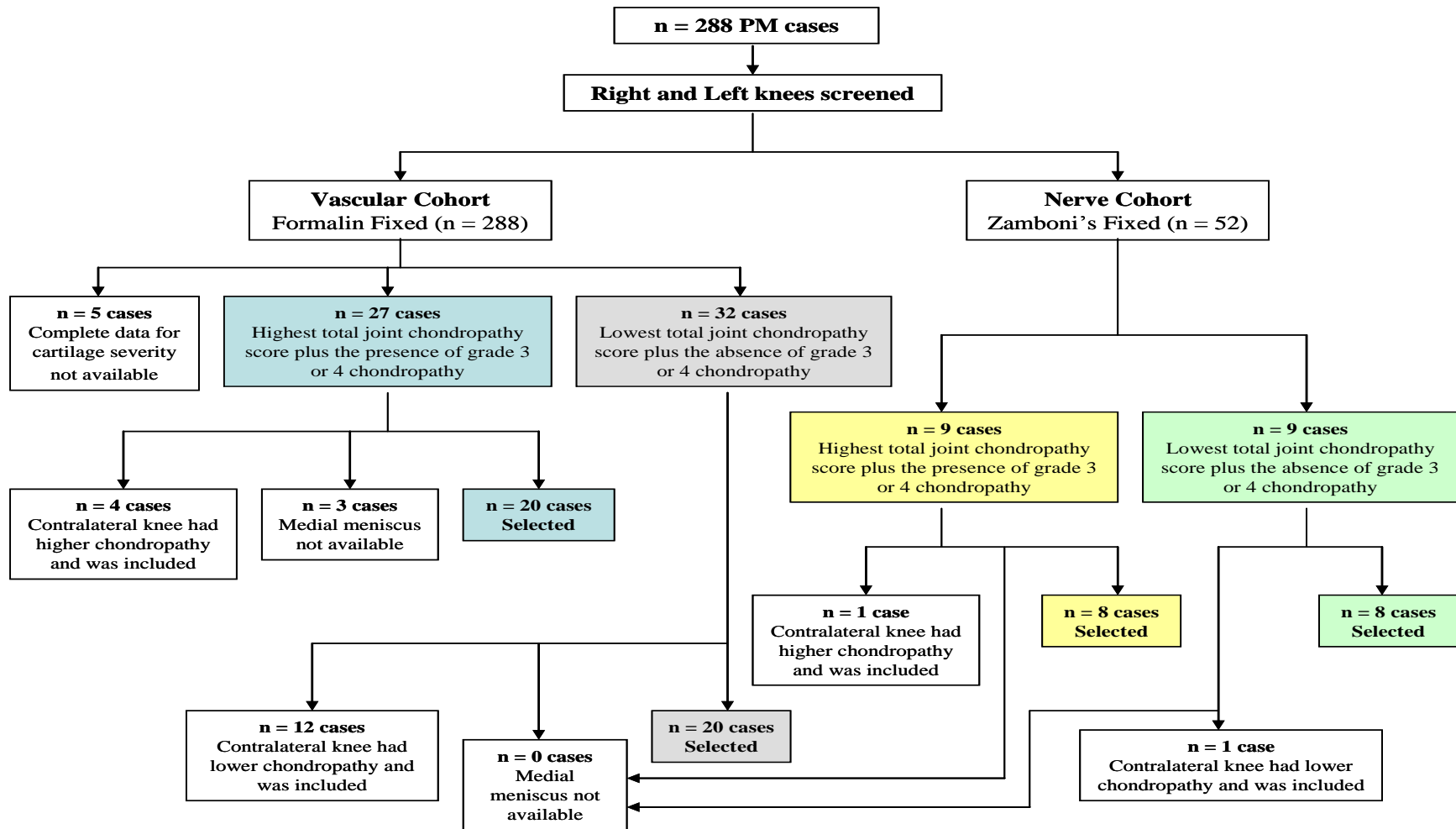


Figure 2.11 Sample selection criteria for human meniscal study.

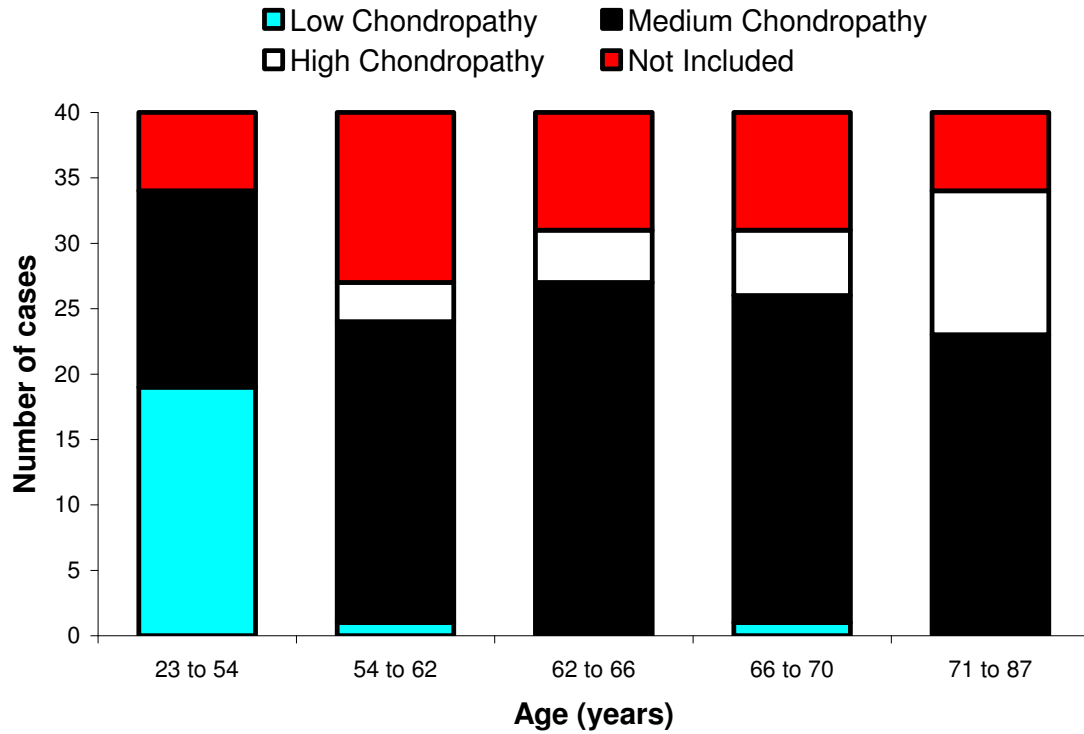


Figure 2.12 The spread of age and the associated macroscopic chondropathy scores of 200 consecutive PM cases within the Academic Rheumatology joint tissue repository,

2.10 Statistical analysis

Four fields per section and one section per case were used for synovial macrophage infiltration and endothelial cell proliferation data. For synovial endothelial fractional area (measure of vascular density) four consecutive sections per case with four fields of view per section were used. This optimal number was determined in previous experiments to minimise the coefficient of variation and so that the observed mean lies within $\pm 12.5\%$ of the true mean (Walsh et al., 1998).

Data were analysed using Statistical package for the Social Sciences v.16 (SPSS inc., Chicago, Illinois, USA) and graphically presented using GraphPad Prism Version 4.03 Software (GraphPad Software, Inc., SanDiego CA, USA). Parametric data (endothelial cell PCNA indices, and endothelial and macrophage fractional areas [logarithmically transformed], incapacitance and knee diameter) were analysed using one-way analysis of variance (ANOVA). Univariate comparisons were made using Student's t-test with Bonferroni's correction for multiple comparisons. Non-parametric data (joint damage scores and osteochondral vascularity) were analysed using Kruskal-Wallis test followed by Mann-Whitney to compare two groups with Bonferroni's correction for multiple comparisons. For the meniscal data, comparisons between groups were made using the Mann Whitney U test and associations between variables expressed as Spearman's correlation coefficients.

Numerical data are quoted as mean (95% confidence interval) or median (Interquartile Range [IQR]) in the text, and, for clarity, graphically as mean \pm standard error of the mean (S.E.M) unless otherwise stated. A two-tailed $P < 0.05$ was taken to indicate statistical significance.

2.11 Reagents

Monoclonal antibody to PCNA (clone PC10) was obtained from DAKO Ltd. (High Wycombe, UK). Biotinylated rat-adsorbed horse anti-mouse antibody, biotinylated goat anti-rabbit secondary antibodies, lectin GS-1 (L1100), goat anti-lectin (AS 2104), biotinylated rabbit anti-goat (BA 5000) and avidin-biotin complexes (ABC Kits) were obtained from Vector Laboratories Ltd. (Peterborough, UK). Monoclonal antibodies to rat CD31 (Platelet endothelial cell adhesion molecule 1[PECAM-1]) antibody (clone TLD-3A12) and to macrophages (clone ED1) were from Serotec Ltd. (Oxford, UK). Polyclonal anti- α CGRP (human) antibody (Ref: T-4239) was from Peninsula Labs Inc (St. Helens, UK). FGF-2 was purchased from Invitrogen LTD. (Paisley, UK). DePeX mounting medium and PBS were from VWR Ltd (Lutterworth, UK). OCT compound and Mayers haematoxylin and eosin were from Raymond Lamb (Eastbourne, UK). Monoclonal mouse antibody to alpha actin (clone 1A4), saline, λ -Carrageenan, DAPI, BSA, Tris, EDTA, HP β CD, neutral buffered formalin, formic acid and other chemicals were obtained from Sigma-Aldrich (Poole, UK). PPI-2458 was a kind donation of GlaxoSmithKline (Middlesex, UK).

3 ROLE OF ANGIOGENESIS IN INFLAMMATION AND PAIN IN TWO RAT MODELS OF SYNOVITIS

3.1 Introduction

Inflammation is normally a protective response to pathogenic, traumatic or toxic injury, reducing tissue damage and leading to resolution or repair (Benelli et al., 2006). Despite the traditional classification of arthritis as inflammatory (e.g. rheumatoid arthritis [RA]) or non-inflammatory (e.g. osteoarthritis [OA]), inflammation is increasingly recognized as an important feature in OA (Ashraf et al., 2008). Persistent inflammation itself causes tissue damage (Charo et al., 2006) but the mechanisms by which inflammation persists rather than resolves remain incompletely understood. Arthritis is a major health problem worldwide, leading to pain and disability in the ageing populations (Reginster et al., 2002; Brooks 2006; Reyes-Llerena et al., 2009). Defining factors which lead to persistent inflammation, a prominent feature of arthritis should lead to novel therapies, reducing the burden of this debilitating condition by facilitating resolution or repair.

Angiogenesis is tightly regulated during normal growth, wound healing and the female reproductive cycle. Increased angiogenesis in the synovium is associated with chronic synovitis in OA (Haywood et al., 2003). Angiogenesis within the inflamed synovium is also typical of both early and established RA (Griffioen et al., 2000; El-Gabalawy 2005; Klareskog et al., 2009). In chronic synovitis, a shift in the balance from anti-angiogenic to angiogenic factors promotes endothelial cell proliferation and blood vessel growth (O'Connell 2000). Chronic inflammation maintains blood vessel growth by the secretion of angiogenic factors from macrophages and various other cells (Jackson et al., 1997). Synovial angiogenesis can further facilitate inflammation by increasing plasma extravasation and enhancing inflammatory cell recruitment (Bonnet et al., 2005; Costa et al., 2007).

The FGF system plays an important role in angiogenesis and the maintenance of vascular integrity (Presta et al., 2005; Murakami et al., 2008). FGF-2 promotes EC proliferation and the physical organisation of ECs into tube-like structures. It also stimulates the proliferation of fibroblasts that give rise to granulation tissue in wound healing (Bussolino et al., 1996). FGF-2-induced angiogenesis occurs in the absence of inflammation (Folkman et al., 1991; Zittermann et al., 2006) a characteristic which distinguishes it from many other angiogenic factors such as VEGF.

The 2 MetAP isoforms; MetAP-1 and MetAP-2 are co-translational regulators of protein synthesis. MetAPs remove the initiator methionine from growing polypeptide chains, a prerequisite for a variety of biological processes such as protein stability (Kusaka et al., 1994; Sin et al., 1997). Inhibition of MetAP-2 prevents the selective removal of the N-terminal methionine and potently inhibits EC proliferation; a prominent mechanism in angiogenesis. PPI-2458 is an anti-angiogenic fumagillin analogue that is an orally

active irreversible inhibitor of MetAP-2 via covalent modification of His-231 in the catalytic site of the enzyme. This triggers growth arrest of ECs in the late G1 phase of the cell cycle, inhibiting EC proliferation and angiogenesis without affecting inflammatory cytokine release (Griffith et al., 1997; Sin et al., 1997; Bainbridge et al., 2007) or inducing apoptosis in ECs (Bernier et al., 2004). PPI-2458 has reduced toxicity and greater selectivity for angiogenesis inhibition versus inflammation compared to another fumagillin analogue AGM-1470/TNP470 (Bernier et al., 2004; Brahn et al., 2009).

PPI-2458 reduces synovitis and bone and cartilage damage in collagen-induced arthritis (CIA) in mice and peptidoglycan polysaccharide (PGPS)-induced arthritis in rats (Bainbridge et al., 2007; Lazarus et al., 2008). Those studies and studies of other anti-angiogenic strategies (Peacock et al., 1992; Abe et al., 1994; Kusaka et al., 1994; Storgard et al., 1999; Clavel et al., 2003) indicate that angiogenesis inhibition may have therapeutic potential in arthritis in humans. However, sustained angiogenesis inhibition for the treatment of arthritis may lead to adverse events due to the blockade of physiological blood vessel growth such as impaired wound healing. An anti-angiogenic strategy targeted to key phases in the development of chronic inflammation may have a more favourable risk: benefit ratio.

Intra-articular injection (100µl) of high dose (2%) of carrageenan induces chronic synovitis with angiogenesis, whereas a low dose (0.03%) of carrageenan induces resolving synovitis without angiogenesis (Walsh et al., 1998). Since when synovitis persists it is accompanied by synovial angiogenesis, it led us to hypothesise that angiogenesis during the early phase of synovitis may be a key factor in determining its persistence, and, where this is the case, that a brief treatment with an angiogenesis inhibitor (PPI-2458) during the onset of arthritis could prevent its subsequent persistence.

3.2 Aims

1. To evaluate if a short course of the angiogenesis inhibitor PPI-2458 makes 2% carrageenan induced chronic synovitis and pain more transient.
2. To deduce the dose of FGF-2 that induces synovial angiogenesis without inflammation.
3. To determine at what time point after injection of FGF-2, synovial angiogenesis returns to levels similar to those in naïve controls.
4. To deduce the dose of carrageenan that induces synovial inflammation without angiogenesis.
5. To determine at what time point after injection of carrageenan, synovial inflammation returns to levels similar to those in naïve controls.
6. To evaluate the combined effects of FGF-2 and carrageenan on synovial angiogenesis and inflammation
7. To evaluate the dose-response effects of PPI-2458 on angiogenesis
8. To evaluate the effects of inhibiting angiogenesis (using PPI-2458) on the transition from acute to persistent synovitis (using combined injection of carrageenan and FGF-2) to model both inflammation and angiogenesis, as seen in early synovitis.

3.3 Methods

General methodology is given in Chapter 2. Experiments were performed on male Wistar rats (Charles River, Margate, Kent, UK) weighing 150-180 gm.

3.3.1 Short-term angiogenesis inhibition using PPI-2458 and 2% carrageenan-induced synovitis

To evaluate if a short course of the angiogenesis inhibitor PPI-2458 makes 2% carrageenan induced chronic synovitis and pain more transient, on day 0 animals were given intra-articular injection of 2% carrageenan into their left knee joints cavities. Starting on day -1, and then every other day until day 9, animals were given an oral dose of 500µl of either 5mg/kg of the angiogenesis inhibitor PPI-2458 or vehicle control buffer. This treatment regime was chosen based on previously published data where it was shown that after 2% carrageenan injection the increases in synovial macrophage fractional area and EC PCNA index started to subside by day 14 to 28 (Walsh et al., 1998).

Synovia (n = 6 per treatment group) were harvested on day 3, 10 and 24 after injection. Naïve animals were used as baseline controls. Weights, knee diameter and incapacitance (n = 8 per treatment group) measurements were monitored throughout the experiment (Figure 3.1).

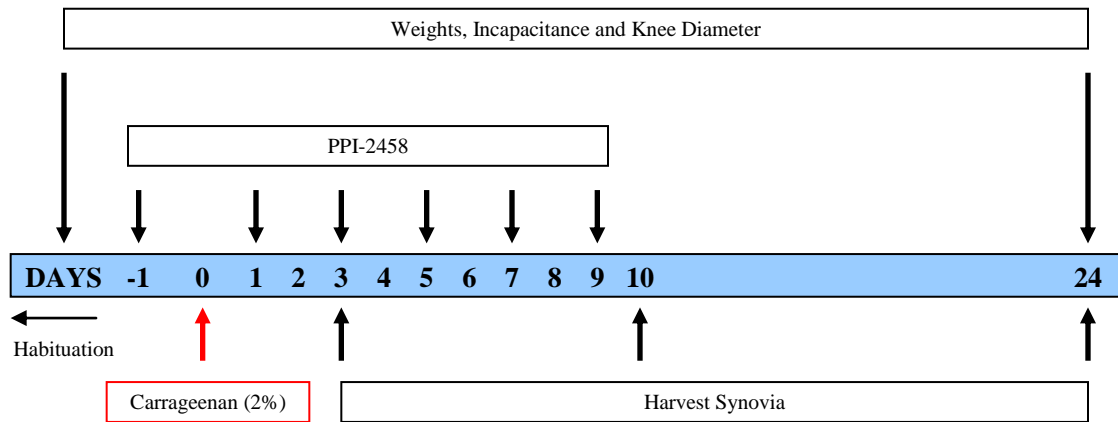


Figure 3.1 Experimental plan to investigate whether a short course of the angiogenesis inhibitor PPI-2458 [administered every other day starting a day before the intra-articular injection of 2% carrageenan (day 0) to day 9] curtails 2% carrageenan-induced synovitis and pain behaviour. Animals were habituated in the incapacitance meter before collecting weight bearing (pain) measurements. Joint tissues were harvested at day 24. At various time-points during the experiment, weights, knee diameters and incapacitance measurements of the animals were recored.

3.3.2 Intra-articular injections of FGF-2 and/or carrageenan

To deduce the dose of FGF-2 that enables synovial angiogenesis without inflammation, on day 0 animals (n = 2 per treatment group) were given bilateral intra-articular injections in their knee joint cavities in the dose range of 6×10^{-4} to 6 picomoles (pmoles) of FGF-2 or 10 mM Tris (pH 7.6) containing 0.1% BSA vehicle control. Synovia were collected on day 1.

In order to confirm the previous findings that 0.03% carrageenan induces synovial inflammation without angiogenesis (Walsh et al., 1998), on day 0 animals (n = 2 per treatment group) were given bilateral intra-articular injections in their knee joint cavities in the dose range 3×10^{-4} to 3×10^{-2} % of carrageenan or sterile 0.9% normal saline control (pH 7.4). Synovia were collected on day 1 (Figure 3.2).

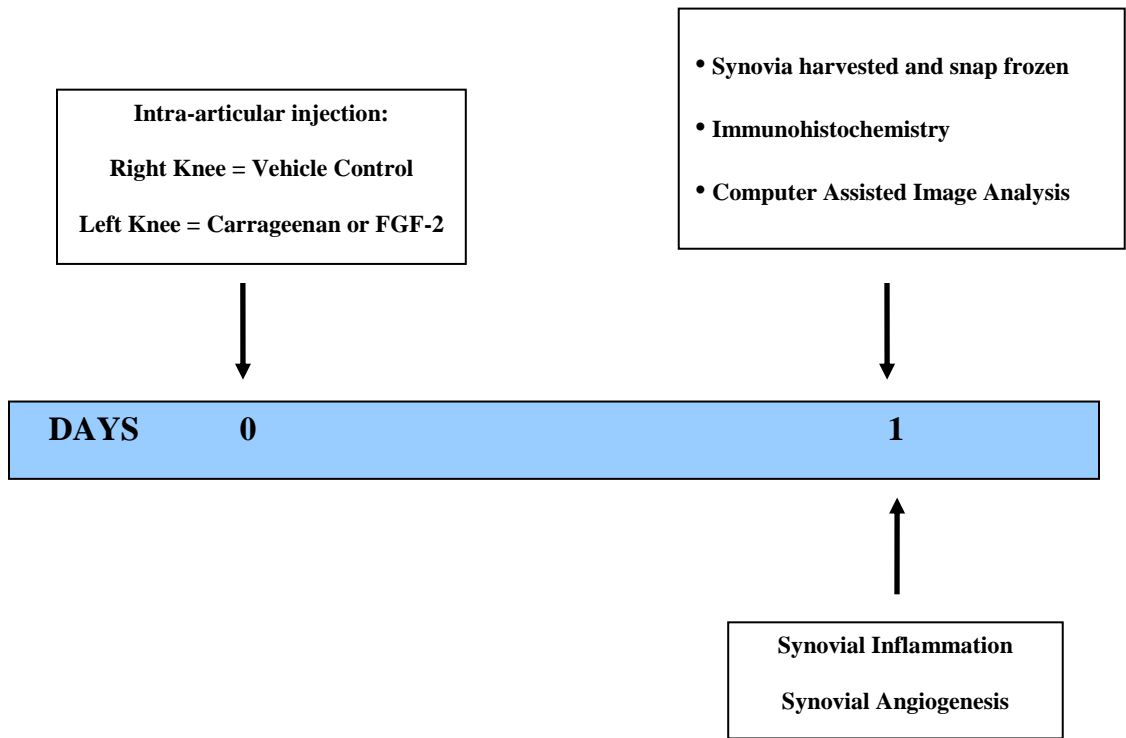


Figure 3.2 Diagram showing the experimental plan of how the doses of FGF-2 and/or carrageenan compounds to be used in this study in inducing angiogenesis/inflammation were selected. Briefly, intra-articular injections of various doses of either carrageenan or FGF2 were given on day 0, 24 hours after the injection (day 1) synovia was harvested and snap frozen. Immunohistochemistry and computer assisted image analysis techniques were used to detect and analyse synovial inflammation and angiogenesis.

To determine at what time point after the injection of 6 pmoles of FGF-2 synovial angiogenesis returns to levels similar to those in naïve controls, on day 0 bilateral intra-articular injection of 6 pmoles of FGF-2 were given into the animals knee joint cavities (n = 3 per group). Synovia were collected from naïve controls and on days 1, 2 and 5 after injection (Figure 3.3).

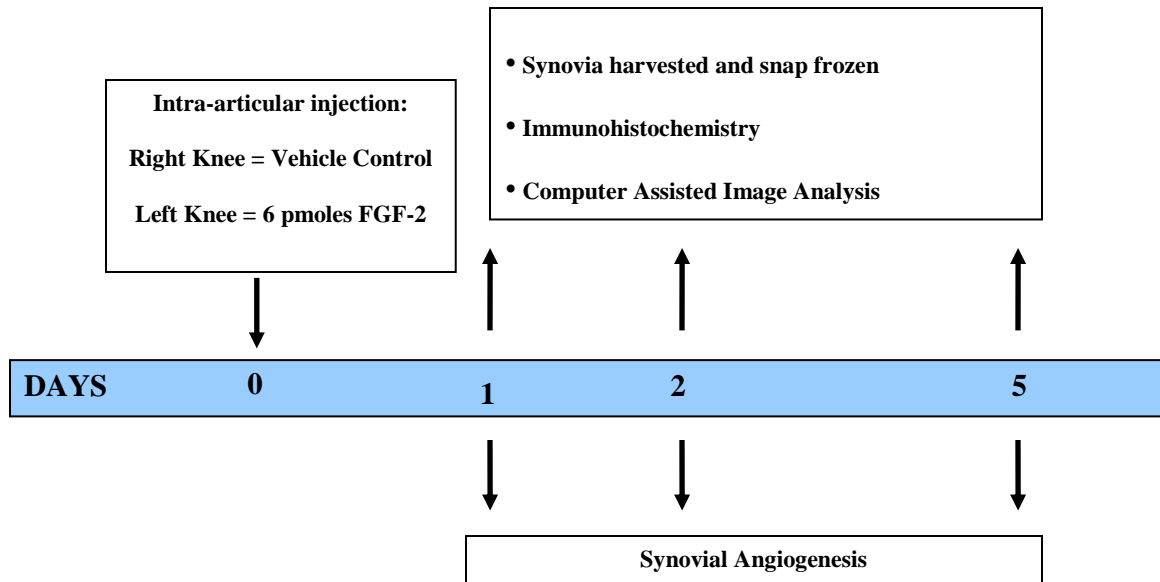


Figure 3.3 Diagram showing the experimental plan to determine the time point after the injection of 6 pmoles of FGF-2 that synovial angiogenesis returned to levels similar to those in naïve controls. Briefly, at each time point, synovia were harvested and snap frozen. Immunohistochemistry and computer assisted image analysis techniques were used to detect and analyse synovial angiogenesis.

To investigate the combined effects of FGF-2 and carrageenan, on day 0, animals (n = 6 per treatment group) were given intra-articular injections of either 0.03% carrageenan or 0.03% carrageenan and 6 pmoles of FGF-2 in their left knee joint cavities and appropriate control treatments (sterile 0.9% normal saline [pH 7.4] or 10mM Tris [pH 7.6] containing 0.1% BSA) in their right knee joint cavities. FGF-2 was injected first, followed by carrageenan after 30 minutes. Control injections were given in a similar manner (Figure 3.4).

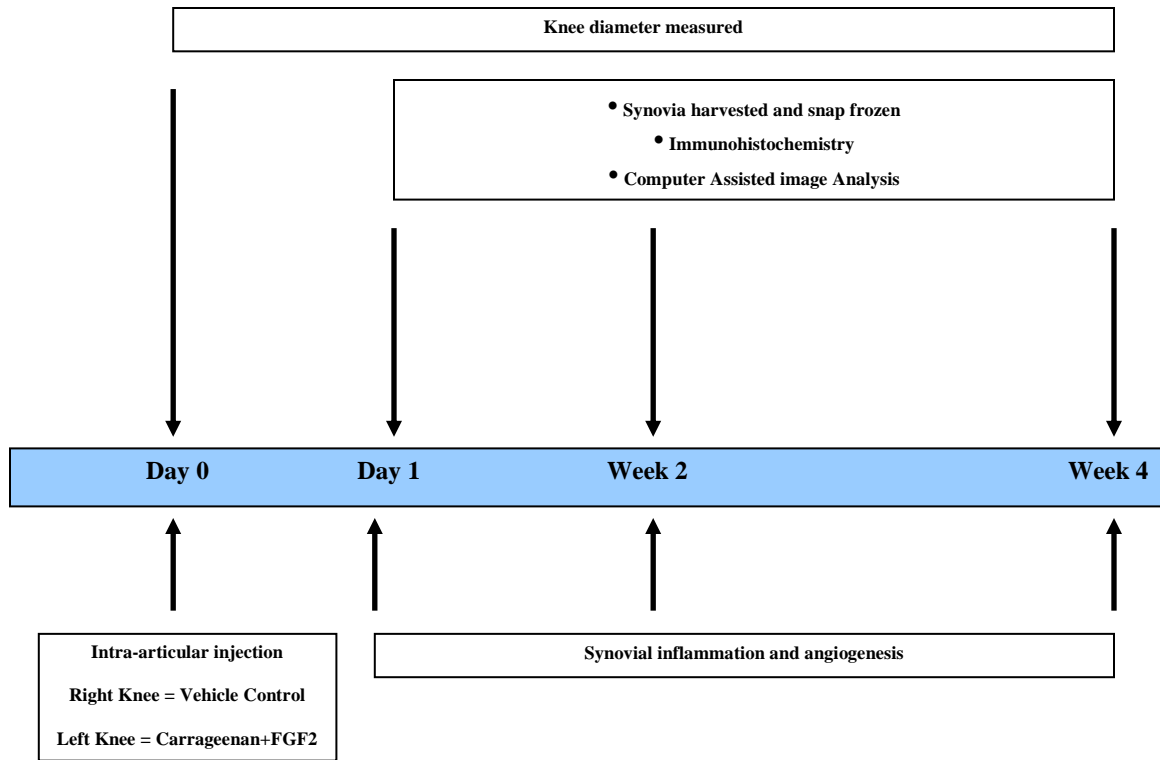


Figure 3.4 Diagram showing the experimental plan used to elucidate the combined effects of FGF-2 and carrageenan on angiogenesis and inflammation. Briefly, after intra-articular injection of either 0.03% carrageenan or 0.03% carrageenan and 6 pmoles of FGF-2, at each time point, synovia were harvested and snap frozen. Immunohistochemistry and computer assisted image analysis techniques were used to detect and analyse synovial inflammation and angiogenesis. Knee diameter was also measured at each time point.

3.3.3 Dose-response effects of PPI-2458 on angiogenesis induced by FGF-2

In-order to select the appropriate dose of PPI-2458 that best inhibited 6 pmoles FGF2-induced angiogenesis, on day -1, animals (n = 3 per treatment group) were given either a 500µl single oral dose of the angiogenesis inhibitor PPI-2458 at either 5mg/kg, 0.5mg/kg, 0.05mg/kg or vehicle control (11% HPβCD [2 hydroxy propyl β cyclodextrin] buffer in PBS). Bilateral intra-articular injections of 6pmoles FGF-2 were given into knee joint cavities on day 0 and the synovia (n=6 per treatment group) were harvested on day 1 (Figure 3.5). Naïve animals (n = 3) were used as the control group.

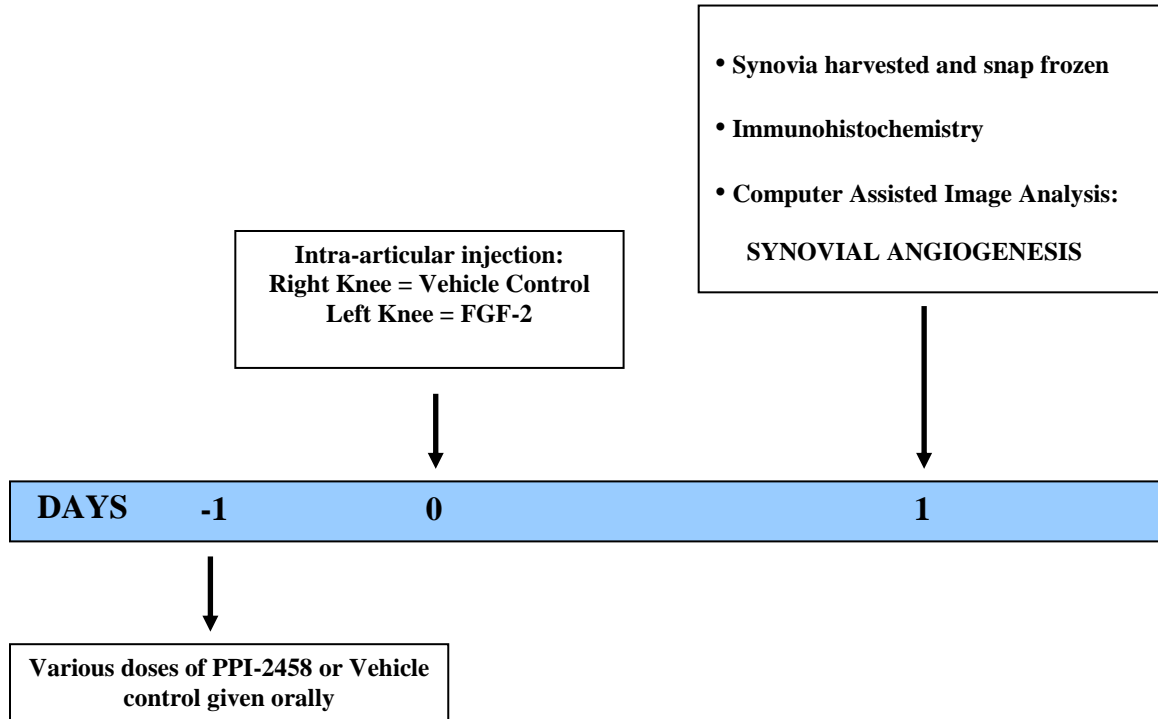


Figure 3.5 Diagram showing the experimental plan of how the dose-response effects of PPI-2458 on FGF-2 induced angiogenesis were analysed. Briefly, various doses (5mg/kg, 0.5mg/kg, 0.05mg/kg) of the angiogenesis inhibitor were given a day before the intra-articular injection of either 6 pmoles of FGF-2 or vehicle control. A day after the injection, synovia was harvested and snap frozen. Immunohistochemistry and computer assisted image analysis techniques were used to detect and analyse synovial angiogenesis.

3.3.4 PPI-2458 and intra-articular injection of FGF-2 and carrageenan

On days -1, 1 and 3, animals (n = 6 per treatment group) were given an oral dose of 500µl of either 5mg/kg of PPI-2458 or vehicle control buffer (Lazarus et al., 2008). Intra-articular injections of 0.03% carrageenan & 6 pmoles FGF-2 (left knee joint cavity) or the appropriate vehicle control (sterile 0.9% normal saline [pH 7.4] or 10mM Tris [pH 7.6] containing 0.1% BSA) (right knee joint cavity) were given at day 0. Synovia was harvested at day 1, week 1 and week 4 (Figure 3.6).

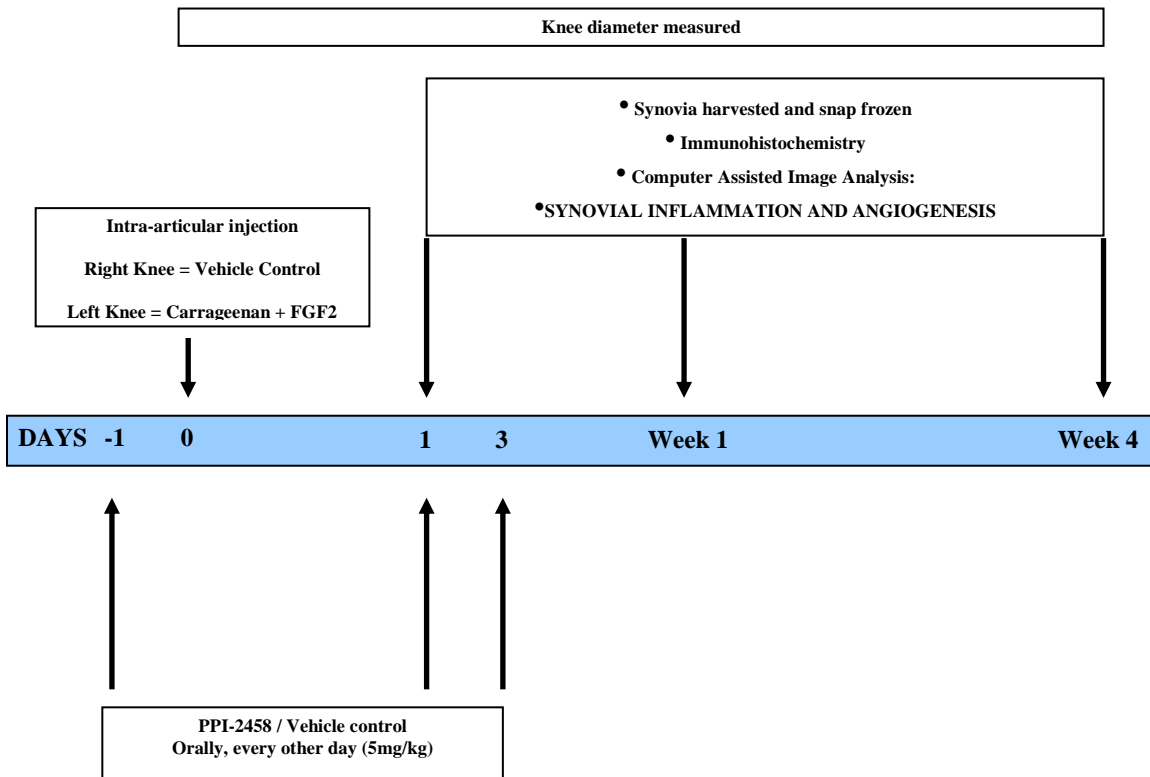


Figure 3.6 Diagram showing the experimental plan of how the effects of PPI-2458 on the ongoing inflammatory response after intra-articular injection of FGF-2 and carrageenan were investigated. Briefly, intra-articular injection of 0.03% carrageenan and 6 pmoles of FGF-2 were given on day 0. Angiogenesis inhibitor PPI-2458 was administered every other day, starting a day before the injection to day 3. At each time point, synovia were harvested and snap frozen. Immunohistochemistry and computer assisted image analysis techniques were used to detect and analyse synovial inflammation and angiogenesis. Knee diameter was also measured at each time point.

3.3.5 Tissue collection and preparation

At each time-point after intra-articular injections (days 3, 10 and 24 for 2% carrageenan; days 1, 2 and 5 for FGF-2; days 1, 14 and 29 for 0.03% carrageenan; days 1, 7, 14, 28 and 29 for FGF-2 and carrageenan combined; day 1 for PPI-2458 and FGF-2; and days 1, 7 and 28 for PPI-2458 and FGF-2 and carrageenan combined) synovia with patellae from right and left knees were immediately harvested.

3.4 Results

3.4.1 Synovial inflammation, angiogenesis and pain behaviour after intra-articular injection of 2% carrageenan and administration of the angiogenesis inhibitor PPI-2458

ED1-immunoreactive macrophages were localised to the synovial lining, and dispersed throughout the synovial sub-lining regions (Figure 3.7 A-C). CD31-immunoreactive blood vessels were distributed throughout the depth of rat synovia, sometimes containing PCNA-immunoreactive nuclei (Figure 3.7 E-G). Synovia from animals given a single intra-articular injection of 2% carrageenan showed increased staining for macrophages, proliferating ECs and EC fractional area. These increases were reduced by day 24 after the administration of 6 doses of PPI-2458 (5mg/kg/every other day) starting a day before the intra-articular injection to day 9.

3.4.1.1 Inflammation

Intra-articular injection of 2% carrageenan treated with vehicle control, was followed by an increase in synovial macrophage fractional area, which was reduced at day 10 by the administration of 6 doses of the angiogenesis inhibitor PPI-2458 [Vehicle: 23% (95% CI 15 to 30), PPI-2458: 8% (95% CI 2 to 15), $P < 0.01$]. The levels however did not reach those of naïve controls [PPI-2458: 8% (95% CI 2 to 15), Naives: 1.1% (95% CI 0.8 to 1.4), $P < 0.001$]. This reduction was maintained to day 24 with-out the levels reaching to those of naïve controls (Figure 3.8 A). Knee joint diameter (joint swelling) was transiently increased following intra-articular injection of 2% carrageenan and then gradually reduced to naïve control levels by day 24. PPI-2458 did not reduce knee joint swelling following intra-articular injection of 2% carrageenan (Figure 3.8 B).

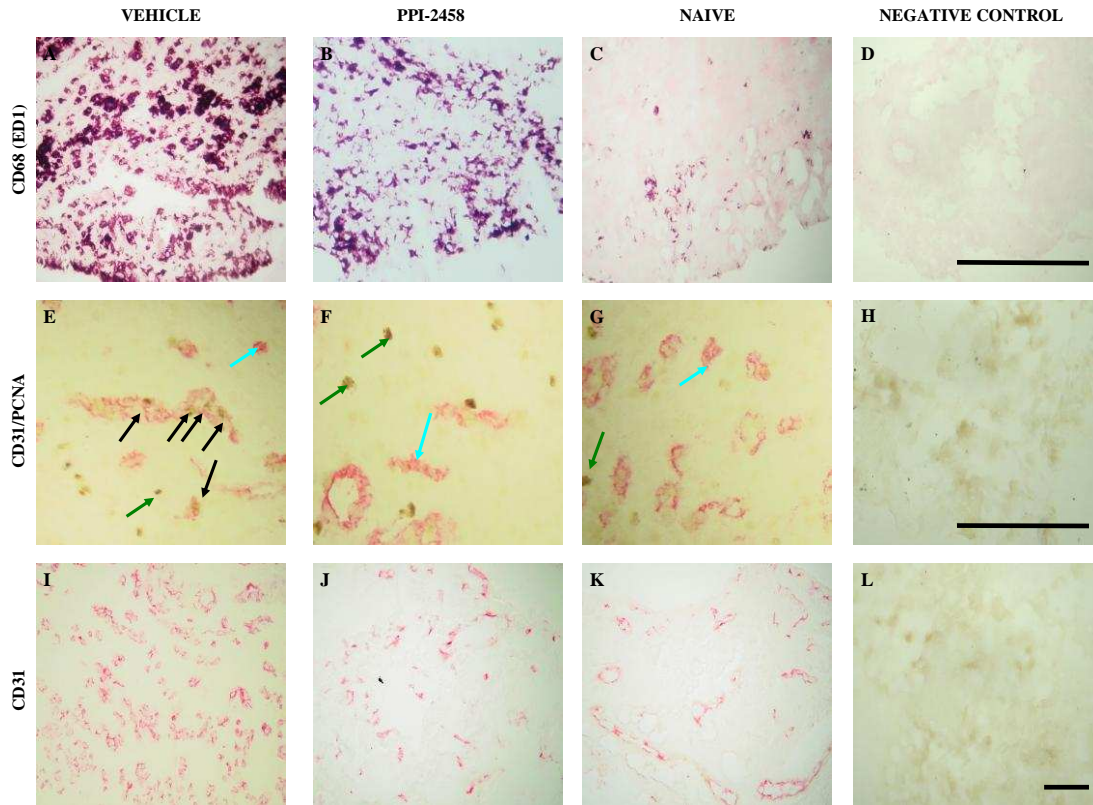


Figure 3.7 Histological evidence of synovial macrophage infiltration, angiogenesis and vascular density after intra-articular injection of 2% carrageenan and effects of oral administration of a short course of either PPI-2458 or vehicle control. Panels show macrophage infiltration (**A-C**), endothelial cell proliferation (**E-G**) and vascular density (**I-K**) 24 days after intra-articular injection of 2% carrageenan. Intra-articular injection of 2% carrageenan induced synovial macrophage infiltration (**A**), angiogenesis (**E**) and vascular density (**I**). Synovial macrophage infiltration was reduced following treatment with the angiogenesis inhibitor PPI-2458 (**B**, 5mg/kg/every other day from a day before intra-articular injection of carrageenan to day 9) but not to naïve control levels (**C**). Synovial angiogenesis and vascular density were reduced by the administration of the anti-angiogenic agent PPI-2458 (**F** and **J** respectively), to naïve control levels (**G** and **K**). **A-C**; macrophages are delineated by immunoreactivity for CD68 (ED1). Negative control section for CD68 (ED1) immunohistochemistry did not show any non-specific staining (**D**). Endothelial cells are delineated in red by immunoreactivity for CD31 [**blue arrows (I-K)**] and proliferating nuclei are delineated black by immunoreactivity for proliferating cell nuclear antigen (PCNA; **green arrows**). **Black arrows** indicate proliferating endothelial cells which contain PCNA-immunoreactive nuclei. Negative control sections for CD31 and/or PCNA immunohistochemistry did not show any non-specific staining (**H** and **L**). Colour transmitted light images were taken using $\times 10$ (**I-L**) and $\times 20$ (**A-H**) objective lenses of a single representative section from $n = 8$ animals per group. Scale bar = 100 μm .

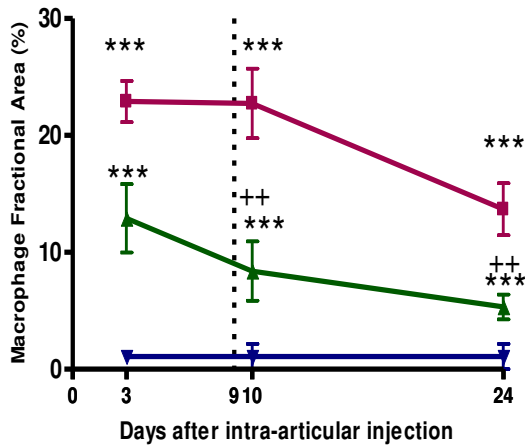
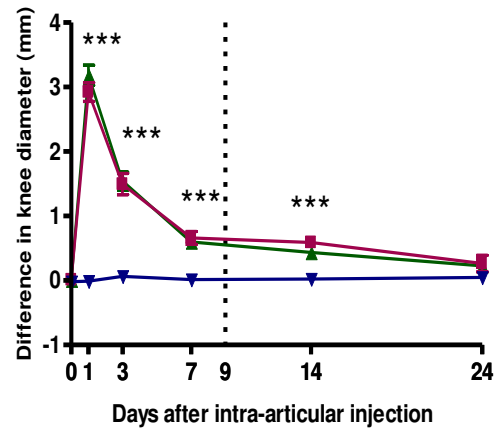
A**B**

Figure 3.8 Inhibition of measures of inflammation (synovial macrophage infiltration and joint swelling) after 2% carrageenan injection in either PPI-2458 or vehicle treated animals. Intra-articular injection was given in rat knee joint cavities on day 0. Oral administration of either PPI-2458 (5mg/kg/every other day) or vehicle control was given from a day before the injection to day 9 (**dotted line** marks the end of PPI-2458 treatment). Synovia were harvested 3, 10 and 24 days after the injection. Intra-articular injection of 2% carrageenan (■) was followed by an increase in synovial macrophage infiltration (**A**) and joint swelling (**B**). These increases were higher than the naïve controls (▼) throughout the experiment. Administration of PPI-2458 (▲) reduced synovial macrophage infiltration from day 10 to 24 but not to naïve control level. PPI-2458 had no effect on knee joint swelling. Graphs show arithmetic mean and \pm S.E.M of 8 knees per group. Macrophage fractional areas (logarithmically transformed) and knee diameters were analysed using one way analysis of variance (ANOVA). Univariate comparisons were made using Student's T-test with Bonferroni's correction for multiple comparisons. *** P < 0.001 versus naïve controls. ++ P < 0.01 versus vehicle controls.

3.4.1.2 Angiogenesis

Synovial EC PCNA index was reduced by day 3 following 2 doses of the angiogenic compound PPI-2458 [1.7% (95% CI 0.8 to 2.6)] compared with vehicle treated animals [6.7% (95% CI 5.3 to 8.2), $P < 0.001$] and this reduction was completely abolished to naïve control levels from day 10 to 24. Increase in synovial endothelial cell fractional area following 2% carrageenan injection was however reduced to naïve levels by day 24 in PPI-2458 treated animals (Figure 3.9).

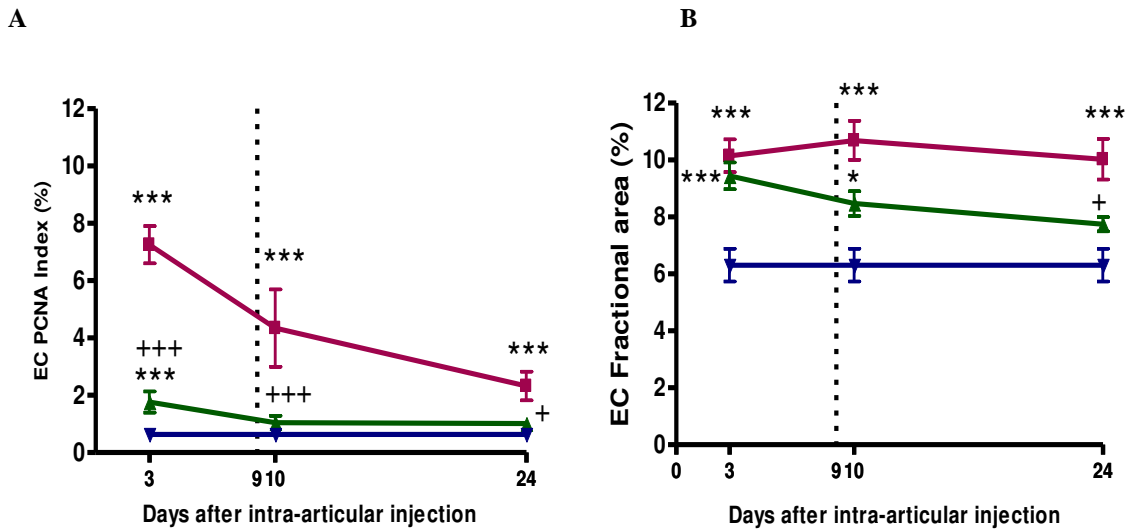


Figure 3.9 Inhibition of synovial angiogenesis (EC proliferation and vascular density) after 2% carrageenan injection in either PPI-2458 or vehicle treated animals. Intra-articular injection was given in rat knee joint cavities on day 0. Oral administration of either PPI-2458 (5mg/kg/every other day) or vehicle control was given from a day before the injection to day 9 (dotted line marks the end of PPI-2458 treatment). Synovia were harvested 3, 10 and 24 days after the injection. Intra-articular injection of 2% carrageenan (■) was followed by an increase in EC proliferation index (A; EC PCNA index) and vascular density (B; EC fractional area). These increases were higher than the naïve controls (▼) throughout the experiment. Administration of PPI-2458 (▲) reduced EC proliferation on day 3, with levels reaching those of controls by day 10. This reduction was maintained to day 24 (A). Synovial vascular density was reduced by day 10 after administration of PPI-2458, with levels reaching those of controls by day 24 (B). Graphs show arithmetic mean and \pm S.E.M of synovia from 8 knees per group. EC PCNA Index and fractional areas (logarithmically transformed) were analysed using one way analysis of variance (ANOVA). Univariate comparisons were made using Student's T-test with Bonferroni's correction for multiple comparisons. * $P < 0.05$, *** $P < 0.001$ versus naïve controls. + $P < 0.05$, +++ $P < 0.001$ versus vehicle controls.

3.4.1.3 Pain Behaviour

Pain behaviour as measured by difference in weight bearing was reduced by day 7 following treatment with PPI-2458 [12g (95% CI 6 to 18)] compared to vehicle treated animals [32g (95% CI 18 to 46), $P < 0.05$]. Pain behaviour was reduced to levels observed in naïve controls by day 10. This reduction was maintained to day 24 (Figure 3.10).

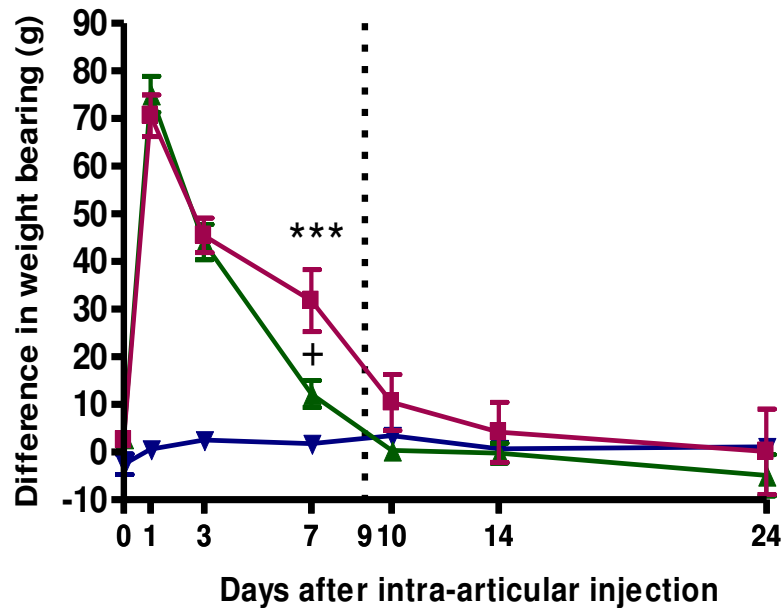


Figure 3.10 Time course of the inhibition of knee joint pain after 2% carrageenan injection in either PPI-2458 or vehicle treated animals. Intra-articular injection was given in rat knee joint cavities on day 0. Oral administration of either PPI-2458 (5mg/kg/every other day) or vehicle control was given from a day before the injection to day 9 (dotted line marks the end of PPI-2458 treatment). Pain behaviour was measured as a difference in hind paw weight bearing between 0 to 24 days after intra-articular injection. Intra-articular injection of 2% carrageenan (■) was followed by an increase in pain behaviour which was reduced to naïve (▼) levels by day 10. Administration of PPI-2458 (▲) reduced pain behaviour by day 7, and completely abolished it to naïve levels by day 10. Bars show arithmetic mean and \pm S.E.M of synovia from 8 knees per group. Differences between groups were analysed using one way analysis of variance (ANOVA). Univariate comparisons were made using Student's T-test with Bonferroni's correction for multiple comparisons. *** $P < 0.001$ versus naïve controls. + $P < 0.05$ versus vehicle controls.

3.4.1.4 Weights

Animals treated with the angiogenesis inhibitor gained weight at a slower rate from day 7 to day 24 compared to vehicle treated animals and to naïve controls. However by day 24, the difference in weight gain between the animals from the three treatment groups had narrowed but not completely abolished (Figure 3.11 and Table 1).

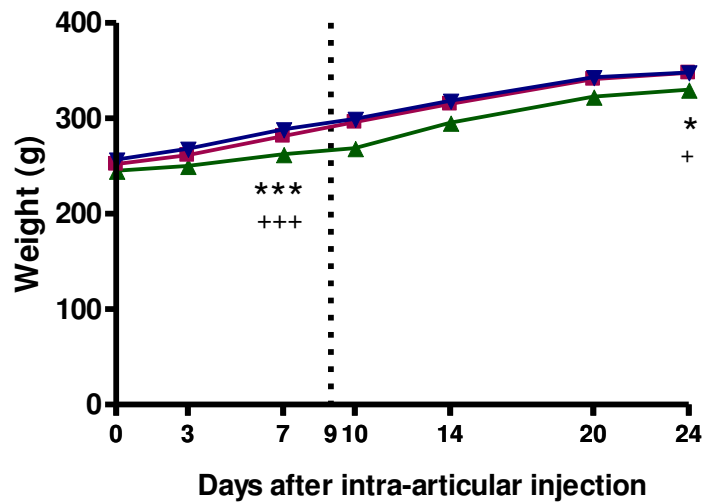


Figure 3.11 Time course of the weight-gain of animals. Intra-articular injection was given in rat knee joint cavities on day 0. Oral administration of either PPI-2458 (5mg/kg/every other day) or vehicle control was given from a day before the injection to day 9 (**dotted line** marks the end of PPI-2458 treatment). Animals treated with the angiogenesis inhibitor PPI-2458 (**▲**) gained weight at a slower rate compared to either the vehicle (**■**) treated animals or naïve controls (**▼**) from day 7 to day 24. Bars show arithmetic mean and \pm S.E.M of synovia from 8 knees per group. Differences between groups were analysed using one way analysis of variance (ANOVA). Univariate comparisons were made using Student's T-test with Bonferroni's correction for multiple comparisons. * $P < 0.05$, *** $P < 0.001$ versus naïve controls. + $P < 0.05$, +++ $P < 0.001$ versus vehicle controls.

Treatment Groups	Weight Gain (g) of animals	
	Day 7	Day 24
2% Carrageenan + Vehicle Control	282 (276 to 287)	348 (334 to 362)
2% Carrageenan + PPI2458	263 (257 to 269) *** +++	330 (326 to 335) * +
Naïve Control	289 (283 to 294)	348 (340 to 357)

Table 1 Weight gain of animals following treatment with the angiogenesis inhibitor PPI-2458. Intra-articular injection was given in rat knee joint cavities on day 0. Oral administration of either PPI-2458 (5mg/kg/every other day) or vehicle control was given from a day before the injection to day 9. Animals treated with the angiogenesis inhibitor PPI-2458 gained weight at a slower rate from day 7 to day 24 compared to those animals that were either given the vehicle treatment or the naïve controls. Data are given as mean (95% confidence interval). Differences between groups (n = 8 animals per group) were analysed using one way analysis of variance (ANOVA). Univariate comparisons were made using Student's T-test with Bonferroni's correction for multiple comparisons. * P < 0.05, *** P < 0.001 versus naïve controls. + P < 0.05, +++ P < 0.001 versus vehicle controls.

3.4.2 Synovial angiogenesis and inflammation after intra-articular FGF-2 and/or carrageenan injection and administration of the angiogenesis inhibitor PPI-2458

CD31-immunoreactive blood vessels were distributed throughout the depth of rat synovia, sometimes containing PCNA-immunoreactive nuclei (Figure 3.12 A-C). ED1-immunoreactive macrophages were localised to the synovial lining, and dispersed throughout the synovial sub-lining regions (Figure 3.12 G-I). Negative control sections (Figure 3.7) did not show any non-specific staining. Synovia from animals given intra-articular injections of 6 pmoles FGF-2 showed increased staining for proliferating ECs (Figure 3.12 A), and those from animals injected with 0.03% carrageenan displayed increased macrophage infiltration (Figure 3.12 G).

3.4.3 FGF-2 induced synovial angiogenesis without inflammation

An increase in EC PCNA index was observed 24 hours after intra-articular injection of FGF-2 (Figure 3.13 A). FGF-2 (6 pmoles) injection was followed by increased synovial EC PCNA index at 24 hours [20% (95% CI, 15 to 27%)] compared to vehicle controls [3% (95% CI, 1 to 6%), $P < 0.01$ (Figure 3.13 A)], which was reduced to naïve levels by day 5 (Figure 3.14). No significant effect was seen 24 hours after injection of 6 pmoles FGF-2 on joint diameter [9.2 mm (95% CI, 9 to 9.5 mm), control; 9.2 mm (95% CI, 8.7 to 9.7 mm), $P > 0.05$], synovial macrophage infiltration (Figure 3.13 B), nor vascular density [EC fractional area; 11% (95% CI, 8 to 16%), control; 11% (95% CI, 9 to 14%), $P > 0.05$].

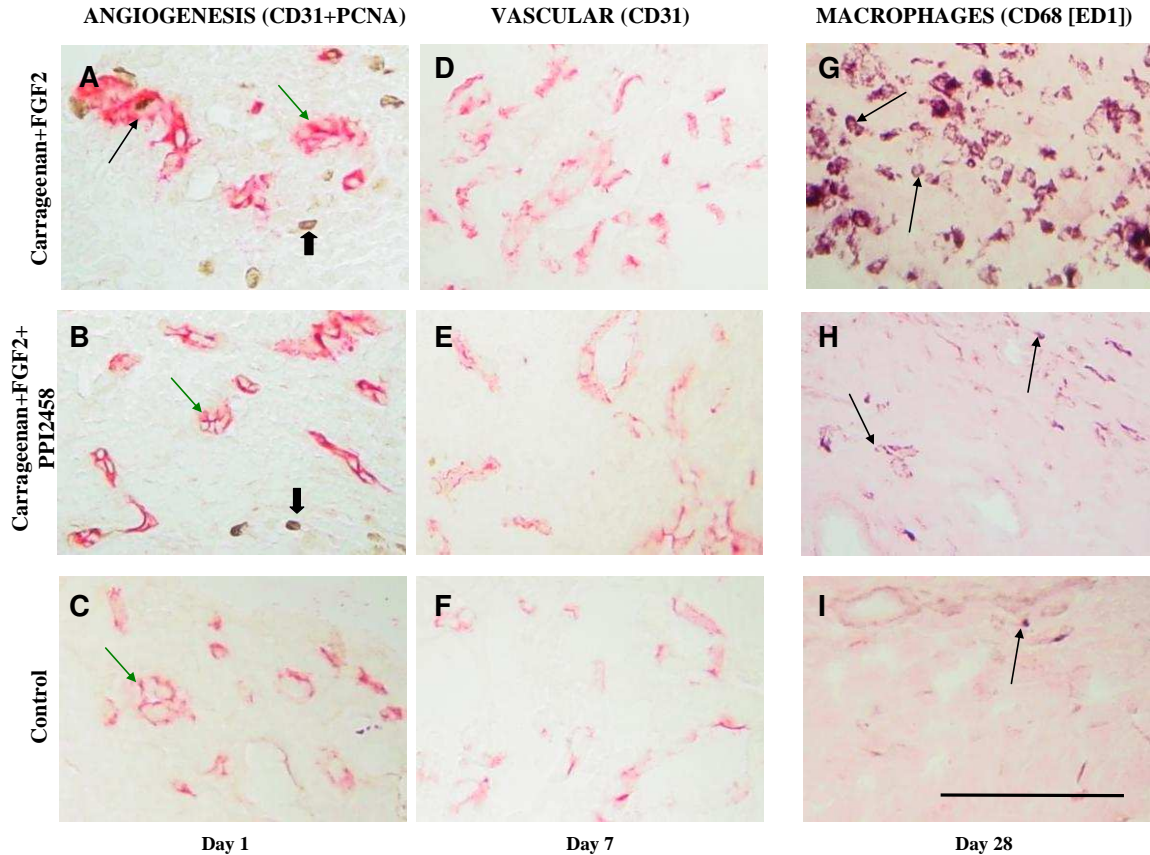


Figure 3.12 Histological evidence of angiogenesis and macrophage infiltration after co-injection of FGF-2 and carrageenan into rat knees. Panels show endothelial cell proliferation at day 1 (**A-C**), extent of endothelial cells at day 7 (**D-F**) and macrophage infiltration at day 28 (**G-I**). Proliferating endothelial cells appear more abundant at day 1 (**A**), after co-injection of FGF-2 and carrageenan compared with vehicle-injected controls (**C**). Administration of PPI-2458 was associated with histological appearances similar to non-synovitic controls (**B**). Increased vascular density was observed at day 7 (**D**). Administration of PPI-2458 reduced vascular density to levels seen in the controls (**E, F**). Macrophage infiltration was increased 28 days after co-administration of FGF-2 and carrageenan (**G**), and reduced in groups given PPI-2458 (**H**) to that of control levels (**I**). Endothelial cells are delineated by CD31-immunoreactivity (red), and (**A-C** only) proliferating nuclei by immunoreactivity for proliferating cell nuclear antigen (PCNA, black). Proliferating endothelial cells (black arrow) contain PCNA-immunoreactive nuclei, whereas non-proliferating endothelial cells (green arrows) do not. Cells other than endothelial cells also display PCNA-immunoreactive nuclei (broad arrows). **G-I**; macrophages are delineated by immunoreactivity for CD68 (ED1), CD31 and/or PCNA immunohistochemistry did not show any non-specific staining (**Figure 3.7**). Colour transmitted light images were taken using $\times 20$ objective lens of a single representative section from $n = 8$ animals per group. Scale bar = 100 μm .

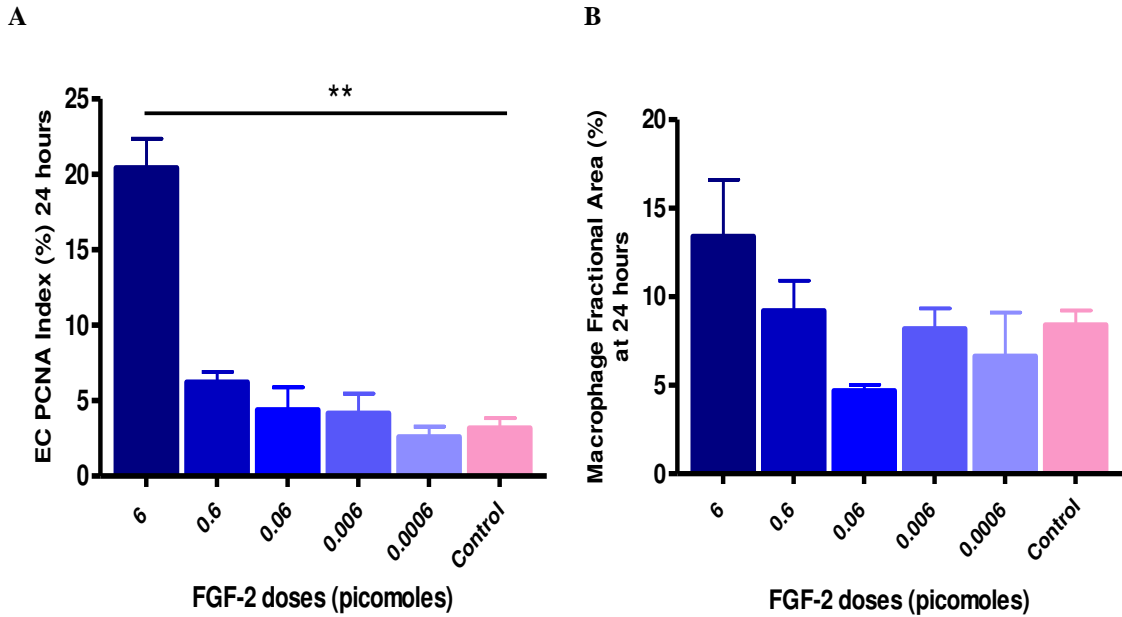


Figure 3.13 Dose response effects of FGF-2 on synovial EC proliferation (A) and macrophage infiltration (B). Twenty four hours after intra-articular injection of either a range of doses of FGF-2 (6×10^{-4} to 6 picomoles) or vehicle control, synovial EC proliferation index (EC PCNA index) increased at a dose of 6 picomoles compared to vehicle injected controls. Synovial macrophage fractional area remained similar to vehicle injected controls at all doses of FGF-2. Bars show arithmetic mean and +S.E.M of synovia from 4 knees per group. EC PCNA Index and macrophage fractional area (logarithmically transformed) were analysed using one way analysis of variance (ANOVA). Univariate comparisons were made using Student's T-test with Bonferroni's correction for multiple comparisons. ** P < 0.01

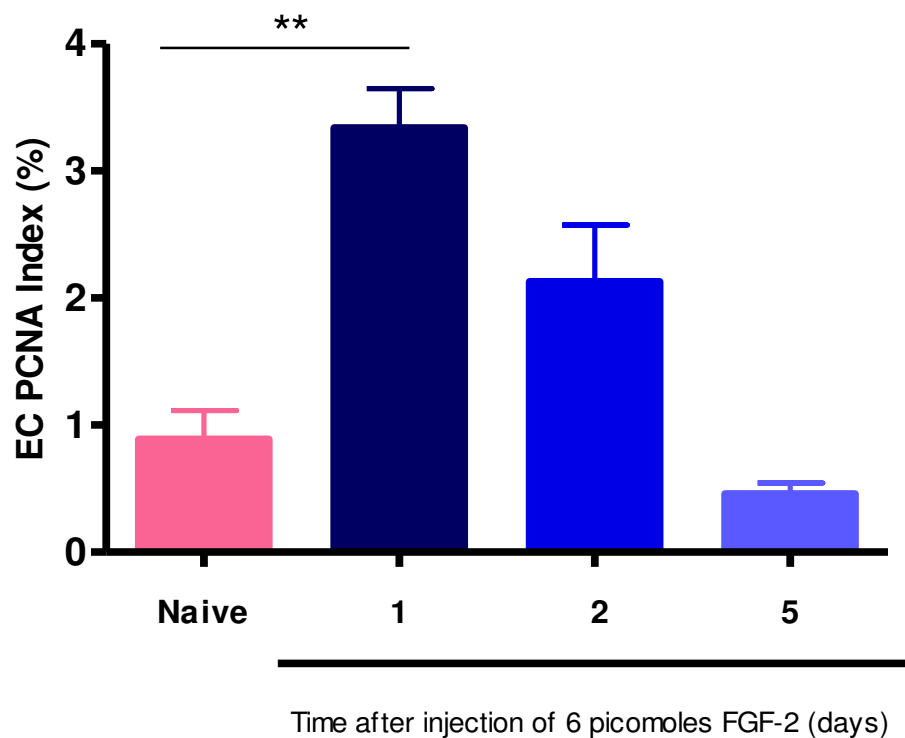


Figure 3.14 Synovial endothelial cell proliferation after intra-articular injection of 6 picomoles of FGF-2. Endothelial cell proliferation index (EC PCNA Index) increased 24 h after intra-articular injection of FGF-2 and returned to naïve levels by 5 days. Arithmetic means (+ S.E.M) of synovia from n = 6 knees per group. EC PCNA Index (logarithmically transformed) was analysed using one way analysis of variance (ANOVA). Univariate comparisons were made using Student's T-test with Bonferroni's correction for multiple comparisons. ** P < 0.01 compared with naïve controls.

3.4.4 Carrageenan induced synovial inflammation without angiogenesis

There was a dose-dependent increase in synovial macrophage infiltration 24 hours after intra-articular carrageenan injection (Figure 3.15). Synovial macrophage infiltration increased 24 hours after injection of 0.03% carrageenan compared with saline-injected controls and had returned to levels similar to controls by day 14 [carrageenan; 5.2% (95% CI, 2.7 to 10.1%), control; 2.7% (95% CI, 1.4 to 5.2%), $P > 0.05$] (Figure 3.16 A). No significant effects of intra-articular injection were observed on either joint swelling (Figure 3.16 B), EC proliferation (Figures 3.15 B and 3.16 C), or vascular density [EC fractional area 24 hours after 0.03% carrageenan; 20% (95% CI, 17 to 23%), control; 16% (95% CI, 12 to 21%), $P > 0.05$].

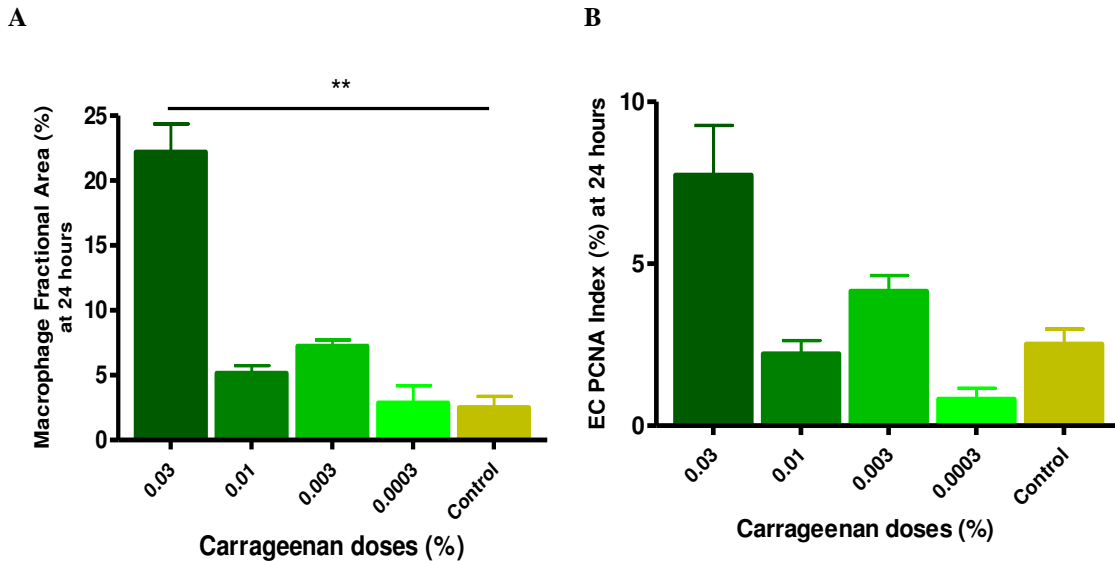


Figure 3.15 Dose response effects of carrageenan on synovial macrophage infiltration (A) and EC proliferation (B). Twenty four hours after intra-articular injection of either a range of doses of carrageenan (3×10^{-4} to 0.03%) or saline control, synovial macrophage fractional increased at a dose of 0.03% compared to saline injected controls. Synovial EC proliferation index (EC PCNA index) remained similar to saline injected controls at all doses of carrageenan. Bars show arithmetic mean and S.E.M of synovia from 4 knees per group. EC PCNA Index and Macrophage Fractional Areas (logarithmically transformed) were analysed using one way analysis of variance (ANOVA). Univariate comparisons were made using Student's T-test with Bonferroni's correction for multiple comparisons. ** $P < 0.01$

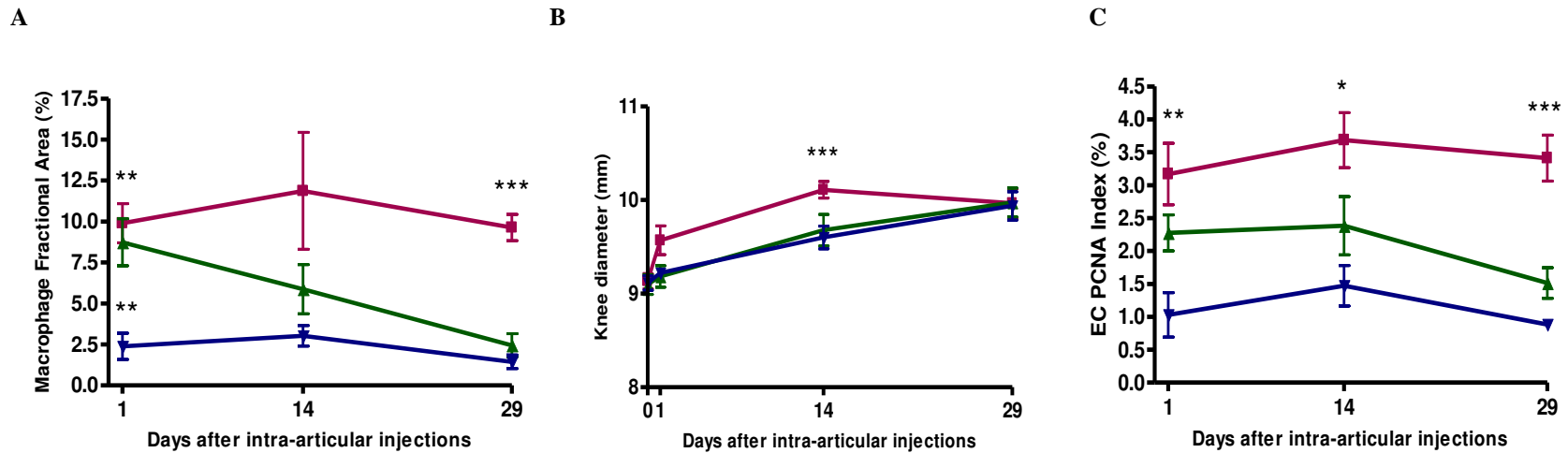


Figure 3.16 Persistent synovitis after co-injection of FGF-2 and carrageenan. Intra-articular injection of 0.03% carrageenan alone (▲) was followed by a brief increase in synovial macrophage infiltration (A), and had no significant effect on joint swelling (B) or endothelial proliferation (C) compared with knees from control animals (▼). Co-injection of 6 pmoles FGF-2 together with 0.03% carrageenan (■) was followed by increased endothelial cell proliferation (C) as well as increased inflammation [macrophage infiltration (A) and joint swelling (B)] at 24 hours, and by persistent synovitis at days 14 and 29. No significant increase in any parameter was observed in vehicle-injected controls compared with naïve knees. EC PCNA Index; Endothelial cell proliferating nuclear antigen index. Arithmetic means (\pm S.E.M) of synovia from 6 knees per group. Macrophage fractional areas, EC PCNA index (logarithmically transformed) and knee diameters were analysed using one way analysis of variance (ANOVA). Univariate comparisons were made using Student's T-test with Bonferroni's correction for multiple comparisons. * $P < 0.05$, ** $P < 0.01$, *** $P < 0.001$ compared with vehicle-injected controls.

3.4.5 Combined effects of FGF-2 and carrageenan on synovial angiogenesis and inflammation

Co-injection of 0.03% carrageenan and 6 pmoles FGF-2 into rat knee joints was followed after 24 hours by increased synovial macrophage infiltration [9.4% (95% CI, 6.4 to 13.8%), Figures 3.16 A and 3.18 A] and joint swelling [9.6 mm (95% CI, 9.2 to 10.0 mm), Figures 3.16 B and 3.18 B] compared with controls [1.6% (95% CI, 0.5 to 4.8%), $P < 0.05$, and 9.1 mm (95% CI, 8.9 to 9.3 mm), $P < 0.01$, respectively]. Co-injection of carrageenan and FGF-2 was also followed after 24 hours by increased synovial EC PCNA index [3% (95% CI, 2 to 4.5%), Figures 3.12, 3.16 C and 3.18 C] and EC fractional area [8.0% (95% CI, 6.0 to 10.6%), Figure 3.18 D] compared with controls [0.8% (95% CI, 0.3 to 1.8%), $P < 0.01$, and [4.9% (95% CI, 3.9 to 6.0%), $P < 0.05$, respectively]. The increases in indices of inflammation and angiogenesis were maintained through day 28 after co-injection of carrageenan and FGF-2 (Figures 3.12, 3.16 and 3.18) indicating the induction of a chronic synovitis. Indices of angiogenesis and inflammation resolved within 28 days in rats injected with FGF-2 or carrageenan alone.

3.4.6 Dose-dependent inhibition of FGF-2-induced angiogenesis by PPI-2458

Intra-articular injection of FGF-2 alone without PPI-2458 administration was followed 24 hours later by an increase in synovial EC PCNA index [6.9% (95% CI, 4.0 to 11.7%)] compared with naïve animals [1.1% (95% CI, 0.6 to 1.9%), $P < 0.001$] (Figure 3.17). A dose dependent reduction in FGF-2 induced synovial angiogenesis was observed in groups treated with increasing doses of PPI-2458 administered orally 1 day prior to FGF-2 injection, with complete inhibition of EC PCNA index to naïve levels by 5mg/kg PPI-2458 [1.1% (95% CI, 0.6 to 2.3%), $p > 0.05$ compared to naïve controls] (Figure 3.17 and 3.18). PPI-2458 did not alter synovial macrophage infiltration and knee diameter (Figure 3.17). The values remained similar to those observed in naïve and vehicle controls.

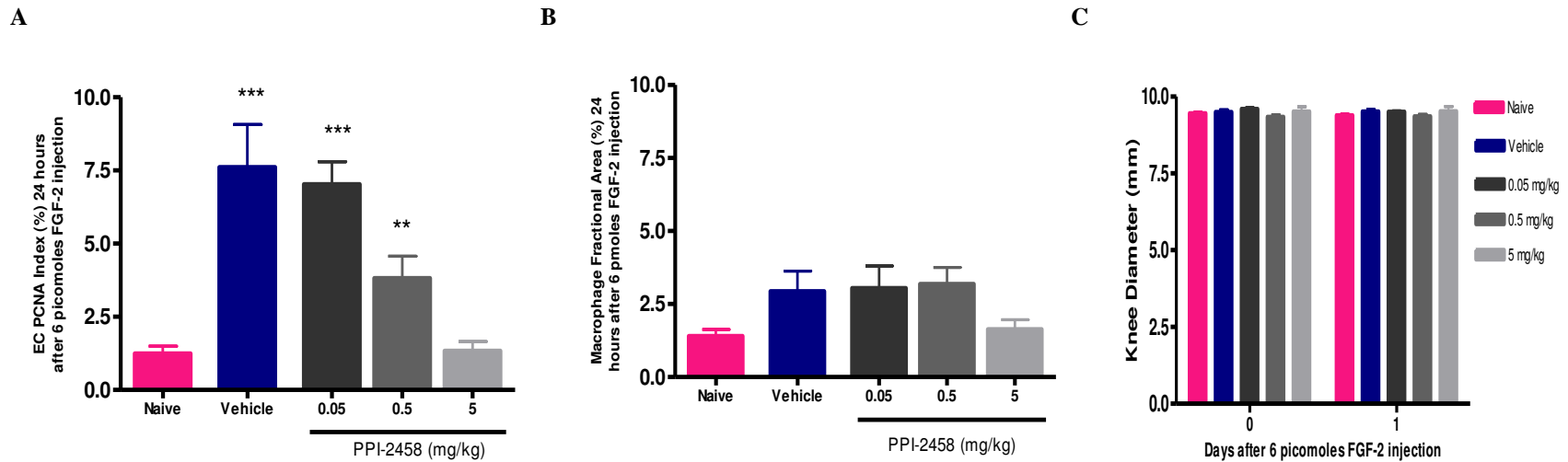


Figure 3.17 Dose-dependent reduction after PPI-2458 in FGF-2-induced synovial endothelial cell proliferation. Oral doses of PPI-2458 were given a day before bilateral intra-articular injection of 6 pmoles FGF-2 into rat knee joints. Endothelial cell proliferation index (EC PCNA Index; **A**) was dose dependently reduced 24 hours after FGF-2 injection, with the highest dose of PPI-2458 reducing EC PCNA Index to naïve control levels. PPI-2458 did not alter either synovial macrophage infiltration (**B**) or knee diameter (**C**). Arithmetic means (+ S.E.M) of synovia from n = 6 knees per group. EC PCNA index, macrophage fractional areas (logarithmically transformed) and knee diameters were analysed using one way analysis of variance (ANOVA). Univariate comparisons were made using Student's T-test with Bonferroni's correction for multiple comparisons. *** P < 0.001, ** P < 0.01 compared with naïve controls.

3.4.7 Synovial angiogenesis and inflammation after brief PPI-2458 administration early during FGF-2/carrageenan- induced synovitis

Animals were given 3 doses of PPI-2458 between the day before and 3 days after the induction of chronic synovitis by co-injection of carrageenan and FGF-2. This dosage regimen was designed to cover the period of FGF-2 enhanced angiogenesis as determined above (figure 3.17). PPI-2458 administration was associated with a reduction of angiogenesis indices to control levels 24 hours after carrageenan/FGF-2 injection (Figures 3.12 and 3.17), whereas inflammation indices were still increased 24 hours after co-injection of carrageenan and FGF-2 in PPI-2458 treated animals when compared to the control animals (Figure 3.18). Furthermore, synovial macrophage infiltration was only partially reduced 7 days after co-injection of carrageenan and FGF-2 injection, remaining elevated in animals given PPI-2458 [9.3% (95% CI, 7.0 to 12.4%), Figure 3.18 A] compared with non-synovitic controls 2.8% (95% CI, 1.9 to 4.2%), $P < 0.001$]. However, inflammation indices were normalised to non-synovitic control levels by day 28 in animals briefly treated with PPI-2458 up to 3 days after intra-articular co-injection of carrageenan and FGF-2 (Figures 3.12 and 3.18 A).

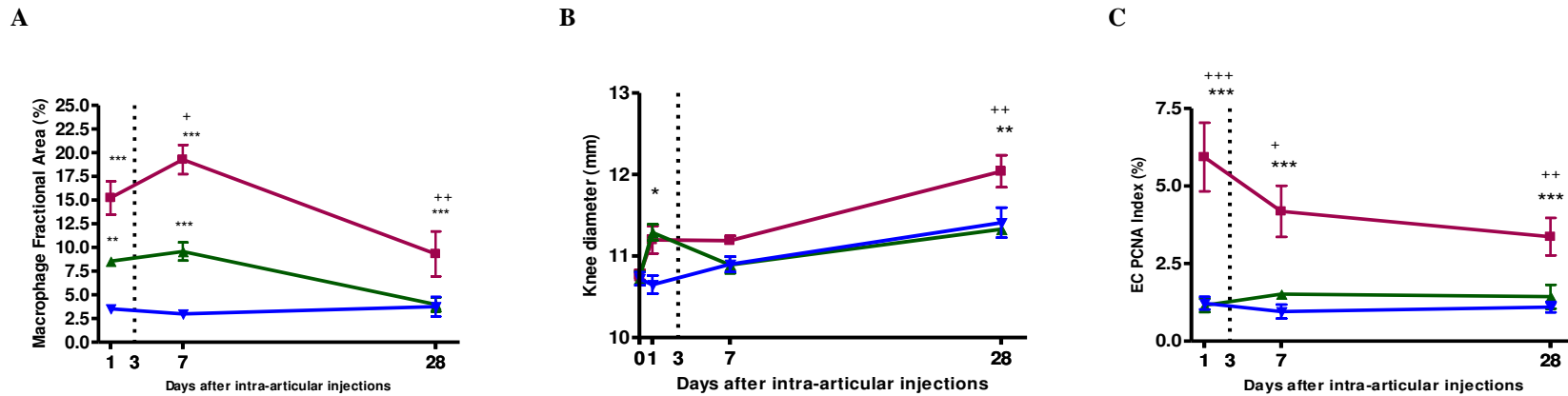


Figure 3.18 Inhibition of FGF-2-induced angiogenesis and promotion of the resolution of synovitis after PPI-2458 administration. Following co-injection of 0.03% carrageenan and 6 pmoles FGF-2 (■) there were sustained increases in joint inflammation (A: synovial macrophage infiltration, B: joint swelling) and synovial angiogenesis (C: endothelial cell proliferation), compared with vehicle injected controls (▼). Animals given 3 oral doses of PPI-2458 (5mg/kg) on alternate days from 1 day before until 3 days after intra-articular injection of 0.03% carrageenan and 6 pmoles FGF-2 (▲) displayed synovial angiogenesis indices (C,D) similar to vehicle-injected controls throughout the experiment. PPI-2458 administration did not significantly inhibit joint inflammation at 24 hours (A, B) and macrophage infiltration was only partially reduced at day 7. However, the brief treatment with PPI-2458, completely inhibited joint inflammation to control levels by day 28, converting the model from one of persistent inflammation to one of transient synovitis (A). EC; endothelial cell, PCNA: proliferating cell nuclear antigen, Dashed line: time of last dose of PPI-2458. Arithmetic mean (\pm S.E.M) of synovia from 6 knees per group. Macrophage fractional area, EC PCNA index (logarithmically transformed) and knee diameters were analysed using one way analysis of variance (ANOVA). Univariate comparisons were made using Student's T-test with Bonferroni's correction for multiple comparisons. * $P < 0.05$, ** $P < 0.01$, *** $P < 0.001$ compared with vehicle-injected controls. + $P < 0.05$, ++ $P < 0.01$, +++ $P < 0.001$ compared with PPI-2458 treated animals.

3.5 Summary of Results

- A short course (6 doses) of the angiogenesis inhibitor PPI-2458, administered during the initial phase of inflammation made 2% carrageenan induced chronic synovitis and pain more transient.
- Administration of FGF-2 (6 picomoles) induced synovial angiogenesis without inflammation. Levels of synovial angiogenesis reached those of naïve controls by day 5.
- At 0.03%, carrageenan induced transient synovitis without angiogenesis. Synovitis resolved within 14 days.
- Co-injection of FGF-2 (6 picomoles) and carrageenan (0.03%) was followed by synovitis which persisted for at least 4 weeks.
- Administration of the angiogenesis inhibitor PPI-2458 (3 doses) in this combined model (6 picomoles FGF-2 and 0.03% carrageenan) of chronic synovitis inhibited FGF-2 induced angiogenesis leading to the resolution of persistent synovitis.

3.6 Discussion

Using animal models of synovitis, these data show that angiogenesis may be a key factor in the transition from acute to persistent inflammation.

In the 2% carrageenan model of persistent synovitis, a short course of PPI-2458 (6 doses) administered during the initial phase of inflammation, reduced synovitis by day 24, but did not completely abolish it. However synovial angiogenesis (EC proliferation and vascular density) was completely abolished at this time point, suggesting that chronic inflammation is in part mediated by angiogenesis. Pain behaviour in this model was also reduced by day 7 following administration of PPI-2458. At this time point, synovial angiogenesis was completely abolished but synovitis persisted, suggesting that angiogenesis, inflammation and pain are indeed inter-connected processes. Inhibiting angiogenesis therefore has the potential to reduce pain.

At a dose of 0.03%, carrageenan alone did not induce angiogenesis. Carrageenan injection alone was associated with a transient synovitis that had resolved at 14 days. When angiogenesis was stimulated with 6 pmoles FGF-2 at the time that synovitis was induced by intra-articular injection of carrageenan, the synovitis persisted for at least 4 weeks. Inhibition of this effect of FGF-2 by PPI-2458 suggests that this chronicity is mediated by angiogenesis rather than other actions of FGF-2.

The mechanisms leading to persistent inflammation in human diseases remain unclear. Autoimmunity contributes to inflammation and tissue damage in diseases such as RA, although its contribution to persistence in early RA remains incompletely understood. Evidence of autoimmunity, such as circulating anti-citrullinated peptide antibodies, has limited sensitivity to predict persistence in early synovitis, and immunosuppression does not prevent persistence in the majority of patients. Many other chronic inflammatory diseases (e.g. psoriasis and inflammatory bowel disease) display little evidence of autoimmunity. Angiogenesis inhibition may reduce arthritis severity in animal models of autoimmunity (Peacock et al., 1992; Storgard et al., 1999; Bernier et al., 2004; Bainbridge et al., 2007; Hannig et al., 2007; Brahn et al., 2008; Lazarus et al., 2008). Inflammation is now increasingly being recognized as one of the prominent features of previously thought non-inflammatory arthritic conditions such as OA (Pelletier et al., 2001). In-vitro studies of human OA synovium and in-vivo studies in animal models of OA have strongly suggested that the inflamed synovium and synovial macrophages are important in promoting OA pathology (Bondeson et al., 2010).

In the current study, FGF-2 and PPI-2458, and specific outcome measures of angiogenesis, inflammation and pain, were used in order to determine the effects of angiogenesis inhibition on persistence of inflammation. These data indicate that angiogenesis inhibition may prevent the progression from acute to

chronic inflammation in situations where new blood vessel growth is the key switch to persistence as well as curtailing pain associated with chronic synovitis.

FGFs are implicated in the initiation and development of synovial hyperplasia and inflammation in RA (Malemud 2007). FGF-8 has been implicated in enhancing cartilage damage and thus exacerbating arthritis in the partial meniscectomy model of OA (Uchii et al., 2008). FGF-2 is upregulated at the cartilage-pannus interface in RA (Qu et al., 1995), and increased synovial fluid levels of FGF-2 are associated with greater disease severity (Nakashima et al., 1994; Manabe et al., 1999). FGF-2 has also been shown to augment antigen-induced arthritis in rabbits (Storgard et al., 1999), and FGF-2 over expression has worsened inflammation and joint damage in adjuvant arthritis in rats (Yamashita et al., 2002).

These data support previous evidence that FGF-2 is pro-angiogenic, but not directly pro-inflammatory (Ziche et al., 1992; Cozzolino et al., 1993; Gualandris et al., 1994). FGF-2 is mitogenic for endothelial cells and acts via specific FGF-2 receptors displayed on these cells. In some experimental systems, FGF-2 can additionally enhance vascular integrity (Murakami et al., 2008), and increase adhesion molecule expression by cytokine activated endothelial cells, thereby synergistically enhancing the recruitment of inflammatory cells (Zittermann et al., 2006). However, in this study it was found that a single intra-articular injection of FGF-2 either alone, or together with carrageenan, was not sufficient to increase joint swelling or macrophage infiltration at 24 hours, despite its ability to increase endothelial cell proliferation. Effects of FGF-2 to augment chronic synovitis were inhibited both by the brief administration of PPI-2458 in this study, and by repeated administration of an anti-angiogenic inhibitor of $\alpha\beta3$ integrin in a previously published study using antigen-induced arthritis (Storgard et al., 1999). FGF-2 therefore may contribute to arthritis by increasing synovial angiogenesis, rather than any direct effect on inflammation.

PPI-2458 inhibits human endothelial cell proliferation by inhibiting MetAP-2, and does not reduce angiogenic growth factor production (Griffith et al., 1997; Sin et al., 1997; Bainbridge et al., 2007), and neither does it induce apoptosis in endothelial cells (Bernier et al., 2004). However, high doses of PPI-2458 may have effects additional to angiogenesis inhibition and mediation of its therapeutic effects by angiogenesis inhibition has been uncertain in previous studies (Bernier et al., 2004). It was found that PPI-2458 administration abolished synovial angiogenesis prior to reduction in synovitis, whereas synovitis reduction followed the discontinuation of PPI-2458. This indicates that PPI-2458 may exert its effects not through the direct inhibition of inflammation, but rather through the inhibition of angiogenesis.

Similar to previously published data, synovial macrophage infiltration was reduced following administration of PPI-2458 in these animal models of synovitis however joint swelling (knee diameter) was not affected at these early time-points. This indicates that synovial macrophage infiltration is not a direct index of joint swelling. Therefore attenuating macrophage infiltration does not necessary mean that joint

swelling will also be reduced. It is also possible that oedema and scar tissues could still be contributing to joint swelling measured at these early time points. It further indicates that PPI-2458 may exert its effects through the inhibition of angiogenesis rather than through direct inhibition of inflammation.

Pain behaviour was also reduced following synovial angiogenesis inhibition when synovitis was still detected suggesting that angiogenesis inhibition has the potential to reduce pain. This finding strengthens the hypothesis and previously published data that angiogenesis, inflammation and pain are interconnected processes (Walsh et al., 2010). A recently published study indicated that metalloproteinase inhibition reduced osteochondral angiogenesis and pain behaviour in a rat model of OA (Mapp et al., 2010). The association between osteochondral angiogenesis and pain behaviour in that study may be explained by nerves growing alongside blood vessels or stimulation of subchondral nerves as a result of loss of osteochondral integrity. Similarly in this study a reduction in pain behaviour was observed following synovial angiogenesis inhibition and this observation may be explained in part by the theory that chronic synovitis is accompanied with increased blood vessel growth and hence perivascular nerves or stimulation and sensitization of these nerves by inflammatory and angiogenic factors.

Synovial angiogenesis is an early feature of both OA and RA, and occurs very early in the development of persistent synovitis in animal models (Walsh et al., 1998; Brahn et al., 2008). Synovial angiogenesis is also a feature of chronic synovitis in both humans and animals (Walsh et al., 1998; Walsh et al., 2001; Haywood et al., 2003). These data also demonstrate increased endothelial cell proliferation during chronic synovitis 29 days after co-injection of carrageenan and FGF-2. It is likely that angiogenesis at day 29 was mediated by factors other than the injected FGF-2, since FGF-2 alone induced only a transient increase in endothelial cell proliferation that had normalised by 5 days. Angiogenesis during chronic synovitis may be mediated by an imbalance between a variety of angiogenic and anti-angiogenic factors (Bonnet et al., 2005). Further studies will be required to understand which molecules sustain synovial angiogenesis in humans or animal models.

Mechanisms by which acute synovitis may lead on to chronic arthritis remain incompletely understood. Clinical trials aiming to induce remission in early synovitis by intensive immunosuppression have raised optimism that it may eventually be possible to modify the course of, for example, OA and RA without the need for lifelong medication. Immunosuppression alone, however, has not yet achieved this goal, and other factors may be important in the transition from acute to chronic synovitis. Angiogenesis is a feature of early as well as persistent synovitis in humans (Griffioen et al., 2000; El-Gabalawy 2005; Klareskog et al., 2009), and these data indicate that synovial angiogenesis may be a factor leading to persistent synovitis. Animal models of synovitis typically progress more rapidly than does arthritis in humans, and further work would be required to determine the duration of any window of opportunity in early synovitis during which inhibition of angiogenesis may facilitate its resolution. Furthermore, as there may be multiple factors

leading to persistence, angiogenesis inhibition may have greatest therapeutic potential in combination with other pharmacological agents. Similar combined approaches with angiogenesis inhibitors have proven successful in oncology (Sund et al., 2005; Rini 2009).

Sustained angiogenesis inhibition commenced during the induction of, or at the onset of synovitis can reduce inflammation and joint damage (Storgard et al., 1999; Bernier et al., 2004; Bainbridge et al., 2007; Hannig et al., 2007; Brahn et al., 2008). However, adverse effects of long term angiogenesis inhibition on physiological blood vessel growth may outweigh therapeutic benefit in chronic inflammatory diseases.

In conclusion, these data indicate that short-term angiogenesis inhibition targeted to a key period in the development of inflammation has the potential to achieve sustained clinical benefit. Clinical studies will be required to determine whether brief anti-angiogenic treatments can facilitate resolution in early synovitis, at the onset of synovitis in a previously uninvolved joint, or at reactivation of previously quiescent inflammation. A greater understanding of the mechanisms underlying persistence in different clinical scenarios will be necessary in order to realise this potential.

4 ROLE OF ANGIOGENESIS IN INFLAMMATION, JOINT DAMAGE AND PAIN IN A RAT MODEL OF KNEE OSTEOARTHRITIS

4.1 Introduction

Osteoarthritis (OA), a common, chronic disorder of the joints, is one of the major causes of pain and disability in ageing populations (Peat et al., 2001). The exact underlying causes of OA remain incompletely understood. Treatments for OA focus on symptomatic relief with little capacity to modify the underlying disease process. Irreversible joint damage in late stages of the disease benefits most from total joint replacement surgery. OA is associated with loss of articular cartilage (chondropathy), synovitis, subchondral bone remodeling, and osteophyte formation (Ashraf et al., 2008). It is widely thought that OA is primarily a disease of the cartilage with associated subchondral and synovial changes (Walsh 1999). However, this notion is challenged by the hypothesis that the primary disorder arises in the subchondral bone and synovium, with loss of articular cartilage and osteophyte growth being secondary phenomena (Imhof et al., 1997).

Normal adult human articular cartilage is avascular (Moses et al., 1990) and aneural (Dye et al., 1998). In OA, loss of integrity of the osteochondral junction is attributed to channels crossing the osteochondral junction. Channels form as extensions of the subchondral bone spaces, breaching the osteochondral junction and tidemark, into the non-calcified articular cartilage. Blood vessels grow into these channels from the subchondral bone, thereby invading the articular cartilage (osteochondral angiogenesis) (Walsh et al., 2007) and are accompanied by sympathetic and sensory nerves (Suri et al., 2007). This osteochondral angiogenesis may potentiate joint damage by stimulating ossification in the articular cartilage. Furthermore, blood vessels and nerves penetrate newly formed cartilage at the joint margins during osteophyte formation (Suri et al., 2007).

Although OA is commonly distinguished from inflammatory arthritides such as RA, it is increasingly recognized that synovitis may contribute both to symptoms and to joint damage in OA (Bonnet et al., 2005; Ashraf et al., 2008; Bondeson et al., 2010). Osteoarthritic synovium is commonly inflamed and infiltrated with macrophages (Walsh et al., 2007). Subchondral inflammation may also be a feature of OA, where fibrovascular tissue replaces fatty bone marrow (Milgram 1983).

Angiogenesis, the growth of new blood vessels from pre-existing ones, is characteristic of OA. Increased angiogenesis in the synovium is associated with chronic synovitis in OA (Walsh et al., 1998; Haywood et al., 2003). Synovial angiogenesis results in a redistribution of blood vessels away from the synovial surface, and it is thought that this may impair chondrocyte function and homeostasis of the articular cartilage as well as contributing towards articular hypoxia (Walsh et al., 2007; Mapp et al., 2008). Although angiogenesis is not in itself painful, it may exacerbate pain by enabling innervation of tissues and

by facilitating inflammation (Bonnet et al., 2005). Inflammation, angiogenesis and innervation are highly integrated processes in OA, thus controlling one could have profound effects on the others. Inhibitors of angiogenesis and/or inflammation therefore, have potential for reducing structural damage and pain in OA.

Intra-articular injection of corticosteroids and oral or topical NSAIDs are recommended treatments for knee OA (Conaghan et al., 2008). In addition to their anti-inflammatory actions, corticosteroids and NSAIDs may also be anti-angiogenic (Folkman et al., 1987; Madhok et al., 1991). Dexamethasone, a corticosteroid with a multiplicity of actions on a wide range of inflammatory cell functions, is suggested to exert its anti-inflammatory effects by inhibiting phospholipase A2, reducing the production and release of inflammatory mediators such as histamine, bradykinin, IL-1 and IL-6, and reducing the production of arachidonic acid metabolism products, including prostaglandins and leukotrienes (Creamer 1999). Each of these factors may stimulate and sensitize nerve fibres, and corticosteroids can therefore reduce pain. Dexamethasone inhibits angiogenic factor production by cultured synoviocytes (Nagashima et al., 2000) as well as inhibiting blood vessel growth into sponges implanted subcutaneously in rats (Hori et al., 1996). Intra-articular or systemic delivery of dexamethasone reduces joint damage in experimental animal models of inflammatory arthritis, such as adjuvant arthritis (AA) and collagen-induced arthritis (CIA) (Bendele 2001; Cuzzocrea et al., 2005; Caparroz-Assef et al., 2007). In a rabbit meniscal transection model of OA, corticosteroids given before the onset of OA reduced osteophyte formation and cartilage loss (Butler et al., 1983). Similar findings have been reported in guinea pig and dog models of experimental OA (Williams et al., 1985; Pelletier et al., 1995). However corticosteroids also inhibit chondrocyte synthetic functions and may therefore exacerbate joint damage (Annefeld et al., 1990).

Indomethacin, a NSAID, is a non-selective inhibitor of COX 1 and 2 enzymes, inhibiting PG synthesis from arachidonic acid, thereby reducing the pain of inflammation. Indomethacin can suppress the growth of colon cancer by inhibiting tumour angiogenesis (Wang et al., 2005). In carrageenan-induced inflammation in rats, indomethacin inhibits angiogenesis by reducing COX-2 dependent production of PGE₂ (Ghosh et al., 2000; Ghosh et al., 2002), and indomethacin also reduces inflammation in experimental animal models of inflammatory arthritis (Van Arman et al., 1970; Van Arman et al., 1973; Hamada et al., 2000; Bernardi et al., 2009). Oral administration of COX-1/2 inhibitors reduced pain but also inhibited anabolic functions of chondrocytes in the MIA model of OA (Bove et al., 2003). Some clinical studies have suggested that indomethacin may increase the rate of radiological deterioration of joint space in patients with OA of the knee and hip (Rashad et al., 1989; Huskisson et al., 1995).

Certain anti-inflammatory drugs therefore have the potential to slow the progression of OA structural damage by inhibiting synovitis. However, shared molecular pathways between inflammation and cartilage homeostasis may result in adverse structural effects of anti-inflammatory drugs. Corticosteroids and NSAIDs are not considered to be disease modifying in human OA, but certainly alleviate symptoms (Ding

2002). Identifying specific mechanisms of inflammation-induced joint damage in OA may therefore indicate novel anti-inflammatory therapies that both improve symptoms and protect against progression of joint damage. Keeping this in mind, it was hypothesised that angiogenesis may not only facilitate inflammation, but could also be a mechanism by which inflammation leads to pain and joint damage in OA. Therefore it was proposed in this study that inhibiting angiogenesis may in turn reduce inflammation, joint damage and pain in OA.

PPI-2458, an anti-angiogenic fumagillin analog, reduces synovitis and bone and cartilage damage in rodent models of immune-mediated inflammatory arthritis; CIA in mice and PGPS-induced arthritis in rats (Bainbridge et al., 2007; Lazarus et al., 2008). It exerts its effects by inhibiting MetAP-2, triggering growth arrest of ECs in the late G₁ phase of the cell cycle, inhibiting EC proliferation and angiogenesis without affecting inflammatory cytokine release (Griffith et al., 1997; Bainbridge et al., 2007).

Transection of the medial meniscus in the rat results in joint pathology similar to that observed in human OA (Bendele 2001; Janusz et al., 2002; Mapp et al., 2008) indicating that this model is useful for the development of pharmacological interventions for treatment of and to explore mechanisms underlying pain in OA. This rat MNX model was used to evaluate the potential contributions of inflammation and angiogenesis to joint damage and pain in OA.

4.2 Aims

1. To show that the MNX model of OA is associated with the expected osteoarthritic changes in the medial tibial plateaux, similar to that observed in human OA.
2. To evaluate the effects of anti-inflammatory drugs (indomethacin and dexamethasone) on synovitis, joint damage and pain in the rat MNX model of OA.
3. To find out if the anti-angiogenic compound, PPI-2458 specifically inhibits angiogenesis without directly affecting inflammation in the rat MNX model of OA.
4. The effects of enhancing synovitis using 2% carrageenan on joint damage and pain in the rat MNX model of OA.
5. To use PPI-2458 to specifically inhibit angiogenesis without directly affecting inflammation in the rat MNX and 2% carrageenan model to explore the contribution of angiogenesis to inflammation, joint damage and pain in OA.

4.3 Methods

General methodology is given in Chapter 2. Experiments were performed on male Lewis rats (Charles River, Margate, Kent, UK) weighing 250-280 gm (n = 8 per treatment group, unless otherwise stated).

4.3.1 Intra-articular injection of 2% carrageenan and MNX model of OA

Animals (n = 8 per treatment group) having either meniscal transection or SHAM surgery on day 0 (left knee joint) were given an intra-articular injection of 2% carrageenan in the operated knee (day 12). Meniscal transection only operated animals, SHAM only operated animals and naïve animals were used as controls. Synovia and knee joints were collected 35 days post surgery. Knee diameter and incapitance measurements were taken throughout the experiment (Figure 4.1).

Statistical analysis to evaluate joint damage (osteophytosis, chondropathy and integrity of the osteochondral junction) was performed by combining two separate experiments (MNX+2% carrageenan: n = 16, MNX: n = 16, SHAM+2% carrageenan: n = 8, SHAM: n = 8, Naives: n = 16), to increase the number of animals, hence the power of the study.

4.3.2 Dexamethasone and Indomethacin

Animals (n = 8 per treatment group) that had meniscal transection surgery were dosed daily, starting on day 11 until sacrifice at day 35, by oral gavage with either 500 µl sterile 0.9% normal saline (vehicle) control (pH 7.4) or vehicle control containing either dexamethasone (0.1 mg/kg) or indomethacin (2 mg/kg). Day 11 was chosen to start intervention studies in the MNX model of OA to allow sufficient amount of time for the animals to recover from the surgical procedure. By this time the sutures had also fallen out and the visible wound on rat knee joints had sufficiently healed. These doses were shown in previous studies to inhibit inflammation in the joint (Ku et al., 1996; Takagi et al., 1998; Cuzzocrea et al., 2005; Sharma 2010). Naïve animals were used as additional controls. Weights, knee diameter and pain behaviour of animals were monitored throughout the experiment and blood glucose levels were measured at day 35 (Figure 4.1).

4.3.3 PPI-2458

Animals (n = 8 per treatment group) that either had meniscal transection surgery or meniscal transection surgery (day 0) and 2% carrageenan intra-articular injection (day 12) were dosed every other day (from day 11 to 35), by oral gavage with either 500 µl vehicle control (11% HPβCD buffer in PBS) or vehicle containing the angiogenesis inhibitor PPI-2458 (5 mg/kg). This dose of PPI-2458 was shown in previous studies to suppress angiogenesis, inflammation and improve bone structure (Bainbridge et al., 2007; Lazarus et al., 2008). At the dose of 5 mg/kg, PPI-2458 was also shown in chapter 3 of this thesis to resolve chronic synovitis. Naïve animals were used as additional controls. Weights of animals, knee

diameter and pain behaviour were monitored throughout the experiment. Synovia and knee joints were harvested 35 days post surgery (Figure 4.1).

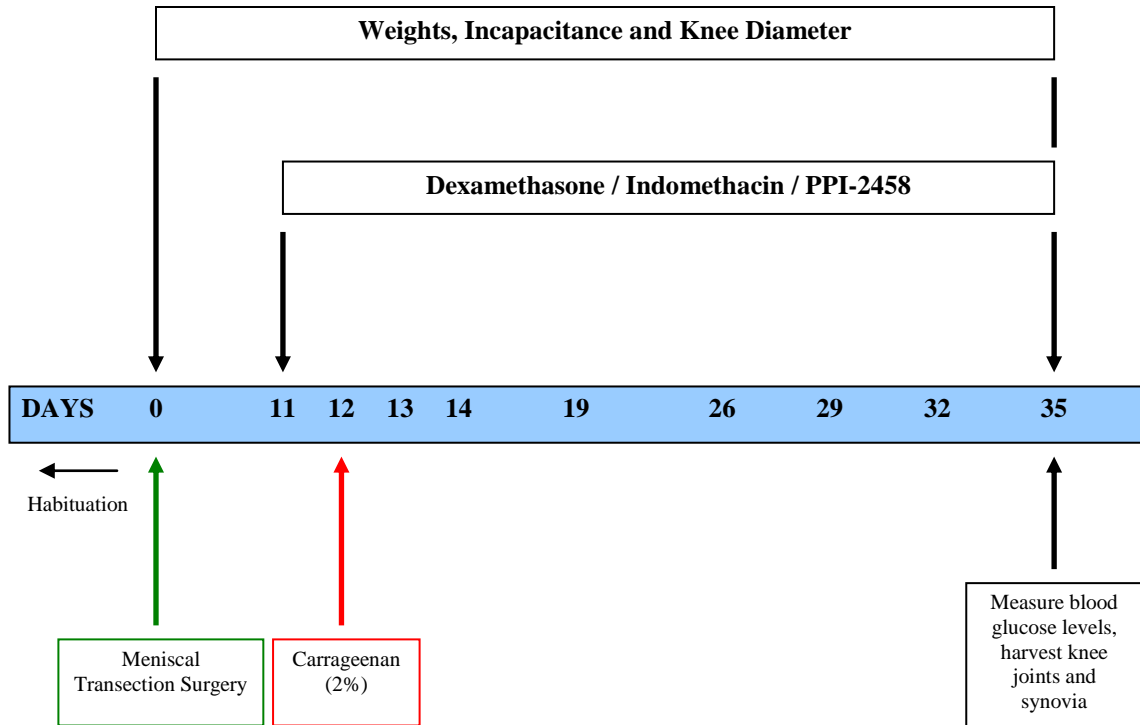


Figure 4.1 Diagram highlighting the experimental plans. (i) The effects of either anti-inflammatory (indomethacin and dexamethasone) or anti-angiogenic (PPI-2458) drugs on synovitis, joint damage and pain in the rat MNX model of OA. (ii) Whether enhancing inflammation using 2% carrageenan has any effects on synovitis, joint damage and pain in this model and (iii) if these structural and behaviour changes can be inhibited using PPI-2458. Surgery was performed on day 0. A single dose of intra-articular carrageenan injection was given on day 12 and treatment was started from day 11 to 35 after surgery, after which joint tissues were harvested. At various time-points during the experiments, weights, knee diameters and incapacitation measurements of the animals were recorded. Blood glucose levels were measured at day 35.

4.4 **Results**

4.4.1 **MNX model of OA**

The MNX model was associated with the expected osteoarthritic changes in the medial tibial plateaux at day 35. These osteoarthritic changes included loss of articular cartilage, reduced chondrocyte density and proteoglycan staining, with subchondral bone remodeling including increased numbers of channels breaching the osteochondral junction, and formation of osteophytes at joint margins (Figure 4.2 A).

Sensory nerves were located in the osteophytes, synovium, and the subchondral bone, adjacent to blood vessels (Figure 4.2 B-D). Increased pain behaviour was also observed following meniscal transection surgery (Figure 4.6).

Measures of inflammation (synovial macrophage infiltration and joint swelling), synovial angiogenesis (EC proliferation index and vascular density) and vascular channels crossing the osteochondral junction were increased 35 days post meniscal transection surgery (Figures 4.3, 4.4. and 4.7).

ED1-immunoreactive macrophages were localized to the synovial lining and dispersed throughout the synovial sublining regions. CD31-immunoreactive blood vessels were distributed throughout the depth of rat synovia, occasionally containing PCNA-immunoreactive nuclei (Figure 4.3). Negative control section did not show any non-specific staining (Figure 3.7).

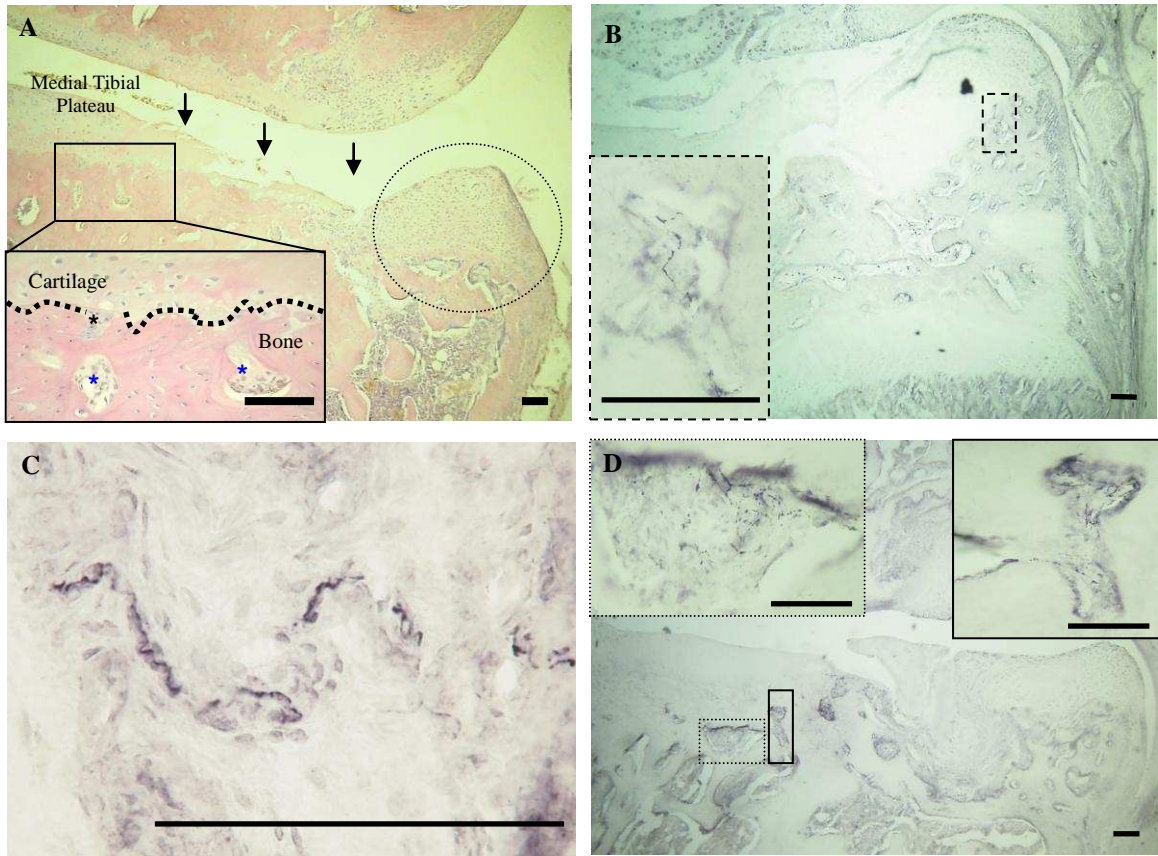


Figure 4.2 Histological changes (chondropathy, osteophytosis, and vascular channels at the osteochondral junction) of the medial tibial plateaux and sensory nerve growth 35 days after meniscal transection surgery in a rat MNX model of OA. **A**, arthritic animal showing full thickness cartilage loss (**arrows**), large osteophyte at the joint margin (**circled**) and several channels crossing into (**black asterisk**) or approaching (**blue asterisk**) the cartilage (**dotted line marks the osteochondral junction**). CGRP positive sensory nerves located in the osteophytes (**B**), in the synovium (**C**) and in the subchondral bone spaces (**D**) of arthritic animals. Coronal sections of the medial tibial plateaux stained with either Haematoxylin and Eosin (**A**) or by immunoreactivity for CGRP positive sensory nerves (**B-D**). Colour transmitted light images were taken using $\times 4$ (**A**, **B** and **D**) and $\times 40$ (**C**) objective lenses of a single representative section from $n = 8$ animals per group. Scale bar = 100 μm .

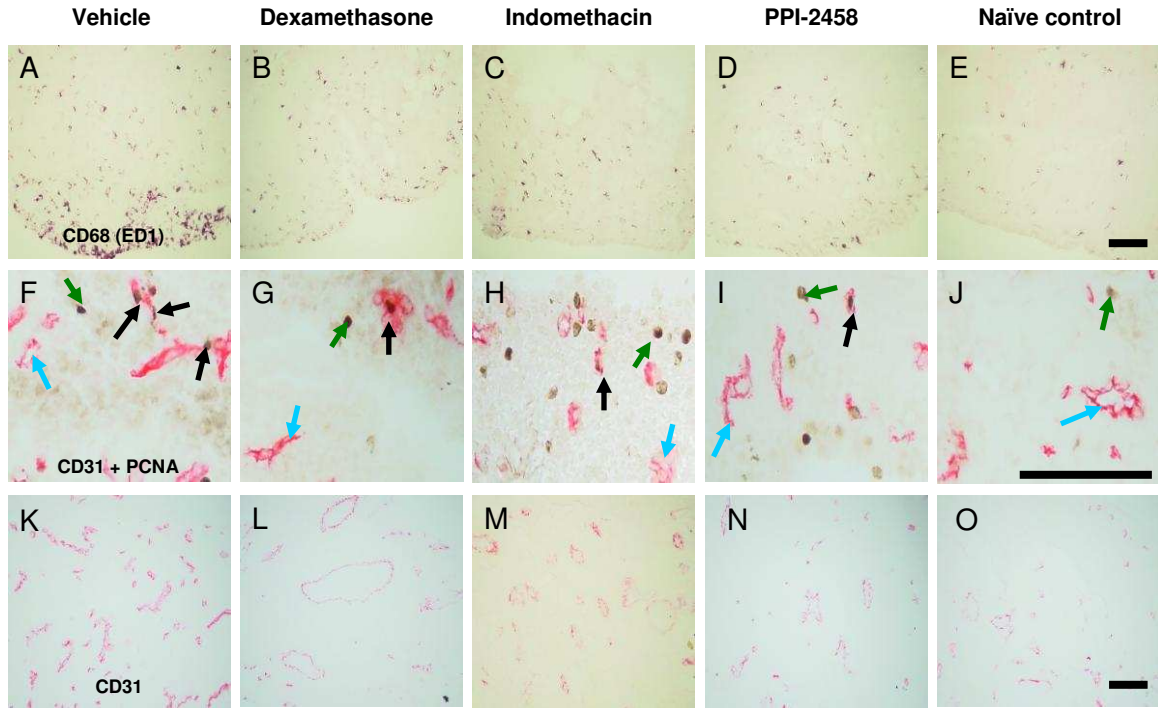


Figure 4.3 Histologic evidence of synovial angiogenesis, vascular density and macrophage infiltration in rat knee joints 35 days after meniscal transection and effects of oral administration of either anti-inflammatory or anti-angiogenic drugs. Macrophage infiltration (**A-E**), EC proliferation (**F-J**) and vascular density (**K-O**) were reduced by the administration of anti-inflammatory drugs (dexamethasone (**B, G** and **L**) and indomethacin (**C, H** and **M**), and the anti-angiogenic agent PPI-2458 (**D, I** and **N**), compared with vehicle-treated arthritic rats (**A, F** and **K**), to naïve control levels (**E, J** and **O**). **A-E**; macrophages (black) delineated by immunoreactivity for ED1. **F-J**; ECs are delineated in red by immunoreactivity for CD31 (**blue arrows**) and proliferating nuclei are delineated black by immunoreactivity for proliferating cell nuclear antigen (PCNA; **green arrows**). **Black arrows** indicate proliferating ECs, which contain PCNA-immunoreactive nuclei. **K-O**; Extent of ECs delineated in red by immunoreactivity for CD31. Negative control sections for CD68 (ED1), CD31 and/or PCNA immunohistochemistry did not show any non-specific staining (**Figure 3.7**). Colour transmitted light images were taken using $\times 10$ (**A-E, K-O**) and $\times 20$ (**F-J**) objective lenses of a single representative section from $n = 8$ animals per group. Scale bar = 100 μm .

4.4.2 Effects of inhibiting inflammation on angiogenesis, joint damage and pain in the MNX model of OA

Following treatment with anti-inflammatory compounds (indomethacin or dexamethasone) measures of synovial inflammation were reduced to levels observed in naïve controls (Figures 4.3 and 4.4 A). Vehicle-treated animals had a greater difference in knee diameter between the operated and non-operated knees at day 12 compared with naïve controls [0.5mm (95% CI 0.2 to 0.8), 0.03 mm (95% CI -0.03 to 0.09), $P < 0.05$], and this persisted to day 35. Treatment with anti-inflammatory drugs reduced knee joint diameter to naïve controls by day 35 (Figure 4.3 B). Indomethacin or dexamethasone significantly reduced indices of synovial angiogenesis (Figures 4.7).

Indomethacin did not significantly reduce joint damage scores (chondropathy and/or osteophytosis) (Figure 4.5 and Table 2), whereas dexamethasone reduced total joint damage [median score 7 (IQR 6 to 8)] compared with vehicle treated controls [median score 12 (IQR 11 to 13), $P = 0.015$] (Figure 4.5 and Table 2). This effect was primarily due to a reduction in chondropathy score [vehicle: median score 10 (IQR 10 to 10), dexamethasone: median score 5 (IQR 5 and 7), $P = 0.03$] (Figures 2C and Table 2). Neither dexamethasone nor indomethacin affected the numbers of channels crossing the osteochondral junction (Table 2).

Vehicle-treated animals having meniscal transection surgery showed a greater weight-bearing asymmetry at day 12 [32g (95% CI 25 to 40)] compared with naïve controls [7g (95% CI -2 to 16), $P < 0.001$]. This asymmetry persisted to day 35 [MNX; 33g (95% CI 25 to 42), naïve; 8 g (95%CI 2 to 13), $P < 0.001$]. Treatment with indomethacin reduced weight-bearing asymmetry at day 14 [13g (95% CI -09 to 27)], compared with vehicle treated controls (40g [95% CI 23 to 56], $P < 0.05$), and weight-bearing asymmetry was completely abolished to naïve control levels by day 35 (Figure 4.6 B). Treatment with dexamethasone was also followed by a reduction at day 26 in weight-bearing asymmetry [4g (95% CI -9 to 17)] compared to vehicle-treated animals [35g (95% CI 25 to 44), $P < 0.01$], and weight-bearing asymmetry was completely abolished to naïve control levels by day 35 (Figure 4.6 A).

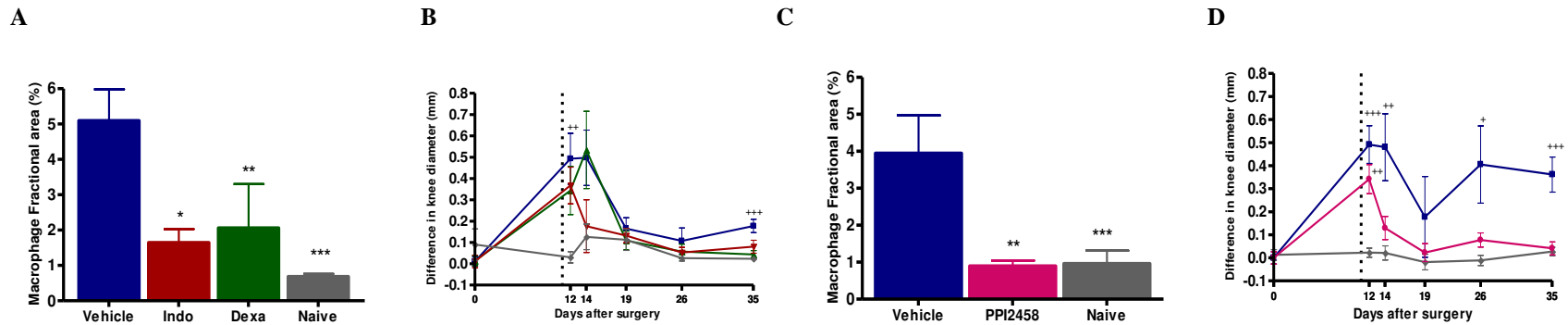


Figure 4.4 Inhibition of measures of inflammation (synovial macrophage infiltration and joint swelling) after meniscal transection surgery in indomethacin, dexamethasone and PPI-2458 treated animals when compared to naïve controls. From day 11 (vertical dotted line in graphs **B** and **D**) to 35, animals having meniscal transection surgery were given oral doses of either indomethacin (2mg/kg/daily) or dexamethasone (0.1mg/kg/daily) or PPI-2458 (5mg/kg/every other day) or vehicle control. Following administration of either indomethacin or dexamethasone (**A** and **B**) macrophage infiltration (**A**) and joint swelling (**B**) were reduced 35 days after meniscal transection surgery compared with vehicle treated animals. The levels were not different from naïve controls. Similarly, following PPI-2458 administration (**C** and **D**), macrophage infiltration (**C**) and joint swelling (**D**) were also reduced 35 days after meniscal transection surgery, compared with vehicle treated animals. The levels were not different from naïve controls. Joint swelling measured by a difference in knee diameter remained higher in animals that had meniscal transection surgery and were treated with vehicle control compared to naïves throughout the experiment. All 3 drugs inhibited joint swelling to levels that were not different to naïve controls by day 35 (**B** and **D**). Arithmetic means (\pm S.E.M) of $n = 8$ animals per group. Macrophage fractional area (logarithmically transformed) and knee diameters were analysed using one way analysis of variance (ANOVA). Univariate comparisons were made using Student's T-test with Bonferroni's correction for multiple comparisons. * $P < 0.05$, ** $P < 0.01$, *** $P < 0.001$ versus arthritic, vehicle control. + $P < 0.05$, ++ $P < 0.01$, +++ $P < 0.001$ versus naïve controls.

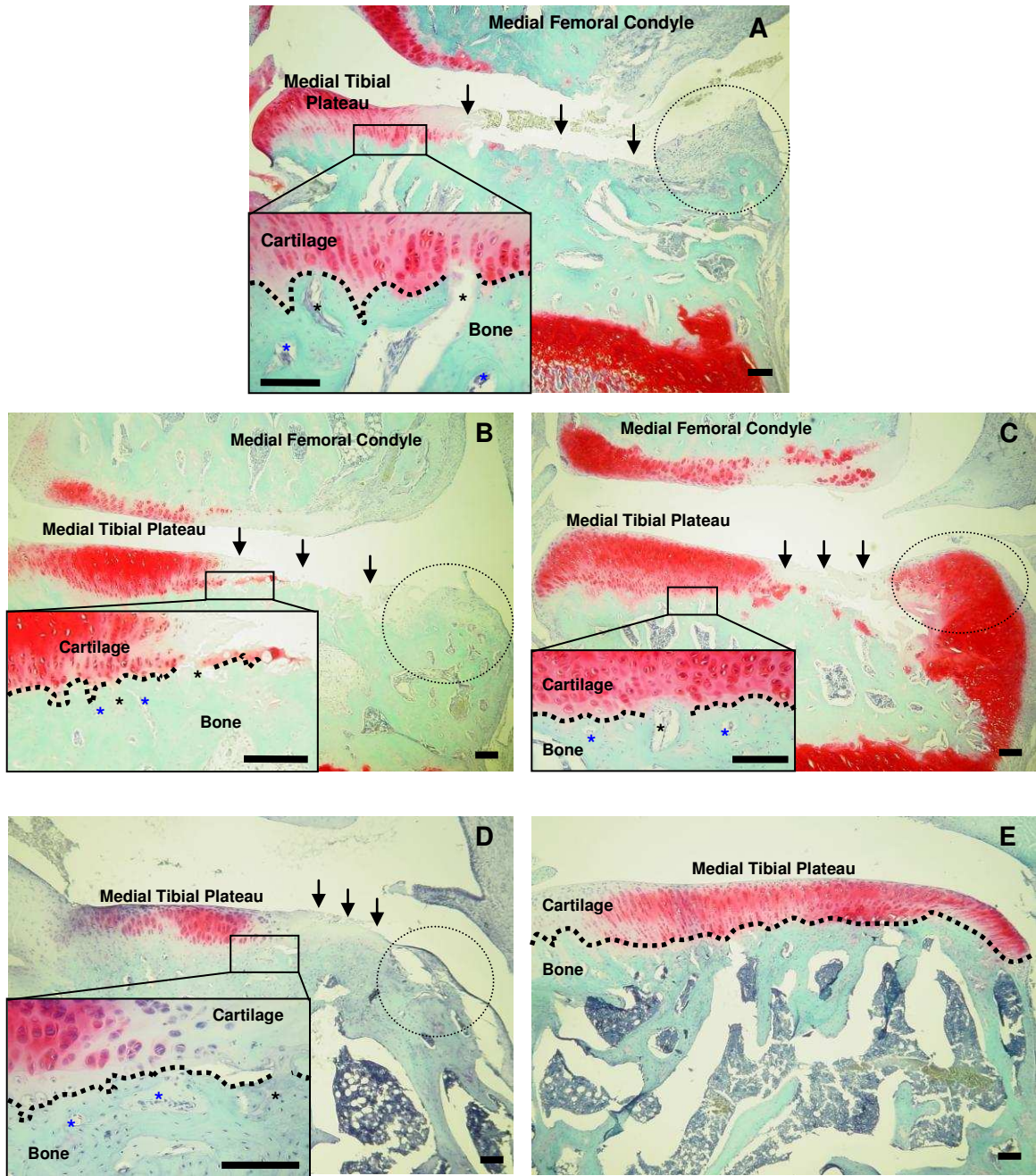


Figure 4.5 Histological changes (chondropathy, osteophytosis and vascular channels at the osteochondral junction) of the medial tibial plateaux 35 days post MNX surgery. **A**, medial tibial plateau of an animal having meniscal transection surgery and vehicle treated arthritic control showing severe, full thickness cartilage loss (**arrows**) with a large osteophyte formed at the joint margin (**circled**) and several channels crossing into (**black asterisk**) or approaching (**blue asterisk**) the cartilage (**dotted line; separates underlying bone from cartilage**). **B** and **C**, medial tibial plateaux from animals that have undergone meniscal transection surgery and treated with anti-inflammatory drugs indomethacin and dexamethasone respectively, showing moderate cartilage loss with fibrillation and reduced proteoglycan staining and

chondrocyte density (**arrows**). A large osteophyte is evident at the joint margins (**circled**) with channels (**black asterisk**) crossing into the cartilage. **D**, medial tibial plateau from PPI-2458 treated animal showing mild cartilage fibrillation and loss of proteoglycan staining and chondrocyte density (**arrows**). A developing osteophyte can be seen at the joint margin (**circled**) with some channels crossing into the cartilage from underlying subchondral bone (**black asterisk**). **E**, naïve control showing normal smooth cartilage and joint margins. The chondrocytes are homogenously distributed throughout the cartilage and there is neither evidence of proteoglycan loss nor channels entering the avascular cartilage. Coronal sections of the medial tibial plateaux stained with Safranin-O. Colour transmitted light images were taken using $\times 4$ objective lens of a single representative section from $n = 8$ animals per group. Scale bar = 100 μm .

Structural Change	Anti-inflammatory Treatment				Anti-angiogenic Treatment		
	Vehicle	Indomethacin	Dexamethasone	Naives	Vehicle	PPI-2458	Naives
Total damage score	12 (11 to 13)	10 (8 to 12)	7 (7 to 9) ⁺⁺	1 (0 to 2) ⁺⁺	13 (10 to 13)	8 (4 to 10) ⁺	1 (0 to 1) ⁺⁺
Osteophytes	2 (2 to 3)	2 (2 to 3)	2 (1 to 2)	0 (0 to 0) ⁺⁺⁺	3 (2 to 3)	1 (0 to 3) ⁺	0 (0 to 0) ⁺⁺⁺
Cartilage damage	10 (10 to 10)	9 (5 to 10)	5 (5 to 7) ⁺	1 (0 to 2) ⁺⁺	10 (8 to 10)	6 (4 to 8)	1 (0 to 1) ⁺⁺
Channels crossing medial OCJ	3 (3 to 5)	3 (2 to 4)	3 (2 to 3)	1 (0 to 1) ⁺⁺	5 (4 to 6)	2 (1 to 5)	1 (0 to 1) ⁺⁺

Table 2 Reduction in OA structural changes in medial tibial plateaux following anti-inflammatory/anti-angiogenic treatment in the MNX model of OA. From day 11 to 35, animals having meniscal transection surgery were given oral doses of either indomethacin (2mg/kg/daily) or dexamethasone (0.1mg/kg/daily), PPI-2458 (5mg/kg/every other day) or vehicle control. Following administration of dexamethasone, total joint damage (combined chondropathy and osteophyte score) was reduced compared to vehicle treated controls. This reduction in total damage score was mainly due to a reduction of cartilage damage. Indomethacin did not significantly reduce joint damage. Channels crossing the osteochondral junction were not significantly reduced following treatment with either indomethacin or dexamethasone, and remained more abundant than in naïve controls. Following PPI-2458 administration total joint damage in the MNX model of OA was reduced compared with vehicle treated controls. This reduction was mainly due to the attenuation of osteophyte growth. Channels growing into the cartilage from underlying subchondral bone were not significantly different after PPI-2458 compared with either naïve or with vehicle treated arthritic controls. Data are given as median (Interquartile Range [IQR]). Differences between groups (n = 8 animals per group) are analysed using Kruskal-Wallis test followed by Man-Whitney U test to compare two groups with Bonferroni's correction for multiple comparisons . ⁺ P < 0.05, ⁺⁺ P < 0.01, ⁺⁺⁺ P < 0.001 versus vehicle-treated arthritic animals.

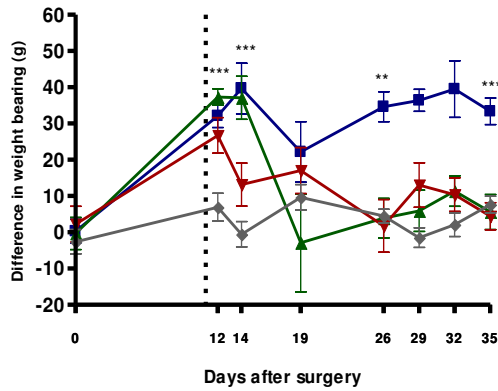
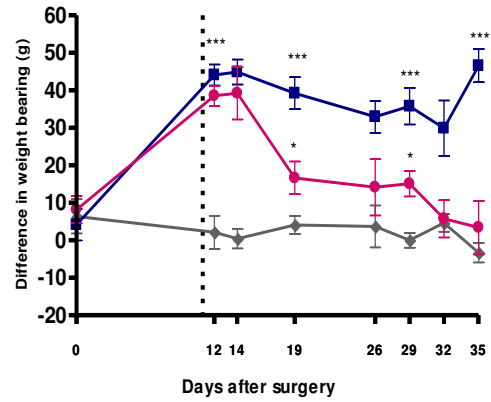
A**B**

Figure 4.6 Time course of the inhibition of meniscal transection-induced knee joint pain behaviour following the administration of anti-inflammatory or anti-angiogenic treatment. **A**, pain behaviour in arthritic animals treated with either indomethacin (\blacktriangledown) or dexamethasone (\blacktriangle) or vehicle control (\blacksquare). **B**, pain behaviour in arthritic animals treated with either PPI-2458 (\bullet) or vehicle control (\blacksquare). On day 0, animals underwent meniscal transection surgery. From day 11 (vertical dotted line) to 35, the arthritic animals were given oral doses of either indomethacin (\blacktriangledown 2mg/kg/daily), of dexamethasone (\blacktriangle 0.1mg/kg/daily), PPI-2458 (\bullet 5mg/kg/every other day) or vehicle control (\blacksquare). Pain behaviour was measured by a difference in hind paw weight bearing between 0 to 35 days after meniscal transection surgery. Vehicle-treated arthritic animals showed increased pain behaviour compared to naïve controls (\diamond) 12 days post meniscal transection surgery and this increase was maintained to day 35. Indomethacin significantly inhibited pain behaviour in the arthritic animals on day 14 and completely abolished it to naïve levels by day 35. In dexamethasone treated animals, pain behaviour was inhibited to naïve levels on day 26 and this inhibition was maintained to day 35. PPI-2458 treated animals showed a reduction in pain behaviour on day 19 which was completely inhibited to naïve control levels by day 35. Data is shown as arithmetic means (\pm S.E.M) of $n = 8$ animals per group. Differences between groups were analysed using one way analysis of variance (ANOVA). Univariate comparisons were made using Student's T-test with Bonferroni's correction for multiple comparisons. * $P < 0.05$, ** $P < 0.01$, *** $P < 0.001$ versus naïve controls.

4.4.3 Effects of inhibiting angiogenesis on inflammation, joint damage and pain in the MNX model of OA

Following treatment with the angiogenesis inhibitor PPI-2458, measures of inflammation (synovial macrophage infiltration and joint swelling) were reduced 35 days after meniscal transection surgery to levels observed in the naïve controls (Figures 4.3 and 4.4). PPI-2458 reduced indices of synovial angiogenesis (Figures 4.3 and 4.7). PPI-2458 also reduced the number of vascularised channels at the osteochondral junction [1 vascularised channel per medial tibial plateau section (IQR 0 to 2)] compared with vehicle treated controls [4 vascularised channels per medial tibial plateau section (IQR 2 to 5), $P = 0.026$] (Figure 4.7).

Total joint damage score was also reduced following treatment with PPI-2458 [Score 8 (IQR 4 to 9.5)] compared with vehicle treated controls [Score 13 (IQR 10 to 13), $P = 0.016$] but not completely abolished to naïve levels (Figure 4.5 and Table 2). Reduction in total joint damage score was primarily due to the attenuation of osteophyte growth [vehicle: median score 3 (IQR 3 to 3), PPI-2458: median score 1 (IQR 0 to 3), $P = 0.044$]. PPI-2458 had no significant effect on the integrity of the osteochondral junction as indicated by the total number of channels crossing the osteochondral junction (Table 2).

PPI-2458 reduced weight-bearing asymmetry [17g (95% CI 6 to 27)] compared with vehicle treatment [39g (95% CI 29 to 49), $P < 0.01$] in the MNX model of OA at day 19. Weight-bearing asymmetry was completely inhibited to naïve control levels by day 35 (Figure 4.6B).

Animals treated with either dexamethasone or PPI-2458 gained weight at a slower rate compared to animals in other treatment groups and to naïve controls. Blood glucose levels (not-fasting) of dexamethasone did not differ significantly between the groups at time on day 35 (Figure 4.8).

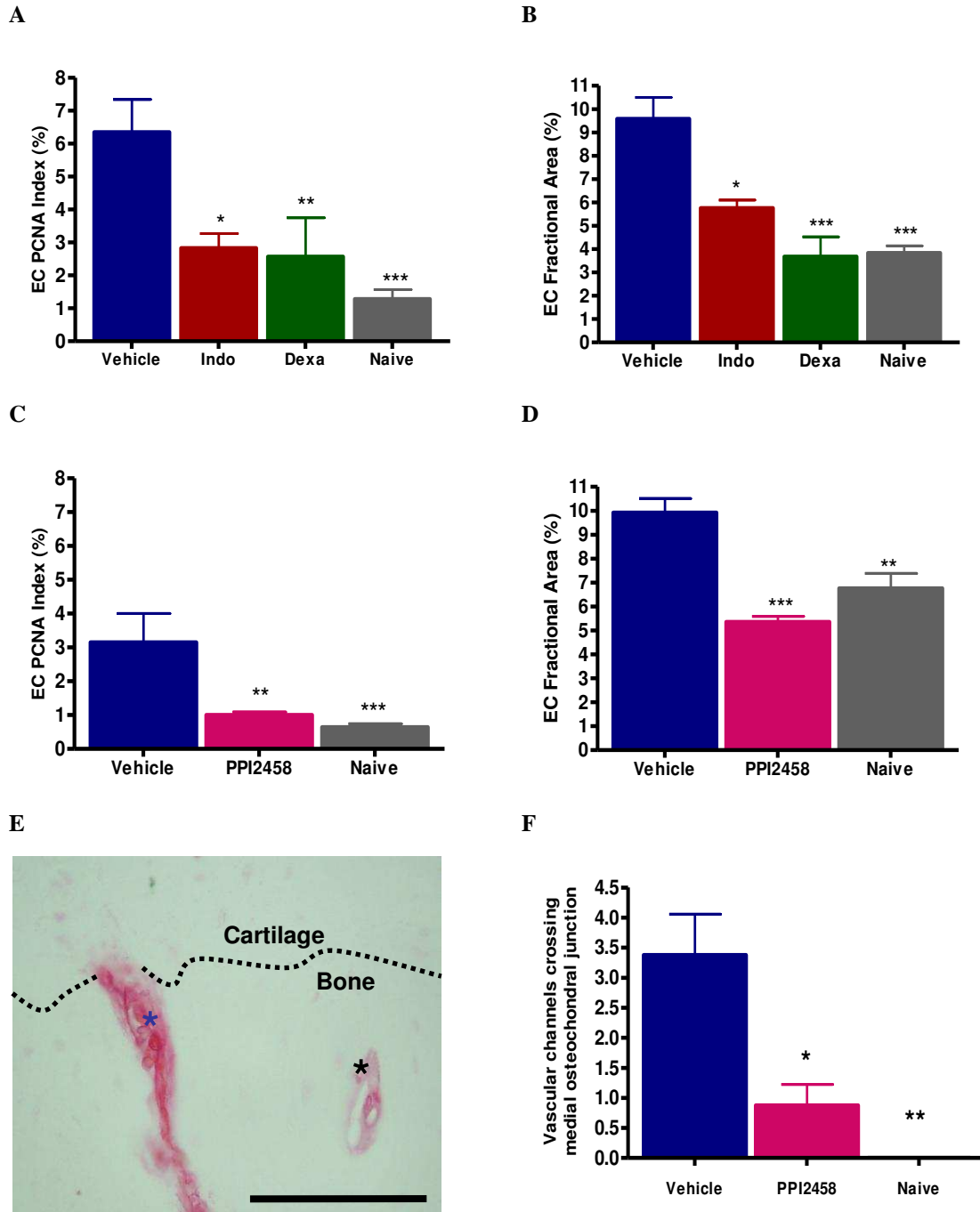


Figure 4.7 Synovial angiogenesis (synovial EC proliferation and vascular density) and vascularisation of channels crossing osteochondral junction in the medial tibial plateaux. From day 11 to 35, animals having meniscal transection surgery were given oral doses of either indomethacin (2mg/kg/daily) or dexamethasone (0.1mg/kg/daily) or PPI-2458 (5mg/kg/every other day) or vehicle control. Following administration of either indomethacin or dexamethasone (**A** and **B**), EC proliferation index (EC PCNA index; **A**) and vascular density (**B**) were significantly reduced compared with vehicle

treated animals. The levels were similar to naïve controls. Similarly, following PPI-2458 administration (**C** and **D**), EC PCNA index (**C**) and vascular density (**D**) were also significantly reduced compared with vehicle treated animals. The levels were similar to naïve controls. Coronal section of medial tibial plateau from an animal having meniscal transection surgery and treated with vehicle control, showing positive-staining with Griffonia simplicifolia lectin-1 (alkaline phosphatase reaction product) (**E**) of vascular channels crossing (**blue asterisk**) or approaching (**black asterisk**) the osteochondral junction (**dotted line**; separates underlying bone from cartilage). Following PPI-2458 administration, vascular channels crossing the medial osteochondral junction were reduced (**F**). Graphs show the arithmetic means (\pm S.E.M) of $n = 8$ animals per group. EC PCNA index and fractional area (logarithmically transformed) were analysed using one way analysis of variance (ANOVA). Univariate comparisons were made using Student's T-test with Bonferroni's correction for multiple comparisons. Osteochondral vascularity was analysed using Kruskal-Wallis test followed by Mann-Whitney to compare two groups with Bonferroni's correction for multiple comparisons. * $P < 0.05$, ** $P < 0.01$, *** $P < 0.001$ versus vehicle control. Colour transmitted light image was taken using $\times 20$ objective lens of a single representative section from $n = 8$ animals per group. Scale bar = 100 μm .

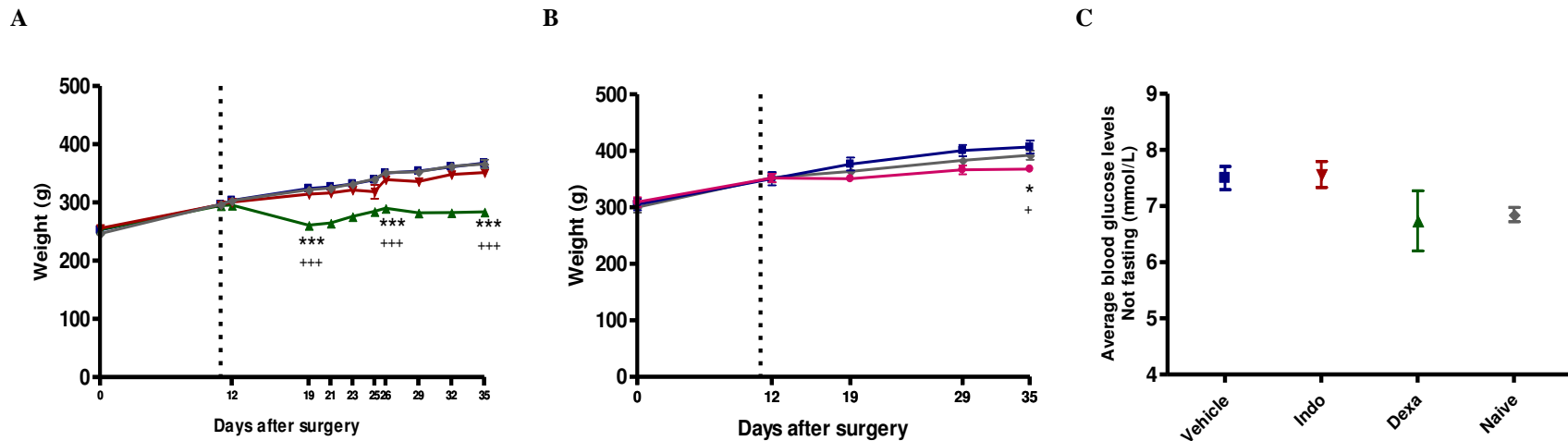


Figure 4.8 Weight gain and blood glucose levels following the administration of either anti-inflammatory or anti-angiogenic treatment. **A**, weight gain of arthritic animals treated with either indomethacin (▼) or dexamethasone (▲) or vehicle control (■). Naïve controls were used as baseline (◆). **B**, weight gain of arthritic animals treated with either PPI-2458 (●) or vehicle control (■). Naïve controls were used as baseline (◆). On day 0, animals underwent meniscal transection surgery. From day 11 (vertical dotted line) to 35, the arthritic animals were given oral doses of either indomethacin (▼ 2mg/kg/daily), or dexamethasone (▲ 0.1mg/kg/daily), PPI-2458 (● 5mg/kg/every other day) or vehicle control (■). Animals treated with either dexamethasone (**A**) or PPI-2458 (**B**) gained weight at a slower rate compared to naïve controls. Animals in all other treatment groups gained weight at a similar rate. At day 35 following meniscal transection surgery, non-fasting blood glucose levels did not differ significantly between groups (**C**). Graphs show the arithmetic means (\pm S.E.M) of $n = 8$ animals per group. Comparisons between groups were made using one way analysis of variance (ANOVA). Univariate comparisons were made using Student's T-test with Bonferroni's correction for multiple comparisons. * $P < 0.05$, *** $P < 0.001$ versus naïve controls. + $P < 0.05$, +++ $P < 0.001$ versus vehicle controls.

4.4.4 Effects of enhancing synovitis using 2% carrageenan on angiogenesis, joint damage and pain in the MNX model of OA

Following intra-articular injection of 2% carrageenan into the operated knee, 12 days after meniscal transection surgery, synovial inflammation and angiogenesis were increased compared with saline injected controls (Figures 4.9 to 4.13). Knee joint swelling was transiently increased above the levels of sham operated and carrageenan injected controls, before returning to naïve levels at day 19 (Figure 4.12).

Carrageenan injection did not significantly exacerbate structural changes observed in the MNX model of OA (Figure 4.14 and Table 3). However, combining data from two separate experiments (Table 4) showed that 2% carrageenan injection did exacerbate total joint damage in the MNX model of OA and this was mainly due to increase in cartilage damage (chondropathy). A greater weight-bearing asymmetry was observed following carrageenan injection at day 13 compared to meniscal transected and saline injected controls [Carrageenan: 94g (95% CI 81 to 106), MNX: 45g (95% CI 33 to 58), $P < 0.001$]. This asymmetry persisted to day 14 before reaching similar levels as those observed in meniscal transected and saline injected controls at day 19 to day 35 (Figure 4.15 A).

4.4.5 Effects of inhibiting angiogenesis on synovitis, joint damage and pain in the combined MNX and 2% carrageenan model

Following treatment with the angiogenesis inhibitor PPI-2458, synovitis and synovial angiogenesis were reduced but not completely abolished to naïve control levels, 35 days after meniscal transection surgery and 23 days after intra-articular injection of 2% carrageenan (Figures 4.9 to 4.13). Total joint damage score was also reduced following treatment with PPI-2458 [Score 9 (IQR 1 to 11)] compared with vehicle treated controls [Score 13 (IQR 12 to 15), $P = 0.02$] but not completely abolished to naïve levels (Figures 4.14 and Table 3). PPI-2458 had no significant effect on the integrity of the osteochondral junction as indicated by the total number of channels crossing the osteochondral junction (Table 3). PPI-2458 reduced weight-bearing asymmetry [42g (95% CI 28 to 57)] compared with vehicle treatment [82g (95% CI 68 to 97), $P < 0.001$] in the meniscal transected and carrageenan injected animals at day 14. Weight-bearing asymmetry was gradually reduced but not completely inhibited to naïve control levels by day 35 (Figure 4.15 B). SHAM operated animals displayed a reduction in weight-bearing asymmetry [12g (95% CI -2 to 27)] compared with meniscal transected animals [40g (95% CI 24 to 55), $P < 0.01$] at day 19. This reduction was maintained to day 35 [SHAM: 2g (95% CI -15 to 21), MNX: 48g (95% CI 22 to 75), $P < 0.001$] (Figure 4.15 C).

PPI-2458 treated animals failed to gain weight at the same rate as naïve controls from day 29 [PPI2458: 351g (95% CI 338 to 364), naïve controls: 376g (95% CI 366 to 386), $P < 0.01$] to day 35 [PPI2458: 361g (95% CI 350 to 372), naïve controls: 392g (95% CI 382 to 401), $P < 0.01$] (Figure 4.16).

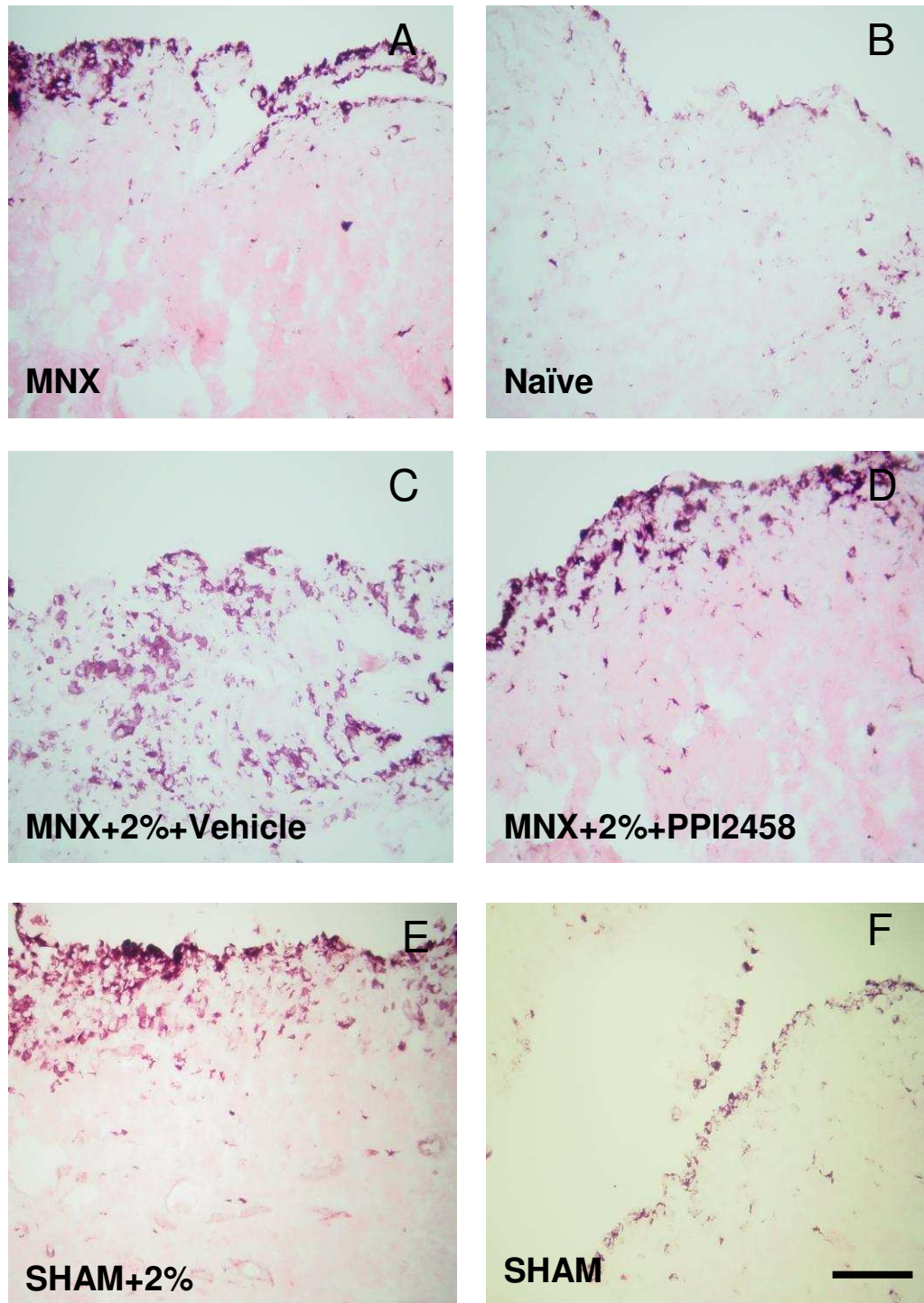


Figure 4.9 Histological evidence of synovial macrophage infiltration in rat knee joints 35 days after either meniscal transection or SHAM surgery with intra-articular injection of 2% carrageenan and either oral administration of PPI-2458 or vehicle control treatment. Macrophage infiltration was increased after meniscal transection surgery (**A**) compared to naïve controls (**B**) and further exacerbated after the intra-articular injection of 2% carrageenan into rat knee joints 12 days after meniscal transection surgery (**C**).

This exacerbation was reduced following administration of anti-angiogenic agent PPI-2458 (**D**). Intra-articular injection of 2% carrageenan following SHAM surgery (**E**) also increased synovial macrophage infiltration compared to the arthritic rats (**A**) and naïve controls (**B**). Levels were however lower than the combined MNX and 2% carrageenan model (**C**). SHAM operated controls (**E**) displayed similar extent of synovial macrophage infiltration to naïve control animals (**B**). Macrophages (black) are delineated by immunoreactivity for ED1. Negative control sections did not show any non-specific staining (**Figure 3.7**). Colour transmitted light images were taken using $\times 10$ objective lens of a single representative section from $n = 8$ animals per group. Scale bar = 100 μm .

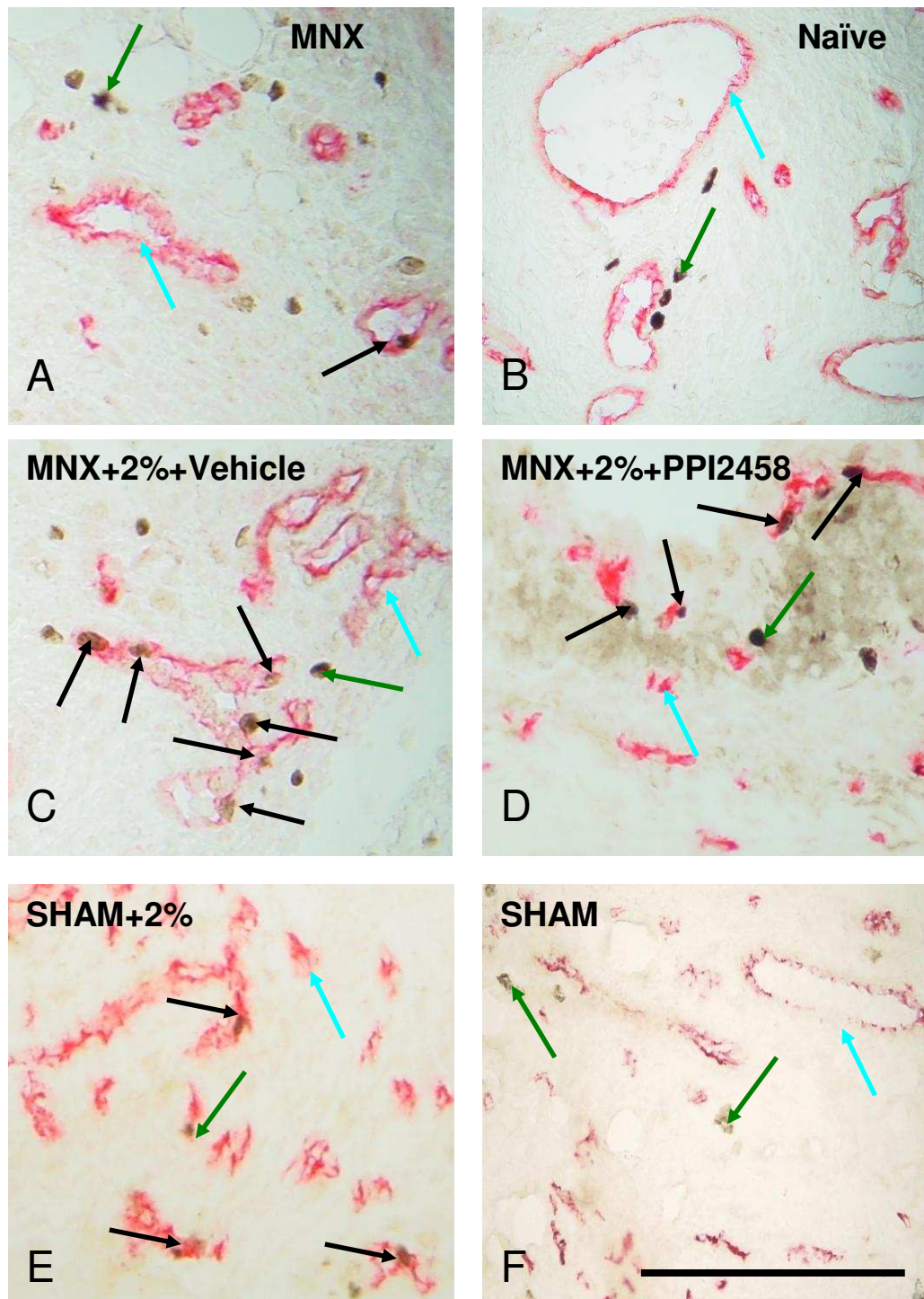


Figure 4.10 Histological evidence of synovial angiogenesis in rat knee joints 35 days after either meniscal transection or SHAM surgery with intra-articular injection of 2% carrageenan and either oral administration of PPI-2458 or vehicle control treatment. Synovial angiogenesis was increased after meniscal transection surgery (A) compared to naïve controls (B) and further exacerbated after the intra-articular injection of 2% carrageenan into rat knee joints 12 days after meniscal transection surgery (C).

This exacerbation was reduced following administration of anti-angiogenic compound PPI-2458 (**D**). Intra-articular injection of 2% carrageenan following SHAM surgery (**E**) also increased synovial angiogenesis compared to the arthritic rats (**A**) and naïve controls (**B**). Levels were however lower than the combined MNX and 2% carrageenan model (**C**). SHAM operated controls (**E**) displayed similar extent of synovial angiogenesis to naïve control animals (**B**). ECs are delineated in red by immunoreactivity for CD31 (**blue arrows**). Proliferating nuclei are delineated black by immunoreactivity for proliferating cell nuclei antigen (PCNA; **green arrows**). **Black arrows** indicate proliferating ECs, which contain PCNA-immunoreactive nuclei. Negative control sections for CD31 and/or PCNA immunohistochemistry did not show any non-specific staining (**Figure 3.7**). Colour transmitted light images were taken using $\times 20$ objective lens of a single representative section from $n = 8$ animals per group. Scale bar = 100 μm .

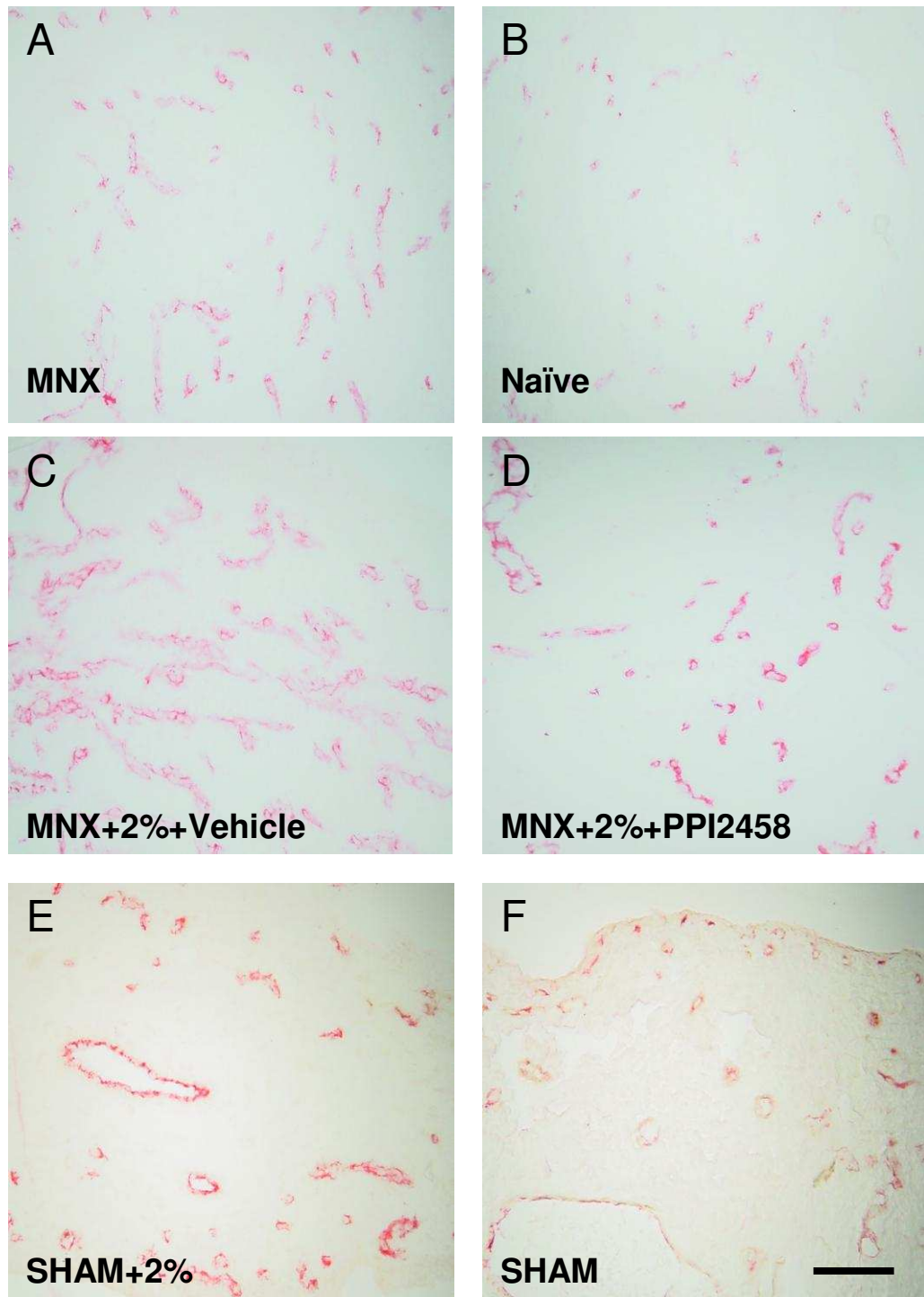


Figure 4.11 Histological evidence of synovial vascular density in rat knee joints 35 days after either meniscal transection or SHAM surgery with intra-articular injection of 2% carrageenan and either oral administration of PPI-2458 or vehicle control treatment. Synovial vascular density was increased after meniscal transection surgery (**A**) compared to naïve controls (**B**) and further exacerbated after the intra-articular injection of 2% carrageenan into rat knee joints 12 days after meniscal transection surgery (**C**).

This exacerbation was reduced following administration of anti-angiogenic agent PPI-2458 (**D**). Intra-articular injection of 2% carrageenan following SHAM surgery (**E**) did not significantly increase synovial vascular density compared to the arthritic rats (**A**) but did to naïve controls (**B**). Levels were similar to the combined MNX and 2% carrageenan model (**C**). SHAM operated controls (**E**) displayed similar extent of synovial angiogenesis to naïve control animals (**B**). The extent of endothelial cells are delineated in red by immunoreactivity for CD31. Negative control sections for CD31 immunohistochemistry did not show any non-specific staining (**Figure 3.7**). Colour transmitted light images were taken using $\times 20$ objective lens of a single representative section from $n = 8$ animals per group. Scale bar = 100 μm .

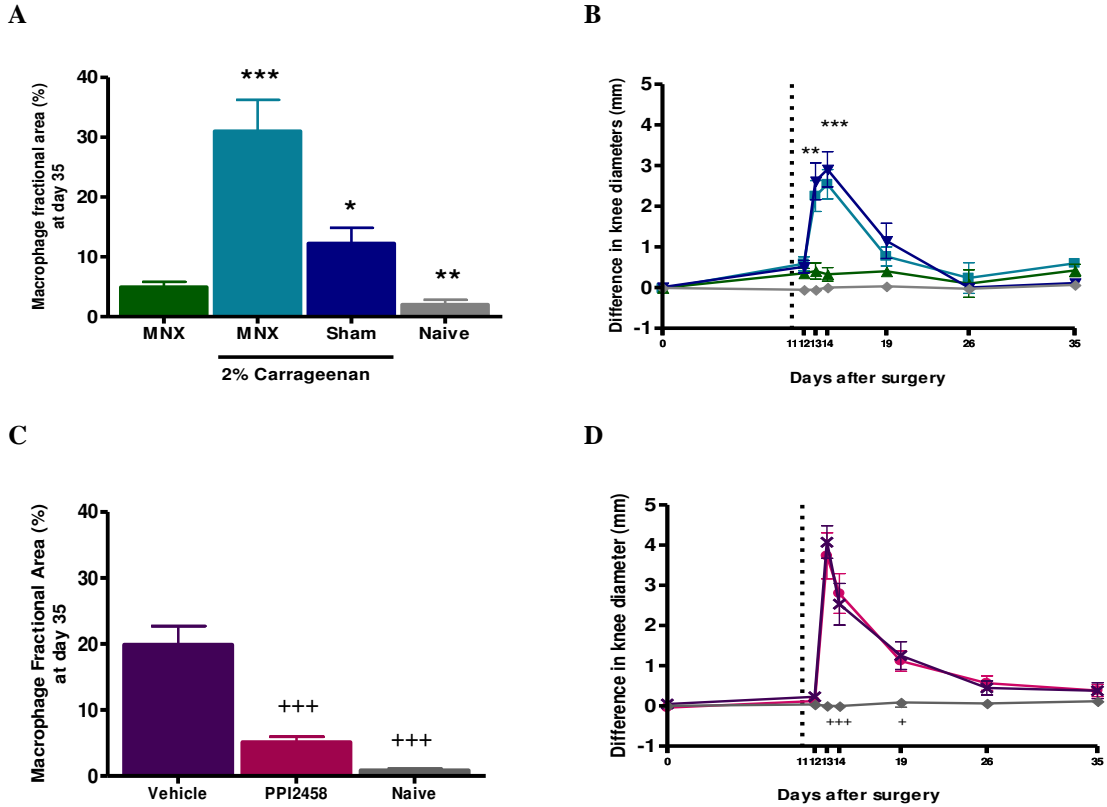


Figure 4.12 Inhibition of measures of inflammation (synovial macrophage infiltration and joint swelling) 35 days after meniscal transection surgery and 23 days after 2% carrageenan injection in either PPI-2458 or vehicle treated animals. Animals had either meniscal transection or SHAM surgery on day 0. Intra-articular injection of either 2% carrageenan or saline control (\blacktriangle) was given in the operated knee on day 12. From day 11 (**vertical dotted line** in graphs **B** and **D**) to 35, animals having either meniscal transection or sham surgery were given oral doses of either PPI-2458 (5mg/kg/every other day) or vehicle control. Intra-articular injection of 2% carrageenan was followed by an increase in macrophage infiltration (**A**) and joint swelling (**B**) in the meniscal transected (\blacksquare) and sham operated (\blacktriangledown) animals. Macrophage infiltration was reduced following the administration of PPI-2458 (**C**), in meniscal transected animals given 2% carrageenan injection (\bullet), 35 days after surgery compared with vehicle treated animals (\times). The levels were not reduced to naïve controls (\blacklozenge). However PPI-2458 did not affect joint swelling in these animals (**D**). Joint swelling measured by a difference in knee diameter remained higher in animals that had meniscal transection surgery and were treated with vehicle control compared to naïves throughout the experiment. Graphs show arithmetic mean and \pm S.E.M of 8 knees per group. Macrophage fractional areas (logarithmically transformed) and knee diameters were analysed using one way analysis of variance (ANOVA). Univariate comparisons were made using Student's T-test with Bonferroni's correction for multiple comparisons. * $P < 0.05$, ** $P < 0.01$, *** $P < 0.001$ versus arthritic, saline control (\blacktriangle). + $P < 0.05$, ++ $P < 0.01$, +++ $P < 0.001$ versus arthritic animals, treated with vehicle control and given 2% carrageenan injection (\times).

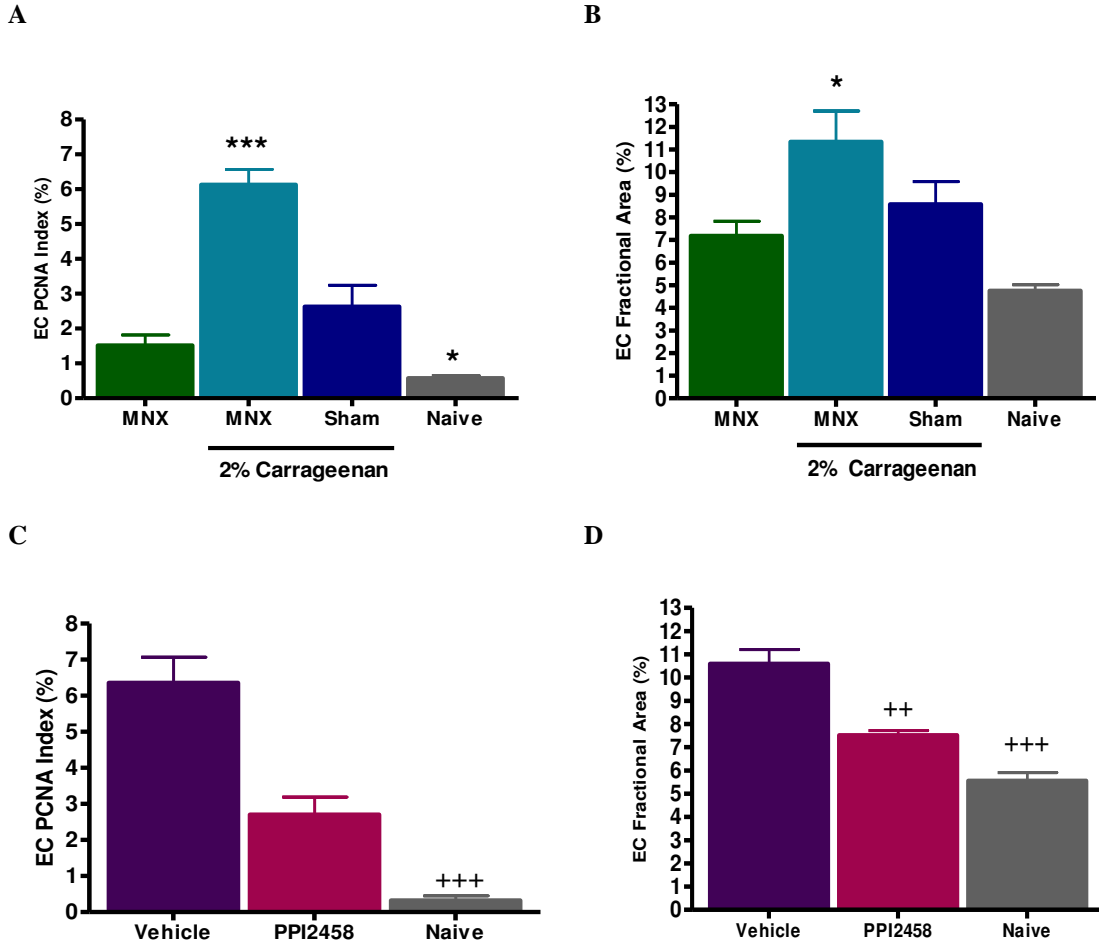


Figure 4.13 Synovial angiogenesis (EC proliferation and vascular density) after meniscal transection surgery and 2% carrageenan injection in PPI-2458 treated animals. Twelve days after either meniscal transection or SHAM surgery, animals were given intra-articular injection of 2% carrageenan into their operated knee joint. From day 11 to 35, the arthritic animals were given oral doses of either PPI-2458 (5mg/kg/every other day) or vehicle control. Following carrageenan injection, EC proliferation index (EC PCNA index; **A**) and vascular density (EC fractional area) (**B**) were increased in the arthritic animals. Indices of angiogenesis were reduced following PPI-2458 treatment, (**C** and **D**), compared with vehicle treated animals. The levels were not similar to naïve controls. Graphs show arithmetic mean and \pm S.E.M of 8 knees per group. EC PCNA index and fractional areas (logarithmically transformed) were analysed using one way analysis of variance (ANOVA). Univariate comparisons were made using Student's T-test with Bonferroni's correction for multiple comparisons * $P < 0.05$, *** $P < 0.001$ versus arthritic and saline injected control. ** $P < 0.01$, *** $P < 0.001$ versus arthritic-carrageenan injected and vehicle treated animals.

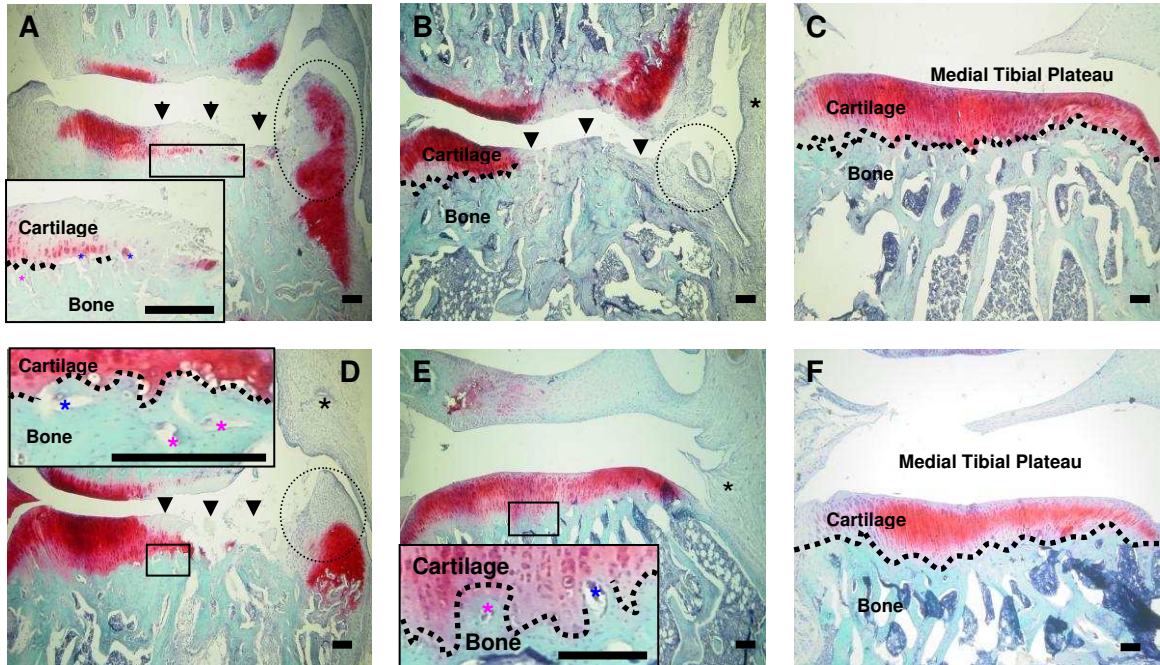


Figure 4.14 Histological changes (chondropathy, osteophytosis and channels at the osteochondral junction) of the medial tibial plateaux 35 days after either meniscal transection or SHAM surgery with intra-articular injection of 2% carrageenan and either oral administration of PPI-2458 or vehicle control treatment. **A**, medial tibial plateau from an animal having meniscal transection surgery showing severe, full thickness cartilage loss (**arrows**) with a large osteophyte formed at the joint margin (**circled**) and several channels crossing into (**blue asterisk**) or approaching (**pink asterisk**) the cartilage (**dotted line; separates underlying bone from cartilage**). No inflammatory tissue infiltration is evident. **B**, medial tibial plateau from an animal having intra-articular injection of 2% carrageenan (12 days after surgery) into the operated knee joint, showing infiltration of inflammatory tissue (**black asterisk**), an osteophyte (**circled**) and grossly enhanced, full thickness cartilage loss (**arrows**). **C**, naïve control showing normal smooth cartilage, joint margins and no inflammatory tissue infiltration. The chondrocytes are homogeneously distributed throughout the cartilage and there is neither evidence of proteoglycan loss nor channels entering the avascular cartilage. **D**, medial tibial plateau from an animal that has undergone meniscal transection surgery with 2% carrageenan injection and treated with PPI-2458 showing cartilage loss, reduced proteoglycan staining and chondrocyte density (**arrows**). An osteophyte can be seen at the joint margin (**circled**) with some channels crossing into the cartilage from underlying subchondral bone (**blue asterisk**). **E**, medial tibial plateau from a sham-operated animal having 2% carrageenan intra-articular injection (12 days after surgery) into the operated knee joint, showing inflammatory tissue infiltration (**black asterisk**), moderate cartilage changes with very few channels crossing into the cartilage (**blue asterisk**). **F**, medial tibial plateau from a SHAM-operated animal, showing normal smooth cartilage and joint margins with no inflammatory tissue infiltration. The chondrocytes are homogeneously distributed throughout the cartilage and there is neither evidence of proteoglycan loss nor channels entering the

avascular cartilage. Coronal sections of the medial tibial plateaux stained with Safranin-O. Colour transmitted light images were taken using $\times 4$ objective lens of a single representative section from $n = 8$ animals per group. Scale bar = 100 μm .

Structural Change	Exacerbation of inflammation using 2% carrageenan				Anti-angiogenic Treatment		
	MNX	MNX + 2%	SHAM + 2%	Naive	Vehicle	PPI-2458	Naive
Total damage score	5 (3 to 11) **	12 (6 to 18) **	2 (1 to 5) * +	0 (0 to 0)	13 (12 to 16) **	9 (1 to 11) * +	0 (0 to 1)
Osteophytes	2 (1 to 3) **	3 (1 to 3) **	1 (0 to 1)	0 (0 to 0)	2 (1 to 2) ***	1 (0 to 1)	0 (0 to 0)
Cartilage damage	3 (2 to 8) **	9 (4 to 15) **	1 (1 to 4) ** +	0 (0 to 0)	10 (10 to 15) **	8 (1 to 10) **	0 (0 to 1)
Channels crossing medial OCJ	4 (4 to 5) **	7 (4 to 9) **	2 (2 to 3) **	0 (0 to 1)	6 (5 to 7) **	5 (5 to 6) **	2 (1 to 2)

Table 3 Exacerbation and/or reduction in OA structural changes in medial tibial plateaux following intra-articular injection of 2% carrageenan into operated knee joints and/or anti-angiogenic treatment in the MNX model of OA. Arthritic or SHAM operated animals were given intra-articular injection into their operated knee joint of 2% carrageenan 12 days after meniscal transection surgery. From day 11 to 35, animals having meniscal transection or SHAM surgery were given oral doses of PPI-2458 (5mg/kg/every other day) or vehicle control. Intra-articular injection of 2% carrageenan did not significantly exacerbate the structural changes in the MNX model of OA. Administration of PPI-2458 was followed by a reduction in total joint damage in the combined MNX and 2% carrageenan model compared with vehicle treated controls. Data are given as median (Interquartile Range [IQR]). Differences between groups (n = 8 animals per group) are analysed using Kruskal-Wallis test followed by Man-Whitney U test to compare two groups with Bonferroni's correction for multiple comparisons. * P < 0.05, ** P < 0.01, *** P < 0.001 versus naives. + P < 0.05 versus meniscal transected and carrageenan injected animals.

Exacerbation of inflammation using 2% carrageenan in the rat MNX model of OA					
Structural Change	MNX	MNX + 2%	SHAM	SHAM + 2%	Naive
Total damage score	9 (9 to 9) ^{***+}	13 (13 to 13) ^{***}	1 (1 to 1) ⁺⁺⁺	0 (0 to 0) ⁺⁺⁺	0 (0 to 0) ⁺⁺⁺
Osteophytes	2 (1 to 3) ^{***}	2 (0 to 3) ^{**}	0 (0 to 1)	0 (0 to 0) ⁺	0 (0 to 0) ⁺⁺
Cartilage damage	6 (5 to 10) ^{***+++}	10 (10 to 12) ^{***}	0 (0 to 1) ⁺⁺⁺	0 (0 to 0) ⁺⁺⁺	0 (0 to 0) ⁺⁺⁺
Channels crossing medial OCJ	15 (10 to 22) ^{***}	18 (12 to 29) ^{***}	0 (0 to 2) ⁺⁺⁺	5 (2 to 6) ⁺	0 (0 to 4) ⁺⁺⁺

Table 4 Exacerbation in OA structural changes in medial tibial plateaux following intra-articular injection of 2% carrageenan in the rat MNX model of OA. These are combined data from two separate experiments (MNX: n = 16, MNX+2%: n = 16, SHAM: n = 8, SHAM+2%: n = 8, Naives: n = 16). Arthritic or SHAM operated animals were given intra-articular injection into their operated knee joint of 2% carrageen 12 days after meniscal transection surgery. Intra-articular injection of 2% carrageenan in the rat MNX model of OA was followed by an increase in total joint damage score which was mainly due to an increase in cartilage damage. Structural changes in the joints were more severe in the combined MNX and carrageenan model compared to SHAM operated and carrageenan treated controls. No difference in structural damage was seen between the SHAM operated and naïve animals. Data are given as median (Interquartile Range [IQR]). Differences between groups are analysed using Kruskal-Wallis test followed by Man-Whitney U test to compare two groups with Bonferroni's correction for multiple comparisons. ** P < 0.01, *** P < 0.001 versus naives. + P < 0.05, ++ P < 0.01, +++ P < 0.001 versus meniscal transected and carrageenan injected animals.

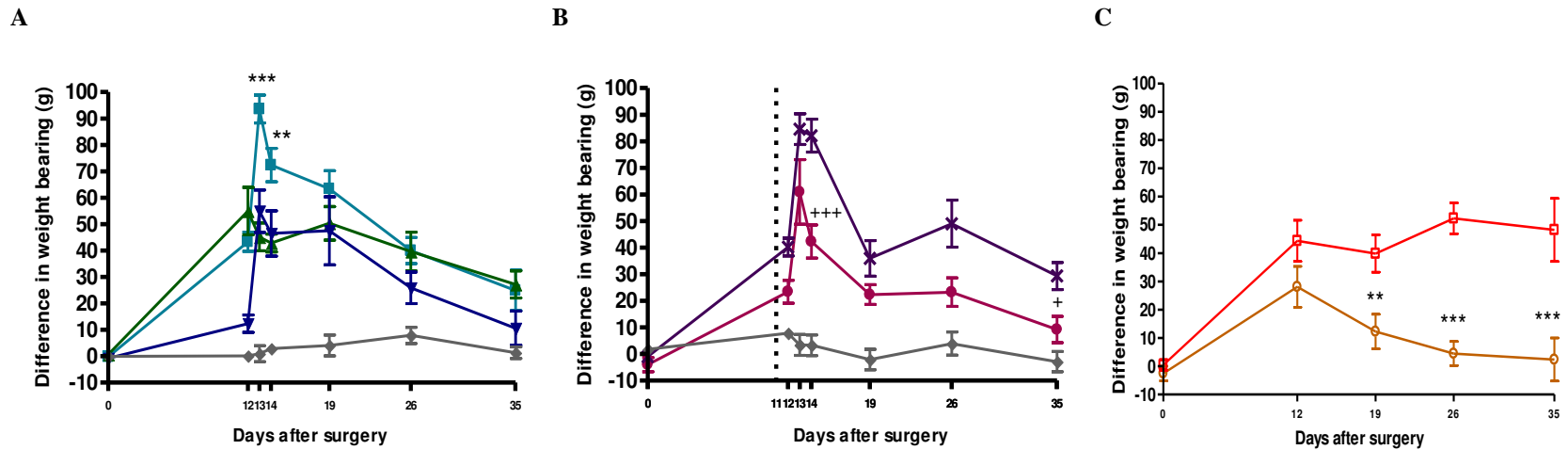


Figure 4.15 Time course of the inhibition of meniscal transection-induced and carrageenan exacerbated knee joint pain behaviour following the administration of anti-angiogenic compound PPI-2458. **A**, pain behaviour in arthritic (■) or SHAM-operated (▼) animals given intra-articular injection of 2% carrageenan into their operated knee joint. **B**, pain behaviour in arthritic animals given carrageenan injection and treated with either PPI-2458 (●) or vehicle control (×). **C**, pain behaviour in arthritic animals (□) and SHAM controls (○). On day 0, animals underwent meniscal transection (□) or SHAM (○) surgery. From day 11 (**vertical dotted line**) to 35, the arthritic animals given a single intra-articular injection of 2% carrageenan (day 12) were orally dosed with either PPI-2458 (● 5mg/kg/every other day) or vehicle control (×). Pain behaviour was measured by a difference in hind paw weight bearing between 0 to 35 days after meniscal transection surgery. Arthritic animals given intra-articular injection of saline controls (▲) showed increased pain behaviour compared to naïve controls (◆) 12 days after meniscal transection surgery and this increase was maintained to day 35. Arthritic animals (□) showed increase pain behaviour compared to SHAM (○) controls 19 days after meniscal transection surgery and this increase was maintained to day 35. Intra-articular injection of 2% carrageenan in either the meniscal transected or SHAM operated animals was followed by a transient increase in pain behaviour. PPI-2458 treated animals showed a reduction in pain behaviour on day 14 which was reduced but not completely inhibited to naive control levels by day 35. Data are shown as arithmetic mean ± S.E.M. Differences between groups (n = 8 animals per group) were analysed using one way analysis of variance (ANOVA). Univariate comparisons were made using Student's T-test with Bonferroni's correction for multiple comparisons. ** P < 0.01, *** P < 0.001 versus either arthritic animals given saline control (▲) or arthritic animals not having intra-articular injection (□). + P < 0.05, +++ P < 0.001 versus combined MNX and 2% carrageenan injected model treated with vehicle control (×).

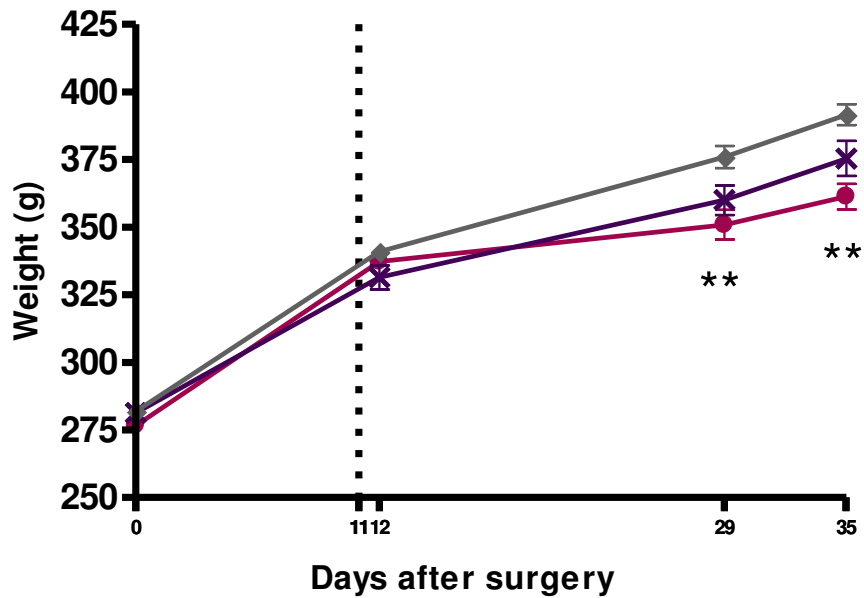


Figure 4.16 Weights of animals following the administration of anti-angiogenic compound PPI-2458. On day 0, animals underwent meniscal transection or SHAM surgery. From day 11 (**vertical dotted line**) to 35, the arthritic animals given a single intra-articular injection of 2% carrageenan (day 12) were orally dosed with either PPI-2458 (● 5mg/kg/every other day) or vehicle control (×). PPI-2458 treated animals gained weight at a slower rate compared to naïve controls (♦). Data are shown as arithmetic mean \pm S.E.M. Differences between groups (n = 8 animals per group) were analysed using one way analysis of variance (ANOVA). Univariate comparisons were made using Student's T-test with Bonferroni's correction for multiple comparisons. ** P < 0.01 versus naïve controls.

4.5 Summary of Results

- The MNX model of OA was associated with osteoarthritic changes in the medial tibial plateaux similar to those seen in human knee OA as well as increased pain behaviour.
- Anti-inflammatory drugs dexamethasone and indomethacin each reduced synovitis, synovial angiogenesis and pain behaviour in the rat MNX model of OA.
- Treatment with dexamethasone reduced total joint damage score by decreasing cartilage damage.
- Anti-angiogenic compound, PPI-2458 reduced synovial and osteochondral angiogenesis, synovitis, joint damage (by reducing osteophyte growth) and pain behaviour in the rat MNX model of OA.
- Exacerbating synovitis in the MNX model of OA enhanced synovial angiogenesis, joint damage and pain behaviour.
- Following treatment with the anti-angiogenic compound PPI-2458, synovitis, joint damage and pain behaviour were all reduced in the rat MNX and 2% carrageenan model.

4.6 Discussion

This study using the rat MNX model of knee OA examines whether synovitis contributes to joint damage and pain through the stimulation of angiogenesis. These data show that exacerbating synovitis leads to more profound structural damage and pain behaviour in the rat MNX model of knee OA. Inhibiting synovitis using either anti-inflammatory or anti-angiogenic compounds can reduce the joint damage and pain behaviour in this model of OA. Angiogenesis may therefore contribute both to inflammation and joint damage, and inhibition of blood vessel growth may be a useful strategy in reducing OA pain.

4.6.1 MNX model of OA

These data reproduce previous evidence that transection of the medial meniscus in the rat results in osteoarthritic changes in the medial tibial plateaux, consisting of fibrillation and eventual loss of cartilage, accompanied by reduced density of chondrocytes and loss of proteoglycan staining, and growth of osteophytes at the joint margins (Janusz et al., 2002; Bove et al., 2006; Mapp et al., 2008; Mapp et al., 2010). The MNX model of OA also demonstrates loss of integrity of the osteochondral junction as channels penetrate the articular cartilage from the subchondral bone spaces, as well as synovitis, indicated by increased synovial macrophage infiltration, and pain behavior, indicated by a reluctance to symmetrically weight bear on the hind limbs.

In each of these respects, this rat model of OA effectively mimics the human condition, and may provide important insights into mechanisms underlying structural changes, pain behavior and responses to pharmacological therapies.

Naïve animals were used as controls rather than SHAM-operated animals because synovitis is an integral component of OA, and it was not the purpose of these studies to separate inflammation due to different sources within this model. SHAM surgery to the knee joint will however induce an inflammatory response but data (pain behaviour) shown in this study and previous published literature has indicated that hindlimb weight-distribution (pain behaviour) and tibiofemoral pathology do not differ between SHAM-operated and naïve animals beyond the first 7 days after surgery (Mapp et al., 2008; Mapp et al., 2010). Hence naïve control group was chosen over SHAM-operated control group and for the purpose of most of these studies it was not felt to be ethically justifiable to have two groups of control animals. In these studies using the MNX model of OA by day 35 a reduction in synovial pathology and hindlimb weight distribution (pain behaviour) compared to naïve control levels was observed, hence it is reasonable to speculate that a reduction to SHAM-operated control group would have been obtained. Similarly, comparing two separate experiments highlighted that following treatment with the angiogenesis inhibitor PPI-2458, meniscal injury-induced hindlimb weight bearing was reduced to SHAM-operated controls by day 19, but not completely abolished to naïve control levels.

4.6.2 Inflammation and pain in OA

OA manifests as joint pain with progressive loss of joint function. A great deal is known about symptoms of the disease, but the pathophysiology underlying those symptoms is less well understood. While the pain of OA is felt to originate from the joint, it is now widely recognized to be of multifactorial origin moderated by both the peripheral and central nervous system (Bove et al., 2006). In the absence of disease modifying drugs to treat OA, pharmacological interventions often target central pain mechanisms in order to relieve symptoms (McColl 2001). Current treatments are often limited by potential adverse events, and a better understanding of how joint pathology leads to pain is required to develop new therapies.

Synovitis is now increasingly recognised as contributing to pain in OA. Intra-articular corticosteroids and topical and oral NSAIDs are established for symptomatic relief of knee OA. The TNF α blocking antibody adalimumab recently has been found to improve pain, whilst reducing synovitis and bone marrow oedema on magnetic resonance images (Grunke et al., 2006). The data presented in this thesis confirms that increasing synovitis enhances structural damage and pain in the rat MNX model of knee OA which can be inhibited by anti-inflammatory treatments.

4.6.3 Angiogenesis and inflammation in OA

Angiogenesis is a feature of OA in rats as well as in humans, both in the synovium and at the osteochondral junction (Walsh et al., 2007; Mapp et al., 2008). Synovial angiogenesis is associated with synovitis. New blood vessel growth may be a consequence of synovitis through the expression of angiogenic factors by macrophages, and also may exacerbate inflammation by facilitating plasma extravasation and cellular influx (Walsh 1999; Bonnet et al., 2005). Synovial and osteochondral angiogenesis are also associated with OA structural changes, and may contribute to those changes either directly or by facilitating inflammation (Haywood et al., 2003). Angiogenesis is followed by innervation of newly formed blood vessels by fine unmyelinated sensory nerves, and may therefore directly contribute to pain in OA (Haywood et al., 2003). These data show that inhibition of angiogenesis by administration of PPI-2454 is associated with reduced synovitis, structural damage and pain behavior in the rat MNX model of knee OA. Angiogenesis inhibition therefore offers a novel therapeutic strategy in OA.

The reduction in synovitis that was observed after targeting angiogenesis using PPI-2458 was similar in extent to that observed after systemic treatment with indomethacin or dexamethasone. PPI-2458 prevents persistence of synovitis after combined intra-articular injection of carrageenan and fibroblast growth factor-2 as well as 2% carrageenan injection in rats (Chapter 3). Synovitis persists throughout the development of knee OA after meniscal injury in rats (Mapp et al., 2008), and these data demonstrate that the anti-inflammatory effects of PPI-2458 commence 12 days after meniscal injury indicating that angiogenesis inhibition can reduce inflammation even after synovitis has become established. PPI-2458 has also inhibited synovitis in collagen and in PGPS-induced arthritis in mice and rats (Bainbridge et al., 2007;

Lazarus et al., 2008), indicating that the anti-inflammatory effects of angiogenesis inhibition may be observed in synovitis induced by a wide variety of agents.

It is difficult to completely exclude the possibility that PPI-2458 might be having other effects distinct from its anti-angiogenic properties. Studies have shown PPI-2458 to be a potent inhibitor of the in-vitro proliferation of activated human umbilical vein endothelial cells (HUVECs) and human fibroblast like synoviocytes (FLS) from RA patients (Bernier et al., 2004; Bernier et al., 2005). Moreover, in a rat model of PG-PS-induced arthritis, the in-vivo protective effect of PPI-2458 against bone destruction leading to structural preservation of affected arthritic joints was attributed to the ability of PPI-2458 to inhibit osteoclast mediated bone resorption in-vitro (Hannig et al., 2007; Lazarus et al., 2008). PPI-2458 was selected as an anti-angiogenic agent because it is believed not to have any direct inhibitory effects on inflammation (Brahn et al., 2009). Data shown in Chapter 3 supports this theory because PPI-2458 inhibited angiogenesis prior to the inhibition of inflammation in two different models of chronic inflammation. These findings further add to the body of evidence which supports PPI-2458 as a selective angiogenesis inhibitor. However it should be noted that since angiogenesis is closely associated with inflammation it would be difficult, if not impossible, to tease out this relationship.

4.6.4 Structural effects of anti-inflammatory and anti-angiogenic treatments

Synovitis is associated with greater chondropathy in human OA (Walsh et al., 2009), and predicts progression of joint damage in longitudinal studies (Ledingham et al., 1995). Inhibition of synovitis is therefore an attractive target for disease modification in OA, although coincidental and detrimental effects of current anti-inflammatory agents on chondrocyte function (Annefeld et al., 1990; Bove et al., 2003) may limit their efficacy as disease modifying agents. In this study, treatment with either dexamethasone or PPI-2458 inhibited total joint damage score. Although dexamethasone predominantly affected chondropathy in this model of OA, angiogenesis inhibition reduced osteophyte size, suggesting that the structural effects of angiogenesis inhibition are not entirely mediated by its anti-inflammatory effects. VEGF blockade has also been found to reduce new bone formation around arthritic joints, an effect that may be partly mediated by inhibition of endochondral ossification (Miotla et al., 2000).

Loss of integrity of the osteochondral junction results, in part, from the extension of channels from subchondral bone spaces into the articular cartilage, both in human and rodent OA (Walsh et al., 2007; Mapp et al., 2008). These channels are typically vascularised, leading to the term 'vascular channels'. Vascular channel formation and pain behavior in the MNX model of knee OA is reduced by matrix metalloproteinase inhibition (Mapp et al., 2010). These data showing that PPI-2458 inhibited vascularisation of channels at the OCJ is consistent with its anti-angiogenic activity. However, the significant increase in total channel numbers in animals having meniscal transection surgery and treated with PPI-2458 compared with non-arthritic control animals indicates that angiogenesis is not a prerequisite

for channel formation. Reductions in pain and structural damage observed in the osteoarthritic animals following treatment with PPI-2458 may be partly due to inhibition of osteophyte growth and angiogenesis at the osteochondral junction, as well as inhibition of synovitis.

This study suffers from limitations that are common to investigations of complex biological processes in intact animals. Although PPI-2458 is well characterized as a specific inhibitor of angiogenesis, the exact consequences of angiogenesis inhibition responsible for its analgesic activity can not be pin-pointed. Similarly indomethacin and dexamethasone may have effects additional to inhibiting inflammation, including direct anti-angiogenic actions.

Animals treated with the angiogenesis inhibitor PPI-2458, failed to gain weight at the same rate as animals in other groups (vehical-treated and naïve animals), this reduction may well be due to the inhibition of angiogenesis at the growth plate, hence smaller animals. In keeping with previous studies using dexamethasone (Roussel et al., 2003; Caparroz-Assef et al., 2007), corticosteroid-treated animals failed to gain weight at the same rate as animals in other groups. This reduction in growth may be due to negative effects on glucose metabolism, although growth curves paralleled those of the other treatment groups by day 35, and non-fasting blood glucose levels did not differ significantly between the groups at the time of sacrifice. Another adverse effect associated with steroid use is myopathy, it is possible that this could be the reason for the slow weight gain of dexamethasone treated animals. Despite these limitations, however, the data presented in this thesis supports the view that anti-inflammatory and anti-angiogenic strategies may have potential not only to relieve symptoms, but also to modify structural progression in OA.

In conclusion, these findings indicate that synovitis and total joint damage are closely associated with pain behaviour in OA and this may, in part, be explained by angiogenesis in the synovium and at the osteochondral junction. Targeting angiogenesis could therefore prove useful in reducing pain and structural damage in OA, either alone or in combination with other drugs.

5 VASCULARISATION AND INNERVATION OF HUMAN MENISCUS

5.1 Introduction

Osteoarthritis (OA), one of the commonest joint diseases (Arden et al., 2006), is a major source of pain and disability in the ageing population (van Saase et al., 1989; Peat et al., 2001; Dixon et al., 2004). OA is associated with loss of articular cartilage (chondropathy), sclerosis and osteophyte formation in the subchondral bone. Chondropathy alone does not equate to OA, but emerging research shows chondropathy scores are representative of the presence and severity of OA (Walsh et al., 2009).

Pain is the predominant symptom of OA, but little is certain about the mechanisms by which this pain arises. Pain has been suggested to originate from articular cartilage (Suri et al., 2007), periosteum (Gronblad et al., 1984), subchondral bone (Reimann et al., 1977), synovium (Mapp 1995), ligaments, muscle and joint capsule (Hukkanen et al., 1992; Hirasawa et al., 2000; Lanzetta et al., 2004; Suri et al., 2007).

Angiogenesis may contribute to pain in OA by enabling growth of new unmyelinated sensory nerves (Bonnet et al., 2005; Ashraf et al., 2008). Angiogenesis and sensory nerves are seen in the synovium and at the osteochondral junction in OA (Walsh et al., 2007) penetrating into non-calcified articular cartilage and osteophytes (Suri et al., 2007). These perivascular, unmyelinated, nerve fibres containing substance-P and CGRP are implicated in mediating sustained burning pain described by patients with OA (Kidd et al., 1992; Dieppe et al., 2005).

The menisci are crescentic wedges of fibrocartilage, located between the femoral condyles and the tibial plateaux (Arnoczky et al., 1982). They increase joint congruity, dispersal of weight, proprioception, and shock absorption, and reduce friction (Seedhom et al., 1974; Messner et al., 1998).

Meniscal tissue consists of cells suspended in an ECM of collagen (mainly type 1), glycoproteins, proteoglycans and elastin (McDevitt et al., 1990). Disruption of collagen bundles, proteoglycan loss, perimeniscal synovitis and calcification not limited to the outer, peripheral portion of the meniscus (Burman et al., 1933; Herwig et al., 1984; Kapadia et al., 2000; Grainger et al., 2007; Sun et al., 2010) are described as meniscal degeneration (Bennett et al., 2002; Englund 2009). A strong association between meniscal degeneration, articular cartilage damage and joint space narrowing has been reported (Gale et al., 1999; Hunter et al., 2006). As well as being a consequence of OA, meniscal changes may contribute to OA structural damage (Bhattacharyya et al., 2003; Hunter et al., 2006; Englund 2009).

Meniscectomy in OA can lead to a reduction in pain (Jackson et al., 1982; Bin et al., 2008), although mechanisms by which this occurs are yet to be elucidated. Myelinated and unmyelinated nerve fibres, and

free nerve endings have been localised in the meniscus (Wilson et al., 1969; Day et al., 1985; Zimny et al., 1988; Assimakopoulos et al., 1992), with perivascular nerves containing substance P (Mine et al., 2000). Blood vessels and nerves penetrate the outer portion of the normal human meniscus, reaching as far as its middle third portion, with the innermost portion remaining avascular and aneural (Wilson et al., 1969; Day et al., 1985). Large variations have been reported in the degree of vascular penetration and innervation between individuals, but it is unclear whether disease contributes to this heterogeneity (Arnoczky et al., 1982). Two studies comparing human menisci with extensive degeneration to normal menisci found no change in vascularity and innervation (Kennedy et al., 1982; Danzig et al., 1983) whilst another indicated increased penetration of blood vessels into the inner portion of the osteoarthritic meniscus (Burman et al., 1933). Most previous studies of human menisci have used small numbers of surgical samples, and the heterogeneity of human meniscal tissue and high prevalence of OA may have compromised their ability to associate changes with disease.

Elucidation of the mechanisms involved in the generation of pain is needed to enable the development of more effective therapeutic and surgical strategies. Therefore examining the role that meniscus might have in the genesis of pain in OA through angiogenesis and nerve growth is vital in increasing our understanding of the pathophysiology of OA. Furthermore, the vasculature plays important roles in tissue repair, and a better understanding of the vascular and neural anatomy of both healthy and diseased meniscus may help develop new treatments for meniscal injuries and OA. It was therefore hypothesised that vascularisation into the meniscus may be increased in OA and could be associated with increased sensory nerve growth.

5.2 Aims

1. To compare the meniscal structure of osteoarthritic and control menisci.
2. To compare the vascular penetration between osteoarthritic and control menisci.
3. To compare the sensory nerve growth between osteoarthritic and control menisci.
4. To determine whether vascular penetration is associated with nerve growth in human menisci.

5.3 Methods

General methodology is given in Chapter 2. Patient and sample selection criteria is stated in section 2.9, whilst demographic details of patients are listed in Table 5. Detailed steps of the image analysis and quantification procedures are given in section 2.8.

Patient/Sample Characteristics	VASCULARITY			NERVE GROWTH		
	High Chondropathy (n = 20)	Low Chondropathy (n = 20)	P Value	High Chondropathy (n = 8)	Low Chondropathy (n = 8)	P Value
Number Male (%)	14 (70%)	11 (55%)	0.32	5 (63%)	3 (38%)	0.32
Age (years)	69 (65 to 81)	41 (34 to 46)	<0.0001	66 (65 to 72)	46 (33 to 55)	0.005
Chondropathy Score (Possible range 0 to 400)	203 (198 to 245)	24 (15 to 27)	<0.0001	199 (181 to 240)	33 (19 to 46)	0.0002
Medications (at time of death)	3 patients taking paracetamol 1 patient taking long term steroids (not for rheumatological reasons) 9 patients taking opioids	2 patients taking paracetamol none taking long term steroids 1 patient taking opioids		2 patients taking paracetamol 2 patients taking long term steroids (not for rheumatological reasons) 1 patient taking opioids	5 patients taking paracetamol 1 patient taking long term steroids (not for rheumatological reasons) 1 patient taking opioids	

Table 5 Patient details and chondropathy scores (possible range 0 to 400) for samples used in study of meniscal vascularity and nerve growth. Data for age and chondropathy scores are medians (IQR). Comparison between groups are made using Man Whitney-U Test. $P < 0.05$ indicates significant difference between high and low chondropathy groups.

5.4 Results

5.4.1 Meniscal Structure

Inner and outer regions of the meniscus were distinguished by differences in matrix structure and proteoglycan staining. The inner region of the meniscus displayed large collagen bundles with a regular arrangement whilst in the outer region fibres were arranged in smaller bundles with a more irregular orientation (Figure 5.1). The junction separating these two regions we refer to as the fibrocartilage junction (Figure 5.1). Synovium, localised to the surface of the outer region of the meniscus, extended to approximately the fibrocartilage junction in menisci from the low chondropathy group (Figure 5.1 A). In menisci from the high chondropathy group, synovium appeared thicker and extended over part of the inner region (Figure 5.1 D). Menisci from high chondropathy group had a more fragmented appearance than menisci from low chondropathy group, displaying more clefts in the matrix of the outer region (Figure 5.1 F), whereas menisci from low chondropathy group displayed homogeneous eosinophilic matrix (Figure 5.1 C). Proteoglycan staining was present in the inner, but not in the outer region of the menisci from both the low and high chondropathy groups. No difference was seen in the intensity of proteoglycan staining between groups. Blood vessels of varying sizes were observed in the outer region of the meniscus, ranging from arteries with a continuous layer of smooth muscle to capillaries with walls of single cell thickness (Figure 5.1 and 5.2).

The extent of synovial ingrowth towards the tip of the meniscus was greater in the high chondropathy group [0.12 mm (IQR 0.04 to 0.20)] compared to the synovia from the low chondropathy group [0.00 mm (IQR 0.00 to 0.00), $P = 0.003$] (Figure 5.1).

Grading of collagen bundle appearance indicated greater degeneration in the outer region of menisci from high chondropathy cases [Grade 1 (IQR 0 to 1)] than from low chondropathy cases [Grade 0 (IQR 0 to 0), $P = 0.048$]. Greater collagen bundle irregularity was associated with higher chondropathy ($r = 0.43$, $P = 0.005$). No significant difference was demonstrated in collagen bundle appearance in the inner region between high [Grade 1 (IQR 0 to 1)] and low chondropathy groups [Grade 0 (IQR 0 to 1), $P = 0.35$] (Figure 5.1 B and E).

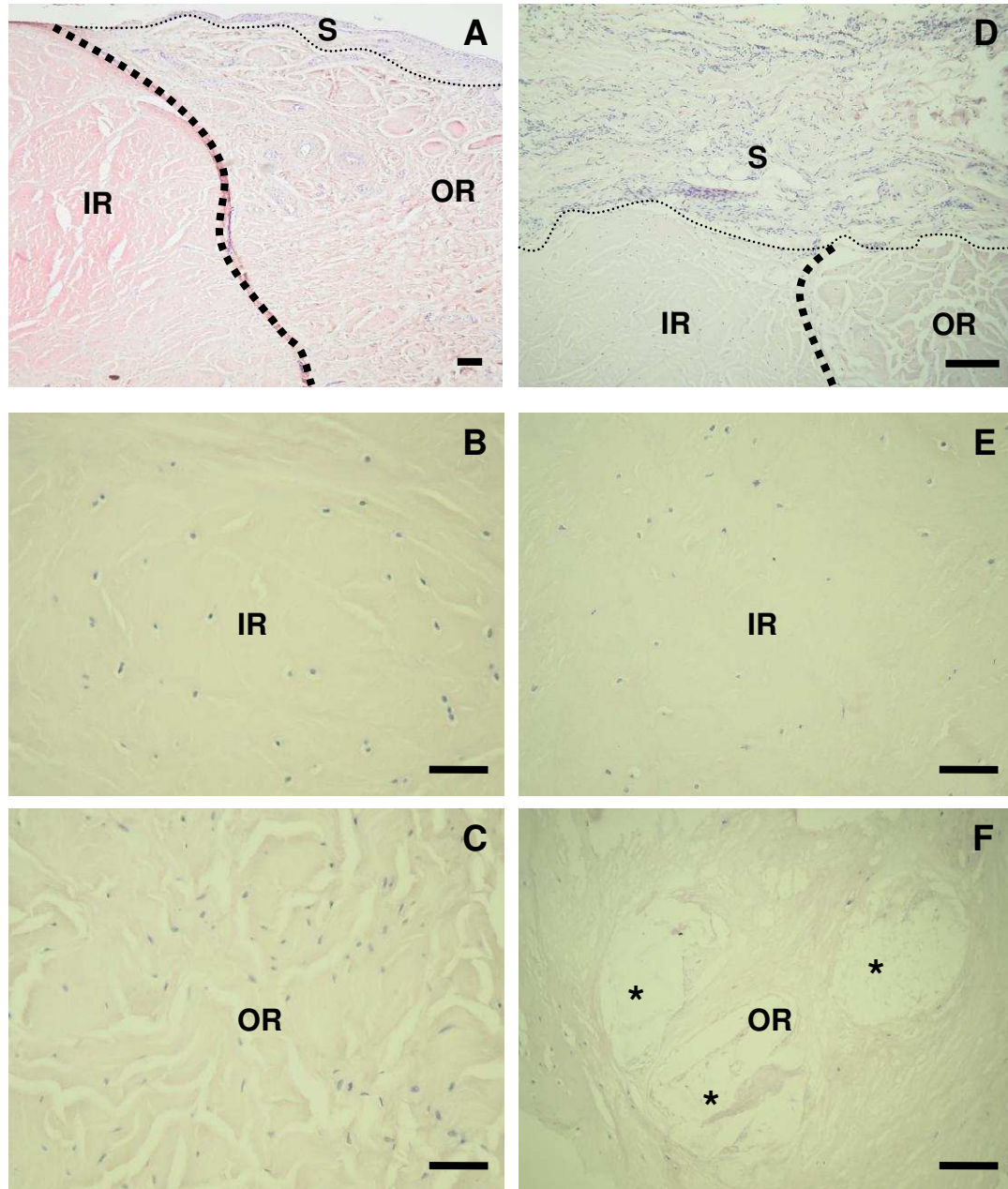


Figure 5.1 Structure of human menisci. Haematoxylin and eosin staining of menisci from the low (A-C) and high (D-F) chondropathy groups. In menisci from the low chondropathy group, a distinct fibrocartilage junction [FCJ (large dotted line)] (A) separated the inner (IR), characterized by regular matrix fibre bundles (B), from the outer (OR) region which displayed irregular fibre bundles (C). A thin synovium (S) was adherent to the OR but did not extend over the IR (A). In menisci from the high chondropathy group, a thick layer of synovium (S) extended over the intact IR (D, E), with the OR having progressive disorientation of fibre bundles bordering hypocellular regions, having clefts (astrix) (F). Transmitted light images were taken using $\times 4$ (A) and $\times 20$ (B-F) objective lenses of a single representative section from $n = 20$ menisci per group. Scale bar = $100\mu\text{m}$.

5.4.2 Meniscal Vascularity

Repeatability for synovial vascularity density was 1.9 for 95% of pairs of observations (i.e. the difference between two measurements for the same case is expected to be <1.9% for 95% of pairs) (Bland et al., 1996). Vascular densities were greater in the high than in the low chondropathy group both in the synovium [3.8% (IQR 2.6 to 5.2), 2.0% (IQR 1.4 to 2.9), $P = 0.002$] and at the fibrocartilage junction [2.3% (IQR 1.7 to 3.1), 1.1% (IQR 0.8 to 1.9), $P=0.003$]. A degree of vessel penetration into the inner region along the midline of the menisci was observed in both groups (Figure 5.2).

The outer meniscal region was more vascular than the inner region, with an abrupt drop in vascularity in the field 4 along the midline from the meniscal tip, which corresponded to the region of the fibrocartilage junction, separating the inner from the outer region of the menisci (Figure 5.2 and 5.3). Vascular densities in field 4 (the fourth consecutive microscopic field from the meniscal tip) were greater in the high than in the low chondropathy group [1.0% (IQR 0.3 to 1.5), 0.3% (IQR 0.0 to 0.8), $P = 0.015$] indicating a greater degree of vascular penetration in the high chondropathy group. Meniscal vascularity at the fibrocartilage junction, in field 4, or in the synovium were not associated with collagen bundle appearance in the outer region ($r = 0.16$, $P = 0.33$, $r = 0.08$, $P = 0.61$, and $r = 0.21$, $P = 0.20$ respectively). Synovial vascular density was associated with meniscal vascularity at the fibrocartilage junction ($r = 0.46$, $P = 0.003$), and in field 4 ($r = 0.46$, $P = 0.003$).

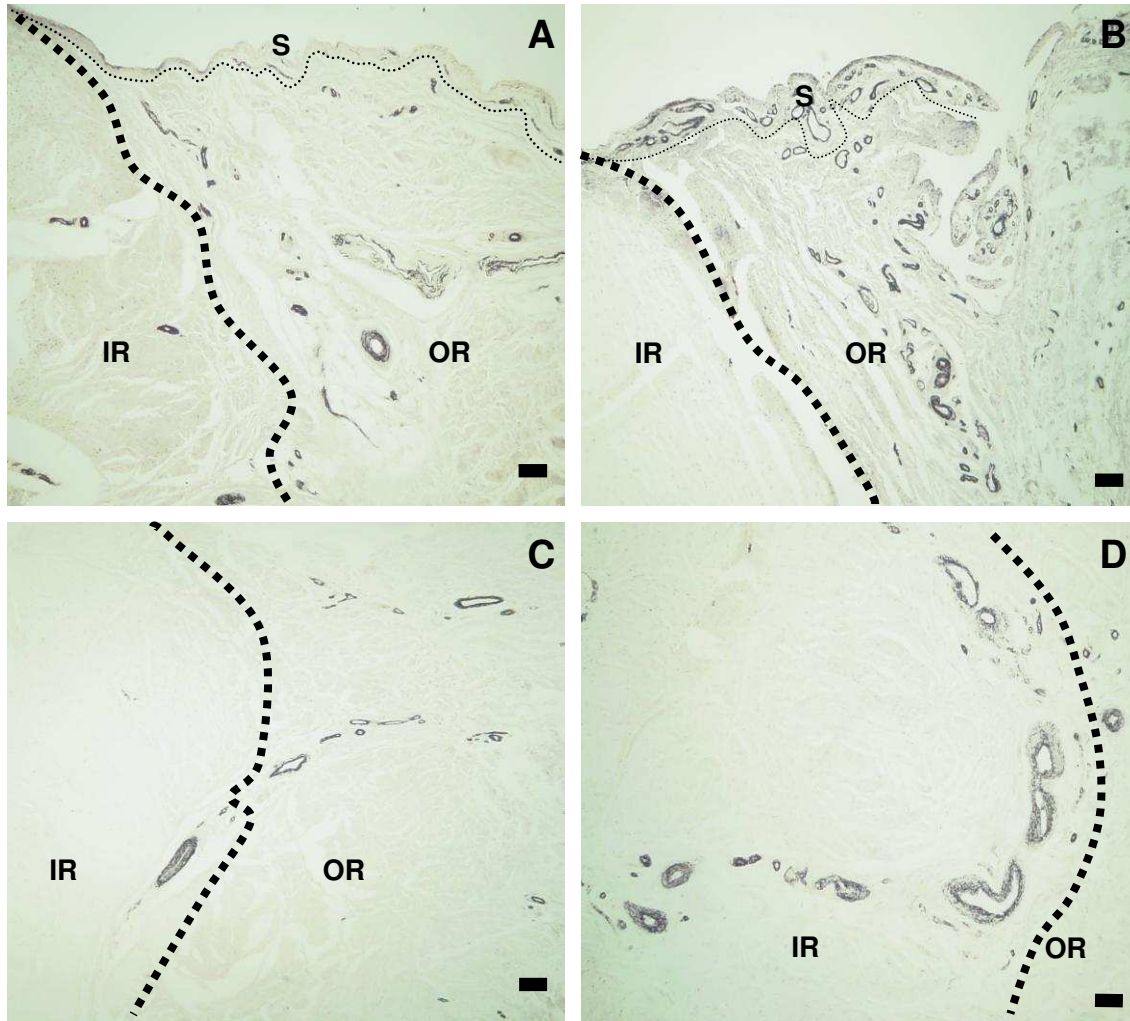


Figure 5.2 Vascularity of human menisci. Alpha-actin positive vasculature in menisci from the low (A and C) and high (B and D) chondropathy groups. In the low chondropathy group, low densities of vessels were found in the outer region (OR), both in the synovium (s) and along the fibrocartilage junction (large dotted line) (A), with vascular penetration into the inner region (IR) along the midline (C). In menisci from high chondropathy group, high densities of vessels were observed in the OR, both in the synovium and along the fibrocartilage junction (B) with increased penetration into the IR along the midline (D). Transmitted light images were taken using $\times 4$ objective lens of a single representative section from $n = 20$ menisci per group. Scale bar = $100\mu\text{m}$

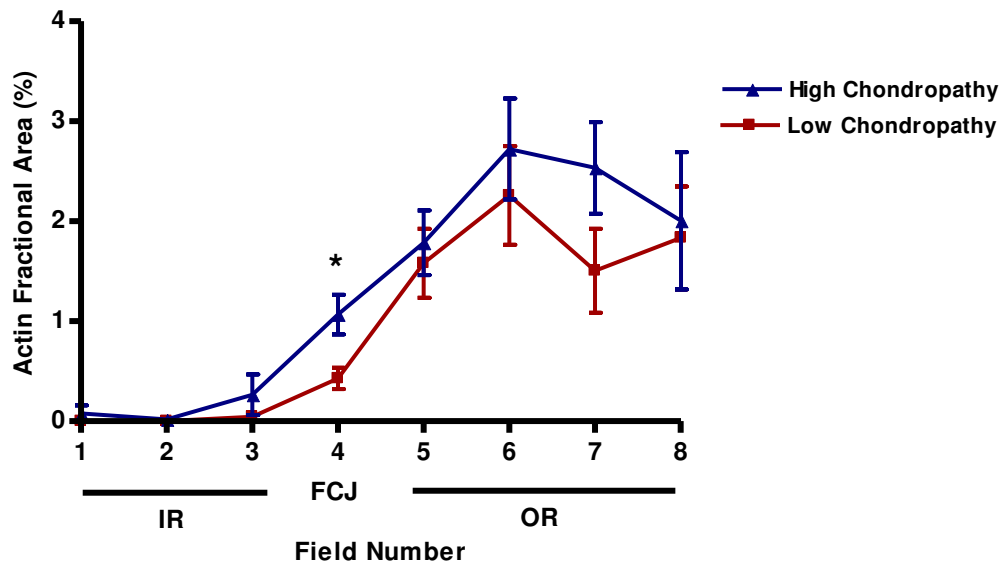


Figure 5.3 Depth of vascular penetration along the midline of menisci. The highest densities of alpha-actin positive vessels were observed in the outer region (OR) of the menisci, where there was no significant difference in vascular density between the low and high chondropathy groups. Fewer vessels were observed in the inner region (IR) of both groups. Menisci from the high chondropathy group were characterised by increased vascular density in the 4th field of view, which corresponded to the region of the fibrocartilage junction (FCJ), indicating increased penetration of vessels from the outer into the inner meniscal region. Each field was 1.4mm in length. Graph shows arithmetic mean \pm S.E.M of n = 20 menisci per group. Comparison between groups are made using Man Whitney-U Test. * P < 0.05

5.4.3 Sensory Innervation

CGRP-immunoreactive nerve profiles were identified alongside blood vessels (small arterioles) and sometimes at a distance from them (Figure 5.4). These vessels and nerves were commonly observed in the outer region near the fibrocartilage junction of the meniscus. The inner region of the meniscus was mostly aneural. Menisci from high chondropathy group had greater number of perivascular sensory nerve profiles in the outer region [144 nerve profiles/mm² (IQR 134 to 189)] compared to menisci from the low chondropathy group [119 nerve profiles/mm² (IQR 104 to 144), P = 0.049]. Nerve profiles in the outer region of the menisci were associated with chondropathy (r = 0.59, P = 0.015), but not with collagen bundle appearance (r = 0.10, P = 0.97).

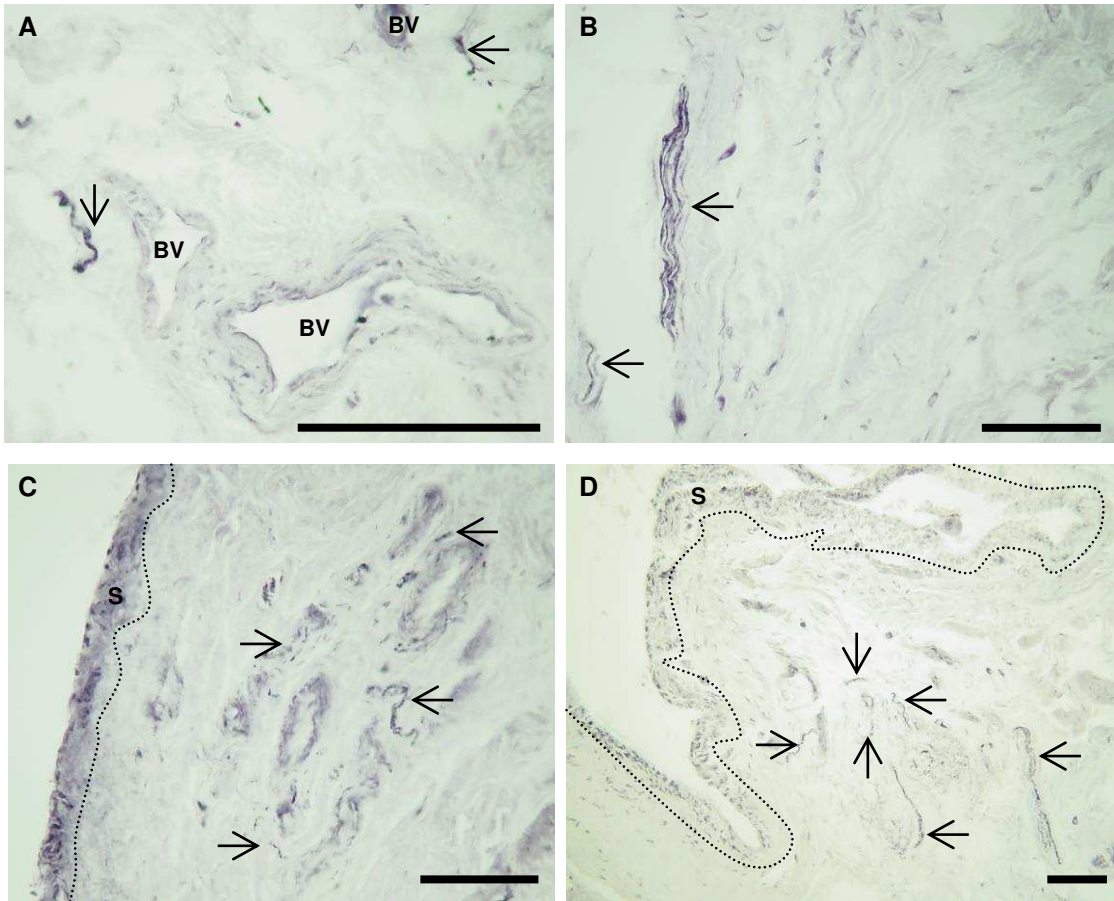


Figure 5.4 Calcitonin gene-related peptide (CGRP)-immunoreactive (sensory) nerve profiles in the outer region of human menisci. **A:** Nerve profiles (arrows) associated with small arterioles (BV). **B:** Apparently free nerve profiles not associated with small arterioles. **C:** Meniscus from low chondropathy group having few nerve profiles associated with small arterioles. **D:** Meniscus from high chondropathy group having several nerve profiles associated with small arterioles. Sample of menisci from high (A, B and D) or low (C) chondropathy cases. Dotted line indicates the boundary of the synovium (S). Transmitted light images were taken using $\times 10$ (D), $\times 20$ (B and C) and $\times 40$ (A) objective lenses of a single representative section from $n = 20$ menisci per group. All scale bars = $100 \mu\text{m}$.

5.5 Summary of Results

- Menisci from knees with high chondropathy had a greater degree of collagen bundle degeneration in the outer region compared with menisci from knees with low chondropathy.
- In menisci from the high chondropathy group, synovium appeared thicker and synovial ingrowth towards the tip of the menisci was greater compared with menisci from the low chondropathy group.
- Outer regions of the menisci from knees with high chondropathy were more vascular than the inner regions with an abrupt drop in vascularity at the fibrocartilage junction separating the outer from the inner region of the menisci.
- Increased vascular densities were observed in menisci from the high compared with low chondropathy group both in the synovium and at the fibrocartilage junction.
- A greater density of perivascular sensory nerve profiles in the outer region of menisci from knees with high chondropathy was seen compared to those with low chondropathy.

5.6 Discussion

This study examines whether vascularisation into the meniscus increases in OA and if it is associated with increased sensory nerve growth. These data show that menisci from knees with high tibiofemoral chondropathy have increased blood vessel densities near the fibrocartilage junction, which are associated with a greater number of perivascular sensory nerves. Angiogenesis and increased meniscal innervation are therefore possible mechanisms contributing to knee pain in tibiofemoral OA.

This study confirms an association between disorganisation of collagenous matrix structure and chondropathy in human knees, and demonstrates increased penetration of blood vessels and nerves towards the meniscal tip with high chondropathy scores. Vascularisation of normally avascular tissues has also been demonstrated in articular cartilage in OA and inner regions of the annulus fibrosus of the intervertebral disc in back pain (Kauppila 1995). Meniscal angiogenesis may be a homeostatic response to minimise meniscal damage in OA. Vascularisation changes tissue biomechanics and may predispose to further damage. Interventional studies would be required to determine whether meniscal angiogenesis protects against or contributes to joint damage in OA.

These findings show that increased angiogenesis previously observed in OA synovium (Bonnet et al., 2005; Ashraf et al., 2008) extends to include synovium attached to menisci. Increased synovial vascularity was associated with vascularisation at the fibrocartilage junction of the meniscus, suggesting that angiogenesis in these different joint compartments may be regulated by common factors. Synovial angiogenesis is associated with synovitis in OA, and may be driven by increased expression of angiogenic factors such as VEGF by cells within the inflamed synovium (Bonnet et al., 2005; Ashraf et al., 2008). Furthermore, the meniscus is closely apposed to articular cartilage in vivo, and VEGF is also upregulated by superficial chondrocytes in OA (Walsh DA 2010). The stimuli to meniscal blood vessel growth deserve further study, but may originate, as well as from cells within the meniscus itself, from adjacent structures such as the synovium and articular cartilage.

These data demonstrate that CGRP positive sensory nerve profiles are present in the outer region of menisci, and most of these nerves are associated with blood vessels. CGRP is co-localised with substance P in unmyelinated sensory nerve fibres, and this work therefore extends previous findings that perivascular nerves containing substance P are located in the peripheral portion of torn menisci (Mine et al., 2000). This study shows an increase in sensory innervation in the outer region of menisci from knees with high chondropathy scores. Nerve growth in menisci may contribute to pain in OA both through an increased density of nociceptive fibres, and through increased sensitivity that occurs during nerve growth (Ma et al., 1997). Recent controlled trials of nerve growth factor blockade have demonstrated its ability to inhibit OA knee pain (Cattaneo 2010), although the rapid onset of its analgesic effect may suggest an action on sensitisation rather than on nerve growth. CGRP-immunoreactive nerves were localised adjacent to blood

vessels within the meniscus, and sensory nerve growth follows blood vessel growth in a variety of tissues (Aoki et al., 1994; Walsh et al., 1996). Angiogenesis inhibition may therefore also have analgesic potential by reducing aberrant innervation in the osteoarthritic knee (Walsh et al., 2001). Substance P and CGRP released from sensory nerve terminals can amplify the inflammatory response (Kidd et al., 1990; Garrett et al., 1992) as well as initiating angiogenesis, with the potential to contribute to both pain and structural damage (Seegers et al., 2003). It remains possible that the increased sensory innervation in menisci from knees with chondropathy contributes to, as well as being a consequence of meniscal angiogenesis.

Macroscopic appearance of chondropathy is used as an indicator of tibiofemoral OA. Chondropathy scores for high chondropathy group are similar to those previously observed at total joint replacement surgery for knee OA [257 (IQR 228-283)] (Walsh et al., 2009), all of whom fulfilled the American College of Rheumatology revised criteria for OA [60]. Synovial and meniscal angiogenesis do not appear to be restricted to knees undergoing arthroplasty. These findings of meniscal pathology are consistent with MRI studies showing meniscal abnormalities associated with symptomatic radiographic OA compared to asymptomatic and non-radiographic groups (Fukuta et al., 2002; Fukuta et al., 2009). Chondropathy alone, however, is insufficient to diagnose knee OA (Altman et al., 1986) and further studies would be required to determine whether the observed meniscal changes are associated with other features of OA. During selection of cases for this study, 3 were excluded from the high chondropathy group due to non-availability of meniscal tissue. Menisci can be completely disrupted in severe OA and the current findings may only be relevant to cases where menisci remain intact. The prevalence and severity of OA increases with age, and it was not possible in this study to exclude the possibility that differences in vascularity and innervation between high and low chondropathy groups may have been age- rather than disease-related. It is not known whether patients from whom the menisci were obtained suffered from knee pain, and the proposal that meniscal pathology may be associated with knee pain remains speculative. Despite these limitations, however, the use of post mortem tissues in this study permitted the analysis of two discrete patient groups, with menisci harvested and processed and chondropathy assessed by identical methodologies, avoiding differences between surgical and control specimens that can often limit interpretation of pathological studies.

In conclusion, these data show an increased vascularity and innervation of menisci from knees displaying high chondropathy scores. Neovascularisation and innervation may contribute to both structural change and pain in OA. Inhibition of angiogenesis and/or nerve growth may each offer the potential to prevent meniscal innervation, and interventional studies are needed to further elucidate the contribution of and the links between angiogenesis, nerve growth and pain.

6 OVERALL SUMMARY OF RESULTS

Using animal models of synovitis, these data show that angiogenesis may be a key factor in the transition from acute to persistent inflammation.

In the 2% carrageenan model of persistent synovitis, a short course of PPI-2458 (6 doses) administered during the initial phase of inflammation, reduced synovitis by day 24, but did not completely abolish it. However synovial angiogenesis (EC proliferation and vascular density) was completely abolished at this time point, suggesting that chronic inflammation is in part mediated by angiogenesis. Pain behaviour in this model was also reduced by day 7 following administration of PPI-2458. At this time point, synovial angiogenesis was completely abolished but synovitis persisted, suggesting that angiogenesis, inflammation and pain are indeed inter-connected processes. Inhibiting angiogenesis therefore has the potential to reduce pain.

In order to confirm that angiogenesis may indeed be an integral component of persistent synovitis it was shown that at a dose of 0.03%, carrageenan alone did not induce angiogenesis. Carrageenan injection alone was associated with a transient synovitis that had resolved at 14 days. When angiogenesis was stimulated with 6 pmoles FGF-2 at the time that synovitis was induced by intra-articular injection of carrageenan, the synovitis persisted for at least 4 weeks. Inhibition of this effect of FGF-2 by PPI-2458 suggests that this chronicity is mediated by angiogenesis rather than other actions of FGF-2.

This relationship of angiogenesis and inflammation was further studied in the rat MNX model of knee OA. Data gathered using the rat MNX model of knee OA highlighted that exacerbating synovitis leads to more profound structural damage and pain behaviour and this may partly be due to the stimulation of angiogenesis in the synovium and at the osteochondral junction. Inhibiting synovitis using either anti-inflammatory or anti-angiogenic compounds reduced the joint damage and pain behaviour in this model of OA. Angiogenesis may therefore contribute both to inflammation and joint damage, and inhibition of blood vessel growth may be a useful strategy in reducing OA pain.

Extending these in-vivo findings to human meniscal tissue showed that tibiofemoral chondropathy is associated with altered matrix structure, increased vascular penetration and increased sensory nerve densities in the medial meniscus. Moreover data from this study showed that increased angiogenesis previously observed in OA synovium extends to include synovium attached to the menisci. Hence, angiogenesis and associated sensory nerves in the meniscus may therefore contribute to pain in knee OA and inhibition of angiogenesis and/or nerve growth may each offer the potential to prevent meniscal innervation and hence pain experienced during OA. Interventional studies are however needed to further elucidate the contribution of and the links between angiogenesis, nerve growth and pain.

Collectively these findings support the hypothesis that inflammation and angiogenesis are indeed co-dependent processes, exacerbating and mediating structural damage and pain in OA. Angiogenesis inhibition has the potential to reduce synovitis, joint damage and pain in OA.

7 CONCLUSIONS AND FUTURE DIRECTIONS

Arthritic conditions on the whole are a significant health problem worldwide placing an enormous burden on global economy (Zhang et al., 2010). OA, undoubtedly by far the most common form of arthritis affecting synovial joints is a heterogeneous condition of unknown aetiology (Driban et al., 2010). OA is one of the leading causes of chronic pain and disability not only in the elderly but also in individuals of working age (Dieppe et al., 2005; Issa et al., 2006). Current treatment recommendations for OA focus on symptomatic relief as pharmacological interventions that slow, arrest or reverse disease progression are not available (Fitzcharles et al., 2010; Zhang et al., 2010), and therefore in many affected individuals OA often leads to total joint replacement surgery (Altman 2010; Feeley et al., 2010). Thus a more in depth knowledge is required to further understand the pathogenesis of disease initiation and progression in OA in order to fulfil the goal of disease modification.

OA is characterised pathologically by a progressive loss of articular cartilage accompanied by new bone formation at the joint margins (osteophytosis), changes in subchondral bone and synovitis (Goldring et al., 2007). Angiogenesis, the growth of new blood vessels from pre-existing ones, is thought to contribute to each of these pathological features of OA. Although the hallmark of OA is the progressive loss of articular cartilage and joint space narrowing (Goldring et al., 2010), abnormalities are also detected in the subchondral bone and the synovium even in very early disease (Martel-Pelletier et al., 2010). Hence an important emerging theme in OA is a broadening of focus from the popular belief that OA is primarily a disease of the cartilage to the one of involving the “whole joint”.

Pain, the predominant symptom of OA can originate from several sources (Dieppe et al., 2005). The mechanisms underlying OA pain are not particularly well understood. Inflammation is implicated in sensitising the sensory nerves growing alongside blood vessels in various compartments of the joints and these sensitised nerves are thought to contribute to neurogenic inflammation, initiating new vessel growth. Angiogenesis may therefore contribute both to the symptoms and pathology of OA and further analysis of its role seems vital in leading to discovering more effective therapies.

In this thesis evidence is presented that angiogenesis contributes to inflammation, structural damage and pain in OA, and targeting angiogenesis reduces these changes. These findings support the hypothesis that inflammation and angiogenesis are co-dependent processes, exacerbating and mediating structural damage and pain in OA.

7.1 Angiogenesis and chronic inflammation

The mechanisms leading to persistent inflammation in human diseases are not fully elucidated. Chronic inflammation is always accompanied by angiogenesis, and although angiogenesis can occur without inflammation, it facilitates plasma extravasation and inflammatory cell recruitment (Costa et al., 2007). Angiogenesis can exacerbate pain by facilitating inflammation (Bonnet et al., 2005). Inflammation is now increasingly being recognized as one of the prominent features of previously thought non-inflammatory arthritic conditions such as OA (Ashraf et al., 2008; Bondeson et al., 2010).

Intra-articular injection of λ carrageenan has been shown in previous studies to induce synovitis (Lam et al., 1989; Lam et al., 1991; Walsh et al., 1998), similarly in this study, intra-articular injection of either 0.03% or 2% carrageenan was used to induce either acute or chronic synovitis respectively in rats. With carrageenan, joint swelling begins within minutes of injection, permitting an accurate definition of the time of synovitis onset. In this study, chronic synovitis was associated with increased pain behaviour and a short course of the angiogenesis inhibitor, PPI-2458 was shown to reduce this pain behaviour in the 2% carrageenan model of chronic synovitis by directly inhibiting synovial angiogenesis prior to the reduction in synovitis. This highlights that angiogenesis could indeed be one of the components of chronic inflammation, indicating that even though angiogenesis is not in itself painful, it may synergise with inflammation to exacerbate pain by sensitizing nerves growing alongside blood vessels. Hence inhibiting angiogenesis may curtail the sensation of pain.

In order to further verify the role of angiogenesis in chronic inflammation, and to show that indeed synovitis persists due to the involvement of angiogenesis and it is this angiogenesis which is being targeted by the angiogenesis inhibitor PPI-2458 in curtailing chronic synovitis, it was shown for the first time that conversion of acute synovitis to chronic synovitis could indeed in part be due to the stimulation of angiogenesis. Previous studies have implicated angiogenic factors including FGFs in the initiation and progression of synovial hyperplasia and inflammation in RA (Malemud 2007). FGFs are one of the candidates that cause progression of OA (Daouti et al., 2005). Angiogenesis induction using FGF-2 at the onset of carrageenan induced acute synovitis in this study resulted in the transition from acute to chronic synovitis. This chronic synovitis was in turn inhibited by a short course of the angiogenesis inhibitor PPI-2458.

The data presented in this thesis supports previous evidence that FGF-2 is pro-angiogenic, but not directly pro-inflammatory (Ziche et al., 1992; Cozzolino et al., 1993; Gualandris et al., 1994) because a single intra-articular injection of FGF-2 either alone, or together with carrageenan, was insufficient to increase joint swelling or macrophage infiltration at 24 hours, despite its ability to increase endothelial cell proliferation. The ability of FGF-2 to augment chronic synovitis were shown to be inhibited in this study by the brief administration of PPI-2458, and in another study by repeated administration of an anti-

angiogenic inhibitor of $\alpha v\beta 3$ integrin in antigen-induced arthritis (Storgard et al., 1999). These data support the idea that FGF-2 therefore may contribute to arthritis by increasing synovial angiogenesis, which may indirectly enhance synovitis, rather than any direct effect on inflammation. Also PPI-2458 abolished synovial angiogenesis prior to reduction in synovitis, whereas synovitis reduction followed the discontinuation of PPI-2458. This indicates that PPI-2458 may exert its effects not through the direct inhibition of inflammation, but rather through the inhibition of angiogenesis.

Synovial angiogenesis is an early feature of both OA and RA, and occurs very early in the development of persistent synovitis in animal models (Walsh et al., 1998; Brahn et al., 2008). Synovial angiogenesis is also a feature of chronic synovitis in both humans and animals (Walsh et al., 1998; Walsh et al., 2001; Haywood et al., 2003). These data also demonstrate increased endothelial cell proliferation during chronic synovitis after co-injection of either carrageenan and FGF-2 or single injection of 2% carrageenan. It is likely that angiogenesis 4 weeks after the induction of chronic synovitis was mediated by factors other than the injected FGF-2, since FGF-2 alone induced only a transient increase in endothelial cell proliferation that had normalised by 5 days. Angiogenesis during chronic synovitis may be mediated by an imbalance between a variety of angiogenic and anti-angiogenic factors (Bonnet et al., 2005). Further studies will be required to understand which molecules sustain synovial angiogenesis in humans or animal models.

Mechanisms by which acute synovitis may lead on to chronic arthritis remain incompletely understood. However, this study supports previous findings that angiogenesis is a feature of early as well as persistent synovitis in humans (Griffioen et al., 2000; El-Gabalawy 2005; Klareskog et al., 2009). It also goes on to provide further evidence that synovial angiogenesis may indeed be a factor leading to persistent synovitis and inhibiting synovial angiogenesis at the onset of chronic synovitis has the capability of reducing pain associated with chronic synovitis.

7.2 Angiogenesis, inflammation, structural damage and pain in OA

Transection of the medial meniscus in the rat was shown to result in osteoarthritic changes in the medial tibial plateaux, consisting of fibrillation and eventual loss of cartilage, accompanied by reduced density of chondrocytes and loss of proteoglycan staining, and growth of osteophytes at the joint margins (Janusz et al., 2002; Bove et al., 2006; Mapp et al., 2008; Mapp et al., 2010). The MNX model of OA also demonstrated loss of integrity of the osteochondral junction as channels were shown in this study to penetrate the articular cartilage from the subchondral bone space. Additionally there is synovitis, indicated by increased synovial macrophage infiltration, and pain behavior, exhibited by a reluctance of the animals to symmetrically weight bear on their hind limbs (Bove et al., 2006; Mapp et al., 2008; Mapp et al., 2010). In each of these respects, MNX model of OA used in this study was shown to effectively mimic the human condition, and provided important insights into mechanisms underlying structural changes, pain behavior and responses to pharmacological therapies.

Typically OA presents as joint pain with progressive loss of joint function. A great deal is known about symptoms of the disease, but the pathophysiology underlying those symptoms is widely acknowledged to be complex and less well understood. In the absence of disease modifying drugs to treat OA, pharmacological interventions often act by subduing pain in order to relieve symptoms (McColl 2001). Current treatments are often limited by potential adverse events, and a better understanding of how joint pathology leads to pain is required to develop new therapies.

It is well documented that angiogenesis is a feature of OA in rats as well as in humans, both in the synovium and at the osteochondral junction (Walsh et al., 2007; Mapp et al., 2008). Synovial angiogenesis is associated with synovitis by either being a consequence of synovitis through the expression of angiogenic factors by macrophages, or angiogenesis could exacerbate inflammation by facilitating plasma extravasation and cellular influx (Walsh 1999; Bonnet et al., 2005). Synovial and osteochondral angiogenesis are also associated with OA structural changes, and could contribute to those changes either directly or by facilitating inflammation (Haywood et al., 2003). Angiogenesis is followed by innervation of newly formed blood vessels by fine unmyelinated sensory nerves, and could therefore directly contribute to pain in OA (Haywood et al., 2003).

Synovitis is associated with increased chondropathy in human OA (Walsh et al., 2009), and predicts progression of joint damage in longitudinal studies (Ledingham et al., 1995; Palosaari et al., 2006). Clinically, osteoarthritic patients have a variable degree of synovitis. In-vitro studies of human OA synovium and studies of OA pathology in animal models have implicated the inflamed synovium and synovial macrophages as important contributors in promoting OA pathology (Bondeson et al., 2010). Synovitis is implicated in many signs and symptoms of OA including swelling and effusion (Pelletier et al., 2001; Benito et al., 2005). Synovitis also contributes to disease progression as indicated by the correlation between biologic markers of inflammation, such as C-reactive protein and cartilage oligomeric matrix protein, with the progression of OA structural changes (Clark et al., 1999; Sowers et al., 2002).

After showing that angiogenesis is an integral component in chronic synovitis, whether synovitis could exacerbate osteoarthritic changes was investigated and if by targeting the angiogenic component of this chronic synovitis instead of directly inhibiting inflammation using anti-inflammatory drugs it would be possible to curtail the structural damage seen and the pain experienced in OA was also looked at. Using the rat MNX model of knee OA, the results presented in this thesis confirm previous findings and show that synovitis exacerbates structural damage and pain. The results go on to illustrate that the administration of either anti-inflammatory (dexamethasone or indomethacin) or anti-angiogenic (PPI-2458) treatments are associated with reduced synovitis, structural damage and pain behavior. This indicates that angiogenesis may contribute both to inflammation and joint damage, and that angiogenesis inhibition works just as well

as anti-inflammatory drugs in reducing inflammation even after synovitis has become established. Hence these data support the notion that inhibition of blood vessel growth may be a useful strategy in reducing OA pain. These findings are an extension of previously published data, where researchers have shown PPI-2458 inhibits synovitis in collagen and in PGPS-induced arthritis in mice and rats (Bainbridge et al., 2007; Lazarus et al., 2008). This indicates that the anti-inflammatory effects of angiogenesis inhibition are observed in synovitis induced by a wide variety of agents.

7.3 Anti-inflammatory and anti-angiogenic treatments in OA

Inhibition of synovitis is an attractive target for disease modification in OA, although coincidental and detrimental effects of current anti-inflammatory agents on chondrocyte function (Annefeld et al., 1990; Bove et al., 2003) could limit their efficacy as disease modifying agents. In this study, treatment with either dexamethasone; a synthetic adrenal corticosteroid or an angiogenesis inhibitor PPI-2458 reduced total joint damage score. Dexamethasone predominantly affected chondropathy in the MNX model, whereas angiogenesis inhibition reduced osteophyte size, suggesting that the structural effects of angiogenesis inhibition could not be entirely mediated by its anti-inflammatory effects. This data complements previous findings where angiogenesis inhibition with VEGF blockade was found to reduce new bone formation around arthritic joints, an effect that could partly be mediated by inhibition of endochondral ossification (Miotla et al., 2000).

Similarly, intra-articular or systemic delivery of dexamethasone have previously been shown to reduce joint damage in experimental animal models of inflammatory arthritis, such as adjuvant arthritis (AA) and collagen-induced arthritis (CIA) (Bendele 2001; Cuzzocrea et al., 2005; Caparroz-Assef et al., 2007). In a rabbit meniscal transection model of OA, corticosteroids given before the onset of OA reduced osteophyte formation and cartilage loss (Butler et al., 1983). Similar findings have been reported in guinea pig and dog models of experimental OA (Williams et al., 1985; Pelletier et al., 1995).

In-vitro findings have shown that functional properties of cartilage explants could be maintained in culture through the addition of dexamethasone to cell media (Bian et al., 2010). However conflicting studies exist indicating that corticosteroids also inhibit chondrocyte synthetic functions and may therefore exacerbate joint damage, limiting their frequent use in clinical setting (Boland 1964; Annefeld et al., 1990).

Similar to previous studies where vascular channel formation and pain behavior in the MNX model of OA was shown to be reduced by matrix metalloproteinase inhibition (Mapp et al., 2010), the data in this thesis show that PPI-2458 inhibited vascularisation of channels at the osteochondral junction which is consistent with its anti-angiogenic activity. However, the significant increase in total channel numbers in animals having meniscal transection surgery and treated with PPI-2458 compared with non-arthritic control animals indicated that angiogenesis is not a prerequisite for channel formation. Reductions in pain and structural

damage observed in the osteoarthritic animals following treatment with PPI-2458 could partly be due to inhibition of osteophyte growth and angiogenesis at the osteochondral junction, as well as inhibition of synovitis.

These findings indicate that synovitis and total joint damage are closely associated with pain behaviour in the rat MNX model of OA and this could, in part, be explained by angiogenesis in the synovium and at the osteochondral junction. Targeting angiogenesis could therefore prove useful in reducing pain and structural damage in OA, either alone or in combination with other drugs (Figure 6.1).

7.4 Meniscus as a source of pain in human tibiofemoral OA

After showing that angiogenesis is an integral component in chronic synovitis, and that synovitis could exacerbate osteoarthritic changes in the rat MNX model of knee OA, I went on to highlight that by targeting the angiogenic component of this chronic synovitis and also by directly inhibiting synovitis using anti-inflammatory drugs it was possible to curtail the structural damage seen and the pain experienced in this MNX model of OA. Angiogenesis is not in itself painful, but since it is possible that angiogenesis may contribute to pain in OA by enabling growth of new unmyelinated sensory nerves (Bonnet et al., 2005; Ashraf et al., 2008), I went on to establish whether menisci could be a source of pain in OA through these mechanisms. I had already shown that in the MNX model of OA, CGRP positive sensory nerves were seen in the synovium, subchondral bone and in osteophytes. Previous literature complements these findings as angiogenesis and sensory nerves have been observed in the synovium and at the osteochondral junction in OA (Walsh et al., 2007) penetrating into non-calcified articular cartilage and osteophytes (Suri et al., 2007). These perivascular, unmyelinated, nerve fibres containing substance-P and CGRP have been implicated in mediating sustained burning pain described by patients with OA (Kidd et al., 1992; Dieppe et al., 2005).

Examining the vascularisation and innervation of human menisci between high and low tibiofemoral chondropathy groups highlighted an association between disorganisation of collagenous matrix structure and chondropathy in human knees. Menisci with high chondropathy scores had increased synovial penetration towards the tip, extending over part of the inner region. The synovium also appeared thicker, in menisci from high chondropathy group compared with those from the low chondropathy group. An increase in penetration of blood vessels and nerves towards the meniscal tip with high chondropathy scores was also demonstrated. Vascularisation of normally avascular tissues has also been demonstrated in articular cartilage in OA and inner regions of the annulus fibrosus of the intervertebral disc in back pain (Kauppila 1995). Meniscal angiogenesis on the other hand could also be a homeostatic response to minimise meniscal damage in OA. Vascularisation changes tissue biomechanics and could predispose to further damage. Interventional studies would therefore be required to determine whether meniscal angiogenesis protects against or contributes to joint damage in OA.

These findings showed that increased angiogenesis and thickness of the synovium observed in OA extends to include synovium attached to menisci. Increased synovial vascularity was associated with vascularisation at the fibrocartilage junction of the meniscus, suggesting that angiogenesis in these different joint compartments may be regulated by common factors. The stimuli to meniscal blood vessel growth deserve further study, because they could originate from cells within the meniscus itself and also from adjacent structures such as the synovium and articular cartilage.

These data demonstrated that CGRP positive sensory nerve profiles were present in the outer region of menisci, and most of these nerves were associated with blood vessels. CGRP is co-localised with substance P in unmyelinated sensory nerve fibres, and this work therefore extends previous findings that perivascular nerves containing substance P are located in the peripheral portion of torn menisci (Mine et al., 2000). In this study, increase in sensory innervation in the outer region of the menisci from knees with high chondropathy scores was observed, therefore, nerve growth in menisci could contribute to pain in OA both through an increased density of nociceptive fibres, and also through increased sensitivity that occurs during nerve growth (Ma et al., 1997). Recent controlled trials of nerve growth factor blockade have demonstrated its ability to inhibit OA knee pain (Cattaneo 2010), although the rapid onset of its analgesic effect could suggest an action on sensitisation rather than on nerve growth. CGRP-immunoreactive nerves were localised adjacent to blood vessels within the meniscus, and sensory nerve growth follows blood vessel growth in a variety of tissues (Aoki et al., 1994; Walsh et al., 1996). It is therefore not far-fetched to predict that angiogenesis inhibition could also have analgesic potential by reducing aberrant innervation in the osteoarthritic knee (Walsh et al., 2001).

So collectively the data collected as part of this thesis highlights that synovium, cartilage, subchondral bone and menisci could all be possible sources of pain in knee OA. In light of the findings shown in this thesis, neovascularisation and innervation of otherwise avascular and aneural regions of the joints could contribute to both structural change and pain in OA. Inhibition of either angiogenesis and/or inflammation and/or nerve growth may each offer the potential to reduce structural damage and pain in OA (Figure 6.1). However interventional studies are needed to further elucidate the contribution of and the links between angiogenesis, inflammation, nerve growth and pain. Never-the-less the data presented in this thesis support the hypothesis that inflammation and angiogenesis are co-dependent processes that can exacerbate and mediate structural damage and pain in OA.

7.5 Limitations of the current studies

Although the results reported in this thesis provide novel evidence of a role for angiogenesis in chronic synovitis, structural damage, innervation and pain in OA, conclusions are limited by a number of factors that are common to investigations of complex biological processes in intact animals. These limitations are discussed below:

- Even though PPI-2458 is well characterized as a specific inhibitor of angiogenesis, it was not fully possible to separate in these in-vivo studies whether the inhibition of angiogenesis following PPI-2458 treatment leads to reduced inflammation and hence pain or whether PPI-2458 is acting in an anti-inflammatory manner distinct from its anti-angiogenic properties.
- The effects of either angiogenesis or inflammation inhibition on innervation of the joint was also not investigated due to time and cost constraints, hence innervation of the joint was not correlated to pain behaviour in these in-vivo models.
- Indomethacin and dexamethasone could have had effects additional to inhibiting inflammation, including direct anti-angiogenic actions.
- Macroscopic appearance of chondropathy is used in the human menisci study as an indicator of tibiofemoral OA. Even though chondropathy scores for high chondropathy group are similar to those previously observed at total joint replacement surgery for knee OA (Walsh et al., 2009), all of whom fulfilled the American College of Rheumatology revised criteria for OA (Altman et al., 1986), chondropathy alone, however, is insufficient to diagnose knee OA and further studies would be required to determine whether the observed meniscal changes are associated with other features of OA.
- During selection of cases for the meniscal study, 3 cases were excluded from the high chondropathy group due to non-availability of meniscal tissue. Menisci can be completely disrupted in severe OA and the current findings will only be relevant to cases where menisci remain intact.
- The prevalence and severity of OA increases with age, and it was not possible in this study to exclude the possibility that differences in vascularity and innervation between high and low chondropathy groups may have been age- rather than disease-related.
- It is not known whether patients from whom the menisci were obtained suffered from knee pain, and the proposal that meniscal pathology may be associated with knee pain remains speculative.
- The meniscal study is not age-matched, it is however extremely difficult to carry out age and disease matched study as it would require a very large repository of human joint tissues. The Academic Rheumatology joint tissue repository is an ongoing repository where joint tissues from PM cases are continuously being added over time. In the current repository containing 288 PM cases, 20 cases within the age range of 23 to 59 and 56 to 91 years fulfilled the criteria of having low and high macroscopic chondropathy scores respectively. Only 1 case in the total repository within the age range 23 to 59 had a high macroscopic chondropathy score. In order to be able to select 20 cases with high chondropathy scores within the age range 23 to 59, repository having 5760 PM cases would be required. Correspondingly, only 2 cases in our repository within the age range 56 to 91 had low macroscopic chondropathy scores. In order

to be able to select 20 cases with low chondropathy scores within the age range 56 to 91, a repository containing 2880 PM cases would have been needed. Therefore an extremely large repository containing approximately over 2500 PM cases is needed to carry out an age matched study. At the moment the Academic Rheumatology joint tissue repository does not house such large number of PM cases. An alternative approach was considered of including cases with milder chondropathy in the high chondropathy group, or more severe chondropathy within the low chondropathy group, but this would have reduced the validity of case selection, increasing the likelihood of cross-contamination between the groups. Including smaller numbers of cases within the groups would have reduced the power of the study to detect clinically important differences in vascularity.

Despite these limitations, however, the data presented in this thesis support the view that anti-inflammatory and anti-angiogenic strategies may have the potential not only to relieve symptoms, but also to modify structural progression in OA. The use of post mortem tissues in the human meniscal study permitted the analysis of two discrete patient groups, with menisci harvested and processed and chondropathy assessed by identical methodologies, avoiding differences between surgical and control specimens that can often limit interpretation of pathological studies. Hence these data presented should help direct the design of future experiments to further elucidate the mechanisms connecting angiogenesis to inflammation, innervation, structural damage and pain in OA.

7.6 Future directions

This thesis has highlighted the contributions of angiogenesis to inflammation, innervation, structural damage and pain in OA both in-vivo using animal models and ex-vivo using human meniscal tissue. The data from two animal models of chronic synovitis presented in this thesis shows that angiogenesis is an important component in the transition of acute to chronic synovitis and a brief anti-angiogenic treatment during the acute phase of synovitis could prevent its subsequent progression. Increased synovitis also exacerbated structural damage and pain in the MNX model of OA and treatment with the anti-angiogenic compound was followed by a reduction in these enhanced pathological changes. Similarly, in the MNX model of OA, both anti-inflammatory (either dexamethasone or indomethacin) and anti-angiogenic (PPI-2458) compounds were able to reduce synovitis, total joint damage and pain behaviour. This indicates that synovitis and joint damage are closely associated with pain behaviour in the MNX model of OA and angiogenesis inhibition may reduce pain behaviour both by reducing synovitis and preventing structural damage. However, future studies mentioned below are needed to address the limitations of the findings presented in this thesis as well as exploring new avenues to further elucidate the connection between inflammation, angiogenesis, structural damage and pain in OA:

- To further characterise the mechanism of action of the angiogenesis inhibitor PPI-2458 in reducing synovitis and understanding whether it is the inhibition of angiogenesis following PPI-2458 treatment which leads to reduced inflammation and hence pain or whether PPI-2458 is acting in an anti-inflammatory manner distinct from its anti-angiogenic properties, it is proposed that the effects of PPI-2458 need to be first verified in an in-vivo model of inflammation without angiogenesis, such as the 0.03% carrageenan model of resolving synovitis.
- Since it was also not possible to investigate whether anti-inflammatory and anti-angiogenic treatments had any effects on the innervation of the osteoarthritic knee joints in the MNX model of OA and hence to correlate those data to the pain measurements as joint tissues needed to be preserved and decalcified separately for innervation and vascular studies and this required the same experiments to be run twice. Looking at the effects that anti-angiogenic (PPI-2458) and anti-inflammatory (Dexamethasone and Indomethacin) drugs have on the innervation of the various compartments of the osteoarthritic knee joint in the MNX model of OA and correlating those data to pain measurements is a logical step forward forming the basis of future investigations.
- To rule out the possibility that indomethacin and dexamethasone could have had effects additional to inhibiting inflammation, including direct anti-angiogenic actions, the behaviour of these drugs need to be tested in an angiogenic model without inflammation such as the 6 picomoles of FGF-2 synovial angiogenesis rat model.
- To further explore the role of angiogenesis in inflammation, joint damage and pain in OA, enhancing angiogenesis in the MNX model of OA using various angiogenic factors such as FGF and VEGF to see whether they have any effect if at all in exacerbating inflammation, joint damage and pain in the osteoarthritic animals could prove interesting.

- The results presented in this thesis have shown that long-term angiogenesis inhibition has the potential to reduce inflammation, structural damage and pain in the MNX model of OA, but this is not without its attached side-effects, but whether short-term angiogenesis inhibition has any effects is not known and needs to be investigated, to reduce the chances of possible side-effects attached to other long term drug-treatment use.
- Looking at the effects of different combinations and durations of anti-inflammatory and anti-angiogenic treatment regimes on synovitis, structural damage and pain in the MNX model of OA are also worth investigating as well as seeing whether the findings reported in this thesis hold true in another model of OA, such as the monosodium-iodoacetate (MIA) model.
- Since it is highly likely that multiple factors could lead to chronic inflammation, angiogenesis inhibition may have greatest therapeutic potential in combination with other pharmacological agents.
- Eventually, clinical studies are also necessary to determine whether the interventional studies done in animal models hold true in clinical settings.

Together, the results from the above mentioned experiments should further elucidate the role of angiogenesis in inflammation, structural damage and pain in the MNX model of OA.

7.7 Concluding remarks

OA is the commonest form of arthritis and is of unknown aetiology. It is associated with articular cartilage loss, synovitis, subchondral bone remodelling and osteophyte formation. Angiogenesis, the growth of new blood vessels from pre-existing ones, contributes to each of these pathological features of OA. Pain, the main symptom of OA originates from several sources within the knee joint some of which are synovium, cartilage, bone and menisci. Inflammation sensitises the sensory nerves growing alongside blood vessels in various compartments of the joints and these sensitised nerves contribute to neurogenic inflammation, initiating new vessel growth. Hence, angiogenesis contributes both to the symptoms and pathology of OA and further analysis of its role seems vital in leading to discovering more effective therapies.

The findings outlined in this thesis have provided evidence in-vivo using animal models of synovitis and of OA that synovitis, synovial angiogenesis and structural damage are closely associated with pain behaviour. Angiogenesis inhibition may therefore have the potential to reduce pain behaviour both by reducing synovitis and also by preventing structural damage. Ex-vivo, using human meniscal tissue it is shown that tibiofemoral chondropathy is associated with altered matrix structure, increased vascular penetration and increased sensory nerve densities in the medial meniscus. Indicating that angiogenesis and associated sensory nerve growth in menisci could contribute to the pain observed in OA (Figure 6.1).

Further studies will concentrate on assessing the effects that anti-inflammatory and anti-angiogenic treatments have on the innervation of the osteoarthritic knee joints in the MNX model of OA and how this data correlates with pain behaviour measurement. Moreover looking at the effects of different combinations and durations of anti-inflammatory and anti-angiogenic treatment regimes on synovitis, structural damage and pain in the MNX model of OA as well as seeing whether these findings hold true in other models of OA, such as the MIA model and other models of synovitis. Looking at whether PPI-2458 has any effects on other angiogenic factors such as VEGF could also be useful. This information could prove vital to increasing our understanding of the contributions of angiogenesis to inflammation, structural damage and pain in OA.

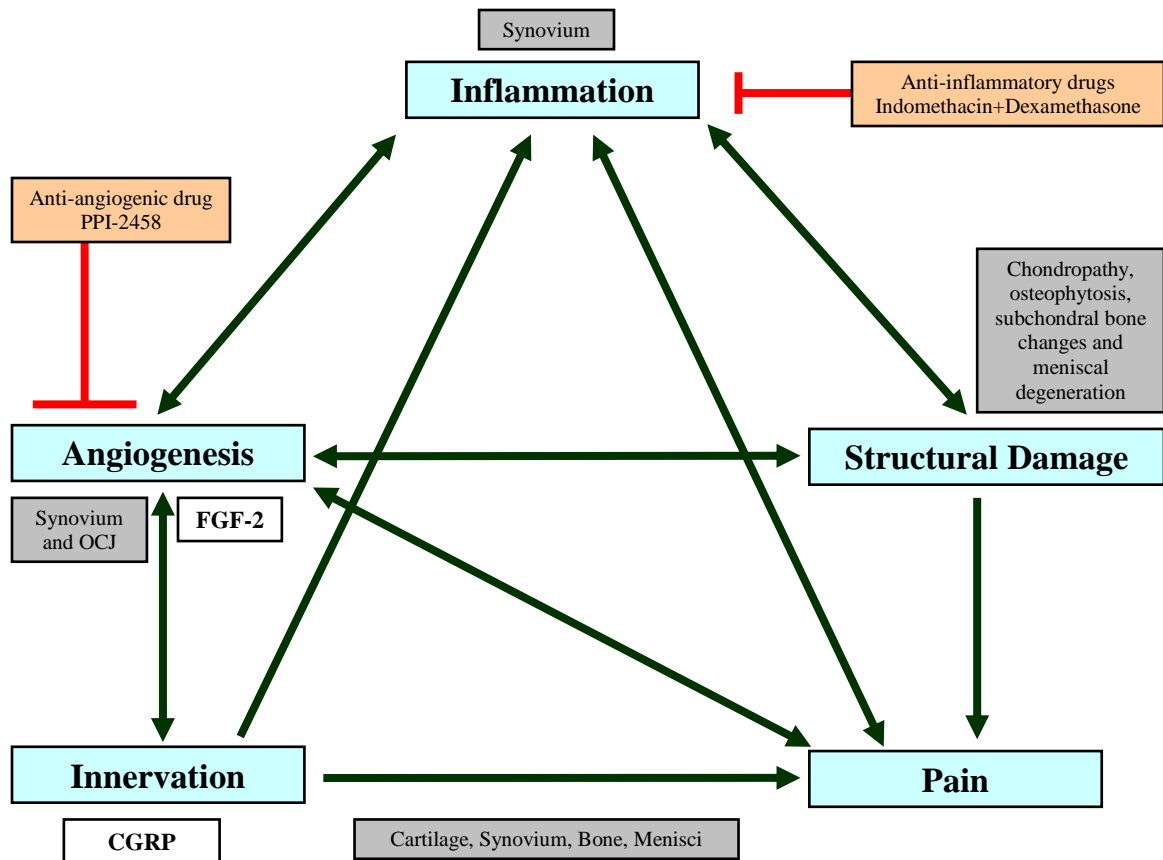


Figure 6.1 Relationship between inflammation, angiogenesis, innervation, structural damage and pain in OA. OA is a dynamic disease process, where the symptoms and structural changes are all interconnected. Angiogenesis inhibition in the synovium and at the osteochondral junction (OCJ) has the potential to curtail synovitis, structural damage and pain in a rat MNX model of OA. Similar effects were seen using anti-inflammatory drugs. Angiogenesis (fibroblast growth factor [FGF] -2) and associated sensory nerve growth (calcitonin gene related peptide; CGRP) in the cartilage, synovium, bone and menisci could contribute to pain in OA.

8 REFERENCES

- Abe, J., Zhou, W., Takuwa, N., Taguchi, J., Kurokawa, K., Kumada, M. and Takuwa, Y. (1994). "A fumagillin derivative angiogenesis inhibitor, AGM-1470, inhibits activation of cyclin-dependent kinases and phosphorylation of retinoblastoma gene product but not protein tyrosyl phosphorylation or protooncogene expression in vascular endothelial cells." Cancer Res **54**(13): 3407-12.
- Abramson, S. B. (2004). "Inflammation in osteoarthritis." J Rheumatol Suppl **70**: 70-6.
- Abramsson, A., Lindblom, P. and Betsholtz, C. (2003). "Endothelial and nonendothelial sources of PDGF-B regulate pericyte recruitment and influence vascular pattern formation in tumors." J Clin Invest **112**(8): 1142-51.
- Aigner, T. and McKenna, L. (2002). "Molecular pathology and pathobiology of osteoarthritic cartilage." Cell Mol Life Sci **59**(1): 5-18.
- Alroy, J., Goyal, V. and Skutelsky, E. (1987). "Lectin histochemistry of mammalian endothelium." Histochemistry **86**(6): 603-7.
- Altman, R., Asch, E., Bloch, D., Bole, G., Borenstein, D., Brandt, K., Christy, W., Cooke, T. D., Greenwald, R., Hochberg, M. and et al. (1986). "Development of criteria for the classification and reporting of osteoarthritis. Classification of osteoarthritis of the knee. Diagnostic and Therapeutic Criteria Committee of the American Rheumatism Association." Arthritis Rheum **29**(8): 1039-49.
- Altman, R. D. (2010). "Early management of osteoarthritis." Am J Manag Care **16 Suppl Management**: S41-7.
- Ameye, L. G. and Young, M. F. (2006). "Animal models of osteoarthritis: lessons learned while seeking the "Holy Grail"." Curr Opin Rheumatol **18**(5): 537-47.
- Annefeld, M., Erne, B. and Rasser, Y. (1990). "Ultrastructural analysis of rat articular cartilage following treatment with dexamethasone and glycosaminoglycan-peptide complex." Clin Exp Rheumatol **8**(2): 151-7.
- Aoki, M., Tamai, K. and Saotome, K. (1994). "Substance P- and calcitonin gene-related peptide-immunofluorescent nerves in the repair of experimental bone defects." Int Orthop **18**(5): 317-24.
- Appleton, C. T., Pitelka, V., Henry, J. and Beier, F. (2007). "Global analyses of gene expression in early experimental osteoarthritis." Arthritis Rheum **56**(6): 1854-68.
- Arden, N. and Nevitt, M. C. (2006). "Osteoarthritis: epidemiology." Best Pract Res Clin Rheumatol **20**(1): 3-25.
- Arnoczky, S. P. and Warren, R. F. (1982). "Microvasculature of the human meniscus." Am J Sports Med **10**(2): 90-5.
- Arnoldi, C. C., Lemperg, K. and Linderholm, H. (1975). "Intraosseous hypertension and pain in the knee." J Bone Joint Surg Br **57**(3): 360-3.
- Ashraf, S. and Walsh, D. A. (2008). "Angiogenesis in osteoarthritis." Curr Opin Rheumatol **20**(5): 573-80.

- Assimakopoulos, A. P., Katonis, P. G., Agapitos, M. V. and Exarchou, E. I. (1992). "The innervation of the human meniscus." Clin Orthop Relat Res(275): 232-6.
- Attur, M. G., Dave, M., Akamatsu, M., Katoh, M. and Amin, A. R. (2002). "Osteoarthritis or osteoarthrosis: the definition of inflammation becomes a semantic issue in the genomic era of molecular medicine." Osteoarthritis Cartilage **10**(1): 1-4.
- Attur, M. G., Patel, I. R., Patel, R. N., Abramson, S. B. and Amin, A. R. (1998). "Autocrine production of IL-1 beta by human osteoarthritis-affected cartilage and differential regulation of endogenous nitric oxide, IL-6, prostaglandin E2, and IL-8." Proc Assoc Am Physicians **110**(1): 65-72.
- Bainbridge, J., Madden, L., Essex, D., Binks, M., Malhotra, R. and Paleolog, E. M. (2007). "Methionine aminopeptidase-2 blockade reduces chronic collagen-induced arthritis: potential role for angiogenesis inhibition." Arthritis Res Ther **9**(6): R127.
- Bakker, A. C., van de Loo, F. A., van Beuningen, H. M., Sime, P., van Lent, P. L., van der Kraan, P. M., Richards, C. D. and van den Berg, W. B. (2001). "Overexpression of active TGF-beta-1 in the murine knee joint: evidence for synovial-layer-dependent chondro-osteocyte formation." Osteoarthritis Cartilage **9**(2): 128-36.
- Bendele, A. M. (2001). "Animal models of osteoarthritis." J Musculoskelet Neuronal Interact **1**(4): 363-76.
- Bendele, A. M., White, S. L. and Hulman, J. F. (1989). "Osteoarthrosis in guinea pigs: histopathologic and scanning electron microscopic features." Lab Anim Sci **39**(2): 115-21.
- Benelli, R., Lorusso, G., Albini, A. and Noonan, D. M. (2006). "Cytokines and chemokines as regulators of angiogenesis in health and disease." Curr Pharm Des **12**(24): 3101-15.
- Benito, M. J., Veale, D. J., FitzGerald, O., van den Berg, W. B. and Bresnihan, B. (2005). "Synovial tissue inflammation in early and late osteoarthritis." Ann Rheum Dis **64**(9): 1263-7.
- Bennett, L. D. and Buckland-Wright, J. C. (2002). "Meniscal and articular cartilage changes in knee osteoarthritis: a cross-sectional double-contrast macroradiographic study." Rheumatology (Oxford) **41**(8): 917-23.
- Bernardi, A., Zilberstein, A. C., Jager, E., Campos, M. M., Morrone, F. B., Calixto, J. B., Pohlmann, A. R., Guterres, S. S. and Battastini, A. M. (2009). "Effects of indomethacin-loaded nanocapsules in experimental models of inflammation in rats." Br J Pharmacol **158**(4): 1104-11.
- Bernier, S. G., Lazarus, D. D., Clark, E., Doyle, B., Labenski, M. T., Thompson, C. D., Westlin, W. F. and Hannig, G. (2004). "A methionine aminopeptidase-2 inhibitor, PPI-2458, for the treatment of rheumatoid arthritis." Proc Natl Acad Sci U S A **101**(29): 10768-73.
- Bernier, S. G., Taghizadeh, N., Thompson, C. D., Westlin, W. F. and Hannig, G. (2005). "Methionine aminopeptidases type I and type II are essential to control cell proliferation." J Cell Biochem **95**(6): 1191-203.
- Bhattacharyya, T., Gale, D., Dewire, P., Totterman, S., Gale, M. E., McLaughlin, S., Einhorn, T. A. and Felson, D. T. (2003). "The clinical importance of meniscal tears demonstrated by magnetic resonance imaging in osteoarthritis of the knee." J Bone Joint Surg Am **85-A**(1): 4-9.

- Bian, L., Stoker, A. M., Marberry, K. M., Ateshian, G. A., Cook, J. L. and Hung, C. T. (2010). "Effects of dexamethasone on the functional properties of cartilage explants during long-term culture." Am J Sports Med **38**(1): 78-85.
- Bin, S. I., Lee, S. H., Kim, C. W., Kim, T. H. and Lee, D. H. (2008). "Results of arthroscopic medial meniscectomy in patients with grade IV osteoarthritis of the medial compartment." Arthroscopy **24**(3): 264-8.
- Bird, G. C., Han, J. S., Fu, Y., Adwanikar, H., Willis, W. D. and Neugebauer, V. (2006). "Pain-related synaptic plasticity in spinal dorsal horn neurons: role of CGRP." Mol Pain **2**: 31.
- Bland, J. M. and Altman, D. G. (1996). "Measurement error." Bmj **313**(7059): 744.
- Blaney Davidson, E. N., Vitters, E. L., van der Kraan, P. M. and van den Berg, W. B. (2006). "Expression of transforming growth factor-beta (TGFbeta) and the TGFbeta signalling molecule SMAD-2P in spontaneous and instability-induced osteoarthritis: role in cartilage degradation, chondrogenesis and osteophyte formation." Ann Rheum Dis **65**(11): 1414-21.
- Blom, A. B., van Lent, P. L., Holthuysen, A. E., van der Kraan, P. M., Roth, J., van Rooijen, N. and van den Berg, W. B. (2004). "Synovial lining macrophages mediate osteophyte formation during experimental osteoarthritis." Osteoarthritis Cartilage **12**(8): 627-35.
- Boland, E. W. (1964). "Nonspecific Anti-Inflammatory Agents. Some Notes on Their Practical Application, Especially in Rheumatic Disorders." Calif Med **100**: 145-55.
- Bondeson, J., Blom, A. B., Wainwright, S., Hughes, C., Caterson, B. and van den Berg, W. B. (2010). "The role of synovial macrophages and macrophage-produced mediators in driving inflammatory and destructive responses in osteoarthritis." Arthritis Rheum **62**(3): 647-57.
- Bondeson, J., Wainwright, S. D., Lauder, S., Amos, N. and Hughes, C. E. (2006). "The role of synovial macrophages and macrophage-produced cytokines in driving aggrecanases, matrix metalloproteinases, and other destructive and inflammatory responses in osteoarthritis." Arthritis Res Ther **8**(6): R187.
- Bonnet, C. S. and Walsh, D. A. (2005). "Osteoarthritis, angiogenesis and inflammation." Rheumatology (Oxford) **44**(1): 7-16.
- Bove, S. E., Calcaterra, S. L., Brooker, R. M., Huber, C. M., Guzman, R. E., Juneau, P. L., Schrier, D. J. and Kilgore, K. S. (2003). "Weight bearing as a measure of disease progression and efficacy of anti-inflammatory compounds in a model of monosodium iodoacetate-induced osteoarthritis." Osteoarthritis Cartilage **11**(11): 821-30.
- Bove, S. E., Laemont, K. D., Brooker, R. M., Osborn, M. N., Sanchez, B. M., Guzman, R. E., Hook, K. E., Juneau, P. L., Connor, J. R. and Kilgore, K. S. (2006). "Surgically induced osteoarthritis in the rat results in the development of both osteoarthritis-like joint pain and secondary hyperalgesia." Osteoarthritis Cartilage **14**(10): 1041-8.
- Brahn, E., Banquerigo, M. L., Lee, J. K., Park, E. J., Fogler, W. E. and Plum, S. M. (2008). "An angiogenesis inhibitor, 2-methoxyestradiol, involutes rat collagen-induced arthritis and suppresses

- gene expression of synovial vascular endothelial growth factor and basic fibroblast growth factor." J Rheumatol **35**(11): 2119-28.
- Brahn, E., Schoettler, N., Lee, S. and Banquerigo, M. L. (2009). "Involution of collagen-induced arthritis with an angiogenesis inhibitor, PPI-2458." J Pharmacol Exp Ther **329**(2): 615-24.
- Brandt, K. D., Fife, R. S., Braunstein, E. M. and Katz, B. (1991). "Radiographic grading of the severity of knee osteoarthritis: relation of the Kellgren and Lawrence grade to a grade based on joint space narrowing, and correlation with arthroscopic evidence of articular cartilage degeneration." Arthritis Rheum **34**(11): 1381-6.
- Brooks, P. M. (2006). "The burden of musculoskeletal disease--a global perspective." Clin Rheumatol **25**(6): 778-81.
- Brown, L. F., Detmar, M., Claffey, K., Nagy, J. A., Feng, D., Dvorak, A. M. and Dvorak, H. F. (1997). "Vascular permeability factor/vascular endothelial growth factor: a multifunctional angiogenic cytokine." Exs **79**: 233-69.
- Brown, R. A. and Weiss, J. B. (1988). "Neovascularisation and its role in the osteoarthritic process." Ann Rheum Dis **47**(11): 881-5.
- Bruckner, P. and van der Rest, M. (1994). "Structure and function of cartilage collagens." Microsc Res Tech **28**(5): 378-84.
- Bulstra, S. K., Drukker, J., Kuijer, R., Buurman, W. A. and van der Linden, A. J. (1993). "Thionin staining of paraffin and plastic embedded sections of cartilage." Biotech Histochem **68**(1): 20-8.
- Burman, M. S. and Charles, J. S. (1933). "A study of the degenerative changes of the menisci of the knee joint and the clinical significance thereof." J Bone Joint Surg Am **15**(4): 835-861.
- Burr, D. B. (2004). "Anatomy and physiology of the mineralized tissues: role in the pathogenesis of osteoarthritis." Osteoarthritis Cartilage **12 Suppl A**: S20-30.
- Bussolino, F., Albin, A., Camussi, G., Presta, M., Vignetto, G., Ziche, M. and Persico, G. (1996). "Role of soluble mediators in angiogenesis." Eur J Cancer **32A**(14): 2401-12.
- Butler, M., Colombo, C., Hickman, L., O'Byrne, E., Steele, R., Steinetz, B., Quintavalla, J. and Yokoyama, N. (1983). "A new model of osteoarthritis in rabbits. III. Evaluation of anti-osteoarthritic effects of selected drugs administered intraarticularly." Arthritis Rheum **26**(11): 1380-6.
- Caparroz-Assef, S. M., Bersani-Amado, C. A., Kelmer-Bracht, A. M., Bracht, A. and Ishii-Iwamoto, E. L. (2007). "The metabolic changes caused by dexamethasone in the adjuvant-induced arthritic rat." Mol Cell Biochem **302**(1-2): 87-98.
- Carmeliet, P. (2000). "Mechanisms of angiogenesis and arteriogenesis." Nat Med **6**(4): 389-95.
- Carmeliet, P. (2003). "Angiogenesis in health and disease." Nat Med **9**(6): 653-60.
- Carrino, J. A., Blum, J., Parellada, J. A., Schweitzer, M. E. and Morrison, W. B. (2006). "MRI of bone marrow edema-like signal in the pathogenesis of subchondral cysts." Osteoarthritis Cartilage **14**(10): 1081-5.

- Cattaneo, A. (2010). "Tanezumab, a recombinant humanized mAb against nerve growth factor for the treatment of acute and chronic pain." Curr Opin Mol Ther **12**(1): 94-106.
- Cawston, T. E. and Wilson, A. J. (2006). "Understanding the role of tissue degrading enzymes and their inhibitors in development and disease." Best Pract Res Clin Rheumatol **20**(5): 983-1002.
- Charo, I. F. and Ransohoff, R. M. (2006). "The many roles of chemokines and chemokine receptors in inflammation." N Engl J Med **354**(6): 610-21.
- Charo, I. F. and Taubman, M. B. (2004). "Chemokines in the pathogenesis of vascular disease." Circ Res **95**(9): 858-66.
- Chen, Y., Willcockson, H. H. and Valtschanoff, J. G. (2008). "Increased expression of CGRP in sensory afferents of arthritic mice--effect of genetic deletion of the vanilloid receptor TRPV1." Neuropeptides **42**(5-6): 551-6.
- Chevalier, X., Giraudeau, B., Conrozier, T., Marliere, J., Kiefer, P. and Goupille, P. (2005). "Safety study of intraarticular injection of interleukin 1 receptor antagonist in patients with painful knee osteoarthritis: a multicenter study." J Rheumatol **32**(7): 1317-23.
- Chuma, H., Mizuta, H., Kudo, S., Takagi, K. and Hiraki, Y. (2004). "One day exposure to FGF-2 was sufficient for the regenerative repair of full-thickness defects of articular cartilage in rabbits." Osteoarthritis Cartilage **12**(10): 834-42.
- Cid, M. C., Cebrian, M., Font, C., Coll-Vinent, B., Hernandez-Rodriguez, J., Esparza, J., Urbano-Marquez, A. and Grau, J. M. (2000). "Cell adhesion molecules in the development of inflammatory infiltrates in giant cell arteritis: inflammation-induced angiogenesis as the preferential site of leukocyte-endothelial cell interactions." Arthritis Rheum **43**(1): 184-94.
- Clark, A. G., Jordan, J. M., Vilim, V., Renner, J. B., Dragomir, A. D., Luta, G. and Kraus, V. B. (1999). "Serum cartilage oligomeric matrix protein reflects osteoarthritis presence and severity: the Johnston County Osteoarthritis Project." Arthritis Rheum **42**(11): 2356-64.
- Clark, J. M. (1990). "The structure of vascular channels in the subchondral plate." J Anat **171**: 105-15.
- Clavel, G., Bessis, N. and Boissier, M. C. (2003). "Recent data on the role for angiogenesis in rheumatoid arthritis." Joint Bone Spine **70**(5): 321-6.
- Coggeshall, R. E., Hong, K. A., Langford, L. A., Schaible, H. G. and Schmidt, R. F. (1983). "Discharge characteristics of fine medial articular afferents at rest and during passive movements of inflamed knee joints." Brain Res **272**(1): 185-8.
- Collier, S. and Ghosh, P. (1995). "Effects of transforming growth factor beta on proteoglycan synthesis by cell and explant cultures derived from the knee joint meniscus." Osteoarthritis Cartilage **3**(2): 127-38.
- Conaghan, P. G., Dickson, J. and Grant, R. L. (2008). "Care and management of osteoarthritis in adults: summary of NICE guidance." Bmj **336**(7642): 502-3.
- Conaghan, P. G., Felson, D., Gold, G., Lohmander, S., Totterman, S. and Altman, R. (2006). "MRI and non-cartilaginous structures in knee osteoarthritis." Osteoarthritis Cartilage **14 Suppl A**: A87-94.

- Conaghan, P. G. and Felson, D. T. (2004). "Structural associations of osteoarthritis pain: lessons from magnetic resonance imaging." Novartis Found Symp **260**: 191-201; discussion 201-5, 277-9.
- Coons, A. H. and Kaplan, M. H. (1950). "Localization of antigen in tissue cells; improvements in a method for the detection of antigen by means of fluorescent antibody." J Exp Med **91**(1): 1-13.
- Cooper, A. C., Karp, R. M., Clark, E. J., Taghizadeh, N. R., Hoyt, J. G., Labenski, M. T., Murray, M. J., Hannig, G., Westlin, W. F. and Thompson, C. D. (2006). "A novel methionine aminopeptidase-2 inhibitor, PPI-2458, inhibits non-Hodgkin's lymphoma cell proliferation in vitro and in vivo." Clin Cancer Res **12**(8): 2583-90.
- Copenhaver W, K. D., Wood RL (1978). The Connective tissues: Cartilage and Bone. Philadelphia, Williams and Wilkins.
- Costa, C., Incio, J. and Soares, R. (2007). "Angiogenesis and chronic inflammation: cause or consequence?" Angiogenesis **10**(3): 149-66.
- Coussens, L. M. and Werb, Z. (2002). "Inflammation and cancer." Nature **420**(6917): 860-7.
- Cozzolino, F., Torcia, M., Lucibello, M., Morbidelli, L., Ziche, M., Platt, J., Fabiani, S., Brett, J. and Stern, D. (1993). "Interferon-alpha and interleukin 2 synergistically enhance basic fibroblast growth factor synthesis and induce release, promoting endothelial cell growth." J Clin Invest **91**(6): 2504-12.
- Creamer, P. (1999). "Intra-articular corticosteroid treatment in osteoarthritis." Curr Opin Rheumatol **11**(5): 417-21.
- Creamer, P. (2000). "Osteoarthritis pain and its treatment." Curr Opin Rheumatol **12**(5): 450-5.
- Cushnaghan, J. and Dieppe, P. (1991). "Study of 500 patients with limb joint osteoarthritis. I. Analysis by age, sex, and distribution of symptomatic joint sites." Ann Rheum Dis **50**(1): 8-13.
- Cuzzocrea, S., Mazzon, E., Paola, R. D., Genovese, T., Muia, C., Caputi, A. P. and Salvemini, D. (2005). "Effects of combination M40403 and dexamethasone therapy on joint disease in a rat model of collagen-induced arthritis." Arthritis Rheum **52**(6): 1929-40.
- Dallegri, F. and Ottonello, L. (1997). "Tissue injury in neutrophilic inflammation." Inflamm Res **46**(10): 382-91.
- Danneman, P. J., Stein, S. and Walshaw, S. O. (1997). "Humane and practical implications of using carbon dioxide mixed with oxygen for anesthesia or euthanasia of rats." Lab Anim Sci **47**(4): 376-85.
- Danzig, L., Resnick, D., Gonsalves, M. and Akeson, W. H. (1983). "Blood supply to the normal and abnormal menisci of the human knee." Clin Orthop Relat Res(172): 271-6.
- Daouti, S., Latario, B., Nagulapalli, S., Buxton, F., Uziel-Fusi, S., Chirn, G. W., Bodian, D., Song, C., Labow, M., Lotz, M., Quintavalla, J. and Kumar, C. (2005). "Development of comprehensive functional genomic screens to identify novel mediators of osteoarthritis." Osteoarthritis Cartilage **13**(6): 508-18.

- Davidson, R. K., Waters, J. G., Kevorkian, L., Darrah, C., Cooper, A., Donell, S. T. and Clark, I. M. (2006). "Expression profiling of metalloproteinases and their inhibitors in synovium and cartilage." *Arthritis Res Ther* **8**(4): R124.
- Day, B., Mackenzie, W. G., Shim, S. S. and Leung, G. (1985). "The vascular and nerve supply of the human meniscus." *Arthroscopy* **1**(1): 58-62.
- de Visser, K. E., Eichten, A. and Coussens, L. M. (2006). "Paradoxical roles of the immune system during cancer development." *Nat Rev Cancer* **6**(1): 24-37.
- Dell'accio, F., De Bari, C., Eltawil, N. M., Vanhummelen, P. and Pitzalis, C. (2008). "Identification of the molecular response of articular cartilage to injury, by microarray screening: Wnt-16 expression and signaling after injury and in osteoarthritis." *Arthritis Rheum* **58**(5): 1410-21.
- Dickenson, A. H. (2002). "Gate control theory of pain stands the test of time." *Br J Anaesth* **88**(6): 755-7.
- Dieppe, P. A. and Lohmander, L. S. (2005). "Pathogenesis and management of pain in osteoarthritis." *Lancet* **365**(9463): 965-73.
- Dijkstra, C. D., Dopp, E. A., Joling, P. and Kraal, G. (1985). "The heterogeneity of mononuclear phagocytes in lymphoid organs: distinct macrophage subpopulations in the rat recognized by monoclonal antibodies ED1, ED2 and ED3." *Immunology* **54**(3): 589-99.
- Ding, C. (2002). "Do NSAIDs affect the progression of osteoarthritis?" *Inflammation* **26**(3): 139-42.
- Ding, C., Cicuttini, F. and Jones, G. (2007). "Tibial subchondral bone size and knee cartilage defects: relevance to knee osteoarthritis." *Osteoarthritis Cartilage* **15**(5): 479-86.
- Dinser, R. (2008). "Animal models for arthritis." *Best Pract Res Clin Rheumatol* **22**(2): 253-67.
- Dixon, T., Shaw, M., Ebrahim, S. and Dieppe, P. (2004). "Trends in hip and knee joint replacement: socioeconomic inequalities and projections of need." *Ann Rheum Dis* **63**(7): 825-30.
- Doherty, M., Watt, I. and Dieppe, P. (1983). "Influence of primary generalised osteoarthritis on development of secondary osteoarthritis." *Lancet* **2**(8340): 8-11.
- Dougados, M., Ayrat, X., Listrat, V., Gueguen, A., Bahuaud, J., Beaufils, P., Beguin, J. A., Bonvarlet, J. P., Boyer, T., Coudane, H. and et al. (1994). "The SFA system for assessing articular cartilage lesions at arthroscopy of the knee." *Arthroscopy* **10**(1): 69-77.
- Driban, J. B., Sitler, M. R., Barbe, M. F. and Balasubramanian, E. (2010). "Is osteoarthritis a heterogeneous disease that can be stratified into subsets?" *Clin Rheumatol* **29**(2): 123-31.
- Dye, S. F., Vaupel, G. L. and Dye, C. C. (1998). "Conscious neurosensory mapping of the internal structures of the human knee without intraarticular anesthesia." *Am J Sports Med* **26**(6): 773-7.
- Eger, E. I., 2nd (1984). "The pharmacology of isoflurane." *Br J Anaesth* **56 Suppl 1**: 71S-99S.
- El-Gabalawy, H. (2005). "Common denominators of inflammatory joint diseases." *J Rheumatol Suppl* **72**: 3-6.
- Englund, M. (2009). "The role of the meniscus in osteoarthritis genesis." *Med Clin North Am* **93**(1): 37-43,

- Enomoto, H., Inoki, I., Komiya, K., Shiomi, T., Ikeda, E., Obata, K., Matsumoto, H., Toyama, Y. and Okada, Y. (2003). "Vascular endothelial growth factor isoforms and their receptors are expressed in human osteoarthritic cartilage." Am J Pathol **162**(1): 171-81.
- Eustace, S., Keogh, C., Blake, M., Ward, R. J., Oder, P. D. and Dimasi, M. (2001). "MR imaging of bone oedema: mechanisms and interpretation." Clin Radiol **56**(1): 4-12.
- Farahat, M. N., Yanni, G., Poston, R. and Panayi, G. S. (1993). "Cytokine expression in synovial membranes of patients with rheumatoid arthritis and osteoarthritis." Ann Rheum Dis **52**(12): 870-5.
- Feeley, B. T., Gallo, R. A., Sherman, S. and Williams, R. J. (2010). "Management of osteoarthritis of the knee in the active patient." J Am Acad Orthop Surg **18**(7): 406-16.
- Felson, D. T. (1988). "Epidemiology of hip and knee osteoarthritis." Epidemiol Rev **10**: 1-28.
- Felson, D. T. (1990). "The epidemiology of knee osteoarthritis: results from the Framingham Osteoarthritis Study." Semin Arthritis Rheum **20**(3 Suppl 1): 42-50.
- Felson, D. T. (2005). "The sources of pain in knee osteoarthritis." Curr Opin Rheumatol **17**(5): 624-8.
- Felson, D. T., Chaisson, C. E., Hill, C. L., Totterman, S. M., Gale, M. E., Skinner, K. M., Kazis, L. and Gale, D. R. (2001). "The association of bone marrow lesions with pain in knee osteoarthritis." Ann Intern Med **134**(7): 541-9.
- Fenwick, S. A., Gregg, P. J. and Rooney, P. (1999). "Osteoarthritic cartilage loses its ability to remain avascular." Osteoarthritis Cartilage **7**(5): 441-52.
- Fernandez-Madrid, F., Karvonen, R. L., Teitge, R. A., Miller, P. R., An, T. and Negendank, W. G. (1995). "Synovial thickening detected by MR imaging in osteoarthritis of the knee confirmed by biopsy as synovitis." Magn Reson Imaging **13**(2): 177-83.
- Fernihough, J., Gentry, C., Malcangio, M., Fox, A., Rediske, J., Pellas, T., Kidd, B., Bevan, S. and Winter, J. (2004). "Pain related behaviour in two models of osteoarthritis in the rat knee." Pain **112**(1-2): 83-93.
- Fiedler, U., Reiss, Y., Scharpfenecker, M., Grunow, V., Koidl, S., Thurston, G., Gale, N. W., Witznath, M., Rosseau, S., Suttorp, N., Sobke, A., Herrmann, M., Preissner, K. T., Vajkoczy, P. and Augustin, H. G. (2006). "Angiopoietin-2 sensitizes endothelial cells to TNF-alpha and has a crucial role in the induction of inflammation." Nat Med **12**(2): 235-9.
- Fioravanti, A., Fabbri, M., Cerase, A. and Galeazzi, M. (2009). "Treatment of erosive osteoarthritis of the hands by intra-articular infliximab injections: a pilot study." Rheumatol Int **29**(8): 961-5.
- Fitzcharles, M. A., Lussier, D. and Shir, Y. (2010). "Management of chronic arthritis pain in the elderly." Drugs Aging **27**(6): 471-90.
- Folkman, J. and Ingber, D. E. (1987). "Angiostatic steroids. Method of discovery and mechanism of action." Ann Surg **206**(3): 374-83.

- Folkman, J., Szabo, S., Stovroff, M., McNeil, P., Li, W. and Shing, Y. (1991). "Duodenal ulcer. Discovery of a new mechanism and development of angiogenic therapy that accelerates healing." Ann Surg **214**(4): 414-25; discussion 426-7.
- Form, D. M. and Auerbach, R. (1983). "PGE2 and angiogenesis." Proc Soc Exp Biol Med **172**(2): 214-8.
- Forsythe, J. A., Jiang, B. H., Iyer, N. V., Agani, F., Leung, S. W., Koos, R. D. and Semenza, G. L. (1996). "Activation of vascular endothelial growth factor gene transcription by hypoxia-inducible factor 1." Mol Cell Biol **16**(9): 4604-13.
- Franses, R. E., McWilliams, D. F., Mapp, P. I. and Walsh, D. A. (2010). "Osteochondral angiogenesis and increased protease inhibitor expression in OA." Osteoarthritis Cartilage **18**(4): 563-71.
- Fukuta, S., Kuge, A. and Korai, F. (2009). "Clinical significance of meniscal abnormalities on magnetic resonance imaging in an older population." Knee **16**(3): 187-90.
- Fukuta, S., Masaki, K. and Korai, F. (2002). "Prevalence of abnormal findings in magnetic resonance images of asymptomatic knees." J Orthop Sci **7**(3): 287-91.
- Gale, D. R., Chaisson, C. E., Totterman, S. M., Schwartz, R. K., Gale, M. E. and Felson, D. (1999). "Meniscal subluxation: association with osteoarthritis and joint space narrowing." Osteoarthritis Cartilage **7**(6): 526-32.
- Garrett, N. E., Mapp, P. I., Cruwys, S. C., Kidd, B. L. and Blake, D. R. (1992). "Role of substance P in inflammatory arthritis." Ann Rheum Dis **51**(8): 1014-8.
- Gerber, H. P., Vu, T. H., Ryan, A. M., Kowalski, J., Werb, Z. and Ferrara, N. (1999). "VEGF couples hypertrophic cartilage remodeling, ossification and angiogenesis during endochondral bone formation." Nat Med **5**(6): 623-8.
- Ghosh, A. K., Hirasawa, N., Lee, Y. S., Kim, Y. S., Shin, K. H., Ryu, N. and Ohuchi, K. (2002). "Inhibition by acharan sulphate of angiogenesis in experimental inflammation models." Br J Pharmacol **137**(4): 441-8.
- Ghosh, A. K., Hirasawa, N., Niki, H. and Ohuchi, K. (2000). "Cyclooxygenase-2-mediated angiogenesis in carrageenin-induced granulation tissue in rats." J Pharmacol Exp Ther **295**(2): 802-9.
- Goldring, M. B. (2001). "Anticytokine therapy for osteoarthritis." Expert Opin Biol Ther **1**(5): 817-29.
- Goldring, M. B. and Goldring, S. R. (2007). "Osteoarthritis." J Cell Physiol **213**(3): 626-34.
- Goldring, M. B. and Goldring, S. R. (2010). "Articular cartilage and subchondral bone in the pathogenesis of osteoarthritis." Ann N Y Acad Sci **1192**(1): 230-7.
- Goldring, S. R. and Goldring, M. B. (2004). "The role of cytokines in cartilage matrix degeneration in osteoarthritis." Clin Orthop Relat Res(427 Suppl): S27-36.
- Gotoh, H., Matsumoto, Y. and Imamura, K. (2004). "General anesthesia of infant mice by isoflurane inhalation for medium-duration surgery." Exp Anim **53**(1): 63-5.
- Goupille, P., Mulleman, D. and Chevalier, X. (2007). "Is interleukin-1 a good target for therapeutic intervention in intervertebral disc degeneration: lessons from the osteoarthritic experience." Arthritis Res Ther **9**(6): 110.

- Grainger, A. J., Rhodes, L. A., Keenan, A. M., Emery, P. and Conaghan, P. G. (2007). "Quantifying perimeniscal synovitis and its relationship to meniscal pathology in osteoarthritis of the knee." Eur Radiol **17**(1): 119-24.
- Gray, J. C. (1999). "Neural and vascular anatomy of the menisci of the human knee." J Orthop Sports Phys Ther **29**(1): 23-30.
- Griffioen, A. W. and Molema, G. (2000). "Angiogenesis: potentials for pharmacologic intervention in the treatment of cancer, cardiovascular diseases, and chronic inflammation." Pharmacol Rev **52**(2): 237-68.
- Griffith, E. C., Su, Z., Turk, B. E., Chen, S., Chang, Y. H., Wu, Z., Biemann, K. and Liu, J. O. (1997). "Methionine aminopeptidase (type 2) is the common target for angiogenesis inhibitors AGM-1470 and ovalicin." Chem Biol **4**(6): 461-71.
- Grigg, P., Schaible, H. G. and Schmidt, R. F. (1986). "Mechanical sensitivity of group III and IV afferents from posterior articular nerve in normal and inflamed cat knee." J Neurophysiol **55**(4): 635-43.
- Gronblad, M., Liesi, P., Korkkala, O., Karaharju, E. and Polak, J. (1984). "Innervation of human bone periosteum by peptidergic nerves." Anat Rec **209**(3): 297-9.
- Grunke, M. and Schulze-Koops, H. (2006). "Successful treatment of inflammatory knee osteoarthritis with tumour necrosis factor blockade." Ann Rheum Dis **65**(4): 555-6.
- Gu, X. H., Terenghi, G., Kangesu, T., Navsaria, H. A., Springall, D. R., Leigh, I. M., Green, C. J. and Polak, J. M. (1995). "Regeneration pattern of blood vessels and nerves in cultured keratinocyte grafts assessed by confocal laser scanning microscopy." Br J Dermatol **132**(3): 376-83.
- Gualandris, A., Urbinati, C., Rusnati, M., Ziche, M. and Presta, M. (1994). "Interaction of high-molecular-weight basic fibroblast growth factor with endothelium: biological activity and intracellular fate of human recombinant M(r) 24,000 bFGF." J Cell Physiol **161**(1): 149-59.
- Guesdon, J. L., Ternynck, T. and Avrameas, S. (1979). "The use of avidin-biotin interaction in immunoenzymatic techniques." J Histochem Cytochem **27**(8): 1131-9.
- Haegerstrand, A., Dalsgaard, C. J., Jonzon, B., Larsson, O. and Nilsson, J. (1990). "Calcitonin gene-related peptide stimulates proliferation of human endothelial cells." Proc Natl Acad Sci U S A **87**(9): 3299-303.
- Hamada, T., Arima, N., Shindo, M., Sugama, K. and Sasaguri, Y. (2000). "Suppression of adjuvant arthritis of rats by a novel matrix metalloproteinase-inhibitor." Br J Pharmacol **131**(8): 1513-20.
- Hanesch, U., Pawlak, M. and McDougall, J. J. (2003). "Gabapentin reduces the mechanosensitivity of fine afferent nerve fibres in normal and inflamed rat knee joints." Pain **104**(1-2): 363-6.
- Hannan, M. T., Felson, D. T. and Pincus, T. (2000). "Analysis of the discordance between radiographic changes and knee pain in osteoarthritis of the knee." J Rheumatol **27**(6): 1513-7.
- Hannig, G., Bernier, S. G., Hoyt, J. G., Doyle, B., Clark, E., Karp, R. M., Lorusso, J. and Westlin, W. F. (2007). "Suppression of inflammation and structural damage in experimental arthritis through molecular targeted therapy with PPI-2458." Arthritis Rheum **56**(3): 850-60.

- Hannig, G., Lazarus, D. D., Bernier, S. G., Karp, R. M., Lorusso, J., Qiu, D., Labenski, M. T., Wakefield, J. D., Thompson, C. D. and Westlin, W. F. (2006). "Inhibition of melanoma tumor growth by a pharmacological inhibitor of MetAP-2, PPI-2458." Int J Oncol **28**(4): 955-63.
- Hashimoto, S., Creighton-Achermann, L., Takahashi, K., Amiel, D., Coutts, R. D. and Lotz, M. (2002). "Development and regulation of osteophyte formation during experimental osteoarthritis." Osteoarthritis Cartilage **10**(3): 180-7.
- Hawighorst, H., Libicher, M., Knopp, M. V., Moehler, T., Kauffmann, G. W. and Kaick, G. (1999). "Evaluation of angiogenesis and perfusion of bone marrow lesions: role of semiquantitative and quantitative dynamic MRI." J Magn Reson Imaging **10**(3): 286-94.
- Hayami, T., Pickarski, M., Zhuo, Y., Wesolowski, G. A., Rodan, G. A. and Duong le, T. (2006). "Characterization of articular cartilage and subchondral bone changes in the rat anterior cruciate ligament transection and meniscectomized models of osteoarthritis." Bone **38**(2): 234-43.
- Haywood, L., McWilliams, D. F., Pearson, C. I., Gill, S. E., Ganesan, A., Wilson, D. and Walsh, D. A. (2003). "Inflammation and angiogenesis in osteoarthritis." Arthritis Rheum **48**(8): 2173-7.
- Haywood, L. and Walsh, D. A. (2001). "Vasculature of the normal and arthritic synovial joint." Histol Histopathol **16**(1): 277-84.
- Hedbom, E. and Hauselmann, H. J. (2002). "Molecular aspects of pathogenesis in osteoarthritis: the role of inflammation." Cell Mol Life Sci **59**(1): 45-53.
- Heppelmann, B. (1997). "Anatomy and histology of joint innervation." J Peripher Nerv Syst **2**(1): 5-16.
- Herwig, J., Egner, E. and Buddecke, E. (1984). "Chemical changes of human knee joint menisci in various stages of degeneration." Ann Rheum Dis **43**(4): 635-40.
- Hewett, T. A., Kovacs, M. S., Artwohl, J. E. and Bennett, B. T. (1993). "A comparison of euthanasia methods in rats, using carbon dioxide in prefilled and fixed flow rate filled chambers." Lab Anim Sci **43**(6): 579-82.
- Hill, C. L., Gale, D. G., Chaisson, C. E., Skinner, K., Kazis, L., Gale, M. E. and Felson, D. T. (2001). "Knee effusions, popliteal cysts, and synovial thickening: association with knee pain in osteoarthritis." J Rheumatol **28**(6): 1330-7.
- Hill, C. L., Hunter, D. J., Niu, J., Clancy, M., Guermazi, A., Genant, H., Gale, D., Grainger, A., Conaghan, P. and Felson, D. T. (2007). "Synovitis detected on magnetic resonance imaging and its relation to pain and cartilage loss in knee osteoarthritis." Ann Rheum Dis **66**(12): 1599-603.
- Hirasawa, Y., Okajima, S., Ohta, M. and Tokioka, T. (2000). "Nerve distribution to the human knee joint: anatomical and immunohistochemical study." Int Orthop **24**(1): 1-4.
- Hirschi, K. K. and D'Amore, P. A. (1997). "Control of angiogenesis by the pericyte: molecular mechanisms and significance." Exs **79**: 419-28.
- Hori, Y., Hu, D. E., Yasui, K., Smither, R. L., Gresham, G. A. and Fan, T. P. (1996). "Differential effects of angiostatic steroids and dexamethasone on angiogenesis and cytokine levels in rat sponge implants." Br J Pharmacol **118**(7): 1584-91.

- Horner, A., Bord, S., Kelsall, A. W., Coleman, N. and Compston, J. E. (2001). "Tie2 ligands angiopoietin-1 and angiopoietin-2 are coexpressed with vascular endothelial cell growth factor in growing human bone." Bone **28**(1): 65-71.
- Hsu, S. M., Raine, L. and Fanger, H. (1981). "Use of avidin-biotin-peroxidase complex (ABC) in immunoperoxidase techniques: a comparison between ABC and unlabeled antibody (PAP) procedures." J Histochem Cytochem **29**(4): 577-80.
- Hukkanen, M., Konttinen, Y. T., Rees, R. G., Santavirta, S., Terenghi, G. and Polak, J. M. (1992). "Distribution of nerve endings and sensory neuropeptides in rat synovium, meniscus and bone." Int J Tissue React **14**(1): 1-10.
- Hunter, D. J., McDougall, J. J. and Keefe, F. J. (2008). "The symptoms of osteoarthritis and the genesis of pain." Rheum Dis Clin North Am **34**(3): 623-43.
- Hunter, D. J. and Spector, T. D. (2003). "The role of bone metabolism in osteoarthritis." Curr Rheumatol Rep **5**(1): 15-9.
- Hunter, D. J., Zhang, Y., Niu, J., Goggins, J., Amin, S., LaValley, M. P., Guermazi, A., Genant, H., Gale, D. and Felson, D. T. (2006). "Increase in bone marrow lesions associated with cartilage loss: a longitudinal magnetic resonance imaging study of knee osteoarthritis." Arthritis Rheum **54**(5): 1529-35.
- Hunter, D. J., Zhang, Y., Niu, J., Tu, X., Amin, S., Goggins, J., Lavalley, M., Guermazi, A., Gale, D. and Felson, D. T. (2005). "Structural factors associated with malalignment in knee osteoarthritis: the Boston osteoarthritis knee study." J Rheumatol **32**(11): 2192-9.
- Hunter, D. J., Zhang, Y. Q., Niu, J. B., Tu, X., Amin, S., Clancy, M., Guermazi, A., Grigorian, M., Gale, D. and Felson, D. T. (2006). "The association of meniscal pathologic changes with cartilage loss in symptomatic knee osteoarthritis." Arthritis Rheum **54**(3): 795-801.
- Huskinson, E. C., Berry, H., Gishen, P., Jubb, R. W. and Whitehead, J. (1995). "Effects of antiinflammatory drugs on the progression of osteoarthritis of the knee. LINK Study Group. Longitudinal Investigation of Nonsteroidal Antiinflammatory Drugs in Knee Osteoarthritis." J Rheumatol **22**(10): 1941-6.
- Imhof, H., Breitenseher, M., Kainberger, F. and Trattnig, S. (1997). "Degenerative joint disease: cartilage or vascular disease?" Skeletal Radiol **26**(7): 398-403.
- Ingber, D., Fujita, T., Kishimoto, S., Sudo, K., Kanamaru, T., Brem, H. and Folkman, J. (1990). "Synthetic analogues of fumagillin that inhibit angiogenesis and suppress tumour growth." Nature **348**(6301): 555-7.
- Ishihara G, K. T., Saito Y, Ishiguro N (2009). "Roles of metalloproteinase -3 and aggrecanase 1 and 2 in aggrecan cleavage during human meniscus degeneration." Orthopedic Reviews **1**(2): e14.
- Issa, S. N. and Sharma, L. (2006). "Epidemiology of osteoarthritis: an update." Curr Rheumatol Rep **8**(1): 7-15.

- Jackson, J. R., Seed, M. P., Kircher, C. H., Willoughby, D. A. and Winkler, J. D. (1997). "The codependence of angiogenesis and chronic inflammation." Faseb J **11**(6): 457-65.
- Jackson, R. W. and Rouse, D. W. (1982). "The results of partial arthroscopic meniscectomy in patients over 40 years of age." J Bone Joint Surg Br **64**(4): 481-5.
- Janusz, M. J., Bendele, A. M., Brown, K. K., Taiwo, Y. O., Hsieh, L. and Heitmeyer, S. A. (2002). "Induction of osteoarthritis in the rat by surgical tear of the meniscus: Inhibition of joint damage by a matrix metalloproteinase inhibitor." Osteoarthritis Cartilage **10**(10): 785-91.
- Jimi, E. and Ghosh, S. (2005). "Role of nuclear factor-kappaB in the immune system and bone." Immunol Rev **208**: 80-7.
- Julius, D. and Basbaum, A. I. (2001). "Molecular mechanisms of nociception." Nature **413**(6852): 203-10.
- Kahler, C. M., Sitte, B. A., Reinisch, N. and Wiedermann, C. J. (1993). "Stimulation of the chemotactic migration of human fibroblasts by substance P." Eur J Pharmacol **249**(3): 281-6.
- Kamekura, S., Hoshi, K., Shimoaka, T., Chung, U., Chikuda, H., Yamada, T., Uchida, M., Ogata, N., Seichi, A., Nakamura, K. and Kawaguchi, H. (2005). "Osteoarthritis development in novel experimental mouse models induced by knee joint instability." Osteoarthritis Cartilage **13**(7): 632-41.
- Kapadia, R. D., Badger, A. M., Levin, J. M., Swift, B., Bhattacharyya, A., Dodds, R. A., Coatney, R. W. and Lark, M. W. (2000). "Meniscal ossification in spontaneous osteoarthritis in the guinea-pig." Osteoarthritis Cartilage **8**(5): 374-7.
- Kasama, T., Isozaki, T., Odai, T., Matsunawa, M., Wakabayashi, K., Takeuchi, H. T., Matsukura, S., Adachi, M., Tezuka, M. and Kobayashi, K. (2007). "Expression of angiopoietin-1 in osteoblasts and its inhibition by tumor necrosis factor-alpha and interferon-gamma." Transl Res **149**(5): 265-73.
- Kashiwagi, M., Tortorella, M., Nagase, H. and Brew, K. (2001). "TIMP-3 is a potent inhibitor of aggrecanase 1 (ADAM-TS4) and aggrecanase 2 (ADAM-TS5)." J Biol Chem **276**(16): 12501-4.
- Kaupilla, L. I. (1995). "Ingrowth of blood vessels in disc degeneration. Angiographic and histological studies of cadaveric spines." J Bone Joint Surg Am **77**(1): 26-31.
- Kellgren, J. H. and Lawrence, J. S. (1957). "Radiological assessment of osteo-arthritis." Ann Rheum Dis **16**(4): 494-502.
- Kennedy, A., Ng, C. T., Biniecka, M., Saber, T., Taylor, C., O'Sullivan, J., Veale, D. J. and Fearon, U. (2010). "Angiogenesis and blood vessel stability in inflammatory arthritis." Arthritis Rheum **62**(3): 711-21.
- Kennedy, J. C., Alexander, I. J. and Hayes, K. C. (1982). "Nerve supply of the human knee and its functional importance." Am J Sports Med **10**(6): 329-35.
- Khan, I. M., Palmer, E. A. and Archer, C. W. (2010). "Fibroblast growth factor-2 induced chondrocyte cluster formation in experimentally wounded articular cartilage is blocked by soluble Jagged-1." Osteoarthritis Cartilage **18**(2): 208-19.

- Kidd, B. L., Cruwys, S., Mapp, P. I. and Blake, D. R. (1992). "Role of the sympathetic nervous system in chronic joint pain and inflammation." *Ann Rheum Dis* **51**(11): 1188-91.
- Kidd, B. L., Mapp, P. I., Blake, D. R., Gibson, S. J. and Polak, J. M. (1990). "Neurogenic influences in arthritis." *Ann Rheum Dis* **49**(8): 649-52.
- King, D. F. and King, L. A. (1986). "A brief historical note on staining by hematoxylin and eosin." *Am J Dermatopathol* **8**(2): 168.
- Klagsbrun, M. and Moses, M. A. (1999). "Molecular angiogenesis." *Chem Biol* **6**(8): R217-24.
- Klareskog, L., Catrina, A. I. and Paget, S. (2009). "Rheumatoid arthritis." *Lancet*.
- Kobayashi, K., Imaizumi, R., Sumichika, H., Tanaka, H., Goda, M., Fukunari, A. and Komatsu, H. (2003). "Sodium iodoacetate-induced experimental osteoarthritis and associated pain model in rats." *J Vet Med Sci* **65**(11): 1195-9.
- Kontinen, Y., Imai, S. and Suda, A. (1996). "Neuropeptides and the puzzle of bone remodeling. State of the art." *Acta Orthop Scand* **67**(6): 632-9.
- Kontinen, Y. T., Tiainen, V. M., Gomez-Barrena, E., Hukkanen, M. and Salo, J. (2006). "Innervation of the joint and role of neuropeptides." *Ann N Y Acad Sci* **1069**: 149-54.
- Ku, G., Faust, T., Lauffer, L. L., Livingston, D. J. and Harding, M. W. (1996). "Interleukin-1 beta converting enzyme inhibition blocks progression of type II collagen-induced arthritis in mice." *Cytokine* **8**(5): 377-86.
- Kusaka, M., Sudo, K., Matsutani, E., Kozai, Y., Marui, S., Fujita, T., Ingber, D. and Folkman, J. (1994). "Cytostatic inhibition of endothelial cell growth by the angiogenesis inhibitor TNP-470 (AGM-1470)." *Br J Cancer* **69**(2): 212-6.
- Kwak, H. J., So, J. N., Lee, S. J., Kim, I. and Koh, G. Y. (1999). "Angiopoietin-1 is an apoptosis survival factor for endothelial cells." *FEBS Lett* **448**(2-3): 249-53.
- Lam, F. Y. and Ferrell, W. R. (1989). "Inhibition of carrageenan induced inflammation in the rat knee joint by substance P antagonist." *Ann Rheum Dis* **48**(11): 928-32.
- Lam, F. Y. and Ferrell, W. R. (1991). "Neurogenic component of different models of acute inflammation in the rat knee joint." *Ann Rheum Dis* **50**(11): 747-51.
- Lanzetta, A., Corradini, C., Verdoia, C., Miani, A., Castano, S. and Castano, P. (2004). "The nervous structures of anterior cruciate ligament of human knee, healthy and lesioned, studied with confocal scanning laser microscopy." *Ital J Anat Embryol* **109**(3): 167-76.
- Lazarus, D. D., Doyle, E. G., Bernier, S. G., Rogers, A. B., Labenski, M. T., Wakefield, J. D., Karp, R. M., Clark, E. J., Lorusso, J., Hoyt, J. G., Thompson, C. D., Hannig, G. and Westlin, W. F. (2008). "An inhibitor of methionine aminopeptidase type-2, PPI-2458, ameliorates the pathophysiological disease processes of rheumatoid arthritis." *Inflamm Res* **57**(1): 18-27.
- Ledingham, J., Regan, M., Jones, A. and Doherty, M. (1995). "Factors affecting radiographic progression of knee osteoarthritis." *Ann Rheum Dis* **54**(1): 53-8.

- Lee, E. W., Grant, D. S., Movafagh, S. and Zukowska, Z. (2003). "Impaired angiogenesis in neuropeptide Y (NPY)-Y2 receptor knockout mice." Peptides **24**(1): 99-106.
- Liekens, S., De Clercq, E. and Neyts, J. (2001). "Angiogenesis: regulators and clinical applications." Biochem Pharmacol **61**(3): 253-70.
- Lisignoli, G., Toneguzzi, S., Pozzi, C., Piacentini, A., Riccio, M., Ferruzzi, A., Gualtieri, G. and Facchini, A. (1999). "Proinflammatory cytokines and chemokine production and expression by human osteoblasts isolated from patients with rheumatoid arthritis and osteoarthritis." J Rheumatol **26**(4): 791-9.
- Little, C. B., Ghosh, P. and Bellenger, C. R. (1996). "Topographic variation in biglycan and decorin synthesis by articular cartilage in the early stages of osteoarthritis: an experimental study in sheep." J Orthop Res **14**(3): 433-44.
- Loeser, R. F. (2006). "Molecular mechanisms of cartilage destruction: mechanics, inflammatory mediators, and aging collide." Arthritis Rheum **54**(5): 1357-60.
- Lorenz, H. and Richter, W. (2006). "Osteoarthritis: cellular and molecular changes in degenerating cartilage." Prog Histochem Cytochem **40**(3): 135-63.
- Lowther, W. T. and Matthews, B. W. (2000). "Structure and function of the methionine aminopeptidases." Biochim Biophys Acta **1477**(1-2): 157-67.
- Ma, Q. P. and Woolf, C. J. (1997). "The progressive tactile hyperalgesia induced by peripheral inflammation is nerve growth factor dependent." Neuroreport **8**(4): 807-10.
- Madhok, R., Wijelath, E., Smith, J., Watson, J., Sturrock, R. D. and Capell, H. A. (1991). "Is the beneficial effect of sulfasalazine due to inhibition of synovial neovascularization?" J Rheumatol **18**(2): 199-202.
- Magnano, M. D., Chakravarty, E. F., Broudy, C., Chung, L., Kelman, A., Hillygus, J. and Genovese, M. C. (2007). "A pilot study of tumor necrosis factor inhibition in erosive/inflammatory osteoarthritis of the hands." J Rheumatol **34**(6): 1323-7.
- Male, D., Rahman, J., Linke, A., Zhao, W. and Hickey, W. (1995). "An interferon-inducible molecule on brain endothelium which controls lymphocyte adhesion mediated by integrins." Immunology **84**(3): 453-60.
- Malemud, C. J. (2007). "Growth hormone, VEGF and FGF: involvement in rheumatoid arthritis." Clin Chim Acta **375**(1-2): 10-9.
- Manabe, N., Oda, H., Nakamura, K., Kuga, Y., Uchida, S. and Kawaguchi, H. (1999). "Involvement of fibroblast growth factor-2 in joint destruction of rheumatoid arthritis patients." Rheumatology (Oxford) **38**(8): 714-20.
- Mapp, P. I. (1995). "Innervation of the synovium." Ann Rheum Dis **54**(5): 398-403.
- Mapp, P. I., Avery, P. S., McWilliams, D. F., Bowyer, J., Day, C., Moores, S., Webster, R. and Walsh, D. A. (2008). "Angiogenesis in two animal models of osteoarthritis." Osteoarthritis Cartilage **16**(1): 61-9.

- Mapp, P. I., Kerslake, S., Brain, S. D., Blake, D. R. and Cambridge, H. (1996). "The effect of intra-articular capsaicin on nerve fibres within the synovium of the rat knee joint." J Chem Neuroanat **10**(1): 11-8.
- Mapp, P. I., Walsh, D. A., Bowyer, J. and Maciewicz, R. A. (2010). "Effects of a metalloproteinase inhibitor on osteochondral angiogenesis, chondropathy and pain behavior in a rat model of osteoarthritis." Osteoarthritis Cartilage **18**(4): 593-600.
- Maroudas, A. I. (1976). "Balance between swelling pressure and collagen tension in normal and degenerate cartilage." Nature **260**(5554): 808-9.
- Martel-Pelletier, J. and Pelletier, J. P. (2010). "Is osteoarthritis a disease involving only cartilage or other articular tissues?" Eklemler Hastalik Cerrahisi **21**(1): 2-14.
- Mason, D. Y. and Sammons, R. (1978). "Rapid preparation of peroxidase: anti-peroxidase complexes for immunocytochemical use." J Immunol Methods **20**: 317-24.
- McCabe, C. S. (2004). "Pain mechanisms and the rheumatic diseases." Musculoskeletal Care **2**(2): 75-89.
- McColl, G. J. (2001). "Pharmacological therapies for the treatment of osteoarthritis." Med J Aust **175** **Suppl**: S108-11.
- McDevitt, C. A. and Webber, R. J. (1990). "The ultrastructure and biochemistry of meniscal cartilage." Clin Orthop Relat Res(252): 8-18.
- McDougall, J. J. (2006). "Arthritis and pain. Neurogenic origin of joint pain." Arthritis Res Ther **8**(6): 220.
- McDougall, J. J., Yeung, G., Leonard, C. A. and Bray, R. C. (2000). "A role for calcitonin gene-related peptide in rabbit knee joint ligament healing." Can J Physiol Pharmacol **78**(7): 535-40.
- McIlwraith, C. W. and Van Sickle, D. C. (1981). "Experimentally induced arthritis of the equine carpus: histologic and histochemical changes in the articular cartilage." Am J Vet Res **42**(2): 209-17.
- McInnes, I. B., Leung, B. P. and Liew, F. Y. (2000). "Cell-cell interactions in synovitis. Interactions between T lymphocytes and synovial cells." Arthritis Res **2**(5): 374-8.
- McKeehan, W. L., Wang, F. and Kan, M. (1998). "The heparan sulfate-fibroblast growth factor family: diversity of structure and function." Prog Nucleic Acid Res Mol Biol **59**: 135-76.
- Melzack, R. (1993). "Pain: past, present and future." Can J Exp Psychol **47**(4): 615-29.
- Melzack, R. and Wall, P. D. (1965). "Pain mechanisms: a new theory." Science **150**(699): 971-9.
- Messner, K. and Gao, J. (1998). "The menisci of the knee joint. Anatomical and functional characteristics, and a rationale for clinical treatment." J Anat **193** (Pt 2): 161-78.
- Michael, J. W., Schluter-Brust, K. U. and Eysel, P. (2010). "The epidemiology, etiology, diagnosis, and treatment of osteoarthritis of the knee." Dtsch Arztebl Int **107**(9): 152-62.
- Milgram, J. W. (1983). "Morphologic alterations of the subchondral bone in advanced degenerative arthritis." Clin Orthop Relat Res(173): 293-312.
- Mine, T., Kimura, M., Sakka, A. and Kawai, S. (2000). "Innervation of nociceptors in the menisci of the knee joint: an immunohistochemical study." Arch Orthop Trauma Surg **120**(3-4): 201-4.

- Miotla, J., Maciewicz, R., Kendrew, J., Feldmann, M. and Paleolog, E. (2000). "Treatment with soluble VEGF receptor reduces disease severity in murine collagen-induced arthritis." Lab Invest **80**(8): 1195-205.
- Mollenhauer, J. A. and Erdmann, S. (2002). "Introduction: molecular and biomechanical basis of osteoarthritis." Cell Mol Life Sci **59**(1): 3-4.
- Morbidelli, L., Chang, C. H., Douglas, J. G., Granger, H. J., Ledda, F. and Ziche, M. (1996). "Nitric oxide mediates mitogenic effect of VEGF on coronary venular endothelium." Am J Physiol **270**(1 Pt 2): H411-5.
- Moses, M. A., Sudhalter, J. and Langer, R. (1990). "Identification of an inhibitor of neovascularization from cartilage." Science **248**(4961): 1408-10.
- Moses, M. A., Wiederschain, D., Wu, I., Fernandez, C. A., Ghazizadeh, V., Lane, W. S., Flynn, E., Sytkowski, A., Tao, T. and Langer, R. (1999). "Troponin I is present in human cartilage and inhibits angiogenesis." Proc Natl Acad Sci U S A **96**(6): 2645-50.
- Moskowitz, R. W. and Goldberg, V. M. (1987). "Osteophyte evolution: studies in an experimental partial meniscectomy model." J Rheumatol **14 Spec No**: 116-8.
- Muir, H. (1995). "The chondrocyte, architect of cartilage. Biomechanics, structure, function and molecular biology of cartilage matrix macromolecules." Bioessays **17**(12): 1039-48.
- Murakami, M., Nguyen, L. T., Zhang, Z. W., Moodie, K. L., Carmeliet, P., Stan, R. V. and Simons, M. (2008). "The FGF system has a key role in regulating vascular integrity." J Clin Invest **118**(10): 3355-66.
- Murata, M., Yudoh, K. and Masuko, K. (2008). "The potential role of vascular endothelial growth factor (VEGF) in cartilage How the angiogenic factor could be involved in the pathogenesis of osteoarthritis?" Osteoarthritis Cartilage **16**(3): 279-86.
- Murata, M., Yudoh, K., Nakamura, H., Kato, T., Inoue, K., Chiba, J., Nishioka, K. and Masuko-Hongo, K. (2006). "Distinct signaling pathways are involved in hypoxia- and IL-1-induced VEGF expression in human articular chondrocytes." J Orthop Res **24**(7): 1544-54.
- Murdoch, C., Muthana, M. and Lewis, C. E. (2005). "Hypoxia regulates macrophage functions in inflammation." J Immunol **175**(10): 6257-63.
- Murphy, G., Knauper, V., Lee, M. H., Amour, A., Worley, J. R., Hutton, M., Atkinson, S., Rapti, M. and Williamson, R. (2003). "Role of TIMPs (tissue inhibitors of metalloproteinases) in pericellular proteolysis: the specificity is in the detail." Biochem Soc Symp(70): 65-80.
- Murphy, G. and Lee, M. H. (2005). "What are the roles of metalloproteinases in cartilage and bone damage?" Ann Rheum Dis **64 Suppl 4**: iv44-7.
- Nagashima, M., Wauke, K., Hirano, D., Ishigami, S., Aono, H., Takai, M., Sasano, M. and Yoshino, S. (2000). "Effects of combinations of anti-rheumatic drugs on the production of vascular endothelial growth factor and basic fibroblast growth factor in cultured synoviocytes and patients with rheumatoid arthritis." Rheumatology (Oxford) **39**(11): 1255-62.

- Nakane, P. K. and Pierce, G. B., Jr. (1966). "Enzyme-labeled antibodies: preparation and application for the localization of antigens." J Histochem Cytochem **14**(12): 929-31.
- Nakano, T., Dodd, C. M. and Scott, P. G. (1997). "Glycosaminoglycans and proteoglycans from different zones of the porcine knee meniscus." J Orthop Res **15**(2): 213-20.
- Nakashima, M., Eguchi, K., Aoyagi, T., Yamashita, I., Ida, H., Sakai, M., Shimada, H., Kawabe, Y., Nagataki, S., Koji, T. and et al. (1994). "Expression of basic fibroblast growth factor in synovial tissues from patients with rheumatoid arthritis: detection by immunohistological staining and in situ hybridisation." Ann Rheum Dis **53**(1): 45-50.
- Nathan, C. (2002). "Points of control in inflammation." Nature **420**(6917): 846-52.
- Neame, R. L., Carr, A. J., Muir, K. and Doherty, M. (2003). "UK community prevalence of knee chondrocalcinosis: evidence that correlation with osteoarthritis is through a shared association with osteophyte." Ann Rheum Dis **62**(6): 513-8.
- Neugebauer, V., Han, J. S., Adwanikar, H., Fu, Y. and Ji, G. (2007). "Techniques for assessing knee joint pain in arthritis." Mol Pain **3**: 8.
- Neugebauer, V., Rumenapp, P. and Schaible, H. G. (1996). "Calcitonin gene-related peptide is involved in the spinal processing of mechanosensory input from the rat's knee joint and in the generation and maintenance of hyperexcitability of dorsal horn-neurons during development of acute inflammation." Neuroscience **71**(4): 1095-109.
- Neugebauer, V., Weiretter, F. and Schaible, H. G. (1995). "Involvement of substance P and neurokinin-1 receptors in the hyperexcitability of dorsal horn neurons during development of acute arthritis in rat's knee joint." J Neurophysiol **73**(4): 1574-83.
- O'Connell, J. X. (2000). "Pathology of the synovium." Am J Clin Pathol **114**(5): 773-84.
- Oegema, T. R., Jr., Carpenter, R. J., Hofmeister, F. and Thompson, R. C., Jr. (1997). "The interaction of the zone of calcified cartilage and subchondral bone in osteoarthritis." Microsc Res Tech **37**(4): 324-32.
- Olee, T., Hashimoto, S., Quach, J. and Lotz, M. (1999). "IL-18 is produced by articular chondrocytes and induces proinflammatory and catabolic responses." J Immunol **162**(2): 1096-100.
- Orgad, U., Alroy, J., Ucci, A. and Merk, F. B. (1984). "Histochemical studies of epithelial cell glycoconjugates in atrophic, metaplastic, hyperplastic, and neoplastic canine prostate." Lab Invest **50**(3): 294-302.
- Otrock, Z. K., Mahfouz, R. A., Makarem, J. A. and Shamseddine, A. I. (2007). "Understanding the biology of angiogenesis: review of the most important molecular mechanisms." Blood Cells Mol Dis **39**(2): 212-20.
- Pacifico, F. and Leonardi, A. (2006). "NF-kappaB in solid tumors." Biochem Pharmacol **72**(9): 1142-52.
- Palosaari, K., Vuotila, J., Takalo, R., Jartti, A., Niemela, R. K., Karjalainen, A., Haaepa, M., Soini, I., Tervonen, O. and Hakala, M. (2006). "Bone oedema predicts erosive progression on wrist MRI in

- early RA--a 2-yr observational MRI and NC scintigraphy study." Rheumatology (Oxford) **45**(12): 1542-8.
- Pardo, A. and Selman, M. (2005). "MMP-1: the elder of the family." Int J Biochem Cell Biol **37**(2): 283-8.
- Peacock, D. J., Banquerigo, M. L. and Brahn, E. (1992). "Angiogenesis inhibition suppresses collagen arthritis." J Exp Med **175**(4): 1135-8.
- Peat, G., McCarney, R. and Croft, P. (2001). "Knee pain and osteoarthritis in older adults: a review of community burden and current use of primary health care." Ann Rheum Dis **60**(2): 91-7.
- Pelletier, J. P., DiBattista, J. A., Raynauld, J. P., Wilhelm, S. and Martel-Pelletier, J. (1995). "The in vivo effects of intraarticular corticosteroid injections on cartilage lesions, stromelysin, interleukin-1, and oncogene protein synthesis in experimental osteoarthritis." Lab Invest **72**(5): 578-86.
- Pelletier, J. P., Martel-Pelletier, J. and Abramson, S. B. (2001). "Osteoarthritis, an inflammatory disease: potential implication for the selection of new therapeutic targets." Arthritis Rheum **44**(6): 1237-47.
- Pelletier, J. P., McCollum, R., Cloutier, J. M. and Martel-Pelletier, J. (1995). "Synthesis of metalloproteinases and interleukin 6 (IL-6) in human osteoarthritic synovial membrane is an IL-1 mediated process." J Rheumatol Suppl **43**: 109-14.
- Pepper, M. S. (2001). "Role of the matrix metalloproteinase and plasminogen activator-plasmin systems in angiogenesis." Arterioscler Thromb Vasc Biol **21**(7): 1104-17.
- Petersson, I. F. (1996). "Occurrence of osteoarthritis of the peripheral joints in European populations." Ann Rheum Dis **55**(9): 659-61.
- Pfander, D., Cramer, T. and Swoboda, B. (2005). "Hypoxia and HIF-1alpha in osteoarthritis." Int Orthop **29**(1): 6-9.
- Pfander, D., Rahmzadeh, R. and Scheller, E. E. (1999). "Presence and distribution of collagen II, collagen I, fibronectin, and tenascin in rabbit normal and osteoarthritic cartilage." J Rheumatol **26**(2): 386-94.
- Philip, M., Rowley, D. A. and Schreiber, H. (2004). "Inflammation as a tumor promoter in cancer induction." Semin Cancer Biol **14**(6): 433-9.
- Polverini, P. J. (2002). "Angiogenesis in health and disease: insights into basic mechanisms and therapeutic opportunities." J Dent Educ **66**(8): 962-75.
- Pond, M. J. and Nuki, G. (1973). "Experimentally-induced osteoarthritis in the dog." Ann Rheum Dis **32**(4): 387-8.
- Poole, C. A., Ayad, S. and Schofield, J. R. (1988). "Chondrons from articular cartilage: I. Immunolocalization of type VI collagen in the pericellular capsule of isolated canine tibial chondrons." J Cell Sci **90** (Pt 4): 635-43.
- Powell, J. (1999). "Update on hemangiomas and vascular malformations." Curr Opin Pediatr **11**(5): 457-63.
- Presta, M., Dell'Era, P., Mitola, S., Moroni, E., Ronca, R. and Rusnati, M. (2005). "Fibroblast growth factor/fibroblast growth factor receptor system in angiogenesis." Cytokine Growth Factor Rev **16**(2): 159-78.

- Priest, R. C., Spaul, J., Buckton, J., Grimley, R. L., Sims, M., Binks, M. and Malhotra, R. (2009). "Immunomodulatory activity of a methionine aminopeptidase-2 inhibitor on B cell differentiation." Clin Exp Immunol **155**(3): 514-22.
- Pufe, T., Kurz, B., Petersen, W., Varoga, D., Mentlein, R., Kulow, S., Lemke, A. and Tillmann, B. (2005). "The influence of biomechanical parameters on the expression of VEGF and endostatin in the bone and joint system." Ann Anat **187**(5-6): 461-72.
- Pufe, T., Lemke, A., Kurz, B., Petersen, W., Tillmann, B., Grodzinsky, A. J. and Mentlein, R. (2004). "Mechanical overload induces VEGF in cartilage discs via hypoxia-inducible factor." Am J Pathol **164**(1): 185-92.
- Qu, Z., Huang, X. N., Ahmadi, P., Andresevic, J., Planck, S. R., Hart, C. E. and Rosenbaum, J. T. (1995). "Expression of basic fibroblast growth factor in synovial tissue from patients with rheumatoid arthritis and degenerative joint disease." Lab Invest **73**(3): 339-46.
- Rashad, S., Revell, P., Hemingway, A., Low, F., Rainsford, K. and Walker, F. (1989). "Effect of non-steroidal anti-inflammatory drugs on the course of osteoarthritis." Lancet **2**(8662): 519-22.
- Ray, B. K., Shakya, A. and Ray, A. (2007). "Vascular endothelial growth factor expression in arthritic joint is regulated by SAF-1 transcription factor." J Immunol **178**(3): 1774-82.
- Reginster, J. Y. and Khaltsev, N. G. (2002). "Introduction and WHO perspective on the global burden of musculoskeletal conditions." Rheumatology (Oxford) **41 Suppl 1**: 1-2.
- Reimann, I. and Christensen, S. B. (1977). "A histological demonstration of nerves in subchondral bone." Acta Orthop Scand **48**(4): 345-52.
- Reyes-Llerena, G. A., Guibert-Toledano, M., Penedo-Coello, A., Perez-Rodriguez, A., Baez-Duenas, R. M., Charnicharo-Vidal, R. and Cardiel, M. H. (2009). "Community-Based Study to Estimate Prevalence and Burden of Illness of Rheumatic Diseases in Cuba: A COPCORD Study." J Clin Rheumatol **15**(2): 51-55.
- Rini, B. I. (2009). "Vascular endothelial growth factor-targeted therapy in metastatic renal cell carcinoma." Cancer **115**(10 Suppl): 2306-12.
- Risau, W. (1997). "Mechanisms of angiogenesis." Nature **386**(6626): 671-4.
- Rosenberg, L. (1971). "Chemical basis for the histological use of safranin O in the study of articular cartilage." J Bone Joint Surg Am **53**(1): 69-82.
- Rousseau, J. C. and Delmas, P. D. (2007). "Biological markers in osteoarthritis." Nat Clin Pract Rheumatol **3**(6): 346-56.
- Roussel, D., Dumas, J. F., Augeraud, A., Douay, O., Foussard, F., Malthiery, Y., Simard, G. and Ritz, P. (2003). "Dexamethasone treatment specifically increases the basal proton conductance of rat liver mitochondria." FEBS Lett **541**(1-3): 75-9.
- Saamanen, A. K., Salminen, H. J., Dean, P. B., De Crombrughe, B., Vuorio, E. I. and Metsaranta, M. P. (2000). "Osteoarthritis-like lesions in transgenic mice harboring a small deletion mutation in type II collagen gene." Osteoarthritis Cartilage **8**(4): 248-57.

- Sanna, P. P., Jirikowski, G. F., Lewandowski, G. A. and Bloom, F. E. (1992). "Applications of DAPI cytochemistry to neurobiology." *Biotech Histochem* **67**(6): 346-50.
- Schaible, H. G. and Grubb, B. D. (1993). "Afferent and spinal mechanisms of joint pain." *Pain* **55**(1): 5-54.
- Schaible, H. G. and Schmidt, R. F. (1985). "Effects of an experimental arthritis on the sensory properties of fine articular afferent units." *J Neurophysiol* **54**(5): 1109-22.
- Schaible, H. G. and Schmidt, R. F. (1988). "Time course of mechanosensitivity changes in articular afferents during a developing experimental arthritis." *J Neurophysiol* **60**(6): 2180-95.
- Schaible, H. G., Schmidt, R. F. and Willis, W. D. (1986). "Responses of spinal cord neurones to stimulation of articular afferent fibres in the cat." *J Physiol* **372**: 575-93.
- Schwartz, E. R. (1987). "Animal models: a means to study the pathogenesis of osteoarthritis." *J Rheumatol* **14 Spec No**: 101-3.
- Schwartz, E. R. and Greenwald, R. A. (1979). "Experimental models of osteoarthritis." *Bull Rheum Dis* **30**(6): 1030-3.
- Scott, B. B., Zaratian, P. F., Gilmartin, A. G., Hansbury, M. J., Colombo, A., Belpasso, C., Winkler, J. D. and Jackson, J. R. (2005). "TNF-alpha modulates angiopoietin-1 expression in rheumatoid synovial fibroblasts via the NF-kappa B signalling pathway." *Biochem Biophys Res Commun* **328**(2): 409-14.
- Seedhom, B. B., Dowson, D. and Wright, V. (1974). "Proceedings: Functions of the menisci. A preliminary study." *Ann Rheum Dis* **33**(1): 111.
- Seegers, H. C., Avery, P. S., McWilliams, D. F., Haywood, L. and Walsh, D. A. (2004). "Combined effect of bradykinin B2 and neurokinin-1 receptor activation on endothelial cell proliferation in acute synovitis." *Faseb J* **18**(6): 762-4.
- Seegers, H. C., Hood, V. C., Kidd, B. L., Cruwys, S. C. and Walsh, D. A. (2003). "Enhancement of angiogenesis by endogenous substance P release and neurokinin-1 receptors during neurogenic inflammation." *J Pharmacol Exp Ther* **306**(1): 8-12.
- Shalom-Barak, T., Quach, J. and Lotz, M. (1998). "Interleukin-17-induced gene expression in articular chondrocytes is associated with activation of mitogen-activated protein kinases and NF-kappaB." *J Biol Chem* **273**(42): 27467-73.
- Sharma, J. N. (2010). "Modifications in tissue kallikrein activity with indomethacin and prednisolone treatment in arthritic rats." *Inflammopharmacology* **18**(3): 113-7.
- Shu, S. Y., Ju, G. and Fan, L. Z. (1988). "The glucose oxidase-DAB-nickel method in peroxidase histochemistry of the nervous system." *Neurosci Lett* **85**(2): 169-71.
- Shukunami, C., Oshima, Y. and Hiraki, Y. (2005). "Chondromodulin-I and tenomodulin: a new class of tissue-specific angiogenesis inhibitors found in hypovascular connective tissues." *Biochem Biophys Res Commun* **333**(2): 299-307.

- Sin, N., Meng, L., Wang, M. Q., Wen, J. J., Bornmann, W. G. and Crews, C. M. (1997). "The anti-angiogenic agent fumagillin covalently binds and inhibits the methionine aminopeptidase, MetAP-2." Proc Natl Acad Sci U S A **94**(12): 6099-103.
- Slemenda, C., Heilman, D. K., Brandt, K. D., Katz, B. P., Mazzuca, S. A., Braunstein, E. M. and Byrd, D. (1998). "Reduced quadriceps strength relative to body weight: a risk factor for knee osteoarthritis in women?" Arthritis Rheum **41**(11): 1951-9.
- Smith, J., Hannon, R., Brunnberg, L., Gebiski, V. and Cullis-Hill, D. (2002). "A multicentre clinical study of the efficacy of sodium pentosan polysulfate and carprofen canine osteoarthritis (osteoarthrosis)." Veterinarmotet.
- Smith, J. O., Oreffo, R. O., Clarke, N. M. and Roach, H. I. (2003). "Changes in the antiangiogenic properties of articular cartilage in osteoarthritis." J Orthop Sci **8**(6): 849-57.
- Smith, M. D., Triantafillou, S., Parker, A., Youssef, P. P. and Coleman, M. (1997). "Synovial membrane inflammation and cytokine production in patients with early osteoarthritis." J Rheumatol **24**(2): 365-71.
- Smith, W. and Harrap, S. B. (1997). "Behavioural and cardiovascular responses of rats to euthanasia using carbon dioxide gas." Lab Anim **31**(4): 337-46.
- Sowers, M., Jannausch, M., Stein, E., Jamadar, D., Hochberg, M. and Lachance, L. (2002). "C-reactive protein as a biomarker of emergent osteoarthritis." Osteoarthritis Cartilage **10**(8): 595-601.
- Spector, T. D. and Cooper, C. (1993). "Radiographic assessment of osteoarthritis in population studies: whither Kellgren and Lawrence?" Osteoarthritis Cartilage **1**(4): 203-6.
- Stannus, O., Jones, G., Cicuttini, F., Parameswaran, V., Quinn, S., Burgess, J. and Ding, C. (2010). "Circulating levels of IL-6 and TNF-alpha are associated with knee radiographic osteoarthritis and knee cartilage loss in older adults." Osteoarthritis Cartilage.
- Stefanini, M., De Martino, C. and Zamboni, L. (1967). "Fixation of ejaculated spermatozoa for electron microscopy." Nature **216**(5111): 173-4.
- Storgard, C. M., Stupack, D. G., Jonczyk, A., Goodman, S. L., Fox, R. I. and Cheresch, D. A. (1999). "Decreased angiogenesis and arthritic disease in rabbits treated with an alphavbeta3 antagonist." J Clin Invest **103**(1): 47-54.
- Streefkerk, J. G. (1972). "Inhibition of erythrocyte pseudoperoxidase activity by treatment with hydrogen peroxide following methanol." J Histochem Cytochem **20**(10): 829-31.
- Sun, Y., Mauerhan, D. R., Honeycutt, P. R., Kneisl, J. S., Norton, H. J., Zinchenko, N., Hanley, E. N., Jr. and Gruber, H. E. (2010). "Calcium deposition in osteoarthritic menisci and meniscal cell culture." Arthritis Res Ther **12**(2): R56.
- Sund, M., Zeisberg, M. and Kalluri, R. (2005). "Endogenous stimulators and inhibitors of angiogenesis in gastrointestinal cancers: basic science to clinical application." Gastroenterology **129**(6): 2076-91.

- Suri, S., Gill, S. E., Massena de Camin, S., Wilson, D., McWilliams, D. F. and Walsh, D. A. (2007). "Neurovascular invasion at the osteochondral junction and in osteophytes in osteoarthritis." Ann Rheum Dis **66**(11): 1423-8.
- Swoboda, B. (2001). "[Epidemiological arthrosis research]." Orthopade **30**(11): 834-40.
- Szebenyi, B., Hollander, A. P., Dieppe, P., Quilty, B., Duddy, J., Clarke, S. and Kirwan, J. R. (2006). "Associations between pain, function, and radiographic features in osteoarthritis of the knee." Arthritis Rheum **54**(1): 230-5.
- Szebenyi, G. and Fallon, J. F. (1999). "Fibroblast growth factors as multifunctional signaling factors." Int Rev Cytol **185**: 45-106.
- Takagi, T., Tsao, P. W., Totsuka, R., Suzuki, T., Murata, T. and Takata, I. (1998). "Dexamethasone prevents the decrease of bone mineral density in type II collagen-induced rat arthritis model." Jpn J Pharmacol **78**(2): 225-8.
- Tanaka, E., Aoyama, J., Miyauchi, M., Takata, T., Hanaoka, K., Iwabe, T. and Tanne, K. (2005). "Vascular endothelial growth factor plays an important autocrine/paracrine role in the progression of osteoarthritis." Histochem Cell Biol **123**(3): 275-81.
- Tetlow, L. C., Adlam, D. J. and Woolley, D. E. (2001). "Matrix metalloproteinase and proinflammatory cytokine production by chondrocytes of human osteoarthritic cartilage: associations with degenerative changes." Arthritis Rheum **44**(3): 585-94.
- Thonar, E. J., Masuda, K., Lenz, M. E., Hauselmann, H. J., Kuettner, K. E. and Manicourt, D. H. (1995). "Serum markers of systemic disease processes in osteoarthritis." J Rheumatol Suppl **43**: 68-70.
- Uchii, M., Tamura, T., Suda, T., Kakuni, M., Tanaka, A. and Miki, I. (2008). "Role of fibroblast growth factor 8 (FGF8) in animal models of osteoarthritis." Arthritis Res Ther **10**(4): R90.
- Valdes, A. M., Van Oene, M., Hart, D. J., Surdulescu, G. L., Loughlin, J., Doherty, M. and Spector, T. D. (2006). "Reproducible genetic associations between candidate genes and clinical knee osteoarthritis in men and women." Arthritis Rheum **54**(2): 533-9.
- Van Arman, C. G., Carlson, R. P., Risley, E. A., Thomas, R. H. and Nuss, G. W. (1970). "Inhibitory effects of indomethacin, aspirin and certain other drugs on inflammations induced in rat and dog by carrageenan, sodium urate and ellagic acid." J Pharmacol Exp Ther **175**(2): 459-68.
- Van Arman, C. G., Nuss, G. W. and Risley, E. A. (1973). "Interactions of aspirin, indomethacin and other drugs in adjuvant-induced arthritis in the rat." J Pharmacol Exp Ther **187**(2): 400-14.
- van der Kraan, P. M., Vitters, E. L., van Beuningen, H. M., van de Putte, L. B. and van den Berg, W. B. (1990). "Degenerative knee joint lesions in mice after a single intra-articular collagenase injection. A new model of osteoarthritis." J Exp Pathol (Oxford) **71**(1): 19-31.
- van Lent, P. L., Blom, A. B., van der Kraan, P., Holthuysen, A. E., Vitters, E., van Rooijen, N., Smeets, R. L., Nabbe, K. C. and van den Berg, W. B. (2004). "Crucial role of synovial lining macrophages in the promotion of transforming growth factor beta-mediated osteophyte formation." Arthritis Rheum **50**(1): 103-11.

- van Saase, J. L., van Romunde, L. K., Cats, A., Vandenbroucke, J. P. and Valkenburg, H. A. (1989). "Epidemiology of osteoarthritis: Zoetermeer survey. Comparison of radiological osteoarthritis in a Dutch population with that in 10 other populations." Ann Rheum Dis **48**(4): 271-80.
- Vermeirsch, H., Biermans, R., Salmon, P. L. and Meert, T. F. (2007). "Evaluation of pain behavior and bone destruction in two arthritic models in guinea pig and rat." Pharmacol Biochem Behav **87**(3): 349-59.
- Wagstaff, S., Smith, O. V. and Wood, P. H. (1985). "Verbal pain descriptors used by patients with arthritis." Ann Rheum Dis **44**(4): 262-5.
- Wahl, S. M., Feldman, G. M. and McCarthy, J. B. (1996). "Regulation of leukocyte adhesion and signaling in inflammation and disease." J Leukoc Biol **59**(6): 789-96.
- Walsh, D. A. (1999). "Angiogenesis and arthritis." Rheumatology (Oxford) **38**(2): 103-12.
- Walsh, D. A. (2004). "Angiogenesis in osteoarthritis and spondylosis: successful repair with undesirable outcomes." Curr Opin Rheumatol **16**(5): 609-15.
- Walsh, D. A., Bonnet, C. S., Turner, E. L., Wilson, D., Situ, M. and McWilliams, D. F. (2007). "Angiogenesis in the synovium and at the osteochondral junction in osteoarthritis." Osteoarthritis Cartilage **15**(7): 743-51.
- Walsh, D. A. and Haywood, L. (2001). "Angiogenesis: a therapeutic target in arthritis." Curr Opin Investig Drugs **2**(8): 1054-63.
- Walsh, D. A., Hu, D. E., Mapp, P. I., Polak, J. M., Blake, D. R. and Fan, T. P. (1996). "Innervation and neurokinin receptors during angiogenesis in the rat sponge granuloma." Histochem J **28**(11): 759-69.
- Walsh, D. A., McWilliams, D. F., Turley, M. J., Dixon, M. R., Franses, R. E., Mapp, P. I. and Wilson, D. (2010). "Angiogenesis and nerve growth factor at the osteochondral junction in rheumatoid arthritis and osteoarthritis." Rheumatology (Oxford) **49**(10): 1852-61.
- Walsh DA, M. D., Turley MJ, Dixon MR, Franses RE, Mapp PI, Wilson D (2010). "Angiogenesis and nerve growth factor at the osteochondral junction in rheumatoid arthritis and osteoarthritis. ." Rheumatology **In Press**.
- Walsh, D. A. and Pearson, C. I. (2001). "Angiogenesis in the pathogenesis of inflammatory joint and lung diseases." Arthritis Res **3**(3): 147-53.
- Walsh, D. A., Rodway, H. A. and Claxson, A. (1998). "Vascular turnover during carrageenan synovitis in the rat." Lab Invest **78**(12): 1513-21.
- Walsh, D. A., Wade, M., Mapp, P. I. and Blake, D. R. (1998). "Focally regulated endothelial proliferation and cell death in human synovium." Am J Pathol **152**(3): 691-702.
- Walsh, D. A. and Wilson, D. (2003). "Post-mortem collection of human joint tissues for research." Rheumatology (Oxford) **42**(12): 1556-8.

- Walsh, D. A., Yousef, A., McWilliams, D. F., Hill, R., Hargin, E. and Wilson, D. (2009). "Evaluation of a Photographic Chondropathy Score (PCS) for pathological samples in a study of inflammation in tibiofemoral osteoarthritis." Osteoarthritis Cartilage **17**(3): 304-12.
- Wang, H. M. and Zhang, G. Y. (2005). "Indomethacin suppresses growth of colon cancer via inhibition of angiogenesis in vivo." World J Gastroenterol **11**(3): 340-3.
- Waseem, N. H. and Lane, D. P. (1990). "Monoclonal antibody analysis of the proliferating cell nuclear antigen (PCNA). Structural conservation and the detection of a nucleolar form." J Cell Sci **96** (Pt 1): 121-9.
- Wilhelmi, G. and Faust, R. (1976). "Suitability of the C57 black mouse as an experimental animal for the study of skeletal changes due to ageing, with special reference to osteo-arthritis and its response to tribenoside." Pharmacology **14**(4): 289-96.
- Williams, J. M. and Brandt, K. D. (1985). "Triamcinolone hexacetonide protects against fibrillation and osteophyte formation following chemically induced articular cartilage damage." Arthritis Rheum **28**(11): 1267-74.
- Wilson, A. S., Legg, P. G. and McNeur, J. C. (1969). "Studies on the innervation of the medial meniscus in the human knee joint." Anat Rec **165**(4): 485-91.
- Wolfensohn, S. and Lloyd, M. (2003). Handbook of Laboratory Animal Management and Welfare (3rd Edition). Oxford, Blackwell Publishing.
- Woods, C. G., Greenwald, A. S. and Haynes, D. W. (1970). "Subchondral vascularity in the human femoral head." Ann Rheum Dis **29**(2): 138-42.
- Yamashita, A., Yonemitsu, Y., Okano, S., Nakagawa, K., Nakashima, Y., Irisa, T., Iwamoto, Y., Nagai, Y., Hasegawa, M. and Sueishi, K. (2002). "Fibroblast growth factor-2 determines severity of joint disease in adjuvant-induced arthritis in rats." J Immunol **168**(1): 450-7.
- Yusuf, E., Kortekaas, M. C., Watt, I., Huizinga, T. W. and Kloppenburg, M. (2010). "Do knee abnormalities visualised on MRI explain knee pain in knee osteoarthritis? A systematic review." Ann Rheum Dis.
- Zanetti, M., Bruder, E., Romero, J. and Hodler, J. (2000). "Bone marrow edema pattern in osteoarthritic knees: correlation between MR imaging and histologic findings." Radiology **215**(3): 835-40.
- Zhang, W., Doherty, M., Peat, G., Bierma-Zeinstra, M. A., Arden, N. K., Bresnihan, B., Herrero-Beaumont, G., Kirschner, S., Leeb, B. F., Lohmander, L. S., Mazieres, B., Pavelka, K., Punzi, L., So, A. K., Tuncer, T., Watt, I. and Bijlsma, J. W. (2010). "EULAR evidence-based recommendations for the diagnosis of knee osteoarthritis." Ann Rheum Dis **69**(3): 483-9.
- Zhang, W., Nuki, G., Moskowitz, R. W., Abramson, S., Altman, R. D., Arden, N. K., Bierma-Zeinstra, S., Brandt, K. D., Croft, P., Doherty, M., Dougados, M., Hochberg, M., Hunter, D. J., Kwoh, K., Lohmander, L. S. and Tugwell, P. (2010). "OARSI recommendations for the management of hip and knee osteoarthritis: part III: Changes in evidence following systematic cumulative update of research published through January 2009." Osteoarthritis Cartilage **18**(4): 476-99.

- Zhang, Y. and Jordan, J. M. (2010). "Epidemiology of osteoarthritis." Clin Geriatr Med **26**(3): 355-69.
- Ziche, M., Morbidelli, L., Alessandri, G. and Gullino, P. M. (1992). "Angiogenesis can be stimulated or repressed in vivo by a change in GM3:GD3 ganglioside ratio." Lab Invest **67**(6): 711-5.
- Ziche, M., Morbidelli, L., Choudhuri, R., Zhang, H. T., Donnini, S., Granger, H. J. and Bicknell, R. (1997). "Nitric oxide synthase lies downstream from vascular endothelial growth factor-induced but not basic fibroblast growth factor-induced angiogenesis." J Clin Invest **99**(11): 2625-34.
- Zimny, M. L., Albright, D. J. and Dabezies, E. (1988). "Mechanoreceptors in the human medial meniscus." Acta Anat (Basel) **133**(1): 35-40.
- Zittermann, S. I. and Issekutz, A. C. (2006). "Basic fibroblast growth factor (bFGF, FGF-2) potentiates leukocyte recruitment to inflammation by enhancing endothelial adhesion molecule expression." Am J Pathol **168**(3): 835-46.
- Zoricic, S., Maric, I., Bobinac, D. and Vukicevic, S. (2003). "Expression of bone morphogenetic proteins and cartilage-derived morphogenetic proteins during osteophyte formation in humans." J Anat **202**(Pt 3): 269-77.
- Zukowska-Grojec, Z. (1998). "Neuropeptide Y: an adrenergic cotransmitter, vasoconstrictor, and a nerve-derived vascular growth factor." Adv Pharmacol **42**: 125-8.

9 APPENDICES

9.1 Materials and Reagents

Acetic acid	VWR Ltd. Lutterworth, UK
Acetone	VWR Ltd. Lutterworth, UK
Albumin, Bovine (A-4503)	Sigma Aldrich, Poole, UK
Ammonium Chloride	VWR Ltd. Lutterworth, UK
Basic FGF, Human, Recombinant (13256-029)	Invitrogen Ltd. Paisley, UK
Beta-D-glucose (G5250)	Sigma Aldrich, Poole, UK
Calcium Chloride (C3306)	Sigma Aldrich, Poole, UK
Ceporex TM	Schering-Plough Animal - Health, Middlesex, UK
Cork Blocks 20mm x 3mm (E7.15/CD)	Raymond Lamb, Eastbourne, UK
Coverslips 22mm x 64mm	VWR Ltd. Lutterworth, UK
DAPI	Sigma Aldrich, Poole, UK
DePeX TM	VWR Ltd. Lutterworth, UK
Dexamethasone (D1756)	Sigma Aldrich, Poole, UK
Diaminobenzidine (D5637)	Sigma Aldrich, Poole, UK
Diammonium Nickle II Sulphate (A1827)	Sigma Aldrich, Poole, UK
Disodium phosphate heptahydrate (S9390)	Sigma Aldrich, Poole, UK
EDTA Disodium Salt (E5134)	Sigma Aldrich, Poole, UK
Electronic Caliper	Miyutoyo UK Ltd. Andover, UK
Eosin (1%)	Raymond Lamb, Eastbourne, UK
Ethanol absolute (32221)	Sigma Aldrich, Poole, UK
Fast Green (F-7258)	Sigma Aldrich, Poole, UK
Formalin Neutral buffered pH 7.0 (4% formaldehyde)	VWR Ltd. Lutterworth, UK
Formic Acid (399388)	Sigma Aldrich, Poole, UK
Glucose Oxidase Aspergillus Niger (G2133)	Sigma Aldrich, Poole, UK
Glycerol (G2025)	Sigma Aldrich, Poole, UK
Goat serum (G9023)	Sigma Aldrich, Poole, UK
Hematoxylin (H3136)	Sigma Aldrich, Poole, UK
Horse Serum	Sigma Aldrich, Poole, UK
Hydrochloric Acid	VWR Ltd. Lutterworth, UK
Hydrogen peroxide (H1009)	Sigma Aldrich, Poole, UK
Hydroxy-propyl-beta-cyclodextrin (C0926)	Sigma Aldrich, Poole, UK
Incapitance Meter	Linton Instruments, Norfolk, UK
Indomethacin (I7378)	Sigma Aldrich, Poole, UK

Iron (III) Chloride (157740)	Sigma Aldrich, Poole, UK
Isopentane	VWR Ltd. Lutterworth, UK
KS300 image analysis software	Imaging Associates Ltd. Thame, UK
Lambda Carrageenan (C-3889)	Sigma Aldrich, Poole, UK
Lewis or Wistar rats	Charles River, Kent, UK
Mayers Haematoxylin	Raymond Lamb, Eastbourne, UK
Methanol	Sigma Aldrich, Poole, UK
Monosodium Phosphate Monohydrate (S9638)	Sigma Aldrich, Poole, UK
Neuraminidase Clostridium perfringens (N2876)	Sigma Aldrich, Poole, UK
Novasapa Cold Steriliser	Pfizer Animal Health, Surrey, UK
OneTouch® Ultra® Blood Glucose Meter and Test Strips	LifeScan Inc. High Wycombe, UK
Paraformaldehyde (P6148)	Sigma Aldrich, Poole, UK
Phosphate Buffered Saline pH 7.4 (43711)	VWR Ltd. Lutterworth, UK
Picric Acid (1.2%)	VWR Ltd. Lutterworth, UK
Polyvinylpyrrolidone (PVP40T)	Sigma Aldrich, Poole, UK
Rabbit Serum	Sigma Aldrich, Poole, UK
Rimadyl™	Pfizer Ltd. Kent, UK
Safranin-O (S-2255)	Sigma Aldrich, Poole, UK
Shandon Pathcentre Tissue Processor	Shandon ThermoScientific, Leicestershire, UK
Sigma Fast™ Red Alkaline Phosphatase Tablets (F4523)	Sigma Aldrich, Poole, UK
Sodium acetate trihydrate (236500)	Sigma Aldrich, Poole, UK
Sodium Azide (8032)	Sigma Aldrich, Poole, UK
Sodium Chloride (S-3014)	Sigma Aldrich, Poole, UK
Sodium Chloride Solution, 0.9% (S8776)	Sigma Aldrich, Poole, UK
Sodium HEPES (H-3375)	Sigma Aldrich, Poole, UK
Sodium Pentobarbital (Euthatal)	Pfizer Ltd. Kent, UK
Sony DSC-s85 CyberShot digital camera	Carl Zeiss Ltd. Welwyn Garden City, UK
Sterile Op-Cover	Kruuse Ltd. Sherburn in Elmet, North Yorkshire
Sucrose (5016)	Sigma Aldrich, Poole, UK
Surgical Instruments	Interfocus Ltd. Cambridge, UK
Tergitol NP40 (NP-40)	Sigma Aldrich, Poole, UK
Tissue Tek® Embedding Centre	Sakura Finetek Europe, The Netherlands

Tissue Tek OCT® mounting medium

Tris base (T1509)

Vectastain® Elite ABC Kit (PK6100)

Vectastain® ABC-AP Kit (AK-5000)

Vetasept Povidone-Iodine Scrub

Xylene

Zeiss Axioscop-50 microscope

Raymond Lamb, Eastbourne, UK

Sigma Aldrich, Poole, UK

Vector Laboratories Ltd.

Peterborough, UK

Vector Laboratories Ltd.

Peterborough, UK

Animalcare Ltd. Dunnington, York

VWR Ltd. Lutterworth, UK

Carl Zeiss Ltd. Welwyn Garden

City, UK

9.2 Antibody List

Primary antibodies:

Description	Specificity	Other names	Clone	Product Type	Code	Company	Reference	Dilution
Mouse Anti-rat Proliferating Cell Nuclear Antigen (PCNA)	PCNA	-	PC-10	Monoclonal	M0879	DAKO Ltd. High Wycombe, UK	Walsh et al., 1998	1:1000
Mouse Anti-rat CD31	CD31	GPIIA, PECAM-1	TLD-3A12	Monoclonal	MCA1334G	Serotec Ltd. Oxford, UK	Male et al., 1995	1:400
Mouse Anti-rat CD68	CD68	ED1, MACROSIALIN	ED1	Monoclonal	MCA341GA	Serotec Ltd. Oxford, UK	Dijkstra et al., 1985	1:1000
Mouse Anti-Actin	Alpha-smooth muscle actin	-	1A4	Monoclonal	A2547	Sigma Aldrich, Poole, UK	Kennedy et al., 2010	1:2000
Rabbit anti- α -CGRP (human)	CGRP	-	-	Polyclonal	T-4239	Peninsula Labs Inc. St. Helens, UK	Suri et al., 2007	1:1000

Secondary antibodies:

Description	Antigen	Donor	Label	Code	Company	Dilution
Anti-Mouse IgG Affinity Purified, Rat Absorbed	Mouse IgG	Horse	Biotinylated	BA-2001	Vector Laboratories Ltd. Peterborough, UK	1:100
Anti-Rabbit IgG, Affinity Purified	Rabbit IgG	Goat	Biotinylated	BA-1000	Vector Laboratories Ltd. Peterborough, UK	1:100
Griffonia (Bandeiraea) Simplicifolia Lectin 1	Lectin-1	-	-	L-1100	Vector Laboratories Ltd. Peterborough, UK	1:6000
Griffonia (Bandeiraea) Simplicifolia Lectin 1, Affinity Purified	Lectin-1	Goat	-	AS-2104	Vector Laboratories Ltd. Peterborough, UK	1:6000
Anti-Goat IgG, Affinity Purified	Goat IgG	Rabbit	Biotinylated	BA-5000	Vector Laboratories Ltd. Peterborough, UK	1:100

9.3 Buffers and solutions used for immunohistochemistry

• Acid Alcohol:	Hydrochloric Acid (1.0 M)	5.0 ml
	Ethanol	350 ml
	Distilled H ₂ O	145 ml
• Acetic Acid Solution:	Acetic Acid (Glacial)	4 ml
	Distilled H ₂ O	396 ml
• DAPI:	Tergitol NP40	0.6 g
	DAPI	0.1 mg
	PBS (0.01 M)	100 ml
• Decalcification Fluid:	Tris base	3.35 g
	EDTA (10%)	250 g
	PVP (7.5%)	187.5 g
	Distilled H ₂ O	2.5 L
	pH	6.95
• Fast Green Solution:	Fast Green	0.1 g
	Distilled H ₂ O	500 ml
• Goat Blocking Buffer:	BSA (5%)	0.01 g
	Goat Serum (3.3%)	0.7 ml
	PBS (0.1 M)	2.0 ml
	Distilled H ₂ O	17.3 ml
• HEPES buffer:	NaHEPES (10 mM)	2.603 g
	NaCl (150 mM)	8.766 g
	CaCl ₂ 2H ₂ O (0.1mM)	0.015 g
	Distilled H ₂ O	1 L
	pH adjusted to	7.5
• Horse Blocking Buffer:	BSA (5%)	0.01 g
	Horse Serum (3.3%)	0.7 ml
	PBS (0.1 M)	2.0 ml
	Distilled H ₂ O	17.3 ml

• Hydrochloric Acid (1.0 M):	Hydrochloric Acid (37%)	0.5 ml
	Distilled H ₂ O	4.5 ml
• Hydrogen Peroxide in Methanol:	Hydrogen Peroxide (0.33%)	3.0 ml
	Methanol	300 ml
• PBS (10 x concentrated at 0.1 M):	Sodium Chloride	70.1 g
	Sodium dihydrogen Orthophosphate	4.4 g
	Di-sodium hydrogen Orthophosphate	12.8 g
	Potassium Chloride	2.0 g
	pH	7.4
Working dilution of PBS:	From 10 x concentrated 0.1M stock solution to working solution of 0.01M using distilled water.	
• Phosphate Buffer (0.2 M):	Monosodium Phosphate Monohydrate	7.41 g
	Disodium Phosphate heptahydrate	39.2 g
	Distilled H ₂ O	1 L
• PBS and Sucrose:	Sucrose (15%)	375 g
	Sodium Azide (0.01%)	0.25 g
	PBS (0.01 M)	2.5 L
	pH	7.4
• Rabbit Blocking Buffer:	BSA (5%)	0.01 g
	Rabbit Serum (3.3%)	0.7 ml
	PBS (0.1 M)	2.0 ml
	Distilled H ₂ O	17.3 ml
• Safranin-O Solution:	Safranin-O	0.4 g
	Distilled H ₂ O	400 ml
• Sodium Acetate (0.1 M):	Sodium Acetate Trihydrate	5.64 g
	Glacial Acetic Acid	3.51 ml
	Distilled H ₂ O	1 L
• Sodium Acetate (0.2 M):	Sodium Acetate Trihydrate	25.77 g

Glacial Acetic Acid	0.6 ml
Distilled H ₂ O	1 L

- Weigert's Haematoxylin:

Reagent A

Haematoxylin	2.0 g
Ethanol	200 ml
Distilled H ₂ O	10 ml

Reagent B

Iron (III) Chloride (2.9 g in 10 ml distilled H ₂ O)	8 ml
HCL (37% concentrated)	2 ml
Distilled H ₂ O	190 ml

Add equal volume of Reagent A to Reagent B to make Weigert's Haematoxylin

- Zamboni's Fixative:

Paraformaldehyde Solution (16%)	250 ml
Saturated Picric Acid Solution	150 ml
Phosphate Buffer (0.2 M)	500 ml
Distilled H ₂ O	100 ml

9.4 Calculations

- Number of fields per section required to give a statistically significant result.

Approximately 8 consecutive sections were stained for the appropriate antigen of interest. Quantification was performed using image analysis and data was recorded on excel for statistical analysis. Indices of each cumulative field per section were Log transformed. The mean and standard deviation for each first field, second field etc. for all sections was calculated using the Log transformed values. Co-efficient of variation for each field was then determined. Two graphs representing, mean versus the number of cumulative fields and co-efficient of variation versus the number of cumulative fields were plotted. Co-efficient of variation expresses the standard deviation as a percentage of the sample mean. It is used to determine the size of the variation relative to the size of the observation. The size of variation decreases with each cumulative field upto a saturation point. The cumulative field that has the lowest variation in the observations determines the number of fields required per section.

- Number of sections per case required to give a statistically significant result.

Once the fields required per section were determined, weighted mean of that field for all sections was determined. For normally distributed data, true mean was calculated from the weighted mean. Standard deviation and standard error of the mean were also calculated. Standard error measures how precisely the population mean is estimated by the sample mean. The size of the standard error depends both on how much variation there is in the population and on the size of the sample i.e. the standard deviation of the mean. In these cases it was determined to be within $\pm 25\%$ of the true mean i.e. there is 95% confidence that the observed mean is between $\pm 25\%$ of the true mean. Number of sections = $\text{Standard deviation}^2 / \text{Standard error}^2$.

- Sample Size

A power calculation was performed to determine the minimal number of animals required to test for a significant difference in the data. A power of 80% was decided to show a difference of 10% at P value of 0.05. Pilot data was used to determine mean and standard deviation. The formula used was; $(u + v)^2 (\sigma_1^2 + \sigma_2^2) / (\mu_1^2 + \mu_2^2)$, where u is the one sided percentage point of the normal distribution corresponding to 100% minus the power. In this case $100 - 80 = 20\%$, so $u = 0.84$. v is the percentage of the normal distribution corresponding to the two sided significant level. In this case the significant level used was 5% i.e. $p = 0.05$, so $v = 1.96$. σ is standard deviation and μ is the mean.

- Intra-observer reliability for image analysis

Repeated measurements on the same case varies around the true value as a result of measurement error, the standard deviation of repeated measurements on the same case determines the size of the measurement error. Measurement error between repeat measurements is expressed as repeatability co-efficient (Bland et al., 1996).

9.5 Consent Forms

1 copy to be retained by research participant, 1 copy to be retained by Investigator

Brief Title: Collection of tissues for research into human disease

Full study title: A study of the molecular mechanisms of various human diseases using post mortem tissue (D6256M000024)

Principal (Chief) Investigator and Study Doctor: Dr David Walsh
(Sherwood Forest Hospitals NHS Foundation Trust and University of Nottingham)
Sponsors: Sherwood Forest Hospitals NHS FoundationTrust, University of Nottingham and AstraZeneca

INFORMATION SHEET

We appreciate this isn't an easy time for you, and are grateful for any time that you spend having this research explained to you. You are being asked for permission for samples of tissue to be removed from the knees of your relative who has recently died. Before you decide if you want to take part it is important for you to understand why Sherwood Forest Hospitals NHS Foundation Trust, the University of Nottingham and AstraZeneca (a Pharmaceutical company who are joint sponsoring this work) are doing the study, how your relative's information and tissue will be used, what the study will involve and the potential benefits and risks. Take your time to read the following information and discuss it with the doctor or nurse. If you are willing to take part you will be asked to sign a consent form and will be given a copy of this information sheet to keep.

WHY IS THIS STUDY BEING DONE?

Many diseases (such as arthritis and lung disease for example) cause unpleasant symptoms and can prevent sufferers from carrying out everyday activities. In many cases available treatments can often be improved upon, and often do not cure the disease. More research is needed to find new and improved treatments for these diseases.

Researchers at Sherwood Forest Hospitals NHS Foundation Trust, Academic Rheumatology at the University of Nottingham, and at AstraZeneca, are carrying out research to identify molecules (the body's chemicals) that cause disease. It is not yet known what causes many diseases, although some research has provided clues about what is important. We are looking for differences in tissues from patients who have had diseases compared with "normal" tissues. These differences may be seen as the presence or absence of molecules that are important for symptoms and tissue damage. We wish to use tissues from people who don't have disease, as well as tissues from people with these diseases, to help us be sure that any changes that we see are really involved in the disease.

WHAT ARE WE ASKING YOU TO DO?

If you are willing for your relative to be included in our research, and you are unaware of any objection to tissue removal that your relative may have raised during his/her lifetime, then we would remove bone and other tissues from both knees. The procedure used for removing tissues is similar to that used in total knee joint replacement surgery. About 4 cm (1½ inches) of bone, cartilage and soft tissue will be removed from each knee. No skin will be removed, and the skin will be closed after tissues have been removed, leaving stitches for about 45 cm (18 inches) down the front of each knee. The collected tissues will be accepted as a gift from you on behalf of your relative.

1 copy to be retained by research participant, 1 copy to be retained by Investigator

You will be asked if, to your knowledge, your relative sought medical help for knee pain during the past year, whether your relative smoked and whether they were housebound at all over the last year of their life.

We will also ask for permission to access your relative's clinical notes for other information that may be helpful to the research ("Study Data"), for example, medical history and medicines that have been prescribed.

**DO I NEED TO TAKE PART?
NO IT IS ENTIRELY VOLUNTARY.**

Participation in this study is voluntary and entirely up to you. You do not have to donate the tissue, if you don't want to. If you decide that you do not want your relative to provide tissue for the study, you don't have to give a reason for this. It won't be held against you in any way. If you do decide to take part you will be given this information sheet and consent form to sign and keep. If you decide to take part you are still free to withdraw at a later date

You can withdraw your consent for tissue collection, without giving any reasons, up to the time of that collection, by phoning the study contacts on 01623 672533 . You can withdraw your consent for the continued retention and use of your relative's samples even after they have been collected, without giving any reasons, by phoning that same number. We will still use the data from any analyses that have already been conducted. The code and link will enable us to identify the samples that need to be destroyed. It will then be the responsibility of Sherwood Forest Hospitals NHS Foundation Trust, the University of Nottingham and AstraZeneca to ensure that all that remains of the coded samples from your relative are destroyed.

Your consent to the use of your relative's Study Data can be withdrawn at any time. If you withdraw your consent, the researchers in this study will no longer use your relative's Study Data or share them with others, any results that have been generated before you withdraw your consent may still be used but no specific data about your relation will be used again, except where the Data are required by regulatory authorities to ensure validity of the Study.

WHAT ARE THE BENEFITS OF TAKING PART?

Agreeing for us to use joint tissues and Study Data from your relative means that you may possibly help people with diseases in the future, as information may be used to develop new treatments. There will be no direct personal gain from participation. There will be no payment for taking part in this study.

HOW WILL THE STUDY DATA AND SAMPLES BE USED?

The Investigator and the Study Sponsors may use the Study Data and samples for administration purposes, research and development of pharmaceutical products, diagnostics and/or medical aids, statistical analysis, the approval, registration and marketing processes relating to their products/study medication, and carrying out safety and efficacy evaluations.

Tissues may be used to measure the amounts of molecules that can cause disease. Some molecules may be extracted from the tissue to help us to identify them. Some tissues may be used to test how they respond to new medicines.

Overall, it is hoped that these studies will help us to treat and diagnose illness in other patients in the future. However, the samples that you donate will not themselves be used to treat or diagnose illness in other patients, or used in any genetic research on your relative's DNA (the material of which genes are made). Whilst there is no specific expiry for the use of these data or tissues samples that are no longer required for research will be disposed of by the research team in a legal and sensitive manner.

WHO WILL USE THE DATA AND SAMPLES THAT I HAVE DONATED?

Samples and Study Data will be stored for at least 15 years. They will be stored, processed and used for investigations at Sherwood Forest Hospitals NHS Foundation Trust, Academic Rheumatology at the University of Nottingham and AstraZeneca. The Study Sponsors may also wish to provide samples and Study Data to third parties such as laboratories with whom they have collaborations, to perform specific analyses. All samples provided will either be completely used up or returned to the Sponsor, and will

1 copy to be retained by research participant, 1 copy to be retained by Investigator

only be used for the purposes described. The researchers with whom we may share your data and samples could be located outside of the European Union, please be aware that such countries data protection laws may be different. The researchers will only use your data in the way described here and for research approved by the ethics committee. The researchers are responsible for handling your data in accordance with applicable Data Protection law(s) in force in their countries.

Special precautions are taken to ensure the research study is carried out with a high degree of confidentiality. A code that is specific to your relative will be used to label the samples and Study Data and identify all results that are recorded. The coding of all information is to ensure that the results are kept confidential by keeping your relative's identity and the results separate.

Samples and Study Data shared with Sponsors and collaborators outside Sherwood Forest Hospitals NHS Foundation Trust will not include your relative's name or address. Only the Study Doctor and his staff at Sherwood Forest Hospitals NHS Foundation Trust have access to the code key with which it is possible to connect the Study Data to your relative. However, any of the personal data that are available to the Study Doctor, may be reviewed at the Sherwood Forest Hospitals NHS Foundation Trust site by the Sponsors and/or their representatives, their contractors, regulatory authorities, or other supervisory bodies. The purpose of these reviews is to assure the proper conduct of the study and/or the quality of the Study Data. Please note, the results of the study may be published in medical literature, but your identity and that of your relative will not be revealed.

WHAT RIGHTS DO I HAVE TO THE RESULTS OF THE RESEARCH?

Any information derived directly or indirectly from this research, as well as any patents, diagnostic tests, drugs, or biological products developed directly or indirectly as a result of this research, are the sole property of the Study Sponsors (and their successors, licensees, and assigns) and may be used for commercial purposes. It is intended that you have no right to this property or to any share of the profits that may be earned directly or indirectly as a result of this research. However, in signing this form and donating the samples for research, you do not give up any rights that you would otherwise have in participating in this research research.

FUTURE CONTACT

There is no planned future contact. You will not have access to the research data. However, if you have an interest in knowing how the tissue donation has contributed to advances in the research on arthritis you may ask to be updated on this in the future by contacting the Study Doctor.

If you have any further questions about this study, or wish to contact the Study Sponsors, please discuss this in the first instance with:

Doctor **DA Walsh** (Principal (Chief) Investigator and Study Doctor)

Telephone 01623 672533

If you wish to complain about any aspect of the way you have been treated during the course of the study you can do so using the normal NHS complaints procedure. The number to ring for the Complaints and Litigation Department is 01623 672533

Thank you for taking the time to read this invitation

This document must be kept in the investigator's study file and retained for a minimum period of 15 years after completion of the study.

Brief Title: Collection of tissues for research into human disease

Full study title: A study of the molecular mechanisms of various human diseases using post mortem tissue (D6256M00024)

Principal (Chief) Investigator and Study Doctor: Dr David Walsh
 (Sherwood Forest Hospitals NHS Foundation Trust and University of Nottingham)
 Sponsors: Sherwood Forest Hospitals NHS Foundation Trust, University of Nottingham, and AstraZeneca

CONSENT FORM

Please circle as appropriate

Have you read and understood the information leaflet (V1 dated 30-09-2008)?	YES
Have you had the opportunity to ask questions and discuss this study, and have all your questions been answered satisfactorily?	YES
Do you agree to donate tissues from your relative's knees? These tissues will be used to identify changes that accompany disease and to help us to develop new drugs that could prevent these changes in patients.	YES
Do you understand that tissue obtained in this study may be stored for more than 15 years at AstraZeneca and Nottingham University?	YES
Do you agree to allow us to record some information about your relative's medical problems from their medical records?	YES
Do you understand that you are free to withdraw from the study at any time, without having to give a reason?	YES
Are you aware of any objection to tissue removal that your relative raised during his/her lifetime, which may indicate that they would not have wished to take part in this research?	NO
Do you agree that some of tissue and data may be provided to other academic centres and commercial companies to assist us with our research?	YES
Do you understand that you and your relative's personal data such as name, address, telephone number will not be provided to AstraZeneca, the University of Nottingham, nor to third parties, and that we treat all information obtained on you in the strictest confidence?	YES
Do you understand that it is not intended that you will benefit financially from your participation in this Study?	YES

Name of the deceased.....

Name of person giving consent.....Relationship to deceased.....

Signature..... Date.....

Name of Witness Signature of Witness Date

I, (Name of person taking consent, block letters) have explained the nature and the purpose of the study to and believe that he/she understands what the study involves.

Signed:Date:

Investigator's Signature:.....Date: