

Prikaz bolesnika | Case report

Vogt-Koyanagi-Harada syndrome – a case report and differential diagnosis of uveitis and meningitis

Sindrom Vogt-Koyanagi-Harada – prikaz bolesnika i diferencijalna dijagnoza uveitisa i meningitisa

Marija Santini^{1,2}, Mirna Vučemilo¹, Andro Vujević¹, Mateja Vujica¹, Barbara Vukić¹, Marija Štanfel³, Željka Petelin Gadže⁴, Ivan Jovanović⁵¹ School of Medicine, University of Zagreb, Zagreb, Croatia² Department of Intensive Care Medicine and Neuroinfectology, University Hospital for Infectious Diseases "Dr. Fran Mihaljević", Zagreb, Croatia³ Department of Ophthalmology, University Hospital Centre Zagreb, Zagreb, Croatia⁴ Department of Neurology, University Hospital Centre Zagreb, Zagreb, Croatia⁵ Department of Diagnostic and Interventional Radiology, University Hospital Centre Zagreb, Zagreb, Croatia**Keywords:***Vogt-Koyanagi-Harada syndrome*
Borrelia burgdorferi
uveitis
*meningitis***Ključne riječi:***Vogt-Koyanagi-Harada sindrom*
Borrelia burgdorferi
uveitis
*meningitis***Primljeno:** 02.06.2019.**Received:** 02.06.2019.**Prihvaćeno:** 26.08.2019.**Accepted:** 26.08.2019. **Corresponding author:**

Marija Santini

School of Medicine, University of Zagreb, Zagreb, Croatia
e-mail: msantini@bfm.hr**Abstract**

Vogt-Koyanagi-Harada syndrome is an autoimmune, multisystem disease and important cause of uveitis. In this case report we address the significance of reliable diagnostics and including autoimmune diseases in differential diagnosis of uveitis and meningitis syndrome.

Sažetak

Vogt-Koyanagi-Harada sindrom je autoimuna, multisistemska bolest i važan uzrok uveitisa. Ovim prikazom bolesnika naglašavamo važnost pouzdane dijagnostike te uključivanje autoimunih bolesti u diferencijalnu dijagnozu sindroma uveitisa i meningitisa.

Introduction

Uveitis is a form of eye inflammation which affects the middle layer of the eye wall (uvea). It is usually bilateral and often accompanied by meningitis. Uveitis often presents with sudden symptoms and progresses quickly. A patient may experience eye redness, pain and blurred vision. The causes of uveitis are infection, injury or an autoimmune disease.

Vogt-Koyanagi-Harada syndrome is a bilateral granulomatous uveitis based on autoimmune mechanism. It is associated with serous retinal detachments, disk hyperaemia, oedema and vitritis, with or without extraocular manifestations on the skin, auditory or central nervous system. It mostly affects people between twenty and fifty years of age^[1]. The incidence of this syndrome varies around the world. While it

accounts for 1 to 4% of uveitis cases in the USA, it is responsible for 6 to 9% of uveitis cases in Japan.

Due to such a wide spectrum of manifestations, typical cases of VKH syndrome are uncommon. In this case report we present a patient with Vogt-Koyanagi-Harada (VKH) syndrome and a false positive serology test to *Borrelia burgdorferi*. The aim of this case report is to address the significance of reliable diagnostics and inclusion of autoimmune diseases in differential diagnosis of uveitis and meningitis syndrome.

Case presentation

An adult 25-year-old female patient with unremarkable medical history and no previous ocular surgery or trauma, experienced first symptoms two days prior to

admission. The patient provided us with the information that she had experienced rapid onset frontal headache and blurred vision on the left eye. Despite symptomatic therapy for headache, frontal headache still persisted on the following day and blurred vision showed progression to both eyes. The patient was urgently admitted to University Hospital Dubrava on the same day. The neurological examination showed no evidence of central or peripheral deficits on admission and brain CT

scan was without abnormalities. Subsequently, the patient was discharged home without therapy and referred to an ophthalmologist for further evaluation. On the third day of the illness, the patient was admitted to the University Hospital Centre Zagreb, Department of Neurology, where the ophthalmology examination indicated exudative retinal detachment on both eyes (Figure 1). Ocular imaging modalities, including fluorescein angiography, were suggestive of VKH (Figure 2).

FIGURE 1 FUNDUS PHOTOGRAPHY AT THE TIME OF ADMISSION TO THE HOSPITAL

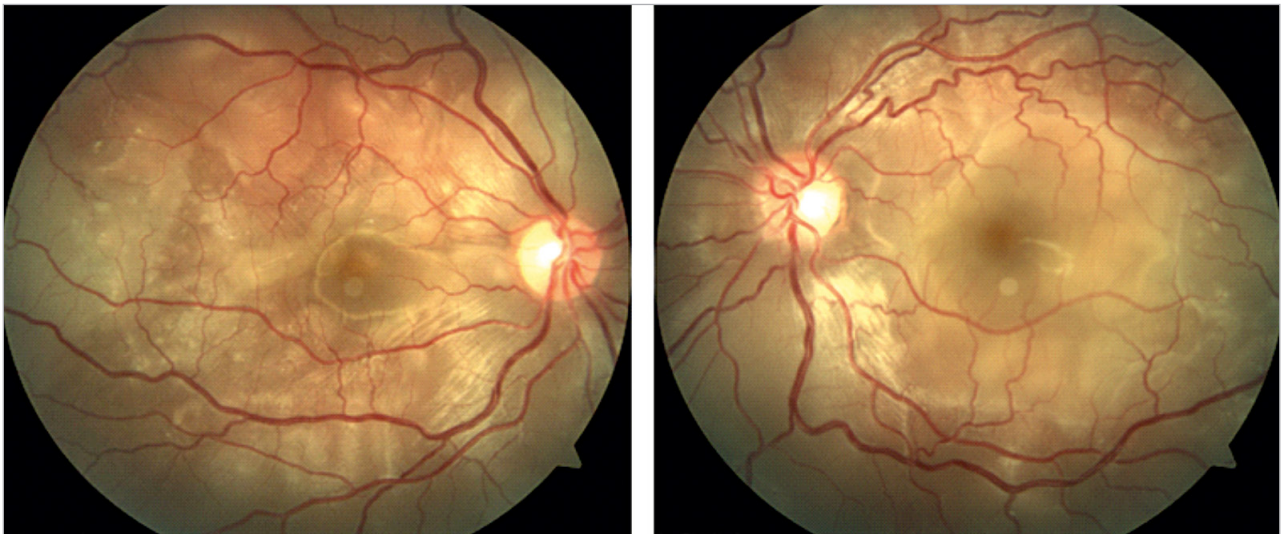
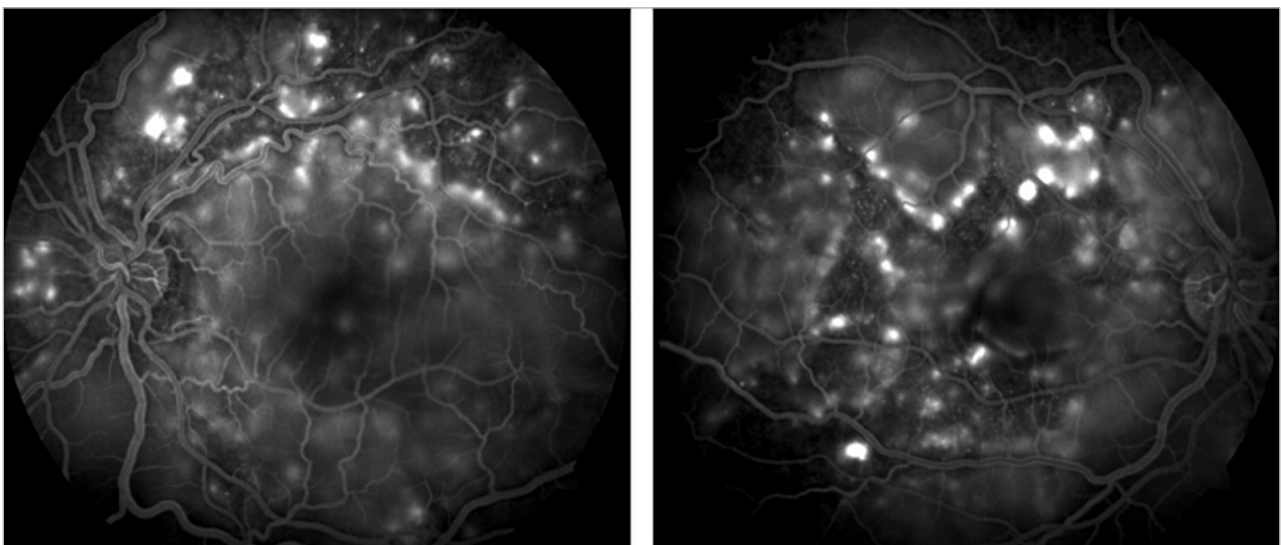


FIGURE 2 FUNDUS FLUORESCIN ANGIOGRAPHY AT THE TIME OF ADMISSION TO THE HOSPITAL



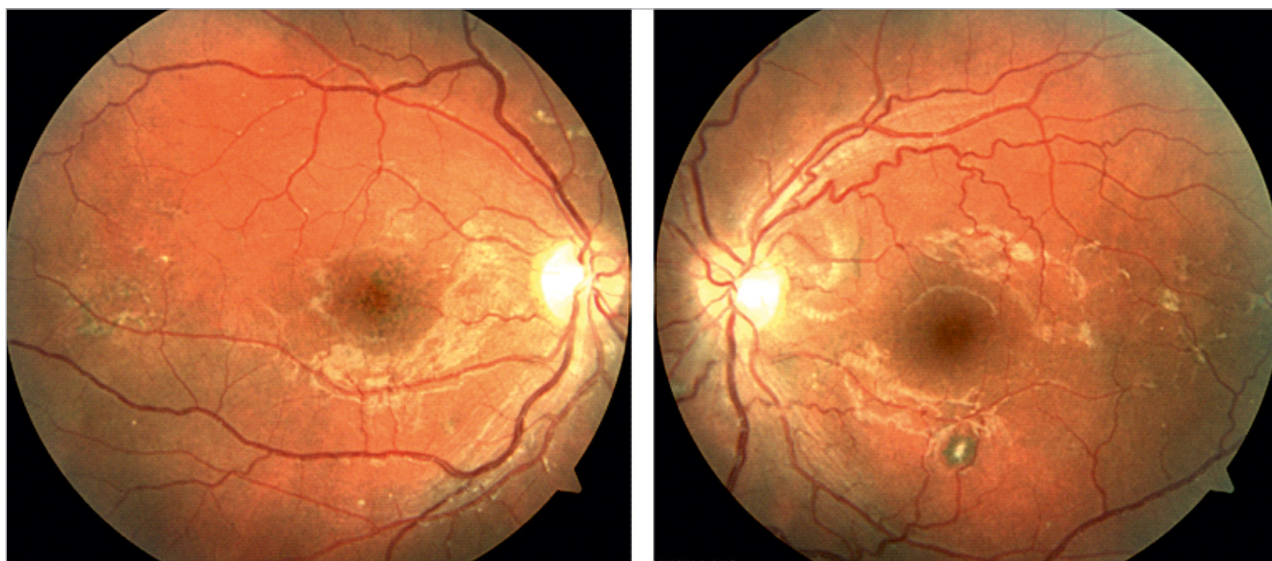
Further examination included an MRI that revealed hyperintensive signal of the intrabulbar segment of the left optic nerve, pointing to optic neuritis. At this stage, the patient was treated with pulse methylprednisolone therapy 1g/5 days. The patient's

condition improved and the treatment was continued with reduction in methylprednisolone dose. The laboratory examination of the cerebrospinal fluid (CSF) was negative for oligoclonal bands and NMO antibody test was also negative. CSF serology results

were as followed: CMV neg., *Toxoplasma gondii* neg., HSV1, HSV2 neg., *B. burgdorferi* positive. For the serodiagnosis, the 2- test approach, using ELISA and Western blot, was performed. Positive IgM and IgG on the ELISA, along with a positive IgG on the Western blot, indicated an infection with *B. burgdorferi*. Consequently, the patient was transferred to the University Hospital for Infectious Diseases „Dr. Fran Mihaljević” due to suspected neuroborreliosis. During hospitalization, the symptoms aggravated to occipital headache, vision blurring and ear buzzing, which pointed to the need for increasing corticosteroid dosage. During follow-up, serology test for neuroborreliosis was re-

peated and the results were negative, which indicated that the previous one was false positive. The patient maintained without new symptoms during hospitalization and at the end of the third week of the illness, the patient was dismissed. Throughout diagnosis and treatment, the patient was afebrile at all times. Finally, the 7-month follow-up showed visual acuity being normal. The ophthalmology examination showed significant reduction of the exudative retinal detachment (Figure 3) and the patient was prescribed therapy that included cyclosporine A 150+125 mg, methylprednisolone 7.5 mg, calcium 1000 mg and vitamin D 3-4 drops.

FIGURE 3 FUNDUS PHOTOGRAPHY AT THE 7-MONTH FOLLOW-UP



Discussion

Differential diagnosis of uveitis should include infectious (CMV, *B. burgdorferi*, TBC, syphilis, West Nile virus, leptospirosis, brucellosis) and non-infectious causes (Behcet’s disease, sarcoidosis, VKH syndrome, bilateral posterior scleritis, lupus choroidopathy, intraocular lymphoma, leukaemia)^[3]. In this case, the typical symptoms, along with fundus ophthalmoscopy showing retinal detachment, were indicative of VKH syndrome. The proposed pathophysiology of VKH is based on a T-cell mediated autoimmune reaction against antigens of melanocytes, since these cells are found in all four affected tissues (eye, inner ear, brain, skin)^[4]. The symptoms include blurred vision, photophobia, headache, vertigo, tinnitus, neck rigidity, vitiligo and alopecia. The diagnosis should be based on clinical findings, as well as ophthalmological imaging methods. The fundus fluorescein angiography was applied to confirm the diagnosis. The other meth-

ods, such as ICGA and OCT, have also been proven very useful in setting the diagnosis. Furthermore, in this particular case, the validity of serological testing to *B. burgdorferi* is compromised, leading to clinical confusion. After eliminating infectious etiology as a cause and repeated CSF serology negative on *Borelia burgdorferi*, based on characteristic abnormal ocular fundus findings and clinical manifestation, the final diagnosis was VKH syndrome.

Our patient with Vogt-Koyanagi-Harada syndrome presented with blurred vision on the left eye and frontal headache. These symptoms are in correlation with prodromal and beginning of uveitic stage of Vogt-Koyanagi-Harada disease (VGH). However, frontal headache and blurred vision are not specific for VGH. In the study by Shoughya and Tabbaraa, 9,2 % (7 out of 76) of patients with VGH had incorrect initial diagnosis. The initial diagnosis included optic neuritis, intracranial hypertension, brain tumour, Susac disease, migraine,

rhegmatogenous retinal detachment or anterior granulomatous uveitis of unknown etiology^[5]. Even though the ophthalmologist suspected VGH disease after examining our patient, after MRI and CSF serology, the initial diagnosis was first optic neuritis and afterwards neuroborreliosis. The repeated CSF serology was negative for *Borrelia burgdorferi*, thus implying false positive result of previous serology. False positivity of *Borrelia* tests is a problem worldwide^[6], with some reports of >20% false positivity from serum samples^[7]. False positivity of *Borrelia* serology could result in unnecessary antibiotics administration and delayed initiation of therapy for conditions resembling neuroborreliosis symptoms. That, along with multiple conditions coinciding symptoms of VGH, could result in later initiation of VGH therapy (cyclosporine A /azathioprine and methylprednisolone), causing irreversible uveal damage resulting in poor visual acuity or vision loss.

Fast, correct diagnosis and subsequent immunosuppressive treatment are of outmost importance, since without these, the disease could easily progress to its chronic phase and cause complications such as glaucoma, cataract, choroidal atrophy, vision loss. This paper highlights the importance of including autoimmune diseases in differential diagnosis and aggressive therapy. Rapid treatment with high dose corticosteroids, combined with long-term corticosteroid and immunosuppressive therapy at appropriate dosage, minimizes these complications and improves visual prognosis.

REFERENCES

- [1] Platzer K. Vogt-Koyanagi-Harada syndrome. 2018. [Internet] Available at: <https://dermnetnz.org/topics/vogt-koyanagi-harada-syndrome/>
- [2] Agarwal A. Gass's Atlas of Macular Diseases, 5th ed., China, Saunders;2012. p. 998-1002.
- [3] O'Keefe GAD, Rao NA. Vogt-Koyanagi-Harada disease. *Surv Ophthalmol* 2017;62:1-25.
- [4] Abad S, Wieërs G, Colau D, et al. Absence of recognition of common melanocytic antigens by T cells isolated from the cerebrospinal fluid of a Vogt-Koyanagi-Harada patient. *Mol Vis* 2014;20:956-969.
- [5] Shoughya SS, Tabbaraa KF. Initial misdiagnosis of Vogt-Koyanagi-Harada disease. *Saudi J Ophthalmol* 2019;33(1):52-55.
- [6] Theel ES, Aguero-Rosenfeld ME, Pritt B, Adem PV, Wormser GP. Limitations and Confusing Aspects of Diagnostic Testing for Neurologic Lyme Disease in the United States. *J Clin Microbiol* 2019;57(1):e01406-18.
- [7] Seriburi V, Ndukwe N, Chang Z, Cox ME, Wormser GP. High frequency of false positive IgM immunoblots for *Borrelia burgdorferi* in clinical practice. *Clin Microbiol Infect* 2012;18(12):1236-1240.
- [8] Rathinam SR, Babu M. Algorithmic approach in the diagnosis of uveitis. *Indian J Ophthalmol* 2013;61(6):255-62.
- [9] Hugo R. Salcedo, MD, et. al. Vogt-Koyanagi-Harada Disease. 2019. [Internet] Available at: https://eyewiki.aao.org/Vogt-Koyanagi-Harada_Disease