

Use of Cone Beam Computed Tomography for Studying Temporomandibular Joint Morphology

Ivan Lukšić, Žiga Lužnik, Ivica Pelivan, Samir Čimić

School of Dental Medicine, University of Zagreb, Zagreb, Croatia

ABSTRACT

The aim of the present study was to investigate morphology of temporomandibular joint using cone beam computer tomography. Study included 45 adults (32 females and 13 males). Articular eminence inclination, glenoid fossa width, glenoid fossa depth, condylar mediolateral distance, condylar anteroposterior distance and condylar type were determined for each temporomandibular joint. Since independent samples *t*-test did not show significant differences between left and right sides for all of observed parameters ($p \geq 0.05$), left and right side values were treated as one sample. The determined glenoid fossa depth was 7.11 ± 2.23 , glenoid fossa width 19.22 ± 2.58 , condylar anteroposterior distance 7.54 ± 1.59 , condylar mediolateral distance 17.95 ± 2.81 and articular eminence inclination was 34.59 ± 7.35 degrees. Most of condyles were classified as convex type (32.5%), followed by flattened (23.8%), rounded (11.3%) and angled (10%). Undefined (other type) were classified 22.5% of condyles. Cone beam computer tomography measurements of temporomandibular joint bone structures in present study showed similarities to most of previous research (with different populations studied). Still, the prevalence of different condylar types differs from those obtained by most of previous studies. Interindividual differences in temporomandibular joint morphology are expected.

Key words: cone beam computer tomography, temporomandibular joint, articular eminence inclination

Introduction

Cone Beam Computer Tomography (CBCT) is a modern radiological technology used in all branches of dentistry for the purpose of diagnostics, therapy planning and design of future restorations^{1,2}. With its progress in reducing radiation doses CBCT is imposed as a radiological standard and has been increasingly used. The anatomy of temporomandibular joint represents an important link in prosthetic rehabilitation of partial, and especially in complete edentulism. Some investigations have shown that changes in the orofacial system can lead to changes in temporomandibular joints morphology³. Zabarovic et al.³ found that the group of edentulous patients showed a greater symmetry and fewer differences between the left and right joint, probably due to articular eminence remodeling with tooth loss. Sa et al.⁴ reported that two or more bone diseases in the condyle had led to a decrease of the articular eminence angulation.

The articular eminence inclination is an important parameter for the determination of the condylar path

during protrusion. It is one of the factors which are important for individualization of articulator, and it is transferred to the articulator during prosthetic rehabilitation⁵⁻⁷.

The purpose of this study was to determine exact values of the right and left condyle and glenoid fossa, condylar shape and articular eminence inclination values with the use of CBCT of the temporomandibular joint.

Materials and Methods

Forty-five adults participated in this study (32 females and 13 males). The study was approved by the Ethical Committee of the School of Dental Medicine, University of Zagreb. CBCT images of participants were recruited from private studios for dental radiographic images, located in Zagreb, Croatia. Accordingly, age of participants and their signs and symptoms could not be

recorded, which is a limitation of the present study. Cone beam computed tomography software („CBCT viewer“) used were Ez3D Plus 3D CDViewer Ver. 1.2.6.23, OnDemand3DApp and One Volume Viewer ver.2.5.1.2770.

Cone beam computed tomography measurements were made in three planes: sagittal, horizontal and vertical (coronal). Each measurement was repeated two times (IL and ZL) and average measures were used. In sagittal plane articular eminence inclination, glenoid fossa width and glenoid fossa depth were measured. First, Frankfort horizontal was defined as connection between the most superior and lateral point of the meatus acusticus externus and the most inferior point of the orbital rim. The articular eminence inclination was measured with respect to Frankfort horizontal, and it was done using „top-roof line“ method according to Sa et al.⁴. The glenoid fossa width and depth were measured similarly to the method used by Paknahad et al.⁸. The glenoid fossa width was determined as a distance between the most inferior point of the articular eminence and the most inferior point of the posterior glenoid process. The glenoid fossa depth was obtained as perpendicular distance between the most superior point of the glenoid fossa and the line connecting the most inferior point of the articular eminence and the most inferior point of posterior glenoid process (Figure 1). The condylar length (mediolateral distance) and the condylar width (anteroposterior distance) were measured on horizontal view. The condylar length was determined as the greatest mediolateral distance, while the condylar width was determined as the greatest anteroposterior distance. Readings were made on two slices (1 mm thickness), and average values were used. If the measured parameter could not be obtained due to CBCT image of lower quality, that temporomandibular joint was excluded from the study. Central coronal slice was used for the determination of the condylar type according to Yale et al.' classification⁹ (A – flat, B – convex, C – angled, D – rounded). Similar to the study by Sa et al.⁴, type E were condyles that could not be assigned to any of A–D groups.

Left – right side differences were compared using independent samples t test ($\alpha=0.05$). For all measured variables descriptive statistics was calculated (Tibco Statistica, Version 13.4.0.14, Tibco Software Inc, Palo Alto, CA, USA).

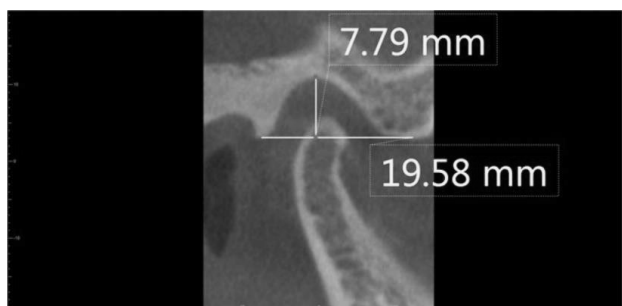


Fig. 1. Measurement of the glenoid fossa width and depth.

Results

T-test for independent samples showed no significant differences between the left and right fossa depth ($p=0.33$), left and right fossa width ($p=0.30$), left and right condylar mediolateral distance ($p=0.83$), left and right condylar anteroposterior distance ($p=0.96$) and between left and right articular eminence inclination ($p=0.91$). Therefore, the left and right temporomandibular joint values were treated as one sample. Table 1 shows descriptive statistics for glenoid fossa depth, glenoid fossa width, condylar anteroposterior distance, condylar mediolateral distance and articular eminence inclination values.

TABLE 1

DESCRIPTIVE STATISTICS OF TRAITS ANALYZED					
	N	Mean	Min	Max	SD
Glenoid fossa depth (mm)	79	7.11	3.68	15.61	2.23
Glenoid fossa width (mm)	79	19.22	14.44	29.17	2.58
Condylar width (anteroposterior distance, mm)	80	7.54	4.18	11.31	1.59
Condylar length (mediolateral distance, mm)	80	17.95	12.57	25.30	2.81
Articular eminence inclination (degrees)	79	34.59	20.44	54.49	7.35

Table 2 compares our values on the condylar shape to those obtained by other studies. According to Yale et al.'s classification, most of the condyles were classified as convex type (32.5%), followed by flattened (23.8%), rounded (11.3%) and angled (10%). Undefined (other type) were 22.5% of condyles.

Discussion and Conclusion

In this study, the morphology of the mandibular condyle and the articular fossa were investigated using CBCT. Previous reports have suggested that CBCT can provide accurate and reliable linear measurements for reconstruction and imaging of the TMJ bones^{10–12}. Ma et al.¹³ found that CBCT had a relatively high diagnostic accuracy for the detection of TMJ bone changes.

The articular eminence inclination determines the condylar path during protrusion movement along with ligaments, articular disc, neuromuscular system and guiding planes of the teeth¹⁴. The condylar path is an important factor during prosthetic rehabilitation of patients. Studies proved that articulators' condylar inclination adjustment affects the cusp height during protrusion¹⁵. Because of its importance during prosthetic rehabilitation, the eminence inclination was highly investigated^{4,16,17}. Yasa and Akgül¹⁶ using the top-roof line method determined in an asymptomatic group of participants the articular eminence inclination of 40.43 ± 6.89 in men and 38.14 ± 6.68 degrees in women. The studies by Sa et al.⁴ and Ilgüy et al.¹⁷ showed similar results. The determined articular emi-

TABLE 2
COMPARISON OF CONDYLAR SHAPES IN DIFFERENT STUDIES

Investigation	Flat (%)	Convex (%)	Angled (%)	Rounded (%)	Other (%)
Yale et al. ⁹	27.1	47.0	14.0	11.9	/
Yasa and Akgül ¹⁶	13.5/15	62.5/46.3	5.5/6.5	13.5/17.5	5/14.8
Sa et al. ⁴	58.5	9.5	8.7	18.0	5.3
Present study	23.8	32.5	10	11.3	22.5

nence inclination values in the present study (Table 1) differ from the results obtained by Yasa and Akgül¹⁶, Sa et al.⁴ and Ilgüy et al.¹⁷ who all used also the top – roof line method. Slightly lower inclination values (Table 1) can be explained with studied populations. Although medical history of the participants was not recorded, which is a limitation of the present investigation, it can be assumed that most of the patients probably had temporomandibular joint problems (since they had radiographic evaluation of temporomandibular joint). In a study by Sa et al.⁴ two or more bone diseases in the condyle resulted in a decrease of the articular eminence angulation. Al-Rawi et al.¹⁸ obtained similar results. Other investigations also showed gender differences in the eminence inclination^{17,19}, where eminence inclination mean values of males were higher than those of females¹⁷. Since 71% of participants in the present study were females, this could also affect the obtained lower values (Table 1) than in previous studies. Relatively large standard deviations are frequent in studies that measure different temporomandibular joint parameters^{20–22}. The studies on the articular eminence inclination^{3,16} also determined variability between different participants, like in the present study (Table 1). It can be concluded that inter-individual differences between the patients are expected.

Al-Rawi et al.¹⁸ determined 18.98 ± 2.55 mm for the condylar mediolateral distance and 7.49 ± 1.1 mm for the con-

dylar anteroposterior distance in men, while these values in women were 15.81 ± 3.05 mm and 6.58 ± 1.34 mm. In a similar study Scariot et al.²³ studied mandibular condylar dimensions. They investigated the correlation between 3D tomography and dried skull measurements. Using CBCT the obtained values were 18.90 ± 3.20 mm for the right condylar mediolateral distance and 18.90 ± 3.03 mm for the left condylar mediolateral distance, while condylar anteroposterior distance values were 9.17 ± 2.77 right and 10.05 ± 2.87 mm left. The study determined the maximal error of CBCT of 1.79 mm²³. Considering the maximal error of CBCT, the condylar mediolateral distance and the anteroposterior distance values in the present study (Table 1) can be observed as close to the studies by Scariot et al.²³ and Al-Rawi et al.¹⁸. Glenoid fossa depth values were also similar to those found in previous studies^{16–18}.

Our results of the condylar shape identification differ from those obtained by previous investigations that used the classification of Yale et al.^{4,9,16}, and are most similar to the study of Yale et al.⁹ (Table 2). The present study had almost 23% of undefined (other type) condyles. Every condyle with characteristics of two groups or other doubt was classified as type E. It can be concluded that different condylar shapes are normal and differences between studies are probably due to different study populations. Still, differences between different criteria of researchers cannot be excluded.

REFERENCES

- KAMBUROGLU K, World J Radiol, 7 (2015) 128. — 2. SHUKLA S, CHUG A, AFRASHTEHFAR KI, J Int Soc Prev Community Dent, 7 (2017) S125. — 3. ZABAROVIC D, JEROLIMOV V, CAREK V, VOJVODIC D, ZABAROVIC K, BUKOVIC D JR, Coll Antropol, 24 Suppl 1 (2000) 37. — 4. SA SC, MELO SL, MELO DP, FREITAS DQ, CAMPOS PS, Braz Oral Res, 31 (2017) e25. — 5. KAUR S, DATTA K, J Indian Prosthodont Soc, 18 (2018) 35. — 6. MAGE K, ČELIĆ R, ČIMIĆ S, DULČIĆ N, Acta Stomatol Croat, 53 (2019) 213. — 7. KRANJCIC J, SLAUS M, VODANOVIC M, PERSIC S, VOJVODIC D, Acta Clin Croat, 55 (2016) 529. — 8. PAKNAHAD M, SHAHIDI S, AKHLAGHIAN M, ABOLVARDI M, J Dent (Shiraz), 17 (2016) 134. — 9. YALE SH, CEBALLOS M, KRESNOFF CS, HAUPTFUEHRER JD, Oral Surg Oral Med Oral Pathol, 16 (1963) 572. — 10. HINTZE H, WIESE M, WENZEL A, Dentomaxillofac Radiol, 36 (2007) 192. — 11. ZHANG ZL, CHENG JG, LI G, ZHANG JZ, ZHANG ZY, MA XC, Oral Surg Oral Med Oral Pathol Oral Radiol, 114 (2012) 112. — 12. HILGERSML, SCARFE WC, SCHEETZ JP, FARMAN AG, Am J Orthod Dentofacial Orthop, 128 (2005) 803. — 13. MA RH, YIN S, LI G, Sci Rep, 6 (2016) 34714. — 14. KUBEIN-MEESENBERG D, FANGHÄNEL J, IHLOW D, LOTZMANN U, HAHN W, THIEME KM, PROFF P, GEDRANGE T, NÄGERL H, Ann Anat, 189 (2007) 393. — 15. PRICE RB, KOLLING JN, CLAYTON JA, J Prosthet Dent, 65 (1991) 237. — 16. YASA Y, AKGUL HM, Oral Radiol, 34 (2018) 31. — 17. ILGUY D, ILGUY M, FISEKCIOGLU E, DOLEKOGLU S, ERSAN N, Scientific World Journal, 2014 (2014) 761714. DOI: 10.1155/2014/761714. — 18. AL-RAWI NH, UTHMAN AT, SODEIFY SM, Eur J Dent, 11 (2017) 99. — 19. LOBO F, TOLENTINO ES, IWAKI LCV, WALEWSKI LA, TAKESHITA WM, CHICARELLI M, J Craniofac Surg, 30 (2019) 1462. — 20. CIMIC S, SIMUNKOVIC SK, GOSPIC RK, BADEL T, DULCIC N, CATIC A, Coll Antropol, 39 (2015) 159. — 21. HERNANDEZ AI, JASINEVICIUS TR, KALEINIKOVA Z, SADAN A, Cranio, 28 (2010) 60. — 22. LESIC N, SEIFERT D, ZECIC M, PEZO H, Coll Antropol, 40 (2016) 189. — 23. SCARIOT R, GONSAR B, GILL N, FURQUIM F, CORSO PFCL, TREVILLATO PC, POTLURI A, VIEIRA AR, Cranio, 37 (2019) 153.

S. Čimić

Department of Removable Prosthodontics, School of Dental Medicine, University of Zagreb, Gundulićeva 5, 10000 Zagreb, Croatia

e-mail: scimic@sfzg.hr

UPORABA KOMPJUTORIZIRANE TOMOGRAFIJE KONUSNIM SNOPIOM ZA PROUČAVANJE MORFOLOGIJE TEMPOROMANDIBULARNOG ZGLOBA

SAŽETAK

Svrha ove studije bila je istražiti morfologiju temporomandibularnog zgloba koristeći kompjutoriziranu tomografiju konusnim snopom. Istraživanje je uključilo 45 odraslih ispitanika (32 žene i 13 muškaraca). Inklinacija zglobne kvržice, širina zglobne jamice, dubina zglobne jamice, širina kondila, dužina kondila i tip kondila su utvrđeni za svaki temporomandibularni zglob. S obzirom da t-test za neovisne uzorke nije potvrdio razlike lijeve i desne strane kod svih ispitivanih parametara ($\alpha=0,05$), vrijednosti lijeve i desne strane su tretirane kao jedan uzorak. Utvrđene su vrijednosti za dubinu zglobne jamice od $7,11\pm 2,23$ mm, širinu zglobne jamice $19,22\pm 2,58$ mm, širinu kondila $7,54\pm 1,59$ mm, dužinu kondila $17,95\pm 2,81$ mm i inklinaciju stražnjeg zida zglobne kvržice od $34,59\pm 7,35$ stupnjeva. Većina kondila su svrstani pod konveksni tip (32,5%), a slijedili su zaravnani (23,8%), zaobljeni (11,3%) i kutni tip kondila (10%). Pod nedefinirane (neki drugi tip) je svrstano 22,5% kondila. Kompjutorizirana tomografija struktura temporomandibularnog zgloba ove studije je utvrdila sličnosti s većinom prijašnjih istraživanja (u različitim proučavanim populacijama). Ipak, prevalencija različitih tipova kondila se razlikuje od onih u većini istraživanja. Interindividualne razlike u morfologiji temporomandibularnog zgloba su očekivane.