



Acute binocular diplopia: peripheral or central?

Olympia Kremmyda¹  · Claudia Frenzel¹ · Katharina Hüfner² · Nicolina Goldschagg¹ · Christian Brem³ · Jennifer Linn⁴ · Michael Strupp¹

Received: 21 April 2020 / Revised: 12 July 2020 / Accepted: 14 July 2020
© The Author(s) 2020

Abstract

Objectives Acute diplopia is a diagnostic challenge for clinicians, in particular in the emergency department. The most common cause of acute diplopia are ocular motor nerve palsies (OMP). In this prospective study, we focused on identifying the most crucial signs and symptoms for differentiating between peripheral and central OMP.

Methods We prospectively evaluated 56 non-consecutive patients who presented at our emergency department with acute binocular diplopia (≤ 10 days). The patient history was taken using a standardized questionnaire and patients underwent a neurological, neuro-ophthalmological and neuro-otological examination, including measurement of the subjective visual vertical (SVV), Harms tangent screen test, and cranial MRI.

Results Forty-six out of 56 patients were diagnosed with an ocular motor cranial nerve palsy (OMP), 21 of peripheral and 23 of central origin; in two patients, the etiology remained unknown. The following features were different in peripheral and central OMP: (1) the presence of vertigo/dizziness was more frequent in central (43.5%) than in peripheral (9.5%) OMP. (2) Central ocular motor signs, such as saccadic smooth pursuit, additional internuclear ophthalmoplegia, skew deviation, and saccade palsies, were also found more frequently in the central than in the peripheral group (86.7% vs. 33.3%). (3) Further, a pathological SVV deviation by monocular testing of the non-affected eye was also more common in central (77.3%) than in peripheral OMP (38.9%). The presence of all three factors has a positive predictive value of 100% (CI 50–100%) for the presence of a central lesion.

Conclusions In acute diplopia due to central OMP, the most important accompanying symptom is vertigo/dizziness, and the most important clinical signs are central ocular motor disorders (which require examination of the non-paretic eye) and an SVV deviation in the non-paretic eye.

Keywords Ocular motility · Diplopia, double vision · Vertigo · Ocular motor nerve palsies · Subjective visual vertical

✉ Olympia Kremmyda
olympia.kremmyda@med.uni-muenchen.de

Claudia Frenzel
claudia.frenzel@med.uni-muenchen.de

Katharina Hüfner
katharina.huefner@tirol-kliniken.at

Nicolina Goldschagg
nicolina.goldschagg@med.uni-muenchen.de

Christian Brem
christian.brem@med.uni-muenchen.de

Jennifer Linn
jennifer.linn@uniklinikum-dresden.de

Michael Strupp
michael.strupp@med.uni-muenchen.de

¹ Department of Neurology and German Center for Vertigo and Balance Disorders, Ludwig Maximilian University, Marchioninstr. 15, 81377 Munich, Germany

² Department of Psychiatry, Psychotherapy and Psychosomatics, University Hospital of Psychiatry II, Medical University Innsbruck, Innsbruck, Austria

³ Institute of Neuroradiology, Ludwig Maximilian University, Munich, Germany

⁴ Department of Neuroradiology, University Hospital Carl Gustav Carus, Dresden, Germany

Introduction

Acute diplopia (perception of two different images) accounts for 0.1% of the patients that present at an emergency department [1]. An ocular misalignment of more than 200 μm [2] can cause binocular diplopia [3].

The most common causes of acute binocular diplopia are acute third (CNIII), fourth (CNIV) and sixth (CVI) cranial nerve palsies [1, 4, 5] (ocular motor palsies: OMP). The ocular motor nuclei are located throughout the brainstem, from the midbrain (CNIII) to the pons (CNIV) and the ponto-medullary junction (CNVI). Within the brainstem they have a long (CNIII, CNVI) or short (CNIV) so-called fascicular part [6]. After exiting the brainstem heading towards the eye, they pass through critical structures, such as the cavernous sinus. Because of their complicated anatomy and vicinity to these structures, prompt diagnosis of the localization of the OMP lesion is both very difficult and very important, in particular to diagnose a brainstem stroke. The importance of a prompt diagnosis in the emergency department is shown in a large prospective study [7], where 16% of the 50,000 emergency department visits due to diplopia were due to a life-threatening underlying disease.

There have been several prospective and retrospective studies on the etiologies of acute OMPs, each from a different point of view [5, 8–13]. The underlying diseases range from microvascular to acute life-threatening diseases, although the reported frequencies vary greatly from study to study.

In addition, Dieterich and Brandt have previously shown the important role of measuring mono- and binocular subjective visual verticality in the differentiation between a central and a peripheral lesion [14, 15].

In this study, we focus on the clinical differentiation of peripheral versus central OMPs in the acute phase in an effort to identify signs and symptoms that would assist a non-specialist in the emergency department in making the correct clinical decision regarding further diagnostic procedures and management.

Methods

Over a period of 3 years, we prospectively recruited adult (≥ 18 years) patients from the neurological emergency department of Campus Grosshadern of the Ludwig Maximilian University, Munich, who presented because of acute diplopia. Diplopia had to be present for less than 10 days and be the leading symptom and the main cause for the patient's referral to our department. Patients with

monocular diplopia or binocular diplopia due to known pre-existing causes, such as myasthenia, were excluded from the study.

At the time of presentation, all patients underwent a complete clinical–neurological evaluation and had to answer a study questionnaire regarding their symptoms and presentation of diplopia. Furthermore, blood samples were obtained. A standardized neuro-ophthalmological and neuro-orthoptic examination, including Harms tangent screen [16] and monocular (each eye separately) measurements of the subjective visual vertical (SVV) [14, 15, 17], was performed on the same or the following day. The SVV was measured using either the bucket test or a dome. The SVV test was performed by an experienced orthoptician, who rotated the bucket manually and slowly from a randomized offset position towards zero, alternating between the two directions in each trial. The patient looked with one eye (the other eye was covered with an eye patch) at a straight line visible on the inner bottom of a bucket or of a dome without other visual cues, and had to align it properly, indicating the vertical position verbally. On the outer bottom surface of the bucket, an angular protractor allowed the examiner to readout the tilt angle; when the dome was used, the tilt angle was computed automatically [17]. Central ocular motor signs included saccadic smooth pursuit, saccade palsy, internuclear ophthalmoplegia, and skew deviation (in addition to the ocular motor palsy).

All patients but one (in whom the underlying diagnosis was evident in computed tomography) received an MRI (with DWI and MR angiography) 1–10 days after presentation. Lumbar puncture was performed when clinically indicated and when the cause of the OMP could not be detected in the MRI, meaning that it was performed in all patients with peripheral lesions, except for a patient with posttraumatic trochlear palsy. The final diagnosis was made taking into account all clinical, radiological and laboratory findings.

The patients were then divided into two categories according to their final diagnosis: peripheral or central OMP. Central OMP included both nuclear and fascicular lesions. The criteria for microvascular, peripheral OMP were based on the following criteria, reported earlier [18]: (1) isolated OMP (CNIII pupil sparing), (2) ESR less than 30 mm/hr and normal CRP, (3) age of 50 years or older, and (4) at least one of the cardiovascular risk factors: diabetes, hypertension, hyperlipidemia or smoking.

Fisher's exact test, Chi-square test and Kruskal–Wallis test were used to compare the two groups. Statistical significance was set at $p < 0.05$. Statistical analysis was performed using IBM SPSS Statistics (Version 25.0.1), and calculation of sensitivity, specificity, positive and negative predictive value, and likelihood ratios was performed using vassarstats.net.

Table 1 Etiologies of peripheral and central OMP

Peripheral		Central	
Etiology	#	Etiology	#
Ischemic	9	Ischemic	11
Infection	3	MS	7
Tumor	2	Tumor	3
Neurosarcoidosis	2	Vasculitis	1
Fisher syndrome	1	Cavernoma	1
Traumatic	1		
ACI dissection	1		
IIH	1		
OM	1		
Total	21		23

ACI internal carotid artery, IIH idiopathic intracranial hypertension, OM ophthalmoplegic migraine, MS multiple sclerosis

Results

Fifty-six patients were initially recruited for the study. Ten of them were subsequently excluded after neuro-ophthalmological examination revealed another cause for the diplopia than an OMP (two patients with solely internuclear ophthalmoplegia, five patients with solely skew deviation, one patient with decompensated strabismus, one patient with thyroid disease and one patient with isolated inferior rectus muscle palsy due to IgG4-associated disease).

In the remaining 46 patients, a cause of the palsy could be identified in 44 patients. The two remaining patients had negative MRI and CSF findings and did not fulfill the criteria for any other disease (such as age and presence of cardiovascular risk factors), and were thus not included in the statistical evaluation.

The etiologies of the OMP are summarized in Table 1. Two patients with peripheral OMP (the patient with Fisher syndrome and the patient with idiopathic intracranial hypertension) and one with central OMP (glioma) had bilateral CNVI palsies.

The results of the statistical comparison between the two groups are given in Table 2. The two groups did not differ statistically regarding age or gender. In both groups, CNVI was the most commonly affected, followed by CNIII and CNIV. Pupil involvement was documented in two out of nine patients with peripheral CNIII lesions (one with neuroborreliosis and one with sarcoidosis) and in two out of five patients with central lesions (both strokes).

Both patient groups had their first medical contact on average 2 days after diplopia onset and were seen in our department on the same day or a day later. 70% of the patients had acute onset diplopia, in 23% the diplopia was progressive, and 7% of patients woke up with the symptoms (no difference between groups).

Regarding patients' symptoms, statistical analysis showed that more central OMP patients reported concomitant vertigo or dizziness, whereas headache and/or periorbital pain were reported equally in both groups. Furthermore, both groups did not differ in terms of the presence of other neurological symptoms (such as hypoesthesia and paresthesia).

Regarding the clinical and neuro-ophthalmological findings, 87% of patients with a central OMP had additional central ocular motor deficits (such as spontaneous nystagmus, saccadic smooth pursuit, saccadic palsy on the healthy eye, internuclear ophthalmoplegia or skew deviation that was not justified by the underlying palsy, e.g. in CNVI palsies). 77% of the non-paretic eyes of patients with central OMP showed a pathological $>2.5^\circ$ deviation, which was significantly more than in peripheral OMP (Table 2). One non-paretic eye in one patient with peripheral OMP could not be tested, due to severe congenital amblyopia. The patient groups showed no difference regarding the presence of other neurological signs.

Based on these findings, we calculated the sensitivity, specificity, positive predictive value, and negative predictive value of these three signs and symptoms (vertigo/dizziness, pathological subjective visual vertical in the non-paretic eye—SVVnp—and central ocular motor disorders—Omd) for identifying a central lesion (Table 3).

According to our data, the concomitant presence of all three factors has a 100% specificity (CI 81–100%) and 100% positive predictive value (CI 50–100%). Therefore, a patient with OMP that reports vertigo or dizziness and has pathological SVV and central ocular motor disorder (Omd) on the non-affected eye most likely has a brainstem lesion.

Discussion

The major finding of this study is that a differentiation between a central and a peripheral OMP lesion can be made clinically on the basis of the combination of (a) the patient history (presence of vertigo/dizziness or not), (b) neuro-ophthalmological examination of the non-paretic eye (central ocular motor disorders or not), and (c) measurement of subjective visual verticality on the non-affected eye [14].

In both our groups, CNVI was the most common documented palsy, followed by CNIII and CNIV, which is in line with previous literature [5, 8–13]. Clinically, a central lesion can be assumed with certainty only if the nuclei are involved: CNIII nuclear lesions can cause ipsilateral ophthalmoplegia with upgaze palsy and bilateral ptosis, CNIV nuclear lesions are associated with an ipsilateral Horner's syndrome, and CNVI nuclear lesions with ipsilateral horizontal gaze palsy [19]. Nevertheless, these nerves, especially CNIII and CNVI, have a significant fascicular course through the brainstem [6] that cannot in itself be clinically

Table 2 Clinical characteristics of the peripheral and central OMP groups

	Peripheral	Central	Total	<i>p</i> value
# Patients	21 (47.7%)	23 (52.3%)	44	
Ocular motor cranial nerve palsies	23 (48.9%)	24 (51.1%)	47	
CNIII	9 (39.1%)	5 (20.8%)	14 (29.8%)	0.26
CNIV	4 (17.4%)	3 (12.5%)	7 (14.9%)	
CNVI	10 (43.5%)	16 (66.7%)	26 (55.3%)	
Age ±SD (years)	58.8 ± 14.6	58.9 ± 17.2	58.8 ± 16.5	0.86 [#]
Gender (women)	4 (19.0%)	11 (47.8%)	15 (34.1%)	0.06
First medical contact ±SD (days)	1.8 ± 0.9	2.1 ± 2.2	2.0 ± 2.2	0.46 [#]
Neurological emergency ±SD (days)	2.9 ± 1.7	2.3 ± 2.2	2.5 ± 2.7	0.93 [#]
Manifestation				
Acute	15 (71.4%)	16 (69.6%)	31 (70.5%)	1
Progressive	5 (23.8%)	5 (21.7%)	10 (22.7%)	
Woke up	1 (4.8%)	2 (8.7%)	3 (6.8%)	
Duration of symptoms				
Permanent	18 (85.7%)	19 (82.6%)	37 (84.1%)	0.20
Increasing	2 (9.5%)	0 (0%)	2 (4.5%)	
Fluctuating	1 (4.8%)	4 (17.4%)	5 (11.4%)	
Cardiovascular risk factors	1.6 ± 1.3	1.7 ± 1.4	1.6 ± 1.3	0.80 [#]
Headache/periobital pain	9 (42.9%)	6 (26.1%)	15 (34.1%)	0.34
Vertigo/dizziness	2 (9.5%)	10 (43.5%)	12 (27.3%)	0.0174
Other neurological symptoms	3 (14.3%)	4 (17.4%)	7 (15.9%)	1
Pathological SVV deviation paretic eye	10 (43.5%)	13 (54.2%)	23 (48.9%)	0.58
Pathological SVV deviation non-paretic eye	7 (38.9%)	17 (77.3%)	24 (60.0%)	0.023
Central ocular motor signs	7 (33.3%)	20 (86.7%)	27 (61.4%)	0.0005
Other neurological signs	7 (33.3%)	10 (43.5%)	17 (38.6%)	0.55

Bold indicates statistical significance

p refers to Fisher's exact test for 2×2 tables and Chi square for 3×2 tables, apart from # that refers to the Kruskal–Wallis test

differentiated with the same certainty from purely peripheral lesions.

Separating a brainstem stroke from a microvascular lesion is important for further therapeutic decisions; although secondary prophylaxis is mandatory in stroke, there is no evidence for or against the use of aspirin or oral anticoagulation in microvascular lesions. For example, in a retrospective study, aspirin did not have a protective effect against microvascular OMPs [20].

Although the presence of central ocular motor signs seems at first self-evident in central lesions, examination of the non-paretic eye is in our experience often neglected in clinical routine. Although most studies and reviews studying acute diplopia due to OMP concentrate on the clinical features of the paretic eye, our study further emphasizes the importance of a systematic examination of the central ocular motor system (saccades, smooth pursuit, cover test to unmask a skew deviation) in the non-paretic eye to detect a

Table 3 Diagnostic performance of central ocular motor disorder (Omd), SVV deviation in the non-paretic eye (SVVnp) and vertigo/dizziness (V/D) for detecting central OMP

	Sensitivity	Specificity	PPV	NPV	LR+	LR–
Central OMP with Omd	0.87 (0.37–0.67)	0.67 (0.43–0.84)	0.74 (0.53–0.88)	0.82 (0.56–0.95)	2.61 (1.39–4.87)	0.19 (0.06–0.59)
Central OMP with SVVnp	0.77 (0.54–0.91)	0.61 (0.36–0.81)	0.71 (0.49–0.87)	0.69 (0.41–0.88)	1.98 (1.07–3.70)	0.37 (0.16–0.86)
Central OMP with V/D	0.43 (0.24–0.65)	0.90 (0.68–0.98)	0.83 (0.51–0.97)	0.59 (0.40–0.76)	4.57 (1.13–18.5)	0.62 (0.43–0.90)
Central OMP with all three factors	0.35 (0.17–0.57)	1 (0.81–1)	1 (0.50–1)	0.58 (0.41–0.74)	Infinity	0.65 (0.48–0.88)

PPV positive predictive value, NPV negative predictive value, LR+ positive likelihood ratio, LR– negative likelihood ratio

brainstem lesion [21]. The centers for ocular motor and vestibular control are abundant throughout the brainstem [22] and adjacent to the ocular motor nerve nuclei and fascicles. Therefore, a central brainstem lesion that affects them is also very likely to cause further central ocular motor deficits. Over the last years, clinical examination of the ocular motor system has been shown to be superior to MRI in identifying brainstem lesions [23–25], especially because ischemic brainstem lesions are often only detectable in the DWI more than 72 h after symptom onset [26]. Central ocular motor signs on the non-paretic eye are nevertheless not sufficient in themselves, since in our peripheral group 33.3% of all patients had central ocular motor signs (mostly saccadic smooth pursuit), which could be pre-existent in many of them.

A significant SVV deviation during binocular testing is considered to be a sign of dysfunction in the graviceptive pathways [27]. The importance of monocular SVV testing for the differentiation of acute brainstem lesions from peripheral ocular motor palsies was already described before [14, 15]. In a retrospective study [14], about 40% of peripheral OMP showed a pathological SVV deviation in the affected eye during monocular testing, which was attributed to changes in visual perception through a lack of afferent extra-retinal information that codes the eye position in space. A pathological SVV in the non-paretic eye was previously documented only in chronic peripheral OMP [14] as a sign of central compensation for the contralateral palsy or in acute vascular brainstem lesions, representing an additional vestibular deficit in the roll plane [15].

The current work prospectively compares directly monocular SVV testing in acute peripheral versus central OMP. Monocular SVV deviation ($>2.5^\circ$) was observed in about 50% of all paretic eyes, independent of the localization of the lesion and the type of palsy. Regarding the non-paretic eye, pathologic SVV deviation was found in 77% of central lesions. This could be attributed to concomitant lesions in the graviceptive vestibular pathways that are anatomically adjacent to the ocular motor nuclei and fascicles [28]. In accordance with this, vertigo/dizziness were also reported more often in central than in peripheral OMP in our study. The patients with peripheral palsies described the sensation as dizziness. In the central group, one patient described a rotational vertigo sensation and two a falling tendency to one side (one to the right and one to the left), the rest described a dizziness sensation as well.

Surprisingly, there was also a small percentage of patients with peripheral OMP that showed a pathological SVV deviation when tested monocularly while viewing with the non-affected eye. In these patients, the pathological SVV deviation could be attributed either to an early compensation (like in the chronic OMP lesions [14]) or to

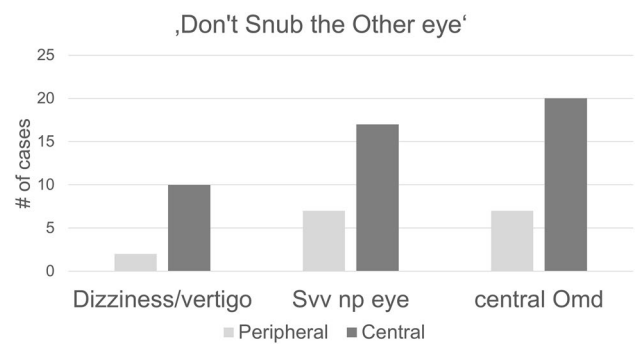


Fig. 1 Number of positive cases of Dizziness/vertigo, SVV deviation and central Ocular motor disorder (Omd) in the non-paretic eye. The initials (DSO) can be remembered using the mnemonic device “Don’t Snub the Other eye”

an additional subclinical peripheral lesion in the seemingly healthy eye caused by a systemic disease, e.g. infection or sarcoidosis. Therefore, pathological SVV deviation in the clinically unaffected eye would justify further diagnostic steps (e.g. MRI, lumbar puncture), even if the OMP itself is clearly peripheral. The bedside examination of the SVV can be easily done using the bucket test [17].

Although pain is often postulated to be a feature of microvascular, peripheral OMP [29], patients with central lesions reported pain and ipsilateral headache as often as patients with peripheral palsy, especially when the central palsies were associated with a brainstem mass. There were no significant differences in the character of pain between the two groups; especially in the peripheral group, the pain was often described as diffuse and not strictly periorbital in our view. These findings undermine the significance of pain as the most significant diagnostic factor for a purely peripheral OMP.

The presence of other neurological signs did not exclude a peripheral lesion. Our patients with peripheral palsies also reported other neurological signs, such as hypesthesia, usually when the underlying disease affected other peripheral nerves, such as in the patient with Fisher syndrome.

Pupil sparing in CNIII palsy is usually considered a peripheral sign. In our study though, three out of five patients with central OMP did not have pupil involvement, which can be the case when the lesion is fascicular [3, 30]. On the other hand, two out of nine peripheral patients with CNIII palsy (due to sarcoidosis and neuroborreliosis) had pupil involvement.

The main findings are summed up in Fig. 1. Based on our data, we suggest the phrase (D)on’t (S) nub the (O)ther Eye (Dizziness, SVV and Ocular motor disorder of the non-paretic eye) as a mnemonic device for remembering these three factors that can assist the clinician in differentiating between acute peripheral and central OMP.

Acknowledgements Open Access funding provided by Projekt DEAL. We would like to thank Katie Göttlinger for copyediting the manuscript.

Author contributions OK: Department of Neurology and German Center for Vertigo and Balance Disorders (DSGZ), Ludwig-Maximilian University, Munich, Campus Grosshadern, Munich, Germany: author, conception of the study, designing of questionnaire, interpretation of the data, statistical analysis, and drafted the manuscript. CF: Department of Neurology and German Center for Vertigo and Balance Disorders (DSGZ), Ludwig-Maximilian University, Munich, Campus Grosshadern, Munich, Germany: author, conception of the study, acquisition and interpretation of the data, and revision of the manuscript. KH: Department of Psychiatry, Psychotherapy and Psychosomatics, University Hospital of Psychiatry II, Medical University Innsbruck, Innsbruck, Austria: author, conception of the study and acquisition of the data, and revision of the manuscript. NG: Department of Neurology and German Center for Vertigo and Balance Disorders (DSGZ), Ludwig-Maximilian University, Munich, Campus Grosshadern, Munich, Germany: author, acquisition of the data, revision of the manuscript. CB: Institute of Neuroradiology, Ludwig-Maximilian University, Munich, Campus Grosshadern, Munich, Germany: author, acquisition and interpretation of the data, and revision of the manuscript. JL: Department of Neuroradiology, University Hospital Carl Gustav Carus, Dresden, Germany: author, conception of the study and acquisition of the data, and revision of the manuscript. MS: Department of Neurology and German Center for Vertigo and Balance Disorders (DSGZ), Ludwig-Maximilian University, Munich, Campus Grosshadern, Munich, Germany: author, conception of the study, designing of the questionnaire, analysis, interpretation of the data, and drafted the manuscript

Funding This work was supported by the German Ministry of Education and Research (BMBF), Grant no. 01EO0901 to the German Center for Vertigo and Balance Disorders. No industry sponsorship was acquired.

Data availability statement The anonymized data can be shared by request from any qualified investigator for purposes of replicating procedures and results.

Compliance with ethical standards

Conflicts of interest The authors report no conflict of interest.

Declarations M. Strupp is Joint Chief Editor of the Journal of Neurology, Editor in Chief of Frontiers of Neuro-otology and Section Editor of F1000. He has received speaker's honoraria from Abbott, Actelion, Auris Medical, Biogen, Eisai, Grünenthal, GSK, Henning Pharma, Interacoustics, Merck, MSD, Otometrics, Pierre-Fabre, TEVA, and UCB. He is a shareholder of IntraBio. He acts as a consultant for Abbott, Actelion, AurisMedical, Heel, IntraBio and Sensorion. He is the distributor of M glasses. O.Kremmyda, C. Frenzel, C. Brem, K. Hüfner, N. Goldschagg, and J. Linn report no disclosures.

Ethical approval The study was performed in accordance with the Declaration of Helsinki and was approved by the ethics committee of the LMU Medical Faculty (Study Number: 314-10).

Informed consent All patients signed a written informed consent form before participating in the study.

Open Access This article is licensed under a Creative Commons Attribution 4.0 International License, which permits use, sharing, adaptation, distribution and reproduction in any medium or format, as long

as you give appropriate credit to the original author(s) and the source, provide a link to the Creative Commons licence, and indicate if changes were made. The images or other third party material in this article are included in the article's Creative Commons licence, unless indicated otherwise in a credit line to the material. If material is not included in the article's Creative Commons licence and your intended use is not permitted by statutory regulation or exceeds the permitted use, you will need to obtain permission directly from the copyright holder. To view a copy of this licence, visit <http://creativecommons.org/licenses/by/4.0/>.

References

1. Nazerian P, Vanni S, Tarocchi C, Portaccio E, Vannucci N, Para O, Giannazzo G, Gigli C, Grifoni S (2014) Causes of diplopia in the emergency department: diagnostic accuracy of clinical assessment and of head computed tomography. *Eur J Emerg Med* 21(2):118–124. <https://doi.org/10.1097/MEJ.0b013e3283636120>
2. Cornblath WT (2014) Diplopia due to ocular motor cranial neuropathies. *Continuum (Minneapolis)* 20(4):966–980. <https://doi.org/10.1212/01.CON.0000453309.44766.b4>
3. Rucker JC, Tomsak RL (2005) Binocular diplopia. A practical approach. *Neurologist* 11(2):98–110. <https://doi.org/10.1097/01.nrl.0000156318.80903.b1>
4. Comer RM, Dawson E, Plant G, Acheson JF, Lee JP (2007) Causes and outcomes for patients presenting with diplopia to an eye casualty department. *Eye (Lond)* 21(3):413–418. <https://doi.org/10.1038/sj.eye.6702415>
5. O'Colmain U, Gilmour C, MacEwen CJ (2014) Acute-onset diplopia. *Acta Ophthalmol* 92(4):382–386. <https://doi.org/10.1111/aos.12062>
6. Kirsch CF, Black K (2017) Diplopia: what to double check in radiographic imaging of double vision. *Radiol Clin N Am* 55(1):69–81. <https://doi.org/10.1016/j.rcl.2016.08.008>
7. De Lott LB, Kerber KA, Lee PP, Brown DL, Burke JF (2017) Diplopia-related ambulatory and emergency department visits in the United States, 2003–2012. *JAMA Ophthalmol* 135(12):1339–1344. <https://doi.org/10.1001/jamaophthalmol.2017.4508>
8. Park UC, Kim SJ, Hwang JM, Yu YS (2008) Clinical features and natural history of acquired third, fourth, and sixth cranial nerve palsy. *Eye (Lond)* 22(5):691–696. <https://doi.org/10.1038/sj.eye.6702720>
9. Tamhankar MA, Biousse V, Ying GS, Prasad S, Subramanian PS, Lee MS, Eggenberger E, Moss HE, Pineles S, Bennett J, Osborne B, Volpe NJ, Liu GT, Bruce BB, Newman NJ, Galetta SL, Balcer LJ (2013) Isolated third, fourth, and sixth cranial nerve palsies from presumed microvascular versus other causes: a prospective study. *Ophthalmology* 120(11):2264–2269. <https://doi.org/10.1016/j.ophtha.2013.04.009>
10. Choi KD, Choi SY, Kim JS, Choi JH, Yang TH, Oh SY, Kim SH, Lee HS, Lee SH, Jeong SH, Kim HJ, Choi JY (2019) Acquired ocular motor nerve palsy in neurology clinics: a prospective multicenter study. *J Clin Neurol* 15(2):221–227. <https://doi.org/10.3988/jcn.2019.15.2.221>
11. Jung JS, Kim DH (2015) Risk factors and prognosis of isolated ischemic third, fourth, or sixth cranial nerve palsies in the Korean population. *J Neuroophthalmol* 35(1):37–40. <https://doi.org/10.1097/WNO.0000000000000214>
12. Chou KL, Galetta SL, Liu GT, Volpe NJ, Bennett JL, Asbury AK, Balcer LJ (2004) Acute ocular motor mononeuropathies: prospective study of the roles of neuroimaging and clinical assessment. *J Neurol Sci* 219(1–2):35–39. <https://doi.org/10.1016/j.jns.2003.12.003>

13. Merino P, Fuentes D, Gomez de Liano P, Ordenez MA (2017) Binocular diplopia in a tertiary hospital: aetiology, diagnosis and treatment. *Arch Soc Esp Ophthalmol* 92(12):565–570. <https://doi.org/10.1016/j.oftal.2017.05.008>
14. Dieterich M, Brandt T (1993) Ocular torsion and perceived vertical in oculomotor, trochlear and abducens nerve palsies. *Brain* 116(Pt 5):1095–1104
15. Dieterich M, Brandt T (1993) Ocular torsion and tilt of subjective visual vertical are sensitive brainstem signs. *Ann Neurol* 33(3):292–299. <https://doi.org/10.1002/ana.410330311>
16. Tyedmers M, Roper-Hall G (2006) The harms tangent screen test. *Am Orthopt J* 56:175–179. <https://doi.org/10.3368/aoj.56.1.175>
17. Zwergal A, Rettinger N, Frenzel C, Dieterich M, Brandt T, Strupp M (2009) A bucket of static vestibular function. *Neurology* 72(19):1689–1692. <https://doi.org/10.1212/WNL.0b013e3181a55ecf>
18. Galtrey CM, Schon F, Nitkunan A (2015) Microvascular non-arteritic ocular motor nerve palsies-what we know and how should we treat? *Neuroophthalmology* 39(1):1–11. <https://doi.org/10.3109/01658107.2014.963252>
19. Buracchio T, Rucker JC (2007) Pearls and oysters of localization in ophthalmoparesis. *Neurology* 69(24):E35–40. <https://doi.org/10.1212/01.wnl.0000291013.26249.74>
20. Johnson LN, Stetson SW, Krohel GB, Cipollo CL, Madsen RW (2000) Aspirin use and the prevention of acute ischemic cranial nerve palsy. *Am J Ophthalmol* 129(3):367–371
21. Strupp M, Kremmyda O, Adamczyk C, Bottcher N, Muth C, Yip CW, Bremova T (2014) Central ocular motor disorders, including gaze palsy and nystagmus. *J Neurol* 261(Suppl 2):S542–558. <https://doi.org/10.1007/s00415-014-7385-9>
22. Büttner U, Büttner-Ennever JA (2006) Present concepts of oculomotor organization. *Prog Brain Res* 151:1–42. [https://doi.org/10.1016/S0079-6123\(05\)51001-X](https://doi.org/10.1016/S0079-6123(05)51001-X)
23. Cnyrim CD, Newman-Toker D, Karch C, Brandt T, Strupp M (2008) Bedside differentiation of vestibular neuritis from central "vestibular pseudoneuritis". *J Neurol Neurosurg Psychiatry* 79(4):458–460. <https://doi.org/10.1136/jnnp.2007.123596>
24. Kattah JC, Talkad AV, Wang DZ, Hsieh YH, Newman-Toker DE (2009) HINTS to diagnose stroke in the acute vestibular syndrome: three-step bedside oculomotor examination more sensitive than early MRI diffusion-weighted imaging. *Stroke* 40(11):3504–3510. <https://doi.org/10.1161/STROKEAHA.109.551234>
25. Saber Tehrani AS, Kattah JC, Mantokoudis G, Pula JH, Nair D, Blitz A, Ying S, Hanley DF, Zee DS, Newman-Toker DE (2014) Small strokes causing severe vertigo: frequency of false-negative MRIs and nonlacunar mechanisms. *Neurology* 83(2):169–173. <https://doi.org/10.1212/WNL.0000000000000573>
26. Choi JH, Oh EH, Park MG, Baik SK, Cho HJ, Choi SY, Lee TH, Kim JS, Choi KD (2018) Early MRI-negative posterior circulation stroke presenting as acute dizziness. *J Neurol* 265(12):2993–3000. <https://doi.org/10.1007/s00415-018-9097-z>
27. Dieterich M, Brandt T (2019) Perception of verticality and vestibular disorders of balance and falls. *Front Neurol* 10:172. <https://doi.org/10.3389/fneur.2019.00172>
28. Zwergal A, Büttner-Ennever J, Brandt T, Strupp M (2008) An ipsilateral vestibulothalamic tract adjacent to the medial lemniscus in humans. *Brain* 131(Pt 11):2928–2935. <https://doi.org/10.1093/brain/awn201>
29. Wilker SC, Rucker JC, Newman NJ, Biousse V, Tomsak RL (2009) Pain in ischaemic ocular motor cranial nerve palsies. *Br J Ophthalmol* 93(12):1657–1659. <https://doi.org/10.1136/bjo.2008.155150>
30. Kang MJ, Shin DJ, Choi KD, Kim JS, Shin DH (2016) Pupil-sparing isolated fascicular third cranial nerve palsy due to infarction: report of a case and literature review. *J Neurol Disord* 4(7):1–4