

Alopecia Fibrosante em Padrão de Distribuição Androgenética: Patogénese, Diagnóstico e Tratamento

A. Marcos-Pinto¹, G. De Caprio², R. Oliveira Soares³ 

¹Clínica Universitária de Dermatologia, Hospital de Santa Maria, Lisboa, Portugal.

²Departamento de Dermatologia, Hospital Heliópolis- São Paulo, Brasil

³Departamento de Dermatologia, Hospital CUF Descobertas, Lisboa, Portugal.

RESUMO – Alopecia fibrosante em padrão de distribuição androgenética é uma forma clínica de alopecia cicatricial recentemente reconhecida, manifestando-se por rarefação de cabelo na área dependente de androgénios. Ausência de orifícios foliculares, eritema e hiperqueratose peri-pilar, e anisotriquia são as pistas em tricoscopia e o infiltrado inflamatório liquenóide folicular achado importante em histopatologia. Partilha características de alopecia androgenética e líquen plano pilar. Os dermatologistas devem estar familiarizados com esta entidade, a fim de otimizar o diagnóstico e tratar precocemente, evitando dano folicular irreversível.

PALAVRAS-CHAVE – Alopecia/diagnóstico; Alopecia/epidemiologia; Alopecia/tratamento farmacológico; Fibrose.

Fibrosing Alopecia in a Pattern Distribution: Pathogenesis, Diagnosis and Treatment

ABSTRACT – Fibrosing alopecia in a pattern distribution is a recently recognized type of scarring alopecia, with hair loss in androgens-dependent area. Loss of follicular openings, perifollicular erythema, perifollicular hyperkeratosis and anisotriquia are the trichoscopic clues and follicular lichenoid inflammatory infiltrate the important finding in histopathology. It shares features of androgenetic alopecia and lichen planopilaris. Dermatologists should be familiarized with this entity in order to optimize the diagnosis and provide early treatment to prevent irreversible follicular damage.

KEYWORDS – Alopecia/diagnosis; Alopecia/drug therapy; Alopecia/epidemiology; Fibrosis.

INTRODUCTION

Fibrosing alopecia in a pattern distribution (FAPD) was initially described by Zinkernagel and Trueb in 2000,¹ as a distinct type of lymphocytic scarring alopecia. It is characterized by a combination of clinical, trichoscopic and histopathological features of both lichen planopilaris (LPP) and androgenetic alopecia (AGA).^{1,2-11} FAPD may also coexist with frontal fibrosing alopecia (FFA).²

AGA is the most common form of non-scarring alopecia, caused by hair thinning on androgen dependent scalp.³ In women, most often, a diffuse hair loss occurs in all androgenetic area with maintenance of the frontal hairline (Ludwig pattern). Male pattern is characterized by bi-temporal

recession of the frontal hairline, followed by diffuse thinning at the vertex (Hamilton-Norwood pattern).³

Classic LPP is an immune-mediated alopecia with chronic lymphocytic inflammation that leads to the selective destruction of hair follicles, resulting in scarring alopecia, with hair loss in patchy areas.⁴ FFA was once considered a subtype of LPP with selective involvement of the frontal-temporal hairline and eyebrows, but nowadays is considered a separate clinical entity.⁵

In FAPD, unlike LPP, we find vellus hair and hair loss in a pattern distribution involving the androgen-dependent scalp (similar to AGA). Unlike AGA, we find many focal areas of cicatricial alopecia, peripilar erythema and peripilar

Correspondência: Ana Marcos Pinto

Clínica Universitária de Dermatologia

Hospital de Santa Maria

Av. Prof. Egas Moniz

1649-028 Lisboa, Portugal

E-mail: anamarcos.pinto@gmail.com

DOI: <https://dx.doi.org/10.29021/spdv.78.3.1222>

Recebido/Received

2020/05/26

Aceite/Accepted

2020/07/18

Publicado/Published

2020/09/30

© Autor (es) (ou seu (s) empregador (es)) 2020 Revista SPDV. Reutilização permitida de acordo com CC BY-NC. Nenhuma reutilização comercial.

© Author(s) (or their employer(s)) 2020 SPDV Journal. Re-use permitted under CC BY-NC. No commercial re-use.

Artigo de Revisão

hyperkeratosis in trichoscopy and lichenoid inflammation in histopathology.^{1,2,6-9}

It has been first described in Caucasians but may also affect Hispanics and African-descents.^{2,6,9} It is more common in women, most often in post-menopause or peri-menopause. It is rare in men and may develop at a younger age.^{2,6,9,11-15}

This entity may easily be misdiagnosis as AGA with concurrent seborrheic dermatitis, with delay in the diagnosis and consequent fibrosis progression, leading to irreversible alopecia.

PATHOGENESIS

It has been suggested that FAPD is a variant of LPP¹⁰ or a lichenoid scarring variant of AGA.¹¹ The last hypothesis is favored by the variable peri-follicular micro-inflammation observed in histopathology in many cases of AGA. The cause for the location of a lichenoid infiltrate primarily around miniaturized hair follicles is unknown. Some authors propose that the damaged hair follicles may express different cytokines, initiating a repairing inflammatory process or an apoptosis-mediated organ deletion.^{2,6} Others suggest that the lichenoid reaction may be caused by unknown antigenic stimulus on altered AGA hair follicles in immunogenetically susceptible patients.^{2,8} Androgens may play a role, considering that anti-androgen therapy decreases scalp inflammation in some cases and stabilizes hair loss progression.^{2,9,10}

There is one report of familial occurrence of FFA and FAPD in both mother and daughter, suggesting nosological relationship between the two conditions with respect to both the androgenetic background and the inflammatory reaction pattern.^{10,13} Further studies are necessary to understand the pathophysiology of FAPD.

DIAGNOSIS

FAPD can be diagnosed by combination of physical exam, trichoscopy and histopathology. The main differential diagnoses are AGA, AGA plus seborrheic dermatitis and classic LPP.

Clinically, FAPD presents with patterned hair loss involving androgen dependent scalp - Ludwig pattern in women (Fig. 1) and Hamilton-Norwood pattern in men – with slowly progressive course. Some patients complain of scalp symptoms such as dysesthesia, pain, burning sensation and pruritus.^{2,16} Physical exam reveals low hair density and sometimes peri-follicular erythema, follicular hyperkeratosis and absence of follicular openings may be detected by open eye.^{2,9} Rare skin findings are frontal hairline recession similar to FFA, red dots in reticulated pattern on the chest and facial papules.^{2,17,18} FAPD may affect the eyebrows, but unlike FFA, FAPD is not known to affect eyelashes or other body hair.^{17,18} Patchy or asymmetric hair loss should be excluded for the diagnosis of FAPD.²

Regarding trichoscopy, the most important distinguishing findings between FAPD (Fig. 2) and AGA (Fig. 3) are loss of follicular openings, perifollicular erythema, and perifollicular hyperkeratosis. The last may have a tubular

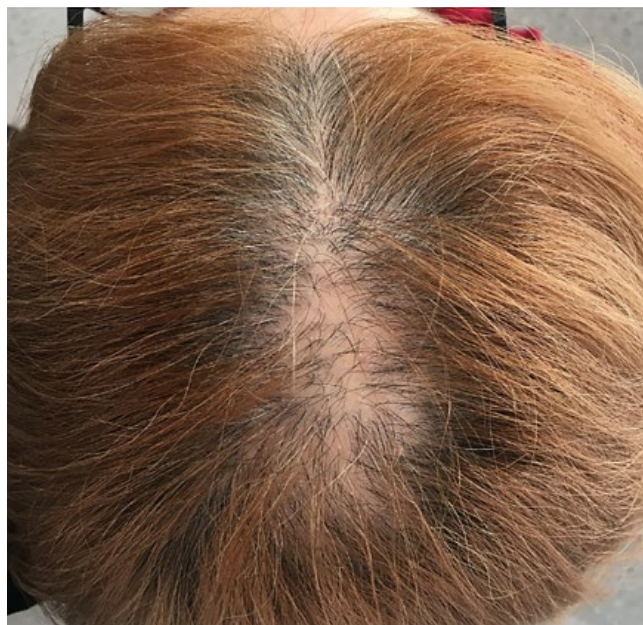

Figure 1 - FAPD in a 60-year-old woman, with hair loss on the crown resembling androgenetic alopecia.

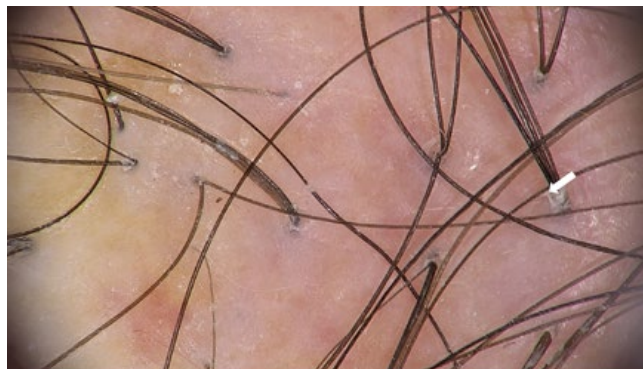

Figure 2 - FAPD Trichoscopy: coexistence of vellus and terminal hair, mild peripilar scaling activity, with peripilar casts surrounding the emergence of tuft of 4 hairs (white arrow), mild interperilar erythema and micro-islands with no follicular orifices (scarring alopecia).

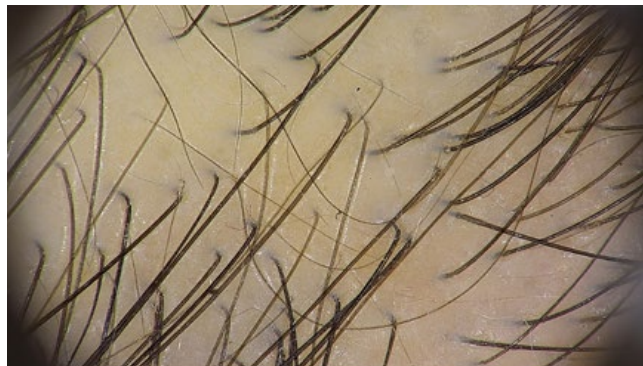

Figure 3 - AGA Trichoscopy: anisotrichia greater than 20%, without peripilar activity.



Figure 4 - Trichoscopy: absence of follicular orifices in a large extension of the field (cicatricial alopecia), mild inter-pilar erythema and marked peripilar activity, consisting of circumferential desquamation (peripilar casts) and follicular plugs. Note the absence of vellus hair.

shape around the hair: peripilar casts. When surrounding the emergence of a tuft of 2-3 hairs, they are very typical and represents the optimal biopsy site for histologic diagnosis.^{2,6-9} Other trichoscopic features are common to AGA, like hair diameter variability and predominance of single hair follicles. The presence of vellus hair in FAPD helps to distinguish it from classic LPP (Fig. 4). In patients with dark skin, a honeycomb pigmented network and scattered white small patches may also be seen, similar in presentation to what is seen in central centrifugal cicatricial alopecia (CCCA).^{2,9} Dermoscopy alone may not be sufficient to distinguish between CCCA and FAPD in dark-skinned patients.

Skin biopsy is important to confirm diagnosis and may be performed with a 4-mm punch biopsy, guided by trichoscopy and processed with horizontal sections. The best locations are peripilar casts. In early lesions, we find a lymphohistiocytic infiltrate surrounding the hair follicle in the isthmus and infundibular regions and follicular interface dermatitis, with vacuolar degeneration of the follicular epitheliocytes. Interface dermatitis in inter-follicular epidermis is rarely found and lower portions of the follicles, including the hair bulbs, are usually spared. Advanced lesions show concentric peri-follicular lamellar fibrosis (Fig. 5) and fibrosed follicular tracts.^{2,6-13,16,17} There is hair follicle miniaturization, apoptosis of the basal keratinocytes and a decrease in sebaceous gland number.^{2,6} In FAPD, the follicular lichenoid reaction affects both miniaturized and non-miniaturized follicles in the affected scalp.²

Combination of clinical pattern, trichoscopy and histopathology differentiates FAPD from AGA or classic LPP (Table 1).^{6,11,14} The distinction between FAPD and AGA with seborrheic dermatitis is easy, because in the latter the scales are observed in the inter-pilar spaces and the follicular openings are present. The difference is important, especially in cases in which hair transplantation is being considered, because patients with FAPD, similarly to those with LPP, might not be good candidates for the procedure due to the potential risk of loss of the transplanted hair.²

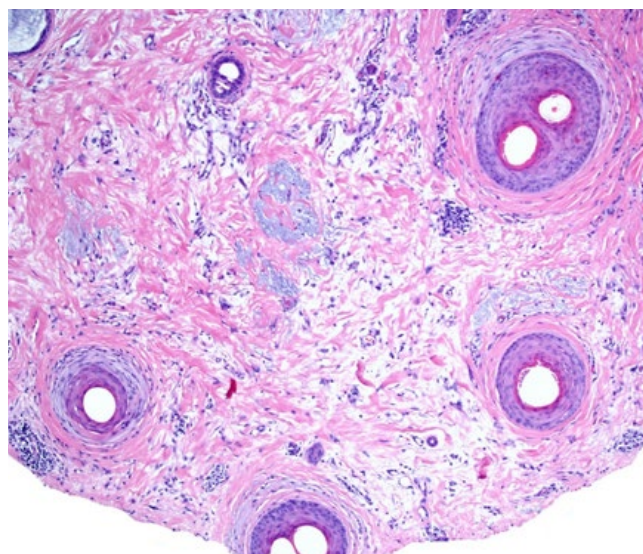


Figure 5 - FAPD Histopathology: several follicles show perifollicular fibrosis and mild lichenoid infiltrate at the upper follicular level. Note the involvement of a vellus follicle. (horizontal sections, Hematoxylin and eosin, x10). Courtesy of Dr. Maryia Miteva (Miami University).

TREATMENT

There are few available data, limited to small retrospective studies and case reports.

The primary treatment goal is to stabilize the progression of hair loss and a secondary goal is to achieve hair regrowth. However, substantial improvement in advanced disease is impossible. Available agents aim to decrease inflammation and reverse miniaturization.

Topical corticosteroids are the mostly used anti-inflammatory drugs, improving scalp symptoms alone and stabilizing hair loss in combination with other agents. Only in one case, stabilization in hair loss with topical clobetasol alone was reported.^{19,20} Topical 0.05% clobetasol propionate (as foam, solution, and shampoo) has been successfully used combined with 5% minoxidil.¹⁶ Triamcinolone acetonide 0.2% solution used in combination with 5% topical minoxidil has also been a successful maintenance therapy.¹⁷

Oral hydroxychloroquine is commonly used in both FFA and LPP. A few data point its potential benefit in FAPD in daily dose of 200-400 mg combined with topical therapy with clobetasol propionate and 5% minoxidil.^{2,16,17}

Minoxidil is a hair growth promoter, thickening miniaturized hairs and is often used as complementary treatment in scarring alopecias. In FAPD, topical minoxidil is always used in combination with other agents to stabilize hair loss.^{1,16,17} There are no data about using oral minoxidil in FAPD.

Antiandrogens drugs, even in monotherapy, may stabilize the disease. One man treated with 1 mg daily finasteride presented both decreased inflammation and hair loss.¹ Finasteride seems to be beneficial in women with FAPD

Artigo de Revisão

Table 1 - Differential diagnosis of FAPD. AGA, androgenetic alopecia; FAPD, fibrosing alopecia in a pattern distribution; LPP, lichen planopilaris.

	AGA	Classic LPP	FAPD
Type	Non-scarring	Scarring	Scarring
Clinical Presentation	Alopecia in the androgen dependent scalp Men: Bitemporal and crown areas (Hamilton-Norwood pattern) Women: Crown and frontal areas (Ludwig pattern) No scalp symptoms	Patches of scarring alopecia occur anywhere on the scalp Scalp symptoms (pain, burning sensation) are frequent	Pattern distributed alopecia similar to as AGA Scalp symptoms (pain, burning sensation) can occur
Trichoscopy	- Hair diameter diversity - Perifollicular pigmentation / peripilar sign - Yellow dots	- Absence of vellus hair - Loss of follicular openings - Perifollicular erythema or/and perifollicular keratosis (peripilar casts) in multifocal scalp areas - White dots	- Hair diameter diversity - Loss of follicular openings - Perifollicular erythema and perifollicular keratosis (peripilar casts) limited to the area of androgenetic hair loss. - Hair tufting
Histopathology	- Miniaturized hair follicle - No interface dermatitis	- Lichenoid inflammation predominantly targeting isthmus and infundibular region of terminal hair follicle - Interface dermatitis in interfollicular epidermis	- Miniaturized hair follicle - Lichenoid inflammation selectively targeting isthmus and infundibular region of miniaturized hair follicle - No interface dermatitis in interfollicular epidermis

refractory to topical therapy with minoxidil and clobetasol.^{2,16} There are two successful cases of women treated with oral cyproterone acetate combined with topical 5% minoxidil and clobetasol propionate,¹ but recently there is concern about the association between oral cyproterone acetate and the occurrence of meningioma.¹⁹⁻²¹

Although topical retinoids may contribute to hair regrowth in patients with AGA, in FAPD no benefit was observed.²

CONCLUSION

FAPD is an entity to consider in the differential diagnoses of scarring alopecias. The scalp shows features of both LPP and AGA. Clinical findings, trichoscopic features and histopathology allows us to distinguish between them. Early recognition and proper treatment allow disease stabilization and avoid permanent follicular hair damage.

KEY-POINTS

- Fibrosing alopecia in a pattern distribution is a scarring alopecia with lichenoid inflammation involving miniaturized hair, in androgen-dependent scalp.
- Clues for diagnosis are hair loss resembling androgenetic alopecia and trichoscopic findings of peripilar casts and loss of follicular openings.
- Anti-inflammatory agents in combination with hair growth promoters and/or anti-androgen drugs can stabilize the disease decreasing hair loss.

Conflitos de interesse: Os autores declaram a inexistência de conflitos de interesse na realização do presente trabalho.

Fontes de financiamento: Não existiram fontes externas de financiamento para a realização deste artigo.

Consentimento: Consentimento do doente para publicação obtido.

Proveniência e revisão por pares: Não comissionado; revisão externa por pares.

Conflicts of interest: The authors have no conflicts of interest to declare.

Financing support: This work has not received any contribution, grant or scholarship.

Patient Consent: Consent for publication was obtained.

Provenance and peer review: Not commissioned; externally peer reviewed

 ORCID

A. Marcos-Pinto

<https://orcid.org/0000-0003-3477-0065>

G. De Caprio

<https://orcid.org/0000-0003-3688-0268>

REFERENCES

1. Zinkernagel MS, Trüeb RM. Fibrosing alopecia in a pattern distribution: patterned lichen planopilaris or androgenetic alopecia with a lichenoid tissue reaction pattern? Arch Dermatol.2000;136:205-11.

2. Griggs J, Trüeb RM, Gavazzoni Dias MF, Hordinsky M, Tosti A. Fibrosing alopecia in a pattern distribution. *J Am Acad Dermatol*. 2020 (in press). doi: 10.1016/j.jaad.2019.12.056
3. Piraccini BM, Alessandrini A. Androgenetic alopecia. *G Ital Dermatol Venereol*. 2014;149:15-24.
4. Kang H, Alzolibani AA, Otberg N, Shapiro J. Lichen planopilaris. *Dermatol Ther*.;21:249-56
5. Iorizzo M, Tosti A. Frontal fibrosing alopecia: an update on pathogenesis, diagnosis, and treatment. *Am J Clin Dermatol*. 2019;20:379-90. doi: 10.1007/s40257-019-00424-y.
6. Amato L, Chiarini C, Berti S, Bruscinò P, Fabbri P. Case study: fibrosing alopecia in a pattern distribution localized on alopecia androgenetica areas and unaffected scalp. *Skinmed*. 2004;3:353-5.
7. Olsen EA. Female pattern hair loss and its relationship to permanent/cicatricial alopecia: a new perspective. *J Invest Dermatol Symp Proc*. 2005;10:217-21.
8. Triyankulsri K, Srisuwanwattana P, Sriphojanart T, Suchonwanit P. Fibrosing Alopecia in a Pattern Distribution: A Case Report and Literature Review. *Case Rep Dermatol*. 2019;11:297-302. doi: 10.1159/000503681.
9. Teixeira MS, Gavazzoni Dias MF, Trüeb RM, Rochael MC, Vilar EA. Fibrosing Alopecia in a Pattern Distribution (FAPD) in 16 African-Descent and Hispanic Female Patients: A Challenging Diagnosis. *Skin Appendage Disord*. 2019;5:211-5. doi: 10.1159/000496837.
10. Bhoyrul DB. Cicatricial pattern hair loss is not a variant of lichen planopilaris. *J Am Acad Dermatol*. 2020 (in press). doi: 10.1016/j.jaad.2020.03.125.
11. Katoulis AC, Diamanti K, Sgouros D, Liakou AI, Bozi E, Avgerinou G, et al. Is there a pathogenetic link between frontal fibrosing alopecia, androgenetic alopecia and fibrosing alopecia in a pattern distribution? *J Eur Acad Dermatol Venereol*. 2018;32:e218-e220.
12. Tawfik SS, Sorour OA, Alariny AF, Elmorsy EH, Moneib H. White and yellow dots as new trichoscopic signs of severe female androgenetic alopecia in dark skin phototypes. *Int J Dermatol*. 2018;57:1221-8.
13. Missio DM, Dias MFRG, Trüeb RM. Familial Cicatricial Alopecia: Report of Familial Frontal Fibrosing Alopecia and Fibrosing Alopecia in a Pattern Distribution. *Int J Trichology*. 2017;9:130-4. doi: 10.4103/ijt.ijt_59_17.
14. Elise A, Olsen. Female Pattern Hair Loss and its Relationship to Permanent/Cicatricial Alopecia: A New Perspective. *J Invest Dermatol Symp Proc*. 2005; 10:217-21.
15. Chiu HY, Lin SJ. Fibrosing alopecia in a pattern distribution. *J Eur Acad Dermatol Venereol*. 2010;24:1113-4. doi: 10.1111/j.1468-3083.2010.03580.x.
16. Mardones F, Hott K, Martinez MC. Clinical study of fibrosing alopecia in a pattern distribution in a Latin American population. *Int J Dermatol*. 2018;57:e12-e14
17. Ramanauskaitė A, Trüeb RM. Facial Papules in Fibrosing Alopecia in a Pattern Distribution (Cicatricial Pattern Hair Loss). *Int J Trichology*. 2015;7:119-122. 335
18. Billero V, Oberlin KE, Miteva M. Red dots in a net-like pattern on the upper chest: a novel clinical observation in frontal fibrosing alopecia and fibrosing alopecia in pattern distribution. *Skin Appendage Disord* 2018;4:47-49
19. Fergie B, Khaira G, Howard V, de Zwaan S. Diffuse scarring alopecia in a female pattern hair loss distribution. *Australas J Dermatol*. 2018;59:e43-e46
20. De Mozzi P, Crichlow SM, Da Forno PD, Alexandroff B. A case report of fibrosing alopecia in a female pattern distribution. *G Ital Dermatol Venereol*. 2013;148:710-11.
21. Mancini I, Rotilio A, Coati I, Seracchioli R, Martelli V, Merigiola MC. Presentation of a meningioma in a transwoman after nine years of cyproterone acetate and estradiol intake: case report and literature review. *Gynecol Endocrinol*. 2018;34:456-9. doi: 10.1080/09513590.2017.1395839.