

Qual o Seu Diagnóstico?

Nódulos Eritematosos Suprapúbicos numa Doente Idosa

Mariana Esteves, Júlia Vide, Filomena Azevedo 

Department of Dermatology and Venereology, Centro Hospitalar Universitário de São João EPE, Porto, Portugal

PALAVRAS-CHAVE – Doenças Linfoproliferativas; Idoso; Linfoma Cutâneo de Células T; Linfoma Difuso de Grandes Células B; Linfoma não Hodgkin.

Dermatology Quiz

Suprapubic Erythematous Nodules in an Elderly Patient

KEY WORDS – Aged; Lymphoma, Large B-Cell, Diffuse; Lymphoma, Non-Hodgkin; Lymphoma, T-Cell, Cutaneous; Lymphoproliferative Disorders.

CASE REPORT

An 83-year-old female patient was admitted to our department for investigation of extensive painless lesions on the lower abdomen. Additionally, she complained of asthenia, anorexia and a weight loss of 10 kg in 6 months. Her previous medical history was only positive for arterial hypertension under treatment with nifedipine.

Physical examination revealed multiple asymptomatic, firm,

erythematous confluent nodules and tumors on the suprapubic area (Fig. 1A), as well as enlarged, bilateral painless inguinal lymph nodes. Moreover, numerous erythematous patches and plaques were observed on the lower back (Fig. 1B) and an indurated subcutaneous tumor was palpable on the lumbosacral region. The remaining examination was unremarkable.

Laboratory evaluation revealed normal complete blood counts, but elevated lactate dehydrogenase (438 U/L; N<225) and beta-2 microglobulin levels (4550 µg/L;

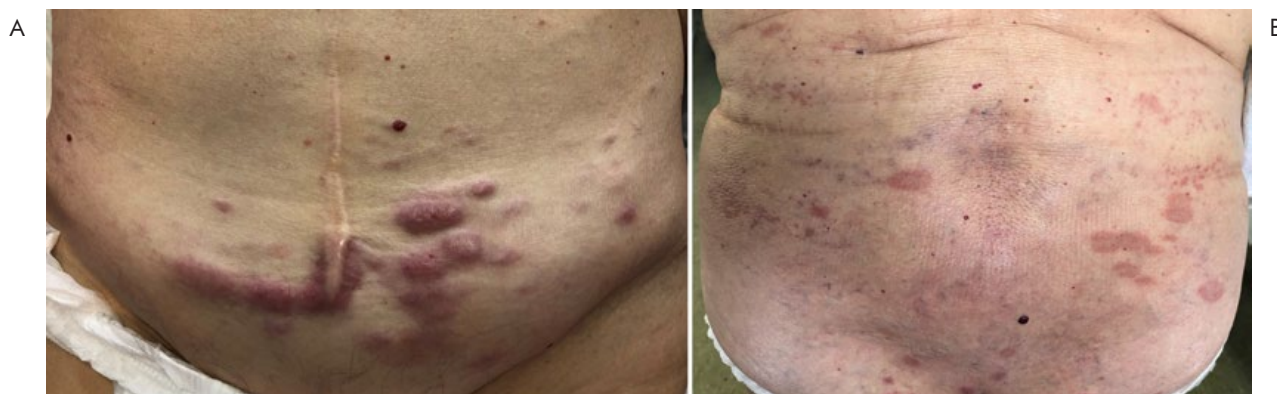

Figure 1 - (A) Several firm, erythematous confluent nodules and tumors on the suprapubic area. (B) Numerous erythematous patches and plaques on the dorsolumbar region.

Correspondência: Mariana Esteves
Serviço de Dermatologia e Venereologia
Centro Hospitalar Universitário de São João EPE
Alameda Professor Hernâni Monteiro
4200-319 Porto, Portugal
E-mail: mariana.cbsteves@gmail.com
DOI: <https://dx.doi.org/10.29021/spdv.78.2.1183>

Recebido/Received 2020/04/09	Aceite/Accepted 2020/04/27	Publicado/Published 2020/06/30
----------------------------------------	--------------------------------------	------------------------------------------

© Autor (es) (ou seu (s) empregador (es)) 2020 Revista SPDV. Reutilização permitida de acordo com CC BY-NC. Nenhuma reutilização comercial.
© Author(s) (or their employer(s)) 2020 SPDV Journal. Re-use permitted under CC BY-NC. No commercial re-use.

Qual o Seu Diagnóstico?

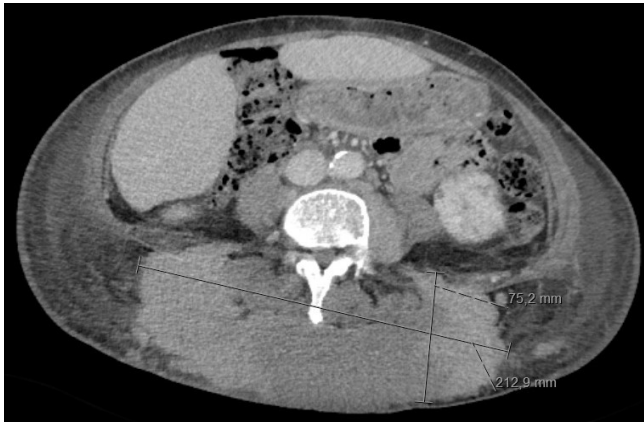

Figure 2 - Computed tomography scan showing a large subcutaneous mass of 17x21x7, 5cm, involving the skin and the adjacent left lumbar and gluteal muscles.

$N < 2350$). A full body computed tomography scan identified numerous inguinal, pelvic and retroperitoneal lymphadenopathies, along with a large subcutaneous mass involving the skin and the adjacent left lumbar and gluteal muscles (Fig. 2).

Histopathological examination of a skin biopsy showed a dense and diffuse infiltrate extending into the deep dermis and sparing its upper portion (Fig. 3A). The infiltrate was comprised of sheets of intermediate to large-sized cells with centroblastic and immunoblastic morphology, displaying frequent mitotic figures and apoptotic bodies (Fig. 3B). Neoplastic cells stained positive for CD20, BCL-2, MUM-1, BCL-6 (Fig. 4) and the Ki-67 proliferation index was 75%. An inguinal lymph node fine-needle biopsy was also performed, which showed infiltration of intermediate to large-sized, irregular lymphoid cells expressing surface CD10 and IgG kappa. Given the skin biopsy result, both bone marrow and excisional lymph node biopsies were not performed.

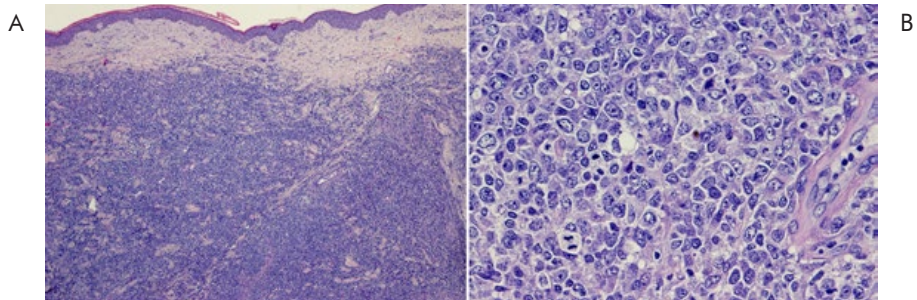


Figure 3 - (A) Dense and diffuse infiltrate extending into the deep dermis and sparing its upper portion ("grenz zone pattern") (H&E, 40x). (B) Sheets of intermediate to large-sized cells with centroblastic and immunoblastic morphology, along with frequent mitotic figures and apoptotic bodies (H&E, 400x).

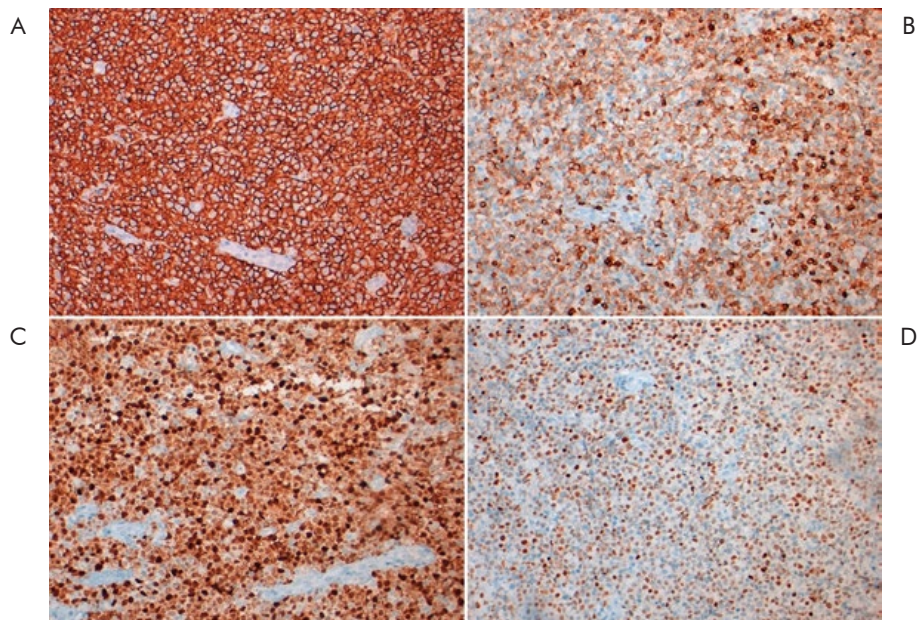


Figure 4 - Immunohistochemical analysis disclosed positivity of neoplastic cells for CD20 (A), BCL-2 (B), MUM-1 (C) and BCL-6 (D).

WHAT IS YOUR DIAGNOSIS?

DIFFUSE LARGE B-CELL LYMPHOMA

Combination of clinical, radiological and histopathological findings led to a diagnosis of systemic diffuse large B-cell lymphoma (DLBCL) with cutaneous infiltration. The patient was started on chemotherapy with rituximab 360 mg/m² and bendamustine 90 mg/m², of which she completed two cycles. Despite an initial clinical improvement, disease progression eventually occurred and she died 3 months after the diagnosis.

Cutaneous lymphoma can be divided into two categories: primary cutaneous lymphoma (PCL), which is confined to the skin without evidence of extracutaneous involvement at the time of presentation, and secondary cutaneous lymphoma (SCL), in which skin lesions develop concurrently or after a diagnosis of systemic lymphoma.¹ While PCL has been analyzed in a few large-scale epidemiological studies, the same is not true for SCL. Consequently, its incidence, clinical features and survival outcomes remain poorly understood.¹⁻³

In the published literature, mature T-cell and NK-cell lymphomas comprise more than half of SCL, while B-cell lineage neoplasms represent about 40% of cases.¹⁻⁴ In PCL, this proportion is much more pronounced, given the contribution of mycosis fungoides and CD30+ T-cell lymphoproliferative disorders. DLBCL is the most frequent subtype of non-Hodgkin lymphoma and accounts for up to 35% of cases of secondary lesions in some series.^{1,2,4}

When comparing primary and secondary cutaneous DLBCL, no significant differences are found regarding number, morphology or location of skin lesions.^{5,6} Nevertheless, cutaneous dissemination, as in our case, is more common in secondary DLBCL and portends a worse prognosis.^{2,5,6}

Overall survival rates vary considerably between patients with DLBCL, given the distinct clinical presentation and response to treatment. Not surprisingly, extranodal involvement in the setting of systemic lymphoma denotes disease progression and is associated with a poorer outcome.^{2,5} Additional factors of prognostic relevance in secondary B-cell lineage lymphoma include elevated serum lactate dehydrogenase levels at initial staging and early occurrence of skin lesions (less than 6 months from the diagnosis of the primary disease),^{2,6} both of which were seen in our patient. In contrast, conventional prognostic factors for DLBCL, such as age, gender or Ann Arbor stage, do not seem to significantly influence survival in SCL.^{2,5}

Herein, we report a case of DLBCL presenting with unusually extensive soft-tissue involvement, which predicted a more aggressive clinical course. Cutaneous lesions were the first manifestation of the systemic disease and therefore represented the key for its diagnosis.

Presentations/Apresentações

This work has been presented as a case report in the "XVIII Congresso Nacional de Dermatologia e Venereologia", held at Porto, Portugal, from 30th November to 2nd December 2018.

Conflitos de interesse: Os autores declaram a inexistência de conflitos de interesse na realização do presente trabalho.

Fontes de financiamento: Não existiram fontes externas de financiamento para a realização deste artigo.

Confidencialidade dos dados: Os autores declaram ter seguido os protocolos da sua instituição acerca da publicação dos dados de doentes.

Consentimento: Consentimento do doente para publicação obtido.

Proveniência e revisão por pares: Não comissionado; revisão externa por pares.

Conflicts of interest: The authors have no conflicts of interest to declare.

Financing support: This work has not received any contribution, grant or scholarship.

Confidentiality of data: The authors declare that they have followed the protocols of their work center on the publication of data from patients.

Patient Consent: Consent for publication was obtained.

Provenance and peer review: Not commissioned; externally peer reviewed

ORCID

Mariana Esteves

<https://orcid.org/0000-0002-7940-5451>

Filomena Azevedo

<https://orcid.org/0000-0003-0402-6382>

Júlia Vide

<https://orcid.org/0000-0002-9542-9103>

REFERENCES

1. Fujii K, Hamada T, Shimauchi T, Asai J, Fujisawa Y, Ihn H, et al. Cutaneous lymphoma in Japan, 2012-2017: A nationwide study. *J Dermatol Sci.* 2020; 97:187-93. doi: 10.1016/j.jdermsci.2020.01.010.
2. Lee WJ, Won KH, Won CH, Chang SE, Choi JH, Moon KC, et al. Secondary cutaneous lymphoma: comparative clinical features and survival outcome analysis of 106 cases according to lymphoma cell lineage. *Br J Dermatol.* 2015; 173:134-45. doi: 10.1111/bjd.13582.
3. Kaddis N, Fisher D, Jacobsen ED. Cutaneous Involvement of Hematologic Malignancies. *Hematol Oncol Clin North Am.* 2019; 33:163-72. doi: 10.1016/j.hoc.2018.08.005.
4. Yasukawa K, Kato N, Kodama K, Hamasaka A, Hata H. The spectrum of cutaneous lymphomas in Japan: a study of 62 cases based on the World Health Organization

Qual o Seu Diagnóstico?

- Classification. *J Cutan Pathol.* 2006; 33:487-91. doi: 10.1111/j.1600-0560.2006.00460.x.
5. Lee WJ, Won KH, Won CH, Chang SE, Choi JH, Moon KC, et al. Secondary cutaneous diffuse large B-cell lymphoma has a higher international prognostic index score and worse prognosis than diffuse large B-cell lymphoma, leg type. *Acta Derm Venereol.* 2016;96:245-50. doi: 10.2340/00015555-2139.
 6. Ferrão JB, Barreira JV, Marote S, Parmanande A. Diffuse large B cell lymphoma: cutaneous presentation. *BMJ Case Rep.* 2018;11:e226839. doi: 10.1136/bcr-2018-226839.