

We are IntechOpen, the world's leading publisher of Open Access books Built by scientists, for scientists

5,000

Open access books available

125,000

International authors and editors

140M

Downloads

Our authors are among the

154

Countries delivered to

TOP 1%

most cited scientists

12.2%

Contributors from top 500 universities



WEB OF SCIENCE™

Selection of our books indexed in the Book Citation Index
in Web of Science™ Core Collection (BKCI)

Interested in publishing with us?
Contact book.department@intechopen.com

Numbers displayed above are based on latest data collected.
For more information visit www.intechopen.com



Femto Laser-Assisted Cataract Surgery

*Clemence Bonnet, Saba Al-Hashimi, Antoine P. Brézin
and Dominique Monnet*

Abstract

Cataract is a leading cause of blindness in the world, and cataract extraction is one of the most commonly performed surgeries. Preferred surgical techniques have changed over the past decades with associated improvements in outcomes and safety. Phacoemulsification is a highly successful technique first introduced over 40 years ago. It is the current method of cataract surgery, with a very low reported rate of major complications and a frequency of overall intraoperative complications of less than 2%. Application of the femtosecond laser evolved to now assist in cataract surgery and has been termed FLACS (femtosecond laser-assisted cataract surgery) and occurs in three steps: corneal incisions (including optional limbal relaxing incisions to reduce astigmatism), anterior capsulotomy, and lens fragmentation. The remaining surgical steps still require the surgeon's hands. The FLACS technique may have some advantages compared with conventional phacoemulsification. It remains however unclear whether FLACS is globally more efficient and safer than conventional surgery. The popularity of FLACS may also be limited by its higher cost compared with conventional surgery. The potential advantages of laser-assisted surgery are yet to be determined as FLACS technology is relatively new and in continuous evolution. This chapter reports scientific data as well as our own experience with this new technology. All the platforms currently available are described.

Keywords: cataract surgery, femtosecond laser, phacoemulsification, FLACS (femtosecond laser-assisted cataract surgery)

1. Introduction

Techniques in cataract surgery have been dramatically progressing over the past half-century with associated improvements in outcomes and safety [1, 2]. Manual phacoemulsification remains the most popular technique in developed countries, representing about 90% of procedures [3]. Although a number of recent developments have occurred in intraocular lens technology, the basic phacoemulsification procedure has remained unchanged over the past 20 years [4, 5].

“Femto” is a prefix of the International System of Units that stands for 10^{-15} , a millionth of a billionth. The femtosecond laser consists of a solid-state laser source that emits impulses of a wavelength close to the infrared spectrum with a duration measurement in femtoseconds. Its emission frequency is 10,000 pulses per second of monochromatic light. Corneal flap creation during laser in situ keratomileusis (LASIK) is the most common use of this laser [6, 7]. The latest innovation is its use

in cataract surgery, called FLACS (femto laser-assisted cataract surgery) [8, 9]. The recent introduction of femtosecond laser to cataract surgery, by Nagy et al. in 2008, and its Food and Drug Administration (FDA) approval in 2010 represents a potentially significant advancement in cataract technology, with expectations of greater safety and better visual outcomes [10–12].

2. Femtosecond laser principles

The femtosecond laser has a similar action to the *Nd:YAG* laser used in pseudophakic capsulotomies. The *Nd:YAG* laser and the femtosecond laser have nearly identical wavelengths, respectively 1.064 and 1.053 nm. The femtosecond laser light pulses are shorter than the impulse of the *Nd:YAG* laser, which is on the order of nanoseconds (**Table 1**).

Photodisruption starts with a process called laser induced optical break-down (LIOB), which occurs when conditions of high frequency laser pulses are highly focused with short duration and applied through a small beam laser diameter [13]. The LIOB generates a high-intensity electrical field. The laser pulses cause ionization, meaning the breaking of the bonds between electrons and atomic nuclei, which is responsible for a cavitation bubble phenomenon, related to the expansion of this plasma consisting of ions [14]. This plasma complex will tend to expand at supersonic speed, separating tissue in its path, rapidly losing energy and vaporizing tiny quantities of corneal tissue. The cavitation bubble consists of CO₂, N₂ and H₂O molecules, which are absorbed by the corneal pump mechanism or eliminated when the corneal flap is raised or the eye opened [15]. These ultrafast pulses are too brief to transfer heat and generate inflammation to the tissue, and therefore are considered particularly adapted to cleave tissue. Hundreds of thousands of adjacent pulses can shape uniform horizontal, vertical or oblique cut surfaces. The pulses are always emitted from the deepest targeted layers of the cornea toward the most superficial ones, to avoid the generated cavitation bubbles from stopping laser pulses focused on the underlying layers. One of fundamental requirement for femtolaser intervention is corneal transparency, allowing precise focus of the laser spots and energy delivery.

The femtosecond laser used in cataract surgery has been specifically developed for the following surgical steps: main and accessory corneal incisions, capsulorhexis, lens fragmentation, and optional arcuate incisions for intraoperative correction of astigmatism. The depth of treatment can reach 8 mm, from the corneal epithelium to lens posterior capsule. The pulsed energy used by a femtosecond laser for cataract surgery is on a scale of microjoules (μJ) and 15 μJ is the maximum energy of pulses.

Laser	Wavelength (nm)	Effect on tissue
Carbon dioxide	10600, far infrared	Photothermal
<i>Nd:YAG</i>	1064, near infrared	Photodisruption
Femtosecond	1053, near infrared	Photodisruption
Krypton	647-531, visible light	Photochemical coagulation
Argon	614-488, visible light	Photochemical coagulation
Excimer	193, far ultraviolet	Photoablation

Table 1.
Use of lasers in ophthalmology.

3. Platforms available and procedure

Five FLACS devices are currently available:

- LenSx (Alcon LenSx, Inc., Aliso Viejo, CA, USA)
- LensAR (LENSAR, Inc., Winter Park, FL, USA)
- Catalys (OptiMedica, Abbott Medical Optics, Santa Clara, CA, USA)
- Victus (Technolas Perfect Vision and Bausch and Lomb, Rochester, NY, USA)
- LDV Z8 (Ziemer Ophthalmic Systems AG, Port, Switzerland)

The laser programming consists in individual steps: (1) customize the treatment with the graphic user interface, (2) dock with patient interface, (3) image via OCT scan, (4) analyze the image and (5) treat with the femtosecond laser. These functions are clustered on a computer supplied with the femtosecond laser (and the patient bed, depending on the device). The association of the femtosecond laser, the graphic user interface, the docking system, and the OCT scan constitutes the femtolaser platform. Femtolaser platforms are quite similar to each other and are fitted either with an optical coherence tomography (OCT) imaging system or a Scheimpflug camera to guide the laser beam to the target. Recording of patient data and customized profiles are made through the touchscreen monitor. Platforms differ in step order, docking interface, lens fragmentation patterns and speed of action (**Table 2**). The environmental needs for the laser system are crucial to provide reproducible procedures. The space in the operative room must be considered as the devices occupies between 2 and 3 m³ (except the LDV Z8, which is a smaller portable device) and must be near to the phacoemulsifier. **Table 3** summarizes these requirements.

	LenSx	LensAR	Catalys	Victus	LDV Z8
	Alcon	LensAR	AMO	Bausch & Lomb, Technolas	Ziemer
Room size (m)	3.4 × 4.3	4.57 × 4.57	3.04 × 3.35	3.4 × 3.7	No specific needs
Laser size (h × l × p, m)	Screen: 1.22 × 0.76 × 0.61; laser: 0.51 × 0.58 × 0.20	1.65 × 1.97 × 0.8	1.15 × 1.64 × 0.84	1.67 × 2.1 × 0.82	1.4 × 1 × 0.6
Docking	Curved applanation lens	Fluid-fill suction ring	Fluid-fill suction ring	Curved applanation lens	Fluid-fill suction ring + curved applanation lens
Imaging	HD-OCT	HD-OCT + Scheimpflug camera	HD-OCT	HD-OCT	HD-OCT
Included bed	No	No	Yes	Yes	No
Corneal refractive procedure	Yes	No	No	Yes	Yes

Table 2.
 FLACS platforms available.

Docking the eye to the system means connecting the eye to the laser. This is done via a patient interface. The patient interface utilizes suction to stabilize the eye and maintain a clear optical pathway for imaging and laser delivery. The goal during suction is to obtain a clear and stable image during the laser treatment while controlling the increased intra ocular pressure and the image quality. Each platform has a specific patient interface, for example, with the Catalys, docking is accomplished with a liquid filled interface which allowed a good cornea visualization during docking. The LenSx uses a curved applanated interface, which can create posterior corneal folds which can interfere with the ability to image and cut tissue effectively. Optimal docking is achieved when there is a symmetric scleral show.

3.1 LenSX

The LenSX laser is a standard unit that does not require external connections to water or gas. Recent updates have changed the diameter of the patient-interface, now called SoftFit PI, which allowed a 20% reduction in intraocular pressure (IOP), providing less discomfort for the patient (**Figure 1**). The SoftFit® interface has a soft lens insert in the interface that allows the reduction of corneal folds during the docking, and a better delivery of the laser beam [16]. The integrated anterior segment optical coherence tomography OCT provides real-time scanning from the corneal epithelium to the posterior lens capsule with a high-resolution video. This imaging system is able to either take a single OCT snapshot, or produce live continuous OCT images (**Figures 2–4**). Thanks to live OCT, surgeons can immediately check if the patient's positioning is adequate, reducing the risk of tilt during the docking procedure.

3.2 LensAR

The LENSAR docking system is a noncontact disposable fluid filled patient. The suction ring is low pressure, which decreases the frequency of subconjunctival

Operating temperature of the environment	18–24°C
Operating humidity	30–65%
24-hour air conditioning system sterility	
Class A operating room (minor surgery under topical or local anesthesia)	
Handwashing facilities	
Smooth and washable floors	

Table 3.
Environmental requirements for the laser system set-up space.

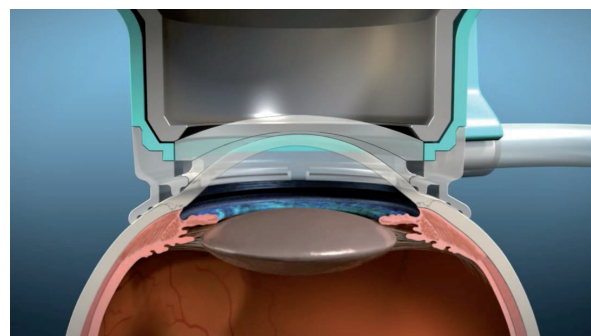


Figure 1.
LenSX docking system, SofFit® interface.

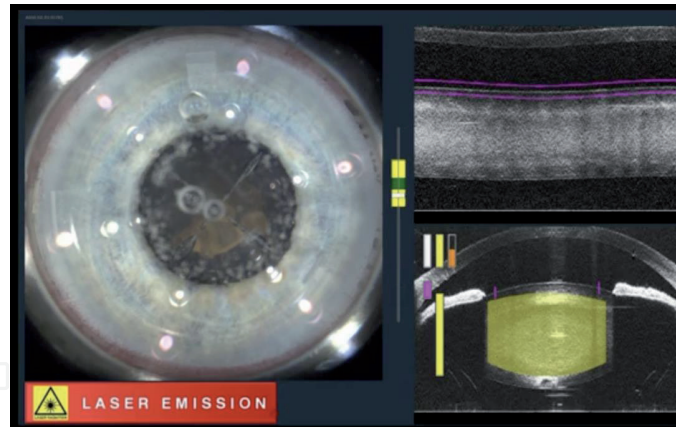


Figure 2.
LensX capsulotomy procedure.

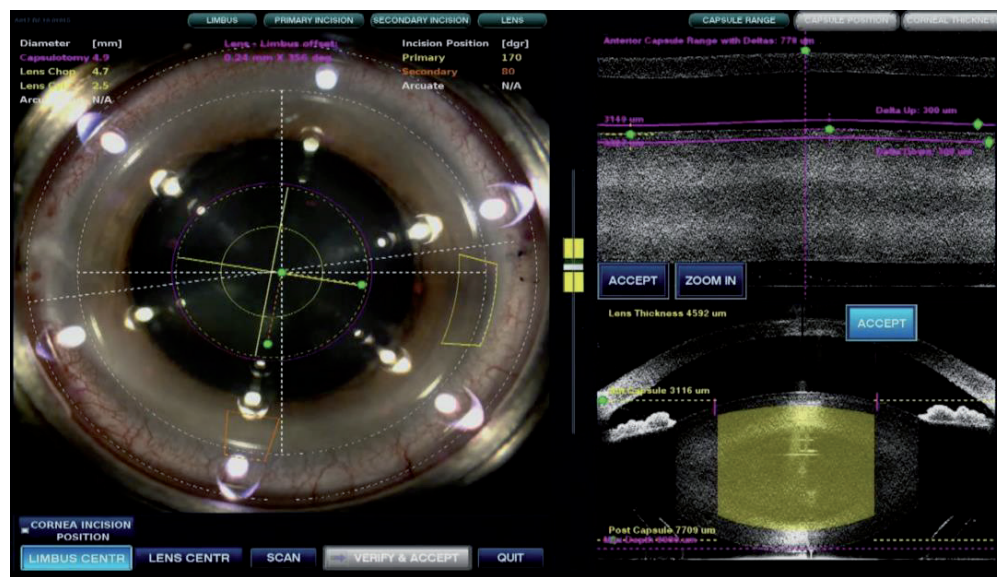


Figure 3.
LensX incisions procedure.




Figure 4.
Free floating continuous, curvilinear, and circular capsulotomy with LensX.

hemorrhages and minimizes the risk of high intraocular pressure. The system includes a Scheimpflug three-dimensional confocal system combined with a laser biometric system allowing scans of the anterior segment at varying speeds. The depth-of-field imaging is enhanced compared with OCT technology. The nuclear fragmentation consists of radial sections or concentric cylindrical cuts and allows cubic, spherical or pie-cut patterns. The system is also able to detect and compensate for tilt (**Figure 5**).

3.3 Catalys

The docking system, called “Liquid Optics®,” includes two parts: one is fitted to the patient by suction and the second couples to the first cone to the console of the Catalys optics system. The suction ring, which is filled with a balanced saline solution (BSS), requires a vacuum that does not exceed 15 mm Hg. The OCT images are guided through a continuous optical system. The system software identifies the ocular surfaces, reconstructs areas to be excluded from laser treatment and customizes the treatment according to the observed structures.

The patterns of lens fragmentation are wide and allow control of grid spacing (from 100 to 2000 μm) (Figures 6–9).




Figure 5.
LensAR lens fragmentation patterns.



Figure 6.
Catalys device.

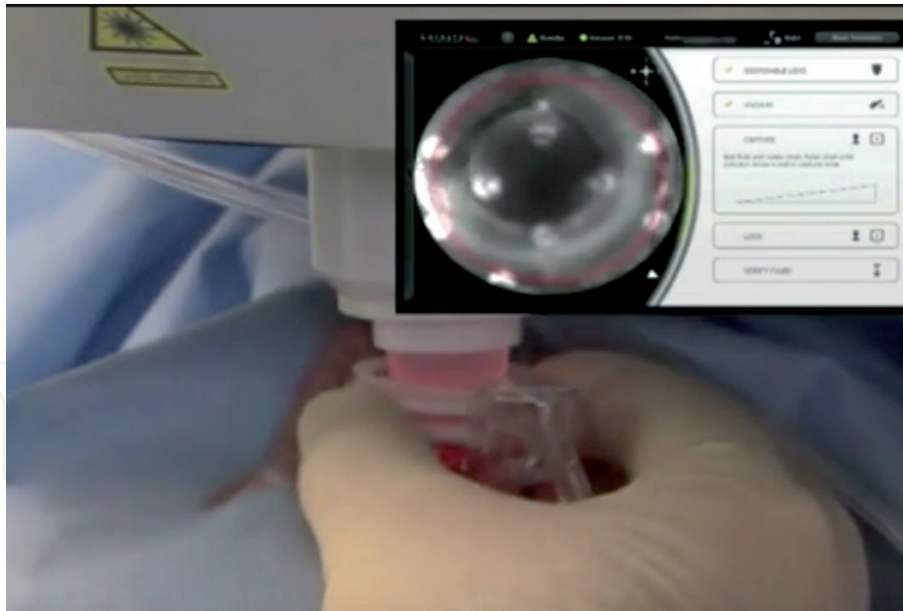


Figure 7.
Liquid optics® Interface.

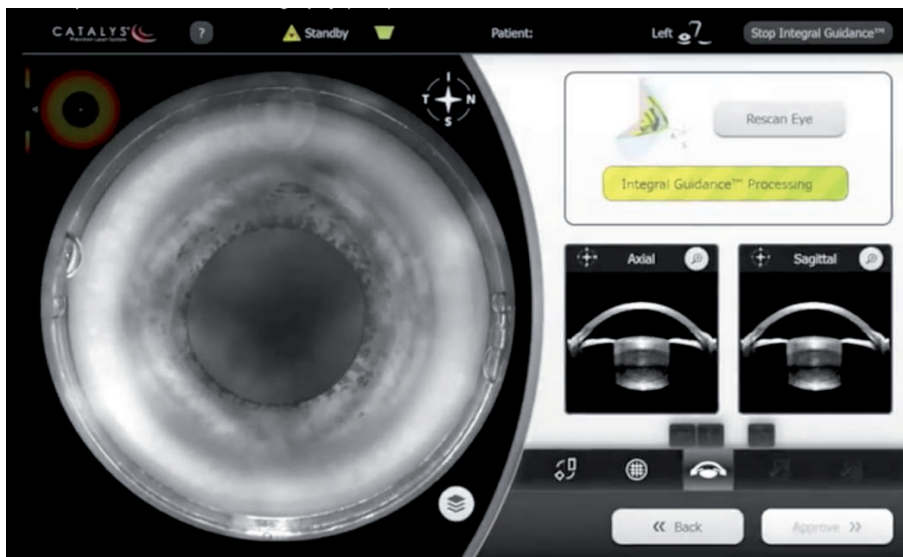

Figure 8.
Per-operative CATALYS visualization.



Figure 9.
Laser treatment with CATALYS.

3.4 VICTUS

The VICTUS system currently uses two components for laser docking: a low-pressure silicone suction ring and a curved interface cone. Adaptation of the curved interface cone is controlled by intelligent sensors, which change pressure levels exerted on the eye depending on the treatment. The image capturing system is a spectral-domain OCT that takes real-time images and identifies anterior segment structures. The surgeon can manually locate the area of photodisruption in the nucleus and its distance to the posterior capsule.

Flaps in refractive corneal procedures and incisions are also possible, making it a versatile femtosecond laser system. The laser source operates at 80 kHz for the FLACS procedure. The optical-acoustic-modulator included allows modulation in the laser pulses' frequency: it can change from 80 kHz for the FLACS procedure to 160 kHz for the LASIK-flap procedure (**Figures 10–12**).

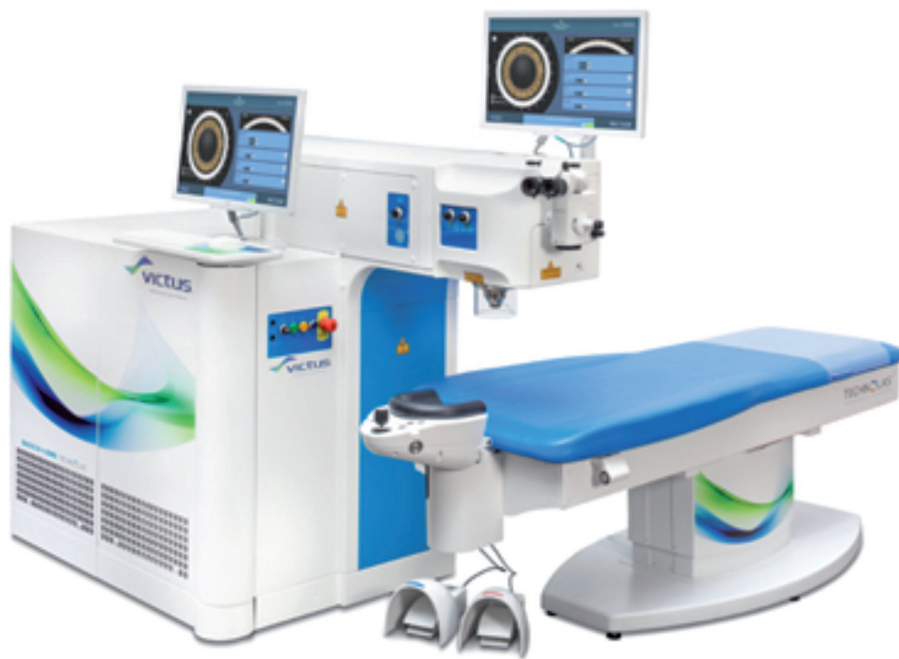

Figure 10.
VICTUS device.



Figure 11.
VICTUS docking system.

3.5 LDV Z8

The device is the first mobile cataract femtosecond laser that can be easily suit in the operating room. Ziemer has developed a liquid-filled nonapplanating interface which adheres to the eye with minimal suction and thus avoids corneal folds. The FEMTO LDV Z8 employs a combination of two imaging systems for real-time visual control of the docking process and of the positioning of dissections: the TopView®, a high-definition camera which provides visual control of the alignment of the patient

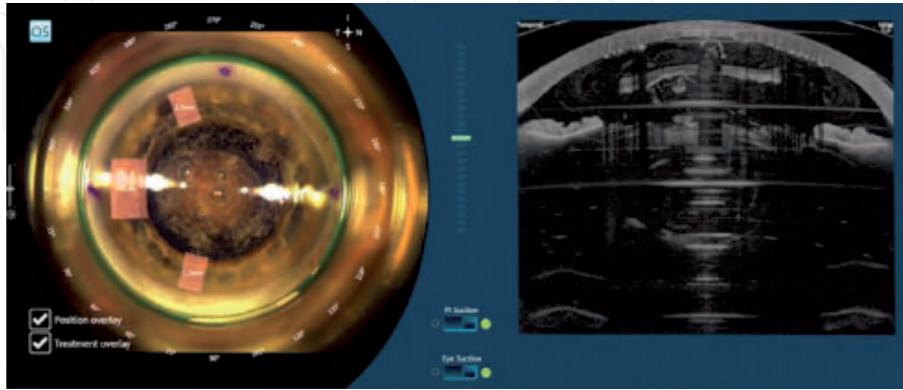


Figure 12.
VICTUS laser treatment with free floating capsulotomy.



Figure 13.
LDV Z8 device.

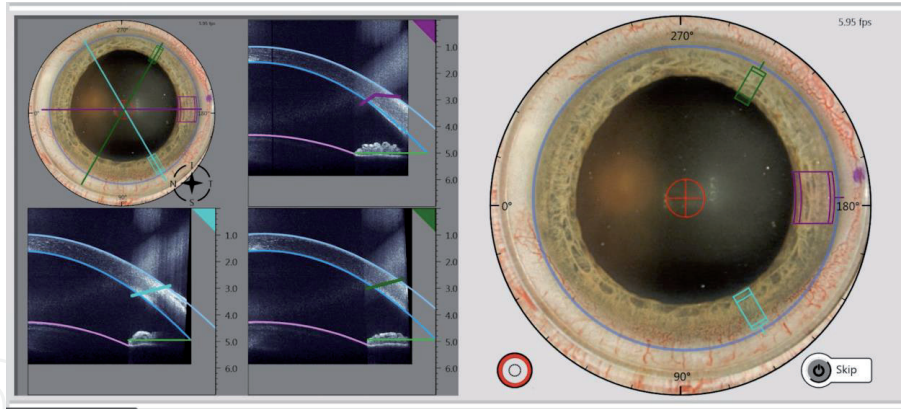


Figure 14.
LDV Z8 procedure and incisions.

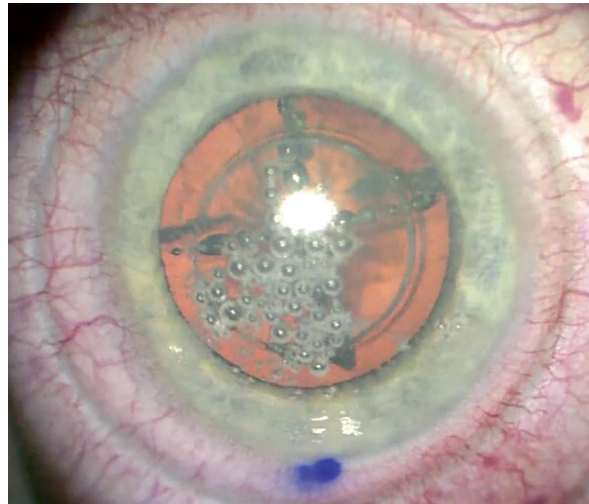


Figure 15.
Eye after LDV Z8 procedure.

interface to the eye and a proprietary OCT system, operating in the near-infrared range (Figures 13–15) [17]. It obtained FDA approval for FLACS in 2016.

3.6 Procedure

Proper docking requires cooperation from the patient. The liquid interface has advantages of causing less tissue distortion and minimal increase in intraocular pressure as well as less mean eye movement during capsulotomy. The cornea should be well centered in the patient interface before docking to avoid misalignment of corneal incisions. Apart from the transient learning curve, docking may cause subconjunctival hemorrhage [18]. The estimated incidence of this side effect is 34% and significantly decreased using the liquid interface device with lower suction pressure, and shorter treatment time [19].

4. Description of the intervention

4.1 Capsulotomy

The capsulotomy cut opens the lens's anterior capsule in a continuous, curvilinear, and circular fashion with high precision to improve safety during intraocular maneuvers. We advise to choose a 5.2 mm diameter capsulotomy, with a delta up at

400 μm and a delta down of 350 μm . The energy recommended is 15 μJ , with a 4 μm spot separation and a 3 μm layer separation. Laser capsulotomies have been shown to be better centered than manual continuous curvilinear capsulorhexis (CCC), with highly predictable sizes [20–22].

4.1.1 Lens fragmentation

The surgeon defines the pattern, the length, and the number of cuts. The energy level, the anterior and posterior lens capsule parameters, pattern separation and the primary incision angle have to be specified. Then, the nucleus can be easily split.

4.1.2 Limbal relaxing incisions

It is possible to correct a small amount of astigmatism ($<1.5\text{ D}$) with arcuate incisions (AI) [23]. Nomograms can facilitate surgical planning by determining the proper treatment for an intended correction [24]. Arcuate incisions can be left unopened until the postoperative period depending on the postoperative refractive error [25].

4.1.3 Corneal incision

All corneal incisions are placed just inside the limbus. The real-time anterior segment imaging provides the peripheral corneal thickness at the location of the incision during the procedure. We recommend a 2.2 mm three planes ($90^\circ/11^\circ/90^\circ$) main incision at 135° and a one plane 1.2 mm incision at 5° for the side-port incision. The spot the layer separation should be 4 μm with an energy level of 5.5 μJ .

4.2 After the laser procedure

After removing the docking system, next steps are similar to manual phaco-emulsification. The cortex aspiration can be tricky because the femtosecond laser cut it just below the capsulotomy. If the irrigation/aspiration probe is not sufficient, a Simcoe cannula can be used. To help, the cortex may be washed with a 25G syringe full of balanced salt solution.

4.3 Complications

4.3.1 Suction break

Sudden suction break can occur in less than 2% of cases, but did not lead to further complications as laser treatment can be started over (**Table 4**) [19]. Most important factors to prevent it are precise patient interface placement and good preoperative anesthesia. Hard headrest avoids the head from being pushed down during insertion of the patient interface and reduces the risk for suction loss.

4.3.2 Pupillary constriction

The incidence of pupillary constriction is 19% and arises during the first steps of the femtolaser procedure [19]. The laser application itself can cause pupillary miosis. Bubble formation in the anterior chamber releases small amounts of free radicals and prostaglandins that can trigger pupillary constriction. Highly myopic eyes and eyes with pseudoexfoliation syndrome are prone to a miotic reaction after femtosecond laser treatment. Intracameral epinephrine before lens removal can help enlarge the pupil and facilitate the surgery [26]. Iris hooks, retractors or a

Conjunctival hemorrhage	34%
Pupillary constriction	19%
Suction break	2%
Capsule complications	2%
Posterior rupture	0.53–1.9%
Anterior tear	0.02%
Block syndrome	0.001%
Endothelial damages	0.002%
Wrong corneal incision localization	0.002%

Table 4.
Rate of complications.

Malyugin ring can be placed after the laser procedure if miosis results. In a case of insufficient mydriasis and an ectopic pupil, Malyugin et al. have developed a surgical technique that combines use of an iris hook and a pupil expansion ring followed by FLACS [27]. Prophylaxis may be an adapted management of the procedure. If the patient is operated immediately after the femtolasar, the prostaglandins released hardly have the time to have effect on the sphincter pupillae. Moreover, pupil dilatation should start 1 hour before, with more frequent instillation of mydriatics.

4.3.3 Capsule complications

4.3.3.1 Incomplete capsulorhexis and anterior capsule tear

A recent meta-analysis shows that the number of anterior capsule and posterior capsule tears for both FLACS and manual phacoemulsification cataract surgery are low, around 0.02% [2]. Tilt, improper docking, loss of suction, corneal folds, and imaging or programming errors can cause partial a capsulotomy. Capsule tags and bridges are usually harmless if they are detected early [28]. The crucial step for capsulotomy removal is to follow the line of the femtosecond laser cut. The absence of a gutter and the presence of bubbles trapped under the capsulotomy cut are signs that help the surgeon identify minor remaining capsule attachments. The surgeon should never pull toward the center of the micro adhesion area because it can cause tags which may run out toward the periphery during hydrodissection or phacoemulsification. One should detach it capsule circumferentially following the contour of the capsulotomy. As small tags can be difficult to see, pulling out the entire anterior capsule with sudden movement is not recommended.

When an anterior capsule tear occurs, the surgeon should perform a very gentle hydrodissection and the canula should be placed 90 degrees from the tear. Avoiding the area of the anterior capsule tear and nucleus rotation is highly advised. During IOL implantation, the leading haptic should be kept away from the tear line.

4.3.3.2 Capsular block syndrome

Capsular block syndrome (CBS) is a rare (0.001%) but serious complication [19]. If hydrodissection with a high-speed influx of fluid is performed, the gas contained in the nucleus cannot access to the anterior chamber, creating an acute intra-capsular high pressure. The subsequent capsular high pressure may lead to a posterior capsular rupture with dropped nucleus. The main signs are the quick constriction of the iris, iris prolapse through the main incision, wrinkling of the capsule and tilting of the lens. Surgeons should be aware of this complication and

avoid it by releasing the gas and decompressing the capsular bag before starting hydrodissection. The nucleus may be gently rocked to allow this gas to be burped out. This rock'n roll technique allows air bubbles to leave the crystalline lens. When the gas bubbles leave the intralenticular plane toward the anterior chamber or leave the eye completely, there is no further danger of CBS or posterior capsular rupture.

4.3.3.3 Posterior capsular rupture

Half of posterior capsular tears and lens dislocations are caused by posterior extension of an anterior radial tear. It is imperative that the notches at the anterior capsular margin are recognized and managed during the capsulotomy removal. Completing nuclear fracture centrally to allow any retrolenticular gas to escape is advised. In case of posterior capsular rupture, the management should be the same as during a manual phacoemulsification.

In the first studies, the capsular complication rate during the learning curve (first 200 FLACS procedures) was 7.5% and then decreased to 0.62% (consecutive 1300 cases) [29, 30]. The overall incidence of posterior capsular tears was 3.5% and that of posterior lens dislocation was 2% [30]. In more recent studies, posterior capsular tears have been reported to vary between 0.53 and 1.9%, whereas the incidence of a dropped nucleus has been reported to be between 0.1 and 0.12% [31]. The debate is ongoing: in a recent meta-analysis, Day et al., including 1700 eyes, found that FLACS did not significantly lower the rate of posterior capsular rupture, which was very low in both the FLACS group and manual phacoemulsification group [2]. Though, Popovic et al., including 15,000 eyes, showed that FLACS was associated with higher rates of posterior capsular tears (risk ratio 3.73, $p < 0.05$) [32]. In both studies, the incidence was very low (0.02%) [32]. FLACS might be safer than manual phacoemulsification: lately, Scott et al published the first study with a statistically significant decrease of vitreous loss rate in the FLACS group compared with manual phacoemulsification group (0.65 vs. 1.65%) with a decrease in the individual surgeon's vitreous loss rate [29].

4.3.4 Endothelial damage

Endothelial damage during capsulotomy should be considered as a serious complication of femtosecond laser treatment. This complication was likely caused by the lack of an integrated OCT system with the first devices. Highly hyperopic eyes with a shallow anterior chamber require closer attention to avoid endothelial cuts. In the published cases, the overall incidence was very low (0.002%) and there were no long-term visual consequences of this complication although the endothelial incision line could be observed 1 year after surgery [19].

4.3.5 Wrong corneal incision localization

During corneal wound creation with the femtosecond laser system, if the wound is too central, it can cause surgically induced astigmatism. On the opposite, if the wound is too peripheral, it cannot be opened. Since real-time OCT devices allow visual control of the procedure, the incidence of this complication has dramatically decreased to become very rare (0.002%) [32].

4.4 Personal experience and tips for success

In our experience, with the new platforms, all capsulotomies are complete and we have not seen capsular tears. Depending of the device, the docking is relatively easy. The Catalys device, with its Liquid Optic Interface allows for easy docking without

posterior corneal folds. Laser induced miosis can be managed by adding 0.5% tropicamide drops in the liquid filled into the patient interface. We have not seen capsular blockage syndrome as we gently rock the nucleus to remove the gas bubbles trapped into the capsule before performing hydrodissection. We recommend the hydrodissection to be soft but complete. Phacoemulsification is easier after laser treatment but should be performed cautiously by the beginner. All the fragment patterns among the different devices effectively cut the nucleus and allow for easy disassembly. The ice-cube pattern available with the Victus is for us the more efficient pattern, as the surgeon only has to separate the first ice cubes to quickly remove all the nucleus.

TIPS FOR SUCCESS

- Verify the eye's centration (avoid tilting)
- Verify complete capsulotomy
- Evacuate the air bubble before hydrodissection
- Gentle hydrodissection and slow nucleus rotation
- Lens removal: Phaco-chop more than Divide and Conquer
- Cortex removal: Easier if the posterior lens off-set is small (800 μm)

In conclusion, FLACS increases the ease and predictability of the steps involved in cataract surgery but has a surgical learning curve and most of the complications occur during the first 100 procedures [19]. Greater surgeon experience and improved technology are associated with a significant reduction in complications. Most complications are predictable and largely preventable.

5. Safety and efficacy of FLACS

5.1 Intraocular energy delivered

By using a laser to fragment the crystalline lens, less US energy is required to complete its removal. The reduction in the effective phako time can reach 70% and zero phacoemulsification time is possible in nearly 50% of operations [13].

Lower endothelial cell loss with the laser-assisted procedure compared with the manual phacoemulsification has been reported in the early post-operative state due to the reduction of EPT, with the LensX, the LensAR, the Catalys, and the Victus platforms [33].

5.2 Refractive outcomes

5.2.1 Distance visual acuity

The clinical comparative studies performed on a selected series of cases have failed to demonstrate any statistical significance of FLACS versus conventional phacoemulsification surgery concerning the visual outcomes, the intraocular lens power predictability, the corrected distance visual acuity (CDVA) and the uncorrected distance visual acuity (UDVA). Some studies reported better CDVA, UDVA and intraocular lens power predictability for FLACS, while others have reported no differences. In all cases, the 12-month post-operative visual acuity is high. The mean CDVA was 0.03 logMAR, range of -0.08 to 0.05 logMAR [2, 13, 32]. Superiority of UDVA in has been reported at 2 hours, 3 days, and 1 week postoperatively. After 1 month and later, no statistically significant

differences between groups are shown [16]. The mean long-term UDVA was 0.13 logMAR, range 0.07 to 0.23 [32, 34].

5.3 Post-operative and long-term complications

5.3.1 Anterior segment inflammation and flare

Two studies demonstrated that postoperative aqueous flare was significantly greater in eyes that had undergone manual cataract surgery at 1 day and at 4 weeks postoperatively than in eyes after FLACS [35, 36] without significant differences regarding retinal thickness after 3 months.

5.3.2 Late capsulorhexis decentration

Compared with manual capsulorhexis, there is evidence of advantages with FLACS by obtaining a more precise shape and size of capsulotomy [22]. This should be associated with a better intraocular lens centration, and then potentially less intraocular lens tilt. However, femtosecond laser capsulotomy shape changes over time and does not improve visual acuity compared with the manual procedure [37].

5.3.3 Vitreoretinal complications

Clinical cystoid macular edema (CME) after cataract surgery, manual or FLACS, remains a rare complication with a prevalence lower than 2% [2]. The peri-operative use of nonsteroidal drops may interfere with the CME rate. Endophthalmitis, expulsive hemorrhage and retinal detachment are rarer complications, estimated at less than 0.1% [38]. No difference between manual phacoemulsification and femtosecond procedures has been described.

5.3.4 Elevated intraocular pressure

The FLACS procedure induces a transient increase of intra-ocular pressure (IOP), during the suction phase, higher with flat and curved applanating contact interfaces compared with the fluid-filled interface. In the 2 years follow-up, no significant elevated IOP was observed after FLACS [39].

In summary, the rate of intra-operative and post-operative complications remains low, less than 2% and not statistically different between FLACS and manual phacoemulsification [40]. Although anterior and posterior capsule tears could have been a concern, the safety of FLACS and phacoemulsification cataract surgery seems equal, considering all complications.

5.4 Cost and resource use

Costs related to FLACS have been much higher than with the conventional procedure so far. It can represent a barrier to wider acceptance by surgeons and clinical centers. This may be difficulty to adopt as more functional benefits have not been yet clearly established with this new technology. An extra-cost of approximately USD 500 to USD 600 per operated eye is associated with FLACS (approximately USD 400,000 for the device, plus USD 150 to 300 for disposables per procedure). However, these elements may vary dramatically among different countries. If FLACS becomes more common in cataract surgery, these costs should decrease. Moreover, sharing a femtolaser platform between several surgeons and/or for several refractive procedures are also a current option to reduce costs [41].

5.5 Advantages and disadvantages of FLACS

Advantages of FLACS over manual phacoemulsification are its precision and predictability regarding the capsulotomy size and centration, corneal wound construction, and nucleus fragmentation [42]. It may be helpful in difficult situations such as pediatric cataracts white or subluxated cataracts. Even if the total energy delivered in the anterior chamber appears lower than during manual phacoemulsification, there is no strong evidence of difference in term of endothelial cell loss between the procedures. The FLACS procedure requires more operating room space as well as increase in operating time. The treatment can also lead to miosis. Altogether, there is no evidence of superior post-operative visual acuity with FLACS, whereas the costs associated with FLACS platforms are currently higher than with manual surgery. Future research on outcomes will help clarify if the increased costs can be supported by evidence of visual and clinical superiority of FLACS.

6. Conclusion: what is the future for FLACS?

The femtosecond laser cataract can be considered a young technology still in significant progress, compared with phacoemulsification, a very mature procedure, which has evolved for decades and has reached a very high level. Each year, companies offer new software evolving to a more user-friendly interface and more efficient versions. Progress is expected in the miniaturization of lasers, making them more moveable. New lenses may be specially designed, based on its perfect laser rhexis and would open a new refractive era, giving significant advantages to the laser procedure. The cost effectiveness is still questioned; many countries cannot afford or consider adopting this technology yet. If adequate improvements are achieved in the “FLACS of the future,” this technique may become the gold standard one day.

Conflict of interest

The authors have no financial interests.

IntechOpen

IntechOpen

Author details

Clemence Bonnet^{1,2}, Saba Al-Hashimi², Antoine P. Brézin¹ and Dominique Monnet^{1*}

1 OphtalmoPôle, Hôpital Cochin, APHP, Université de Paris, France

2 Stein Eye Institute, David Geffen School of Medicine, University of Los Angeles, Los Angeles, United States

*Address all correspondence to: dominique.monnet@aphp.fr

IntechOpen

© 2020 The Author(s). Licensee IntechOpen. This chapter is distributed under the terms of the Creative Commons Attribution License (<http://creativecommons.org/licenses/by/3.0>), which permits unrestricted use, distribution, and reproduction in any medium, provided the original work is properly cited. 

References

- [1] Clark A, Morlet N, Ng JQ, Preen DB, Semmens JB. Whole population trends in complications of cataract surgery over 22 years in Western Australia. *Ophthalmology*. 2011;**118**(6):1055-1061
- [2] Day AC, Gore DM, Bunce C, Evans JR. Laser-assisted cataract surgery versus standard ultrasound phacoemulsification cataract surgery. *Cochrane Database of Systematic Reviews*. 2016;**7**:CD010735
- [3] de Silva SR, Riaz Y, Evans JR. Phacoemulsification with posterior chamber intraocular lens versus extracapsular cataract extraction (ECCE) with posterior chamber intraocular lens for age-related cataract. *Cochrane Database of Systematic Reviews*. 2014;**1**:CD008812
- [4] Kessel L, Andresen J, Erngaard D, Flesner P, Tendal B, Hjortdal J. Indication for cataract surgery. Do we have evidence of who will benefit from surgery? A systematic review and meta-analysis. *Acta Ophthalmologica*. 2016;**94**(1):10-20
- [5] Erie JC, Baratz KH, Hodge DO, Schleck CD, Burke JP. Incidence of cataract surgery from 1980 through 2004: 25-year population-based study. *Journal of Cataract and Refractive Surgery*. 2007;**33**(7):1273-1277
- [6] Chen S, Feng Y, Stojanovic A, Jankov MR, Wang Q. IntraLase femtosecond laser vs mechanical microkeratomes in LASIK for myopia: A systematic review and meta-analysis. *Journal of Refractive Surgery (Thorofare, N.J.: 1995)*. 2012;**28**(1):15-24
- [7] Torky MA, Al Zafiri YA, Khattab AM, Farag RK, Awad EA. Visumax femtolasik versus Moria M2 microkeratome in mild to moderate myopia: Efficacy, safety, predictability, aberrometric changes and flap thickness predictability. *BMC Ophthalmology*. 2017;**17**(1):125
- [8] Sugar A. Ultrafast (femtosecond) laser refractive surgery. *Current Opinion in Ophthalmology*. 2002;**13**(4):246-249
- [9] He L, Sheehy K, Culbertson W. Femtosecond laser-assisted cataract surgery. *Current Opinion in Ophthalmology*. 2011;**22**(1):43-52
- [10] Nagy Z, Takacs A, Filkorn T, Sarayba M. Initial clinical evaluation of an intraocular femtosecond laser in cataract surgery. *Journal of Refractive Surgery (Thorofare, N.J.: 1995)*. 2009;**25**(12):1053-1060
- [11] Aristeidou A, Taniguchi EV, Tsatsos M, Muller R, McAlinden C, Pineda R, et al. The evolution of corneal and refractive surgery with the femtosecond laser. *Eye and Vision (London, England)*. 2015;**2**:12
- [12] Ahn H, Kim J-K, Kim CK, Han GH, Seo KY, Kim EK, et al. Comparison of laser in situ keratomileusis flaps created by 3 femtosecond lasers and a microkeratome. *Journal of Cataract and Refractive Surgery*. 2011;**37**(2):349-357
- [13] Grewal DS, Schultz T, Basti S, Dick HB. Femtosecond laser-assisted cataract surgery--Current status and future directions. *Survey of Ophthalmology*. 2016;**61**(2):103-131
- [14] Alió JL, Abdou AA, Soria F, Javaloy J, Fernández-Buenaga R, Nagy ZZ, et al. Femtosecond laser cataract incision morphology and corneal higher-order aberration analysis. *Journal of Refractive Surgery (Thorofare, N.J.: 1995)*. 2013;**29**(9):590-595
- [15] Montés-Micó R, Rodríguez-Galietero A, Alió JL.

- Femtosecond laser versus mechanical keratome LASIK for myopia. *Ophthalmology*. 2007;**114**(1):62-68
- [16] Chen X, Yu Y, Song X, Zhu Y, Wang W, Yao K. Clinical outcomes of femtosecond laser-assisted cataract surgery versus conventional phacoemulsification surgery for hard nuclear cataracts. *Journal of Cataract and Refractive Surgery*. 2017;**43**(4):486-491
- [17] Mariacher S, Ebner M, Seuthe A-M, Januschowski K, Ivanescu C, Opitz N, et al. Femtosecond laser-assisted cataract surgery: First clinical results with special regard to central corneal thickness, endothelial cell count, and aqueous flare levels. *Journal of Cataract and Refractive Surgery*. 2016;**42**(8):1151-1156
- [18] Alió JL, Abdou AA, Puente AA, Zato MA, Nagy Z. Femtosecond laser cataract surgery: Updates on technologies and outcomes. *Journal of Refractive Surgery (Thorofare, N.J.: 1995)*. 2014;**30**(6):420-427
- [19] Nagy ZZ, Takacs AI, Filkorn T, Kránitz K, Gyenes A, Juhász É, et al. Complications of femtosecond laser-assisted cataract surgery. *Journal of Cataract and Refractive Surgery*. 2014;**40**(1):20-28
- [20] Mayer WJ, Klaproth OK, Hengerer FH, Kohlen T. Impact of crystalline lens opacification on effective phacoemulsification time in femtosecond laser-assisted cataract surgery. *American Journal of Ophthalmology*. 2014;**157**(2):426-432.e1
- [21] Zhang J, Zhou Y, Zheng Y, Liu Q, Zhai C, Wang Y. Effect of suction on macular and retinal nerve fiber layer thickness during femtosecond lenticule extraction and femtosecond laser-assisted laser in situ keratomileusis. *Journal of Cataract and Refractive Surgery*. 2014;**40**(12):1994-2001
- [22] Kang M-J, Lee Y-E, Choi J-S, Joo C-K. Ideal parameters for femto-second laser-assisted anterior capsulotomy: Animal studies. *PLoS One*. 2018;**13**(1):e0190858
- [23] Diakonis VF, Yesilirmak N, Cabot F, Kankariya VP, Kounis GA, Warren D, et al. Comparison of surgically induced astigmatism between femtosecond laser and manual clear corneal incisions for cataract surgery. *Journal of Cataract and Refractive Surgery*. 2015;**41**(10):2075-2080
- [24] Hoffmann PC, Hütz WW. Analysis of biometry and prevalence data for corneal astigmatism in 23,239 eyes. *Journal of Cataract and Refractive Surgery*. 2010;**36**(9):1479-1485
- [25] Baharozian CJ, Song C, Hatch KM, Talamo JH. A novel nomogram for the treatment of astigmatism with femtosecond-laser arcuate incisions at the time of cataract surgery. *Clinical Ophthalmology (Auckland, N.Z.)*. 2017;**11**:1841-1848
- [26] Bali SJ, Hodge C, Lawless M, Roberts TV, Sutton G. Early experience with the femtosecond laser for cataract surgery. *Ophthalmology*. 2012;**119**(5):891-899
- [27] Malyugin B, Sobolev N, Arbisser LB, Anisimova N. Combined use of an iris hook and pupil expansion ring for femtosecond laser-assisted cataract surgery in patients with cataracts complicated by insufficient mydriasis and an ectopic pupil. *Journal of Cataract and Refractive Surgery*. 2016;**42**(8):1112-1118
- [28] Gupta PC, Ram J. Femtosecond laser-assisted cataract surgery in complex cases. *Journal of Cataract and Refractive Surgery*. 2016;**42**(11):1693
- [29] Scott WJ, Tauber S, Gessler JA, Ohly JG, Owsiak RR, Eck CD. Comparison of vitreous loss rates

between manual phacoemulsification and femtosecond laser-assisted cataract surgery. *Journal of Cataract and Refractive Surgery*. 2016;**42**(7):1003-1008

[30] Sutton G, Bali SJ, Hodge C. Femtosecond cataract surgery: Transitioning to laser cataract. *Current Opinion in Ophthalmology*. 2013;**24**(1):3-8

[31] Ye Z, Li Z, He S. A meta-analysis comparing postoperative complications and outcomes of femtosecond laser-assisted cataract surgery versus conventional phacoemulsification for cataract. *Journal of Ophthalmology*. 2017;**2017**:3849152

[32] Popovic M, Campos-Möller X, Schlenker MB, Ahmed IIK. Efficacy and safety of femtosecond laser-assisted cataract surgery compared with manual cataract surgery: A meta-analysis of 14567 eyes. *Ophthalmology*. 2016;**123**(10):2113-2126

[33] Abell RG, Kerr NM, Howie AR, Mustaffa Kamal MAA, Allen PL, Vote BJ. Effect of femtosecond laser-assisted cataract surgery on the corneal endothelium. *Journal of Cataract and Refractive Surgery*. 2014;**40**(11):1777-1783

[34] Conrad-Hengerer I, Sheikh MA, Hengerer FH, Schultz T, Dick HB. Comparison of visual recovery and refractive stability between femtosecond laser-assisted cataract surgery and standard phacoemulsification: Six-month follow-up. *Journal of Cataract and Refractive Surgery*. 2015;**41**(7):1356-1364

[35] Jun JH, Yoo Y-S, Lim SA, Joo C-K. Effects of topical ketorolac tromethamine 0.45% on intraoperative miosis and prostaglandin E2 release during femtosecond laser-assisted cataract surgery. *Journal of Cataract and Refractive Surgery*. 2017;**43**(4):492-497

[36] Jun JH, Hwang KY, Chang SD, Joo C-K. Pupil-size alterations induced by photodisruption during femtosecond laser-assisted cataract surgery. *Journal of Cataract and Refractive Surgery*. 2015;**41**(2):278-285

[37] Panthier C, Costantini F, Rigal-Sastourné JC, Brézin A, Mehanna C, Guedj M, et al. Change of capsulotomy over 1 year in femtosecond laser-assisted cataract surgery and its impact on visual quality. *Journal of Refractive Surgery (Thorofare, N.J.: 1995)*. 2017;**33**(1):44-49

[38] Taravella MJ, Meghpara B, Frank G, Gensheimer W, Davidson R. Femtosecond laser-assisted cataract surgery in complex cases. *Journal of Cataract and Refractive Surgery*. 2016;**42**(6):813-816

[39] Baig NB, Cheng GPM, Lam JKM, Jhanji V, Chong KKL, Woo VCP, et al. Intraocular pressure profiles during femtosecond laser-assisted cataract surgery. *Journal of Cataract and Refractive Surgery*. 2014;**40**(11):1784-1789

[40] Tran DB, Vargas V, Potvin R. Neodymium:YAG capsulotomy rates associated with femtosecond laser-assisted versus manual cataract surgery. *Journal of Cataract and Refractive Surgery*. 2016;**42**(10):1470-1476

[41] Bartlett JD, Miller KM. The economics of femtosecond laser-assisted cataract surgery. *Current Opinion in Ophthalmology*. 2016;**27**(1):76-81

[42] Donaldson KE, Braga-Mele R, Cabot F, Davidson R, Dhaliwal DK, Hamilton R, et al. Femtosecond laser-assisted cataract surgery. *Journal of Cataract and Refractive Surgery*. 2013;**39**(11):1753-1763