

We are IntechOpen, the world's leading publisher of Open Access books Built by scientists, for scientists

5,000

Open access books available

125,000

International authors and editors

140M

Downloads

Our authors are among the

154

Countries delivered to

TOP 1%

most cited scientists

12.2%

Contributors from top 500 universities



WEB OF SCIENCE™

Selection of our books indexed in the Book Citation Index
in Web of Science™ Core Collection (BKCI)

Interested in publishing with us?
Contact book.department@intechopen.com

Numbers displayed above are based on latest data collected.
For more information visit www.intechopen.com



Toward a Molecular Classification of the Head and Neck Squamous Cell Carcinoma

Amalia Raluca Ceausu, Eugen Radu Boia, Eugen Sorin Boia, Anca Maria Cimpean and Marius Raica

Abstract

The frequency of the squamous cell carcinoma of the head and neck is constantly increasing, with over 550.000 new cases registered globally each year. The conventional histopathological diagnosis most commonly indicates the squamous cell carcinoma as tumor type and G2 as differentiation grade. Despite of this relative morphological uniformity, there is a great heterogeneity in the molecular profile, the therapeutic response and prognosis. Most probably, this entity includes many diseases, similar in basic morphologic features, but different in the biological behavior. Trying to answer this question and to show discrepancies when they exist, we have evaluated in this book chapter, our own results and data from the literature in terms of molecular profile at the protein level, including the spectrum of proliferation markers, growth factors and their receptors, stromal proliferation, angiogenesis and lymphangiogenesis. These data will allow to identify some major criteria for a better stratification of cases, selected for gene analysis and personalized therapy as a future perspective and direction.

Keywords: HNSCC, molecular profile, stroma, stratification of cases, gene analysis

1. Introduction

The recent data regarding the global cancer statistic [1] indicate an increase number of new diagnosed HNSCC cases each year. Despite the efforts, the 5 years OS rate of HNSCC has not improve significantly over the last years. There are several reasons that can be mentioned: the classic causative factors such as alcohol consumption and tobacco usage, the presence of the lymph nodes metastases at the time of the diagnosis, important increase in the HPV infections in the Western world. [2]. Between 40 to 60% of HNSCC treated patients have recurrence and not respond to subsequent therapeutic interventions [3]. Another important reason may be the accentuated heterogeneity of HNSCC at the molecular level, the inability of a clear stratification of the cases and the absence of a certain link between the molecular subtypes and the clinical outcome. A number between four and six molecular types of HNSCC were described in the literature. Chung [4] described four distinct subtypes: first (displays EGFR pathway and hypoxia related molecular signatures), the second is mesenchymal marker enriched, the third has features of normal epithelia and the fourth expresses high levels of transcripts coding for

antioxidant and detoxification enzymes. The four groups of HNSCC proposed by Walter [5] are: basal, mesenchymal, atypical, and classical. Five subgroups of HNSCC were described also by another research team: three HPV negative (basal, classical non- HPV and mesenchymal non -HPV) and two HPV positive (classical HPV and mesenchymal HPV) [6]. Other author described six subtypes (immuno-reactive, inflammatory, HPV-like, classical, hypoxia associated and mesenchymal) [7]. The heterogeneity of the tumor microenvironment and the clear histological margin used today may be other reasons for tumor recurrences.

We try in the following to identify some major criteria for a better stratification of the cases, and for a better surveillance of the postoperative margins, targeting the personalized therapy.

2. The conventional histopathological diagnostic and morphological features

The head and neck squamous cell carcinomas are epithelial tumors originating in the covering mucosa of oral cavity, larynx, oropharynx, and hypopharynx [8]. In an attempt to cover the heterogeneous spectrum of these tumors, the most used clinical management is based on anatomic location, phenotype, evaluation of the existence of tumor -node-metastasis by the TNM classification and the depth of tumor invasions [9]. The WHO classification of head and neck tumors includes tumors of the nasal cavity, paranasal sinuses and skull base (with the keratinizing, non-keratinizing and spindle cell squamous cell carcinoma types), tumors of the nasopharynx, of the hypopharynx, larynx, trachea, parapharyngeal space (with the conventional, verrucous, basaloid, papillary, spindle cell types of squamous cell carcinomas), tumors of the oral cavity and mobile tongue, of the oropharynx (base of the tongue, tonsils, adenoids) with HPV positive and HPV negative types of squamous cell carcinoma, tumors and tumors-like lesions of the neck and lymph nodes, tumors of salivary glands, odontogenic and maxillofacial bone tumors, tumors of the ear and paraganglion tumors [10].

In the conventional histopathological diagnosis, the squamous cell carcinoma may be graded as well, moderate, and poorly differentiated type. The well differentiated type of keratinized squamous cell carcinoma is characterized by the presence of the keratinizing and para-keratinizing pearls. Morphological features in the moderately differentiated squamous cell carcinoma are nuclear pleomorphism, mitoses, including atypical type and less keratinization. The poorly differentiated type is characterized by the predominance of the immature cells, a high number of typical and atypical mitoses, reduced keratinization and necrosis either over large areas of the section or in the center of the tumor areas, variable in extent. Most HNSCC are moderately- differentiated [11, 12] aspect sustained by our data where a percentage of 73.8% and 71% from HNSCC evaluated cases were diagnosed as G2 [13, 14]. The non-keratinized squamous cell carcinomas have the following morphological features: the existence of a large, interconnected band of tumor epithelial cells without keratinization and minimal or absent necrosis, pleomorphic cells, hyperchromasia and an intense mitotic activity.

The histologic grade prognostic impact remains controversial in HNSCC. It was accepted by the current edition of the Classification of Head and Neck Tumors but with the mention that grading alone does not correlate well with prognosis [15]. It is not a part of the UICC staging system, but some data consider high grade as an indication for the adjuvant treatment in OSCC [16, 17].

Starting from these premises it may be launched the question why the patients with the same histological grade have such a heterogeneous therapeutic response and prognosis.

3. The molecular profile at the protein level- cytokeratins, vimentin, podoplanin

The present molecular classification described four types of HNSCC as following: classical, basal, mesenchymal, and atypical subgroups. Excepted from this are the hypopharyngeal cancers characterized by the absence of the BA subgroup.

Keratins are a family of the intermediate filament proteins which are present in epithelial cells. Some of the main functions of keratins are structural in forming the cytoskeleton, protein synthesis, cell growth, signaling, organelle transport, mobility, and cell proliferation [18]. The keratin pattern distribution in a stratified epithelium is as follows: K1, 2, 10 and 11 are positive in cornified cells, K4 and 13 in stratified cells and K5 and 14 in basal cells [19].

The aberrant expression of keratins was found to be associated with HNSCC development and progression. High values of K 8, 17 and 19 immunoexpression were noticed in the biopsies of head and neck squamous cell carcinoma patients [20].

Keratin 5 was showed to be expressed with value of score between 1 and 3 (more than 30% positive cells), in squamous cell carcinoma with different histological grade and anatomical localization [21]. K5 together with EGFR, p63, CD 117 may be a helpful marker for define a distinct class of HNSCC (basal -like type, characterized by K5+/EGFR +/p63+/CD117+ profile). On the other hand, keratin 5 expression has been shown to correlate with the intermediate phenotype of cells involved in the epithelial-mesenchymal transition phenomenon [13, 22]. Some data demonstrated the by the immunohistochemical evaluation a loss of epithelial markers such as keratin 76 and epithelial cell adhesion molecule in the HNSCC [23, 24]. E- cadherin, involved in the cancer progression and metastasis by decrease of cellular adhesion and increase in cellular motility is co-expressed with Ep CAM. A decrease of E-cadherin expression associated with HPV 18 positivity were found in well and moderately differentiated type of HNSCC with larynx, oropharynx, pharyngo- laryngeal, and nasal-sinus localization. The rhino-pharynx, hypo-pharyngeal and laryngeal HPV18 negative cases were associated with a decrease of E-cadherin values in the moderately, poorly, and undifferentiated types.

The demonstrated role of cytokeratins in the diagnosis and prognosis of squamous cell carcinomas by using surrogate markers and biopsy tissues, oriented the research in the direction of a non-invasive diagnostic biomarker such as salivary keratins for the HNSCC [14, 19, 25].

The other molecule expressed in the basal cells of stratified epithelium is K14 which has an important role in cell differentiation. It was shown that K14 downregulation is associated with an increase in TAp63 and Notch-1 intracellular expression which regulates genes responsible for differentiation [26].

Vimentin is an intermediate filament intensely expressed in cells with mesenchymal phenotype. Its expression in oral epithelial cells has been linked by the tumor invasion, metastasis and EMT phenomenon [27].

It was shown that miR-876-5p, a tumor suppressor in HNSCC, represent a novel therapeutic target by acting on vimentin and inhibits metastasis [28].

The potential prognostic role of vimentin was described for TSCC and OSCC [29, 30]. In the first situation, vimentin among the EMT related proteins such as Snail, E- cadherin and N-cadherin are involved. In the second situation, an association between vimentin intense immunoexpression and a high risk for cervical lymph node metastatic potential was noticed. It was showed that vimentin-SOX 2 interrelation may represent an unfavorable risk factor for survival of head and neck squamous cell carcinoma. The loss of SOX2 expression induces cell motility by vimentin up-regulation [31].

Podoplanin, a 38 KDa type I transmembrane glycoprotein is overexpressed in different human cancers, including HNSCC.

An interrelation between histological grade differentiation and podoplanin immunoexpression was described in HNSCC. The main pattern of immunoexpression was in the cytoplasm and membrane with focal (mainly in the well differentiated OSCC) and diffuse distribution type (mainly in the moderately and poorly differentiated OSCC). The podoplanin was not expressed in the some of the well and poorly differentiated oral SCC cases. In all the moderately differentiated cases of SCC a positive reaction for podoplanin was noticed. The highest values for podoplanin with cytoplasm and membrane pattern expression was associated with poorly differentiated of oral SCC type. High levels of podoplanin expression was associated with high frequency of lymph node metastasis in OSCC [32]. A tendency of increasing podoplanin expression with decreasing of differentiation grade was noticed [33]. In OSCC was demonstrated the podoplanin involvement in the cytoskeleton remodeling, ECM degradation and tumor invasion. These are realized by co-location, co-ordination of podoplanin, Cdc42 and MT1-MMP in the invadopodia [34].

SCCs of the larynx and hypopharynx with high values of podoplanin expression were associated with an unfavorable prognosis also [35]. Podoplanin may have a predictive value of aggressiveness in HNSCC evolution, together with other markers such as EGFR and E-cadherin.

Another pathway through which podoplanin induces a decrease in overall survival was shown in the murine experimental models. Podoplanin expression in the OSCC tumors increased platelet activation and promotes intravascular platelet aggregation and intratumor platelet infiltration. The coagulation state is favored [36].

4. Proliferation markers: p53 and Bcl2

P53 is a transcription factor that regulates the cell cycle, DNA repair and apoptosis. One of its main role is to maintain cellular integrity after DNA damage. Consecutive to this moment, p53 is regulated in a MDM2-dependent manner and activated by cell cycle checkpoint kinases type 1 and 2 [37]. In normal conditions, p53 may be expressed with a nuclear pattern in basal cells of the epithelium. In HNSCC p53 immunoexpression was described in 50% of the evaluated cases or more. Controversial data concerning p53/EGFR co-expression exists. In our data, 44% of larynx and 70.5% of pharynx cases co-expressed p53/ EGFR. All of the p53 positive cases co-expressed EGFR. These features were noticed by using a double immunohistochemical staining p 53/ EGFR. For larynx localization, p53/ EGFR co-expression was noticed mainly at the periphery of the tumor area (in all of the moderately differentiate cases- **Figure 1**, in 25% of well differentiate cases with much more reduced number of co-expressing cells, in 50% of poorly differentiated type). In corresponding lymph nodes of laryngeal tumors, the co-expressing cells were present in the immediate vicinity of the lymphoid tissue and to the periphery of tumor areas. In the center of tumor areas EGFR or p53 positive cells only were found, not co-expressing cells. The distribution pattern of the co-expressing cells from the hypopharynx may be noticed in the **Figure 2**. The distribution pattern of co-expressing cells to the periphery of tumor areas was found in the oropharynx, pharyngo-laryngeal and sinus nose localization. The co-expressing cells were absent in the naso-pharyngeal localization. A significant correlation was found between p53 intensity of expression and extranodal extension and tumor grade, mainly grades II and III [38, 39]. All of these p53/EGFR co-expression data may be useful for a better stratification of HNSCC, regarding the diagnostic but the therapy also.

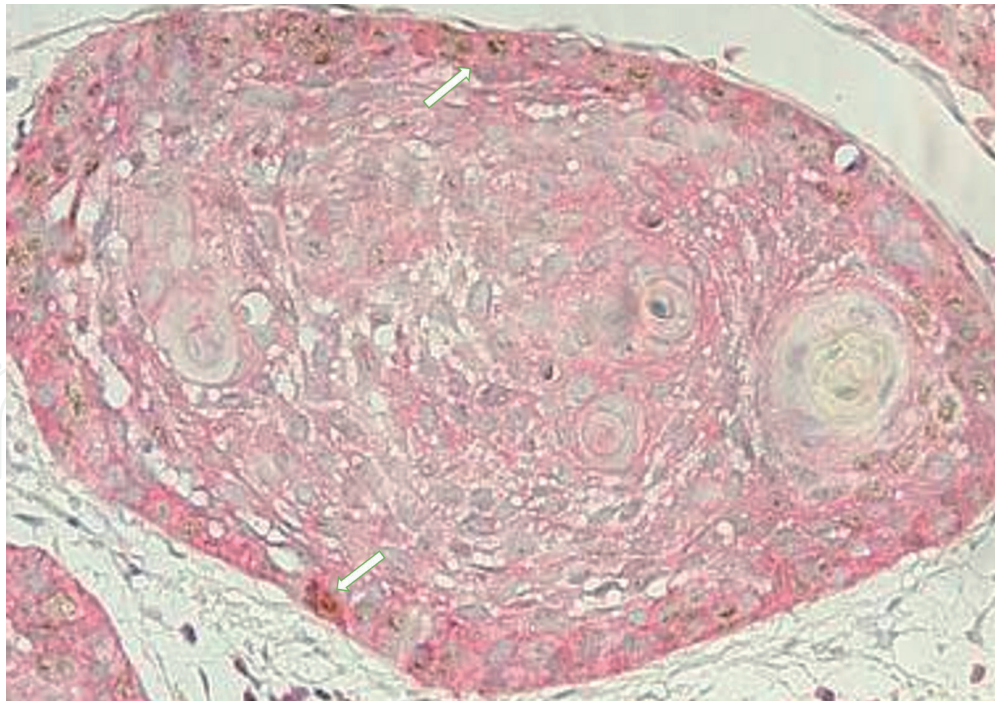


Figure 1.
p53/EGFR co- expression (white arrows) in tumor area in a case of moderately differentiated squamous cell carcinoma with larynx localization, double immunostaining p53/EGFR, ob.X40.

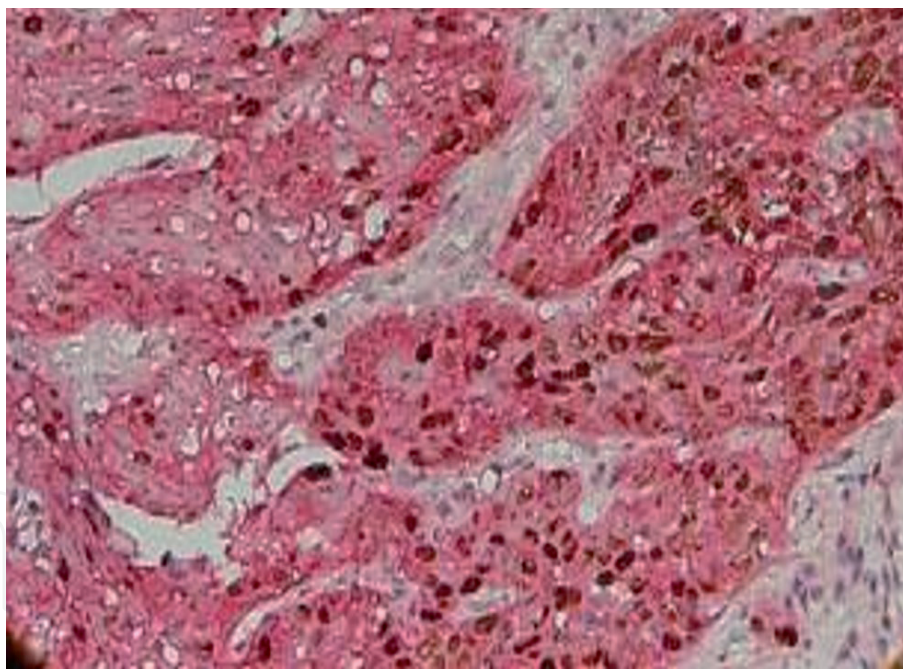


Figure 2.
EGFR/p53 immunoexpression, non-keratinized squamous cell carcinoma, moderately differentiated of hypopharynx, double immunostaining p53/EGFR, ob.X40.

The major pathways involved in the tumorigenesis of HNSCC include dysregulation of the following processes: cellular survival and proliferation, cell-cycle control, cellular differentiation and adhesion and invasion signaling. The main important factors involved in the cellular survival and proliferation are: TP53, HRAS, EGFR, PIK3CA. The functional inactivation of the p53 pathway was demonstrated in 80% of HNSCC, that why a therapeutic strategy which focus on the restoration of p53 function was developed for the HPV negative and HPV associated HNSCC. Unfortunately, the adenoviral p53 gene therapy has not been shown to be effective in clinical trials [40, 41].

Another important role of p 53 is the expression in the surgical margins. Pathology in the margin represent an considerable prognostic factor for relapse free survival (RFS) in the management of HNSCC treated with primary surgery. In the OSCC, a local recurrence value varies between 10 and 30% even if the histological status of margins is clear. The following surgical margins classification is used by surgeons and pathologists: involved margins (margin ≤ 1 mm), close margins (margin 1–5 mm) and clear margins (margin > 5 mm) [42]. Severe dysplasia and invasive carcinoma needing additional resection while moderate and mild dysplasia do not. Evaluation of the p53 overexpression in histological resection margins of oral and oropharyngeal SCC demonstrated a 5.333 times higher chance of local recurrences if at least one margin overexpressed p53. P53 as an independent risk factor has been demonstrated in early OSCC with dysplastic surgical margin. It may be a useful marker for postoperative decision for these patients [43, 44].

Bcl-2 (B-cell lymphoma 2) encoded in humans by the Bcl2 gene is a member of the family of regulatory proteins that influence apoptosis through both pro and anti-apoptotic or inhibitory effects. Pro-survival Bcl-2 proteins (Bcl-2, Bcl-xL, MCL-1) inhibit Bcl-2 pro-apoptotic effectors (BAX and BAK).

The immunohistochemical evaluation of cases from our studies, revealed a relatively reduce number of bcl2 cases. The value of positive cases was close to 30%. The differences were noticed between anatomic areas. At the larynx, oropharynx, hypopharynx, nasopharynx, bcl 2 expression in some of the cases was found. At the pharyngo-larynx, nasal sinus, bcl 2 expression was absent. Cases of well and poorly differentiated keratinized squamous cell carcinoma of the larynx were characterized by the absence of Bcl2 immunohistochemical expression in tumor cells. A similar appearance was noticed in the tumor cells of the corresponding lymph node. The Bcl2 immunoexpression had a score value 2 (10–30% positive tumor cells) in primary tumor and corresponding lymph node of the squamous keratinized moderately differentiated larynx carcinoma. The same value was found in the oropharynx. In the lymph node of the non-keratinized moderately differentiated type of the larynx squamous cell carcinoma more than 50% of bcl 2 positive tumor cells were noticed (a value 3 of the score).

In the hypopharynx localization isolated Bcl 2 positive tumor cells were found in the tumor areas (score value 1, with less than 10% Bcl2 positive tumor cells- **Figure 3**). An intense Bcl2 expression as intensity and value of the score was expressed in the stromal cells in the vicinity of tumor areas.

The highest value score of Bcl2 (value 3: more than 50% Bcl2 positive tumor cells- **Figure 4**) was present in the non-keratinized moderately differentiated squamous cell carcinoma with rhino-pharynx localization. In the group of EGFR positive cases, 3 sub groups were described: EGFR+/p53-/bcl2-, EGFR+/p53+/bcl2+ and EGFR+/p53+/bcl2-/with a significant correlation between N parameter and EGFR expression in this last subgroup. In the K5+/EGFR + cases significant correlation between bcl2 and M ($p = 0.01$) and N ($p = 0.04$) parameters were found. Other HNSCC immunohistochemistry data indicated a higher Bcl 2 expression, compare with our data, around 88% of evaluated cases. A significant correlation was reported between the Bcl2 expression and histological grade, lymph node involvement but not clinical stage. They noticed a significant association between p53+/Bcl2 + and histological grade, lymph node involvement [13, 45].

Other authors considered that immunohistochemical staining of Bcl2 is not significantly correlated with tumoral aggressiveness and prognosis to the patients diagnosed with laryngeal squamous cell carcinoma and treated with primary surgery [46]. The molecular mechanism and genetic basis of the development of larynx carcinoma have not been fully elucidated. Some data revealed the involvement of Bcl2-Hsp90beta in the anti-apoptotic progression of larynx carcinoma. The

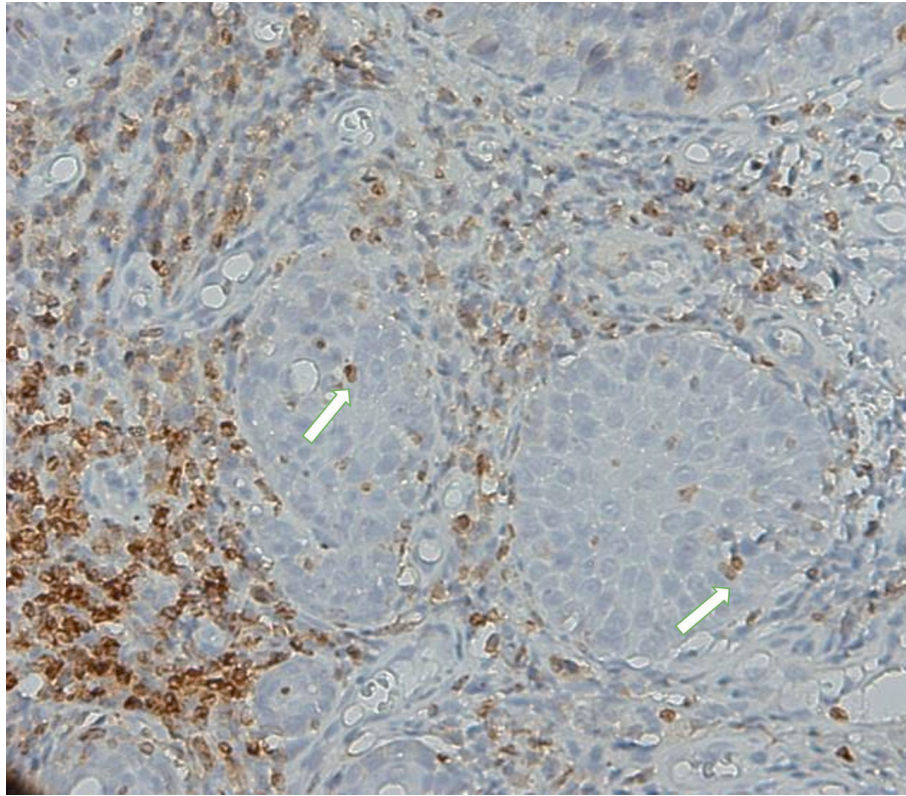


Figure 3.
Value 1 of Bcl2 immunorexpression score inside the tumor area (white arrows), in a moderately differentiated squamous cell carcinoma of the hypopharynx, Bcl2 immunostaining, ob.X40.

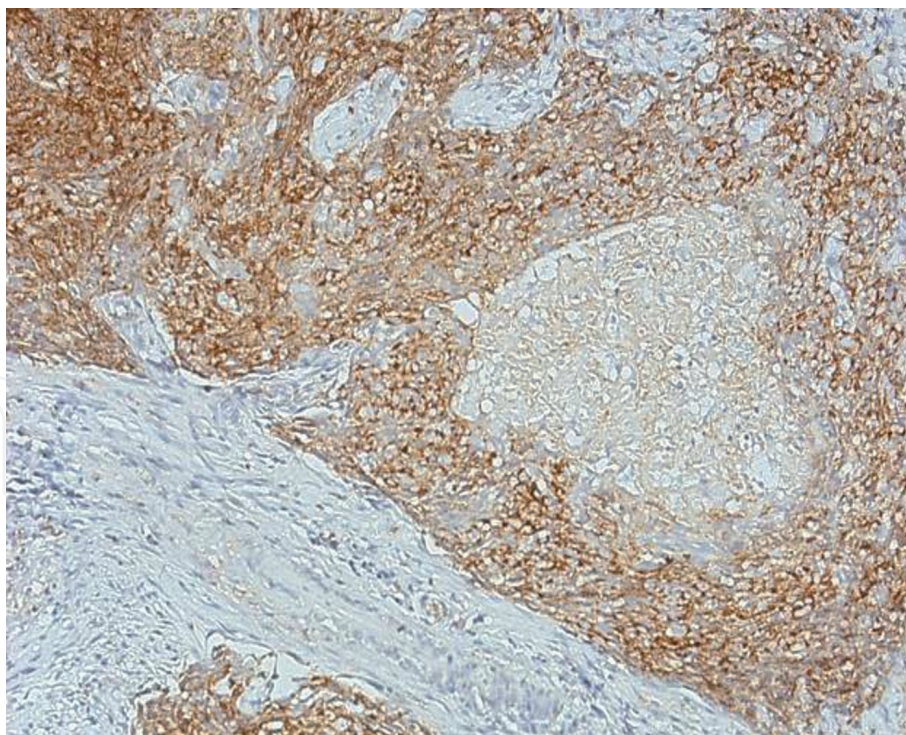


Figure 4.
Value 3 of Bcl-2 expression score in a moderately differentiated, non-keratinized squamous cell carcinoma of the rhinopharynx, Bcl2 immunostaining, ob. X 20.

disruption of Bcl2-Hsp90beta interaction inhibited the anti-apoptotic ability of Bcl2 and reduced the capsizae activation in larynx carcinomas [47].

It was demonstrated the role of miR-15a as a suppressor in HPV positive by targeting bcl2 in HSCC [48]. The effect of Navitoclax (a small inhibitor molecule

of Bcl-2/Bcl-xL), in high doses was the death of HNSCC cells. But a limited effect was found in combination with radiation or cisplatin. Co-inhibition of MCL-1 was required to improve approaches targeting Bcl-2/Bcl-xL in HNSCC. [49]

By evaluate two groups of metastatic and non-metastatic primary OSCC, Pavithra et al. [50] found no significant difference in the expression of Bcl2 between the two groups. They sustained that evaluation of Bcl2 along with other apoptotic proteins could define the role in prognosis and pathogenesis of OSCC.

Taking into account all these data, bcl2 alone or together with p53 expression may still represent some important markers for tumor aggressivity and survival rates in the conditions of a better stratification of the patients.

5. Growth factors and their receptors

Some of the most important growth factors already described to be involved in the prognosis or therapy resistance of HNSCC are: epidermal growth factor (EGF) and its receptor EGFR, vascular endothelial growth factor (VEGF) and VEGFR 1 and 2 mainly, platelet derived growth factor (PDGF AA) and PDGFR alpha, nerve growth factor (NGF) and transforming growth factor beta (TGF-beta).

There are some molecular-targeted therapies used in the treatment of head and neck squamous cell carcinoma. The molecular targeted therapy such as Cetuximab, panitumumab, zalutumumab and nimotuzumab acts on EGFR monoclonal antibodies; Gefitinib, erlotinib, lapatinib, afatinib, dacomitinib inhibit EGFR tyrosine kinase receptors; Bevacizumab (VEGF inhibitor); Sorafenib, sunitinib, vandetanib (VEGFR inhibitors); Rapamycin, temsirolimus, everolimus, torin 1, PP242 and PP30 (PI3K/AKT/mTOR pathway); Pembrolizumab and nivolumab (anti-PD-1).

The EGFR ligands such as EGF, transforming growth factor alpha (TGFA), heparin-binding EGF-like growth factor (HBEGF), amphiregulin (AREG), betacellulin (BTC), epiregulin (EREG) and epigen (EPGN) are involved in tumor growth, invasion and metastatic process through EGFR activation. In HNSCC, these ligands/receptors are deregulated. It was noticed an important correlation between mRNA levels of four EGFR ligands and the poor prognosis in HNSCC. The inhibiting EGF-induced AREG expression was proposed as a new treatment option in HNSCC [51].

The EGFR targeting monoclonal antibody, Cetuximab was FDA approved for HNSCC treatment in 2006. But, despite the advances in therapy, the overall five years survival rate of patients with advanced HNSCC remains relatively reduced, around 40–50%. Some data described mutations in various oncogenes and tumor suppressor genes in HNSCC profile, as following: PIK3CA (21%), HRAS (4%), TP53 (72%), CDKN (22%), FBXW7 (5%), KMT2D (MLL2) (18%) and PTEN (2%). PI3K/AKT pathway responsible of proliferation, survival and cell differentiation exhibit alterations in around 34% of patients diagnosed with HNSCC. This pathway may be responsible for tumor escape during EGFR targeting in HNSCC. It was demonstrated the role of PIK3CA and RAS mutations in predicted cetuximab resistance in the first line recurrent and/or metastatic setting and the role of PTEN protein expression loss in predicted resistance to cetuximab when combined to radiotherapy [52].

VEGF-A and the others family members (VEGF-B, VEGF-C, VEGF-D) are overexpressed in the majority of HNSCC cases. They act by inducing tumor growth by changing the microvascular density, favorizing cell migration and metastasis. The reduced sensitivity to radiation and progression of HNSCC is associated with stimulation of angiogenesis by tumor cells that undergo radiotherapy. The results of phase I and II clinical trials of Bevacizumab and erlotinib combined administration

indicated an increase of median survival by seven months. One of the therapeutic agents, which induce autophagy and inhibits tumor growth was Sorafenib, a serine-threonine protein kinase inhibitor b-Raf, C-Raf, VEGF and PDGFR. Sunitinib, a small molecule kinase inhibitor of VEGFR, PDGFR and c-kit tyrosine kinase has a reduced effect if it is use as monotherapy but associated with Cetuximab favored the decrease of tumor cell proliferation and an increase of cell differentiation. Vandetanib, which targeted on EGFR, VEGFR2, RTK used in combination with cisplatin and radiotherapy reduced the resistance to EGFR inhibitors in preclinical trials [53]. It was demonstrated also the role of the preoperative or postoperative serum levels of VEGF as a predictive factor for recurrence, disease-free and overall survival of patients with HNSCC [54]. The results obtained on culture cells support the application in clinical practice of the levels of the VEGFR promoters. Methylation of VEGFR1 and VEGFR3 promoters correlated with poor prognosis. It was established a link between methylation of the VEGFR2 promoter and lymph node metastasis [55].

Concerning PDGF and their receptor it was found a prognostic role of PDGF serum level in patients with OSCC and a worse prognostic of HNSCC patients induced by the presence of PDGFR-alfa expression in the tumor microenvironment [56, 57].

Both normal and malignant epithelial cells expressed NGF receptors and NGF gene. Neurotrophins are involved in perineural growth in HNSCC, a pathway of tumor progression associated with poor prognosis. Neurotrophins link to low affinity nerve growth factor (LNGFR/p75 neurotrophin receptor-p75 NTR) or to the high affinity Trk (tropomyosin related kinase) tyrosine kinase receptors. P75 NTR was described in an undifferentiated cell population of oral leukoplakia and in OSCC where was associate with a poor prognosis. P75NTR contribute to drug resistance, by involvement in multiple signaling pathways. A correlation between neurotrophin receptor tyrosine kinase (NTRK2) overexpression and epithelial to mesenchymal transition in HNSCC tumor cells was found. It seems that p75NTR might related with NGF -independent therapy resistance in HNSCC, while NTRK1 might transduce a survival signal on NGF and improved cell survival after cell cycle arrest [58].

Another important growth factor with increased importance in HNSCC is hepatocyte growth factor (HGF) and its receptor c-MET. The overexpression of HGF was commonly reported in HNSCC cases. C-MET was overexpressed in lymph node metastasis of HNSCC. C-MET encodes mesenchymal epithelial transition factor which favored invasion and metastatic potential in cancers. Their overexpression may be associated with worse prognostic and reduced overall survival rate. EGFR and c-MET share common downstream pathways: RAS-RAF-MAPK and PI3K-AKT-mTOR. In the patients with resistance to EGFR targeted therapies c-MET/HGF inhibitors may represent an alternative solution. Capmatinib as monotherapy and Ficlaturzumab combined with Cetuximab are some of c-MET/HGF axis therapeutic solutions.

Transforming growth factor beta realized homeostasis between the proliferation and apoptosis of normal epithelial cell by Smads or Smad independent downstream pathways. Tumor suppression and tumor promotion is the main role of TGF beta in HNSCC [59].

6. The afferent stroma proliferation. The mast cell, blood vessels and lymphatic vessels involvement

The stromal component of the tumor microenvironment contains different cells types such as: cancer associated fibroblast, macrophages, regulatory T cells and mast cells.

Regulatory T cells recruitment is regulated by chemokines and associated receptors (CCL28-CCR10 and CXCL12-CXCR4). The immunohistochemical specific markers of these cells are CD4 and CD25. It was identified a subgroup of Tregs, TIM3, with high levels of T-cell immunoglobulin and mucin domain-3. It was notice that these cells are linked with resistance to radiotherapy and their number decrease after PD-1 monoclonal antibody administration. In HNSCC, a high number of Tregs induces a negative prognostic [60].

Described for the first time by Ehrlich in 1878, mast cells differ through their localization and content, depending on their phenotype: connective tissue MCs and mucosal MCs. Mast cells granules contained preformed mediators such as: tryptase, chymase, cathepsin G, histamine, heparin, serotonin, IL-16, and TNF alpha. Mediators synthesized after mast cell activation are interleukines (IL1, IL 3, IL4, IL 5, IL6, IL 8, IL 10, IL 13, IL 16, platelet activating factor, RANTES, MIF 1 alpha) and arachidonic acid metabolites, prostaglandin and leukotriene C4 [61, 62].

In HNSCC, some authors noticed a decrease in mast cell number associated with advanced histological grade in OSCC, other found a significant correlation between mast cells density and G1, G2 histological grade in larynx carcinoma [63, 64].

By the content of their granules such as VEGF or other substances with angiogenic properties, mast cells may stimulate angiogenesis. In the larynx carcinoma, the differentiation grade was correlated with mast cell density but not with the microvascular density [64]. Other data indicated a higher MVD in HNSCC compare with MVD values noticed in dysplasia of the upper respiratory tract epithelium. No significant correlation was found between MVD/CD34 values and local invasiveness (the T feature) in HNSCC [65]. Increased values of MVD and mast cell density were present in OSCC compare with leukoplakia with and without dysplasia. [66]

Lymphangiogenesis is the process of new lymphatic vessel formation. The growth factors such as VEGF-C, VEGF -D, PDGF-BB and HGF may influence the formation of new lymphatic vessels. Both lymphatic and microvascular density in peritumoral area may have a prognostic value. Some data demonstrated that peritumoral MVD was associated with metastasis and LMVD was inversely related to both metastasis and progression in HNSCC [67]. Other authors compared the intra and peritumoral lymphatic microvascular density and found a significantly lower density in the peri-tumoral areas. They found significant correlation between LMVD values (intra and peri-tumoral) and differentiation degree. From clinical parameters, an important correlation between total LMVD and lymph node status, but not tumor stage was reported [68]. These observations were reconfirmed by other study which reported an important correlation between both high intra-tumoral and peritumoral LVD and lymph node metastasis. The morphology of peri-tumoral lymphatic vessels was similar, with a large lumen, like in the previously study, but the number of lymphatic vessels was higher in peritumoral area compared with intra-tumoral area, opposite to previous study [69].

These results support the importance of the lymphangiogenesis and lymphatic vascular density as risk and prognostic factors of the patients with lymph node metastasis.

7. Conclusions

From the mentioned data results the necessity of a better stratification of HNSCC. The novel molecular techniques of the surgical margins can offer a more accurate risk assessment. The results of genetic and molecular biology studies may outline the criteria for the targeted therapy as a fundamental method of cancer treatment in the future.

Conflict of interest

The authors declare no conflict of interest.

IntechOpen

Author details

Amalia Raluca Ceausu^{1*}, Eugen Radu Boia², Eugen Sorin Boia³,
Anca Maria Cimpean¹ and Marius Raica¹


1 Department of Microscopic Morphology/Histology, Angiogenesis Research Center, “Victor Babes” University of Medicine and Pharmacy, Eftimie Murgu Square, No. 2, 300041, Timisoara, Romania

2 ENT Department, “Victor Babes” University of Medicine and Pharmacy Timișoara, Eftimie Murgu Square, No. 2, 300041, Timisoara, Romania

3 Department of Pediatric Surgery and Ortopedics, “Victor Babeș” University of Medicine and Pharmacy Timișoara, Eftimie Murgu Square, No. 2, 300041, Timisoara, Romania

*Address all correspondence to: ra.ceausu@umft.ro

IntechOpen

© 2020 The Author(s). Licensee IntechOpen. This chapter is distributed under the terms of the Creative Commons Attribution License (<http://creativecommons.org/licenses/by/3.0>), which permits unrestricted use, distribution, and reproduction in any medium, provided the original work is properly cited. 

References

- [1] Bray F, Ferlay J, Soerjomataram I, Siegel RL, Torre LA, Jemal A. Global cancer statistics 2018: GLOBOCAN estimates of incidence and mortality worldwide for 36 cancers in 185 countries. *CA Cancer J. Clin.* 2018; 68: 394-424. DOI: 10.3322/caac.21492
- [2] Leemans CR, Snijders PJF, Brakenhoff RH. The molecular landscape of head and neck cancer. *Nat. Rev. Cancer.* 2018; 18: 269-282. DOI: 10.138/nrc.2018.11
- [3] Tolstong G, Simon C. Trends in surgical research in head and neck cancer. *Curr. Treat. Options Oncol.* 2017; 18: 38-51. DOI: 10.1007/s11864-017-0475-z
- [4] Chung CH, Parker JS, Karaca G, Wu J, Funkhouser WK, Moore D, Butterfoss D, Xiang D, Zanation A, Yin X, Shockley WW, Weissler MC, Dressler LG, Shores CG, Yarbrough WG, Perou CM. Molecular classification of head and neck squamous cell carcinomas using patterns of gene expression. *Cancer Cell.* 2004; 5: 489-500. DOI: 10.1016/S1535-6108 (04) 00112-6
- [5] Walter V, Yin X, Wilkerson MD, Cabanski CR, Zhao N, Du Y, Ang MK, Hayward MC, Salazar AH, Hoadley KA, Fritchie K, Sailey CJ, Weissler MC, Shockley WW, Zanation AM, Hackman T, Thorne LB, Funkhouser WD, Muldrew KL, Olshan AF, Randell SH, Wright FA, Shores CG, Hayes DN. Molecular subtypes in head and neck cancer exhibit distinct patterns of chromosomal gain and loss of canonical cancer genes. *Plos One.* 2013; 8(2): e56823. DOI:10.1371/journal.pone.0056823
- [6] Keck MK, Zuo Z, Khattri A, Stricker TP, Brown CD, Imanguli M, Rieke D, Endhardt K, Fang P, Bragelmann J, DeBoer R, El-Dinali M, Aktolga S, Lei Z, Tan P, Rozen SG, Salgia R, Weichselbaum RR, Lingen MW, Story MD, Ang KK, Cohen EEW, White PK, Vokes EE, Seiwert TY. Integrative analysis of head and neck cancer identifies two biologically distinct HPV and three non-HPV subtypes. *Clin. Cancer Res.* 2015; 21: 870-881. DOI: 10.1158/1078-0432.CCR-14-2481
- [7] De Cecco L, Nicolau M, Giannoccaro M, Daidone MG, Bossi P, Locati L, Licitra L, Canevari S. Head, and neck cancer subtypes with biological and clinical relevance: meta-analysis of gene- expression data. *Oncotarget.* 2015; 6: 9627-9642. DOI: 10.18632/oncotarget.3301
- [8] Canning M, Guo G, Yu M, Myint C, Groves MW, Byrd JK, Cui Y. Heterogeneity of the head and neck squamous cell carcinoma immune landscape and its impact on immunotherapy. *Front Cell Dev Biol.* 2019; 7:52. DOI: 10.3389/fcell.2019.00052
- [9] Brierley JD, Gospodarowicz MK, Wittekind C. TNM Classification of malignant tumors. 8th ed. UICC: Wiley; 2017. 272 p.
- [10] Westra WH, Lewis JS. Update from the 4th edition of the World Health Organization classification of head and neck tumours: Oropharynx. *Head Neck Pathol.* 2017; 11 (1): 41-47. DOI: 10.1007/s12105-017-0793-2
- [11] Barnes L, Eveson JW, Reichart P, Sidransky D. World Health Organization Classification of Tumours. 9th ed. WHO: IARC Press; 2005. 422 p.
- [12] Thompson L. Head and neck pathology. *Foundations in Diagnostic Pathology Series*: Churchill Livingstone, Elsevier, 2006. 640 p.

- [13] Cimpean AM, Balica AR, Doros CI, Balica NC, Gaje PN, Popovici AR, Raica M. Epidermal growth factor receptor (EGFR) and keratin 5 (K5): versatile keyplayers defining prognostic and therapeutic sub-classes of head and neck squamous cell carcinomas. *Cancer Genomics and Proteomics*. 2016; 13 (1): 75-81
- [14] Boia S, Boia ER, Ceausu AR, Balica NC, Mederle OA. HPV 18 associated E-cadherin expression in head and neck squamous cell carcinoma. *Rev Chim*. 2018; 69 (10): 2638-2641. DOI: 10.37358/RC.18.10.6596
- [15] El-Naggar AK, Chan J, Grandis J, Takata T, Slootweg P. WHO classification of head and neck tumours. 4th ed. WHO: IARC Press; 2017. 400 p.
- [16] Broglie MA, Dulguerov P, Henke G, Siano M, Putora PM, Simon C, Zwahlen D, Huber GF, Ballerini G, Beffa L, Giger R, Rothschild S, Negri SV, Elicin O. A review of controversial issues in the management of head and neck cancer: a Swiss multidisciplinary and multi-institutional patterns of care study -part 4 (biomarkers). *Front Oncol*. 2019; 9:1128-1133. DOI: 10.3389/fonc.2019.01128
- [17] Grimm M. Prognostic value of clinicopathological parameters and outcome in 484 patients with oral squamous cell carcinoma: microvascular invasion (V+) is an independent prognostic factor for OSCC. *Clin Transl Oncol*. 2012; 14: 870-880. DOI: 10.1007/s12094-012-0867-2
- [18] Coelho BA, Peterle GT, Santos M, Agostini LP, Maia LL, Stur E, Silva CVM, Mendes SO, Almanca CCJ, Freitas FV, Borcoi AR, Archanjo AB, Mercante AMC, Nunes FD, Carvalho MB, Tajara EH, Louro ID, Conforti-Silva AMA. Keratins 17 and 19 expression as prognostic markers in oral squamous cell carcinoma. *Genet Mol Res*. 2015; 14(4): 15123-15132. DOI: 10.4238/2015.November.24.21
- [19] Tang KD, Kenny L, Perry C, Frazer I, Punyadeera C. The overexpression of salivary cytokeratins as potential diagnostic biomarkers in head and neck squamous cell carcinomas. *Oncotarget*. 2017; 8(42): 72272-72280. DOI: 10.18632/oncotarget.19731
- [20] Dahiya K, Dhankhar R. Updated overview of current biomarkers in head and neck carcinoma. *World J Methodol*. 2016; 6: 77-86. DOI: 10.5662/wjmv6.i1.77
- [21] Vasca V, Vasca E, Freiman P, Marian D, Luce A, Mesolella M, Caraglia M, Ricciardiello F, Duminica T. Keratin 5 expression in squamocellular carcinoma of the head and neck. *Oncol Lett*. 2014; 8 (6): 2501-2504. DOI: 10.3892/ol.2014.2591
- [22] Savagner P. The epithelial-mesenchymal transition (EMT) phenomenon. *Annals of Oncology*. 2010; 21 (7): 89-92. DOI: 10.1093/annonc/mdq292
- [23] Gaiser MR, Hirsch D, Gaiser T. Loss of epithelial cell adhesion molecule (EpCAM) in infiltrative basal cell carcinoma. *Int J Clin Exp. Pathol*. 2018; 11 (1): 406-412. Published 2018 Jan 1.
- [24] Sequeira I, Neves JF, Carrero D, Peng Q, Palasz N, Liakath-Ali K, Lord GM, Morgan PR, Lombardi G, Watt FM. Immunomodulatory role of keratin 76 in oral and gastric cancer. *Nat. Commun*. 2018; 9: 3437. DOI: 10.1038/s41467-018-05872
- [25] Srivastava SS, Alam H, Patil SJ, Shrinivasan R, Raikundalia S, Chaudhari PR, Vaidya MM. Keratin 5/14 mediated cell differentiation and transformation are regulated by TAp63 and Notch-1 in oral squamous cell carcinoma-derived cells. *Oncol*

Rep 2018; 39: 2393-2401. DOI: 10.3892/or.2018.6298

[26] Litvinov SV, Balzar M, Winter MJ, Bakker HA, Briaire-de Bruijn IH, Prins F, Fleuren GJ, Warnaar SO. Epithelial cell adhesion molecule (Ep-CAM) modulates cell-cell interactions mediated by classic cadherins. *J Cell Biol.* 1997; 139: 1337-1348. DOI: 10.1083/jcb. 139.5.1337

[27] Chaw SY, Majeed AJ, Chan A, Stein S, Farah CS. Epithelial to mesenchymal transition (EMT) biomarkers- E-cadherin, beta-catenin, APC, and vimentin – in oral squamous cell carcinogenesis and transformation. *Oral Oncol.* 2012 ; 48 (10) : 997-1006. DOI : 10.1016/j.oraloncology.2012.05.011

[28] Dong Y, Zheng Y, Wang C, Ding X, Du Y, Liu L, Zhang W, Zhong Y, Wu Y, Song X. MiR-876-5p modulates head and neck squamous cell carcinoma metastasis and invasion by targeting vimentin. *Cancer Cell Int.* 2018; 18: 121. DOI: 10.1186/s12935-018-0619-7

[29] Liu PF, Kang BH, Wu YM, Sun JH, Yen LM, Fu TY, Lin YC, Liou HH, Lin YS, Sie HC, Hsieh IC, Tseng YK, Shu CW, Hsieh DY, Ger LP. Vimentin is a potential prognostic factor for tongue squamous cell carcinoma among five epithelial-mesenchymal transition related proteins. *Plos One.* 2017; 12(6): e0178581. DOI: 10.1371/ journal. pone. 0178581

[30] Liu S, Liu L, Ye W, Ye D, Wang T, Guo W, Liao Y, Xu D, Song H, Zhang L, Zhu H, Deng J, Zhang Z. High vimentin expression associated with lymph node metastasis and predicated a poor prognosis in oral squamous cell carcinoma. *Sci Rep.* 2016; 6: 38834. DOI: 10.1038/srep38834

[31] Bayo A, Jou A, Stenzinger A, Shao C, Gross M, Jensen A, Grabe N, Mende CH, Rados PV, Debus J, Weichert W, Plinkert PK, Lichter P,

Freier K, Hess J. Loss of SOX2 expression induces cell motility via vimentin up-regulation and is an unfavorable risk factor for survival of head and neck squamous cell carcinoma. *Mol Oncol.* 2015; 9(8): 1704-1719. DOI: 10.1016/j.molonc.2015.05.006

[32] Prasad B, Kashyap B, Babu GS, Kumar GR, Manyam R. Expression of podoplanin in different grades of oral squamous cell carcinoma. *Ann Med Health Sci Res.* 2015; 5(4): 299-304. DOI: 10.4103/2141-9248.160181

[33] Deepa AG, Bindu JN, Varun BR. Podoplanin expression in oral potentially malignant disorders and oral squamous cell carcinoma. *Journal of Clinical and Experimental Dentistry.* 2017; 9(12): e 1418-e 1424. DOI: 10.4317/jced.54213

[34] Li YY, Zhou CX, Gao Y. Podoplanin promotes the invasion of oral squamous cell carcinoma in coordination with MT1-MMP and Rho GTPases. *Am J Cancer Res.* 2015; 5(2): 514-529

[35] Voelker HU, Hintermer I, Strehl A, Scheich M. Prognostic potential of the expression of podoplanin (D2-40) within cells of squamous cell carcinoma of the larynx and hypopharynx. *World J Oncol.* 2020; 11(2): 65-71. DOI: 10.14740/wjon1259

[36] Lee NY, Yu NY, Lee SH, Tsai HJ, Wu CC, Cheng JC, Chen PD, Wang RY, Tseng CP. Podoplanin promotes cancer-associated thrombosis and contributes to unfavorable overall survival in an ectopic xenograft mouse model of oral cancer. *Biomed J.* 2020; 43(2): 146-162. DOI: 10.1016/j.bj.2019.07.001

[37] Wu D, Prives C. Relevance of the p53-MDM 2 axis to aging. *Cell Death Differ.* 2018; 25:169-179. DOI: 1038/cdd.2017.187

[38] Hashmi AA, Hussain ZF, Hashmi SK, Irfan M, Khan EY,

- Faridi N, Khan A, Edhi MM. Immunohistochemical over expression of p53 in head and neck squamous cell carcinoma: clinical and prognostic significance. *BMC Res Notes* 2018; 11: 433. DOI: 10.1186/s13104-018-3547-7
- [39] Boia ER. Clinical-pathological and historical features of latero-cervical lymphadenopathy [thesis]. Marioara Poenaru: Victor Babes University of Medicine and Pharmacy; 2014.
- [40] Castellanos MR, Pan Q. Novel p53 therapies for head and neck cancer. *World J Otorhinolaryngol Head Neck Surg.* 2016; 2(2): 68-75. DOI: 10.1016/j.wjorl.2016.05.005
- [41] Zhou G, Liu Z, Myers JN. TP53 mutations in head and neck squamous cell carcinoma and their impact on disease progression and treatment response. *J Cell Biochem.* 2016; 117(12): 2682-2692. DOI: 10.1002/jcb.25592
- [42] Prya SR, D'Cruz AK, Pai PS. Cut margins and disease control in oral cancers. *J Cancer Res Ther.* 2012; 8(1): 74-79. DOI: 10.4103/0973-1482.95178
- [43] Yang XH, Ding L, Fu Y, Chen S, Zhang L, Zhang XX, Huang XF, Lu ZY, Ni YH, Hu QG. p53 positive expression in dysplastic surgical margins is a predictor of tumor recurrence in patients with early oral squamous cell carcinoma. *Cancer Manag Res* 2019; 11: 1465-1472. DOI: 10.2147/CMAR.S192500
- [44] Shah AK. Postoperative pathologic assessment of surgical margins in oral cancer: a contemporary review. *J Oral Maxillofac Pathol.* 2018; 22(1): 78-85. DOI: 10.4103/jomfp.JOMFP_185_16
- [45] Taneja K, Gupta S, Chauhan AK, Kalra R, Arora A, Arora S, Sen R. Expression of p53 and bcl2 in squamous cell carcinoma of head and neck. *Archives of Clinical and Experimental Surgery.* 2016; 5: 160-168. DOI: 10.5455/aces.20151006071751
- [46] Gioacchini FM, Ciufelli MA, Rubini C, Magliulo G, Re M. Prognostic value of Bcl2 expression in squamous cell carcinoma of the larynx: a systematic review. *The International Journal of Biological Markers.* 2018; 30: 155-160. DOI: 10.5301/jbm.5000116
- [47] Li S, Li J, Hu T, Zhang C, Lv X, He S, Yan H, Tan Y, Wen M, Lei M, Zuo J. Bcl2 overexpression contributes to laryngeal carcinoma cell survival by forming a complex with Hsp90beta. *Oncology Reports.* 2016; 37: 849-856. DOI: 10.3892/or.2016.5295
- [48] Lu W, Feng L, Zhang Y, Ma Y, Li P, Wang Y, Du Y, Chen X, Wu S, Zhao G, Lou W. miR-15a induces cell apoptosis by targeting Bcl2L2 and Bcl2 in HPV positive hypopharyngeal squamous cell carcinoma. *Oncol. Rep.* 2016; 36(4): 2169-2176. DOI: 10.3892/or.2016.5049
- [49] Ow TJ, Fulcher CD, Thomas C, Broin PO, Lopez A, Reyna DE, Smith RV, Sarta C, Prystowsky MB, Schlecht NF, Schiff BA, Rosenblatt G, Belbin TJ, Harris TM, Childs GC, Kawachi N, Guha C, Gavathiotis E. Optimal targeting of Bcl-family proteins in head and neck squamous cell carcinoma requires inhibition of both Bcl-xL and MCL-1. *Oncotarget.* 2019; 10: 494-510. DOI: 10.18632/oncotarget.26563
- [50] Pavithra V, Kumari K, Haragannavar VC, Rao RS, Nambiar S, Augustine D, Sowmya SV. Possible role of Bcl2 expression in metastatic and non -metastatic oral squamous cell carcinoma. *J Clin Diagn Res.* 2017; 11(9): 51-54. DOI: 10.7860/JCDR/2017/29363.10601
- [51] Gao J, Ulekleiv CH, Halstensen TS. Epidermal growth factor (EGF) receptor ligand based molecular staging predicts prognosis in head and neck squamous cell carcinoma partly due to deregulated

- EGF- induced amphiregulin expression. *Journal of Experimental & Clinical Cancer Research*. 2016; 35:151. DOI: 10.1186/s13046-016-0422-z
- [52] Leblanc O, Vacher S, Lecerf C, Jeannot E, Klijanienko J, Berger F, Hoffmann C, Calugaru V, Badois N, Chilles A, Lesnik M, Krhili S, Bieche I, Le Tourneau C, Kamal M. Biomarkers of cetuximab resistance in patients with head and neck squamous cell carcinoma. *Cancer Biol Med*. 2020; 17(1): 208-217. DOI: 10.20892/j.issn.2095-3941.2019.0153
- [53] Kozakiewicz P, Szatkowska LG. Application of molecular targeted therapies in the treatment of head and neck squamous cell carcinoma. *Oncology Letters*. 2018; 15(5): 7497-7505. DOI: 10.3892/ol.2018.8300
- [54] Khademi B, Soleimanpour M, Ghaderi A, Mohammadianpanah M. Prognostic and predictive value of serum vascular endothelial growth factor (VEGF) in squamous cell carcinoma of the head and neck. *Oral Maxillofac Surg*. 2014; 18(2): 187-196. DOI: 10.1007/s10006-013-0402-9
- [55] Misawa Y, Misawa K, Kawasaki H, Imai A, Mochizuki D, Ishikawa R, Endo S, Mima M, Kanazawa T, Iwashita T, Mineta H. Evaluation of epigenetic inactivation of vascular endothelial growth factor receptors in head and neck squamous cell carcinoma. *Tumor Biology*. 2017; 7:1-10. DOI: 10.1177/1010428317711657
- [56] Lin LH, Lin JS, Yang CC, Cheng HW, Chang KW, Liu CJ. Overexpression of platelet-derived growth factor and its receptor are correlated with oral tumorigenesis and poor prognosis in oral squamous cell carcinoma. *Int J Mol Sci*. 2020; 21(7): 2360. DOI: 10.3390/ijms21072360
- [57] Watts TL, Cui R, Szaniszló P, Resto AV, Powell DW, Pinchuk I, PDGF-AA mediates mesenchymal stromal cell chemotaxis to the head and neck squamous cell carcinoma tumor microenvironment. *J Transl Med*. 2016; 14: 337. DOI: 10.1186/s12967-016-1091-6
- [58] Dudas J, Dietl W, Romani A, Reinold S, Glueckert R, Fischer AS, Deiacó D, Chacko LJ, Tuertscher R, Scharfingher VH, Riechelmann H. Nerve growth factor (NGF) receptor survival axis in head and neck squamous cell carcinoma. *Int J Mol Sci*. 2018; 19(6): 1771. DOI : 10.3390/ijms19061771
- [59] Pang X, Tang YL, Liang XH. Transforming growth factor- beta signaling in head and neck squamous cell carcinoma: insights into cellular responses. *Oncol Lett*. 2018; 16(4): 4799-4806. DOI: 10.3892/ol.2018.9319
- [60] Wang HC, Chan LP, Cho SF. Targeting the immune microenvironment in the treatment of head and neck squamous cell carcinoma. *Front Oncol*. 2019; 9: 1084. DOI: 10.3389/fonc.2019.01084
- [61] Gaje PN, Ceausu AR, Jitariu A, Stratul SI, Rusu LC, Popovici AR, Raica M. Mast cells: key players in the shadow in oral inflammation and in squamous cell carcinoma of the oral cavity. *Bio Med Research International*. 2016; DOI: 10.1155.2016/9235080
- [62] Peltanova B, Raudenska M, Masarik M. Effect of tumor microenvironment on pathogenesis of the head and neck squamous cell carcinoma: a systematic review. *Mol Cancer*. 2010; 18: 63. DOI: 10.1186/s12943-019-0983-5
- [63] Balica NC, Ceausu AR, Gaje PN, Doros C, Poenaru M. Microvessel and mast cell densities in malignant laryngeal neoplasm. *Archives of Biological Sciences*. 2014. 66(3): 1163-1169. DOI: 10.2298/ABS1403163B
- [64] Belgaumi UI, Patil S, Baad R, Vibhute N, Kadashetti V, Sushma B,

Kamate W. A study of association of mast cell count in different grades of oral squamous cell carcinoma. *Ann Med Health Sci Res.* 2017; 7:102-105.

[65] Szafarowski T, Sierdzinski J, Szczepanski MJ, Whiteside TL, Ludwig N, Krzeski A. Microvessel density in head and neck squamous cell carcinoma. *Eur Arch Otorhinolaryngol.* 2018; 275 (7): 1845-1851. DOI: 10.1007/s00405-018-4996-2

[66] Laishram D, Rao K, Devi HSU, Priya NS, Smitha T, Sheethal HS. Mast cells and angiogenesis in malignant and premalignant oral lesions: an immunohistochemical study. *J Oral Maxillofac Pathol.* 2017; 21 (2): 229-238. DOI: 10.4103/jomfp.JOMFP_111_15

[67] Evans M, Baddour HM, Magliocca KR, Muller S, Nannapaneni S, Chen AY, Kim S, Chen Z, Shin DM, Wang AY, Saba NF, Chen ZG. Prognostic implications of peritumoral vasculature in head and neck cancer. *Cancer Medicine.* 2019; 8:147-154. DOI: 10.1002/cam4.1910

[68] Cirligeriu L, Cimpean AM, Raica M, Doros CI. Dual role of podoplanin in oral cancer development. *In vivo.* 2014; 28(3): 341-347

[69] Parmar P, Marwah N, Parshad S. Clinicopathological significance of tumor lymphatic vessel density in head and neck squamous cell carcinoma. *Indian Journal of Otolaryngology and head and neck surgery: official publication of the Association of Otolaryngologists of India.* 2018. 70(1): 102-110. DOI: 10.1007/s12070-017-1216-0