

We are IntechOpen, the world's leading publisher of Open Access books Built by scientists, for scientists

5,000

Open access books available

125,000

International authors and editors

140M

Downloads

Our authors are among the

154

Countries delivered to

TOP 1%

most cited scientists

12.2%

Contributors from top 500 universities



WEB OF SCIENCE™

Selection of our books indexed in the Book Citation Index
in Web of Science™ Core Collection (BKCI)

Interested in publishing with us?
Contact book.department@intechopen.com

Numbers displayed above are based on latest data collected.
For more information visit www.intechopen.com



Surgical Anatomy of the Temporal Bone

Gülray Açar and Aynur Emine Çiçekcibaşı

Abstract

Numerous neurological lesions and tumors of the paranasal sinuses and oral cavity may spread into the middle and posterior cranial fossae through the anatomical apertures. For the appropriate management of these pathologies, many extensive surgical approaches with a comprehensive overview of the anatomical landmarks are required from the maxillofacial surgery's point of view. The surgical significance lies in the fact that iatrogenic injury to the petrous segment of the temporal bone including the carotid artery, sigmoid sinus, and internal jugular vein, can lead to surgical morbidity and postoperative pseudoaneurysm, vasospasm, or carotid-cavernous fistula. To simplify understanding complex anatomy of the temporal bone, we aimed to review the surgical anatomy of the temporal bone focusing on the associations between the surface landmarks and inner structures. Also, breaking down an intricate bony structure into smaller parts by compartmental approach could ease a deep concentration and navigation. To identify the anatomic architecture of the temporal bone by using reference points, lines and compartments can be used to supplement anatomy knowledge of maxillofacial surgeons and may improve confidence by surgical trainees. Especially, this systematic method may provide an easier way to teach and learn surgical spatial structure of the petrous pyramid in clinical applications.

Keywords: maxillofacial surgery, segmentation, surface landmarks, surgical anatomy, temporal bone

1. Introduction

The temporal bone is a dense complex bone that constitutes the lower lateral aspect of the skull and has complex anatomy because of the three-dimensional relationships between neurovascular structures. The petrous portion of the temporal bone has a role as the partition between the middle and posterior cranial fossae. It articulates with the occipital bone (occipitomastoid suture) posteriorly, the parietal bone (squamous suture) superiorly, the sphenoid bone (sphenosquamosal suture) and the zygomatic bone (arcus zygomaticus) anteriorly, and the mandible (temporomandibular joint) inferiorly [1, 2]. It contains multiple intrinsic channels, along with the internal carotid artery (ICA), cranial nerves, and sigmoid sinus (SS), all within intricate spatial architecture. Owing to a complex web of foramina and neurovascular structures of the temporal bone, the lateral skull base is a technically difficult region for surgeons. Because the middle and inner ear structures of hearing and equilibrium are preserved in the temporal bone,

a surgical dissection of it requires thorough understanding of three-dimensional (3D) map of the topographic anatomy to avoid iatrogenic risks. The relationship between the surface landmarks and expected internal structures and the segmentation of the temporal structures by using key surgical lines and spaces allow a better understanding of its anatomic architecture. Each temporal bone consists of five distinct osseous segments including the squamous, tympanic, petrous, mastoid, and styloid portions [3, 4].

2. External anatomy of the temporal portions

2.1 The squamous portion

The anterosuperior part of the temporal bone is a large flattened scale-like plate that forms the lateral boundary of the middle cranial fossa. It has three borders and two surfaces [1].

2.1.1 Borders and surfaces of the squamous portion

Superiorly, it overlaps the sculpted squamous margin of the middle third of the parietal bone and constructs the squamosal suture. Posteriorly, it forms the occipitomastoid suture with the squamous part of the occipital bone. Also, there is an angle, parietal notch, between the squamous and mastoid portions of the temporal bone (**Figure 1**). Antero-inferiorly, its thick serrated margin takes part in pterion formation and articulates with the greater wing of the sphenoid bone to form the spheno-squamosal suture. Inferiorly, it fuses and forms the petro-squamous suture with the superior surface of the petrous portion by extending medially as tegmen tympany [5, 6].

External surface, the greater part of the temporal fossa, provides origin to the temporalis muscle and is limited below by the curved line, the temporal line, that lies from the supra-meatal crest to the mastoid cortex posteriorly. Below this line, just above and behind the external acoustic meatus (EAM), the supra-meatal triangle (Macewen's triangle) contains the supra-meatal spine, spine of Henle and the cribriform area (**Figure 1**). Also, the squamo-mastoid suture is located approximately 1 cm below the temporal line [5–7]. On this smooth surface, there is a sulcus for the middle temporal artery, which is the medial branch of the superficial temporal artery (STA). Antero-inferiorly, the zygomatic process projects by two roots: the upper border of the posterior root forms the supra-meatal crest and the lower border forms a laterally based projection, known as post-glenoid tubercle or process (PGP). Inferiorly, the concavity along the surface of the anterior root is called the glenoid fossa (GF), which is bounded by the articular eminence (ArE) anteriorly and the PGP posteriorly [5–7].

Internal surface is rough and concave in shape, and the anterior and posterior divisions of middle meningeal artery (MMA) run in a groove on this surface that defines the boundary of middle cranial fossa with impressions for the gyri of the temporal lobe. Inferiorly, it forms the petro-squamosal suture with the anterior surface of the petrous part [5, 6].

2.1.2 Surgical landmarks and ossification of the squamous portion

The Macewen's triangle, a surgical surface marking for the mastoid antrum (MA), is formed between the temporal line superiorly, the posterosuperior wall of the EAM antero-inferiorly, and the opening of the mastoid emissary vein or

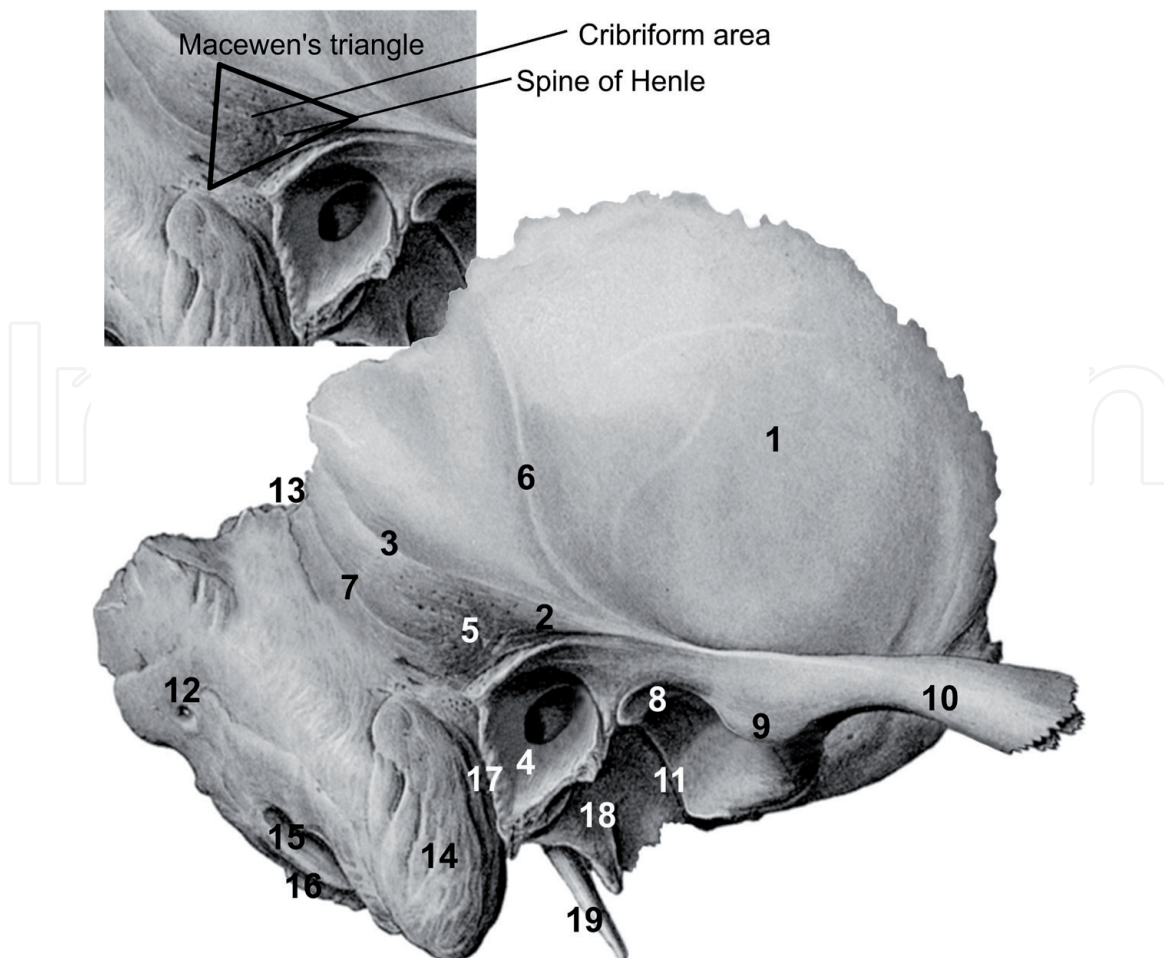


Figure 1.

The surface landmarks on the squamous portion: 1, temporal fossa; 2, supra-meatal crest; 3, temporal line; 4, external acoustic meatus; 5, supra-meatal triangle (Macewen's triangle); 6, middle temporal artery; 7, squamo-mastoid suture; 8, mandibular fossa (glenoid fossa); 9, articular eminence; 10, zygomatic process; 11, petrotympanic fissure (Glaserian fissure); 12, mastoid foramen; 13, parietal notch; 14, mastoid process; 15, mastoid notch (digastric fossa); 16, occipital sulcus; 17, tympano-mastoid suture; 18, vaginal process; 19, styloid process.

sinodural angle posteriorly (**Figure 1**). The temporal line corresponds to the tegmen tympani (TT), which is a bony plate below the middle cranial fossa dura and over the mastoid air cells. The mastoid cortex posterior to the spine of Henle is a guide to the lateral wall of the MA and located 15 mm deep to it in adults but in new born about 2 mm [5, 6, 8]. The cribriform area in Macewen's triangle is perforated by numerous small holes that serve as a passage for the vessels of the mucosa of the antrum. The dissection along the margins of this triangle is safer because the vital neurovascular structures are absent. Peris-Celda et al. reported that the temporal line is supratentorial and infratentorial in 93% and 7% of the cases, respectively [9]. During retro-auricular mastoidectomy, the MA may be exposed by drilling the cribriform area and provides a safer surgical approach to the tympanic cavity. The tympanic portion and the styloid process may show variations depending on the shape and the position of the spine of Henle. The MA is located in the same line of the spine of Henle at about 10 years; then the MA is enlarged and placed 1 cm behind it [6, 9].

The MMA lies underneath the pterion which is a common junction between the temporal, parietal, frontal, and sphenoid bones. The fracture of this weakest bony part may result in an epidural bleeding. Between the temporal muscle and fascia, the STA and the superficial temporal vein (STV) courses in close proximity with the zygomaticotemporal (ZTN) and the auriculotemporal (ATN) nerves, branches

of the trigeminal nerve (TN). Because of a vessel running superficial to the nerve (80% STA), the underlying nerve may be compressed and results in temporal migraine headache. Lee et al. reported that the intersection (compression) point among the ATN, STA, and STV was at an average of 40 mm superior and 10 mm anterior to the tragus, which is a significant surface landmark at the most anterosuperior point of the EAM. The applications of surgical decompression of the ATN in these compression points improve migraine headache [10].

The anterior articular part of the GF is formed by a gentle sloped area of the squamous portion, which facilitates the movement of the temporomandibular joint (TMJ) during wide mouth opening. At the lateral aspect of the ArE, a small bony ridge, articular tubercle (AT), serves as an attachment for the lateral collateral ligament. The PGP inhibits backward displacement of mandibular head and participates to the superior wall of the EAM [8]. The posterior nonarticular part of the GP is formed by the tympanic portion and the squamo-tympanic suture intervenes between them. The inferior edge of the TT (petrous part) divides this suture into two: a petro-squamosal fissure in front and a petrotympanic fissure (Glaserian fissure) behind (**Figure 1**). The chorda tympani nerve, a branch of the facial nerve, exits the temporal bone through the Glaserian fissure and joins the lingual nerve as the parasympathetic input to start the submandibular and sublingual gland secretions [2, 4, 5].

The articulation between the GF and the condyle of the mandible is called TMJ, which plays an essential role in speech, respiration, swallowing, and specially mastication. Because the TMJ is in close proximity with the MMA, some surgical landmarks around the TMJ and foramen spinosum (FS) play a critical role in surgical approaches. Miller et al. reported that researchers measured the distances from the zygomatic root (first projection of the zygomatic arch = PGP) to some surgical landmarks such as the arcuate eminence (AE), the head of the malleus (HM) under the TT, and the FS to identify the location of the internal auditory meatus (IAM) or the superior semicircular canal (SSC). Also, they described the superior petrosal triangle as a consistent triangle between the zygomatic root, the FR, and the HM to localize the bony tegmen over the tympanic cavity [11]. Baur et al. offered simply identifiable reference landmarks including the AE, the most lateral aspect of the Glaserian fissure and the FS and measured the distances between them to predict the location of the MMA [12]. According to these researchers, the internal landmarks including the HM and Bill's bar (the vertical crest in the fundus of the internal auditory canal) are in a single plane with the zygomatic root [11].

After the ArE forming the anterior limit of the GF, the anterior root continues in front as a bony ridge that forms the posterior boundary of the infratemporal fossa, which is a small triangular area transmitting the neurovascular structures between the pterygopalatine fossa and temporal fossa. Then, a serrated anterior end of the zygomatic process passes straight forward and articulates with the temporal process of the zygomatic bone and completes the zygomatic arch. The temporal fascia inserts to this arch and the temporal line superiorly and also the masseter muscle origins from the arch inferiorly. The lateral temporomandibular ligament attaches to the AT, and the GF is covered with an articular disc to construct the synovial TMJ with the condyle of the mandible [5–7].

Anteriorly, the small part of squamous portion takes part in the infratemporal fossa formation with the zygomatic bone and the greater wing of the sphenoid bone. Below the zygomatic bone, the branches of the first and second mandibular parts of the MA with veins and the pterygoid plexus of veins, the mandibular and lingual nerves pass through the infratemporal fossa. During the infratemporal fossa approaching for surgical removal of tumors localized in the orbit, the maxillary and sphenoid sinuses, the detailed anatomical knowledge of these neurovascular

structures is needed. Depending on the position of the infratemporal fossa below the floor of the middle cranial fossa and posterior to the maxilla, it is in close proximity with the parapharyngeal and masticator spaces. The parapharyngeal carotid artery enters the carotid canal (CC) behind the FS and foramen ovale. During transpterygoid infratemporal fossa approach, the positions of these surgical landmarks can be used to prevent ICA injury [13].

Ossification of the squamous portion starts intramembranously from one center around the zygomatic process at the 2nd month. At birth it fuses with the other membranous bone, tympanic portion. Normally, at birth the temporal bone consists of three parts; the petrous, squamous, and the tympanic [1].

2.2 The mastoid portion

The mastoid portion forms the pneumatized thick posterior part of the temporal bone. It fuses with the squamous portion antero-superiorly and the tympanic portion anteriorly and the petrous portion anteromedially. It has three borders and two surfaces [5, 6].

2.2.1 Borders and surfaces of the mastoid portion

Posteriorly, it articulates with the squamous part of the occipital bone between lateral angle and the jugular process and constructs the occipitomastoid suture. Inferiorly, the mastoid process extends as a rough and conical shaped projection and filled with mastoid cells variable in shape and size. Anteriorly, it associates with the tympanic portions of the temporal bone to form the tympano-mastoid suture, and the inferior auricular branch of the vagus nerve (Arnold's nerve) exits through this suture [5, 14, 15].

Near the squamo-mastoid suture, the occipital belly of occipito-frontalis and auricularis posterior muscles attach on the external surface that is perforated by numerous small foramina. At the posterior border of the mastoid portion or the occipitomastoid suture, the largest one, mastoid foramen is located and transmits an emissary vein connecting the SS with the posterior auricular vein and a branch of occipital artery to the dura mater (**Figure 1**). The mastoid process serves for the attachment of the sternocleidomastoid, splenius capitis, and longissimus capitis muscles and shows variations in shape and size with respect to sex. The posterior belly of the digastric muscle is originated from the mastoid notch (digastric fossa), which is a depression on the inferomedial margin of the mastoid process (**Figure 1**). More medial to the notch lies a sulcus, the occipital sulcus, forming a groove for the occipital artery [4, 6].

The internal surface includes a well-defined and curved sigmoid sulcus lying along its junction with the posterior surface of petrous part and lodges the SS, partially the transverse sinus, which are separated from mastoid air cells by a thin plate of bone. The mastoid foramen transmitting the mastoid emissary vein may be open to this sulcus. The SS begins as the continuation of the transverse sinus and lies downward in a S-shaped groove and opens into the superior jugular bulb. There is a sinodural angle between the dura plates of the SS and middle and posterior cranial fossae [2, 5, 9, 16].

2.2.2 Surgical landmarks and ossification of the mastoid portion

The mastoid process shows three types of pneumatization patterns including pneumatic (full air cell), sclerotic (solid mass of bone), and mixed (air cells and bone marrow) types. Especially, in the anterosuperior part of the mastoid process,

there is an irregular cavity that is larger than other mastoid cells and called MA, which corresponds to the cribriform area. It is covered with the mucous membrane of the tympanic cavity and communicates anteriorly with the epitympanic recess of the middle ear via the aditus ad antrum. The tegmen antri, a roof of the MA, separates it from the middle cranial fossa. During embryonic period, the squamous and petrous portions fused each other and forms the petro-squamous suture. In adults, it forms a thin bony septum, the Körner's septum, by extending into the mastoid process [1, 4, 6, 9, 17]. Körner's septum divides the mastoid air cells in the mastoid process into a deep petrous part medially and a superficial squamous part laterally. The petro-squamosal sinus or the mastoid emissary vein may infrequently be observed along this septum. During mastoidectomy or transmastoid approaches, awareness of this crucial landmark and its variations is essential to avoid iatrogenic complications. The squamous part starts to develop at 8th week, whereas the petrous part develops later at 6th months during embryogenesis, and each part opens into the MA separately [1]. Also, the mastoid cells are separated by bony plates from the adjacent structures such as the posterior wall of the EAM anteriorly, tegmen plate superiorly, SS posteriorly, digastric ridge inferiorly, and the lateral semicircular canal (LSC) or solid triangle medially. The solid triangle is a compact bony angle between three SCs. During the mastoidectomy, all the air cells around this septum and adjacent bony structures should be removed without damaging the bony plates. To avoid iatrogenic injury to the adjacent structures, the MA must be open superiorly toward TT. The tympano-mastoid suture at the posterior wall of the MA is surface marking of the course of the vertical portion of the facial nerve (FN) [9, 16, 18]. Peris-Celda et al. reported that the parietal notch corresponds to the posterior petrosal point and the SS (the transverse-SS junction) in 66 and 34% of the cases, respectively [9].

Ossification of the mastoid portion is endochondral which is identical to the petrous and styloid portions. At birth, the mastoid process is absent, and the MA is invisible and covered by a thin bony plate that is extension of the squamous portion. At the first year, the mastoid process becomes prominent and the petro-squamous suture arises. The antrum can be seen obviously at about the fifth year. During puberty, the thickness of the process increases, and it becomes pneumatic that is lined by mucous membrane. In adults, the mastoid process may not contain air cells in 20% cases [1, 2, 17].

2.3 The tympanic portion

An annular shaped part of the temporal bone forms the tympano-mastoid suture posteriorly and the squamo-tympanic suture superiorly (**Figure 1**). Medially, it fuses with the petrous portion, whereas a free lateral part of it constructs the major part of the EAM and also serves an attachment for the cartilaginous part of the external auditory canal (EAC). Its inferior margin is free, and it has two parts on the lateral surface; posterosuperior part forms the EAM, and anteroinferior part limits the mandibular fossa posteriorly [5, 19].

2.3.1 Borders and surfaces of the tympanic portion

Medially, just above the GF, this suture is subdivided by a thin tegmen part of the petrous portion into two: the petrotympanic fissure posteriorly and the petro-squamosal fissure anteriorly. Lateral part of this upper margin fuses with the back of the PGP to form the nonarticular part of the GF. Inferiorly, the lateral part of the margin gives an attachment for the deep part of the parotid fascia and forms the vaginal process, which wraps the root of the styloid process laterally [2, 4].

Laterally, external surface is bounded by the cartilaginous part of the EAC which extends from the auricle to the tympanic membrane. The EAC is an S-shaped tube, about 2.5 cm in long, that is composed of the lateral third cartilaginous part and the medial two-thirds osseous part [14, 15, 18]. The tympanic part constructs the anterior wall and floor and the lower part of posterior wall of the EAM, whereas the squamous part forms the superior and upper part of the posterior wall of it (**Figure 1**). The tympanic part grows from the tympanic ring, which is open U-shaped possessing two edge anterior and posterior. The anterior edge forms the tympano-squamous fissure within the anterosuperior part of the EAM and the petrotympanic fissure within the middle ear, whereas the posterior edge forms the tympano-mastoid fissure within the posteroinferior part of the EAM near the stylomastoid foramen (SMF) [2, 4, 19].

The internal surface fuses with the petrous portion and forms the tympanic sulcus for the lodgement of the tympanic membrane, which forms an angle about 55° with the floor of the EAM and separates the external and middle ear (ME). At the upper part, the tympanic sulcus does not fuse each other by forming the greater and lesser tympanic spines and a notch called Rivinus between them. This notch is closed by the pars flaccida of the tympanic membrane. The notch of Rivinus corresponds to the junction between the squamous and tympanic portions [1, 4, 14, 20].

2.3.2 Surgical landmarks and ossification of the tympanic portion

Ossification starts from the four centers around the tympanic ring at the end of the embryonic period (8th week) via intramembranous ossification of the EAM. The tympanic ring at first is nearly straight and then turns into horseshoe shape (annular) and then, the open arms extending upwards terminate in a notch for the location of the tympanic membrane between them. After birth, the upper segment of the tympanic bone grows rapidly but because of the gradual development of the lower segment, a deep notch (tympanic foramen) is left in the anterior part of the bony EAM. Normally, the tympanic ring fuses until the age of 5 year but a dehiscence may persist (range 4.6–22.7%) at the anteroinferior aspect of the EAM, called foramen of Huschke (foramen tympanicum). This fusion defect is not a true foramen, but it may cause a connection between the EAM and the posteromedial part of the TMJ and results in TMJ herniation and the secretion of the parotid gland and also the dissemination of tumor and infections into the EAM [1, 14, 19, 20]. Anteriorly, the EAM may communicate with the retromandibular part of the parotid gland via the fissures of Santorini within the anterior cartilage. Peris-Celda et al. reported that the SSC dehiscence can be observed approximately 1.5 cm posterior to the middle point of the EAM in 86% of the cases [9]. In newborn, the tympanic membrane is infiltrated with air and the tympanic ring forms a bony plate, which may cause the development of a cleft, the auricular fissure, posteriorly and a cleft, the tympano-squamous fissure, anteriorly [19, 20].

2.4 The petrous portion

The petrous portion is a dense pyramid-shaped bone and composed of the labyrinth of the internal ear, the tympanic cavity of the middle ear and a bony part of the auditory Eustachian tube (ET), and canals for the passage of the ICA and the FN. It is ossified from the otic capsule by forming a 45° angle with the horizontal axis. It has a base, an apex, and three surfaces and three borders [3, 4, 21].

2.4.1 Borders of the petrous portion

Superiorly, the petrous ridge is the longest border and a boundary between the posterior part of the middle cranial fossa (the anterior surface of the petrous part) and the anterior part of the posterior cranial fossa (the posterior surface of the petrous part). It contains a groove that lodges the superior petrosal sinus (SPS) and the lateral margin of tentorium cerebelli attaches to this margin (**Figure 2**). Posteriorly, the medial part of the posterior margin articulates with the basilar part of occipital bone along the petro-clival fissure and forms a groove that lodges the inferior petrosal sinus (IPS) that extends from the posteroinferior part of the cavernous sinus to the internal jugular vein (IJV). The lateral part of the posterior margin is free and limits the jugular foramen (JF) supero-laterally and has a triangular notch for the lodgement of the inferior ganglion of the glossopharyngeal

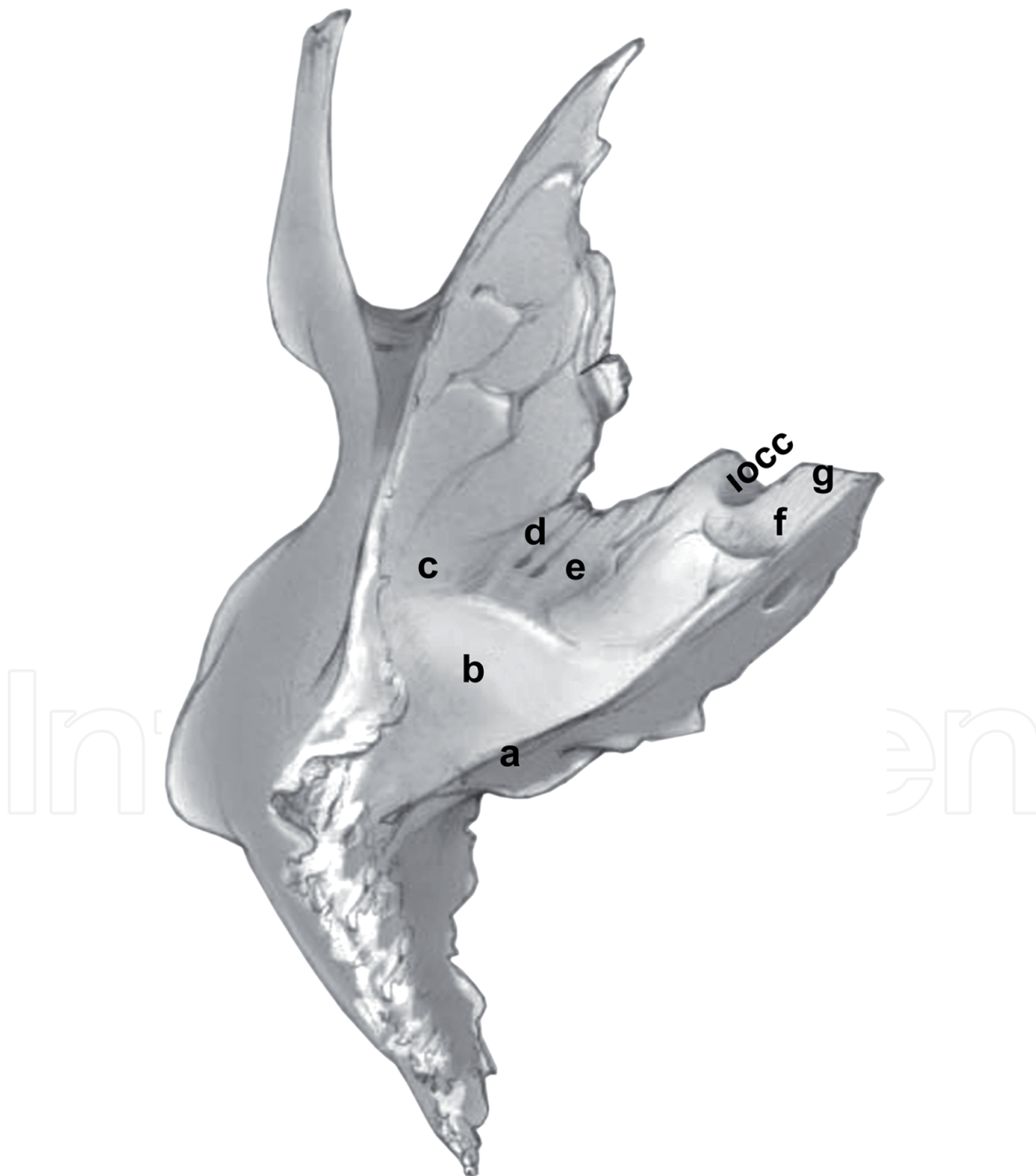


Figure 2.
The surface landmarks on the anterior surface of the petrous portion: a, petrous ridge (sulcus of the superior petrosal sinus); b, arcuate eminence; c, tegmen tympani; d, sulcus of the lesser petrosal nerve; e, sulcus of the greater petrosal nerve; f, trigeminal impression; g, petrous apex; iocc, internal opening of carotid canal.

nerve (Jacobson's nerve = GPN). Anterolateral border is formed by the ET extending from the anteroinferior wall of the tympanic cavity to the nasopharynx [3, 4, 9].

The base is integrated with the inner surface of the squamous and mastoid portions, whereas the apex forms the posterolateral margin of the foramen lacerum (FL) and faces the Meckel's cave medially. There is a fibrocartilage connection between the apex and the clivus. The internal opening of the carotid canal (IOCC) is observed at the apex for the intracranial entry of the ICA. At the anterolateral part of the FL, the petro-sphenoid ligament connects the tip of the apex to the dorsum sellae of the sphenoid and the abducent nerve lies below this ligament and enters the cavernous sinus adjoining the ICA [1, 7, 16].

2.4.2 Surgical landmarks on the anterior surface of the petrous portion

Anterior surface describes a triangular area, between the linear lines as follows: a horizontal line that starts from the preauricular burrhole in front of the tragus to petrous apex at the FL and passes through the FS anteriorly, the petrous ridge posteriorly and the petro-squamous suture, which lies along the junction of the petrous pyramid with the vertical part of the squamous portion laterally [3, 16, 22]. It consists of some marking landmarks (**Figure 2**).

- a. The anteromedial two-third of the musculotubal canal is cartilaginous, whereas the posterolateral third is bony. The bony part consists of two small canals that are separated by a thin bony septum at the lateral part the petrous portion. The tensor tympani muscle passes through the superior semicanal, whereas the inferior semicanal forms the bony portion of the ET. The tensor tympani muscle originates from the greater wing of the sphenoid and inserts into the upper part of the medial surface of the handle of malleus after making a bend around the processus cochleariformis in the tympanic cavity [4, 6]. The ET lies between the tympanic orifice and the isthmus, which has the smallest diameter at the intersection point of the petrous and squamous parts of the temporal bone just behind the sphenoid spine. Brown et al. reported that the ET is subdivided by genu within the membranocartilaginous part into two portions; posterior horizontal ET between the genu and the anterior attachment of the tympanic membrane ridge, whereas the anterior vertical ET lies from the genu to the nasopharyngeal orifice and opens into the nasopharynx. During endoscopic eustachian tube obliteration, the ET is cannulated to treat refractory CSF rhinorrhea by identifying three anatomic parameters: the ET length, isthmus diameter, and genu location. According to a new surgical classification, the cartilaginous portion of the ET is divided into the petrous, lacerum, pterygoid, and nasopharyngeal parts. The bony part attaches to the ET sulcus or sulcus tuba, which is contiguous to the FL medially. The FL is located in the incomplete confluence of the union of the body and the lingular process of the greater sphenoid wing anteriorly, the clivus of the occipital bone medially and the petrous apex posteriorly and covered with the fibrocartilaginous tissue that separates the ET from the ICA [23].
- b. The internal opening of the CC is located near the FL for the passage of the ICA, which is freed at the petrous apex into the cavernous sinus (**Figure 2**). It is localized medial to the ET, below the greater superficial petrosal nerve (GSPN), a branch of the FN and the trigeminal ganglion [1, 3, 4]. The petrous segment of the ICA within the CC has four anatomic parts, called vertical, posterior genu, horizontal, and anterior genu. During endoscopic endonasal surgery, the junctional part of the ET at the sphenoid spine and FS is crucial landmark to identify and protect the petrous segment of the ICA [13]. The anatomical and

surgical relationships between the ET and the petrous segment of the ICA are as follows:

The first curve, posterior genu is located at the level of the bulging basal turn of the cochlea within the bend of the CC. Laterally, the bony part of the ET and the tendon of the tensor tympani muscle; posterolaterally, the promontory and posterosuperiorly, geniculate ganglion are paramount landmarks for the posterior genu of the ICA. The V3 lying anteromedially to the FS and the parapharyngeal segment of the ICA, which passes posteroinferiorly to the sphenoid spine, are critical landmarks. Posterolaterally, the petroclival fissure cartilage is an important landmark to separate the pharyngobasilar fascia from the anterior genu of ICA.

The second turn of the ICA, anterior genu, above the fibrous tissue of the FL is in close proximity to the lacerum segment of the cartilaginous ET laterally and continues as the paraclival ICA in the carotid groove. During the endoscopic approach, the Vidian artery and nerve (VN) are critical landmarks for the second curve of the ICA.

For safe manipulation of the horizontal part of the ICA, the GSPN can be used as surgical landmark. Above the anterolateral margin of the FL the union of the GSPN and the deep petrosal branch of the carotid neural plexus forms the VN which is located anteroinferiorly and lateral to the second turn of the ICA. Malignancies that involve the petrous apex or the carotid artery require the extended endoscopic endonasal approach (EEA). During this procedure, the medial and lateral optico-carotid recesses in the cavernous sinus and the vidian canal (VC) are vital surgical landmarks, which allow to identify the position of the ICA for safe surgical resection near the ICA [13].

- c. At the apex above the CC, a shallow fossa called trigeminal impression (**Figure 2**) is located for the lodgement of the sensory ganglion of the TN (semilunar ganglion or Gasser's ganglion) that is covered by a pouch-shaped dura mater called Meckel's cave [3]. Vascular compression and arachnoid adherence of the TN branches result in trigeminal neuralgia. During endoscopic vascular decompression and Meckel's cave approaches, the VC, the bone between V2 and the VC and the pneumatization of the sphenoid sinus form a safe route to access and to decompress Gasser's ganglion with branches, the cranial nerves (III, IV, VI), and the petrous ICA [13, 23].
- d. Behind the trigeminal impression, the roof of the IAM is indicated as a shallow fossa, then it continues with the AE, which is a surgical landmark for the middle fossa approach and located at the junction of the posterior third and the anterior two-thirds of the petrous portion (**Figure 2**). It is a valuable guide to signify the SSC and the roof of the vestibule up to 93% of the temporal bones [19, 22].
- e. The TT is a thin bony layer covering all of the anterior surface (**Figure 2**). It forms the roof of the mucosal line including from behind to forward the MA, tympanic cavity and ET which are lined with mucosa. Also, its lateral edge turns downward to subdivide the squamo-tympanic fissure into two parts [1, 3].
- f. On the TT, a bony roof of the geniculate ganglion, there are two foramina, which continue as a small groove adjoining anteromedially; the medial one

starts from the hiatus of the facial canal and lodges the GSPN, a branch of the FN and the petrosal branch of the MMA, whereas the lateral one lodges the lesser superficial petrosal nerve, a branch of GPN (**Figure 2**) [3, 9, 16, 22].

Kaen et al. described the “VELPPHA” area indicating the posterior limit of the transpterygoid EEA. It is composed of the VC (V), the ET (E), the FL (L), the petroclival fissure (P), the pharyngobasilar fascia (PHA), and multiple cartilaginous fibers between them. The posterior opening of the VC, the posterior limit of surgical corridor in the transpterygoid approach, is located above the ET and below the petrous ICA. Behind the posterior margin of the medial pterygoid process, the superomedial border of the ET attaches to the cartilaginous fibers of the FL. The petroclival fissure is situated between the lateral border of the clivus (occipital bone) and the petrous part of the temporal bone and lodges the IPS. The horizontal segment of the petrous ICA turns upward at the medial border of the petrous apex to form the anterior genu of the ICA, and then it continues as the lacerum segment, second vertical segment of the ICA. So, the VC-ET junction is a safe and critical landmark for efficient localization of the lacerum segment of the ICA, as part of the transpterygoid extension of EEA [24].

Tayebi Meybodi et al. described the pterygoclival ligament as a thickened extension of the pharyngobasilar fascia from the pterygoid process to the anteromedial aspect of the lacerum segment of the ICA and reported that the course of the pterygoclival ligament consistently refers to the anteromedial aspect of the lacerum ICA. So, they suggested that the pterygoclival ligament can be used as a safe landmark in case of tumor invasion of the VN, and drilling along the medial aspect of this ligament is more reliable way compared with the VN to avoid the ICA injury during extended EEA. Also, they remarked that this ligament may localize in a venous compartment, which is in contact with the cavernous sinus superiorly and the pterygoid venous plexus posteroinferiorly [25].

2.4.3 Surgical landmarks on the posterior surface of the petrous portion

The posterior surface, anterior wall of the posterior cranial fossa, is encircled by a venous triangle that is formed by the grooves for SS posteriorly and SPS at the petrous ridge and IPS at the junction of the pars lateralis of the occipital bone and the temporal bone anteroinferiorly. The SS drains into the bulb of the IJV, which exists from the JF together with the cranial nerves (IX-XI) [1, 6, 9].

- a. The IAM is a short canal, about 1 cm long, and has a large orifice, which allows passage of the vestibulocochlear nerve below the FN, the superficial petrosal artery (a branch of the MMA) and the labyrinthine artery (branch of the basilar artery). The bottom (fundus) of the IAM is subdivided into unequal superior and inferior portions by a transverse falciform crest, and into the anterior and posterior portions by a vertical segment, Bill's bar, respectively (**Figure 3**) [2, 15]. The localization of the nerves within the IAM is determined by a triangular shaped Bill's bar as follows; posteriorly the superior and inferior vestibular nerves, anteroinferiorly the cochlear nerve, anterosuperiorly the FN and nervus intermedius pass through the foramina of the fundus (**Figure 3**) Mortazavi [1, 4, 6].
- b. The aqueductus vestibuli is a bony canal which contains the saccus and ductus endolymphaticus. Its opening is an oblique slit behind the IAM (**Figure 3**). The endolymphatic sac is located at the lateral part of the posterior surface medial to the posterior SSC [2, 18].

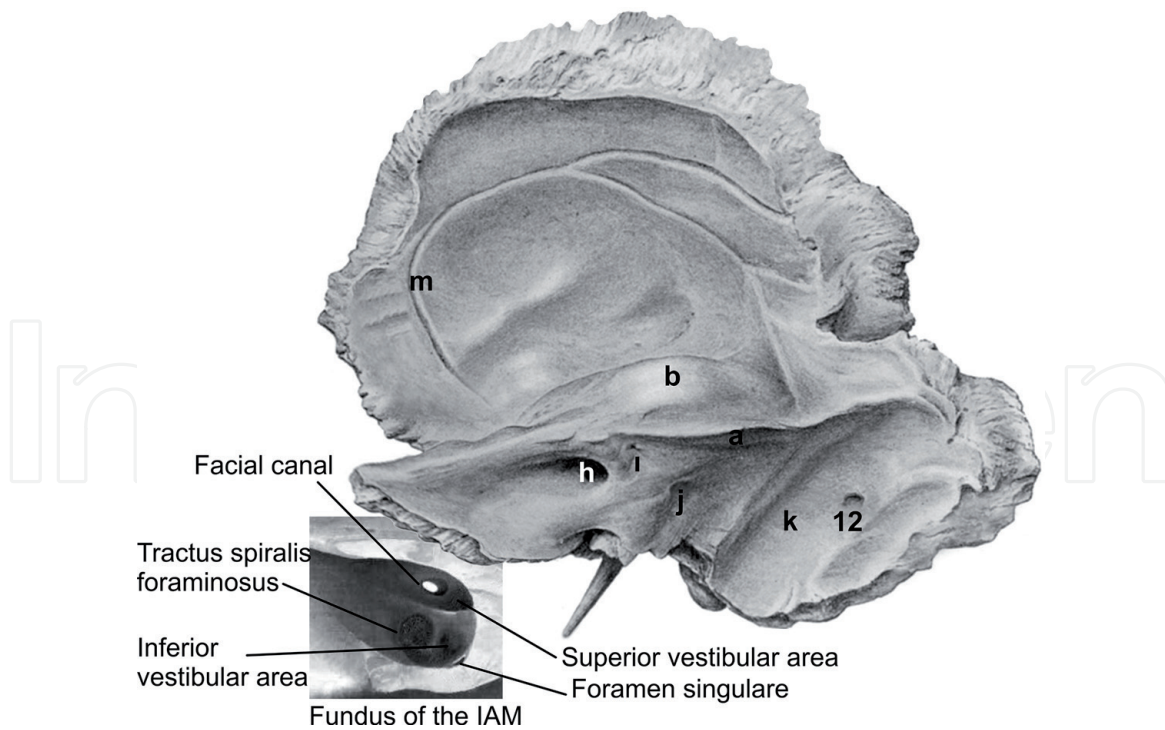


Figure 3.

The surface landmarks on the posterior surface of the petrous portion: a, petrous ridge; b, arcuate eminence; h, internal acoustic meatus; i, subarcuate fossa; j, aqueductus vestibuli; k, sigmoid sinus sulcus; m, sulcus of the middle meningeal artery; 12, mastoid foramen.

- c. The subarcuate fossa is an indistinct depression (large in new born) located behind the IAM (**Figure 3**) and transmits a small vein and the subarcuate artery, which is a branch of the meatal segment of the anterior inferior cerebellar artery [4, 5, 9, 14].

2.4.4 Surgical landmarks on the inferior surface of the petrous portion

The inferior surface articulates with the basilar part of occipital bone medially, and the greater wing of the sphenoid bone anteriorly and forms an irregular external surface of the base of the skull. Below the apex, there is a quadrilateral area that serves as an attachment for the levator veli palatini muscle. The lateral part of this area merges with the posterior margin of the greater wing of sphenoid to form the sulcus tuba in front of the cartilaginous portion of the auditory tube [4, 5, 21]. It presents some anatomical landmarks as follows:

1. The external opening of the CC, which shows an inverted L-shape course, forms the entrance for the ICA, which is surrounded by a plexus of sympathetic nerves (**Figure 4**). The anterior margin of the horizontal segment of the CC is separated from the musculotubal canal by a thin layer of bone laterally [1, 5, 18].
2. The jugular fossa is a deep dome-shaped depression at the lateral wall of the JF and located behind the CC and below the floor of the tympanic cavity. It houses the superior bulb of the IJV and the mastoid canaliculus (**Figure 4**) for the entry of the Arnold's nerve, which provides sensory innervation of the EAC and auricle [9, 15]. The jugular spine in the jugular notch of the occipital bone divides the JF into the pars nervosa (anterior) and pars venosa (posterior) [4, 5, 9]. Normally, the jugular bulb is located between the IJV and the

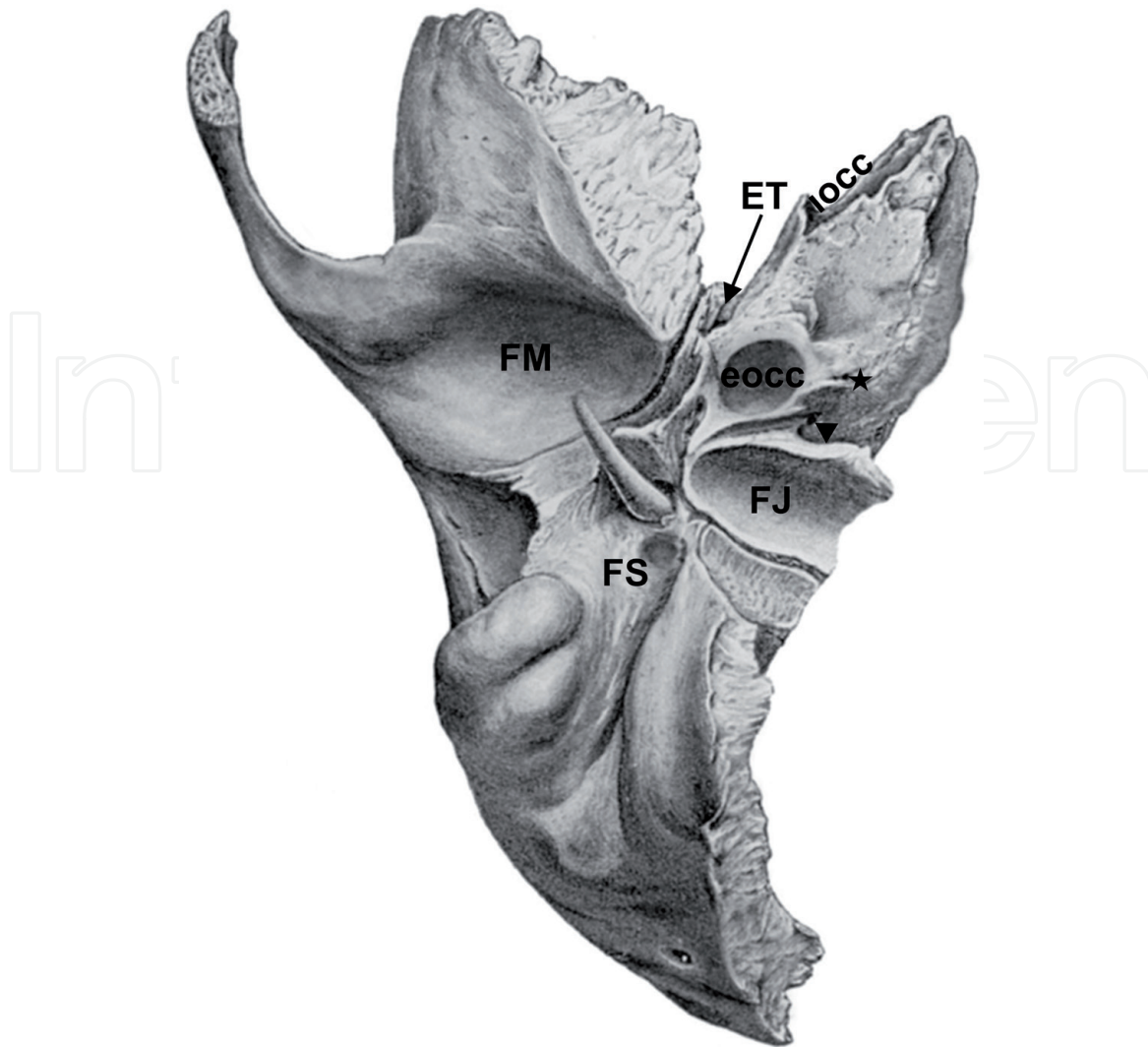


Figure 4.

The surface landmarks on the inferior surface of the petrous portion: FM, fossa mandibularis; FS, foramen stylomastoideum; FJ, fossa jugularis; ET, eustachian tube; eocc, external opening of carotid canal; iocc, internal opening of carotid canal; star: inferior tympanic canaliculus; arrowhead: cochlear aqueduct.

horizontal course of the SS. Abnormalities of it (80% below the FN in the mastoid cavity) result in dehiscence of the adjacent structures such as: the mediolateral enlargement of the JB results in the vestibular aqueduct, PSC, and IAC dehiscence, whereas the anteroposterior enlargement of the JB may cause the FN dehiscence. Abnormal high riding JB shows both mediolateral and anteroposterior enlargement and results in dehiscence of the FN [26].

3. Between the jugular fossa and the CC, the inferior ganglion of the GPN is localized in a triangular depression, whereas the inferior tympanic canaliculus penetrates into wedge-shaped bony ridge and transmits the tympanic branch of the GPN and inferior tympanic artery. At the apex of this triangular depression, there is an external opening of the cochlear aqueduct (**Figure 4**), which connects the perilymphatic space to the subarachnoid space and transmits the cochlear vein [1, 5, 14].
4. Behind the CC the vaginal process which is the extension of the sharp lower border of the tympanic plate wraps the root of the styloid process (**Figure 4**). The lower border of that extension serves an attachment for the deep layer of parotid fascia [1, 3, 5, 6].

2.4.5 Internal anatomy and ossification of the petrous portion

Internal structures in the petrous portion contain the ME and inner ear. The ME contains an air-filled tympanic cavity and the ossicular chain which is composed of the malleus, incus, and stapes [14]. The walls of the ME:

1. Lateral wall contains the tympanic membrane and the scutum pointed inferomedially from the squamous portion. The tympanic membrane has two parts; pars flaccida is located in a fibrocartilaginous ring called the tympanic sulcus and susceptible to perforations and pars tensa is situated in the notch of Rivinus above the lateral process of the malleus. At the medial surface of the membrane a depression called umbo is formed by attachment of the manubrium of the malleus.
2. Medial wall consists of the cochlear promontory, the FC, the oval and round windows. It is divided into three part by the bony ridges: the ponticulus superiorly and the subiculum inferiorly. The oval window (vestibular window) is located above the ponticulus whereas the round window (cochlear window) is below the subiculum, and the tympanic sinus between them is located medial to the FC. The vestibular window is closed by the base of the stapes. The facial recess lies below the lateral SSC and superolateral to the oval window.
3. Superior wall, the TT, which forms the roof of the ME.
4. Inferior wall is a bony roof of the IJV.
5. Anterior wall includes the anterior epitympanic recess superiorly, below it the tensor tympani muscle lies posteriorly and attaches to the neck of the malleus after turning laterally. The orifice of the ET and below it the CC is located inferiorly.
6. Posterior wall consists of the pyramidal eminence, epitympanum, and facial recess. The stapedius muscle passes through the pyramidal eminence and inserts to the head of the stapes [2, 5, 7, 14, 18].

The tympanic cavity is lined with the mucous membrane that extending into the MA posteriorly and the ET anteriorly. This cavity consists of three parts changing according to the level of the tympanic membrane; the epitympanum (superior to the level of the tympanic membrane), mesotympanum (at the level of the tympanic membrane), and hypotympanum (inferior to the level of the tympanic membrane). The hypotympanum has the orifice of the ET. At the lateral part of the epitympanum below the lateral malleal ligament there is the Prussak space which is bounded by the neck of the malleus medially and the pars flaccida and scutum laterally [2, 3, 5, 14].

Inner ear is comprised of the otic capsule (osseous labyrinth), which surrounds the membranous labyrinth and is divided into three parts from anterior to posterior including the cochlea, vestibule, and three SCs [14]. Cochlea is the spiral shaped bony labyrinth of the inner ear that looks like a snail shell making $2\frac{3}{4}$ turns about the modiolus and consists of the vestibular and the tympanic and the cochlear ducts, which are formed by an inner membranous partition. The vestibular duct (scala vestibuli) locates at the superior part of the cochlear canal and contains perilymph (rich in sodium ions) and is limited by the oval window, and is separated from the cochlear duct by Reissner's membrane. The cochlear

duct (scala media) locates at the middle part of the cochlear canal and contains endolymph (rich in potassium ions) and is separated from the tympanic duct by the basilar membrane, which has the Organ of Corti including the sensory hair cells. The stereocilia of these cells perceives the potential difference between the perilymph and the endolymph and converts that motion to electrical signals and finally hearing occurs. The tympanic duct (scala tympani) locates at the inferior part of the cochlear canal and contains perilymph as the vestibular duct and is limited by the round window [3, 5, 14, 15]. Vestibule contains the utricle and saccule. SSCs containing three semicircular ducts organized like three flower leafs that join the vestibule. They are located perpendicular to each other; the superior corresponds to the AE, the posterior is parallel to the posterior surface of the pyramid, and the lateral is perpendicular the mucosal plane and angled at 30° from the transverse plane [3, 15].

The FN passes through the anterosuperior part of the IAM and enters the fallopian canal (FC). It contains motor, sensory, and parasympathetic fibers and has six segments as follows:

1. Cisternal segment lies from the brain stem to the IAM. This part runs together with the cisternal part of vestibulocochlear nerve in same pia mater coverage.
2. Meatal segment is the smallest part of the FC and contains Bill's bar as an important landmark.
3. Petrous (labyrinthine) segment forms first genu (geniculate ganglion) above the cochlea at the lateral wall of the ME and gives a branch named as GSPN. Then, it enters the tympanic cavity and forms an angle ranging from 19 to 107° with tympanic segment of the FC [7, 20]. Because of this segment is the narrowest part and lack of arterial anastomoses, it is susceptible to embolic attacks and vascular compression.
4. Tympanic segment (first part) starts from first genu and turns backwards to lie in a thin-walled bony canal that runs evenly between the lateral SSC superiorly and the oval window inferiorly and medial to the incus. A dehiscence of the bony canal is more common at this segment in average 41–75%.
5. Pyramidal segment (second part of the tympanic segment) forms second genu at the posterior wall of the ME above the pyramidal process. It forms an angle ranging from 95 to 125° with mastoid segment of the FC [7, 20].
6. In the mastoid or vertical segment, the FN gives the acoustic branch for the stapedius muscle, the chorda tympani, and sensitive branch for the auricular region. This segment is located 5.50 mm anteromedially to the SS and extends from the level of the LSC to the digastric ridge (~3.8 mm). Then it exits the temporal bone at the SMF and enters the parotid gland [14, 27].

According to the classical description, the FC has four segments: labyrinthine, tympanic, pyramidal, and mastoid, but the meatal segment is important from an anatomical and surgical perspective. The stylomastoid artery, a branch of the posterior auricular or the occipital arteries, supplies the inferior parts of the FC up to the second genu and anastomoses directly with the petrosal branch of the MMA, which supplies the geniculate ganglion. The FC pathologies are composed of agenesis, aplasia, narrowing, and osteopetrosis of the canal, which result in complete or incomplete facial paralysis. Bell's palsy depending on the activation of a dormant

herpes virus, is responsible for 50% of peripheral FN palsies. The FC dehiscence can be congenital or secondary to the surgical intervention or pathology of adjacent structures and results in cerebrospinal fluid (CSF) otorrhea. Several surgical approaches, including the translabyrinthine, transcochlear and retrosigmoid, are used to treat the FC pathologies [27].

Ossification of the petrous portion begins from the 14 centers that fuse to form otic capsule and is completed at birth. The petrous portion develops from the cartilaginous differentiation of the mesenchyme by endochondral ossification at the 16th week of gestation. The cementum layer in teeth roots and petrous portion of the temporal bone contain the optimal endogenous DNA substrate which can provide information to specify the geographic location for genomic analyses [28]. Damgaard et al. reported that the prevalence of the endogenous DNA contents in nonpetrous bones and teeth is ranged from 0.3 to 20.7%, while the levels for petrous bones ranges between 37.4 and 85.4% [29]. Due to the high density and resistance to harsher climatic conditions of the petrous bone, the otic capsule of the petrous bone preserves DNA substrate extremely well and has much higher endogenous DNA level than the teeth by 5.2-fold on average. So, it is currently acknowledged as the optimal substrates for ancient genomic research [28, 29].

2.4.6 Triangles on the anterior and posterior surfaces of the petrous portion

Kawase's triangle: Borghei-Razavi et al. evaluated the safety of this postero-medial middle fossa triangle for removal of the tumors locating or spreading into the cerebellopontine angle and petroclival area. Kawase's triangle was identified

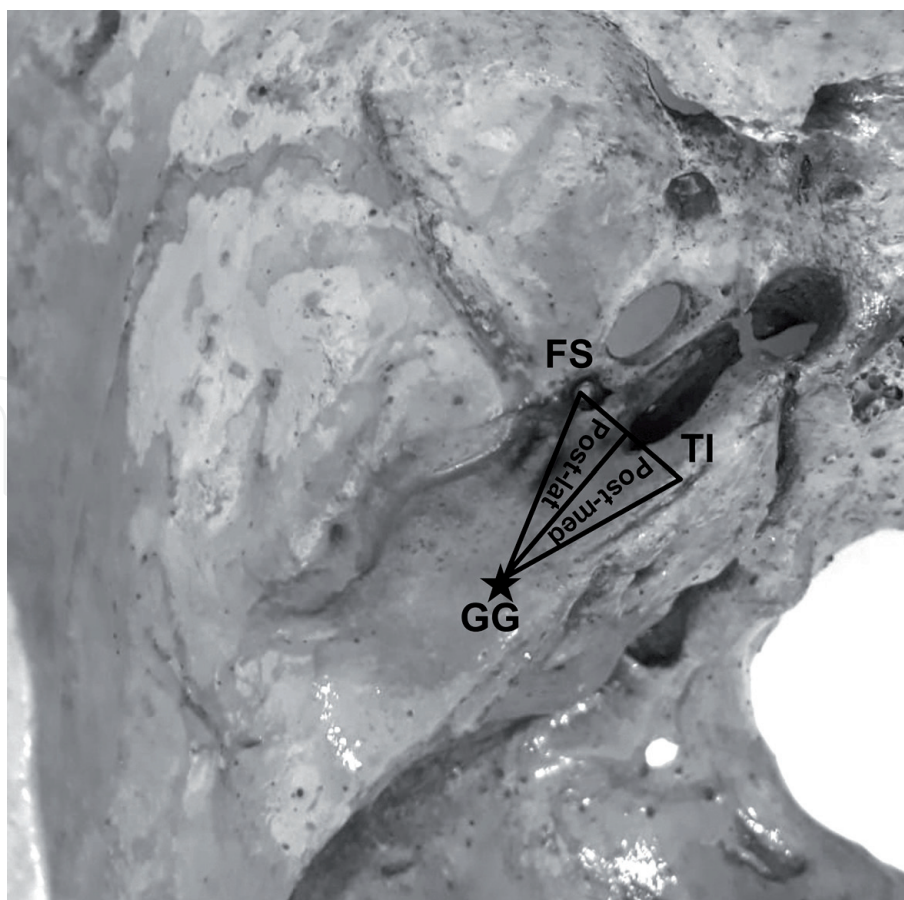


Figure 5. The surgical triangles on the anterior surface: Kawase's triangle: Post-med (posteromedial triangle) and Glasscock's triangle: post-lat (posterolateral triangle). FS, foramen spinosum; GG, geniculate ganglion; TI, trigeminal impression.

between the GSPN laterally, the geniculate ganglion at the AE posteriorly, and ganglion gasserian at the trigeminal impression anteriorly. During anterior petrosectomy for accessing the posterior cranial fossa via middle fossa, the GSPN forms the lateral border of the surgical approach (**Figure 5**) [30].

Glasscock's triangle, or the posterolateral middle fossa triangle, is identified between the TN (V3), the geniculate ganglion at the AE and FS (**Figure 5**). The margins of this triangle are formed by a line between where the GSPN crosses under V3 and the FS medially, a line between the FS and geniculate ganglion laterally, and GSPN describing the base [3, 5, 16].

Rhomboid area (Kawase triangle+postmeatal area) is situated between the GPN, petrous ridge, AE, and the posterior border of the V3. A large tumor located in the midline skull base or spreading into the infratemporal and petroclival region even the cavernous sinus can be removed by extended EEA through V2-V3 corridor to avoid complications including ICA injury, IPS bleeding, TN injury and CSF leak [31].

Trautmann's triangle is bounded by the SPS superiorly, SS posteriorly, and solid angle which is formed by three SCs anteriorly (**Figure 6**). In this triangle, the retro-labyrinthine tract from the MA, the endolymphatic sac, and the vestibular aqueduct are located [5, 9].

Donaldson's line is a surgical line that is parallel to the LSC whereas it is vertical to the posterior SSC and divide it into superior and inferior portions. Below this line medial to the labyrinth the endolymphatic sac is situated. Citelli's angle (sinodural angle); is bounded by the middle fossa dura plate (SPS) superiorly, posterior fossa dura plate (bony plate covering the MA) anteriorly and the SS posteriorly (**Figure 6**). During mastoidectomy the air cells in this triangle should be removed [1, 5, 6].

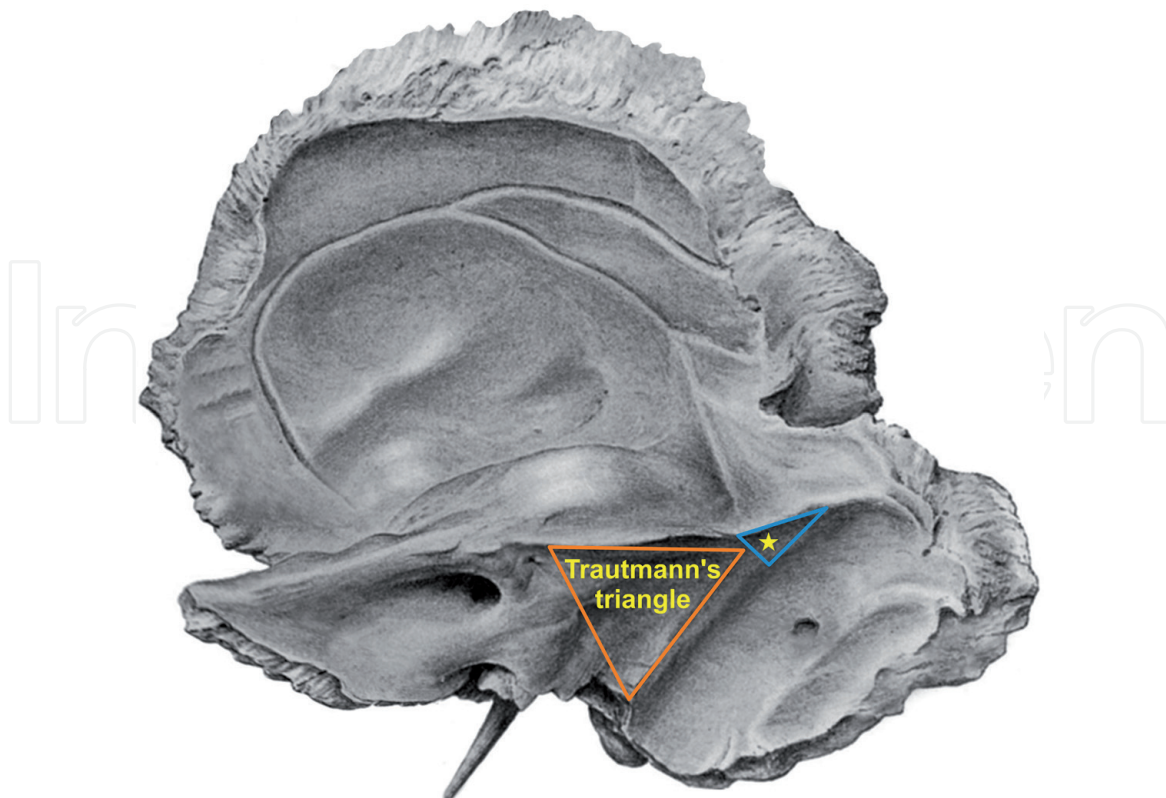


Figure 6.

The surgical triangles on the posterior surface: Trautmann's triangle margins are formed between the superior petrosal sinus superiorly, the sigmoid sinus posteriorly, and the semicircular canals antero-inferiorly. Star: Citelli's angle (sinodural angle) is formed between the dural plates of the middle fossa superiorly, the posterior fossa anteriorly and the sigmoid sinus posteriorly.

3. Segmental anatomy of the petrous portion

In clinical applications, for fully understanding of the tridimensional architecture of the petrous portion, a reference lines and angles can be defined on the anterior and posterior surfaces from a superior view.

Peris-Celda et al. reported that the EAM and the IAM are located in the same coronal plane on the anterior surface forming surgical triangle [9]. Tawfik-Helika et al. separated the pyramid into four compartments and described two segmentation method to provide better understanding of the distributions of these compartments. They identified four compartments based on their connections: mucosal, cutaneous, neural, and vascular [3, 21].

The mucosal compartment consists of an air filled and mucosa lined cavities from anterior to posterior: the ET, ME, and the MA (**Figure 7**). The mucosal line in an oblique anteromedial direction extends along these structures and is used for segmental description of this pyramid, and all major anatomical landmarks can be identified relative to this axis for surgical approaches [3, 9, 21].

Extending the mucosal line posteriorly, the MA is separated into medial and lateral parts, whereas anteriorly, the bony portion of the ET is localized at the junction of the petrous and squamous parts and the cartilaginous part opens into the pharynx anteriorly. Medially the line passing through the sulcus of the GSPN and laterally a straight line lying between the foramen ovale and FS are parallel to this line (**Figure 7**) [3, 9, 21].

The cutaneous compartment is composed of the EAM, which is covered by the skin and separated from the ME by the tympanic membrane medially.

The neural compartment is composed of the otic capsule, which is located medial to ME and the mucosal line. In this bony container, the cochlea, vestibule, and SCs are located from anterior to posterior around the fundus of the IAM (**Figure 7**).

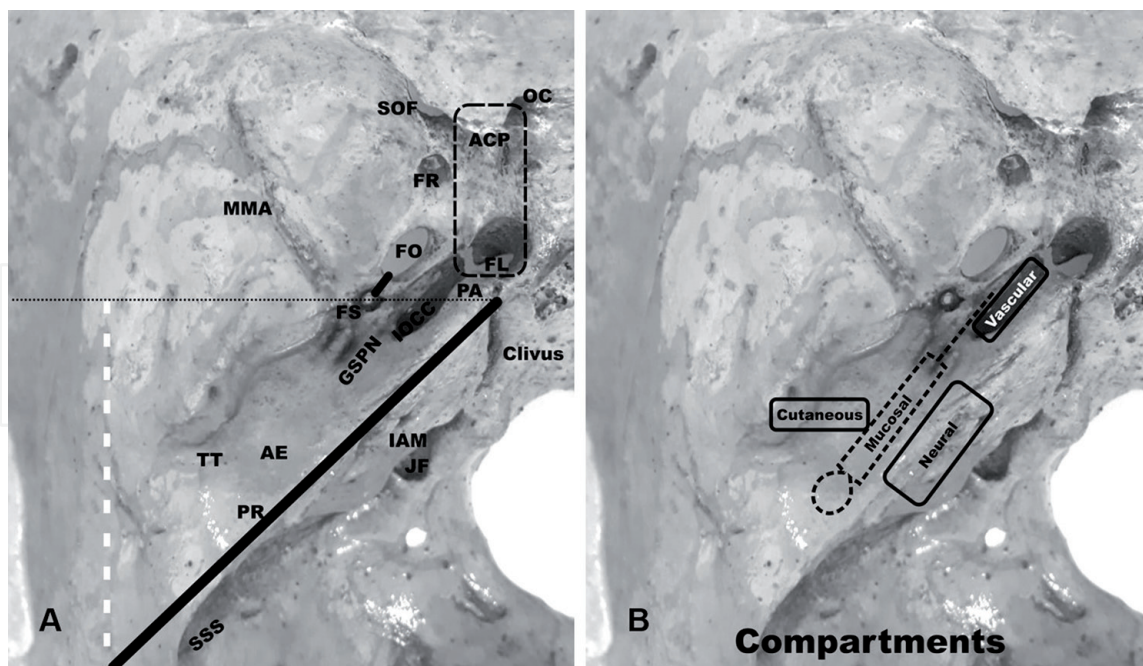


Figure 7.

(A) The margins of the anterior surface of the left petrous portion from a superior view are shown posteriorly by a (thick black) line along the PR, petrous ridge; anteriorly by a (dashed black) line lying from the preauricular burrhole to PA, petrous apex and passing through the FS, foramen spinosum; and laterally by a (dashed white) line along the petro-squamous suture. OC, optic canal; ACP, anterior clinoid process; FL, foramen lacerum; SOF, superior orbital fissure; FR, foramen rotundum; FO, foramen ovale; MMA, middle meningeal artery; IOCC, internal opening of carotid canal; GSPN, greater petrosal nerve; AE, arcuate eminence; TT, tegmen tympani; JF, jugular foramen; IAM, internal acoustic meatus; SSS, sulcus sigmoid sinus. (B) The segmentation of the left petrous pyramid into four compartments including mucosal, cutaneous, neural, and vascular is shown on the left petrous portion.

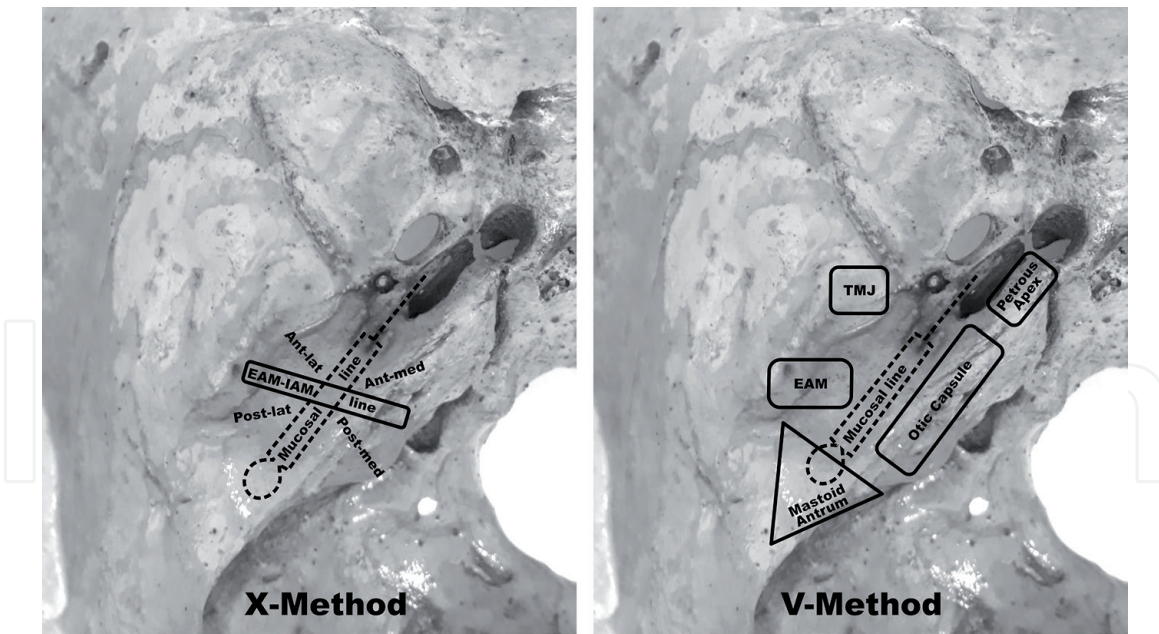


Figure 8.
 Schematic representations of the segmentation of the left petrous portion by using X and V methods.

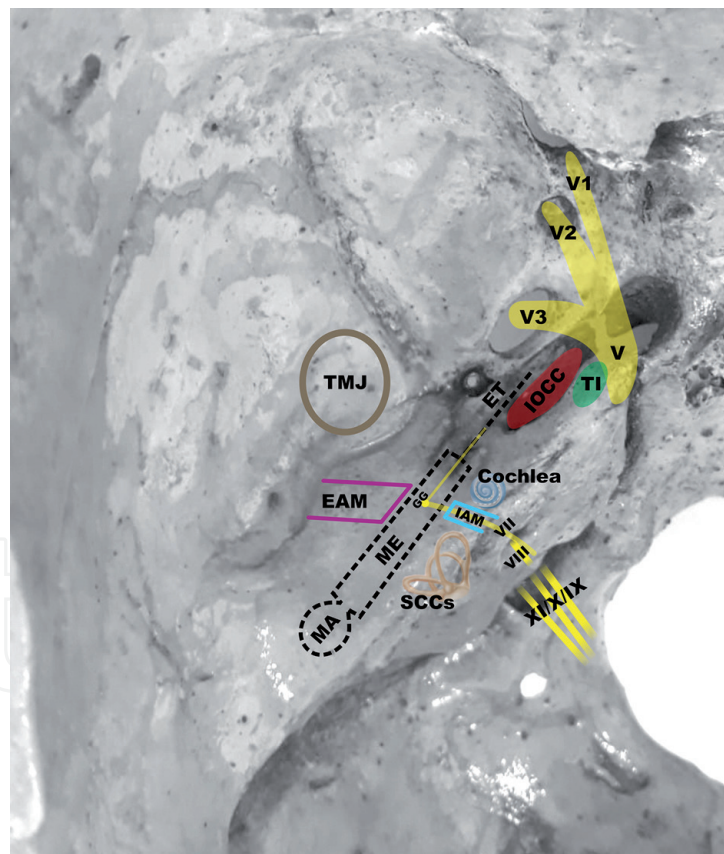


Figure 9.
 Schematic representation of the external and internal landmarks on the left petrous portion. V, trigeminal nerve and branches (V1, V2, V3); TI, trigeminal impression; IOCC, internal opening of carotid canal; ET, Eustachian tube; GG, geniculate ganglion; ME, middle ear; MA; mastoid antrum; EAM, external acoustic meatus; TMJ, temporomandibular joint; SCCs, semicircular canals; IAM, internal acoustic meatus; VII, facial nerve; VIII, vestibulocochlear nerve; IX, glossopharyngeal nerve; X, vagus nerve; XI, accessory nerve.

The vascular compartment is composed of the ICA. The axis passing through the horizontal part of the CC is parallel and medial to the mucosal line (**Figure 7**) [3]. Moreover, Tawfik-Helika et al. described X and V segmentation methods to advance and enhance education of the compartments.

The X method divides the petrous pyramid into four spaces by using two reference lines intersecting with each other at the ME; the mucosal line and the EAM-IAM line form the X letter (**Figures 8 and 9**). These four spaces around the ME and the contents in it are as follows:

The anteromedial space—the cochlea and the petrous apex including the ICA

The anterolateral space—the roof of the TMJ

The posterolateral space—the lateral part of the MA

The posteromedial space—the posterior labyrinth and the medial part of the MA

The V method arranges five segments around the mucosal line (**Figures 8 and 9**)

These five segments and the contents in it are as follows:

The petrous apex segment—the ICA medial to the ET

The otic capsule segment—the IAM, cochlea, vestibule and SCs

The mastoid segment—the angle around the MA

The EAM segment—the lateral part of the ME

The TMJ segment—the roof of the TMJ lateral to the ET [3].

4. Conclusions

Detailed description of the temporal anatomy pointing to relationships between internal and external landmarks and a holistic approach including X and V segmentation methods that break down the petrous pyramid into spaces and compartments can provide an easy way to understand and to use surgical applications. The compartmental approach can be helpful in the fields of education and radiological applications as well as surgery.

IntechOpen


Author details

Gülay Açar and Aynur Emine Çiçekcibaşı*

Department of Anatomy, Meram Faculty of Medicine, Necmettin Erbakan University, Konya, Turkey

*Address all correspondence to: aynurcicekcibasi@yahoo.com.tr

IntechOpen

© 2020 The Author(s). Licensee IntechOpen. This chapter is distributed under the terms of the Creative Commons Attribution License (<http://creativecommons.org/licenses/by/3.0>), which permits unrestricted use, distribution, and reproduction in any medium, provided the original work is properly cited. 

References

- [1] Mansour S, Magnan J, Haidar H, Nicolas KSL. *Comprehensive and Clinical Anatomy of the Middle Ear*. 1st ed. Heidelberg: Springer-Verlag; 2013
- [2] Juliano AF, Ginat DT, Moonis G. Imaging review of the temporal bone: Part I. Anatomy and inflammatory and neoplastic processes. *Radiology*. 2013;**269**(1):17-33
- [3] Tawfik-Helika M, Mertens P, Ribas G, Cusimano MD, Catala M, Kirollos R, et al. Understanding anatomy of the petrous pyramid-a new compartmental approach. *World Neurosurgery*. 2019;**124**:e65-e80
- [4] Powell KA, Kashikar T, Hittle B, Stredney D, Kerwin T, Wiet GJ. Atlas-based segmentation of temporal bone surface structures. *International Journal of Computer Assisted Radiology and Surgery*. 2019;**14**(8):1267-1273
- [5] Gray SS. *Gray's Anatomy: The Anatomical Basis of Clinical Practice*. Philadelphia: Elsevier; 2016
- [6] Belsare GS. *Step by Step Temporal Bone Dissection*. New Delhi, India: Jaypee Brothers Medical Publishers; 2014
- [7] Alhussaini MA, Mattingly JK, Cass SP. Anatomical relationship of the middle cranial fossa dura to surface landmarks of the temporal bone. *Otology & Neurotology*. 2017;**38**(9):1351-1354. DOI: 10.1097/MAO.0000000000001532
- [8] Bender ME, Lipin RB, Goudy SL. Development of the pediatric temporomandibular joint. *Oral and Maxillofacial Surgery Clinics of North America*. 2018;**30**(1):1-9. DOI: 10.1016/j.coms.2017.09.002
- [9] Peris-Celda M, Perry A, Carlstrom LP, Graffeo CS, Driscoll CLW, Link MJ. Key anatomical landmarks for middle fossa surgery: A surgical anatomy study. *Journal of Neurosurgery*. 2018;**131**:1561-1570. DOI: 10.3171/2018.5.JNS1841
- [10] Lee HJ, Choi YJ, Lee KW, Kim HJ. Positional patterns among the auriculotemporal nerve, superficial temporal artery, and superficial temporal vein for use in decompression treatments for migraine. *Scientific Reports*. 2018;**8**(1):16539. DOI: 10.1038/s41598-018-34765-1
- [11] Todd NW. Helpful and unhelpful parts of the superior petrosal triangle. *Otolaryngology and Head and Neck Surgery*. 2006;**134**(6):966-969
- [12] Baur DA, Beushausen M, Leech B, Quereshy F, Fitzgerald N. Anatomic study of the distance between the articular eminence and foramen spinosum and foramen spinosum and petrotympanic fissure. *Journal of Oral and Maxillofacial Surgery*. 2014;**72**(6):1125-1129. DOI: 10.1016/j.joms.2013.12.030
- [13] Oyama K, Tahara S, Hirohata T, Ishii Y, Prevedello DM, Carrau RL, et al. Surgical anatomy for the endoscopic endonasal approach to the ventrolateral skull base. *Neurologia Medico-Chirurgica (Tokyo)*. 2017;**57**(10):534-541
- [14] Juliano AF. Cross sectional imaging of the ear and temporal bone. *Head and Neck Pathology*. 2018;**12**(3):302-320
- [15] Benson JC, Eckel L, Guerin J, Silvera VM, Diehn F, Passe T, et al. Review of temporal bone microanatomy: Aqueducts, canals, clefts and nerves. *Clinical Neuroradiology*. 2019;**30**(2):209-219. DOI: 10.1007/s00062-019-00864-3
- [16] Altieri R, Sameshima T, Pacca P, Crobeddu E, Garbossa D, Ducati A, et al.

Detailed anatomy knowledge:
First step to approach petroclival meningiomas through the petrous apex. Anatomy lab experience and surgical series. Neurosurgical Review. 2017;**40**(2):231-239

[17] Przewozny TT, Kosinski A, Markiet K, Sierszen W, Kuczkowski J, Kurylowicz J, et al. Körner's septum (petrosquamosal lamina): The anatomical variant or clinical problem? *Folia Morphologica*. 2020;**79**(2): 205-210. DOI: 10.5603/FM.a2019.0079

[18] Isaacson B. Anatomy and surgical approach of the ear and temporal bone. *Head and Neck Pathology*. 2018;**12**(3):321-327

[19] Deniz Y, Geduk G, Zengin AZ. Examination of foramen tympanicum: An anatomical study using cone-beam computed tomography. *Folia Morphologica*. 2018;**77**(2):335-339

[20] Mittal S, Singal S, Mittal A, Singal R, Jindal G. Identification of foramen of Huschke with reversible herniation of temporomandibular joint soft tissue into the external auditory canal on multidetector computed tomography. *Proceedings (Baylor University Medical Center)*. 2017;**30**(1):92-93. DOI: 10.1080/08998280.2017.11929544

[21] Pellet W, Cannoni M, Pech A. *Otoneurosurgery*. Berlin: Springer; 2012

[22] Singh A, Kumar R, Irugu DVK, Kumar R, Sagar P. Morphometric analysis of arcuate eminence: A distinctive landmark for middle cranial fossa approach. *Journal of Cranio-Maxillo-Facial Surgery*. 2018;**46**(10):1703-1706. DOI: 10.1371/journal.pone.0129102

[23] Brown EC, Lucke-Wold B, Cetas JS, Dogan A, Gupta S, Hullar TE, et al. Surgical parameters for minimally

invasive trans-eustachian tube csf leak repair: A cadaveric study and literature review. *World Neurosurgery*. 2019;**122**:e121-e129. DOI: 10.1016/j.wneu.2018.09.123

[24] Kaen A, Ruiz-Valdepeñas EC, Di Somma A, Esteban F, Rivas JM, Fernandez JA. Refining the anatomic boundaries of the endoscopic endonasal transpterygoid approach: The "VELPPHA area" concept. *Journal of Neurosurgery*. 2018;**131**(3):911-919. DOI: 10.3171/2018.4.JNS173070

[25] Tayebi Meybodi AS, Little A, Vigo V, Benet A, Kakaizada ST, Lawton M. The pterygoclivial ligament: A novel landmark for localization of the internal carotid artery during the endoscopic endonasal approach. *Journal of Neurosurgery*. 2018;**18**:1-11. DOI: 10.3171/2017.12.JNS172435

[26] Cömert E, Kiliç C, Cömert A. Jugular bulb anatomy for lateral skull base approaches. *The Journal of Craniofacial Surgery*. 2018;**29**(7):1969-1972. DOI: 10.1097/SCS.00000000000004637

[27] Mortazavi MM, Latif B, Verma K, Adeeb N, Deep A, Griessenauer CJ, et al. The Fallopian Canal: A comprehensive review and proposal of a new classification. *Child's Nervous System*. 2014;**30**(3):387-395. DOI: 10.1007/s00381-013-2332-0

[28] Hansen HB, Damgaard PB, Margaryan A, Stenderup J, Lynnerup N, Willerslev E, et al. Comparing ancient DNA preservation in petrous bone and tooth cementum. *PLoS One*. 2017;**12**(1):e0170940

[29] Damgaard PB, Margaryan A, Schroeder H, Orlando L, Willerslev E, Allentoft ME. Improving access to endogenous DNA in ancient bones and teeth. *Scientific Reports*. 2015;**5**:11184. DOI: 10.1038/srep11184

[30] Borghei-Razavi H,
Tomio R, Fereshtehnejad SM,
Shibao S, Schick U, Toda M, et al.
Anterior petrosal approach: The safety
of kawase triangle as an anatomical
landmark for anterior petrosectomy
in petroclival meningiomas. *Clinical
Neurology and Neurosurgery*.
2015;**139**:282-287. DOI: 10.1016/j.
clineuro.2015.10.032

[31] Watanabe K, Zomorodi AR,
Labidi M, Satoh S, Froelich S,
Fukushima T. Visualization of dark side
of skull base with surgical navigation
and endoscopic assistance: Extended
petrous rhomboid and rhomboid with
maxillary nerve-mandibular nerve
vidian corridor. *World Neurosurgery*.
2019;**129**:e134-e145. DOI: 10.1016/j.
wneu.2019.05.062