

# We are IntechOpen, the world's leading publisher of Open Access books Built by scientists, for scientists

5,000

Open access books available

125,000

International authors and editors

140M

Downloads

Our authors are among the

154

Countries delivered to

TOP 1%

most cited scientists

12.2%

Contributors from top 500 universities



WEB OF SCIENCE™

Selection of our books indexed in the Book Citation Index  
in Web of Science™ Core Collection (BKCI)

Interested in publishing with us?  
Contact [book.department@intechopen.com](mailto:book.department@intechopen.com)

Numbers displayed above are based on latest data collected.  
For more information visit [www.intechopen.com](http://www.intechopen.com)



# Peripheral Edema: Differential Diagnosis

*Sandro Michelini, Alessandro Failla, Giovanni Moneta,  
Alessandro Fiorentino and Cardone Marco*

## Abstract

Peripheral edemas can be generated by multiple causes, local and/or systemic. The difficulties in recognizing the exact nature of the edema and the cause that originates it often lead to erroneous considerations that determine an inappropriate therapeutic approach. In this chapter the various causes that generate peripheral edema are analyzed (systemic: cardiac diastolic dysfunction, kidney failure, liver failure, myxedema, from drugs, and idiopathic; and local: venous and/or lymphatic transport insufficiency). They are also described, according to the diagnosis made and the clinical and instrumental criteria to attain a correct and early diagnosis and to proceed to the most appropriate therapeutic measures (drugs, surgery, physical rehabilitative by means of manual and mechanical techniques) in individual cases.

**Keywords:** peripheral edema diagnosis, edema diagnosis, peripheral edema of limbs differential diagnosis

## 1. Introduction

Lower limb edema recognizes more etiological factors that are frequently confused during differential diagnosis. Sometimes there are more causes with preponderance of one over the other, either local or systemic.

The doubts in the diagnostic definition derive from an insufficient evaluation of clinical symptomatological aspects and of any instrumental and hemato-chemical tests performed in individual cases.

From a correct clinical and consequently ethiopathogenetic classification derives the most appropriate therapeutic option. Pharmacological, physical rehabilitative, or surgical therapies not inspired by edema correction principles based on its ethiopathogenesis may result in therapeutic failure or even in the worsening of local or systemic clinical status.

### 1.1 Description

The causes of edema of the lower limbs are various (local and/or systemic), sometimes multiple, and are to be found on the basis of a series of anamnestic and semeiological elements that, if properly considered and identified, allow better management of the clinical picture [1].

Too often, in fact, even today we are witnessing the diagnosis of lymphostatic edemas of lower limbs, ignoring that in many cases the loco-regional lymphatic system is normally developed and adequately functional.

The same monolaterality of edema, by itself alone, allows to address the diagnostic suspicions towards a local and non-systemic cause. A systemic cause of edema of lower limbs, in fact, always determines bilateral edema (albeit with relative prevalence in one of the two limbs), never being unilateral [1].

Therefore, on the one hand, it is necessary to have a clear presence of the systemic causes of edema and of the loco-regional ones and, on the other hand, the clinical and instrumental criteria which, together, allow to formulate the correct diagnosis and to prepare the most indicated therapeutic measures.

## 2. Causes of edema of the lower limbs

### 2.1 Local

- Insufficiency of the superficial lymphatic system (the deep one does not assume the importance that it has as in the venous system); it can be unilateral or bilateral [2–7].
- Insufficiency of the deep venous system (the insufficiency of the superficial one is not able to autonomously generate edema, as many subjects with varicose veins of the lower limbs do not have localized or widespread edema and, above all, clinically present the feet ‘dry’). In these cases the edema is unilateral (post-thrombotic syndrome) [8, 9].
- Lipedema which is normally bilateral and frequently associated with a similar clinical aspect of the upper limbs [10–12].
- Inflammatory/infectious states of the soft tissues (joints, tendons, muscles) or bones.
- Benign or malignant neoplasms (primitive or metastatic).

### 2.2 Systemic

- Heart failure (from diastolic dysfunction) [13]
- Hepatic insufficiency [14]
- Acute and chronic renal failure
- Myxedema [15]
- Drugs edema
- Idiopathic edema

Among the **loco-regional** causes, the most important and frequent is represented by lymphedema (primary and secondary).

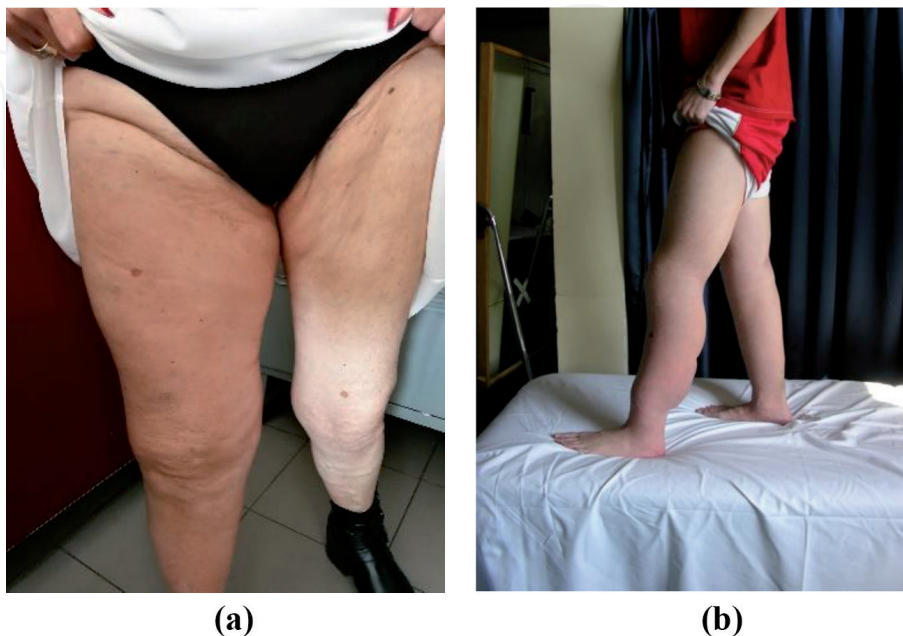
### 2.3 Lymphedema

Lymphedema derives from an altered (qualitative or quantitative) development of the loco-regional system. In primary forms (which may occur at birth or, more frequently, in the second, third, fourth, fifth decade of life), an altered development

of the lymphatic pathways, an altered lymph-node architectural code (lymphadenodysplasia), or an insufficient number of them (often on a genetic basis in the development of lymph glandular stations) causes a slowing of the lymphatic return that can go as far as the stop of the flow at the loco-regional level. In some cases the familiarity for the affection is documented, in others (the so-called sporadic forms, because we do not know their existence in other family members), the lymphedema appears in the only subject clinically affected without affecting other members of the same family nucleus; then there is a third type of primary lymphedema in which the edema constitutes only one (and not always the “determinant”) of the various clinical aspects of a syndrome (Prader-Willi, Noonan, Proteus, Hennekam, Gorham-Stout).

The secondary forms are sometimes considered primary for the predisposition in some subjects to develop secondary edema following certain clinical conditions (one example is the “post-mastectomy lymphedema”, which develops in one in four woman, while the others remain with the same limb, in volume and consistency, throughout their lives, even if they are of the same age and in the same physical condition, and undergo the same surgery by the same operator); the genesis and the ethiopathogenetic evolution, in these cases, are the same as in the primary forms; in these cases, as a result of inflammatory processes, traumas, or, more frequently, surgical lymphadenectomy for neoplasms or radiotherapy, the anatomical continuity of the local lymphatic circulation is lost in an acquired manner so that the clinical picture of the lymphostasis is observed. One of the clinical peculiarities of lymphedema of the lower limbs is the different progression of stasis along the limb: from the more distal portions towards the proximal ones in the primary forms and from the proximal ones to the distal ones in the secondary forms (**Figure 1a** and **b**).

Lymphedema is characterized by being the only edema with high interstitial protein concentration, distinguishing itself for this from all other types of edema [16, 17]. The presence of a high rate of proteins in the interstitium determines the activation of fibroblasts that increase their production of collagen fibers, inducing more or less early and more or less marked tissue sclerosis. Lymphatic edema, therefore, is characterized by an early increase in the consistency of the tissues in which it is located and that, in the most advanced clinical stages, can reach the wooden consistency. Under these conditions the compression of the skin generates a depression (or “pitting test”) that can be “fleeting” or even absent [18–23].



**Figure 1.**  
*Lymphedema of the lower limb: primary (a) and secondary (b).*

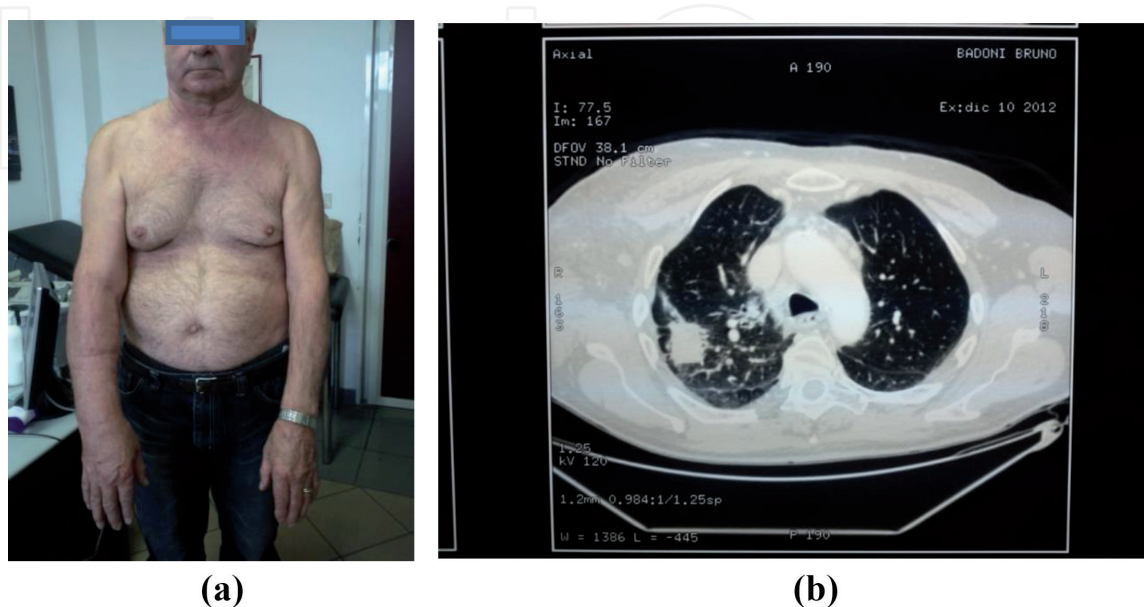
For the rarefaction of the arteriolar capillaries which, with the same volumetric unit, is carried out in the cutaneous and subcutaneous tissues, the skin color is not “rosy” as in the skin of normal limbs but pale. For the same ethiopathogenetic reason, the limb skin with lymphedema is colder than of a normal limb [24–28].

The lymphatic system presents some well-recognizable outward signs. The lymphatic system communicates us, but often the examiner does not recognize the messages sent. An example of this is the location of the primary or metastatic cancer in the lymphatic system itself. Sometimes a monolateral edema of the upper limb, sent for decongestive complex therapy with the prescription of a manual lymphatic drainage cycle for forearm edema and a recent onset, may be the expression of a symptomatic edema of a metastatic cancer (**Figure 2a and b**). In these cases, an aprioristic therapeutic approach, without the most opportune clinical considerations, can fatally delay the care that the patient really needs.

The commonly recognized four clinical stages of the disease are:

- **First stage:** It is the pre-clinical stage in which there is an undoubted predisposition to the possible onset of lymphedema (a consanguinity of a patient with primary lymphedema, mastectomized with limbs coincident in terms of volume and consistency of the two limbs).
- **Second stage:** The edema is present and regresses partially with nighttime rest and decongestive physical treatments.
- **Third stage:** Elephantiasis with disappearance of the bony and tendon salencies normally present in the affected limb.
- **Fourth stage:** Elephantiasis complicated by verrucosis, pachydermia, ulcer, or tissue changes in the lymphosarcomatosis sense.

In primary forms of lower limbs, there is also a pathognomonic sign that takes its name from the person who first described it: the Stemmer sign. Its positivity consists in the impossibility to “pinch” with the fingers of the examiner the skin of the patient’s toe; you cannot lift it from the underlying bone phalanx due to the



**Figure 2.** Forearm and hand edema, determined by the presence of metastases of the supraclavicular lymph nodes from unknown primitive pulmonary cancer (first clinical manifestation of neoplasia).

early fibrosis that is generated in the over-factory layers of the tissue itself. The diagnosis of lymphedema is clinical (fundamental is the anamnesis and a correct objective examination); however, there are some instrumental exams that complete the picture, allowing a better definition of the therapeutic approach and the prognostic one. In the primary forms, the lymphoscintigraphy is essential which consists of subcutaneous inoculation, at the root of the toes, of some drops of radioactive tracer (nanocolloids of albumin labeled with technetium-99) which has a particular tropism for the lymphatic system. After inoculation, the patient practices physical exercise to allow the tracer to “gain” more quickly the lymphatic pathways. After 30', and after 90', a gamma-chamber performs that uptake of the tracer which, in the meantime, is distributed in the lymphatic vessels and lymph nodes of the whole lower limb and in the iliac chains. The resulting image provides important morphological indications on the normal/pathological development of the lymphatic system allowing better orienting the therapeutic intervention and being able to conceive also a prognosis.

The high-resolution ultrasound examination also highlights the thickening of the epidermis on the affected side, the increase in thickness of the over-fascial layer, and the tissue compressibility that is a function of the more or less developed fibrosis.

The ultrasound also allows the monitoring of pharmacological, physical rehabilitative, and surgical treatment by comparing the pre- and posttreatment over-fascial thicknesses.

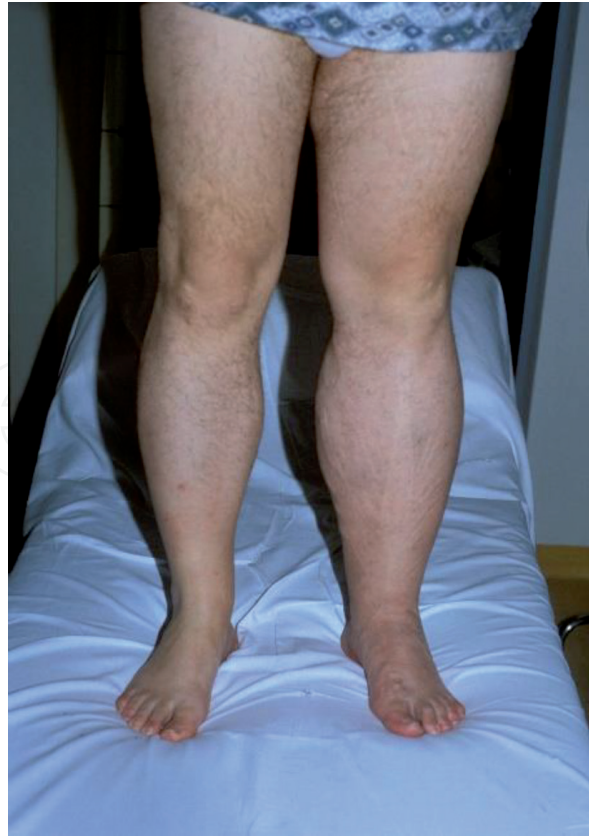Videofluoroscopy is more complex and difficult to access because it is not widely practiced at a territorial level. It consists of the study of the anatomy physio-lymphatic pathology by injection of a dye, the indocyanine green, which flows into the lymphatic vessels and allows to visualize the flow in real time (on videoscope) both basal and during manual or mechanical stimulation; the lymphangio-MR, even less widespread as practiced in very few centers at the international level, allows, in more detail, to highlight the entire local lymphatic system and its possible anatomical defects.

## 2.4 Venous edema

It is very rare, in contrast to the lymphatic stasis edema, to observe a venous edema deriving from the supra-fascial venous compartment. In this sense the lymphatic system and the venous system behave in a completely opposite way from the clinical point of view. Lymphedema never develops in deep tissues, unless congenital dysplasia is located in the deep tissues; it is always located at the supra-fascial level.

Venous edema, on the other hand, never develops in the supra-fascial compartment (in the clinical practice, it is common to find patients who have large varicose veins of the lower limbs, but their feet are “dry”, with no signs of edema.). Venous edema is an edema that is located at a deep level (for this reason, it is difficult to manage, from the therapeutic point of view, with conventional manual or mechanical drainage techniques). It is located at the sub-fascial level and, in the overwhelming majority of cases, represents the most striking aspect of the permanent clinical picture of a so-called “post-thrombotic syndrome” (**Figure 3**).

In deep venous thrombosis of the lower limbs, in fact, after thrombotic occlusion of the deep veins, follows more or less precociously a “compensatory” dilatation of the deep collateral and often superficial circle in correspondence of the same anatomical district (secondary or symptomatic varices). This muscular imbibition (therefore deep) assumes the characters of chronicity and corresponds to the permanent edema in which it is not possible to observe alterations of skin color or



**Figure 3.**  
*Post-thrombotic oedema of the lower limb.*

skin temperature in its correspondence, and the pitting sign is absent and does not appreciate changes in tissue texture. In doubtful cases (previous venous thrombosis passed “unobserved” from a clinical point of view due to lack of characteristic signs and symptoms), a key examination is represented by the computerized tomography.

According to the “CT cuts” of the two limbs in comparison with the lymphatic edema it is possible to observe an increase in supra-fascial thickness, over-folded with the sub-fascial compartment coinciding in the two limbs, in venous edema (from deep vein thrombosis); on the contrary, the supra-fascial thicknesses appears coincident, while the sub-fascial thickness is considerably increased in the affected side.

Symptoms in the post-thrombotic syndrome of the lower limb (in the one-sided form) are generally non specific; patients often show paresthesia, rarely pain, mostly vague, hardly epicritic, and often associated with protopathic sensitivity.

The so-called venous claudication which consists in pain during walking but with a variable free-range of motion (unlike “arterial claudication”), is rare and appears in the worsening of the deep venous circulation due to incomplete recanalization of the deep venous axis when the acute phase is past.

Obviously, the high-resolution ultrasound examination in these cases shows a relative increase of the sub-fascial layers, and the echo color Doppler of the examined districts confirms the outcomes of deep vein thrombosis with frequent evidence of parietal sclerosis and partial or total disappeared endoluminal valvular structures.

## **2.5 Phlebolympheoedema**

Phlebolympheoedema represents a particular type of peripheral edema that is determined by the contemporary etiopathogenetic association of venous and

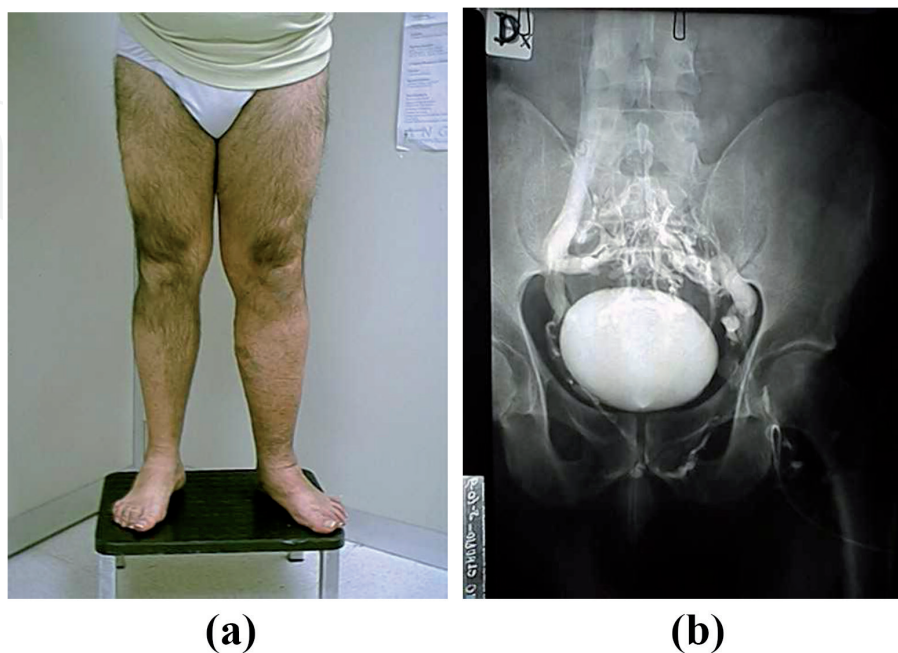
lymphatic insufficiency. It is generally present in cancer, due to the simultaneous macroscopic and microscopic anatomical involvement of the two venous and lymphatic drainage systems of a certain anatomical district<sup>8</sup>.

The most striking manifestation is a secondary lymphedema of the lower limb determined by inguinal or pelvic lymphadenectomy (necessary for compliance with surgical criteria of “radical cancer therapy”) associated with a partial or complete occlusion of a deep venous vessel of the limb same. In these cases the increase in interstitial oncotic pressure determined by the mechanical lymphatic stasis (removal of lymphoglandular stations) is associated with a venous hypertension (increase of the intravascular hydrostatic pressure in the venous side of the microvascular tissue unit) caused by the occlusion of the main venous axis of outflow from the lower limb itself (**Figure 4**).

## 2.6 Lipedema

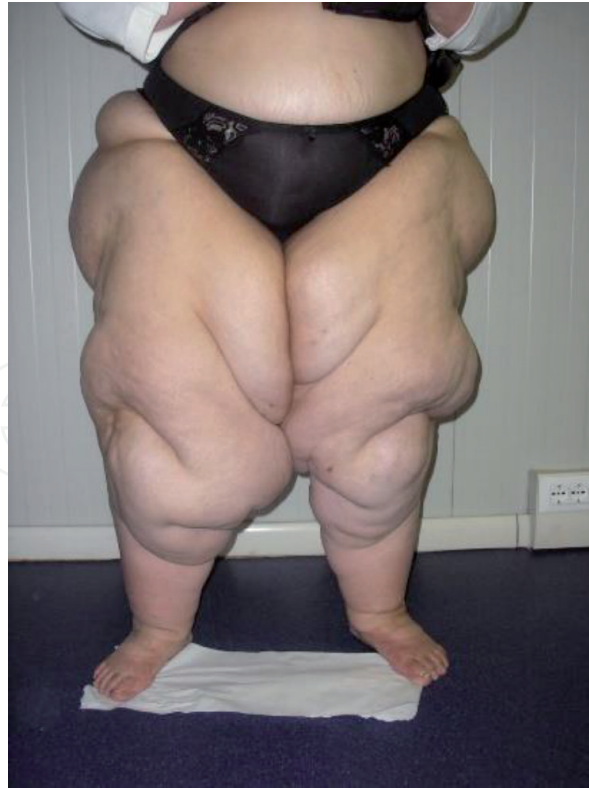Lipedema is a very common disease in the female population consisting predominantly of lipid cells that is established in certain specific anatomical districts. It has a familiar character with the male that results (as found in several pedigrees) in “healthy carrier.” In the lower limbs, the localization can be variable but always bilateral; it can be limited to the thighs, but it can also affect the gluteal regions, affecting only the legs, affecting the thighs and legs, or involving, in addition to these, the buttocks (**Figure 5**). The feet are always spared. Sometimes the arms and forearms are also affected, and hands are always spared. The edema is associated with constant pain, which becomes acute with the passing of the hours of the day and during the summer, and ease of spontaneous bruising [10–12, 29].

Edema, generally, appears at puberty and is exacerbated at some particular moments in a woman’s life (breastfeeding more than pregnancy and menopause). The edema appears simultaneously in all the regions of the affected limbs, and there is never a progression along the limbs (neither in the distal-proximal or proximal-distal sense) but only a possible simultaneous increase of the edematous zones. It is an edema that does not respond to hypocaloric dietary treatments or physical exercise.



**Figure 4.**  
*(a and b) Phlebolympheoedema: a case of prostate cancer with pelvic lymphadenectomy associated with venous left iliac thrombosis. (a) Clinical case and (b) phlebography of the lower limb.*





**Figure 5.**  
*Lipedema of the lower limbs.*

We recognize four clinical stages of the disease:

- **First stage:** Mild edema located in the sites already described in the possible combinations with conserved limb conformation. The skin presents slight and widespread increase in consistency.
- **Second stage:** Important edema involving the sites described in the possible combinations, with pain and gross deformations of some regions of the limbs. Increased skin of consistency.
- **Third stage:** Painful elephantiasis with extremely gross plication, alteration of the gait pattern, and possible cutaneous lesions, prevalent on the inner surfaces of the thighs. Occurrence of serotine foot edema or after prolonged standing station.
- **Fourth stage:** Painful elephantiasis with gross plication, alteration of the gait pattern, trophic lesions, and permanent edema of the feet (lipolymphedema).

The lymphoscintigraphy of lower limbs, in the early stages, shows a normal development and draining lymphatic circulation. In the advanced clinical stages of the disease, it is possible to underline bilateral sub-rotuleous stagnation of the tracer (dermal back flow) and lymph node stop that corresponds, from the clinical point of view, to the so-called lipolymphedema of the lower limbs.

High-resolution ultrasound allows to highlight a constant echogenic pattern of the supra-fascial compartment (skin-fascia). It is an extremely useful test for the differential diagnosis with lymphedema of the lower limbs. In lipedema, in fact, the compression of tissues with a linear probe shows a reduction in the sub-fascial thicknesses with the supra-fascial which remained unchanged; in the case of lymphedema, on the contrary, the compression with linear probe shows a decrease

in the over-fascial thicknesses, while the sub-fascial remain unchanged. This testifies that in lipedema the volumetric increase is given by an increased cellular component (hypertrophic and hyperplastic lipid cells) while in the lymphedema the volumetric increase is given by more or less copious presence of extracellular interstitial fluids that the pressure of the probe can move.

The BMI is variable in the two pathologies. In lipedema it is generally within the limits of the norm and is not minimally influenced by physical treatments nor by the overall weight loss. In lymphedema it can be equally variable even if it is higher on average than in patients with lipedema.

The differential diagnosis with obesity is quite simple. In the obese patients, the collection of fatty deposits is widespread in all the body regions with a particular preference for the anatomical areas typical of each sex (gynoid type and android type).

Obesity responds positively to physical exercises and diet, in all body districts, while lipedema is not affected at all by these factors.

## **2.7 Inflammatory or infectious states**

The edema of the lower limb can be determined by inflammatory and/or infectious diseases. In these cases the localization is generally monolateral and is secondary to an inflammatory/infectious process of the soft tissues (cellulitis, myositis, myofascitis, necrotizing fasciitis). The localization may involve only one area of the limb (thigh, leg, foot) assuming the topographic configuration of the “suspended edema.” Besides the edema, all the other characters of inflammation are generally present (increase in skin temperature, hyperemia, pain, and reduction of functional capacity (*functio laesa*). The resolution of edema is due, in these cases, to anti-inflammatory and pharmacological treatment and, if necessary, to antibiotics. A special case of edema that can induce doubts of differential diagnosis with deep vein thrombosis and that is determined by the presence of serous cyst of the popliteal cable is known as Baker’s cyst. Particularly developed, it can compress the surrounding venous and lymphatic vessels, inducing a distal edema (generally subpatellar) also extended to the whole leg and to the foot. With the treatment of cystic formation (puncture with evacuation, surgical excision, simple anti-inflammatory therapy), we are witnessing the resolution of the edema.

## **2.8 Benign or malignant neoplasms**

Benign or malignant tumoral formations may develop in the lower limbs, especially the soft tissues (mainly muscles). Their localization, particularly in the leg muscles, occupying space, also due to the compressive phenomena exerted on the surrounding vessels, can determine circumscribed or diffused edema which, for the differential diagnosis, must make use of more discriminating investigations, such as CT or MR. Obviously, the edema, in these cases, recedes only after surgical removal of the mass.

## **2.9 Systemic causes**

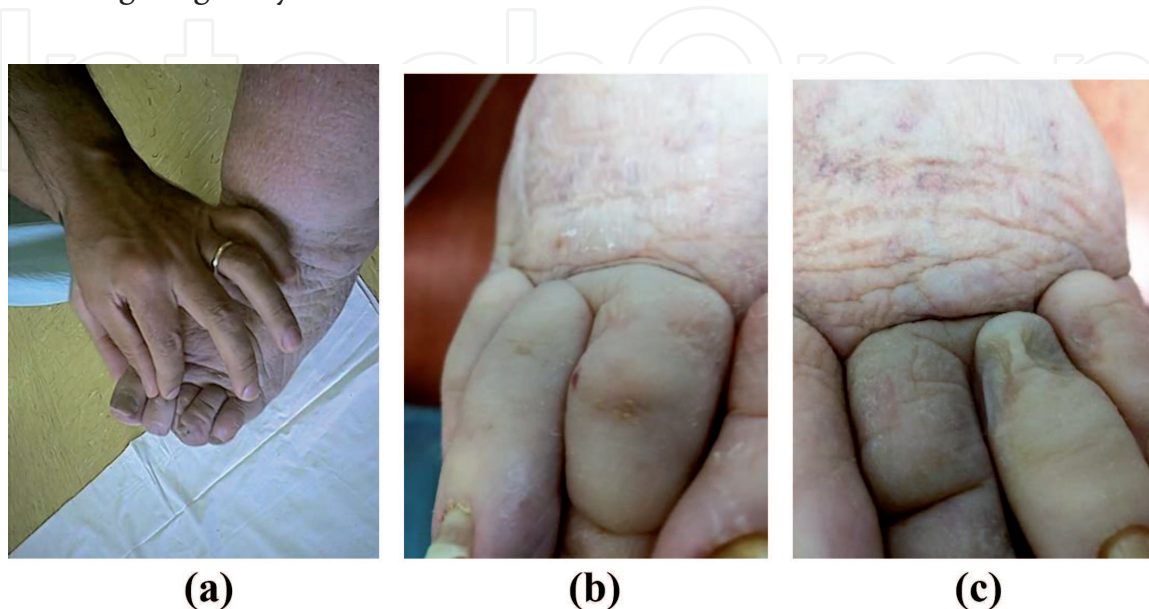
### *2.9.1 Edema in heart failure (from diastolic dysfunction)*

In the case of heart failure, the echocardiographic examination may be apparently normal (the ventricular ejection fraction, in these cases, provides normal indications, and no particular problems are highlighted). In these conditions, however, a careful clinical examination is required which highlights a bilateral and symmetrical lower limb edema (often confused with lymphedema); the sign of the fovea is particularly

evocable and persistent over time. The Stemmer sign is negative (**Figure 6**). The edema is established by an important increase in venous pressure in the microvascular tissue units, whereby the normal pressure gradient at the micro-tissutal level which, from the hydrostatic point of view, under normal conditions, would help the return of fluids from the interstitium towards the venous capillaries is gone and many water molecules remain in the interstitium. The thoracic auscultation demonstrates the presence of bilateral basal crackles. The liver may appear increased in volume and with rounded margins<sup>13</sup>. The subject refers to dyspnea for slight efforts or even at rest. During nocturnal rest the patient needs to observe a decubitus which raises the thorax and head with respect to the other bodily districts. In these cases, the dosage of the inactive form of the Brain Natriuretic Peptide (BNP, substance produced by the cardiac endothelium, whose serum concentration increases in the case of inability of filling by the cardiac chambers) results elevated, suggesting that the heart has difficulty in receiving fluids returning from the periphery (second- or third-degree diastolic dysfunction); this disfunctions are relatively frequent in women above 65 years. In these cases conventional draining physical therapies risk aggravating subjective and objective symptoms, and the same elastic garment to be worn in the morning should be prescribed only after the clinical compensation obtained with the appropriate dosage of diuretics and positive inotropic drugs (e.g., digoxin) indicated for each individual case.

### 2.9.2 Hepatic insufficiency

The edema of hepatic insufficiency can be defined as “gravitational”; it is collected mainly in the sloping body areas. It is essentially localized in the toes and feet when the subject is standing or sitting with the legs “dangling.” When the subject is lying on the bed, the most gravitational area is the presacral region<sup>14</sup>. It is not uncommon in these cases, if the patient holds a higher limb outside the bed, observe the edema at the level of the elbow of the arm itself. The conventional physical therapies, even in this case, do not solve the problem that benefits only from the administration of intravenous albumin. It is hypo-albumin, which in fact generates edema: since each protein molecule behaves like a kind of magnet to water molecules (it attracts them); in the case of hypo-albuminemia, liquids are no longer held within the intra-vascular compartment and tend to flee to interstitial space, following the gravity.



**Figure 6.**  
Stemmer sign: positive in lymphedema (a), negative in cardiac failure (b) before compression and (c) after compression.

### *2.9.3 Acute and chronic renal failure*

In chronic renal failure at third or fourth stage, the relative inability of the nephron to produce “pre-urine” inevitably leads to a generalized “water retention” affecting all body districts. The subject, frequently, in the morning wakes up with the edematous eyelids and only an adequate dosage of diuretics, respecting the values of the electrolytes and, above all, of the renal function (azotemia, creatinine). Decongestive physical treatments cannot find an elective indication even in this form.

### *2.9.4 Myxedema*

Myxedema is a particular form of edema affecting the lower limbs (generally bilaterally, symmetrically, and localized to the pretibial surfaces) determined by accumulation of mucopolysaccharides in the derma. In these cases, the pretibial edema is also accompanied by ocular edema (exophthalmos), with generalized dryness of the skin and, sometimes, psychic hypo-evolution [15]. It is determined by serious conditions of hypothyroidism (congenital or acquired), in which TSH (which, for various reasons, does not respond to the thyroid parenchyma) would stimulate tissue fibroblasts and adipocytes to replicate and produce mucopolysaccharide complexes, with local deposition inside the dermis, or, on the contrary, in cases of hyperthyroidism (as in Flaiani-Basedow’s disease). This type of edema is reversible and recognizes as a fundamental therapeutic treatment the correction of thyroid defect (in defect or excess of glandular function). It is presented as a “suspended edema,” not painful, and without local typical signs of inflammatory processes.

### *2.9.5 Drug edema*

Drug edema occurs, in most cases, by a particular idiosyncrasy of the subject to certain molecules. The drugs most commonly called into question in these forms are some molecules with antihypertensive effect (especially amlodipine and other calcium antagonists, in which the edema is localized mainly in the two ankles—bilateral edema—and in the back of the feet, and the sartanics that can induce generalized edemas, up to anasarca) and the corticosteroids which cause a generalized water retention. In all these forms, physical treatment is not conclusive, and the therapy consists in the simple suspension of the drug (with substitution with different molecules). In almost all the cases, the complete resolution of the clinical picture is achieved within a maximum of 7 days from the suspension of the drug.

### *2.9.6 Idiopathic edema*

Many authors are reminded of the possible presence of “idiopathic edema,” or an edema (generally distal and bilateral) that arises at certain times of the day (especially after prolonged standing) or in the summer season. It regresses with the wearing of the definitive elastic garment for a variable period of time.

### *2.9.7 Differential diagnosis of edema of the lower limbs*

The differential diagnosis of edema of the lower limbs can be easily formulated through simple observations concerning skin color, skin temperature, mono- or bilaterality localization, the presence of the sign of pitting, the presence of the Stemmer sign, the sense of progression of the edema along the limb, and the date

of onset of edema, compared to the time of observation. From a combined analysis of these elements, it is possible to easily reach the diagnosis that can be further confirmed by other exams, already described in the individual-treated paragraphs [4, 12, 30–36].

In particular, in relation to:

- **Skin color:** in the cardiac edema, it can appear bright pink up to taking on bluish-cyanotic nuances, in particular at the level of visible mucous. In the hepatic edema, it can assume a yellowish shade; in case of renal failure, it can appear “greenish.” In superficial venous root edema (acute varicophlebitis), it can be red to cyanosis. In the deep vein thrombosis edema, it generally maintains the rosy color that coincides with that of the healthy limb. Lipedema, myxedema, idiopathic edema and the drugs-related one keep rosy the complexion; instead the skin remains pale in primary or secondary lymphedema, tending to whitish, due to the rarefaction of the arteriolar capillaries which occurs in the tissue volumetric unit [39].
- **The cutaneous temperature** remains normal in cardiac, hepatic, renal, and idiopathic edema, in myxedema, lipedema, and drug-related edema. It remains normal also in deep vein thrombosis edema (except in cases where there is an important lymphatic overload of the superficial circle—with vicarious goals—that can cause a slight reduction of skin temperature in the affected limb compared to the contralateral one). In superficial venous root edema (varicophlebitis), the local temperature increases, while in lymphedema, primary or secondary, for the same reason for which the skin is whitish (except for concomitant acute lymphangitis), it is also characterized by a decrease in local temperature [37, 38].
- **Mono- or bilateral localization:** in all edemas of a “systemic” cause (cardiac, hepatic, renal, myxedema, drug-related), the localization is always bilateral and generally symmetrical. Also in lipedema it is bilateral. In lymphatic edema, both primary and secondary, localization can be both unilateral and bilateral. Idiopathic edema, superficial venous cause edema (varicophlebitis), and deep venous cause (deep venous thrombosis) are generally unilateral.
- **Pain:** in the “systemic” causes of edema, pain is generally absent, unless concomitant allergenic irritating spines coexist. In the edema caused by superficial varicophlebitis, often cyclical exacerbations are present. In the deep vein thrombosis edema, pain is not acute; it is deaf, not well definable from the anatomical point of view, and not epicritic, diffused to the interested limb. Pain is one of the peculiar characteristics of the clinical picture in lipedema. It is variable in various hours of the day being described as particularly important in the evening hours and in the summer season (obviously also depending on the clinical stage of the disease).
- **Pitting sign:** it is particularly present and persistent in the diastolic heart dysfunction edema, as in the typical edema of the hepatic insufficiency and in that of the renal insufficiency. It is present in myxedema, idiopathic edema, drug-related edema, and edema of superficial venous affections. It is generally absent in deep vein thrombosis. It is also fleeting and not very persistent in lymphatic edema, both primary and secondary, due to tissue fibrosis that more or less establishes in the tissues due to the persistence of interstitial protein component which induces fibrosis with consequent increase of tissue consistency

itself. In lipedema, in the early clinical stages, the pitting sign is absent (the volumetric increase is determined by the exclusive presence of hyperplastic and hypertrophic adipose cells and not to fluids in the interstitium). It can appear in the most advanced clinical stages (lipolymphedema) [39].

- **Stemmer's sign:** it is pathognomonic of lymphedema. It is in fact undetectable in all edemas that recognize a systemic cause, in idiopathic edema, and in lipedema (in which the feet are always spared from the edematous localization). In lymphedema, it is always present, and if it would be well-known by general practitioners and, unfortunately, also by many specialists, many unnecessary examinations (repeated echo color Doppler, Rx, high-resolution ultrasound, computed tomography, and MRI) would not be prescribed, looking for what is not recognized by simple clinical examination (it is of very frequent experience, even today). In the secondary forms of lymphedema of the lower limb, the Stemmer sign is initially negative and is only positively delayed [40].
- **Progression of edema along the limb:** in systemic edema and idiopathic edema as well as in primary lymphedema, the progression of edema in the lower limbs takes place in a distal-proximal direction (first the toes and the foot are affected and then the leg and, lastly, the thigh). In secondary lymphedema, on the contrary, the progression takes place in the opposite direction, in the proximal-distal direction (first the thigh is affected and then the leg and lastly the foot and the toes with consequent "late" positivity of the Stemmer sign). In Lipedema and myxedema, there is no progressive development of the edema itself, but this originates and increases simultaneously in all the body regions involved [41, 42].
- **Time of onset:** the time of onset of the edema is extremely variable. Cardiac edema occurs due to continuous pharmacological adjustments, especially diuretic therapy, generally given by months or years with alternating clinical intensity, as well as hepatic or renal edema. Drug-related edema appears after 1 to 3/4 days of taking the drug responsible for the side effect (an easily traced anamnestic data), and normally, as recalled, it reduces completely after the suspension of the drug. Lipedema generally appears at puberty (between 15 and 20 years of age) and may present clinical resurgence in particular moments of the woman's fertile life. Myxedema may arise at birth or develop in subsequent periods depending on thyroid glandular activity. Idiopathic edema generally occurs at puberty. Venous edema certainly occurs the most sudden, both in the superficial (varicophlebitis) and in the deep (deep vein thrombosis) form. In this last case, the edema appears absolutely fast and involves the whole limb from the level of localization of the thrombus in the deep vein. In these cases the appearance and evolution (proximal-distal) is almost immediate. From coincident arts we highlight the important edema within 6–12 h from the onset. The formation of the thrombus precedes the clinical evidence of the edema that only manifests when the dimensions of the thrombus hinders a large part of the habitual venous return [43–45].

### 3. Conclusions

The opinion that an edema of the lower limbs, regardless of the patient's age, of the general clinical conditions and symptoms and signs that accompany the picture,

is of a lymphostatic nature is still widespread today. So it happens that many cardiologists send to the angiologist or to the vascular surgeon patients over 70 years, with a fairly delineated symptom complex, albeit unidentified, with the diagnosis of “recent-onset limb lymphedema”; clinical cases that, if properly considered, are of strict cardiological relevance and not of physical rehabilitative medicine. Just as Lipedema is still unknown, as a pathology, by over 50% of the same vascular surgeons and of the angiology and by the overwhelming majority of family doctors [46].

The hemato-chemical and instrumental examinations are undoubtedly useful for a better definition of individual cases, both for the purposes of the therapeutic approach and the prognosis and monitoring.

However, the diagnosis must be essentially clinical and is based on the considerations described, simply by analyzing the individual objective and subjective parameters, between them, and crossing the information. Clinical experience can accelerate the diagnosis and the accuracy of the subsequent therapeutic approach, but it is fundamental, in any case, that before a definitive diagnosis, we consider the “semeiological picture” which, combined with an accurate clinical history, allows to reach the certainty of differential diagnosis.

Even today there are diagnostic mistakes in evaluation of many edema of the lower limbs. The lack of specific clinical experience and the underestimation of important anamnestic elements, supported by clinical evidence that often are not sought in the various details or, the misinterpretation of instrumental investigations can lead to inaccurate etiopathogenetic diagnoses with negative consequences from the point of view of treatment that is undertaken in the individual clinical case.

The proposed analysis aims at avoiding reckless or “discounted” clinical judgments, but not responding to the real needs of the individual patient, and helping the medical doctor, the physiotherapist, and the nurse to follow the most appropriate diagnostic and therapeutic procedures in line with the current principle prevention, early diagnosis, and treatment.

## **Conflict of interest**

The authors declare no conflict of interest.

IntechOpen

## **Author details**

Sandro Micheli<sup>\*</sup>, Alessandro Failla, Giovanni Moneta, Alessandro Fiorentino and Cardone Marco  
Department of Rehabilitation, S. Giovanni Battista Hospital, Rome, Italy

<sup>\*</sup>Address all correspondence to: [s.micheli@acismom.it](mailto:s.micheli@acismom.it)

## **IntechOpen**

© 2020 The Author(s). Licensee IntechOpen. This chapter is distributed under the terms of the Creative Commons Attribution License (<http://creativecommons.org/licenses/by/3.0>), which permits unrestricted use, distribution, and reproduction in any medium, provided the original work is properly cited. 

## References

- [1] Tiwari A, Cheng KS, Button M, Myint F, Hamilton G. Differential diagnosis, investigation, and current treatment of lower limb lymphedema. *Archives of Surgery*. 2003;**138**(2):152-161
- [2] Michelini S. Phlebolympoedema. From Diagnosis to Therapy. Bologna: Edizioni P.R.; 1998
- [3] Badini A, Fulcheri E, Campisi C, Boccardo F. A new approach in histopathological diagnosis of lymphedema: Pathophysiological and therapeutic implications. *Lymphology*. 1996;**29**(S):190-198
- [4] Gasbarro V, Michelini S, Antignani PL, Tsolaki E, Ricci M, Allegra C. The CEAP-L classification for lymphedemas of the limbs: The Italian experience. *International Angiology*. 2009;**28**(4):315-324
- [5] Lee B, Andrade M, Bergan J, Boccardo F, Campisi C, Damstra R, Flour M, Gloviczki P, Laredo J, Piller N, Michelini S, Mortimer P, Villavicencio JL. Diagnosis and treatment of primary lymphedema. Consensus Document of the International Union of Phlebology (IUP)-2009. *International Angiology*. 2010;**29**(5):454-470
- [6] International Lymph Framework. Best Practice for the Management of Lymphoedema. 2nd ed. 2012. Available at: [www.lympho.org](http://www.lympho.org)
- [7] The diagnosis and treatment of peripheral lymphedema: 2013 consensus document of the international society of lymphology. *Lymphology*; **46**(2013):1-11
- [8] Michelini S, Cardone M. Venolympatic vascular malformations: Medical therapy. In: Mattassi R, Loose DA, Vaghi M, editors. *Hemangiomas and Vascular Malformations*. Italia: Springer; 2015. pp. 445-450
- [9] Michelini S, Pissas A, Olszewski W, Dimakakos E, Cordero IF, Caldirola R, et al. Linforoll: A new device for lymphoedema treatment: Preliminary experience. *Lymphology*. 2015;**47**(Suppl):218-221
- [10] Mariani G, Campisi C, Taddei G, Boccardo F, Martini F, Rahimi Mansour A, et al. The current role of lymphoscintigraphy in the diagnostic evaluation of patients with peripheral lymphedema. *Lymphology*. 1998;**31**(Suppl):316-319
- [11] Cavezzi A, Michelini S. *PHlebolympoedema*. Bologna: Edizioni P.R; 1998
- [12] Nicolaides AN. Therapeutic outcome and quality of life in patients with chronic venous and lymphatic disorders. *Phlebolympology*. 2008;**20**:2-3
- [13] Schmeller W, Hueppe M, Meier-Vollrath I. Tumescant liposuction in lipoedema yields good long-term results. *The British Journal of Dermatology*. 2012;**166**:161-168
- [14] Schmeller W, Meier-Vollrath. Lipödem: Ein update (Lipedema: an update). *Lymphol Forsch Prax*. 2005;**9**(1):10-20
- [15] Forner-Cordero I, Szolnoky G, Forner-Cordero A, Kemény L. Lipedema: An overview of its clinical manifestations, diagnosis and treatment of the disproportional fatty deposition syndrome—Systematic review. *Clinical Obesity*. 2012;**2**:86-95
- [16] Pascual-Figal DA, Domingo M, Casas T, Gich I, Ordoñez-Llanos J, Martínez P, et al. Usefulness of clinical and NT-proBNP monitoring for



prognostic guidance in destabilized heart failure outpatients. *European Heart Journal*. 2008;**29**(8):1011-1018

[17] Younossi ZM, Guyatt G, Kiwi M, Boparai N, King D. Development of a disease specific questionnaire to measure health related quality of life in patients with chronic liver disease. *Gut*. 1999;**45**:295-300

[18] Schwartz KM, Fatourech V, Ahmed DDF, Pond GR. Dermopathy of Graves' disease (pretibial myxedema): Long-term outcome. *The Journal of Clinical Endocrinology & Metabolism*. 2002;**87**(2):438-446

[19] Bellini C, Arioni C, Mazzella M, Campisi C, Taddei G, Boccardo F, et al. Lymphoscintigraphic evaluation of congenital lymphedema of the newborn. *Clinical Nuclear Medicine*. 2002;**27**(5):383-384

[20] Boccardo F, Michelini S, Zilli A, Campisi C. Epidemiology of lymphedema. *Phlebolympology*. 1999;**26**:24-28

[21] Werngren-Elgstrom M, Lidman D. Lymphoedema of the lower extremities after surgery and radiotherapy for cancer of the cervix. *Scandinavian Journal of Plastic and Reconstructive Surgery and Hand Surgery*. 1994;**28**(4):289-293

[22] Campisi C, Michelini S, Boccardo F, Zilli A. Lymphedema epidemiology in Italy. *Lymphology*. 1998;**31**(Suppl):243-244

[23] Casley-Smith J. *Modern Treatment for Lymphoedema*. Adelaide: The Lymphoedema Association of Australia, Inc.; 1994

[24] Dellachà A, Fulcheri E, Boccardo F, Campisi C. Post-surgical lymphedema: Iatrogenic or pre-existing disease? *Lymphology*. 1998;**31**:562-565

[25] Földi E, Földi M. *Physiothérapie Complete Décongestive*. Paris: Editions Frison-Roche; 1993

[26] Leduc A. *Le drainage lymphatique*. Paris, Masson: Théorie et pratique; 1980

[27] Michelini S, Failla A, Moneta G, Campisi C, Boccardo F. Clinical staging of lymphedema and therapeutical implications. *Lymphology*. 2002;**35**:168-176

[28] Michelini S, Failla A. Linfedemi: Inquadramento diagnostico clinico e strumentale. *Minerva Cardioangiologica*. 1997;**45**(Suppl I): 11-15

[29] Tosatti E. *Lymphatique profonds et lymphoedèmes chroniques des membres*. Paris: Masson; 1974

[30] Vodder E. *La méthode Vodder—Le drainage lymphatique manuel*. DK-2880, Bagsvaer: Inst. For Lymph Drainage; 1969

[31] Olszewski W. Recurrent bacterial dermatolymphangioadenitis (DLA) is responsible for progression of lymphoedema. *Lymphology*. 1996;**29**(Suppl):331

[32] Michelini S, Campisi C, Failla A, Boccardo F. Proposal for stadiation of phlebolympoedema. *European Journal of Lymphology and Related Problems*. 1995;**6**(20):1-14

[33] Campisi C. Lymphoedema: Modern diagnostic and therapeutic aspects. *International Angiology*. 1999;**18**(1):14-24

[34] Case TC, Witte CL, Witte MH, Unger EC, Williams WH. Magnetic resonance imaging in human lymphedema: Comparison with Lymphangioscintigraphy. *Journal of Magnetic Resonance Imaging*. 1992;**10**:549-558

[35] Ferrel RE, Levinson KL, Esman JH, Komak MA, Lawrence EC, Barmada MM, et al. Hereditary lymphedema evidence for linkage and

- genetic heterogeneity. *Human Molecular Genetics*. 1998 Dec. 7;13:2073-2078
- [36] Michelini S, Failla A, Moneta G. Lymphedema: Epidemiology, disability and social costs. *Lymphology*. 2002;35:169-171
- [37] Michelini S, Failla A, Moneta G, Zinicola V, Romaldini PD. International classification of lymphedema functioning and disability evaluation. *European Journal of Lymphology*. 2007;17(51):16-19
- [38] Michelini S, De Giorgio D, Cestari M, Corda D, Ricci M, Cardone M, et al. Clinical and genetic study of 46 Italian patients with primary lymphoedema. *Lymphology*. 2012;45:3-12
- [39] Michelini S, Failla A, Moneta G, Cardone M, Michelotti L, Zinicola V, et al. Linee guida e protocolli diagnostico-terapeutici nel linfedema. *Eur. Med. Phys.* 2008;44(Suppl. 1-3)
- [40] Michelini S, Failla A, Moneta G, Zinicola V, Macaluso B, Cardone M, et al. Treatment of lymphedema with shockwave therapy: Preliminary study. *The European Journal of Lymphology and Related Problems*. 2007;17(51):29
- [41] Michelini S, Failla A, Moneta G, Cardone M, Fiorentino A. Immunostimulation and reduction of infective complications in patients with lymphoedema. *European Journal of Lymphology and Related Problems*. 2009;20(56):17-18
- [42] Partsch H. Indirect lymphography in different kinds of leg oedema. In: *Lymphology: Advances in Europe*. Ecig: Genova; 1989. pp. 95-99
- [43] Pecking AP, Cluzan RV. Assessment of lymphatic function: 15 years experience using radionuclide methods. *Lymphology*. 1994;27(Suppl):301-304
- [44] Schingale FJ. Lipoedema. In: Schingale FJ, editor. *Lymphoedema, Lipoedema: A Guide for those Effected*. Hannover: Schlütersche; 2003. pp. 64-71
- [45] Trévidic P, Marzelle J, Cormier JM. Apport de la microchirurgie au traitement des lymphoedèmes. In: *Editions Techniques -Encycl. Méd. Chir. Paris, France: Techniques chirurgicales-Chirurgie vasculaire*; 1994 F.a. 43-225
- [46] Földi M. The therapy of lymphedema. *European Society of Lymphology*. 1993-1994;14:43-49