

We are IntechOpen, the world's leading publisher of Open Access books Built by scientists, for scientists

5,000

Open access books available

125,000

International authors and editors

140M

Downloads

Our authors are among the

154

Countries delivered to

TOP 1%

most cited scientists

12.2%

Contributors from top 500 universities

**WEB OF SCIENCE™**Selection of our books indexed in the Book Citation Index
in Web of Science™ Core Collection (BKCI)

Interested in publishing with us?
Contact book.department@intechopen.com

Numbers displayed above are based on latest data collected.

For more information visit www.intechopen.com

Vasculitis and Vasculopathies

*Ana Paula Urzedo, Mariane Martins Manso
and Thaisa Macarini de Faria*

Abstract

Our organism, as complex as it is, needs a giant vascular network to deliver nutrients to all cells, so vasculopathies and vasculitis are diseases present in all medical specialties. The skin and subcutaneous cellular tissue are irrigated by a vast vascular network, with cutaneous involvement related to these frequent pathologies. These can be restricted to the integumentary system or be part of systemic diseases with cutaneous manifestations, which make them of great interest to dermatologists. They can affect any caliber of vessels and present with several dermatological manifestations such as erythema, livedo reticularis, palpable purpura, nodules, ulcers, urticaria, hemorrhagic blisters, gangrene and other manifestations that can be isolated or associated with systemic signs and symptoms. However, there is no worldwide consensus regarding the classification of vasculitis, and the classification proposed in this chapter is based on the International Chapel Hill Conference Nomenclature of Vasculitides 2012, which is based on the size of the vessels. The purpose of this chapter is to compile a review of the most current treatments for these conditions.

Keywords: vasculitis, lymphocytic, cutaneous small vessel, systemic vasculitis, leukocytoclastic, cutaneous, vascular diseases

1. Introduction

Vasculitis and vasculopathies are a group of diseases that course with an inflammatory process, which attacks vascular endothelium of vessels of different calibers. Usually, they course with dermatology lesions, the diagnosis is difficult, and they have a few treatment options. Despite that, an early diagnosis can contribute to a better quality of patient's life and prevent further complications (**Figure 1**) [1].

2. Methods

The authors performed a bibliographic review from cutaneous vasculitis and vasculopathies from literature, including online academics platforms such as PubMed and Google Scholar and dermatology books as Rivitti and Fitispack. The keywords used from this chapter were cutaneous vasculitis, Takayasu arteritis, Giant Cell Arteritis, Polyarteritis Nodosa, Kawasaki Disease, Microscopic polyangiitis, Granulomatosis with Polyangiitis (Wegener's), Eosinophilic Granulomatosis with Polyangiitis (Churg-Strauss), Cryoglobulinemic Vasculitis, Urticaria Vasculitis, Henoch-Schönlein, Behçet's syndrome, Cutaneous leukocytoclastic angiitis, cutaneous vasculopathies,

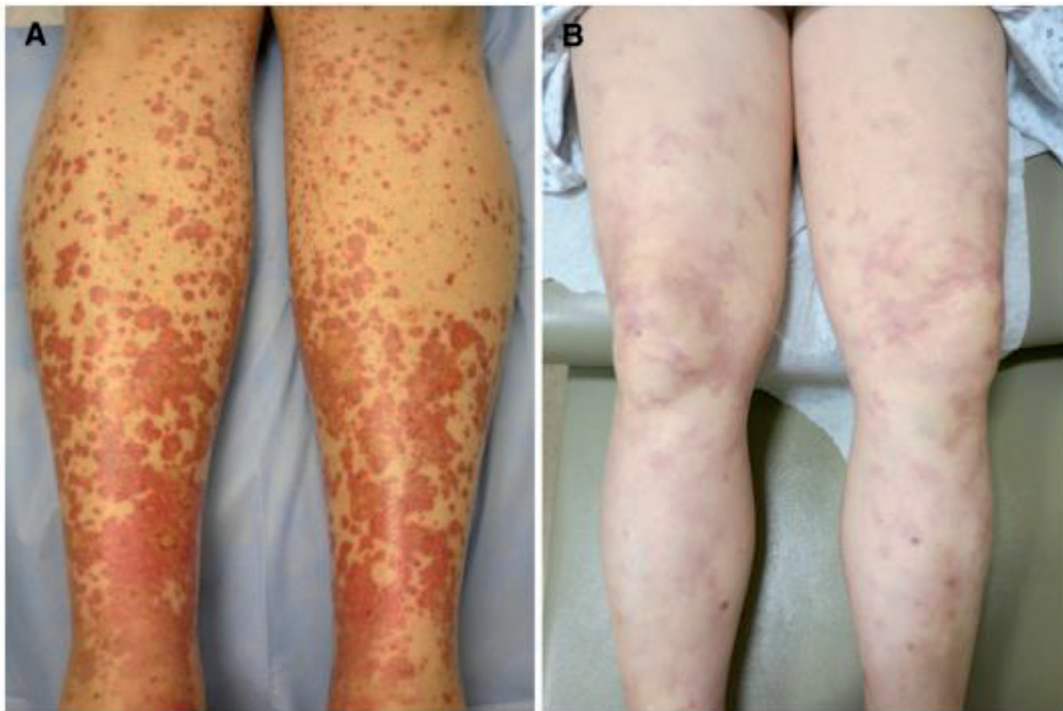

Figure 1.

Purpuric macules and papules coalescing into patches (A) in small vessel vasculitis and fixed livedo reticularis and subcutaneous nodules (B) in medium vessel vasculitis (polyarteritis nodosa) [2].

Phospholipid Antibody Syndrome, Blue Finger Syndrome, Acrocyanosis and others. The final objective was summing up the dermatology vasculitis and vasculopathies and helping physicians in early diagnosis and treatment.

3. Cutaneous vasculitis

Cutaneous vasculitis may affect vessels of different calibers, especially small and medium in the skin and the subcutaneous tissue, resulting in just a small cutaneous lesion until serious systemic commitment. Nevertheless, the classification is not a consensus. In general, they are classified using clinical criteria, size of the vessels, histopathological exams, laboratorial findings and etiologic agents [3, 4]. In 2012, the *Chapel Hill Consensus Conference (CHCC)* proposed a new classification from the most used since 1994, removing many eponymous. The classification is a strategic pillar to help choose the right path to lead these patients through the right treatment [4, 5] (**Table 1**).

3.1 Large vessel vasculitis

3.1.1 Takayasu arteritis

It is a large vessel vasculitis whose etiologic agent is unknown. It is more frequently found in young Asiatic women, in the proportion from 5 to 12 W:1 M, and usually affects the aorta and its main branches. It is not a rare disease but is not as usual as arteritis of giant cells. The diagnosis is usually late because these patients develop many collateral arteries, they have nonspecific symptoms and the development of these affections is very slow. Pregnancy in patients affected by Takayasu arteritis is a troubling problem because it affects women of childbearing age, and it will cause risks to the mother and the child. The arteritis could be associated with Crohn's and rectocolitis disease [6].

	Classification	Diseases
1	Large vessel vasculitis	Takayasu arteritis Giant cell arteritis
2	Medium vessel	Polyarteritis nodosa Kawasaki disease
3	Small vessel vasculitis ANCA-associated vasculitis	Microscopic polyangiitis Granulomatosis with polyangiitis (Wegener's) Eosinophilic granulomatosis with polyangiitis (Churg-Strauss)
4	Small vessel vasculitis Immune complex	Antiglomerular basement membrane disease Cryoglobulinemic vasculitis (CV) Hypocomplementemic urticarial vasculitis (anti-C1q vasculitis) IgA vasculitis (Henoch-Schönlein)
5	Variable vessel vasculitis	Behçet's syndrome Cogan's syndrome
6	Single-organ vasculitis	Cutaneous leukocytoclastic angiitis Cutaneous arteritis Primary central nervous system vasculitis
7	Vasculitis associated with systemic disease	Lupus vasculitis Rheumatoid vasculitis Sarcoid vasculitis Others
8	Vasculitis associated with probable cause	Hepatitis C virus-associated CV Hepatitis B virus-associated vasculitis Syphilis-associated aortitis Drug-associated immune complex vasculitis Drug-associated ANCA-associated vasculitis Cancer-associated vasculitis Others

Table 1.
 2012 International Chapel Hill Consensus Conference Nomenclature of Vasculitides [3].

The more effective treatments are oral corticosteroids, but there are many relapses when corticosteroids taper. High doses of corticosteroids (40–60 mg/day of prednisone or equivalent) should be initiated immediately after the diagnosis to induce remission. During disease remission, it is necessary sparing the drug until 15-20mg/day for two or three months, and after a year decrease the doses to 10mg/day or less. The immunosuppressive agents are used as corticoid sparing agents such as methotrexate, azathioprine, leflunomide, mycophenolate mofetil and cyclophosphamide [6]. There are evidences that biological agents such as anti-TNF-alpha, tocilizumab and rituximab could be effective in refractory cases, but more trials are necessary to evaluate the effectiveness of these drugs [8]. In addition, patients with ischemic problems need endovascular interventions. The mortality range is between 3 and 21% [6].

3.1.2 Giant cell arteritis (GCA)

It is a systemic vasculitis of large vessels, with tropism to the aorta and its branches, mainly external carotid. It is a most common vasculitis in above 50-year-olds and affects more women than men (3 W:2 M). The corticosteroids are the most common therapeutic used in these cases. In the beginning, we need high doses of corticosteroids to control the inflammation, and then it could be used sparingly

until controlled in the patient. These strategies are valid for simple and complicated forms of the disease [7].

Simple form is defined by cephalic isolated symptoms with visual disturbance or changes in central nervous system. Nowadays, the gold standard treatment is oral prednisone or equivalent 40–60 mg/day, and methylprednisolone is not used anymore. The initial dose recommended is 0.7 mg/kg day of prednisone and the maximum dose is 80 mg/day [7].

The complicated form is defined when there is an ophthalmologic or a central nervous or extracephalic complication, mainly aorta and its branches. In these cases, methylprednisolone in pulses of 500 mg⁻¹ g a day shall be used for 1 to 5 consecutive days. During maintenance, some authors believe in doses less than 5 mg/day. The American Society of Ophthalmology recommends pulses of intravenous methylprednisolone, when patients have ophthalmologic symptoms, but the Rheumatology Society prefers oral corticosteroid [7].

It is strategic to introduce corticosteroid-sparing drugs when the disease course is lasting long. Methotrexate is the most used treatment and with more evidence levels. There are four trials with methotrexate as a sparing drug, but the doses and the management are variable from 7.5–15 mg/week [7].

Cyclophosphamide has demonstrated effectiveness in patients dependent on corticosteroids or resistant to treatment. It is necessary to give more than 20 mg/day for 6 months or 10 mg/day for 1 year or more. The dose from 500 mg/m² or 500 mg/injection in 6 courses is standard from 5 months on average. It is highly important to warn patients of several side effects such as bone marrow suppression [7].

Azathioprine therapy has less controlled studies. Some studies showed a modest improvement. Hydroxychloroquine, an antimalarial synthetic drug, was tested also. One French study divided patients into two groups: one took prednisone 0.7 mg/kg/day in the beginning associated with hydroxychloroquine (400 mg/day) and the control group just received prednisone and placebo. The group that had hydroxychloroquine and corticoid had usually stopped later the prednisone and they had more relapses [7].

Nowadays, one option is biologics medicines. Anti-TNF-alpha does not have enough studies that showed control of the disease with this class of medication [7]. Tocilizumab, a humanized antibody that blocked membranous and soluble receptors of IL-6 (IL-6R), is a current option since IL-6 is implicated in the etiopathogenesis of this affection. Three main studies evaluated the efficacy of the drug, although the therapeutics was different between these studies [7, 8].

A randomized control trial with 30 patients had tested 20 patients receiving corticoids and tocilizumab (8 mg/kg every 4 week during a year), and 10 received corticoids and placebo. The survival without relapses during a year was highest in patients treated with tocilizumab. However, there are no data available after the medication was stopped [7, 8].

Another promising biotherapy is abatacept. This medication with corticoids could decrease the risk of relapses, although more data is necessary to corroborate this hypothesis.

Ustekinumab, a subunit against anti-p40 IL-12/23 targeting Th1 and Th17 responses, has been showing similar side effects as corticoids. Some patients, who had refractory disease, have been treated with anakinra and they achieved success. Anakinra is a biopharmaceutical drug that blocks IL-1. All patients who had taken the drug had shown improvement in inflammation biomarkers and/or in their symptoms, with the disappearance of arterial inflammation in PET/CT. More studies are necessary though [7].

Other pharmacological drugs can be used as adjuvant treatments such as anti-platelets and anticoagulants, but there is no official recommendation about these

drugs in the treatment of GAC. The statins do not influence the evolution of the disease, but they are used to prevent cardiovascular risk. Furthermore, these drugs could have an anti-inflammatory role via the inhibition of TH17 pathway [7].

3.2 Medium vessel vasculitis

3.2.1 Polyarteritis nodosa (PAN)

It is a rare necrotizing systemic vasculitis that affects small- and medium-sized vessels and is not usually associated with ANCA [8, 9], although there are reports in the literature of patients with PAN and positive ANCA. Several treatments are suggested for this condition, and the control is still a challenge [9].

Cutaneous involvement and peripheral nerves are the favorite sites of the disease, cutaneous and gastrointestinal vasculitis have specific histopathological characteristics, and until now, it has no development glomerulonephritis described. Gastrointestinal tract involvement is common and is one of the predictors of disease morbidity and mortality. There is cutaneous PAN without systemic involvement, and it very rarely progresses to the systemic form of the disease. According to the new classification, PAN is subdivided into idiopathic PAN and hepatitis B-associated PAN [9].

Treatment of PAN is usually based on the combination of systemic corticosteroids and immunosuppressants. The most commonly used medications are cyclophosphamide, azathioprine, methotrexate or mycophenolate mofetil [9].

The use of biological medications is reserved for cases of refractory PAN without association with hepatitis B. The use of rituximab, an anti-CD20 monoclonal antibody, has not been formally indicated for patients with PAN, but its use is supported in patients with ANCA-associated vasculitis. There are case reports using anti-TNF-alpha, such as etanercept and infliximab, and tocilizumab, but only in refractory cases [8].

3.2.2 Kawasaki disease (DK)

It is a systemic vasculitis, common in male child, with fever, rash, non-exudative bilateral conjunctivitis, oral and pharyngeal mucosal erythema, cervical lymphadenopathy, and it can affect the extremity. They may have fewer common symptoms such as pyuria, meningitis, shock and retropharyngeal or parapharyngeal abscess [10].

The etiology of Kawasaki disease is unknown. The diagnosis of Kawasaki disease is based on the presence of fever for ≥ 5 days, along with the presence of at least 4 of the 5 main clinical features [10] (**Table 2**).

Clinical features	
1	Erythema and cracking of the lips, strawberry tongue and/or pharyngeal and oral mucosa erythema
2	Bilateral bulbar conjunctival injection without exudate
3	Rash
4	Erythema and edema of the hands and feet in the acute phase and/or periungual scaling in the subacute phase
5	Cervical lymphadenopathy (≥ 1.5 cm in diameter), usually unilateral

Table 2.
Clinical features in Kawasaki disease [10].

Patients who have met the diagnostic criteria are considered to have complete Kawasaki disease (also referred to as typical or classic Kawasaki disease). Patients who do not have enough major clinical findings can be diagnosed with incomplete Kawasaki disease [10].

Intravenous immunoglobulin (IVIG) is the basis for treatment. Usually, it is initiated before 10 days of fever and significantly reduces coronary artery aneurysms (CAAs) that decrease from 25% to less than 5%. Around 10–30% of patients are resistant to IVIG treatment [10].

Unfortunately, in some cases, IVIG is discontinued or administered at a reduced dose due to cost. Evidence for therapies beyond IVIG is limited, with no evidence-based recommendations for the management of patients with resistance to initial IVIG treatment.

In the initial treatment, if the patient is in the acute phase treatment, aspirin (30–50 to 80–100 mg/kg/day) and IVIG (2 g/kg) are recommended. The treatment of patients with resistance (persistent or recurrent fever after the end of IVIG after 24 hours) is to initiate IVIG 2 g/kg, associated to corticosteroids and/or infliximab [10, 11].

The use of corticosteroids is controversial due to the cardiovascular risk in prolonged use.

Anti-TNF-alpha is also recommended for patients with coronary artery aneurysms, and in the minority of cases, it can be used in patients without aneurysms. Other therapies possible are anti-interleukin 1, canakinumab and cyclosporine [11].

3.3 Small vessel vasculitis (SVV)

3.3.1 Microscopic polyangiitis

Microscopic polyangiitis is an ANCA-associated vasculitis with significant morbidity and mortality. Treatment follows the same protocol as granulomatosis with polyangiitis [12].

3.3.2 Granulomatosis with polyangiitis (Wegener's)

It is another necrotizing systemic vasculitis that affects small and medium vessels and is often associated with ANCA. It occurs in patients between 45 and 60 years old from both genders and is rarely observed in Negroids. The main features are the involvement of the upper and lower respiratory tract and the kidneys. Ears, nose and throat may develop with sinusitis and crusted rhinorrhea that are usually severe. Pulmonary nodules and renal involvement with crescent glomerulonephritis can be seen [13, 14].

It is a serious disease, and if left untreated, it almost always progresses to death. With the advent of new therapies, 90% of patients evolve to remission and the survival rate is 80% in 10 years. The first phase, known as the induction phase, aims to put the patient into remission, and it lasts between 3 and 6 months according to the clinical response. The second phase is known as the maintenance phase trying to consolidate the first phase and prevent relapses. It lasts from 12–24 months [13] (**Figure 2**).

In induction, prednisone 1 mg/kg is recommended. For severe forms, methylprednisolone pulse is indicated at doses of 7.5–15 mg/kg/day for 1–3 consecutive days. After 3–4 weeks of treatment, the corticosteroid dose is gradually decreased, but without reaching doses of less than 15 mg/day until 4th month. The combination of two immunosuppressants in the induction phase is essential for severe or refractory patients such as cyclophosphamide or rituximab.

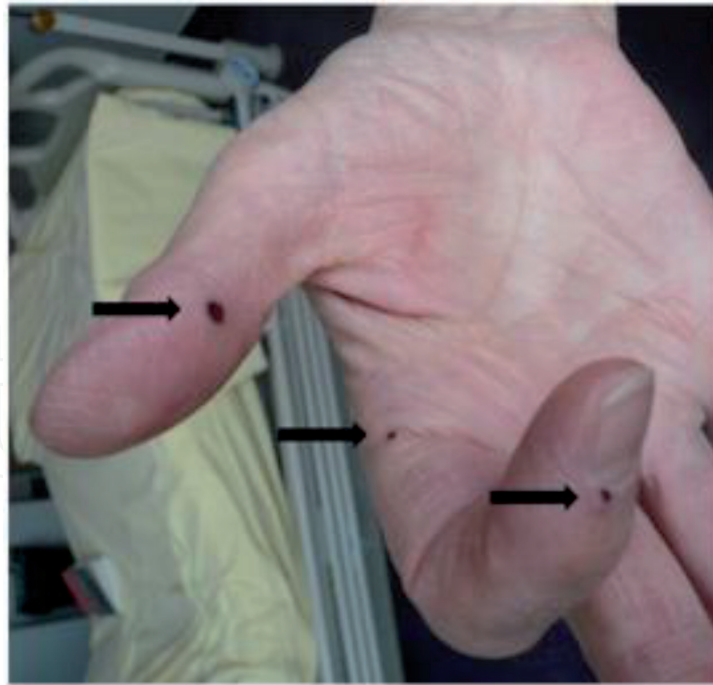


Figure 2.
Necrotic vascular purpura (black arrows) of the upper limbs in granulomatosis with polyangiitis-Wegener's [13].

Cyclophosphamide is preferred if rapid renal failure occurs at a dose of 600 mg/m^2 (maximum 1.2 g/bolus) every 2 weeks for 1 month (day+1, day+15, day+30) and then 700 mg/m^2 every 3 weeks until remission (average of 6–9 cycles in total). The dose can be adjusted for age and renal function (500 mg/m^2 in the presence of renal failure and 500 mg fixed dose every 3 weeks—maximum 6 bolus) [13, 14].

Rituximab is the choice for pregnant women or patients who have failed cyclophosphamide or have relapsed. It is used at a dose of 375 mg/m^2 per week for 4 weeks. Plasmapheresis may be used in severe forms of the disease with severe renal involvement ($\text{Cr} > 500 \mu\text{mol/L}$) or alveolar hemorrhage. Also, corticosteroid therapy can be associated with immunosuppressants [13, 14].

For localized or not very severe cases, methotrexate ($20\text{--}25 \text{ mg}$ per week) is an option. The AGATA study demonstrated efficacy of abatacept (1 mg/kg IV on day+1, day+29 and then once per month) combined with prednisone and an immunosuppressant (azathioprine, methotrexate or mycophenolate mofetil) for recurrent and limited forms.

Maintenance lasts between 18 and 24 months after remission has been achieved. Corticosteroids may be combined with azathioprine (2 mg/kg/day) or methotrexate ($20\text{--}25 \text{ mg/week}$) [13].

Treatment with sulfamethoxazole/trimethoprim ($400/800 \text{ mg}$) is given to prevent relapse from *Pneumocystis jirovecii* infection. Patients should be vaccinated following the regional schedule and is contraindicated live virus vaccines [13]. *Staphylococcus aureus* was the most identified pathogen in positive cultures, and it is important to remember that it also deserves prevention [14].

3.3.3 Eosinophilic granulomatosis with polyangiitis (Churg-Strauss)

Eosinophilic granulomatosis polyangiitis (EGPA), also known as Churg-Strauss disease, is characterized by patients with asthma, eosinophilia and necrotizing vasculitis with extravascular eosinophilic granulomas that affect small and large vessels. It is a vasculitis associated with ANCA (neutrophilic cytoplasmic antibodies) and

the rarest vasculitis within the group of ANCA-associated vasculitis, and that is why there are no highly recommended treatments based on the literature [15].

Corticosteroids are usually used to induce remission of the disease as well as immunosuppressants, for example cyclophosphamide in more severe cases. Long-term maintenance of immunosuppressants is used to prevent disease recurrence, but their long-term efficacy is discussed. Azathioprine has been recommended as maintenance therapy. The efficacy of mepolizumab, an anti-IL5 monoclonal antibody, has been recommended for these patients alone or in combination with corticotherapy. Others monoclonal anti-IL5, reslizumab and benralizumab drugs are still being studied. Studies suggest that rituximab may be effective in EGPA. Other drugs such as IFN- α appear to be effective in remission induction and maintenance; however, the safety profile restricts their use. Drugs such as anti-IgE (omalizumab) are used to control asthma, but their effects are unknown in the treatment of vasculitis. High doses of immunoglobulin have also been used to induce disease remission with good results. Intravenous immunoglobulin may be effective in treating residual peripheral neuropathy [15].

3.4 Immune complex SVV

3.4.1 Cryoglobulinemic vasculitis

Cryoglobulins are cold precipitated immunoglobulins that can cause vasculitis and vasculopathy. Type I cryoglobulins are responsible for 10–15% of symptomatic vasculitis cases and are related to malignant hematological disorders such as myeloma, B-cell lymphoma or undetermined monoclonal gammopathy (MGUS). Mixed cryoglobulins correspond to 80–85% of cases and are associated with infectious diseases, especially chronic hepatitis C, B-cell malignancies and autoimmune diseases such as Sjögren's syndrome and lupus. Vasculitis is most associated with mixed cryoglobulins. Women are affected more than men 2:1 [12].

In symptomatic patients with cryoglobulinemia type I, it is indicated to treat the hematologic basis diseases. Lymphomas require a combination of chemotherapy and myeloma treatment with drugs such as bortezomib, thalidomide, lenalidomide and other alkylating agents. Bone marrow transplantation can be performed in patients with cryoglobulinemia-associated myeloma. MGUS can be treated with the same myeloma drugs; however, rituximab has been the drug of choice. Plasmapheresis may be used for patients with severe renal involvement or extensive lower limb necrosis. Avoiding exposure to cold is essential [12].

Mixed cryoglobulins, usually hepatitis C-associated cryoglobulinemic vasculitis, are well-treated as suppression of hepatitis C replication occurs. Studies reported between 2011 and 2013 associated with pegylated interferon (PegIFN) and ribavirin for 12 months achieved a 50–60% control response to hepatitis C. The introduction of antiviral agents dramatically changed cryoglobulinemia-associated vasculitis. They promote shorter treatment without the need for interferon and with responses greater than 95% associated with few adverse effects. The drugs used are sofosbuvir, simeprevir, ledipasvir and daclatasvir, that can be associated with ribavirin. In some cases of more severe vasculitis, low doses of rituximab and other immunosuppressants may be used in selected cases. Rituximab targets B-cell populations that produce cryoglobulins and treats severe vasculitis [12] (**Figure 3**).

3.4.2 Urticaria vasculitis

The term urticaria vasculitis is used for plaques of urticaria that present leukocytoclasia on histopathological examination. It is a clinical pathological diagnosis,

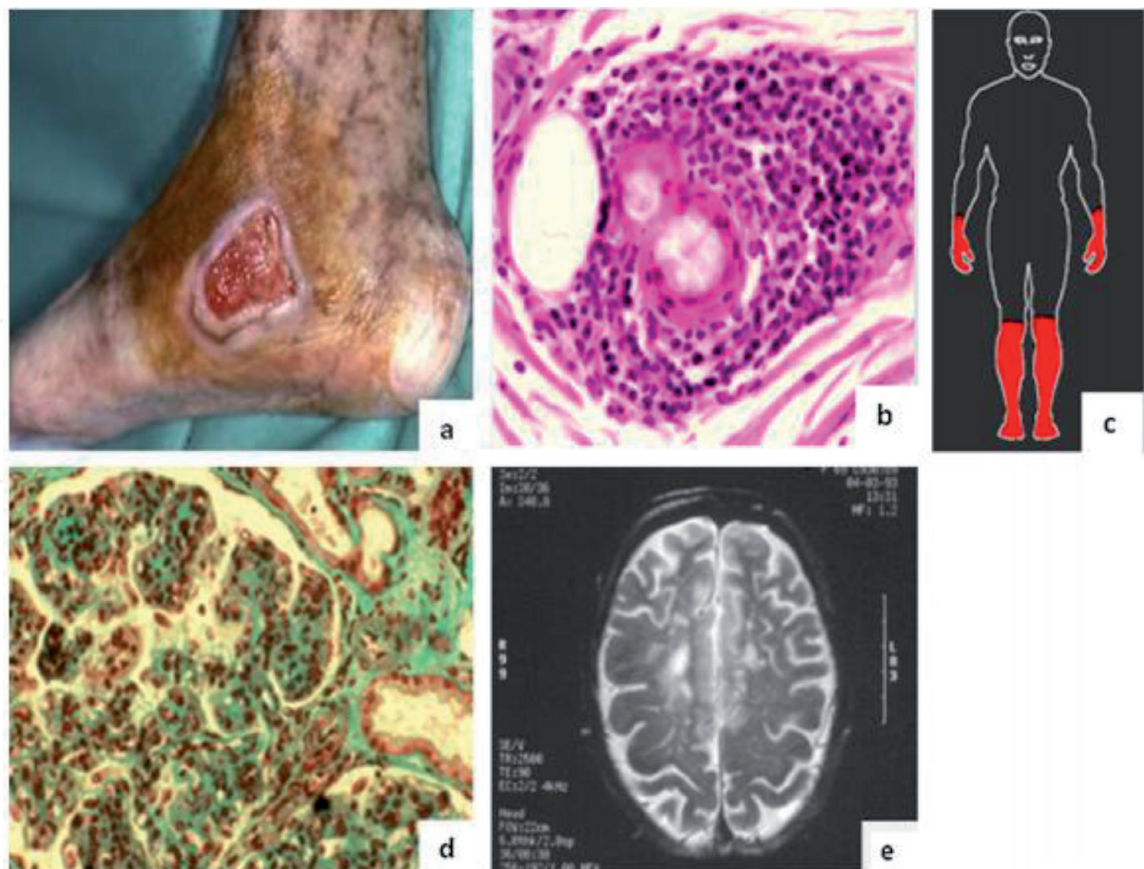


Figure 3.
Clinical manifestations of cryoglobulinemic vasculitis; (a) severe skin ulcer; (b) nerve biopsy specimen showing vasculitis with a perivascular inflammatory infiltrate; (c) distribution of the peripheral neurological involvement indicating length dependency; (d) renal biopsy showing membranoproliferative glomerulonephritis; (e) magnetic resonance imaging of the brain showing vasculitis [12].

characterized by a skin inflammation of the dermis capillaries and postcapillary venules, with a range of clinical signs from hives picture to a well-established vasculitis. Like any vasculitis, it can affect the skin and other organs, including skeletal, pulmonary, renal, gastrointestinal, cardiac and ophthalmic systems. The disease is spectral, ranging from mild to severe [16, 17].

Related etiological factors are infections, medications, autoimmune reactions, malignancies or idiopathic reasons. It can be classified as normocomplementemic or NUV that presents normal levels of complement, usually not with systemic involvement, and hypocomplementemic or HUV that has low complement levels and may have systemic involvement [17].

The treatment of vasculitis urticaria is a challenge, and there are no guidelines for the management of this disease. There are reports in the literature of the use of hydroxychloroquine and colchicine, which are as effective as systemic corticosteroids [16, 18].

Immunosuppressive drugs are used such as azathioprine, mycophenolate mofetil or cyclophosphamide. Rituximab with the usual doses also seems to have a good response. To manage the symptoms, sedative and nonsedating antihistamines may be used if urticaria is prominent. However, it is not usually effective. Nonsteroidal anti-inflammatory drugs are very useful in these cases such as naproxen, indomethacin and ibuprofen [13, 16].

Another alternative therapy is to combine corticosteroids up to 1 mg/kg and another immunosuppressant (methotrexate, mycophenolate mofetil, azathioprine, cyclosporine and very rarely cyclophosphamide). Recent reports include rituximab, anakinra, canakinumab and omalizumab as therapeutic arsenal [17].

3.4.3 Immunoglobulin A vasculitis (*Henoch-Schönlein purpura*)

It is the most common small vessel vasculitis of childhood, with a predominance of IgA deposits. Typically, it involves the skin, intestines and glomeruli and may be associated with arthralgia and/or arthritis. In most patients, only supportive treatment is required and analgesia [19, 20]. The disease regresses spontaneously most often within 4 weeks, but in some cases, it may last for more than 6 weeks [19]. In these cases, the therapeutic options may be dapsone (on average 1–2 mg/kg) or colchicine, but there are still no randomized controlled trials with the optimal dose and duration of treatment [18, 21]. Some patients require treatment with systemic corticosteroids, such as nephritis, orchitis, cerebral vasculitis, pulmonary hemorrhage and severe gastrointestinal involvement [19].

Other therapies used are the addition of cytotoxic immunosuppressants, intravenous immunoglobulins and plasmapheresis [20]. In case of severe rectal pain or abdominal pain, the use of systemic corticosteroids is recommended [19, 20].

The recommended doses for prednisolone are 1–2 mg/kg/day for 1–2 weeks followed by weaning. In severe cases, it is possible also to use methylprednisolone pulses 10–30 mg/kg maximum 1 g/day for 3 consecutive days. Corticosteroid prophylaxis to decrease the chance of developing nephritis is not indicated. There is evidence showing that the use of angiotensin-converting enzyme inhibitors (ACE inhibitors) may have beneficial effects in patients with proteinuria. In patients with proteinuria longer than 3 months, regardless of whether they are receiving prednisone or another immunosuppressive drug, the use of ACE inhibitors or angiotensin receptor blockers is recommended to prevent and/or limit secondary glomerular injury. The first choice for mild nephritis treatment is prednisolone. If proteinuria persists, azathioprine, mycophenolate mofetil, cyclosporine or other corticosteroid-sparing treatment can be started. Also, IV methylprednisolone pulses can be considered.

In the treatment for moderate nephritis, the first line is oral, or IV prednisolone, or IV methylprednisolone. Azathioprine, mycophenolate mofetil IV or cyclosporine may be used according to renal histopathological findings [19].

The treatment for severe nephritis however is high doses of corticosteroids and IV cyclosporine to induce remission, and low doses of corticosteroids associated with azathioprine or mycophenolate mofetil as maintenance treatment [19].

3.5 Variable vessel vasculitis

3.5.1 *Behçet's syndrome*

Behçet's syndrome has been known since ancient times and was described by Hippocrates, but it was reported as a separate disease by Huluci Behçet in 1937. It is currently classified as a vasculitis belonging to the subgroup of variable vessel vasculitis. It was initially reported in countries bordering the silk route, but nowadays, it is found all over the world. The most common manifestation is oral aphthosis and is seen in over 90% of cases [22].

It is characterized by progressing multiple attacks and remissions. The duration of remission may vary from one attack to another and from one system to another. The attack, in most cases, is followed by a complete recovery called *Restitutio ad Integrum* of the tissue. A good example is oral aphthosis, and it is exceptional to see a scar. In case of oral aphthosis, it is uncommon to have a scar. In other organs such as the eyes, central nervous system and vascular system, we usually observe sequelae, which may even progress to death. In these cases, aggressive treatment is mandatory [22].

Treatment will vary depending on systemic involvement. Mucocutaneous manifestations do not require aggressive treatment, only topical treatment. Arthritis goes on with outbreaks and remissions, which can last from weeks to months, but usually respond well to nonsteroidal anti-inflammatory drugs (NSAIDs). Usually, the remission in these cases is long and the patient may discontinue the medication. There is usually no progression to destruction and deformities [22, 23].

Treatment of the gastrointestinal tract depends on the severity. For other manifestations, aggressive treatments are often required, starting with cytotoxic/immunomodulatory drugs associated with corticotherapy. Eventually, biological drugs are used such as apremilast [23].

When the patient suffers from eye involvement, infliximab or adalimumab anti-TNF drugs may be considered as first- or second-line therapies, or in the exacerbation of pre-existing disease. The European League first recommends corticosteroid-associated azathioprine therapy in all patients with subsequent involvement and the addition of cyclosporine or infliximab, or switching to interferon alfa with or without corticosteroids in patients with severe involvement as more than two drop lines in visual acuity on a 10/10 scale and/or retinal disease (retinal vasculitis or macular involvement) [23]. Other biological drugs are being studied such as IL-1 and IL-6 blockers [8].

Intravitreal use of fluocinolone acetonide also has been suggested in refractory cases. In these cases, the increased intraocular pressure and infections should be monitored. With the higher cause of morbidity and mortality, it is vascular involvement. It can affect arteries and veins of any caliber, and with various presentations such as thrombosis, occlusions and aneurysms. Immunosuppressive therapy is one of choices in these cases and there is no consensus regarding anticoagulants [23].

A retrospective multicenter study demonstrated a decrease in relapse in immunosuppressant versus untreated patients. Behçet-associated Budd-Chiari syndrome has a high mortality rate, and monthly cyclophosphamide pulses associated with corticosteroid therapy are the treatment of choice. Anti-TNF- α was used in 5 patients with refractory disease. Two of these patients already had terminal liver disease during infliximab administration and died due to liver failure. Two patients were successfully treated with infliximab and the fifth patient was stable with etanercept but had dural sinus thrombosis during follow-up [23].

3.6 Single-organ vasculitis

3.6.1 Cutaneous leukocytoclastic angiitis

Cutaneous leukocytoclastic angiitis is an inflammation of small vessels, characterized by an inflammatory infiltrate associated with leukocytoclasia by neutrophil fragmentation and fibrinoid necrosis in small vessel postcapillary venules. It is the most common histological type of cutaneous vasculitis and usually is idiopathic, although antibiotics are also linked [24]. It is often clinically manifested by a palpable purpura, which is found anywhere on the body, but usually affects more lower limbs and can cause arthralgia [24, 25].

Several symptomatic treatments may be proposed to patients: analgesics, nonsteroidal anti-inflammatory drugs and antihistamines. For chronic or persistent vasculitis, dapsone and/or colchicine may be effective. The use of colchicine in the treatment is beneficial through its effect on reducing neutrophil chemotaxis, blocking leukocyte adhesion and stabilizing lysosomal membranes. Colchicine at a dose of 0.6–1.8 mg/day induces resolution within 1–2 weeks, according to several authors [18].

The best indication for colchicine is in moderate severity vasculitis. It is an effective and inexpensive treatment that can be used alone or in combination. However, its prescription is sometimes limited because of its gastrointestinal side effects [18].

In cases of severe skin necrosis and/or systemic manifestations, systemic corticotherapy (prednisolone or prednisone 20–60 mg/d) with progressive weaning may control the situation in some cases. For patients with systemic manifestations, initial therapy should include high doses of corticosteroids and/or cyclophosphamide. Intravenous immunoglobulins may be useful in the treatment of severe and refractory disease in patients who have a contraindication to traditional immunosuppressive therapy [26].

Other drug-associated vasculitis, autoimmune diseases or even infectious diseases require treatment of the underlying disease. In some cases, systemic corticosteroid therapy is necessary, and corticosteroid-sparing immunosuppressive drugs and even intravenous immunoglobulin may be required [26].

4. Cutaneous vasculopathies

Vasculopathies are diseases that present a hyperactivity of blood vessels in the skin with systemic repercussions, but of unknown etiology. They are usually classified as diseases with circulatory disorders such as acrocyanosis, livedo reticularis, Raynaud's phenomenon, erythromelalgia, vessel occlusion leading to necrosis such as atherosclerosis obliterans, Buerger's disease, lymphocyte-mediated inflammatory changes such as livedoid vasculitis, malignant atrophic papulosis and neutrophil-mediated inflammatory changes such as pyoderma gangrenosum. Below, the most common representatives will be discussed [27].

4.1 Antiphospholipid antibodies syndrome (APS)

Antiphospholipid antibodies syndrome or Hughes syndrome is a systemic, autoimmune disease in which there are repeat thrombotic events, repeated fetal losses and positive autoantibodies such as anticardiolipin and lupus anticoagulant. As skin manifestations, ulcerations and livedo reticularis are the most common signs [27, 28]. Some authors relate Sneddon's syndrome, which is a disease with strokes and livedo reticularis, as a spectrum of APS [29]. Libman-Sacks endocarditis in systemic lupus erythematosus patients also has an accumulation of antiphospholipid antibodies in the subendothelial layer of the heart valves. However, the correlation with APS is not well established [30].

For patients with a diagnosis of APS, treatment as well as prophylaxis is required. However, there are patients who have met the diagnostic criteria but with no thrombotic events. In these patients, behavioral changes such as smoking and alcohol cessation, lipid control, diabetes management and nonuse of exogenous estrogens are the most important measures [27].

Avoiding prolonged immobilizations and other behaviors that predispose to thrombotic events is also recommended. Some authors advocate the use of aspirin without scientific consensus [28].

Primary prophylaxis with low-dose aspirin prophylaxis is usually prescribed to prevent thrombosis in women with recurrent miscarriages, but it does not prevent deep vein thrombosis in men with APS. In systemic lupus and secondary APS, hydroxychloroquine has been proven to have a protective effect against thrombosis, as well as a reduction in cholesterol and glycemia. Patients who undergo surgery and require prolonged immobilization require prophylactic heparinization, and in APS,

sometimes doses should be higher than usual due to resistance to anticoagulant effects. For treatment, as initial therapy, unfractionated heparin or low molecular weight heparin is used. Warfarin may also be used [28].

Because patients with APS and thrombosis are at high risk for recurrent thromboembolism episodes, prolonged oral anticoagulant therapy is the best option for attempting to prevent further episodes. The most used oral anticoagulant is warfarin with a therapeutic goal of maintaining INR greater than or equal to 3 [31].

In cases of APS secondary to the underlying systemic disease, it should not open the treatment with systemic oral corticoid. Other agents that can be used are plasmapheresis, immunoglobulin and dapsone, among others [27].

In refractory and catastrophic cases that there is multiple organ infarction, anticoagulation combinations, steroids, plasmapheresis, intravenous immunoglobulin and fish oil derivatives can be used. Fibrinolytic agents have no proven benefit [28].

In case of pregnancy, the best alternative during this period is heparin associated with low doses of aspirin. Combined treatment is more effective to prevent miscarriages than just aspirin alone. Unfractionated heparin, low molecular weight heparin (enoxaparin 40 mg/day) and dalteparin 5000 UI/day can be used during this period. Warfarin should not be used in pregnant women. Accidental discovery of antiphospholipid antibodies during pregnancy, with no clinical history of problems such as thromboembolic events or systemic lupus erythematosus, does not require treatment [28].

4.2 Blue finger syndrome

It is a sudden cutaneous manifestation in which the fingers, especially the toe, develop cyanotic and painful character. The priority etiology is embolic, but there may be other causes such as rheumatologic and neoplastic, among others. Treatment for this condition depends on the treatment of the underlying disease. However, general and local care such as limb warm-up, physical protection, treatment of secondary infections are essential [32].

4.3 Acrocyanosis

Acrocyanosis is a disease resulting from chronic vasospasm that causes reflex vasodilation in the affected extremities, usually by medication or central nervous system disorders. It may be painful, cold, discolored, hyperhidrosis, paresthesia and even tingling. Like for blue finger syndrome, treatment is only supportive [27].

4.4 Erythromelalgia

Erythromelalgia is characterized by vasodilation of the extremities, especially in male children, and is usually associated with limb warm-up, pain and burning. It is believed that there is some change in calcium channels, so therapy is directed toward this focus.

In the case of primary erythromelalgia, anesthetics, antiarrhythmics, anticonvulsants and even oral magnesium may be used. In the case of secondary erythromelalgia, besides the treatment already discussed, the underlying disease needs to be controlled [27].

Its treatment includes topical drugs like 5% lidocaine and 0.075% capsaicin. For oral medications, we have amitriptyline 10 mg/day, gabapentin 900–1800 mg/day, pregabalin 75 mg/day, flecainide 200 mg/day and buflomedil 200–330 mg/day. Tricyclic antidepressants, selective serotonin reuptake inhibitors and, in selected cases, acetylsalicylic acid, beta blockers and calcium channel antagonists may be excellent associations. In refractory cases, we may use epidural infusions of opioids,

bupivacaine and, in the latter case, sympathectomy. However, responses are quite variable and complete remission of symptoms is rarely observed [27, 33].

4.5 Livedo reticularis

Reticular livedo is a common dermatological manifestation in which the limb in question suffers a vasospasm and has a cyanotic, erythematous and erythematous-violet coloration. When the blood plot does not have a confluent pattern, it is called a racemose livedo. In clinical practice, it may be isolated by cold or trauma or may be associated with some systemic diseases such as lupus erythematosus, scleroderma and HIV. Although it is more common in the limbs, it can also affect the trunk and there may be ulcerations. Cold stimulates vasospasm, when the cause is removed, however, over time, vessels may become permanently dilated and become permanently telangiectatic [27, 34].

The treatment of livedo, primarily, is protection against the cold. Vasodilators may be an alternative and corticosteroids should be avoided as much as possible. If there are ulcerations or a racemose livedo associated with antiphospholipid antibody syndrome, anticoagulation is recommended. When livedo is associated with some underlying disease, the management of the disease usually improves its manifestation. Other medications may be tried such as danazol, tissue plasminogen activator (tPA), pentoxifylline and antiplatelets. Immunosuppressants such as azathioprine and sympathectomy are reserved for refractory cases [27, 34, 35].

4.6 Raynaud's phenomenon

It is a paroxysmal vasospastic disorder characterized by the simultaneous alternation of pallor (vasoconstriction), cyanosis (blood stasis) and redness (compensatory vasodilation).

We consider Raynaud's disease (20% of the cases) when it occurs primarily and not associated with other acne. And we consider Raynaud's phenomenon (80%) when it occurs secondary to another disease [27].

Treatment consists of treating the basic disease and quitting smoking. Protection against the cold is necessary to avoid triggering the frame. In idiopathic forms, the use of nifedipine 30–120 mg/day can be used. Other treatment modalities may also be employed such as topical nitroglycerin, iloprost, losartan, serotonin receptor inhibitors, phosphodiesterase inhibitors, n-acetylcysteine, botulinum toxin, bosentan, platelet inhibitors and fibrinolytics. In refractory cases, sympathectomy may be performed [27].

4.7 Erythema pernio or perniosis

Perniosis is a rare panniculitis that develops with painful erythematous-violaceous nodules in young people more susceptible to cold. There is also a certain uncertain relationship with tobacco. Treatment, like other cold-related conditions, requires protection from the cold such as appropriate clothing, gloves, socks, boots and smoking cessation. Behavior changes and topical corticoid creams can help to heal the lesions. Some vasodilators may also be applied as nicotinic acid, nifedipine and pentoxifylline. In refractory cases, sympathectomy and UVB phototherapy may also be considered [36].

4.8 Livedoid vasculitis or Millian's white atrophy

Livedoid vasculitis is one of the most common vasculopathies, described in 1929, and can affect up to about 5% of the healthy population, reaching 70% in patients

with venous ulcers. Some authors differentiate livedoid vasculitis from Millian's white atrophy in relation to etiology. Livedoid vasculitis is persistent livedoid reticularis associated with an ulcer [37]. White atrophy is a white atrophy scar with a stellar pattern most common in the lower limbs of women aged 30–60 years that may or may not be associated with collagenases and neoplasia; however, the best-established link is with chronic venous insufficiency [35].

The treatment for this disease is divided into some of the following groups:

- Vasodilators such as nifedipine [27, 35].
- Drugs stimulating endogenous fibrinolytic activity such as danazol, the activating factor of recombinant tissue plasminogen, rt-PA, low dose alteplase, associated or not with heparin and aspirin [27, 35].
- Drugs such as dipyridamole, cilostazol, the thienopyridine group (clopidogrel, ticlopidine hydrochloride, whether associated with aspirin) and sarpogrelate.
- Hemorheological drugs that decrease blood viscosity, increase red blood cell flexibility and improve circulation. From this group, the example is pentoxifylline and buflomedil hydrochloride [27, 35].
- Modulating lymphocyte response therapy as systemic PUVA phototherapy [27].
- Other drugs such oral corticosteroids, intravenous immunoglobulin, cyclosporine, hyperbaric oxygen therapy and intravenous iloprost [27].

For patients with any associated thrombophilia, warfarin, unfractionated heparin, low molecular weight heparin and even heparin minidoses may also be used [27].

4.9 Atherosclerosis obliterans

It is a chronic disease associated with diabetes that gradually occludes the vessel light. It affects the feet more than the hands in patients over 50 years. There is no specific treatment, but oral corticosteroids may be employed associated with diabetes with strict disease control. Behavioral change with diabetes mellitus improvement and antibiotic therapy, if secondary injuries, is the therapy of choice. Vasodilators do not have their proven efficiency. In severe cases, sympathectomy and vascular surgery may be used [38].

4.10 Thromboangiitis obliterans (Buerger's disease)

The priority treatment is smoking cessation and rest. Iloprost IV may be an alternative to retard evolution. In many cases, amputation is required, with excision of the gangrenous fingers, sympathectomy and surgeries such as arterialization of the venous arch of the foot. The vascular surgeon is extremely important for follow-up [27, 39].

4.11 Malignant atrophic papulosis (Köhlmeier-Degos disease)

Malignant atrophic papulosis (MAP) is an obliterating endovasculitis of small- and medium-sized arteries that produces tissue infarction as its main feature. It is considered an uncommon disease of unknown cause and can affect the skin, gastrointestinal tract and central nervous system, and the involvement of these last two systems can be fatal [40].

There is no fully effective treatment for the disease. Some authors use acetylsalicylic acid (300 mg daily) and/or dipyridamole (75 mg twice daily) as the first therapeutic modality, which facilitates blood perfusion. Other therapeutic options such as aspirin, heparin and warfarin can be used, however, aspirin is more associated with resurgence of lesions when discontinuing the drug [41].

More recently, studies have been conducted using eculizumab that have shown initial efficacy in skin and intestinal lesions, but the drug has not been able to prevent the development or progression of systemic manifestations. Subcutaneous treprostinil has been successfully tested in some cases with dramatic and sustained improvement in clinical status, although the response was not immediate. The mechanism of action of treprostinil in this scenario is not yet well understood [42, 43].

The use of corticosteroids, chloroquine or other immunosuppressants has proved unsatisfactory and has great potential to worsen the disease by unknown mechanism; therefore, they are not indicated [43].

4.12 Superficial thrombophlebitis

These are vascular inflammations with thrombus formation and consequent occlusion or may occur due to slow flow within a varicose vein. If thrombophlebitis is found in apparently normal superficial veins, attention should be paid to the possibility of underlying malignancy, thrombosing coagulopathy and silent deep vein thrombosis [44].

For therapeutic management, in cases of limited superficial thrombophlebitis below the knee, without evidence of deep vein thrombosis, compression by specific stockings and the use of nonsteroidal anti-inflammatory drugs are enough, providing symptomatic relief. However, if there is deep venous thrombosis or extension to the saphenofemoral or saphenopopliteal junctions, prophylactic use of low molecular weight heparin may be necessary [44].

5. Conclusion

Vasculitis and vasculopathies are a challenge physicians face on a daily basis. Due to rarity of the diseases all over the globe, the scientific community is not able to perform studies with a great number of patients and biological medications seem to be the promise to a cure or the disease control. These groups of drugs are relatively new and still expensive in most countries. Furthermore, more studies need to be developed and long follow-ups should be performed before they are considered gold-standard treatment. In the medical reality nowadays, despite any consideration, an early diagnosis can change the whole disease course and prevent disabilities, and even without cure, it is indispensable to control symptoms and provide a better quality of life to patients.

IntechOpen

Author details

Ana Paula Urzedo^{1,2*}, Mariane Martins Manso^{1,3,4} and Thaisa Macarini de Faria^{5,6,7}

1 Dermatology, BWS Institute, Brazil

2 Cosmiatry, Faculdade de Medicina do ABC and Hospital Albert Einstein, Brazil

3 Faculdade de Medicina do ABC, Brazil

4 Health Administration, Fundação Getulio Vargas, Brazil

5 Faculdades Integradas da União Educacional do Planalto Central, Brazil

6 Clinical Dermatology, Instituto BWS, Brazil

7 Cosmiatry, Instituto Superior de Medicina, Brazil

*Address all correspondence to: apurzedo.71@gmail.com

IntechOpen

© 2020 The Author(s). Licensee IntechOpen. This chapter is distributed under the terms of the Creative Commons Attribution License (<http://creativecommons.org/licenses/by/3.0>), which permits unrestricted use, distribution, and reproduction in any medium, provided the original work is properly cited. 

References

- [1] Radic M, Radic J. Updates in the Diagnosis and Treatment of Vasculitis. London: IntechOpen; 2013. Available from: <https://www.intechopen.com/books/updates-in-the-diagnosis-and-treatment-of-vasculitis/vasculitis-and-vasculopathy-in-rheumatic-diseases>
- [2] Micheletti RG. Cutaneous vasculitis in rheumatologic disease: Current concepts of skin and systemic manifestations. *Clinics in Dermatology*. 2018;**36**(4):561-566. Available from: <https://www.ncbi.nlm.nih.gov/pubmed/30047438> [Accessed: 13 July 2019]
- [3] Caproni M, Verdelli A. An update on the nomenclature for cutaneous vasculitis. *Current Opinion in Rheumatology*. 2019;**31**(1):46-52. Available from: <https://www.ncbi.nlm.nih.gov/pubmed/30394939> [Accessed: 17 July 2019]
- [4] Ortiz-Sanjuán F, Blanco R, Hernández JL, Pina T, González-Vela MC, Fernández-Llaca H, et al. Drug-associated cutaneous vasculitis: Study of 239 patients from a single referral center. *The Journal of Rheumatology*. 2014;**41**(11):2201-2207. Available from: <https://www.ncbi.nlm.nih.gov/pubmed/25225278> [Accessed: 17 July 2019]
- [5] Sunderkötter CH, Zelger B, Chen KR, Requena L, Piette W, Carlson JA, et al. Nomenclature of cutaneous vasculitis: Dermatologic addendum to the 2012 revised International Chapel Hill Consensus Conference Nomenclature of Vasculitides. *Journal of the German Society of Dermatology*. 2018;**70**(2):171-184. Available from: <https://www.ncbi.nlm.nih.gov/pubmed/29136340> [Accessed: 13 July 2019]
- [6] Seyahi E. Takayasu arteritis: An update. *Current Opinion in Rheumatology*. 2017;**29**(1):51-56. Available from: <https://www.ncbi.nlm.nih.gov/pubmed/27748689> [Accessed: 17 July 2019]
- [7] Watelet B, Samson M, de Boysson H, Bienvenu B. Treatment of giant-cell arteritis, a literature review. *Modern Rheumatology: Japanese Journal of Rheumatology*. 2017;**27**(5):747-754. Available from: <https://www.ncbi.nlm.nih.gov/pubmed/27919193> [Accessed: 13 July 2019]
- [8] Krusche M, Ruffer N, Kötter I. Tocilizumab treatment in refractory polyarteritis nodosa: A case report and review of the literature. *Rheumatology International*. 2019;**39**(2):337-344. Available from: <https://www.ncbi.nlm.nih.gov/pubmed/30465270> [Accessed: 13 July 2019]
- [9] Alibaz-Oner F, Koster MJ, Crowson CS, Makol A, Ytterberg SR, Salvarani C, et al. Clinical spectrum of medium-sized vessel vasculitis. *Arthritis Care & Research*. 2017;**69**(6):884-891. Available from: <https://www.ncbi.nlm.nih.gov/pubmed/27564269> [Accessed: 13 July 2019]
- [10] Li Y, Yang Q, Yu X, Qiao H. A case of Kawasaki disease presenting with parotitis: A case report and literature review. *Medicine*. 2019;**98**(22):e15817. Available from: <https://www.ncbi.nlm.nih.gov/pmc/articles/PMC6708832/> [Accessed: 13 July 2019]
- [11] Dionne A, Burgner D, De Ferranti S, Singh-Grewal D, Newburger J, Dahdah N. Variation in the management of Kawasaki disease. *Archives of Disease in Childhood (ADC)*. 2019:317191. Available from: <https://www.ncbi.nlm.nih.gov/pubmed/31196912>
- [12] Desbois AC, Cacoub P, Saadoun D. Cryoglobulinemia: An update in 2019. *Joint, Bone, Spine*. 2019;**86**(6):707-713. Available from: <https://www.ncbi.nlm.nih.gov/pubmed/31196912>

[nih.gov/pubmed/30731128](https://pubmed.ncbi.nlm.nih.gov/30731128/) [Accessed: 13 July 2019]

[13] Comarmond C, Cacoub P. Granulomatosis with polyangiitis (Wegener): Clinical aspects and treatment. *Autoimmunity Reviews*. 2014;**13**(11):1121-1125. Available from: <https://www.ncbi.nlm.nih.gov/pubmed/25149391>. [Accessed: 13 July 2019]

[14] Jennette JC, Nachman PH. ANCA glomerulonephritis and vasculitis. *Clinical Journal of the American Society of Nephrology*. 2017;**12**(10):1680-1691. Available from: <https://www.ncbi.nlm.nih.gov/pubmed/28842398> [Accessed: 13 July 2019]

[15] Furuta S, Iwamoto T, Nakajima H. Update on eosinophilic granulomatosis with polyangiitis. *Allergology International*. 2019;**68**(4):430-436. Available from: <https://www.ncbi.nlm.nih.gov/pubmed/31266709> [Accessed: 13 July 2019]

[16] Younger DS, Carlson A. Dermatologic aspects of systemic vasculitis. *Neurologic Clinics*. 2019;**37**(2):465-473. Available from: <https://www.ncbi.nlm.nih.gov/pubmed/30952419> [Accessed: 13 July 2019]

[17] Davis MDP, Hilst, JCVD. Mimickers of urticaria: Urticarial vasculitis and autoinflammatory diseases. *The Journal of Allergy and Clinical Immunology: In Practice*. 2018;**6**(4):1162-1170. Available from: <https://www.ncbi.nlm.nih.gov/pubmed/29871797> [Accessed: 13 July 2019]

[18] Robinson KP, Chan JJ. Colchicine in dermatology: A review. *Australasian Journal of Dermatology*. 2018;**59**(4):278-285. Available from: <https://www.ncbi.nlm.nih.gov/pubmed/29430631>. [Accessed: 17 July 2019]

[19] Ozen S, Marks SD, Brogan P, Groot N, de Graeff N, Avcin T, et al. European

consensus-based recommendations for diagnosis and treatment of immunoglobulin A vasculitis: The SHARE initiative. *Rheumatology*. 2019;**58**(9):1607-1616. Available from: <https://www.ncbi.nlm.nih.gov/pubmed/30879080> [Accessed: 13 July 2019]

[20] Mauro A, Mauro S, Rega R, Martemucci L, Sottile R. Successful treatment of hemorrhagic bullous Henoch-Schonlein purpura with intravenous immunoglobulins. *Pediatric Dermatology*. 2019;**36**(1):e34-e36. Available from: <https://www.ncbi.nlm.nih.gov/pubmed/30561101> [Accessed: 13 July 2019]

[21] Roman C, Dima B, Muyschont L, Schurmans T, Gilliaux O. Indications and efficiency of dapsone in IgA vasculitis (Henoch-Schonlein purpura): Case series and a review of the literature. *European Journal of Pediatrics*. 2019;**178**(8):1275-1281. Available from: <https://www.ncbi.nlm.nih.gov/pubmed/31230197> [Accessed: 13 July 2019]

[22] Davatchi F. Behçet's disease. *International Journal of Rheumatic Diseases*. 2018;**21**(12):2057-2058. Available from: <https://www.ncbi.nlm.nih.gov/pubmed/30681276> [Accessed: 17 July 2019]

[23] Ozguler Y, Hatemi G. Management of Behçet's syndrome. *Current Opinion in Rheumatology*. 2016;**28**(1):45-50. Available from: <https://www.ncbi.nlm.nih.gov/pubmed/26555450> [Accessed: 17 July 2019]

[24] Cakiter AU, Kucuk OS, Ozkaya DB, Topukcu B, Onsun N. Demographic characteristics, aetiology, and assessment of treatment options in leukocytoclastic vasculitis. *Postepy Dermatologii I Alergologii*. 2017;**34**(2):104-109. Available from: <https://www.ncbi.nlm.nih.gov/pmc/articles/PMC5420600/> [Accessed: 13 July 2019]

- [25] Gambichler T, Kulik MA, Skrygan M, Rooms I, Höxtermann S. Cutaneous leukocytoclastic vasculitis: The role of lymphocytes and related immune markers. *Postępy Dermatologii I Alergologii*. 2017;**34**(4):299-305. Available from: <https://www.ncbi.nlm.nih.gov/pmc/articles/PMC5560176/> [Accessed: 11 June 2019]
- [26] Aounallah A, Arouss A, Ghariani N, Saidi W, Sriha B, Denguezli M. Cutaneous leukocytoclastic vasculitis: About 85 cases. *The Pan African Medical Journal*. 2017;**26**:138. Available from: <https://www.ncbi.nlm.nih.gov/pubmed/28533861> [Accessed: 17 July 2019]
- [27] Rivitti EA. *Dermatologia: De Sampaio e Rivitti*. 4ª ed. São Paulo: Artes Médicas; 2018:527-564
- [28] Santamaria JR, Badziak D, Barros MFD. Síndrome antifosfolípide. *Anais Brasileiros de Dermatologia*. 2005;**80**(3):225-239. Available from: <http://www.scielo.br/pdf/abd/v80n3/v80n3a02.pdf> [Accessed: 17 July 2019]
- [29] Dutra LA, Braga-Neto P, Pedroso JL, Barsottini OGP. Sneddon's syndrome: Case report and review of its relationship with antiphospholipid syndrome. *Revista Einstein*. 2012;**10**(2):230-232. Available from: <https://journal.einstein.br/pt-br/article/sindrome-de-sneddon-relato-de-caso-e-revisao-sobre-a-relacao-com-a-sindrome-do-anticorpo-antifosfolipidio/> [Accessed: 12 July 2019]
- [30] Brito FA, Tófani MLMC, Tófani FA, Kakehasi AM, Lanna CCD, Carvalho MAP. Libmann-sacks endocarditis and oral anticoagulation. *Arquivos Brasileiros de Cardiologia*. 2004;**82**(4):378-380. Available from: http://www.scielo.br/scielo.php?pid=S0066-782X2004000400009&script=sci_arttext [Accessed: 12 July 2019]
- [31] Criado PR, Rivitti EA, Vasconcellos C, Valente NYS, Martins JEC. Cutaneous manifestations of thrombophilia. *Anais Brasileiros de Dermatologia*. 2008;**83**(6):491-506. Available from: <https://core.ac.uk/download/pdf/37453598.pdf> [Accessed: 17 July 2019]
- [32] Reis PEO. Síndrome do dedo azul. *Jornal Vascular Brasileiro*. 2005;**4**(4):391-393. Available from: <http://www.scielo.br/pdf/jvb/v4n4/v4n4a16.pdf> [Accessed: 17 July 2019]
- [33] Leroux MB, Carbo E. Revisões Terapêuticas: Manejo racional de la eritromelalgia. *Actualizaciones Terapéutica Dermatológicas*. 2010;**33**:126. Available from: https://www.researchgate.net/publication/306392597_REVISIONES_TERAPEUTICAS_Manejo_racional_de_la_eritromelalgia_Manejo_racional_de_la_eritromelalgia [Accessed: 17 July 2019]
- [34] Criado PR, Faillace C, Magalhães LS, Brito K, de Carvalho JF. Livedo reticularis: classification, causes e differential diagnosis. *Acta Reumatologica Portuguesa*. 2012;**37**(3):218-225. Available from: https://www.researchgate.net/profile/Paulo_Criado/publication/235004250_Livedo_reticularis_Classification_causes_and_differential_diagnosis/links/02bfe5103d0eb1b4f5000000/Livedo-reticularis-Classification-causes-and-differential-diagnosis.pdf [Accessed: 17 July 2019]
- [35] Wolff K, Goldsmith LA, Katz SI, Gilchrist BA, Paller AS, Leffell DJ. *Fitzpatrick's: Dermatology in General Medicine*. 7th ed. United States of America: McGraw Hill Medical; 2008;**88**:1603-1604
- [36] Tonoli RE, Souza PRM. Case for diagnosis. *Anais Brasileiros de Dermatologia*. 2012;**87**(4):649-650.

Available from: http://www.scielo.br/scielo.php?script=sci_arttext&pid=S0365-05962012000400027
[Accessed: 17 July 2019]

[37] Zanini M, Wulkan C, Bertino D, Ito L. Livedoid vasculopathy or vasculitis? *Anais Brasileiros de Dermatologia*. 2003;**78**(6):755-757. Available from: http://www.scielo.br/scielo.php?script=sci_arttext&pid=S0365-05962003000600012
[Accessed: 17 July 2019]

[38] Pitta GBB, Castro AA, Burihan E. *Angiologia e cirurgia vascular: guia ilustrado*. 2nd ed. Maceió: UNCISAL/ECMAL & LAVA; 2003:1-21

[39] Busato CR, Utrabo CAL, Gomes RZ, Housome JK, Hoeldtke E, Pinto CT, et al. Arterialization of venous arch of the foot for the treatment of thromboangiitis obliterans. *Jornal Vascular Brasileiro*. 2008;**7**(3):267-271. Available from: <http://www.scielo.br/pdf/jvb/v7n3/v7n3a13> [Accessed: 17 July 2019]

[40] Slaviero F, Annes RD, Frighetto L, Schirmer LM, Vanzin JR, Fröhlich AC, et al. Köhlmeier-Degos disease (malignant atrophic papulosis) and neurologic involvement. *Arquivos de Neuro-Psiquiatria*. 2009;**67**(3):692-694. Available from: http://www.scielo.br/scielo.php?script=sci_arttext&pid=S0004-282X2009000400022 [Accessed: 17 July 2019]

[41] Carvalho JFD. Degos' disease as a cutaneous manifestation of systemic lupus erythematosus. *Acta Reumatológica Portuguesa*. 2009;**34**(2A):246-250. Available from: <http://www.actareumatologica.pt/repositorio/pdf/2A-09.pdf#page=91>
[Accessed: 17 July 2019]

[42] Shapiro LS, Toledo-Garcia AE, Farrell JF. Effective treatment of malignant atrophic papulosis

(Köhlmeier-Degos disease) with treprostinil: Early experience. *Orphanet Journal of Rare Diseases*. 2013;**8**:52. DOI: 10.1186/1750-1172-8-52 [Accessed: 17 July 2019]

[43] Theodoridis A, Makrantonaki E, Zouboulis CC. Malignant atrophic papulosis (Köhlmeier-Degos disease): A review. *Orphanet Journal of Rare Diseases*. 2013;**8**:10. Available from: <https://www.ncbi.nlm.nih.gov/pmc/articles/PMC3566938/> [Accessed: 17 July 2019]

[44] Nasr H, Scriven JM. Superficial thrombophlebitis (superficial venous thrombosis). *BMJ*. 2015;**350**:h2039. Available from: <https://www.bmj.com/content/350/bmj.h2039> [Accessed: 17 July 2019]