

We are IntechOpen, the world's leading publisher of Open Access books Built by scientists, for scientists

5,000

Open access books available

125,000

International authors and editors

140M

Downloads

Our authors are among the

154

Countries delivered to

TOP 1%

most cited scientists

12.2%

Contributors from top 500 universities



WEB OF SCIENCE™

Selection of our books indexed in the Book Citation Index
in Web of Science™ Core Collection (BKCI)

Interested in publishing with us?
Contact book.department@intechopen.com

Numbers displayed above are based on latest data collected.
For more information visit www.intechopen.com



Autopsy in Foetal Infant Deaths

Luv Sharma

Abstract

Child autopsies are not more difficult than adult autopsies, but do require a number of extra techniques to be performed routinely. This chapter aims to cover the basic techniques required for foetal, perinatal, and infant post mortems. Post mortem examinations of children older than 2 years of age do not differ greatly from adult autopsies.

Keywords: autopsy, incisions, paediatric, neonatal, pathology

1. Introduction

At present, specialised foetal/child autopsy is more in demand as parents want need to be informed about the cause of death of their child and its effect on future pregnancies. The post mortem examination helps in planning better treatment and caution for the future. The normal anatomy of the adult and child are similar, differences do exist in foetal/neonate anatomy of the cardio-vascular system making the prenatal/paediatric autopsy significantly different from the adult one. The presence of congenital anomalies found in perinatal and foetal autopsies is another confounding factor making meticulous examination during autopsy necessary for getting information to educate families concerning future pregnancies [1]. An autopsy is not required in every case; though debates about the cause of death do necessitate an autopsy to be performed. Normally, a deceased's body is the property of the relatives. However, in deaths that are unusual, unnatural or suspicious in nature the state has an overriding interest which supersedes the interests of the family; such circumstances fall into the category of medico-legal cases. A death case with an obvious cause and manner of death may require an autopsy for legal purposes. The usual classifications of death are: natural, accident, suicide, homicide or undetermined. A forensic autopsy is normally requested by the police, the coroner or in the Latin countries by that quaint institution 'the Investigating Judge' [2]. The age at which a foetus becomes legally viable is defined either by the gestational age or by the body weight, and varies from nation to nation. A foetus exhibiting one or more of the described signs of life are technically considered viable, however foetuses below intrauterine age of 180 days have negligible to no chance of survival. Post mortem examinations are carried out on all foetuses, though the inferences drawn from them are legally applicable only to viable foetuses. Most of the foetal and neonatal autopsies are hospital admitted cases. However, infant post mortems may be medico-legal cases if the cause of death is not known.

2. Rules for autopsy

(1) Conducted in mortuary only, except spot post mortem. (2) Requisition from police or Magistrate necessary. (3) Avoid delay. (4) Collect information

from inquest, accident register, case sheet, etc. (5) Conducted in day-light as far as possible, because colour changes, such as jaundice, P.M. hypostasis and colour of contusions cannot be made out in artificial light. (6) Body should be identified by the police officials. (7) No unauthorised person should be present. (8) Assistant should note findings. (9) Autopsy must be complete and never partial [7].

Important definitions [2]:

Embryo – 1–8 weeks of gestation.

Foetus – 8 weeks of gestation to term.

Stillbirth intrauterine/intrapartum foetal death – after the age of legal viability, i.e., born with no “signs of life.”

Perinatal – stillbirths + neonates in first week after birth.

Early neonate – first week after birth.

Neonatal period – first month after birth.

Post neonatal period – between 28 days and 1 year.

Infant – from 1 month of age to 1 years of age.

Preterm – <37 weeks of gestation or weight less than <2500 gram at birth.

Term – 37–41 weeks of gestation.

Post term – >42 weeks of gestation.

Small for dates weight at birth <10th centile expected for gestational age.

Very low birth weight – weight at birth <1500 gram.

Premature – preterm, small for dates and very low birth weight.

Intrauterine growth retardation – weight/other parameters <10th centile expected for gestational age.

Objectives of a medico-legal autopsy are:

1. To establish the identity of a person.
2. To determine the cause of death whether Natural or Unnatural.
3. If death is unnatural whether it is suicidal, accidental, or homicidal.
4. If death is homicidal, to determine if trace evidence was left behind by assailant.
5. To determine the time elapsed since death.

3. Protocol to be followed at the time of receipt of dead body & autopsy requisition papers

The basic procedures remain the same as with adult autopsies. However, the hospital records must be gone through with great detail. A great deal of vital information can be gathered from notes made by the gynaecologist and the paediatrician involved in the delivery process. The demographic details of the mother & family are also important. The number of pregnancies and their outcome, the method of delivery, any hereditary or congenital illnesses, antenatal records and investigations done assume importance while dealing with an autopsy of a neonate. In addition, if a termination of pregnancy (TOP) for foetal abnormality has been done then the copy of the scan report for comparison with the post mortem findings is necessary [1].

3.1 Autopsy protocol of child

A protocol is a signed document containing a written record which serves as proof of something. Autopsy protocol is used in two basic forms:

1. Narrative
2. Numerical

A numerical protocol is always better to sum up procedures to be followed at autopsy. It is a checklist of sorts and makes the work of the autopsy surgeon more easy and orderly [7].

1. Steps to be done before the autopsy.
2. A summary of the clinical history.
3. A summary of the documents related to the case in order of time sequence.
4. Gross external examination of the dead body.
5. Findings related to identification if the body is unknown or unclaimed.
6. Internal examination of the dead body in relation to pathological findings.
7. A full chart of the viscera.
8. Details of wounds if any.
9. Exhibits to be preserved and sent for analysis.
10. Handing over of the exhibits to the police for onward transmission to concerned centres.

The relatives should identify the body, and radiological examination should be done prior to autopsy. Whole-body radiographs (anteroposterior and lateral) are taken. Photographs of the external features—frontal pictures of the entire body and close-ups of the face and side of the head, as well as, any other unusual aspects are taken [6].

It is best to follow standard guidelines or protocols methodically in each case, whether they be national or have been produced locally as required. In this way, mistakes of omission will be avoided. Although the basic autopsy varies little, there are various special investigations that may or may not be necessary, depending on the particular case. Foetal/infant autopsies are having a slightly different protocol than adult autopsies as findings of the umbilicus and the cord, the placenta, scalp hairs, lanugo hairs, nails & their length, skin colour & texture, scrotal sac wrinkling, as well as specific foetal measurements of the head, chest and abdominal circumference are to be noted.

3.2 Pathology encountered at autopsy

Amniotic infection sequence, oligohydramnios, growth restriction: symmetric, asymmetric (nutritional), viral/protozoal infection (CMV, Parvovirus,

toxoplasmosis, other), congenital malformation (all systems), hydrops foetalis, foetal akinesia sequence, placental and umbilical cord disease, changes in the baby and placenta secondary to intrauterine death.

4. External examination

The body should not be embalmed before the autopsy [7]. A careful external examination should be made to assess any external abnormality. The external features may provide the only information necessary to make the diagnosis of a malformation syndrome. In case of foetal bodies, the measurement of head circumference, chest circumference (at the level of the nipples) and abdominal girth should be measured. The total vertex to heel length has to be noted for an idea regarding maturity and intra-uterine age. The head contour assumes importance in such cases as instrumental delivery may produce trauma mimicking actual violence. Other important procedures include assessing the patency of natural orifices such as the nose, mouth, ears, anus. Evidence of petechial haemorrhages should be looked for in the eyes. For hospital deaths or even in cases found dead after delivery, careful examination of the umbilical cord is paramount; the edges should be checked for sharp cuts, evidence of tearing or gnawing. All puncture marks, needle marks and other injuries should be noted. The skin of the foetus should be examined for staining, discolouration and petechiae. Rodents gnaw away soft tissues of body especially ear, nose, lips etc. They produce shallow craters with irregular border nibbling with leave long grooves and lacks vital reaction [4].

A rough classification exists to help in estimation of maceration (aseptic autolysis) though the changes mentioned are variable depending on temperature and condition of body storage [2].

12 hours – slippage of skin is noted.

24 hours – blebs are formed on the skin.

48 hours – there is sloughing of the skin with blebs rupturing and haemolysis is noted in the viscera.

5 days – the brain liquefies, the cranial sutures overlap (Spalding's sign) and the calvarium collapses.

7 days – the joints get lax and are dislocated.

4.1 External measurements

As already explained above, the following careful measurements should be made with a ruler and a length of string, and compared to tables of normal values to aid assessment of gestational age and allow assessment of growth retardation:

1. Body weight in kg.
2. Crown-rump length (sitting height) in cm.
3. Crown-heel length (standing height) in cm.
4. Foot length in cm.
5. Head circumference in cm.
6. Abdominal girth (at the level of the umbilicus) in cm.

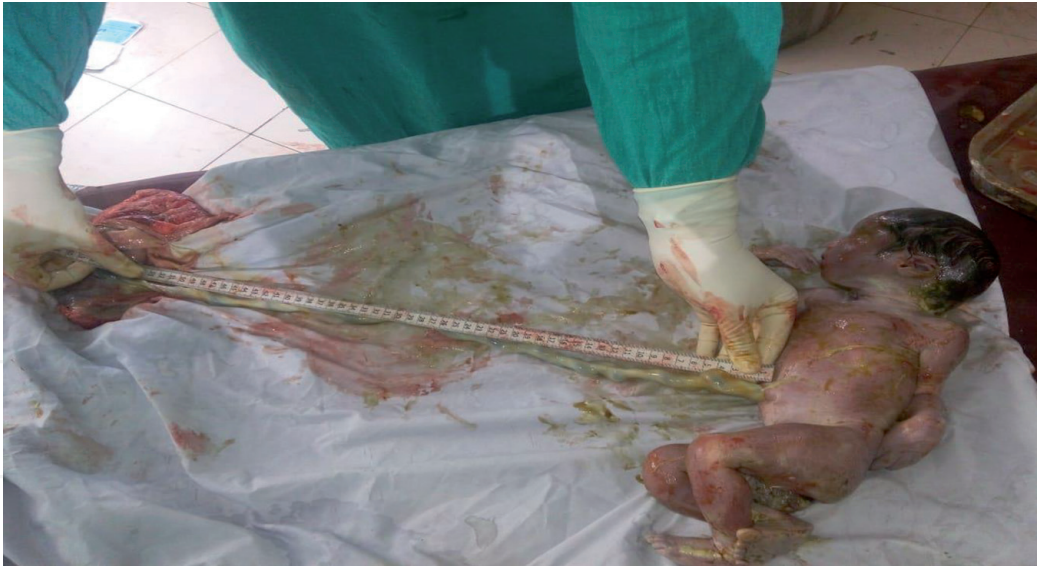

Figure 1.
Measuring the length of umbilical cord.

7. Chest circumference (at the level of the nipples) in cm.

If any abnormality is suspected, relevant radiological investigations (X-rays) and photography is done [2]. In situ photographs can be very helpful, preserving anatomic relationships and depicting visceral lesions before evisceration and fixation (**Figure 1**).

5. Internal examination

There are of three types of primary incisions:

1. The 'I' shaped incision: extending from the chin straight down to the pubic symphysis, passing either side of umbilicus because of excess fibrous tissue in umbilicus which causes the difficult penetration of needle during stitching of body after autopsy.
2. The 'Y' shaped incision: begins at a point close to the acromion process and carried downward to pubic symphysis.
3. Modified 'Y' shaped incision.

Opening of body cavities: preference given to cavities depending upon the findings. Initially open such cavities which give trace evidences and lastly open such cavity which give maximum evidence it reduces the various artefacts.

5.1 Method of removal of organs

Evisceration and Block Dissection equipment: It is essential to have a selection of small forceps, scissors, and probes, in addition to a scalpel. A pair of scales accurate at low weights is also necessary. Of all the methods used for eviscerate a foetus, the most common would be the method of Letulle, in which all organs are removed en bloc with the advantage of keeping continuity if malformations are suspected [2]. Alternate techniques for evisceration and dissection include Ghon, which removes the organs in functional "blocks" and Virchow and Rokitansky techniques [2]:

Rokinansky method is an in-situ examination of viscera with removal of notable organs. Virchow method is an organ by organ removal.

Initial Stages of Evisceration: the best incision involves an inverted Y, with a central cut from below the chin to just above the umbilicus and then two branches, one down to each inguinal fossa which allows a good exposure of the umbilical arteries.

During reflection the scalp, note whether there is any subaponeurotic haemorrhage to exclude asphyxia or deep bruises (**Figure 2**).

Procedure: In foetuses and infants, Beneke's technique is used to open the skull. The cranium and dura on both the sides are cut with blunt scissors starting at the lateral edge of the anterior fontanelle extending the incisions along the midline and the lateral sides of the skull. The midline strip about 1 cm wide containing the superior sagittal sinus and the falx is left, and also an intact area in the temporal squama on either side, which serves as a hinge when the bone is reflected in a 'butterfly' manner [5].

An alternative method of cutting which follows the cranial suture lines i.e. Rokitansky's method [6]. After carefully inspecting the hemispheres, falx cerebri and tentorium cerebelli through the openings, the midline bone and sinus are removed. Injuries to fontanelles (e.g. punctured wounds through anterior fontanelle) and subdural/subarachnoid haemorrhages are looked for [5] (**Figure 3**).

5.2 Removal of the brain of a macerated baby

If the dura is left intact when the skull plates are cut, and carefully dissected from the skull when the bone flaps are reflected, then the entire brain can be removed while intact inside the dura.

5.3 Removal of the brain in a case of cystic congenital anomalies

It is better to fix the brain before removal of these anomalies. A CSF needle can be used to extract CSF from the ventricles which then can be filled with 50 ml of formalin. An hour of fixation of the brain would help it in maintaining its shape, whereupon removal of the anomaly can be done. If contrast mixture is mixed with the formalin then X-ray films can be taken that will outline the ventricular system [2].

5.4 Removal of the spinal cord in a suspected neural tube defect

The best method is the posterior approach. The skin is incised and at the point of the defect an ellipse shaped piece of the skin is removed, which completely encircles

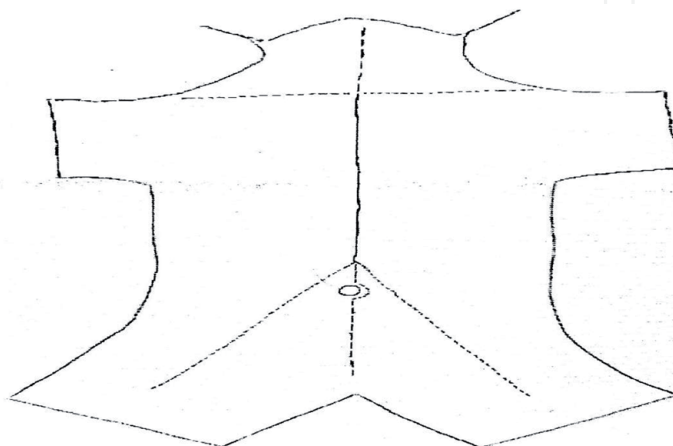


Figure 2.
Removal of the brain.

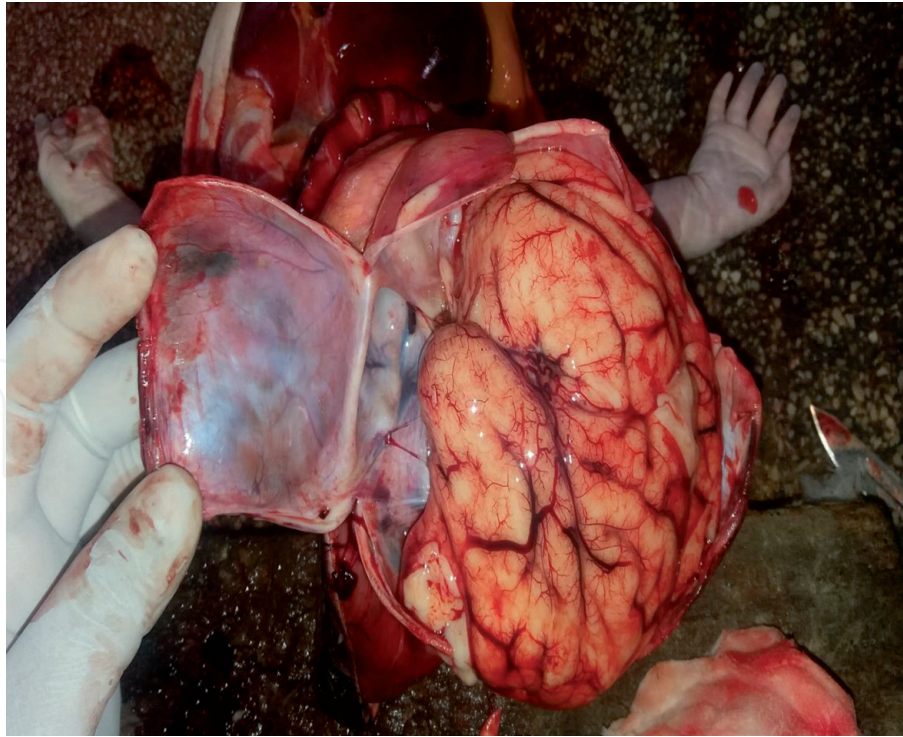


Figure 3.
Opening of skull and dissection of underlying dura and brain.

the defect. When the pedicles have been cut above and below the defect with bony forceps, the cord is removed. Once the cord has been removed above and below the defect, the vertebral column can be transacted. This can be fixed and examined histologically after serial sectioning. The resulting skin defect should be covered.

5.5 Examination of the eye

This may be necessary in cases of non accidental injury, to look for retinal haemorrhage, or in cases of intrauterine infection or suspected retrolental fibroplasia.

5.6 Examination of the musculoskeletal system

This may be necessary in cases of suspected birth injury, other causes of trauma, congenital deformity, or tumours.

5.7 Examination of the neuromuscular system

This would be necessary in cases of suspected neuromuscular disorders or metabolic storage disorders.

5.8 Dissection of pelvic organs with continuity of perineum and anus

This is sometimes when there is suspicion of a urinary tract anomaly or if the external genitalia are ambiguous. The symphysis pubis is bisected with a sharp scalpel. All the connective tissues around the pelvic organs are dissected freeing them anteriorly, posteriorly and sideways. In males, the muscular part of the penis is denuded till the terminal part is reached. The attachment to the glans penis is cut so that the penis can be removed in continuity to the bladder. In females, the skin of the vulva is incised as a circle near the external os. Blunt dissection around the vagina frees the vagina and uterus to be removed. The anus in both sexes, is removed

by blunt dissection in a circular manner in the perineum around the anal aperture. Further dissection would allow the anus to be removed with the pelvic organs [2].

5.9 Organ dissection

All major organs should be accurately weighed after removal, and then compared to normal values. These are produced in terms of both gestational age and body weight, for both live and stillborn babies.

5.10 The cardiovascular system

If congenital heart disease is suspected, the heart is dissected along the path of blood flow, as for the adult. Careful inspection of the chambers in the manner of blood flow is done. Any defects or asymmetrical findings are noted. Cardiac wall hypertrophy or dilatation is noted for each chamber. The openings of the valves are examined and their diameters are noted. Any focal myocardial lesions should be looked for during examination of the ostia. The whole heart must be preserved for histo-pathological examination.

5.11 The respiratory system

The hydrostatic test must be undertaken to come at a conclusion regarding life or dead birth. A piece of the liver acts as a control in such cases. If the liver piece floats when placed on water, it means that putrefaction has set in and then there is no utility of this test as false positive results would be expected when the lungs are placed in the water container. The shape, consistency and weight of the lungs should be noted. It is always better to send the lungs for histo-pathology in such cases where a clearer picture would emerge [1].

A rough estimate of foetal maturity can be got from weight of the lungs: body weight ratio: Lung weight: body weight ratio < 0.012: 1 in gestations ≥ 28 weeks.

Lung weight: body weight ratio < 0.015: 1 in gestations < 28 weeks.

Deep dissection of the bronchial & pulmonary arteries should be carried out as far as possible. The pulmonary lobes are best dissected in the coronal plane. The lung parenchyma should be examined for consolidation, abscess, haemorrhage, oedema & focal lesions. Small areas of collapse are seen as depressed reddish areas. All pulmonary lobes should be sampled for histology. If a tracheo-oesophageal fistula is suspected, the trachea should be opened anteriorly and the oesophagus dissected distally and attached to the trachea. The trachea and oesophagus should be sampled for histo-pathology preferably at the level of the laryngeal cartilage so as to include thyroid gland in the same block.

5.12 The gastrointestinal system

It is always better to locate the caecum which forms the boundary between the small & large gut. The entire intestines should be opened and the mucosa examined. The distribution of meconium should also be assessed. The mesentery of the gut should also be examined during autopsy.

The liver should be weighed after removal before being dissected in a coronal plane to allow comparison between the right and left lobes. Any colour change or focal lesions should be noted and both lobes should be sampled for histo-pathology [3].

The pancreas usually is auto digested before the body reaches the mortuary. However, if present it should also be sent for histo-pathology.

The Genitourinary System: Malformations of the urinary tract are quite common and should be looked for. In males these anomalies are found with obstructive lesions of the urinary tract and may require special attention.

The kidneys should be weighed and dissected coronally. The cortices and medullae should be identified. The renal pelvis and calyces should also be examined. Yellow streaks of urate may be seen and prove neonatal survival. Each kidney should be sampled for histo-pathology [6].

The testes normally lie within the scrotum from 32 weeks of gestation.

5.13 The lymphoreticular system

The thymus is a part of the anterior mediastinum and is proportionately much larger than in adults and easier to identify. The spleen should be weighed. Any focal lesions in the splenic parenchyma should be identified. Splenic enlargement is seen in haemolytic syndromes. The spleen should be sampled for histo-pathology [1]. Any lymphadenopathy should obviously be identified and sampled for histo-pathology. Routine histology should include a block of small bowel mesentery which will contain several lymph nodes.

Routine examination of bone marrow is not necessary, but if haematopoietic disturbance is suspected, marrow should be sampled for histology. The ribs is the most approachable and convenient site.

5.14 Precautions

In regions of high maternal HIV prevalence, autopsy practice using universal precautions will significantly protect against accidental transmission.

5.15 The placenta examination

Placenta is a vital part of any foetal or perinatal post mortem. Examination of the placenta is also an essential part of the autopsy of a perinatal case. Before starting the dissection, a bacteriological sample should be taken from the placental membranes and parenchyma in cases of stillbirth, prematurity, or IUGR, or if generalised infection is noted. The site of cord insertion must be identified and the length of cord noted. True knots, ruptured varices, and number of vessels must be noted. The vessels themselves should also be sectioned to assess the possibility of thrombus, an important point in identification is that all arterial branches cross superficial to venous branches. The foetal membranes should also be examined, and any meconium staining or discolouration (suggesting infection) noted. The size of the placental sac and the point of rupture should also be noted. The maternal cotyledons should be examined closely. The membranes and cord should then be removed, and the placental disc weighed and measured. Any blood clot received with the placenta should also be weighed. Serial slices should be made through the placental disc at approximately 1-cm intervals, one of which should go through the insertion of the cord. Any focal lesions, such as infarction, thrombosis, and haemangiomas should of course be noted. For histo-pathology, sections of cord, rolled up membranes, and placental parenchyma should be taken, in addition to any lesions identified macroscopically. The placental sections should include cord insertion, placental edge and membrane. In twin or other multiple placentae, the dividing membranes should be carefully examined to assess the number of chorionic and amniotic membranes. Monochorionic placentae indicate monozygosity whereas dichorionic placentae can occur in both homozygous and heterozygous multiple pregnancies. Any

apparent anastomoses of foetal vessels should also be noted. Histological samples should also include the rolled up dividing membrane(s) and/or the placenta at the point of the division(s).

6. Estimation of gestational age and growth

It is important to make as accurate an estimation of gestational age as possible, and then to use this estimation to make an assessment of intrauterine growth. Measurements of crown-rump, crown-heel, and foot lengths, together with whole body weights and organ weights are the best starting points as already discussed above (Figures 4–6).

To assess gestational age, the following points must be taken into consideration:

1. Fusion of palatal shelves and fingerprints is seen at around 10 weeks.
2. Differentiated external genitalia are identifiable at 12 weeks.
3. Head is erect and lower limbs are well developed at 14 weeks.
4. Ears stand out from head at around 16 weeks.
5. Vernix caseosa is present and early toenail development is seen at 18 weeks.
6. Head and body (lanugo) hairs are visible at 20 weeks.
7. Skin is wrinkled and red at 22 weeks.
8. Fingernails are present at 24 weeks.

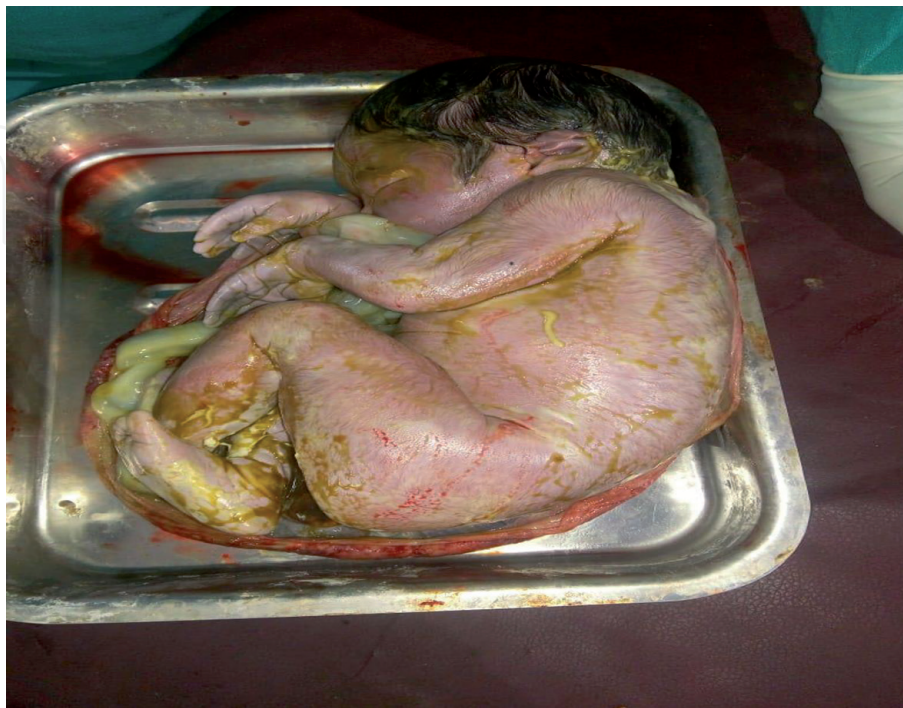

Figure 4.
Vernix caseosa, scalp and body (lanugo) hairs and fingernails reach fingertips.

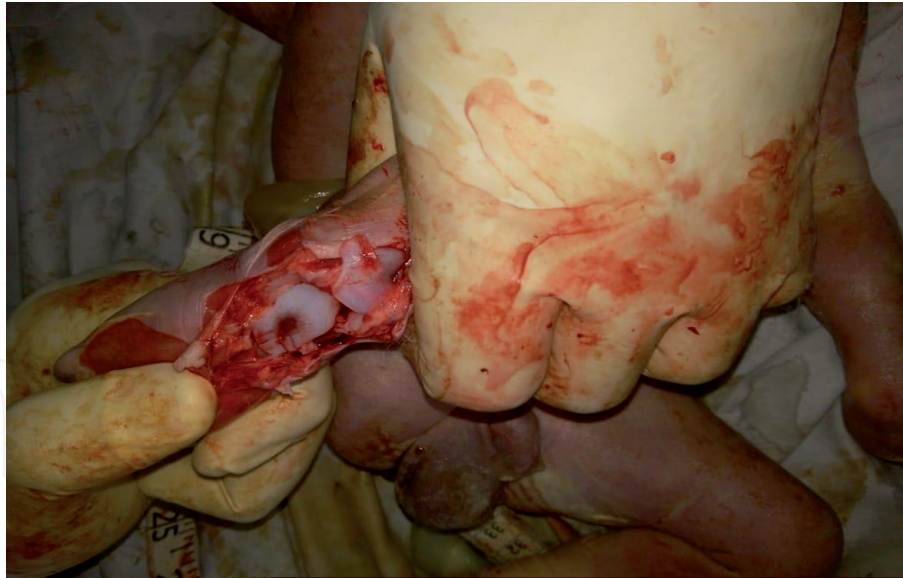

Figure 5.
Ossification centre of Talus bone i.e. 5 months.

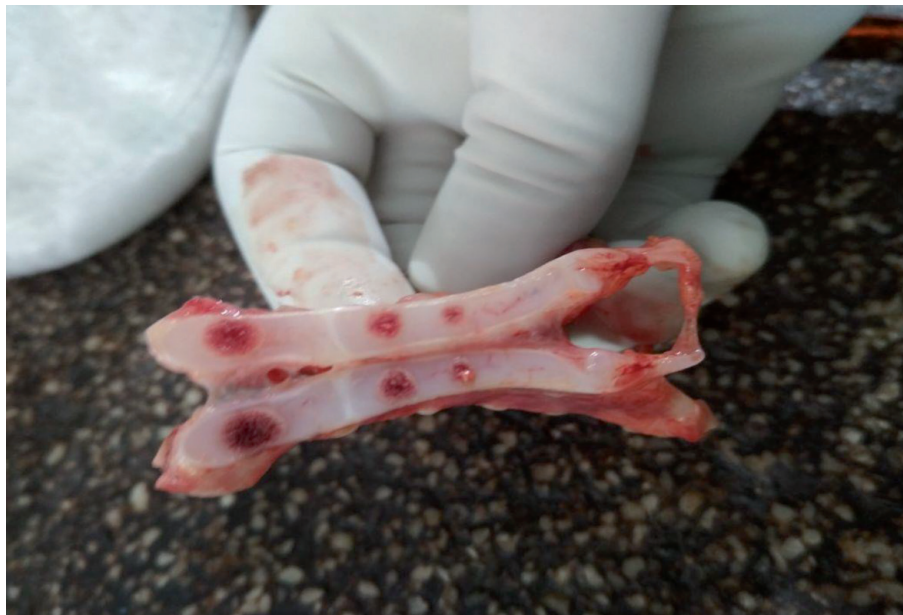

Figure 6.
Ossification centre of body of sternum.

9. Partial separation of eyelids; eyelashes present at 26 weeks.
10. Eyes are open, scalp hair well formed at 28 weeks.
11. Toe nails are present at 30 weeks.
12. Fingernails reach fingertips, skin is smooth at 32 weeks.
13. Body plump, lanugo absent, toenails reach toe tips at 36 weeks.
14. Testes palpable, fingernails beyond tips at 38 weeks.
15. Various ossification centres: such as calcaneum at 20 weeks, talus at 28 weeks, lower end of femur at birth and upper end of tibia just after birth are also important indicators of foetal maturity.

7. Cause of death

While giving cause of death the word 'probably' should be avoided. The doctor must consider history, description of fatal environment and circumstances optimally provided by primary sources, treatment leading up to death which can cause injuries, before arriving an autopsy interpretation. After completing the post mortem examination, a complete but concise report should be prepared in duplicate. One copy is sent to investigating officer and another copy is retained for future references [7].

8. Summarising the whole infant/foetal autopsy procedure [6]

1. A whole body X-ray is recommended for each case. This would help in assessing gestational age and congenital malformations in a better way. If need arises other radiological investigations can be carried out.
2. Photographic records of the case; important for documentation of the findings and a recap of them if a subsequent opinion is required by the law enforcement agencies.
3. Specific external body measurements (body weight, crown-rump length, crown-heel length, foot length, occipito-frontal circumference, head circumference, chest circumference & abdominal girth) for assessing gestational age.
4. A detailed external examination of the dead body for findings on the skin, eyes and for injuries if present.
5. Preferably T- or Y-shaped skin incision on body.
6. Cardio-vascular, Respiratory & Central nervous system examination along with examination of the gastrointestinal system.

CNS examination: if there is suspicion of a CNS malformation (including ventriculomegaly), then examination of posterior fossa structures by posterior approach is advised. One may consider sending the whole central nervous system for neuropathological examination in appropriate cases. This may include sampling of peripheral nervous tissue (nerve root, peripheral nerve, muscle, etc.).

7. Detailed systematic examination of other internal organs, including: Umbilical arteries and vein, ductus venosus, in situ examination of the heart and great vessels with sequential segmental analysis of malformations, in situ examination of thoracic and abdominal organs; consider removing in continuity to assess abnormal structures crossing diaphragm, weights of internal organs (minimum: brain, heart, lungs, liver, kidneys, thymus, adrenals, spleen) is always advisable.
8. Detailed examination of placenta and umbilical cord, including: dimensions of placenta umbilical cord: length, diameter, insertion into placental disc, number of vessels, coiling, lesions, membranes: appearance, foetal surface/chorionic vessels: appearance, infection, maternal surface: completeness, craters, etc.
9. An infant/foetal autopsy may include clinical specialities for guidance & expertise such as paediatrics, neurology, neurosurgery, etc.

Limited autopsy: a situation in which consent for a full autopsy is not given by the legal heirs of the dead body. This limited examination may be of some value for arriving at an opinion. The types of such limited autopsy are:

1. Autopsy limited to one or more body cavities only.
2. Open or needle biopsy of specific internal organs.
3. External examination of the body with X-ray, photography in specific situations such as highly infected dead bodies.
4. Placental examination only with genetic sampling if indicated.
5. Imaging (CT, MRI) alone or in combination with biopsy samples.
6. Specific significant organ systems.

For histological examination, the recommended organs include: thymus, heart (septum and free walls), lungs (right and left, each lobe), liver (both major lobes), pancreas, spleen, adrenal glands, kidneys, muscle, diaphragm, stomach, small and large bowels, larynx/trachea and thyroid. Sometimes samples of bone i.e. ribs including growth plate in stillbirth; long bone (including growth plate), vertebral body and skull mandatory for suspected skeletal dysplasia are required to be taken in specific conditions.

Bacteriology may be helpful when there is amniotic infection. In such cases, lung (swab/tissue) & blood (swab/formal culture) are to taken & sent for further analysis. Other samples may also be required depending upon the history & clinical course of the disease.

Genetic samples: genetic samples do assume importance for detailed study of acquired conditions in the young. Skin, muscle, blood from the heart, placenta, etc. can be sampled. One can consider retention of frozen tissue sample (liver/lung/ other) as further DNA resource.

Virology – Virology samples as indicated by clinical history or macroscopic findings can also be taken & sent for analysis in suspected conditions.

Biochemistry & electron microscopy – Biochemical samples can be considered in cases of fetal akinesia and hydrops foetalis. Fibroblast culture and/or snap frozen liver/muscle for metabolic biochemistry can also be taken if indicated.

Author details

Luv Sharma

Department of Forensic Medicine, Pt. B.D. Sharma Post-Graduate Institute of Medical Sciences, University of Health Sciences, Rohtak, Haryana, India

*Address all correspondence to: drluvksharma@yahoo.com

IntechOpen

© 2020 The Author(s). Licensee IntechOpen. This chapter is distributed under the terms of the Creative Commons Attribution License (<http://creativecommons.org/licenses/by/3.0>), which permits unrestricted use, distribution, and reproduction in any medium, provided the original work is properly cited. 

References

[1] Barness EG, Spicer DE, Steffensen TS. Pediatric. In: Handbook of Pediatric Autopsy Pathology. 2nd ed. London: Springer New York Heidelberg Dordrecht; 2014

[2] Sheaff MT, Hopster DJ. Fetal. In: Post Mortem Technique Handbook. 2nd ed. London: Springer-Verlag London Limited; 2005

[3] Knudsen PJT, Thomsen JL, Ampanozi G, Thali MJ. Autopsy. In: Madea B, editor. Handbook of Forensic Medicine. Germany: John Wiley & Sons, Ltd; 2014

[4] Bardale R. Principles of Forensic Medicine and Toxicology. New Delhi, Panama City, London: Jaypee Brothers Medical Publisher (P) Ltd; 2011

[5] Biswas G, Paul G, Verma SK. Review of Forensic Medicine and Toxicology. 3rd ed. New Delhi, London, Philadelphia and Panama: Jaypee Brothers Medical Publishers (P) Ltd; 2015

[6] Osborn M, Cox P, Hargitai B, Marton T. Guidelines on Autopsy Practice: Foetal Autopsy (2nd Trimester Foetal Loss and Termination of Pregnancy for Congenital Anomaly). London: The Royal College of Pathologists; 2017. Available from: www.rcpath.org

[7] Reddy KSN, Murty OP. Medicolegal autopsy. In: The Essentials of Forensic Medicine & Toxicology. 34th ed. New Delhi: Jaypee Brother Medical Publisher (P) Ltd; 2017