

# We are IntechOpen, the world's leading publisher of Open Access books Built by scientists, for scientists

**5,000**

Open access books available

**125,000**

International authors and editors

**140M**

Downloads

Our authors are among the

**154**

Countries delivered to

**TOP 1%**

most cited scientists

**12.2%**

Contributors from top 500 universities



**WEB OF SCIENCE™**

Selection of our books indexed in the Book Citation Index  
in Web of Science™ Core Collection (BKCI)

Interested in publishing with us?  
Contact [book.department@intechopen.com](mailto:book.department@intechopen.com)

Numbers displayed above are based on latest data collected.

For more information visit [www.intechopen.com](http://www.intechopen.com)



# Meniere's Disease: Surgical Treatment

*Yetkin Zeki Yilmaz, Begum Bahar Yilmaz and Mehmet Yilmaz*

## Abstract

When Meniere's disease's vertigo attacks are too frequent and medical treatment options fail, surgical treatment options should be considered. Meniere's disease is progressive, and there is not a known cure, and all treatment options are symptomatic. Also the possibility of bilateral involvement is another well-known characteristic of this condition as well as its effect on hearing. Some of the patients have progressive hearing loss with vertigo attacks. In order to decide a surgical procedure for these patients, clinicians must be aware of the natural course of Meniere's disease. In order to their effects on vestibular system, there are two types of surgical procedures. Nondestructive surgeries aim to alter the course of disease, and destructive surgeries aim to control symptoms while eliminating all vestibular functions of the effected ear.

**Keywords:** Meniere's disease, labyrinthectomy, vestibular neurectomy, endolymphatic sac surgery, neuro-otology

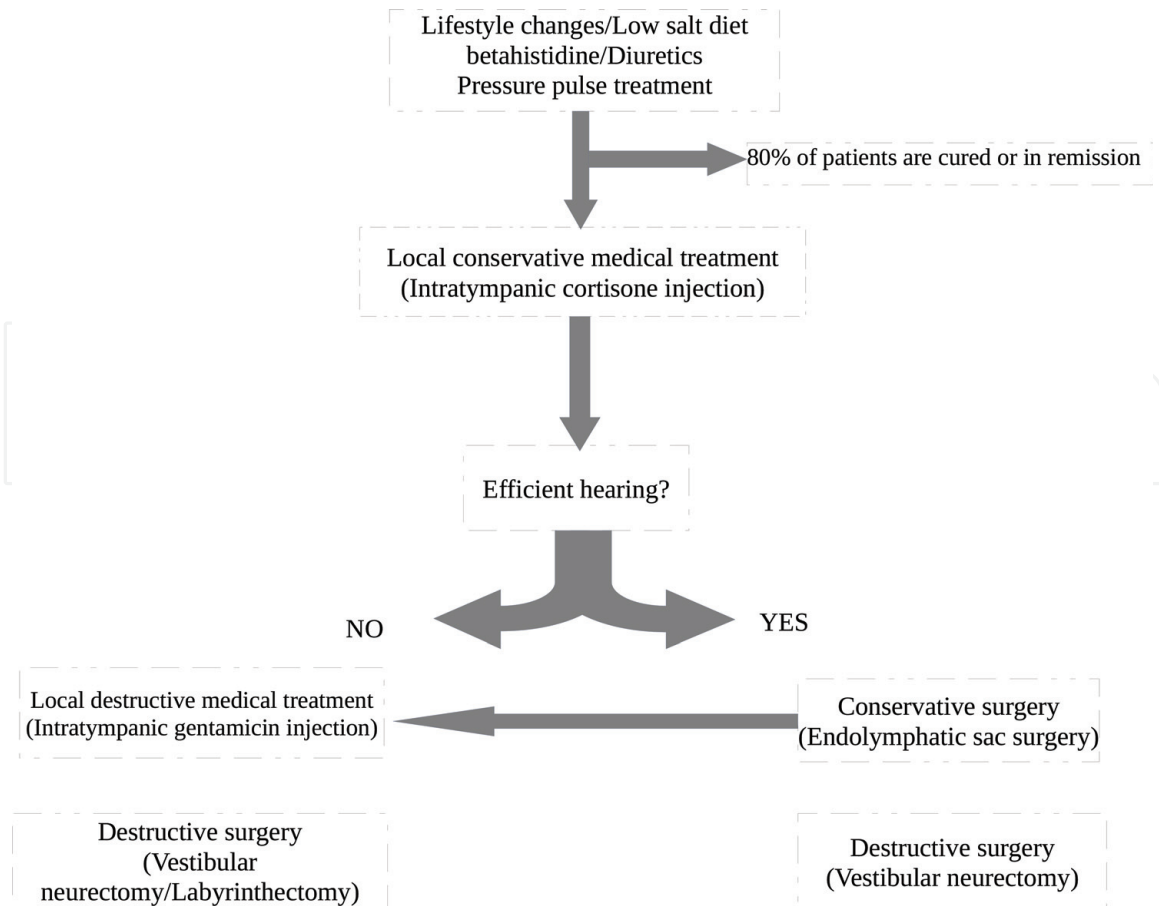
## 1. Introduction

When Meniere's disease's vertigo attacks are too frequent and medical treatment options fail, surgical treatment options should be considered. Meniere's disease is progressive; there is not a known cure and all treatment options are symptomatic. Also the possibility of bilateral involvement is another well-known characteristic of this condition as well as its effect on hearing. Some of the patients have progressive hearing loss with vertigo attacks. In order to decide a surgical procedure for these patients, clinicians must be aware of the natural course of Meniere's disease.

Some authors recommend to wait 6–12 months in order to recommend surgery for intractable Meniere's disease. However, there are different definitions of "intractability." When medical treatment fails and patient keep experiencing severe and frequent vertigo attacks, surgery option could be evaluated. If the symptoms are resistant to medical and psychological therapy for at least 3–6 months, hearing loss and vertigo attacks are frequent, and the condition could be accepted as intractable [1]. Ten to twenty percent of Meniere's disease patients are considered to have an intractable disease [2].

There are destructive and nondestructive surgical options; in decision process, patients' general health condition, age, and hearing levels should be considered. Progressive and bilateral nature of the disease always should be considered.

The ideal surgery must restore remaining functions while relieving patients' severe symptoms. International Consensus (ICON) on treatment of Meniere's



**Figure 1.**  
Treatment algorithm of Meniere's disease, proposed by ICON in 2018.

disease recently proposed a treatment algorithm. When conservatory treatment options were insufficient to control patient's symptoms, it is recommended to evaluate patient's remaining hearing. If the effected ear has efficient hearing, conservative surgical treatment options are recommended, but if remained hearing is not efficient, destructive surgical or medical treatment options are recommended. Conservative surgery is the third step of the treatment, while destructive surgery is the fifth and last option (**Figure 1**) [3].

French Otorhinolaryngology Head and Neck Surgery Society (SFORL)'s guideline of Meniere's disease recommends surgical options after noninvasive treatment options were tried [4]. European position statement on diagnosis and treatment of Meniere's disease has similar opinions about surgery with ICON and SFORL guidelines [5].

Since local destructive medical treatment (intratympanic gentamicin) is another subject of another chapter of this book, the main focus of this chapter will be surgical procedures.

## 2. Patient selection

A successful treatment requires precise diagnosis. Typical Meniere's disease causes fluctuating hearing loss and episodic vertigo that could last minutes to hours with tinnitus and ear fullness. For every patient who describes one or more of these symptoms, clinician should consider Meniere's disease in differential diagnosis. Even nowadays, diagnosis of Meniere's disease is clinical. Detailed history and complete physical examination should be taken. After routine exam, there are some diagnostic tests that should be ordered like complete audiometric assessment,

vestibular test battery, and imaging studies. Differential diagnosis of unilateral vestibular disorders is summarized in **Table 1**.

MR imaging studies should be ordered in all unilateral cases of Meniere's disease. It is helpful to exclude retrocochlear pathologies, endolymphatic sac tumors, vestibular schwannomas, or any other conditions that could mimic the symptoms of Meniere's disease. Also Nakashima et al. managed to visualize endolymphatic hydrops in Meniere's disease after administering the contrast substance gadolinium intratympanically [6]. Miyagawa et al. visualized the endolymphatic hydrops with intravenous administered gadolinium MRI [7]. Naganawa and Nakashima evaluated the imaging for Meniere's disease and its correlation with vestibular tests of Meniere's disease patients. They reported that endolymphatic hydrops could be observed with MRI, and also all patients with Meniere's disease had endolymphatic hydrops in imaging studies, but not all patients who had endolymphatic hydrops were diagnosed with Meniere's disease [8]. If patient is unable to go under MRI, auditory brainstem response audiometry could be helpful to evaluate retrocochlear pathologies [9]. Nevertheless imaging studies are important part of differential diagnosis; also if surgery is going to be performed, computed tomography should be ordered for surgery plan.

Serial audiograms are helpful to document fluctuating hearing loss. Most specific pattern is sensorineural hearing loss of low frequency and its reversibility. Most authors reported sensorineural hearing loss at low frequencies with better hearing at 2000 Hz, called peak pattern [10, 11].

Unilateral vestibular hypofunction is most common finding of unilateral Meniere's disease, although it is reported that half of the Meniere's disease patients have completely normal responses in bithermal caloric tests [12]. Video head impulse test (VHIT) is a significant parameter to evaluate peripheral vestibular system since it evaluates semicircular canals individually. In order to evaluate utricle and saccule functions, vestibular evoked myogenic potentials (VEMPs) are very useful [13].

Electrocochleography is considered to be the most valuable test to diagnose Meniere's disease. Summation and action potentials that arise from cochlea are

Autosomal dominant sensorineural hearing loss type 9 (DFNA9) caused by COCH gene
Autosomal dominant sensorineural hearing loss type 6/14 (DFNA6/14) caused by WFS1 gene
Autoimmune inner ear disease
Cerebrovascular disease (stroke or transient ischemic attack in the vertebrobasilar system, bleeding)
Cogan's syndrome
Endolymphatic sac tumor
Cerebellopontine tumors (such as meningioma)
Neuroborreliosis
Otosyphilis
Susac syndrome
Third window syndromes (perilymph fistula, canal dehiscence, enlarged vestibular aqueduct)
Vestibular migraine
Vestibular schwannoma
Vogt-Koyanagi-Harada syndrome

**Table 1.**  
*Differential diagnosis of unilateral vestibular disorders.*

Peripheral labyrinth dysfunction	<ul style="list-style-type: none"> <li>• Unilateral caloric weakness</li> <li>• Spontaneous or positional nystagmus (although oculomotor findings are normal)</li> <li>• Nystagmus could be provoked with specific maneuvers (Dix-Hallpike, Roll, etc.)</li> <li>• Asymmetric or abnormal rotational chair phase</li> <li>• Reduced gain on rotational chair phase (bilateral weakness)</li> </ul>
Central nervous system pathology	<ul style="list-style-type: none"> <li>• Vertical or perverted nystagmus</li> <li>• Abnormal oculomotor test results</li> <li>• Nystagmus would not be suppressed with visual fixation</li> </ul>
Uncompensation	<ul style="list-style-type: none"> <li>• Persistent nystagmus (positional or spontaneous)</li> <li>• Post head-shaking nystagmus</li> <li>• Asymmetric rotational chair phase</li> <li>• Abnormal dynamic posturography</li> </ul>
Compensation	<ul style="list-style-type: none"> <li>• Resolution of nystagmus</li> <li>• Resolution of asymmetric rotational chair phase</li> <li>• Improvement of performance on dynamic posturography</li> </ul>

**Table 2.**  
*Clinical interpretations of vestibular tests.*

evaluated. Summation potential/action potential ratio increases in order of endolymphatic hydrops [14]. It is not diagnostic for Meniere's disease; the ratio is found to be elevated at 62% of Meniere's disease patients as well as 21% of control subjects [15].

Sixty to eighty-seven percent of patients with Meniere's disease reported to be able to continue their normal life style with medical treatment [16, 17]. If medical treatment tried for 3–6 months and attacks of patient was not able to be controlled with medical treatment, surgical options must be considered [18, 19]. Character of the surgery is decided upon patient's remaining hearing. If hearing levels are 50 dB or higher or speech discrimination scores are 80% or higher, conservative surgeries should be offered, but if hearing is not functional, destructive options must be considered [20].

The interpretation of vestibular test results was summarized in **Table 2**.

### 3. Surgical procedures

In order to their effects on vestibular system, there are two types of surgical procedures. Nondestructive surgeries aim to alter the course of disease, and destructive surgeries aim to control symptoms while eliminating all vestibular functions of the effected ear.

Nondestructive procedures are endolymphatic sac decompression or shunt in order to increase endolymph drainage, ventilation tube insertion in order to equalize increased pressure of inner and middle ear, and lateral semicircular canal plugging to block the movement of endolymph into the effected canal [21].

Destructive procedures aim to abolish the end vestibular organs. Most of these procedures have high risk to harm the cochlea. Selective vestibular neurectomy aims to cut all the inputs coming from vestibular organs, cochleovestibular nerve section aims to stop all vestibular and audiologic input from the effected ear, labyrinthectomy aims to destruct the labyrinth which also leads to total hearing loss of the operated side, and chemical ablation aims to abolish vestibular inputs, which also has a risk to cause hearing loss and will be evaluated in another chapter [22].

### **3.1 Nondestructive procedures**

#### *3.1.1 Cochleosacculotomy*

Cochleosacculotomy is also called “cochlear endolymphatic shunt procedure.” This procedure’s aim is to equalize the pressure between the perilymph and endolymph by creating a permanent shunt [23].

##### *3.1.1.1 Definition of the procedure*

Tympanomeatal flap is elevated and a round window niche is visualized. Angled pick is inserted through the round window membrane and directed to the oval window, and then osseous spiral lamina of cochlea is fractured.

##### *3.1.1.2 Indications and complications*

This procedure is rather easy when compared to other surgeries. It does not have risk of cerebrospinal fluid leakage. However, sensorineural hearing loss is expected to be 25% on high-frequency sensorineural hearing loss and 10% of profound hearing loss are reported [24]. Success rates are up to 70% with long-term vertigo relief [25]. It should be considered as an alternative of labyrinthectomy in elder patient who already had severe hearing loss [26].

#### *3.1.2 Endolymphatic sac surgery*

The exact pathophysiology of Meniere’s disease is still unclear, but one of the most accepted theories is endolymphatic hydrops. Temporal bone studies of Meniere’s disease patients reported endolymphatic hydrops [27, 28]. The AAO-HNS guideline of Meniere’s disease defines “certain” Meniere’s disease when endolymphatic hydrops are demonstrated histopathologically in the postmortem temporal bone specimen of the patient [29].

Endolymph is produced in stria vascularis and dark vestibular cells. It flows through the duct to the sac, and with active transport mechanisms, it is absorbed [30]. Animal study designed by Kimura et al. achieved to cause cochlear hydrops by ductus reuniens obliteration [31].

Paparella suggested that inadequate absorption of endolymph leads to endolymphatic hydrops. He described his theory with “lake-river-pond” comparison while endolymphatic sac is the pond, vestibular aqueduct is the river, and endolymphatic space is the lake. Any obstruction or overproduction leads to hydrops [32]. Perisacculary fibrosis, endolymphatic sac atrophy, loss of epithelial integrity of endolymphatic sac, vestibular aqueduct hypoplasia, and narrowing of endolymphatic duct lumen were observed in the pathological findings in temporal bone studies [30, 33–35].

Also some anatomic abnormalities were observed during endolymphatic sac procedures and proposed as a cause of hydrops. Some of the patient’s lateral semicircular canal are located anteriorly and observed in many of the patients. It was suggested to cause vascular compression of endolymphatic sac that leads to hydrops [36, 37].

The findings of revision endolymphatic sac surgeries are another source that used to gather information about the pathophysiology of the disease. Hypoplastic mastoid air cell system with perisacculary fibrosis, discoloration of silastic tube that is inserted at primer surgery, incomplete decompression of sigmoid sinus and mastoid cavity, granulation formation in mastoid cavity, and perisacculary space were the reported findings [36–38].

Portmann was the first surgeon who suggested endolymphatic sac surgery for Meniere's disease nearly 90 years ago and reported improvement of hearing and vestibular functions of patients [39]. In the 1960s, House suggested endolymphatic subarachnoid shunt procedure [40]. Endolymphatic sac enhancement to mastoid cavity was proposed by Paparella et al. in 1980 [41].

### *3.1.2.1 Definition of the procedure*

First cortical mastoidectomy is performed and carried on until the mastoid antrum is visualized. Then the bony labyrinth should be identified. Horizontal and superior semicircular canals are important landmarks of this procedure. Imaginary line that parallel to the horizontal semicircular canal toward to the dome of the superior semicircular canal is called "Donaldson line" is drawn. Endolymphatic sac is always located inferior of this line.

Boundaries of the endolymphatic sac are Donaldson line in superior, sigmoid sinus in posterior, jugular bulb in anteroinferior, and mastoid segment of facial nerve in lateral. These structures are in danger during this procedure. Sigmoid sinus should be skeletonized widely and facial nerve should be followed toward the digastric ridge and stylomastoid foramen in order to avoid to harm these structures. Posterior fossa dura behind the sigmoid sinus as well as the sigmoid sinus is decompressed with a large diamond drill.

Sigmoid sinus is retracted and bony dural plate and presigmoid posterior fossa dura is dissected. The sigmoid sinus and dura are retracted, and the bony dural plate that is located inferior of the Donaldson line is removed to the jugular bulb. In order to see the endolymphatic duct's entry in to bone medial to posterior semicircular canal, dissection should be carried anteromedially into retrofacial air cells. When the endolymphatic sac is identified, it is up to the surgeon to terminate the procedure or open the lumen and place a shunt. Shunt could be placed into mastoid cavity of subarachnoid space.

This procedure has many variations, sac decompression with or without decompression of posterior fossa dura or sigmoid sinus and sac drainage or shunt placement to sac [42, 43].

The role of endolymphatic sac in development of Meniere's disease is still unknown. Inadequate absorption of endolymph by the endolymphatic sac hypothetically causes hydrops which leads to Meniere's disease. The aim of decompression of the sac is to relieve the pressure that inhibits the absorptive capacity of the sac. However, when the temporal bones of patients who underwent endolymphatic sac decompression surgery were studied histopathologically by Chung et al., they observed a diffuse hydrops of the cochlea, saccule, utricle, and ampulla and reported that the decompression is the opposite of the aim of the surgery, not efficient to relieve the hydrops [44]. Linthicum and Santos reported that complete endolymphatic sac removal does not lead to hydrops in the endolymphatic duct or cochlea [45]. According to these findings, Saliba et al. recently described a novel method, endolymphatic sac blockage. They described their procedure in their recently published paper in 2015. Procedure is similar with endolymphatic sac decompression surgery; after the endolymphatic sac identification, they block the endolymphatic duct with two titanium clips. The results were found significantly better than the endolymphatic sac decompression [46].

### *3.1.2.2 Indications and complications*

If medical treatment options failed and hearing function of the patient is sufficient and patient is relatively young, endolymphatic sac surgery should be

recommended [3]. Its effect on hearing is minimal and recommended especially in bilateral Meniere's disease [4]. Possible complications are facial paralysis, CSF leak, and hearing loss. Also in order to reach to the endolymphatic sac, the drilling is close to the posterior semicircular canal, so surgery could stimulate the otolith displacement that leads to benign paroxysmal vertigo.

### 3.1.2.3 Results

The results of this procedure are mostly from retrospective or observational studies. It is usually reported as an efficient and relatively safe procedure. However most of the studies lack randomization or placebo control.

The rate of complete control of vertigo after endolymphatic sac surgery is reported to be 30–72% in literature [47–52].

Thomsen, Bretlau et al. designed a randomized controlled trial to observe the efficacy of endolymphatic sac surgery. They performed endolymphatic sac surgery and cortical mastoidectomy as placebo procedure on intractable Meniere's disease patients. The results were like a milestone in otology society. Endolymphatic sac surgery results were the same with placebo surgery [2]. This paper decreased the popularity of the procedure. Twenty years later, Welling and Nagaraja re-examined their results. They found that patients who underwent placebo procedure had a complete cortical mastoidectomy when the Trautmann triangle was decompressed. Thomsen and colleagues had completed the most important step of successful decompression surgery, a complete mastoidectomy, in placebo group. After these findings, data was re-analyzed, and it was reported that endolymphatic sac surgery results on vertigo control and hearing preservation in short term were significantly better than the placebo procedure [53].

Ostrowski et al. reported that 72% of their patients were significantly improved in long term [43]. Very large group of patients, 3000, had over 90% complete or substantial control of vertigo after 3 years of endolymphatic sac decompression [54].

Kitahara et al. reported that vertigo attacks of patients who received endolymphatic sac surgery, with intraendolymphatic sac steroid injection, had significantly declined, compared to the patients who refused surgery, after 12 years of observation [55].

Cochrane review on surgery for Meniere's disease in 2013 analyzed the literature. Only two studies were suitable for inclusion. Neither of these studies' results were significantly effective on Meniere's disease symptom control, and they reported that the recent data was insufficient in order to demonstrate the benefits of endolymphatic sac surgery [56].

Sood et al. published a meta-analysis on endolymphatic sac surgery procedures. They compared the results of decompression, mastoid shunt with silastic tube and without silastic tube, in short- and long term. Decompression or shunt procedures were found to have similar vertigo control rates in short term, and the same results were observed in long term. Also no significant difference was reported between shunting procedures with or without silastic tube usage. Rates of vertigo control or hearing preservation were found similar between these procedures in short and long term. However hearing preservation results were significantly better in shunting without silastic in short- and long term.

Shunting and decompression have similar effects, but the usage of silastic tube for shunting procedure is not advised [57].

Silverstein compared the results of 83 patients who received endolymphatic sac surgery, vestibular neurectomy, and labyrinthectomy to 50 patients who were surgical candidates but refused the intervention. About 70% of patients who refused the surgery found to be freed of their vertigo attacks in 8.3 years [48].



Saliba et al. described a new approach by blocking the endolymphatic duct. They randomly distributed patients into two groups, and endolymphatic sac decompression and endolymphatic blockage were performed. They compared the results of endolymphatic sac decompression and endolymphatic duct blockage. After 24 months of follow-up endolymphatic duct blockage group's vertigo spells were significantly improved. Also tinnitus and aural fullness were improved significantly [46].

The results of these procedures may vary between authors, but due to its relatively conservative nature and low complication rates, endolymphatic sac procedures were advised as first line of surgical treatment of intractable Meniere's disease.

### **3.2 Destructive surgical procedures**

When the medical or nondestructive surgical procedures are not able to control the vertigo or after these interventions vertigo is recurrent destruction of the effected side must be considered. Destruction of the labyrinth is the gold standard procedure in order to relieve the patient whose vertigo is caused by an inner ear problem. Remaining hearing is lost completely after labyrinthectomy. If hearing must be preserved, selective vestibular neurectomy should be considered. Both of these procedures' aim is to block any input that come from the defective side.

While blocking the input from the periphery, it is important to prepare the central for better compensation. Before offering any surgical intervention to the vestibular system, adequate vestibular rehabilitation should be tried. After labyrinthectomy or neurectomy, complete unilateral vestibular loss is created. It has been reported that early vestibular rehabilitation after vestibular neurectomy for acoustic neuroma showed improved results to adapt [58–60]. The pathology is different with Meniere's disease, but the result of the ablative procedures is similar. It is an accepted practice to improve the daily functions of the patients. The program should be customized for each patient. Somatosensory sensation is found to be adapted earlier, and within 3 weeks, the sensation of disequilibrium resolves, but gaining of postural stability may take months [61].

Patients' mental state is another important factor that affects the success of the treatment. Patients who had no mental stress found to have better results, compared to stressed ones. Also surgical interventions are found to have better results than nonsurgical treatment in psychologically affected group. The patients' state of mind is an important factor to be considered, and psychological support should be advised to all Meniere's disease effected patients [62]. Patients who have psychological stress like depression, vestibular rehabilitation might be helpful in diagnostic process. This program could help compensation of the remaining vestibular disorder as well as coping with its effects on their psychology. If rehabilitation fails after 4–6 weeks of trial, an unstable vestibular lesion should be added in the differential diagnosis list [63].

Ablative procedures are irreversible, and surgeon must carefully evaluate the patient. Documentation of the symptoms is important to guide the patient to the most appropriate treatment option. Further vestibular investigation should be performed with every patient. These tests provide very useful information on the location of the pathology, labyrinth dysfunction, and compensation statuses.

The observation of spontaneous, positional nystagmus with electronystagmography or videonystagmography means failure of central compensation. In case of an uncompensated peripheral vestibular lesion, vestibuloocular reflex results are persistently asymmetric after several tests. Resolution of this asymmetry is a clue of compensation. Dynamic posturography could provide additional information about

all systems that contribute to balance, like vision and somatosensory sense. When the test results are indicating a peripheral vestibular pathology, the offended side must be identified.

Unilateral caloric weakness, under normal oculomotor condition if spontaneous or positional nystagmus is observed, positional nystagmus that provoked with Dix-Hallpike maneuver, asymmetric findings on vestibular tests are indicate to a peripheral labyrinth dysfunction. If nystagmus is persistent, asymmetric results are present rotational chair test or dynamic posturography results indicate an abnormal sensory organization, patient is in an uncompensated status, however if nystagmus, asymmetric results resolve or posturography performance is improving, compensation status of the patient is improving with the advised treatment method.

Asymmetric sensorineural hearing loss is the best indicator to identify the affected side [64]. The other helpful but less reliable findings are tinnitus, aural fullness, the side that trigger the nystagmus, or asymmetric results from vestibular test batteries. Sometimes patients could describe tinnitus and aural fullness at the unsuspected ear, and this may be a clue of a beginning of a bilateral involvement. In this case if surgery is considered to be offered, the procedures that preserve the hearing should be advised [26].

If vertical or perverted nystagmus is present, oculomotor test results are abnormal, or in order to suppress the nystagmus visual fixation fails, it indicates the central nervous system involvement. Intracranial lesion of posterior fossa lesions could mimic the symptoms of peripheral pathologies; in order to eliminate these conditions, gadolinium-enhanced MRI studies must be performed [65]. If the patients are at high risk of general anesthesia or surgery due to their general health problem, nonsurgical destructive treatment options should be considered.

If surgery is the decided treatment method, the next step is to decide on the procedure. The most important factor in decision process is hearing function of the patients and his perception of their hearing. If patient has a residual hearing and he/she finds it useful, then vestibular neurectomy, which is aimed to preserve hearing, should be advised. If no evidence of remaining hearing or patient cannot acknowledge the hearing on the affected side, labyrinthectomy, which destructs the remaining hearing function completely, should be advised.

French Otorhinolaryngology Head and Neck Surgery Society guideline of Meniere's disease management advises to start with less invasive and destructive procedures, such as ventilation tube placement and endolymphatic sac surgery. Especially in bilateral cases, clinician is advised to avoid from any destructive procedures. If these approaches are insufficient, destructive procedures should be considered according to the hearing function of the patient [4]. European position statement on Meniere's disease management advise the destructive procedures as the fifth and last line of treatment [5]. International Consensus (ICON) on treatment of Meniere's disease also keeps the destructive surgical options as the last resort [3].

Meniere's disease's progressive nature, the risk of bilateral involvement in any time of the life and possibility of spontaneous relief of vertigo in years always have to be kept in mind. Paparella recommended that treatment should be started with less invasive and destructive options; if the current treatment method seemed to fail, more invasive and destructive procedures should be considered [1].

### **3.3 Destructive procedures**

#### *3.3.1 Labyrinthectomy*

If the affected side's hearing is not functional and the labyrinthine symptoms are recurrent, labyrinthectomy could be performed for any vestibular dysfunction.

If patients have profound hearing loss and have intractable vertigo or Tumarkin crisis and disease is unilateral, then labyrinthectomy should be considered [4]. It could be performed in a transcanal or transmastoid approach.

### *3.3.1.1 Transcanal labyrinthectomy*

Tympanomeatal flap is elevated transcanally and middle ear is visualized. Stapes is removed from the oval window in order to access to the bony part of labyrinth. If visualization of the vestibule is needed, the bone from the promontory that lies below the oval window to round window could be removed. Sacculle and utricle are identified and then removed. Access to the ampullae of the horizontal and superior semicircular canals is performed with a right angled instrument that is placed medial to the facial nerve and conducted with blind dissection. The bony part of the vestibule could be drilled to the round window to improve visualization and identification of the nerve that innervates the posterior semicircular canal, located to the posterior ampullae. Posterior semicircular canal nerve should be identified, and in order to not leave any residual PSCC function must be sectioned.

Some authors choose to pack the cavity with soluble packing materials that soaked with aminoglycoside, to prevent from its ototoxic effects and improve the surgery success.

### *3.3.1.2 Transmastoid labyrinthectomy*

Transmastoid labyrinthectomy is a gold standard procedure of the vestibular function destruction. Mastoid cortex is presented in retroauricular approach. Cortical mastoidectomy is performed, and sinodural angle and middle fossa dura should be carefully dissected to have adequate visualization to facial nerve and access to the vestibule and posterior canal ampullae. The antrum is identified and the dome of horizontal semicircular canal is visualized at the depth. The largest bur that fits between middle fossa dura and horizontal semicircular canal should be chosen. The drilling must be deepened with solid angle between the three bony semicircular canals before any canal lumen is opened. Lumens of bony canals are opened from the internal surface of each canal toward the center of a deeper bony cup until the labyrinthine bone is removed completely.

Horizontal semicircular canal is an important landmark to identify the tympanic segment of the facial nerve so it usually opened first. The drill should never rise to a level that is lateral to the inferior lip of the bony cup to prevent facial nerve injury. After horizontal canal is opened, dissection is continued toward its nonampullated end until the superior canal is identified and opened. The posterior canal is followed to its ampulla end. At this site, bleeding from subarcuate artery is expected and should be controlled. Following the posterior canal, ampulla is opened which is adjacent to the horizontal canal ampulla.

Dissection stays inside the cup, and inner surface of the posterior canal must be followed to prevent the injury of the second genu of the facial nerve. By skeletonize the facial canal and removal of and bony structure to limit the visualization should be removed to protect the facial nerve. Drilling should be carried on to the parallel of the facial nerve canal. After the posterior canal ampulla is opened, the bone that connects the three ampullae is removed. All membranous labyrinth is carefully removed, and the thin bone at the lateral end of the internal acoustic canal should be preserved.

### 3.3.1.3 Complications

It is not a complication but an expected result, but the remaining hearing of the ipsilateral ear is lost with vestibular function. Nystagmus could persist for days, and most of the patients are able to move without any assistance in 2–3 days, but the complete vestibular compensation takes months. Disequilibrium could persist in some patients.

Possible complications are facial nerve injury, CSF leak, and chronic disequilibrium. The dura of the posterior cranial fossa or IAC must be preserved to prevent CSF leak or meningitis.

### 3.3.1.4 Results

Labyrinthectomy is the oldest procedure to treat Meniere's disease and gold standard. Wareing and O'Connor demonstrated that vertigo control rates of labyrinthectomy are 93–100%; however in longer follow-up 76% of the patients reported to have residual symptoms. Possible incomplete removal of the vestibular tissue might be the reason of recurrence in long term [66]. It is also reported that some patients have hard time of compensation, first 1 or 2 weeks of disequilibrium is expected but it could take months for fully compensation also inadequate removal of the vestibular tissue could cause these residual symptoms [67]. Vertigo control rates are superior compared to vestibular neurectomy or endolymphatic sac surgery [68].

### 3.3.2 Vestibular neurectomy

The aim of this procedure is to inhibit the inputs from peripheral vestibular system and prevent the cochlear nerve to protect remaining hearing. It has high vertigo control rates which vary from 80 to 95% but still not better than labyrinthectomy [26].

### 3.3.3 Translabyrinthine approach and transcochlear approach

For these approaches, common labyrinthectomy is performed. Then the dissection is carried on with intradural dissection of the vestibular nerve within IAC. The vestibular nerve is dissected to the medial of Scarpa's ganglion. After labyrinthectomy is performed in transmastoid approach, IAC dura is identified and opened. The division of vestibular nerve to superior and inferior is identified and sectioned.

Transcochlear approach begins with transcanal labyrinthectomy. Then the cochlea is opened and cochlear nerve is followed in IAC with vestibular nerve. This approach aims to decrease tinnitus. However these approaches contain high risk of CSF leak and meningitis, and desired results could be achieved with adequate transmastoid labyrinthectomy [69].

### 3.3.4 Middle fossa approach

House was the first surgeon to introduce middle fossa approach for vestibular neurectomy in 1961 [70]. Later it was improved by Fisch and Glasscock et al. in the 1970s [71–73].

It is a very refined surgical procedure, and vestibular nerve fibers are identified in the lateral part of IAC where the vestibular nerve separates from the cochlear nerve.

Temporal craniotomy that is centered to external auditory canal is performed. Dura is elevated from the temporal bone and the temporal lobe is retracted. Dura of IAC is skeletonized; in order to prevent further injury to the cochlea, superior semicircular canal, and facial nerve, dissection should be carried around IAC widely. First superior then inferior vestibular nerve are identified and sectioned. While sectioning of inferior vestibular nerve, labyrinthine artery must be preserved. This artery is located close to the inferior vestibular nerve at the distal part of IAC.

### 3.3.5 Retrolabyrinthine approach

Retrolabyrinthine approach for vestibular neurectomy was first described by Silverstein and Norrell [74, 75]. Retrolabyrinthine approach was developed in the 1980s, and it was reported to have lower facial nerve injury and hearing loss [75–77]. This procedure is also simpler than middle fossa approach. The eighth cranial nerve is only exposed between the brainstem and IAC; therefore it may be harder to identify auditory nerve than vestibular nerve specifically.

Dandy reported eighth cranial nerve section for vertigo treatment with suboccipital craniotomy in the 1930s, and long-term follow-up results were reported at 90% rate of complete vertigo control [78, 79]. This approach is named “retrosigmoid approach” nowadays.

The middle and posterior dura should be decompressed widely to get an ideal exposure, and retrosigmoid dura should be uncovered at least 1.5 cm posterior to the sigmoid sinus. This should allow enough extradural retraction. The bone that covers sigmoid sinus anteriorly is removed to the bony labyrinth's outline. Jugular bulb is the inferior limit of the dissection. Appropriate precautions should be taken to prevent the bone dust to enter the middle ear space.

The presigmoid dura and endolymphatic sac are incised parallel to sigmoid sinus to expose the posterior fossa dura. The cerebellum is retracted to visualize the cerebellopontine angle. Tentorium cerebelli and trigeminal nerve are identified superiorly, and the eighth cranial nerve is located inferiorly. This angle allows to visualize the posterior side of the petrous bone, so the internal acoustic canal is not visible. With minor retraction of the eighth cranial nerve, facial nerve could be visualized and advised to be controlled with electrostimulation. Vestibular fibers of the eighth nerve are located caudally (superiorly); this portion should be divided from the inferior portion of the nerve and separated with sharp dissection.

Musculus temporalis fascia is advised to be used for dural closure in order to prevent cerebrospinal fluid leak. The aditus ad antrum is blocked with fascia, and mastoidectomy defect is filled with harvested abdominal fat graft.

Retrosigmoid approach has some disadvantages such as the restricted recognition of vestibular and cochlear nerve, incomplete section of vestibular nerve, and possible damage to the cochlear nerve. However the hearing results of this approach were reported the same with other approaches. Postoperative headache is another significant trouble due to the intradural retraction of the cerebellum. Fukuhara et al. suggested the use of lumbar drainage for decompression of posterior fossa before the operation and reported that their operation time shortened, no CSF leakage occurred, and postoperative headache incidence is lowered [80].

Retrolabyrinthine-retrosigmoid combined approach was modified by Silverstein and his team in 1985. This modification allows effective access to cerebellopontine angle, and distinction of vestibular and cochlear nerve is clearer. Later they reported 85% of the patients had complete vertigo control, and the hearing preservation results were called “excellent.” Only 20% of the patients had minor change at hearing, and only 4% of them experienced serious sensorineural hearing loss [81].

In order to identify cochlear and vestibular nerve clearer, some surgeons combine retrolabyrinthine approach with retrosigmoid approach. This procedure allows to remove the bone behind internal acoustic canal for better distinction of the nerve bundles [81, 82]. Retrolabyrinthine-retrosigmoid combined approach is still a gold standard in vestibular neurectomy procedure [83].

### *3.3.6 Infralabyrinthine approach*

This technique is rarely used for vestibular neurectomy. The posterior semicircular canal is outlined, and the retrofacial air cells are tracted inferiorly. Internal acoustic canal is located inferiorly to the bony labyrinth.

Intradural dissection is limited to the internal acoustic canal's distal part, and vestibular nerve could be clearly identified while preserving the facial nerve. However poorly pneumatized temporal bones are hard to be dissected with this technique [84].

Intradural approaches for vestibular neurectomy could have serious complications such as stroke, subdural hematoma, and meningitis. Another life-changing complication is facial nerve paralysis, but rarely reported. Sensorineural hearing loss is another complication, reported in less than 10% of the cases [85].

#### *3.3.6.1 Results*

Most of the patients return to their daily lifestyle 2–4 months after the surgery. Vertigo control rates of vestibular neurectomy is slightly worse than labyrinthectomy, reported 80–95% [86].

## **3.4 Comparison of surgical interventions**

Surgery is the last resort for Meniere's disease. Most of the patients' symptoms could be taken under control with less invasive methods. If surgery is on the table, it is decided upon the patients hearing and general health performance. The ideal result of the surgery must control the vestibular symptoms completely while, if present, hearing should be preserved.

Endolymphatic sac decompression is frequently performed procedure if patient has remaining hearing function. Recent Cochrane review investigated the results of endolymphatic sac decompression with other procedures. Two randomized controlled studies were included. Bretlau et al. compared endolymphatic sac shunt to placebo procedure. Placebo procedure was simple mastoidectomy. The second study was by Thomsen et al.; they compared endolymphatic sac shunt to ventilation tube insertion. Vertigo control and hearing preservation were found the same at both studies. Bretlau reported the tinnitus was improved in both groups; however, Thomsen did not find any difference between the two groups. Both of the studies used different procedures as placebo and reported that 70% of their patients had been relieved of their symptoms regardless the procedure. However it is emphasized that the blinding of the studies were poor and methodic quality is low [22].

Moffat [87], Huang and Lin [88], Gibson [89], and Gianoli et al. [90] reported their 2-year results after endolymphatic sac surgery and reported that their vertigo control rates were 43.0, 84.4, 56.8, and 60.0%, while their hearing preservation with less than 10 dB loss or improvement 10 dB or more were reported 74.0, 83.4, 44.2, and 82.0%. However these studies were lack of comparison groups.

Kitahara et al. suggested that high dose of steroid administration during endolymphatic sac drainage to improve the effectiveness of the procedure. While the endolymphatic sac was opened in to mastoidectomy cavity, steroid was applied

around the sac. All of their patients had intractable disease and are grouped blindly into two groups, while the group 1 was administered steroids during surgery and group 2 did not. Patients who had intractable disease but refused surgical intervention were used as control group, Group 3. Surgery group was reported to have better vertigo control rates than nonsurgery group after 7-year follow-up, while there was no significant difference between group 1 and group 2. Steroid-administered group 1's hearing function results were significantly better than group 2. Later they reported their findings in 2013 while including group 1 and nonsurgical group 3. Group 1 reported to have significantly better hearing and vertigo control rates [91].

Paparella and Fina investigated over 2000 patients who went through endolymphatic sac enhancement surgery. Seventy-five percent of the patients had complete relief from vertigo, and over 90% of them reported that their vertigo was improved. Only 5% of the patients had revision usually 3–4 years after the first procedure. They reported that hearing preservation was achieved over 98% of the patients, and 40% of the patients hearing were improved. Serious sensorineural hearing loss after endolymphatic sac procedure was reported only to be 2% [92].

Endolymphatic sac shunt and endolymphatic sac decompression are similar operations, and both of them have similar results like more than 70% of vertigo control [93]. Further investigations of shunt procedures according to their choice on silastic placement and direct shunting to mastoidectomy cavity. Patients' hearing functions were reported better when silastic tube had not been placed, but vertigo control rates were found similar (75.0–76.9%) [55, 91].

Endolymphatic sac surgery's safety in elder population is also investigated and established as safe. Sajjadi et al. presented their results in elder Meniere's disease patients aged 65 years and older. Seventy-seven percent of their patients reported to have complete relieve of vertigo in 2-year follow-up, and no significant complications, sequels, or deaths were reported. The most major complication that reported was cardiac arrhythmia which was recorded on 1.6% of the patients [94].

Vestibular neurectomy is another option while residual hearing presents. Vestibular neurectomy with middle cranial fossa approach had 90% or above at vertigo control while hearing preservation rates are reported to be 76–92% in 2-year follow-up. However the long-term results showed that vestibular neurectomy did not prevent the hearing loss progression, and 5–10 years after the procedure, nearly 50% of the patients had hearing loss [95, 96].

Quaranta et al. reported their findings on hearing preservation of patients who had vestibular neurectomy, another group who had endolymphatic sac surgery, and the group who refused to had any surgical interventions. Hearing preservation rates were 58.6% in vestibular neurectomy group, 58.8% in endolymphatic sac surgery group, and 50.0% of nonsurgical group in long-term follow-up, and no significant difference was found [97].

Recent review of Kitahara et al. reviewed the results of different surgical intervention results for intractable Meniere's disease in 5–10 years. They also included nonsurgical destructive treatment and intratympanic gentamicin administration's results. Over 90% of vestibular neurectomy cases, complete vertigo control achieved while intratympanic gentamicin control rates were over 80%, endolymphatic sac surgery control rates were 70–80% and nonsurgical group vertigo control rates were 25–70%. They also evaluated the hearing function preservation (10 dB or higher) [93]. Their results were summarized in **Table 3**.

While vestibular neurectomy is superior to control vertigo attacks, endolymphatic sac surgery has better hearing preservation rates.

Labyrinthectomy is still the gold standard to control peripheral vertigo. However it is a highly destructive procedure. It destroys peripheral vestibular organ as well as the remaining hearing function. It is advised for patients who had total

	Complete vertigo control (%)	Hearing preservation >10 dB (%)
Vestibular neurectomy	>90	50–60
Intratympanic gentamicin	>80	50–60
Endolymphatic sac surgery	70–80	60–80
Nonsurgical	25–70	25–50

**Table 3.**  
*Results of interventions to intractable Meniere's disease in 5–10 years.*

hearing loss at the affected ear. Selective vestibular neurectomy has advantages on this subject. Vestibular neurectomy interrupts the vestibular input while preserving the hearing functions. Both of these procedures have very successful vertigo control rates (98.8% for labyrinthectomy and 97.8% for vestibular neurectomy) [98–101].

De la Cruz et al. conducted a study to investigate the efficacy of surgical treatment modalities. They evaluated 3637 procedures that were performed on 30-year period, such as endolymphatic sac shunt, vestibular nerve section (translabyrinthine, retrolabyrinthine, retrosigmoid, and middle fossa approaches), and labyrinthectomy. They assessed the outcomes of these procedures with a questionnaire. Vertigo characteristics were reported to be improved at each group; endolymphatic sac shunt and vestibular neurectomy groups also had stated that their balance was improved. Some of the patients who had labyrinthectomy reported that their imbalance worsened after surgery. All groups reported that they still have some balance problems, while endolymphatic sac shunt group had less problems, and labyrinthectomy group's balance problems were worse than the other groups [102]. Glasscock et al. [103], Schuknecht [104], and Kemink et al. [105] also reported similar results.

It is reported that some patients' vertigo attacks were recurred after vestibular neurectomy. Incomplete nerve section, neuroma formation, inadequate compensation, vestibular disorder at the contralateral side, and unwanted nerve regeneration were suggested as an explanation for these cases [106].

Vestibular neurectomy with translabyrinthine approach and labyrinthectomy results is expected to be similar. De la Cruz et al. also compared these sub-groups with each other and found that over 80% of each group had complete control of vertigo; however labyrinthectomy groups stated that their current imbalance is more severe than the translabyrinthine vestibular neurectomy group [102]; similar results were reported by different authors [103–105].

Surgical outcomes are also related with preoperative factors. Teufert et al. designed a study to assess the prognostic factors that could affect surgical outcomes. They assessed patients with the AAO-HNS vertigo score and class, number of vertigo attacks per month, current and change in AAO-HNS disability rating, and vertigo and imbalance severity ratings and imbalance frequency. AAO-HNS disability rating, imbalance frequency and duration of symptoms were found related to outcome. Higher disability ratings and more frequent imbalance are related with poorer outcomes. Longer the symptoms had been presented, related with better outcome. The characteristic of the vertigo was not associated with outcome. Also patients who had contralateral tinnitus had worse outcome. If the first symptom was vertigo, tinnitus was present at contralateral side, and poor visual function is also found to be related with poor outcome [107].

In conclusion, there are many surgical procedures present nowadays, and each one of them has advantages as well as disadvantages. Some of the results were predictable, like hearing loss after labyrinthectomy. However surgeon must assess the patient thoroughly and choose the most appropriate procedure for him/her.



The outcome has a very close relationship with patients' psychological state. Patients who did not have any psychological problems were reported to have better outcomes from treatment (surgical or nonsurgical). Surgical procedures found to be more effective than nonsurgical treatment at the patients with psychological problems [62].

#### **4. Vestibular compensation after the surgery**

It could take months to compensate the loss of unilateral vestibular input. Thirty percent of the patients were reported to have disequilibrium after the vestibular surgery. Pereira and Kerr demonstrated that most patients after labyrinthectomy reported that their vertigo had been relieved completely, but only 50% of them were able to return to their routine lifestyles [108]. Vertigo control is the first goal of the surgery, but compensation after surgery should not be underestimated.

The recovery after vestibular neurectomy is reported longer than labyrinthectomy and usually more incomplete; it is reported that postoperative ataxia incidence of vestibular neurectomy is 11%, but labyrinthectomy rates are reported 2% [109].

Vestibular rehabilitation is mandatory for all patients before and after the surgery. The rehabilitation program should be customized for each patient. Patients who had additional sensory deficit, visual problems, or neurologic conditions are candidates for delayed recovery. Psychological factors also play an important role in recovery phase.

Labyrinthectomy failures could occur if the diagnosis had been wrong or the neuroepithelium removal had been performed incompletely. Vestibular compensation of these patients was inadequate. Late failures of this procedure could be a result of central decompensation, but it responds to vestibular rehabilitation [110].

Vestibular neurectomy failures are usually associated with incomplete section of the vestibular nerve fibers. If the condition worsens, revision surgery should be considered.

Vestibular rehabilitation has a very important role after vestibular neurectomy and labyrinthectomy. Both procedures cause a complete loss of unilateral vestibular function. Vestibular rehabilitation is accepted as the best way to improve imbalance problems and regenerate patients' daily functions. The rehabilitation program must be customized. The somatosensory system is the first one to adapt, disequilibrium reduces within 3 weeks, and postural stability prevails months after [111].

IntechOpen

IntechOpen

### **Author details**

Yetkin Zeki Yilmaz<sup>1\*</sup>, Begum Bahar Yilmaz<sup>1</sup> and Mehmet Yilmaz<sup>2</sup>

1 ENT, Cerrahpasa Medical Faculty, Istanbul University, Istanbul, Turkey

2 Yunus Emre Clinic, Turkey

\*Address all correspondence to: [dr\\_yzy@hotmail.com](mailto:dr_yzy@hotmail.com)

### **IntechOpen**

---

© 2020 The Author(s). Licensee IntechOpen. This chapter is distributed under the terms of the Creative Commons Attribution License (<http://creativecommons.org/licenses/by/3.0>), which permits unrestricted use, distribution, and reproduction in any medium, provided the original work is properly cited. 

## References

- [1] Sajjadi H, Paparella MM. Meniere's disease. *Lancet*. 2008. DOI: 10.1016/S0140-6736(08)61161-7
- [2] Arenberg I. Proposition for endolymphatic sac and duct surgery. In: Arenberg I, Graham MD, editors. *Treatment Options for Meniere's Disease*. Singular Publishing; 1998. pp. 19-23
- [3] Nevoux J, Barbara M, Dornhoffer J, Gibson W, Kitahara T, Darrouzet V. International consensus (ICON) on treatment of Ménière's disease. *European Annals of Otorhinolaryngology, Head and Neck Diseases*. 2018. DOI: 10.1016/j.anorl.2017.12.006
- [4] Nevoux J, Franco-Vidal V, Bouccara D, et al. Diagnostic and therapeutic strategy in Ménière's disease. Guidelines of the French Otorhinolaryngology-Head and Neck Surgery Society (SFORL). *European Annals of Otorhinolaryngology, Head and Neck Diseases*. 2017. DOI: 10.1016/j.anorl.2016.12.003
- [5] Magnan J, Ozgirgin ON, Trabalzini F, et al. European position statement on diagnosis, and treatment of Meniere's disease. *The Journal of International Advanced Otolaryngology*. 2018;14(2):317-321. DOI: 10.5152/iao.2018.140818
- [6] Nakashima T, Naganawa S, Sugiura M, et al. Visualization of endolymphatic hydrops in patients with Meniere's disease. *The Laryngoscope*. 2007;117(3):415-420. DOI: 10.1097/MLG.0b013e31802c300c
- [7] Naganawa S, Yamazaki M, Kawai H, Bokura K, Sone M, Nakashima T. Visualization of endolymphatic hydrops in Ménière's disease with single-dose intravenous gadolinium-based contrast media using heavily T2-weighted 3D-FLAIR. *Magnetic Resonance in Medical Sciences*. 2010. DOI: 10.2463/mrms.9.237
- [8] Naganawa S, Nakashima T. Visualization of endolymphatic hydrops with MR imaging in patients with Ménière's disease and related pathologies: Current status of its methods and clinical significance. *Japanese Journal of Radiology*. 2014. DOI: 10.1007/s11604-014-0290-4
- [9] De Sousa LCA, De Toledo Piza MR, Da Costa SS. Diagnosis of Meniere's disease: Routine and extended tests. *Otolaryngologic Clinics of North America*. 2002. DOI: 10.1016/S0030-6665(02)00029-4
- [10] Paparella MM. Methods of diagnosis and treatment of Meniere's disease. *Acta Oto-Laryngologica*. 1991. DOI: 10.3109/00016489109128050
- [11] Paparella MM, Mcdermott JC, Sousa LCA. Meniere's disease and the peak audiogram. *Archives of Otolaryngology*. 1982. DOI: 10.1001/archotol.1982.00790570021005
- [12] Dobie RA, Snyder JM, Donaldson JA. Electronystagmographic and audiologic findings in patients with Meniere's disease. *Acta Oto-Laryngologica*. 1982. DOI: 10.3109/00016488209128885
- [13] Young Y-H, Huang T-W, Cheng P-W. Vestibular evoked myogenic potentials in delayed endolymphatic hydrops. *The Laryngoscope*. 2002; 112(9):1623-1626. DOI: 10.1097/00005537-200209000-00018
- [14] Nedzelski JM, Schessel DA, Bryce GE, Pfliegerer AG. Chemical labyrinthectomy: Local application of gentamicin for the treatment of unilateral Ménière's disease. *The American Journal of Otolaryngology*. 1992

- [15] Doyle KJ, Bauch C, Battista R, et al. Intratympanic steroid treatment: A review. *Otology & Neurotology*. 2004. DOI: 10.1097/00129492-200411000-00031
- [16] Claes J, Van De Heyning PH. A review of medical treatment for Ménière's disease. *Acta Oto-Laryngologica*. 2000. DOI: 10.1080/000164800750044461
- [17] Santos PM, Hall RA, Snyder JM, Hughes LF, Dobie RA. Diuretic and diet effect on Meniere's disease evaluated by the 1985 committee on hearing and equilibrium guidelines. *Otolaryngology - Head and Neck Surgery*. 1993. DOI: 10.1177/019459989310900408
- [18] Konrad HR. Intractable vertigo—When not to operate. *Otolaryngology - Head and Neck Surgery*. 1986. DOI: 10.1177/019459988609500411
- [19] Monsell EM, Brackmann DE, Linthicum FH. Why do vestibular destructive procedures sometimes fail? *Otolaryngology - Head and Neck Surgery*. 1988. DOI: 10.1177/019459988809900505
- [20] Wiet RJ, Kazan R, Shambaugh GEJ. An holistic approach to Meniere's disease. Medical and surgical management. *The Laryngoscope*. 1981
- [21] Charpiot A, Rohmer D, Gentine A. Lateral semicircular canal plugging in severe Ménière's disease: A clinical prospective study about 28 patients. *Otology & Neurotology*. 2010. DOI: 10.1097/MAO.0b013e3181ca85a2
- [22] Pullens B, Hp V, Pp VB. Surgery for Ménière's disease (review). 2013;(2)
- [23] Schuknecht HF, Bartley M. Cochlear endolymphatic shunt for Meniere's disease. *The American Journal of Otology*. 1985
- [24] Schuknecht HF. Cochleosacculotomy for Meniere's disease: Internal endolymphatic shunt. *Operative Techniques in Otolaryngology-Head and Neck Surgery*. 1991. DOI: 10.1016/S1043-1810(10)80227-1
- [25] Kinney WC, Nalepa N, Hughes GB, Kinney SE. Cochleosacculotomy for the treatment of Meniere's disease in the elderly patient. *The Laryngoscope*. 1995. DOI: 10.1288/00005537-199509000-00012
- [26] Telian SA, Basura GJ. Surgery for vestibular disorders. In: Flint PW, Haughey BH, Lund VJ, et al., editors. *Cummings Otolaryngology: Head and Neck Surgery*. 6th ed. Saunders: Canada; 2015. pp. 2581-2593
- [27] Yamakawa K. Über die pathologische Veränderung bei einem Meniere-Kranken. *Journal of Otolaryngology*. 1938;44:2310-2312
- [28] Hallpike CS, Cairns H. Observations on the pathology of Ménière's syndrome. *Proceedings of the Royal Society of Medicine*. 1938. DOI: 10.1017/S0022215100003947
- [29] Committee on Hearing and Equilibrium guidelines for the diagnosis and evaluation of therapy in Meniere's disease. *Otolaryngology - Head and Neck Surgery*. 1995. DOI: 10.1016/S0194-5998(95)70102-8
- [30] Kaufman AI. Viral theory for Meniere's disease and endolymphatic hydrops: Overview and new therapeutic options for viral labyrinthitis. *Annals of the New York Academy of Sciences*. 1997. DOI: 10.1111/j.1749-6632.1997.tb51901.x
- [31] Kimura RS, Schuknecht HF, Ota CY, Jones DD. Obliteration of the ductus reuniens. *Acta Oto-Laryngologica*. 1980. DOI: 10.3109/00016488009127141

- [32] Paparella MM. Pathogenesis and pathophysiology of Meniere's disease. *Acta Oto-Laryngologica*. 1991. DOI: 10.3109/00016489109128041
- [33] Zechner G, Altmann F. Histological studies on the human endolymphatic duct and sac. *Practica oto-Rhino-Laryngologica*. 1969;**31**:65-83
- [34] Sando I, Ikeda M. The vestibular aqueduct in patients with Meniere's disease: A temporal bone histopathological investigation. *Acta Oto-Laryngologica*. 1984. DOI: 10.3109/00016488409132934
- [35] Ikeda M, Sando I. Endolymphatic duct and sac in patients with Meniere's disease: A temporal bone histopathological study. *The Annals of Otolaryngology, Rhinology, and Laryngology*. 1984. DOI: 10.1177/000348948409300603
- [36] Paparella MM, Sajjadi H. Endolymphatic sac revision for recurrent Meniere's disease. *The American Journal of Otolaryngology*. 1988
- [37] Paparella M, Sajjadi H. Endolymphatic sac procedures. In: Brackmann DE, Shelton C, Arriaga M, editors. *Otologic Surgery*. Philadelphia: WB Saunders; 2001. pp. 371-384
- [38] Arts HA, Kileny PR, Telian SA. Diagnostic testing for endolymphatic hydrops. *Otolaryngologic Clinics of North America*. 1997
- [39] Portmann G. Surgical treatment of vertigo by opening of the saccus endolymphaticus. *Archives of Otolaryngology*. 1969. DOI: 10.1001/archotol.1969.00770020811005
- [40] House W. Subarachnoid shunt for drainage of endolymphatic hydrops. *The Laryngoscope*. 1962;**72**:713-729
- [41] Paparella MM, And CSK, Shea DA. Sac decompression for refractory luetic vertigo. *Acta Oto-Laryngologica*. 1980. DOI: 10.3109/00016488009127172
- [42] Graham MD, Kemink JL. Surgical management of Meniere's disease with endolymphatic sac decompression by wide bony decompression of the posterior fossa dura: Technique and results. *The Laryngoscope*. 1984
- [43] Ostrowski VB, Kartush JM. Endolymphatic sac-vein decompression for intractable Meniere's disease: Long term treatment results. *Otolaryngology - Head and Neck Surgery*. 2003. DOI: 10.1016/S0194-5998(03)00084-6
- [44] Chung JW, Fayad J, Linthicum F, Ishiyama A, Merchant SN. Histopathology after endolymphatic sac surgery for Ménière's syndrome. *Otology & Neurotology*. 2011. DOI: 10.1097/MAO.0b013e31821553ce
- [45] Linthicum FH, Santos F. Endolymphatic sac amputation without hydrops. *Otology & Neurotology*. 2011. DOI: 10.1097/MAO.0b013e3181db733e
- [46] Saliba I, Gabra N, Alzahrani M, Berbiche D. Endolymphatic duct blockage: A randomized controlled trial of a novel surgical technique for Ménière's disease treatment. *Otolaryngology - Head and Neck Surgery*. 2015. DOI: 10.1177/0194599814555840
- [47] Sennaroglu L, Sennaroglu G, Gursel B, Dini FM. Intratympanic dexamethasone, intratympanic gentamicin and endolymphatic sac surgery for intractable vertigo in Meniere's disease. *Otolaryngology - Head and Neck Surgery*. 2001. DOI: 10.1067/mhn.2001.119485
- [48] Silverstein H, Smouha E, Jones R. Natural history vs. surgery for Meniere's disease. *Otolaryngology - Head and Neck Surgery*. 1989. DOI: 10.1177/019459988910000102

- [49] Jackson CG, Dickins JR, McMenomey SO, et al. Endolymphatic system shunting: A long-term profile of the Denver inner ear shunt. *The American Journal of Otolaryngology*. 1996
- [50] Smith DR, Pyle GM. Outcome-based assessment of endolymphatic sac surgery for Meniere's disease. *The Laryngoscope*. 1997. DOI: 10.1097/00005537-199709000-00010
- [51] Pensak ML, Friedman RA. The role of endolymphatic mastoid shunt surgery in the managed care era. *The American Journal of Otolaryngology*. 1998
- [52] Huang TS, Lin CC, Chang YL. Endolymphatic sac surgery for Meniere's disease: A cumulative study of twelve years' experience. *Acta Oto-Laryngologica*. 1991. DOI: 10.3109/00016489109128054
- [53] Welling DB, Nagaraja HN. Endolymphatic mastoid shunt: A reevaluation of efficacy. *Otolaryngology - Head and Neck Surgery*. 2000. DOI: 10.1067/mhn.2000.101575
- [54] Huang TS. Endolymphatic sac surgery for Meniere's disease: Experience with over 3000 cases. *Otolaryngologic Clinics of North America*. 2002. DOI: 10.1016/S0030-6665(02)00027-0
- [55] Kitahara T, Fukushima M, Uno A, et al. Long-term results of endolymphatic sac drainage with local steroids for intractable Meniere's disease. *Auris, Nasus, Larynx*. 2013. DOI: 10.1016/j.anl.2012.11.008
- [56] Pullens B, Verschuur HP, Van Benthem PP. Surgery for Ménière's disease. *Cochrane Database of Systematic Reviews* 2013. doi:10.1002/14651858.CD005395.pub3
- [57] Sood AJ, Lambert PR, Nguyen SA, Meyer TA. Endolymphatic sac surgery for ménière's disease: A systematic review and meta-analysis. *Otology & Neurotology*. 2014;35(6):1033-1045. DOI: 10.1097/MAO.00000000000000324
- [58] Vereeck L, Wuyts FL, Truijten S, De Valck C, Van de Heyning PH. The effect of early customized vestibular rehabilitation on balance after acoustic neuroma resection. *Clinical Rehabilitation*. 2008. DOI: 10.1177/0269215508089066
- [59] Enticott JC, O'Leary SJ, Briggs RJS. Effects of vestibulo-ocular reflex exercises on vestibular compensation after vestibular schwannoma surgery. *Otology & Neurotology*. 2005. DOI: 10.1097/00129492-200503000-00024
- [60] Tjernström F, Fransson PA, Kahlon B, et al. Vestibular PREHAB and gentamicin before schwannoma surgery may improve long-term postural function. *Journal of Neurology, Neurosurgery, and Psychiatry*. 2009. DOI: 10.1136/jnnp.2008.170878
- [61] Gottshall KR, Topp SG, Hoffer ME. Early vestibular physical therapy rehabilitation for Meniere's disease. *Otolaryngologic Clinics of North America*. 2010;43(5):1113-1119. DOI: 10.1016/j.otc.2010.05.006
- [62] Yokota Y, Kitahara T, Sakagami M, et al. Surgical results and psychological status in patients with intractable Ménière's disease. *Auris, Nasus, Larynx*. 2016;43(3):287-291. DOI: 10.1016/j.anl.2015.10.007
- [63] Telian SASNT. Update on vestibular rehabilitation therapy. *Otolaryngologic Clinics of North America*. 1996
- [64] Shone G, Kemink JL, Telian SA, Shone GR. Prognostic significance of hearing loss as a lateralizing indicator in the surgical treatment of vertigo. *The Journal of Laryngology and Otolaryngology*. 1991. DOI: 10.1017/S0022215100116834

- [65] Disher M, Telian S, Kemink JL. Evaluation of acute vertigo: Unusual lesions imitating vestibular neuritis. *The American Journal of Otology*. 1991; **12**(3):227-231
- [66] Wareing MJ, O'Connor AF. The role of labyrinthectomy and cochlear implantation in Meniere's disease. *Ear, Nose, & Throat Journal*. 1997
- [67] Alarcón AV, Hidalgo LOV, Arévalo RJ, Diaz MP. Labyrinthectomy and vestibular neurectomy for intractable vertiginous symptoms. *International Archives of Otorhinolaryngology*. 2017. DOI: 10.1055/s-0037-1599242
- [68] Kartush J. Endolymphatic sac surgery. In: Arriaga M, editor. *Essentials of Neurotology*. London: Thieme; 2002
- [69] Langman AW, Lindeman RC. Surgery for vertigo in the nonserviceable hearing ear: Transmastoid labyrinthectomy or translabyrinthine vestibular nerve section. *The Laryngoscope*. 1993. DOI: 10.1288/00005537-199312000-00001
- [70] House W. Surgical exposure of the internal auditory canal and its contents through the middle cranial fossa. *The Laryngoscope*. 1961;**71**:1363
- [71] Fisch U. Vestibular and cochlear neurectomy. *Transactions of the American Academy of Ophthalmology and Otolaryngology*. 1974;**78**(4):252-255
- [72] Glasscock M 3rd. Vestibular nerve section. Middle fossa and translabyrinthine. *Archives of Otolaryngology*. 1973;**97**(2):112-114
- [73] Glasscock ME, Kveton JF, Christiansen SG. Middle fossa vestibular neurectomy: An update. *Otolaryngology - Head and Neck Surgery*. 1984. DOI: 10.1177/019459988409200215
- [74] Silverstein H, Norrell H. Retrolabyrinthine surgery: A direct approach to the cerebellopontine angle. In: Silverstein H, Norrell H, editors. *Neurological Surgery of the Ear*. Birmingham, AL: Aesculapius; 1979. pp. 318-322
- [75] Silverstein H, Norrell H. Retrolabyrinthine surgery: A direct approach to the cerebellopontine angle. *Otolaryngology - Head and Neck Surgery*. 1980. DOI: 10.1177/019459988008800425
- [76] House JW, Hitselberger WE, Mcelveen J, Brackmann DE. Retrolabyrinthine section of the vestibular nerve. *Otolaryngology - Head and Neck Surgery*. 1984. DOI: 10.1177/019459988409200214
- [77] Kemink JL, Hoff JT. Retrolabyrinthine vestibular nerve section: Analysis of results. *The Laryngoscope*. 1986
- [78] Dandy WE. Benign, encapsulated tumors in the lateral ventricles of the brain. *The Journal of Nervous and Mental Disease*. 2006. DOI: 10.1097/00005053-193510000-00042
- [79] Green R. Surgical treatment of vertigo with follow up on Walter Dandy's cases. In: *Proceedings of the Congress of Neurological Surgeons*. Baltimore: Williams and Williams; 1958. p. 141
- [80] Fukuhara T, Silverman DA, Hughes GB, et al. Vestibular nerve sectioning for intractable vertigo: Efficacy of simplified retrosigmoid approach. *Otology & Neurotology*. 2002. DOI: 10.1097/00129492-200201000-00016
- [81] Silverstein H, Norrell H, Smouha EE. Retrosigmoid-internal auditory canal approach vs. retrolabyrinthine approach for vestibular neurectomy. *Otolaryngology - Head and*

Neck Surgery. 1987. DOI: 10.1177/  
019459988709700309

[82] McKenna MJ, Nadol JB Jr, Ojemann RG, Halpin C. Vestibular neurectomy: Retrosigmoid-intracanalicular versus retrolabyrinthine approach. *The American Journal of Otolaryngology*. 1996

[83] Silverstein H, Norrell H, Smouha E, Jones R. Combined retrolab-retrosigmoid vestibular neurectomy. An evolution in approach. *The American Journal of Otolaryngology*. 1989

[84] Vernick DM. Infralabyrinthine approach to the internal auditory canal. *Otolaryngology - Head and Neck Surgery*. 1990. DOI: 10.1177/  
019459989010200401

[85] Moody-Antonio S, House JW. Hearing outcome after concurrent endolymphatic shunt and vestibular nerve section. *Otolaryngology & Neurotology*. 2003. DOI: 10.1097/00129492-200305000-00016

[86] Green JD, Shelton C, Brackmann DE. Middle fossa vestibular neurectomy in retrolabyrinthine neurectomy failures. *Archives of Otolaryngology - Head and Neck Surgery*. 1992. DOI: 10.1001/archotol.1992.01880100048012

[87] Moffat DA. Endolymphatic sac surgery: Analysis of 100 operations. *Clinical Otolaryngology and Allied Sciences*. 1994. DOI: 10.1111/j.1365-2273.1994.tb01228.x

[88] Huang TS, Lin CC. Endolymphatic sac ballooning surgery for Meniere's disease. *The Annals of Otolaryngology, Rhinology, and Laryngology*. 1994. DOI: 10.1177/000348949410300509

[89] Gibson WPR. The effect of surgical removal of the extraosseous portion of the endolymphatic sac in patients suffering from Meniere's disease.

*The Journal of Laryngology and Otolaryngology*. 1996. DOI: 10.1017/S0022215100135637

[90] Gianou GJ, Larouere MJ, Kartush JM, Wayman J. Sac-vein decompression for intractable Meniere's disease: Two-year treatment results. *Otolaryngology - Head and Neck Surgery*. 1998. DOI: 10.1016/S0194-5998(98)70370-5

[91] Kitahara T, Kubo T, Okumura SI, Kitahara M. Effects of endolymphatic sac drainage with steroids for intractable Ménière's disease: A long-term follow-up and randomized controlled study. *The Laryngoscope*. 2008. DOI: 10.1097/MLG.0b013e3181651c4a

[92] Paparella M. Revision of endolymphatic sac surgery for recurrent Meniere's disease. *Otolaryngologic Clinics of North America*. 2002;35(3): 607-619. DOI: 10.1016/S0030-6665(02)00032-4

[93] Kitahara T. Evidence of surgical treatments for intractable Meniere's disease. *Auris, Nasus, Larynx*. 2018; 45(3):393-398. DOI: 10.1016/j.anl.2017.07.016

[94] Sajjadi H, Paparella MM, Williams T. Endolymphatic sac enhancement surgery in elderly patients with Meniere's disease. *Ear, Nose, & Throat Journal*. 1998

[95] Silverstein H, Rosenberg S, Arruda J, Isaacson JE. Surgical ablation of the vestibular system in the treatment of Meniere's disease. *Otolaryngologic Clinics of North America*. 1997

[96] Tewary AK, Riley N, Kerr AG. Long-term results of vestibular nerve section. *The Journal of Laryngology and Otolaryngology*. 1998. DOI: 10.1017/S0022215100142719

[97] Quaranta A, Onofri M, Sallustio V, Iurato S. Comparison of long-term



hearing results after vestibular neurectomy, endolymphatic mastoid shunt, and medical therapy. *The American Journal of Otolaryngology*. 1997

[98] Fisch U. Middle fossa vestibular neurectomy. In: Silverstein H, Norrell H, editors. *Neurological Surgery of the Ear*. Aesculapius; 1977

[99] Hammerschlag PE, Schuknecht HF. Transcanal labyrinthectomy for intractable vertigo. *Archives of Otolaryngology*. 1981. DOI: 10.1001/archotol.1981.00790390018006

[100] Levine SC, Glasscock M, McKennan KX. Long-term results of labyrinthectomy. *The Laryngoscope*. 2006. DOI: 10.1288/00005537-199002000-00003

[101] Iurato S, Onofri M. A five to thirteen year follow-up of thirty-one consecutive cases of vestibular neurectomy for Meniere's disease. In: Nadol JBJ, editor. *Second International Symposium on Meniere's Disease*. Cambridge; 1988. pp. 563-566

[102] De la Cruz A, Teufert KB, Berliner KI. Surgical treatment for vertigo: Patient survey of vertigo, imbalance, and time course for recovery. *Otolaryngology - Head and Neck Surgery*. 2006. DOI: 10.1016/j.otohns.2006.05.011

[103] Glasscock ME, Davis WE, Hughes GB, Jackson CG. Labyrinthectomy versus middle fossa vestibular nerve section in Meniere's disease; a critical evaluation of relief of vertigo. *The Annals of Otolaryngology, Rhinology, and Laryngology*. 1980. DOI: 10.1177/000348948008900405

[104] Schuknecht HF. Behavior of the vestibular nerve following labyrinthectomy. *The Annals of Otolaryngology, Rhinology, and Laryngology*. 1982

[105] Kemink JL, Telian SA, Graham MD, Joynt L. Transmastoid labyrinthectomy: Reliable surgical management of vertigo. *Otolaryngology - Head and Neck Surgery*. 1989. DOI: 10.1177/019459988910100102

[106] Thedinger BS, Thedinger BA. Analysis of patients with persistent dizziness after vestibular nerve section. *Ear, Nose, & Throat Journal*. 1998

[107] Teufert KB, Berliner KI, De La Cruz A. Persistent dizziness after surgical treatment of vertigo: An exploratory study of prognostic factors. *Otolaryngology & Neurotology*. 2007. DOI: 10.1097/MAO.0b013e318157fdd0

[108] Pereira KD, Kerr AG. Disability after labyrinthectomy. *The Journal of Laryngology and Otolaryngology*. 2007. DOI: 10.1017/s0022215100133237

[109] Gacek RR, Gacek MR. Comparison of labyrinthectomy and vestibular neurectomy in the control of vertigo. *The Laryngoscope*. 1996;106(2): 225-230. DOI: 10.1097/00005537-199602000-00023

[110] Katsarkas A, Segal BN. Unilateral loss of peripheral vestibular function in patients: Degree of compensation and factors causing decompensation. *Otolaryngology - Head and Neck Surgery*. 1988. DOI: 10.1177/019459988809800108

[111] Magnusson M, Kahlon B, Karlberg M, Lindberg S, Siesjö P, Tjernström F. Vestibular "pREHAB.". *Annals of the New York Academy of Sciences*. 2009. DOI: 10.1111/j.1749-6632.2009.03778.x