

10-2019

## **Keratoconus in a patient with Alport syndrome: A case report**

Majid Moshirfar

David F. Skanchy

Aaron T. Gomez

*The University of Texas Rio Grande Valley*

Yasmyne C. Ronquillo

Benjamin Buckner

*See next page for additional authors*

Follow this and additional works at: [https://scholarworks.utrgv.edu/som\\_pub](https://scholarworks.utrgv.edu/som_pub)



Part of the [Ophthalmology Commons](#)

---

### **Recommended Citation**

Moshirfar, M., Skanchy, D. F., Gomez, A. T., Ronquillo, Y. C., Buckner, B., & Hoopes, P. C. (2019). Keratoconus in a patient with Alport syndrome: A case report. *World Journal of Clinical Cases*, 7(19), 3012–3017. <https://doi.org/10.12998/wjcc.v7.i19.3012>

This Article is brought to you for free and open access by the School of Medicine at ScholarWorks @ UTRGV. It has been accepted for inclusion in School of Medicine Publications and Presentations by an authorized administrator of ScholarWorks @ UTRGV. For more information, please contact [justin.white@utrgv.edu](mailto:justin.white@utrgv.edu), [william.flores01@utrgv.edu](mailto:william.flores01@utrgv.edu).

---

**Authors**

Majid Moshirfar, David F. Skanchy, Aaron T. Gomez, Yasmyne C. Ronquillo, Benjamin Buckner, and Phillip C. Hoopes

## Keratoconus in a patient with Alport syndrome: A case report

Majid Moshirfar, David F Skanchy, Aaron T Gomez, Yasmyne C Ronquillo, Benjamin Buckner, Phillip C Hoopes

**ORCID number:** Majid Moshirfar (0000-0003-1024-6250); David F Skanchy (0000-0002-7400-6232); Aaron T Gomez (0000-0002-2835-7218); Yasmyne C Ronquillo (0000-0002-8852-4380); Benjamin Buckner (0000-0003-0641-889X); Phillip C Hoopes (0000-0002-2567-8331).

**Author contributions:** Moshirfar M was the patient's physician with all authors contributing by reviewing the literature, manuscript drafting, and manuscript revisions. All authors issued final approval for this version to be submitted.

**Informed consent statement:** Informed consent was obtained from the patient for publication of this report.

**Conflict-of-interest statement:** The authors declare that they have no conflict of interest.

**CARE Checklist (2016) statement:** The manuscript was prepared and revised according to the CARE Checklist (2016).

**Open-Access:** This article is an open-access article which was selected by an in-house editor and fully peer-reviewed by external reviewers. It is distributed in accordance with the Creative Commons Attribution Non Commercial (CC BY-NC 4.0) license, which permits others to distribute, remix, adapt, build upon this work non-commercially, and license their derivative works on different terms, provided the original work is properly cited and the use is non-commercial. See: <http://creativecommons.org/licenses/by-nc/4.0/>

**Manuscript source:** Unsolicited

**Majid Moshirfar**, John A. Moran Eye Center, Department of Ophthalmology and Visual Sciences, University of Utah School of Medicine, Salt Lake City, UT 84101, United States

**Majid Moshirfar**, Utah Lions Eye Bank, Salt Lake City, UT 84101, United States

**Majid Moshirfar, Yasmyne C Ronquillo, Benjamin Buckner, Phillip C Hoopes**, Hoopes Durrie Rivera Research Center, Hoopes Vision, Draper, UT 84020, United States

**David F Skanchy**, Kellogg Eye Center, Department of Ophthalmology, University of Michigan Medical School, Ann Arbor, MI 48103, United States

**Aaron T Gomez**, The University of Texas Rio Grande Valley School of Medicine, Edinburg, TX 78542, United States

**Corresponding author:** Majid Moshirfar, FACS, MD, Adjunct Professor, Director, Hoopes Durrie Rivera Research Center, Hoopes Vision, 11820 S. State Street Suite No.200, Draper, UT 84020, United States. [cornea2020@me.com](mailto:cornea2020@me.com)

**Telephone:** +1-435-5680200

**Fax:** +1-435-5630200

### Abstract

#### BACKGROUND

Known ocular manifestations of Alport syndrome include features such as anterior lenticonus and fleck retinopathy. Reports of keratoconus in such patients are limited. We report tomographic findings consistent with keratoconus in a patient with Alport syndrome.

#### CASE SUMMARY

A 52-year-old female was referred to our ophthalmology clinic with decreased vision and increased tearing. She was diagnosed with stage III Alport syndrome two years prior. Upon examination she was found to have average keratometries of 48 D bilaterally with tomographic evidence of keratoconus.

#### CONCLUSION

Although a rare presentation, concurrent Alport syndrome and keratoconus should be considered when reviewing the ocular health of Alport syndrome patients and appropriate management steps should be taken upon the diagnosis.

**Key words:** Alport syndrome; Keratoconus; Type IV collagen; COL4A genes; Corneal ectasia; Case report

©The Author(s) 2019. Published by Baishideng Publishing Group Inc. All rights reserved.

manuscript

**Received:** May 15, 2019**Peer-review started:** May 21, 2019**First decision:** July 30, 2019**Revised:** September 2, 2019**Accepted:** September 9, 2019**Article in press:** September 9, 2019**Published online:** October 6, 2019**P-Reviewer:** Liang Y**S-Editor:** Zhang L**L-Editor:** A**E-Editor:** Liu MY

**Core Tip:** Various ocular manifestations of Alport syndrome have been well described. However, reports of keratoconus in the presence of Alport syndrome is limited in the literature. Keratoconus is a form of corneal ectasia and has shown disorganized and thinning collagen under microscopy. Both Alport syndrome and keratoconus demonstrate collagenous changes which may eventually lead to impaired function of the affected tissue. We present a case of keratoconus in the presence of Alport syndrome.

**Citation:** Moshirfar M, Skanchy DF, Gomez AT, Ronquillo YC, Buckner B, Hoopes PC. Keratoconus in a patient with Alport syndrome: A case report. *World J Clin Cases* 2019; 7(19): 3012-3017

**URL:** <https://www.wjgnet.com/2307-8960/full/v7/i19/3012.htm>

**DOI:** <https://dx.doi.org/10.12998/wjcc.v7.i19.3012>

## INTRODUCTION

Alport syndrome is an inherited disease characterized by progressive renal disease, hearing loss, and ocular abnormalities. It was first described as “familial congenital haemorrhagic nephritis” by Arthur Cecil Alport in 1927<sup>[1]</sup>. Inherited genetic mutations of *COL4A5* (X-linked), *COL4A3* and *COL4A4* (autosomal recessive) produce defects in the alpha chains that form type IV collagen<sup>[2,3]</sup>. Type IV collagen is a component of basement membranes throughout the body<sup>[4]</sup>. Specifically, the heterotrimer *α3α4α5* plays a crucial role in the glomerular basement membrane of the kidney, stria vascularis of the cochlea, Descemet’s membrane and Bowman’s layer of the cornea, lens capsule, and both the inner limiting membrane and Bruch’s membrane of the retina<sup>[5]</sup>. The most common ocular manifestations in Alport patients are corneal opacities, anterior lenticonus, cataract, fleck retinopathies, and temporal retinal thinning<sup>[5]</sup>. The prevalence of the disease has been estimated around 1:10000 with the X-linked variant accounting for 85% of the disease<sup>[6]</sup>.

Keratoconus is a corneal dystrophy resulting in corneal ectasia due to central or paracentral stromal thinning<sup>[7]</sup>. The pathophysiology is poorly understood, but breaks in Bowman’s layer, collagen disorganization, and scarring have all been described. Although the etiology remains unknown, both genetic and environmental factors, such as eye rubbing, are believed to contribute to the disease process. Keratoconus has a known association with Down syndrome, Leber’s congenital amaurosis, and connective tissue diseases such as Ehler’s Danlos<sup>[8]</sup>.

Despite the wide variety of ocular manifestations found in patients with Alport syndrome, corneal ectasia appears to be a rare finding. The literature is limited on the presence of keratoconus in these patients<sup>[9]</sup>. We report an interesting case of tomographic findings consistent with keratoconus in a patient with Alport syndrome.

## CASE PRESENTATION

### Chief complaints

A 52-year-old female was referred to our ophthalmology clinic with decreased vision and increased tearing.

### History of present illness

She was diagnosed with stage III Alport syndrome two years prior which was currently stable per her nephrologist. During these two years had gradual decline in her visual acuity that was not correctable to 20/20.

### History of past illness

She had a past medical history of asthma, diabetes mellitus, and hypertension.

### Family history

Family history was positive for Alport syndrome in her mother and brother but without any known ocular or hearing abnormalities.

### Physical examination

On initial examination (Table 1), uncorrected distance visual acuity was 20/60 on the right and 20/30 on the left, with a corrected visual acuity of 20/30 bilaterally.

**Table 1** Parameters from the patient's initial and follow-up encounters

Encounter	Initial encounter	2 mo follow up	Initial encounter	2 mo follow up
Eye	OD	OD	OS	OS
Vision Acuity				
UDVA	20/60	20/60	20/30	20/40
BCVA	20/30	20/25-2	20/30	20/25+
Man. Refraction	-1.50-1.75 x 031	-0.75-2.25 x 037	-1.00-2.75 x 149	-0.75-3.75 x 147
Tomography				
Front				
K1 (flat)	47.0 D	46.7 D	47.1 D	47.1 D
K2 (steep)	48.9 D	49.5 D	49.6 D	50.1 D
Km	47.9 D	48.1 D	48.3 D	48.5 D
Axis	31.0°	36.1°	146.4°	148.7°
Back				
K1	-6.5	-6.5	-6.7	-6.7
K2	-6.9	-6.9	-6.9	-7.0
Km	-6.7	-6.7	-6.8	-6.8
Axis	40.3°	53.6°	123.9°	134.2°
Pachymetry				
Pupil center	506 µm	502 µm	474 µm	472 µm
Pachy apex	505 µm	499 µm	472 µm	463 µm
Thinnest	496 µm	489 µm	454 µm	448 µm

UDVA: Uncorrected distance visual acuity; BCVA: Corrected distance visual acuity; Km: Mean keratometry.

Slit lamp examination showed bilateral eyelid laxity, papillary conjunctival changes, prominent nerves, superficial punctate keratitis, unilateral (OD) anterior basement membrane changes, with no guttata, apical scarring, or corneal striae. Dilated fundus exam revealed bilateral floaters in the vitreous humor and normal retinal vasculature.

### Imaging examinations

Initial Pentacam (Oculus, Wetzlar, Germany) tomography revealed mean keratometry of 47.9 D in the right and 48.3 D in the left, with a 2 mo follow-up scan revealing a mean keratometry of 48.1 D and 48.5 D respectively (Table 1). During this 2 mo period progressive corneal thinning occurred bilaterally. There was also bilateral anterior curvature steepening with no appreciable changes in the posterior curvature.

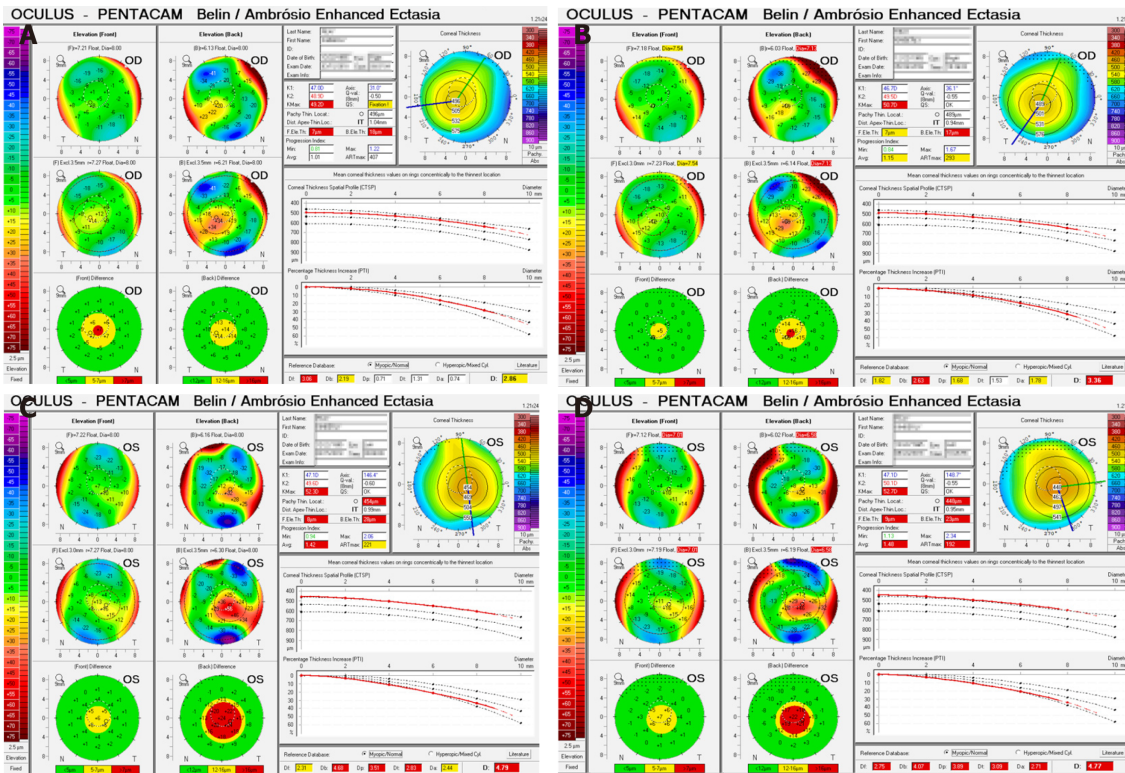
## FINAL DIAGNOSIS

Average keratometries above 47 to 48 D have been shown to correlate with keratoconus<sup>[10,11]</sup>. Based on the Amsler-Krumeich Classification system our patient was diagnosed with stage 2 keratoconus, with signs of progression over two months, including further corneal thinning and increased steepening. the disease<sup>[12,13]</sup>. This diagnosis was reinforced with the Pentacam Belin/Ambrosio Enhanced Ectasia Display which highlights tomographic abnormalities consistent with keratoconus (Figure 1).

## TREATMENT

Although no curative treatment is available for patients with Alport syndrome, Angiotensin-converting enzyme inhibitors, angiotensin receptor blockers, and aldosterone inhibitors reduce stress on the kidneys and may slow the progression of renal failure<sup>[14,15]</sup>. Yearly hearing and vision tests are recommended for patients diagnosed with Alport syndrome from the time the patient is 7 or 8 years old<sup>[14]</sup>.

Ophthalmologic manifestations of Alport syndrome are treated symptomatically, including lens removal and intraocular lens placement for lenticonus and cataract. Our patient was advised to continue to use glasses and avoid eye rubbing.



**Figure 1** Pentacam Belin/Ambrosio enhanced ectasia display highlighting abnormal values of deviation of front elevation difference map, deviation of back elevation difference map, deviation of average pachymetric progression, deviation of minimum thickness, deviation of Ambrosio relational thickness (ART max), and total deviation. A: Initial examination of right eye; B: 2 Mo follow-up of right eye; C: Initial examination of left eye; D: 2-Mo follow-up of left eye. Df: Deviation of front; Db: Deviation of back; Dp: Deviation of average pachymetric; Dt: Deviation of minimum thickness; Da: Deviation of Ambrosio; D: Total deviation.

## OUTCOME AND FOLLOW-UP

While her keratoconus was mild, continued signs of disease progression would warrant discussion of corneal collagen crosslinking while reserving corneal transplantation for advanced disease.

## DISCUSSION

The concurrent presentation of Alport syndrome and keratoconus, to our knowledge, has only been described once in the literature. Chugh *et al*<sup>[9]</sup> reported that 3 of 45 (6.7%) patients diagnosed with Alport syndrome were found to have associated keratoconus. This is the first report in the literature of tomographic findings consistent with keratoconus in a patient with Alport syndrome. While the inheritance patterns for Alport syndrome are well defined, the inheritance of keratoconus is under much investigation. Variants of the COL4A3 and COL4A4 genes are two of many possible genetic causes of keratoconus<sup>[16-18]</sup>. One study found that seven polymorphisms of COL4A3 and COL4A4 were associated with keratoconus, although no mutations were directly linked with the disease<sup>[17]</sup>. A meta-analysis of genetic associations for keratoconus concluded that COL4A4 had differential effects on keratoconus between ethnic groups<sup>[18]</sup>. Specific mutations of the COL4A3 and COL4A4 genes are known to cause of Alport syndrome.

A range of kidney-related diseases including chronic renal failure, kidney transplant, hypertension, diabetes mellitus, and various medications have been associated with keratoconus<sup>[19]</sup>. One theory is that both renal and ocular tissues express the PAX6 gene. PAX6 is linked to corneal gelatinase B, which is a metalloprotease responsible for corneal structure regulation. Thus, a mutated PAX6 gene may contribute to keratoconus and renal pathology<sup>[19]</sup>. Aldave *et al*<sup>[20]</sup> reported cases of polymorphous corneal dystrophy (PPCD) in Alport patients<sup>[5]</sup>. However, the process of corneal steepening found in PPCD is likely independent from that found in keratoconus, as the steepening often presents with the absence of other clinical features of keratoconus.

In Alport syndrome, the normal collagen IV  $\alpha3\alpha4\alpha5$  network is lost and the

immature  $\alpha 1\alpha 2$  network persists. This  $\alpha 1\alpha 2$  network has fewer crosslinks and more proteolytic cleavage sites. This produces basement membranes that are more susceptible to biomechanical strain. It also induces an increase in matrix metalloprotease activity<sup>[5]</sup>. Increased activity of protease enzymes and decreased protease inhibitors have been found in keratoconus<sup>[11]</sup>. Disorganization of collagen fibrils and a diminished number of crosslinks within and between such fibrils contributes to the weakened biomechanical state of the cornea in keratoconus<sup>[21]</sup>. Increased protease activity and decreased crosslinking may be a possible connection between the two diseases.

Further studies are necessary to elucidate the underlying molecular mechanisms possibly linking keratoconus and Alport syndrome. One of the limitations of this report is an absence of genetic testing. We were unable to obtain sequencing and analysis of the patient's exome or genome. These tests would have the potential to reveal specific genetic mutations leading to Alport syndrome in this patient and a more definitive link to keratoconus. When obtained, these tests will provide much value.

## CONCLUSION

Although a rare presentation, concurrent Alport syndrome and keratoconus should be considered when reviewing the ocular health of Alport syndrome patients and appropriate management steps should be taken upon the diagnosis.

## REFERENCES

- 1 **Alport AC.** Hereditary familial congenital haemorrhagic nephritis. *Br Med J* 1927; **1**: 504-506 [PMID: 20773074 DOI: 10.1136/bmj.1.3454.504]
- 2 **Barker DF,** Hostikka SL, Zhou J, Chow LT, Oliphant AR, Gerken SC, Gregory MC, Skolnick MH, Atkin CL, Tryggvason K. Identification of mutations in the COL4A5 collagen gene in Alport syndrome. *Science* 1990; **248**: 1224-1227 [PMID: 2349482 DOI: 10.1126/science.2349482]
- 3 **Nagel M,** Nagorka S, Gross O. Novel COL4A5, COL4A4, and COL4A3 mutations in Alport syndrome. *Hum Mutat* 2005; **26**: 60 [PMID: 15954103 DOI: 10.1002/humu.9349]
- 4 **Khoshnoodi J,** Pedchenko V, Hudson BG. Mammalian collagen IV. *Microsc Res Tech* 2008; **71**: 357-370 [PMID: 18219669 DOI: 10.1002/jemt.20564]
- 5 **Savage J,** Sheth S, Leys A, Nicholson A, Mack HG, Colville D. Ocular features in Alport syndrome: pathogenesis and clinical significance. *Clin J Am Soc Nephrol* 2015; **10**: 703-709 [PMID: 25649157 DOI: 10.2215/CJN.10581014]
- 6 **Hertz JM,** Thomassen M, Storey H, Flinter F. Clinical utility gene card for Alport syndrome. *Eur J Hum Genet* 2012; **20** [PMID: 22166944 DOI: 10.1038/ejhg.2011.237]
- 7 **Rosen ES.** Keratoconus. *J Cataract Refract Surg* 2012; **38**: 927-928 [PMID: 22624888 DOI: 10.1016/j.jcrs.2012.04.017]
- 8 **Davidson AE,** Hayes S, Hardcastle AJ, Tuft SJ. The pathogenesis of keratoconus. *Eye (Lond)* 2014; **28**: 189-195 [PMID: 24357835 DOI: 10.1038/eye.2013.278]
- 9 **Chugh KS,** Sakhuja V, Agarwal A, Jha V, Joshi K, Datta BN, Gupta A, Gupta KL. Hereditary nephritis (Alport's syndrome)-clinical profile and inheritance in 28 kindreds. *Nephrol Dial Transplant* 1993; **8**: 690-695 [PMID: 8414153 DOI: 10.1093/ndt/8.8.690]
- 10 **Rabinowitz YS.** Videokeratographic indices to aid in screening for keratoconus. *J Refract Surg* 1995; **11**: 371-379 [PMID: 8528916]
- 11 **Mas Tur V,** MacGregor C, Jayaswal R, O'Brart D, Maycock N. A review of keratoconus: Diagnosis, pathophysiology, and genetics. *Surv Ophthalmol* 2017; **62**: 770-783 [PMID: 28688894 DOI: 10.1016/j.survophthal.2017.06.009]
- 12 **Amsler M.** Le k eratoc one fruste au Javal. *Ophthalmologica* 1938; **96**: 77-83
- 13 **Amsler M.** [Not Available]. *Ophthalmologica* 1946; **111**: 96-101 [PMID: 20275788 DOI: 10.1159/000300309]
- 14 **Kashtan CE,** Ding J, Gregory M, Gross O, Heidet L, Knebelmann B, Rheault M, Licht C; Alport Syndrome Research Collaborative. Clinical practice recommendations for the treatment of Alport syndrome: a statement of the Alport Syndrome Research Collaborative. *Pediatr Nephrol* 2013; **28**: 5-11 [PMID: 22461141 DOI: 10.1007/s00467-012-2138-4]
- 15 **Stock J,** Kuenanz J, Glonke N, Sonntag J, Frese J, T nshoff B, H cker B, Hoppe B, Feldk tter M, Pape L, Lerch C, Wygoda S, Weber M, M ller GA, Gross O. Prospective study on the potential of RAAS blockade to halt renal disease in Alport syndrome patients with heterozygous mutations. *Pediatr Nephrol* 2017; **32**: 131-137 [PMID: 27402170 DOI: 10.1007/s00467-016-3452-z]
- 16 **Saravani R,** Hasanian-Langroudi F, Validad MH, Yari D, Bahari G, Faramarzi M, Khateri M, Bahadoram S. Evaluation of possible relationship between COL4A4 gene polymorphisms and risk of keratoconus. *Cornea* 2015; **34**: 318-322 [PMID: 25651396 DOI: 10.1097/ICO.0000000000000356]
- 17 **Stabuc-Silih M,** Ravnik-Glavac M, Glavac D, Hawlina M, Strazisar M. Polymorphisms in COL4A3 and COL4A4 genes associated with keratoconus. *Mol Vis* 2009; **15**: 2848-2860 [PMID: 20029656]
- 18 **Rong SS,** Ma STU, Yu XT, Ma L, Chu WK, Chan TCY, Wang YM, Young AL, Pang CP, Jhanji V, Chen LJ. Genetic associations for keratoconus: a systematic review and meta-analysis. *Sci Rep* 2017; **7**: 4620 [PMID: 28676647 DOI: 10.1038/s41598-017-04393-2]
- 19 **Bahar I,** Vinker S, Livny E, Kaiserman I. Possible Association between Keratoconus and Renal Diseases. *J Clin Exp Ophthalmol* 2010; **01** [DOI: 10.4172/2155-9570.1000112]
- 20 **Aldave AJ,** Ann LB, Frausto RF, Nguyen CK, Yu F, Raber IM. Classification of posterior polymorphous

- corneal dystrophy as a corneal ectatic disorder following confirmation of associated significant corneal steepening. *JAMA Ophthalmol* 2013; **131**: 1583-1590 [PMID: [24113819](#) DOI: [10.1001/jamaophthalmol.2013.5036](#)]
- 21 **Ambekar R**, Toussaint KC, Wagoner Johnson A. The effect of keratoconus on the structural, mechanical, and optical properties of the cornea. *J Mech Behav Biomed Mater* 2011; **4**: 223-236 [PMID: [21316609](#) DOI: [10.1016/j.jmbbm.2010.09.014](#)]





Published By Baishideng Publishing Group Inc  
7041 Koll Center Parkway, Suite 160, Pleasanton, CA 94566, USA  
Telephone: +1-925-2238242  
E-mail: [bpgoffice@wjgnet.com](mailto:bpgoffice@wjgnet.com)  
Help Desk: <https://www.f6publishing.com/helpdesk>  
<https://www.wjgnet.com>

