

Barrow Neurological Institute at St. Joseph's Hospital and Medical Center

## Barrow - St. Joseph's Scholarly Commons

---

Neurosurgery

---

8-1-2005

### Graft harvesting for revascularization in the head and neck.

Terence E Johnson

John E Wanebo

Stephen W Bayles

Charles Y Liu

Follow this and additional works at: <https://scholar.barrowneuro.org/neurosurgery>

---

# Graft Harvesting for Revascularization in the Head and Neck

Terence E. Johnson, M.D.,<sup>1</sup> John E. Wanebo, M.D.,<sup>2</sup>  
Stephen W. Bayles, M.D., F.A.C.S.,<sup>3</sup> and Charles Y. Liu, M.D., Ph.D.<sup>4</sup>

## ABSTRACT

---

The techniques for revascularization in the neurocranium, skull base, and neck continue to evolve at an exciting pace. In this body of literature, however, techniques for harvesting radial artery and saphenous vein grafts are mainly reported using traditional open techniques. Minimally invasive procedures are fast becoming an alternative to open techniques in many fields and have the potential to become the standard of care. The cardiovascular literature is replete with reports of endoscopically harvested vascular grafts. This article reviews both methods, since the current state of the art involves knowledge of open and endoscopic harvesting techniques.

**KEYWORDS:** Radial artery, saphenous vein, graft, endoscopic harvest, microvascular

From their branches on the aortic arch, the carotid arteries, vertebral arteries, and thyrocervical and costocervical trunks, via direct or intricate anastomotic pathways, supply blood to the complex structures of the head and neck. By virtue of this extensive collateral flow, the vasculature of the head and neck provides a very forgiving environment from which to harvest vessels locally for bypass. When the caliber and length of local vessels, however, is not adequate to reconstitute blood flow to critical areas, arterial or venous interposition grafts

are required. From repair of intracranial aneurysms and skull base lesions, to metastatic squamous cell carcinoma invading the carotid, the saphenous vein (SV) and the radial artery (RA) have a significant history of use as vascular grafts in the head and neck.<sup>1-4</sup> The past century certainly has provided a treasure trove of scientific literature dedicated to these vascular grafts from which surgeons of the new millennium have drawn to advance their art.<sup>5-9</sup>

The last decade has even shown us that lengthy incisions, in all aspects of surgery, are being

---

*Skull Base*, volume 15, number 3, 2005. Address for correspondence and reprint requests: Terence E. Johnson, M.D., Department of Otolaryngology, Naval Medical Center San Diego, 34520 Bob Wilson Dr., Ste. 200, San Diego, CA 92134-2200. E-mail: tejohnson@nmcsd.med.navy.mil. Departments of <sup>1</sup>Otolaryngology and <sup>2</sup>Neurosciences, Division of Neurosurgery, Naval Medical Center San Diego, San Diego, California; <sup>3</sup>Department of Otolaryngology, Virginia Mason Seattle Main Clinic, Seattle, Washington; <sup>4</sup>Department of Neurological Surgery, Keck School of Medicine, University of Southern California, Los Angeles, California. Published by Thieme Medical Publishers, Inc., 333 Seventh Avenue, New York, NY 10001, USA. Tel: +1(212) 584-4662. DOI 10.1055/s-2005-872599. Published online August 17, 2005. 1531-5010,p;2005,15,03,241,251,ftx,en;sbs00459x.

“replaced” with minimally invasive ones. Neurosurgical procedures and vascular graft harvesting are no exception to this trend.<sup>10,11</sup> Online physician advertising is full of statements proposing that endoscopic procedures may supplant open graft harvesting techniques for coronary artery bypass. In fact, some cardiovascular centers advertise that they currently perform 95 to 100% of saphenous harvesting endoscopically.<sup>12</sup> Though there has been a recent report of superficial temporal artery harvesting using endoscopic techniques,<sup>13</sup> there remains a paucity of reports of endoscopically harvested RA and SV grafts used for procedures in the neurocranium, skull base, and neck.

It stands to reason that, in time, patients will seek out surgeons and centers that offer minimally invasive techniques for vascular harvests regardless of the recipient site. The era of proper informed consent also dictates an adequate discussion of “alternatives.” If surgeons, residents, nurse first assistants, and physician assistants are performing hundreds of these procedures a year for cardiovascular procedures, endoscopic harvesting should, at the very least, be cited as an alternative for procedures in the head and neck. Despite the exciting technology currently available, however, experience with open techniques will always be necessary. For example, in emergent situations, one would obtain a graft by whatever means necessary. Surgeon experience and preference are also factors. Certainly, if problems arose while performing an endoscopic procedure, conversion to open technique might be necessary. Finally, there is a learning curve to any technique and conversion to open harvest may be required during the learning period.

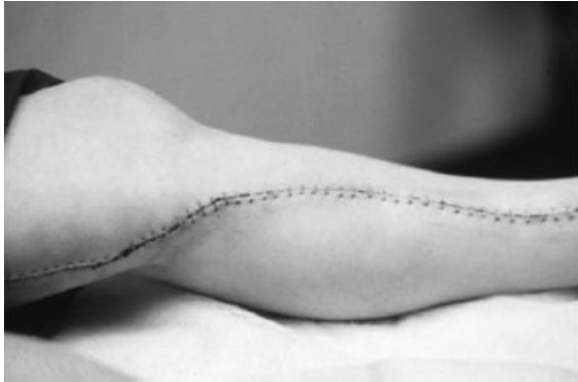Since Gluck, Carrel, Guthrie and Goyanes’s<sup>14</sup> work around 1900, a century of experience exists in the literature on the use of veins and arteries as bypass conduits. Minimally invasive procedures are at the forefront of current technology. A review of RA and SV harvesting cannot be considered complete without mention of both techniques. We therefore present a technical review of open and endoscopic harvesting techniques for RA and SV grafts.

## PREOPERATIVE COUNSELING—COMPLICATIONS

Preoperative counseling should include adequate discussion of donor site complications. Complication rates, in general, are relatively low. For example, in the article by Desai et al,<sup>11</sup> only 1 of 561 patients required readmission because of infection at the RA donor site. One patient had a hand-questionnaire score greater than 18 (implying clinically significant functional limitation). However, 5.7% reported moderate-to-severe symptoms of thenar paresthesia or numbness at 1 month. What is significant is that this decreased to 1.1% at the 12-month follow-up. Similarly, 1.8% reported moderate-to-severe weakness of the hand at 1 month, but, again, this number decreased to 0.9% at 12 months. No patients in this series reported hand claudication or ischemia.

A thorough discussion of risks, similar for open and endoscopic RA harvesting, should include the following: hematoma, infection, scarring, cosmetic deformity, seroma, edema, sensory and motor nerve injury, chronic pain, vascular injury, CO<sub>2</sub> embolus, risks of anesthesia, need for further procedures, and hand ischemia.<sup>11,15–22</sup> Regarding the dreaded complication of an ischemic hand, a recent study showed that blood flow and pressure of the digits returned to preoperative levels within 1 year and also concluded that RA harvesting may have a lesser effect on hand blood circulation than radial forearm flap harvesting does.<sup>23</sup> With only one severe ischemic event in over 1200 radial forearm flaps in another study, patients can be safely counseled that hand ischemia does occur, but is surprisingly rare with adequate preoperative assessment (Allen’s test, Doppler, etc.).<sup>22</sup> Vein grafting the RA defect on a routine basis is unnecessary and should generally be reserved for subsequent symptomatic ischemia.<sup>22</sup> Controversy still exists, however, and there are ongoing studies to elucidate the symptoms of claudication and cold intolerance.<sup>22,24</sup>

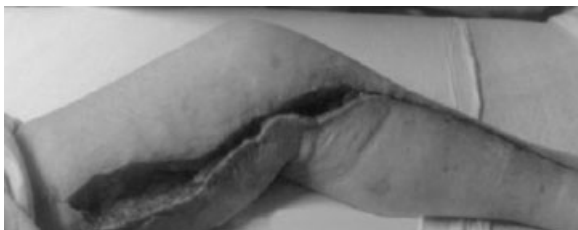SV graft donor site complications are, in general, similar and are related to proximate anatomy. The incision is of even greater cosmetic



**Figure 1** Length of incision for open SV harvesting. (Courtesy of Cardioventions, Division of Ethicon, Inc., Somerville, NJ.) SV, saphenous vein.

concern, however, due to its length (Fig. 1), especially when wound complications occur (Fig. 2).

Recipient site complications are beyond the scope of this article. It remains important to disclose to the patient, however, especially if newer endoscopic harvesting techniques were to be used, that perioperative failure of the graft could be caused by the harvesting technique. For example, the rare but well-reported complication of graft aneurysm has been described, in the cardiovascular literature, as recently as October 2004, where three, late, simultaneous SV graft aneurysms occurred.<sup>25</sup> Patients also must be aware that significant cardiovascular literature exists regarding mechanisms contributing to patency rates for both RA and SV grafts and there is some dependence of these rates on technical errors in harvesting.<sup>26</sup> These data, however, do not necessarily correlate with the statistics in the neurosurgical literature, especially in regard to recipient



**Figure 2** Wound complications for lengthy SV, though infrequent, can cause significant morbidity. (Courtesy of Cardioventions, Division of Ethicon, Inc., Somerville, NJ.) SV, saphenous veins.

site complications or late graft disease caused by atherosclerosis and fibrointimal hyperplasia.<sup>1,27</sup>

## CONTRAINDICATIONS

Contraindications to RA harvesting include inadequate palmar arch circulation (nonpalpable ulnar arteries or a positive Allen's test), calcification, chronic dissection, coronary angiography, trauma (including history of an invasive blood pressure catheter), renal disease (when the patient may be a future candidate for dialysis), cellulitis, subclavian artery stenosis, irradiation, abnormal Doppler or ultrasonographic study of the arms, history of vasculitis or Raynaud's syndrome, bilateral varicose veins, and vein stripping.

Risk factors for complications must be considered on a case-by-case basis and include general vascular atherosclerosis, diabetes, postoperative smoking, hyperlipidemia, history of endarterectomy of the grafted artery, local atheroma at the arteriotomy site, and Marfan syndrome.<sup>1,26</sup> Though hypertension was not found to be a risk factor in some studies, it may be a risk factor for late graft disease.<sup>26</sup>

Relative contraindications for endoscopic vein harvesting (EVH) include emergencies, subdermal vein, very thin lower legs, absent preoperative vein mapping, dual venous systems, and small or fragile veins. Additional relative risk factors to consider include diabetes mellitus, obesity, preoperative anemia, female gender, peripheral vascular disease, and hypoalbuminemia.

## PREOPERATIVE ASSESSMENT/ OTHER STUDIES

For both RA and SV graft harvesting, the history should include documentation of age, gender, and smoking history. Past medical history should include hypertension, diabetes mellitus, hypercholesterolemia, cardiovascular disease, cerebrovascular

disease, peripheral vascular disease, Marfan syndrome, renal function radiotherapy, cancer, and malnutrition (which may produce a hypercoagulable state).<sup>1</sup> A thorough physical exam and documentation of an Allen's test is essential for RA harvesting, especially in light of the test's reported ability to predict short-term and long-term safety of the hand.<sup>23</sup> The Allen's test is performed by occluding both the radial and ulnar arteries until there is an obvious pallor of the hand. Pressure on the ulnar artery is then released (while maintaining pressure on the radial site). An abnormal test occurs when the color of the hand does not return within 8 seconds.

Laboratory work-up should include prothrombin time, partial thromboplastin time, bleeding time, and a complete blood count. With a previous history of stroke, protein C, protein S, and Factor V Leyden tests should be performed.<sup>1</sup>

Adjunctive studies are at the surgeon's discretion and include Doppler, pulse oximetry, direct pressure measurement,<sup>28</sup> and contrast-enhanced magnetic resonance angiography (MRA). Doppler sounds may be acquired at the palmar arch then the RA is occluded. If the sounds continue without lessened volume, changes, or loss of signal, the radial is a good donor artery. Pulse oximetry may be used to document perfusion throughout the hand and fingers in a similar fashion. Finally, contrast-enhanced MRA may provide complementary imaging data in unclear or confusing cases where non-imaging tests are inconclusive.<sup>29</sup>

## CHOICE OF CONDUIT AND METHOD

Indications for type of graft selection for various procedures are well covered by the recent article by Wolfe and associates<sup>9</sup> on cerebral revascularization. Choice will often be dictated either by a contraindication specific to a particular patient's extremities, or by size, length, and flow requirements for the recipient site. When these factors are equivocal, then it may be necessary to draw from the extensive

cardiovascular experience to help decide which is the "better" conduit. The matter, however, is still heavily debated. Studies with thousands of patients are available with impressive p-values.<sup>30</sup> More recent studies state clearly that RA grafts have a higher long-term patency rate when "occlusion" rates are compared with SV grafts (8.2 versus 13.6%, respectively).<sup>11</sup> The combination of occluded (8.2%) and narrowed (7.0%) RA grafts, however, exceeded the SV failure rate in this study. It may, therefore, be important to consider the concept of a "bad graft" rate when evaluating and comparing the merit of articles and for future study design.<sup>20</sup>

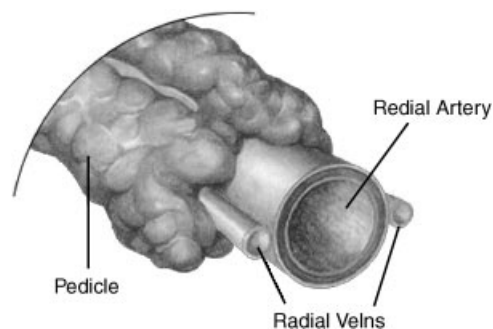
If an endoscopic method is considered for harvesting, it may also be necessary to draw from the extensive cardiovascular experience until analogous evidence is available in the neurosurgical literature.

## ANATOMY

In general, veins accompany the arteries of the lower limb, and those that parallel the large arteries of the leg are paired. There are five major venous structures of the leg: the greater and lesser SVs, posterior and anterior tibial veins, and peroneal veins. Venous conduits may be harvested as long as ~60 cm (in a very tall patient), with an average diameter ranging from 3 to 9 mm.

The greater SV originates from the medial marginal vein on the medial side of the foot and, accompanied by the saphenous nerve, passes up the medial side of the leg and knee, then continues upward to end in the femoral vein in the femoral triangle. The branches of the greater SV include the superficial epigastric, the superficial circumflex iliac, the superficial external pudendal, and the accessory saphenous.

The lesser SV begins in the lateral marginal vein of the foot and ascends posterior to the lateral malleolus of the fibula, accompanied by the sural nerve on the lateral margin of the Achilles tendon. In the proximal half of the leg, the lesser SV is

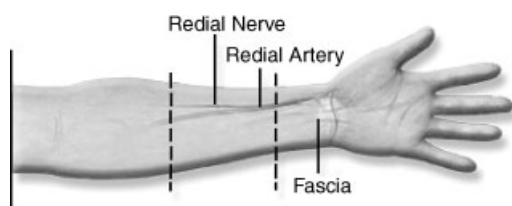

**Figure 3** The RA harvested with its pedicle intact, including the two radial veins. (Courtesy of Cardioventions, Division of Ethicon, Inc., Somerville, NJ.) RA, radial artery.

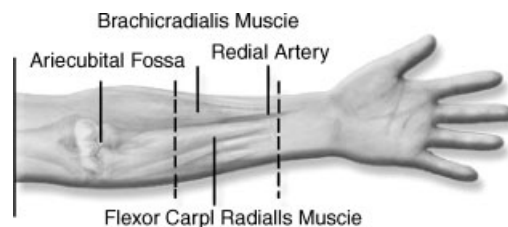
proximate to the medial sural cutaneous nerve and courses upward along the posterior side of the leg and ends in the popliteal vein.

The RA is a muscular artery with a thin intima and a well-developed internal elastic lamina. The vasoconstriction response of the RA is strong and it is prone to spasm when handled roughly. Therefore, understanding forearm anatomy is essential to prevent inadvertent dissection in the wrong tissue planes. The RA is generally harvested with its pedicle intact, including the two radial veins (Fig. 3).

In the distal forearm (Fig. 4), branches of the RA form a collateral network around the wrist and hand. The superficial branch of the radial nerve runs distally parallel to the RA, sometimes crossing the artery near the wrist. In the mid forearm (Fig. 5), the RA lies beneath the brachioradialis and flexor carpi radialis muscles. The superficial branch of the radial nerve lies deep to the brachioradialis. In the proximal forearm (Fig. 6), the brachial artery divides into the radial and ulnar arteries in the antecubital fossa, level with the neck of the radius,



**Figure 4** Distal forearm anatomy. (Courtesy of Cardioventions, Division of Ethicon, Inc., Somerville, NJ.)



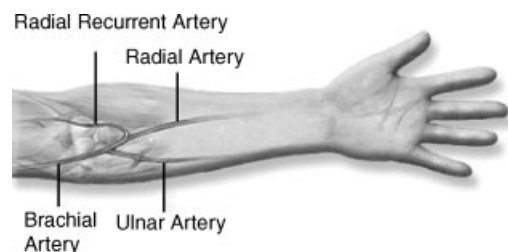
**Figure 5** Mid forearm anatomy. (Courtesy of Cardioventions, Division of Ethicon, Inc., Somerville, NJ.)

~1 cm below the elbow joint. The first branch is the radial recurrent artery, which takes part in collateral circulation around the elbow joint. Conduits can be harvested up to 24 cm in length and intraluminal diameter ranges from 2.5 to 3.5 mm proximally to 2 to 3 mm distally.

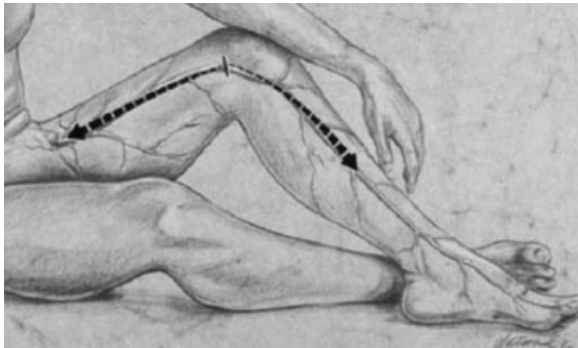
## TECHNIQUES

### SV—Open Harvesting Technique

While harvesting, it is prudent to keep in mind the mechanisms of injury that predispose to graft failure. Endothelial injury may be caused by direct physical harm, response of leukocytes, high distension pressure, ischemia of wall after loss of vasorum, arterIALIZATION, risk factors of smoking, and high low-density lipoproteins.<sup>26</sup> Though the cranial bypass literature<sup>27</sup> does not report late fibrointimal hyperplasia, overdistension of the vein should be avoided based on the knowledge that basic fibroblast growth factor released from injured endothelial cells and the density of its receptors increases when the vein graft is distended to



**Figure 6** Proximal forearm anatomy. (Courtesy of Cardioventions, Division of Ethicon, Inc., Somerville, NJ.)



**Figure 7** Potential saphenous conduit length can be significant, especially in taller patients. (Courtesy of Cardioventions, Division of Ethicon, Inc., Somerville, NJ.)

200 mm Hg.<sup>26</sup> Since success of the anastomosis is dependent on adequate length to prevent tension, “enough” extra vein length should be harvested. Though the potential conduit length available approaches ~60 cm (Fig. 7), donor site diameter matching may limit the amount appropriate for use.

Sekhar and Kalavakonda put it very succinctly, “The SV may be extracted from the thigh or the leg, depending on the caliber of the graft required. The lower limb is positioned with the hip externally rotated and flexed at the knee. For extraction from the thigh, the femoral arterial pulse is palpated, and an incision is marked from the presumed site of the femoral vein (medial to the arterial pulse) to the adductor tubercle. A small incision is made, and the vein is located by dissection through the subcutaneous tissue. If a sufficiently large (at least 4 mm in diameter) vein is not found, then the surgeon should search more medially.”<sup>1</sup> Duplications of a portion of the SV are not infrequent, and care must be taken to clearly identify the main SV.

“The vein is slowly traced inferiorly for a distance of 10 to 25 cm, as needed. Branches joining the vein are either ligated or occluded with small titanium clips.”<sup>1</sup> Ligation close to the wall can narrow the vein by pulling traction on the adventitia connective fibers. Ligating a side branch too far from the vein can potentially lead to aneurysm formation when under arterial pressure.<sup>31</sup> Additionally, leaving tributary stumps too long may also produce a nidus for thrombus formation. In

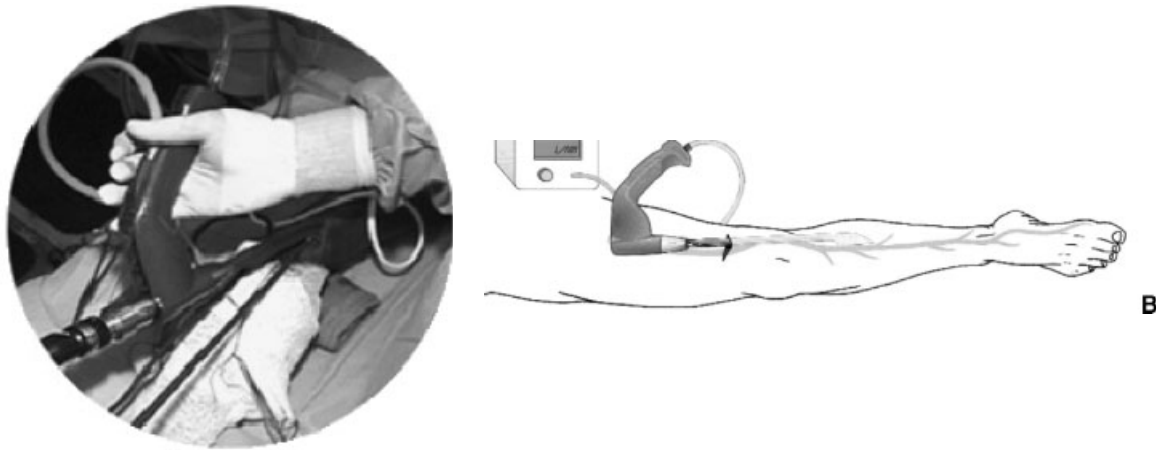
general, therefore, ligation is performed ~1 mm from the wall.

“The dissected vein is then covered on both sides with cottonoids soaked in 3% papaverine, to relax the vasospasm, and is left in situ until extraction. At the time of extraction, the vein is ligated proximally and distally, sectioned, and removed. Heparinized saline solution is used to wash out the blood inside the vessel and to check for leaks. If any leak site is encountered, it is repaired with 6–0 Prolene sutures. The vein graft surface is marked with a marking pencil, to avoid twisting. For extraction of the SV from the leg, the vein is exposed on the medial surface of the tibial tubercle, where it can be palpated and traced upward medial to the knee and into the thigh.”<sup>1</sup>

Further information on treatment of the harvested vein, including the “no-touch” technique (retaining a cushion of surrounding tissue) can be found in numerous articles.<sup>14,32</sup>

### SV—Endoscopic Vein Harvesting Techniques

Almost a century has passed since Mayo first described a semiclosed technique for SV harvesting in 1906.<sup>33</sup> Several articles remind us that state of the art is not necessarily faster or cost-effective and simple modification of older techniques can achieve a similar result. These include use of modified laryngoscopes, reusable systems, and “Less Invasive Non-Endoscopic” SV harvesting.<sup>33–35</sup> On the other hand, cost analysis is complex and factoring in patient satisfaction and reduced complication rates are driving development and widespread use of current endoscopic technologies. Several competing systems (e.g., Cardioventions, division of Ethicon, Inc. and Johnson & Johnson, Somerville, NJ, and VasoView<sup>®</sup> by Guidant Corporation, Indianapolis, IN) are being used with either open or closed CO<sub>2</sub> equipment. Open system proponents feel the lack of risk of CO<sub>2</sub> embolism provides an advantage (Fig. 8A, 8B). Simple kits (Fig. 9) provide ligation and cautery equipment to provide SV grafts with



**Figure 8** (A) Example of open CO<sub>2</sub> EVH equipment. (B) Saphenous grafts of the entire thigh and leg can be harvested with minimal incisions. (Both courtesy of Cardioventions, Division of Ethicon, Inc., Somerville, NJ.) EVH, endoscopic vein harvesting.

minimal scarring (Fig. 10) in contrast to traditional incisions (Fig. 1).

### RA—Open Harvesting Technique

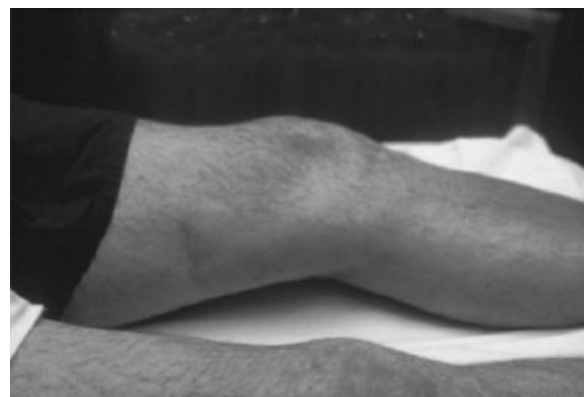
This requires an 18-cm incision along the forearm extending from wrist to elbow (Fig. 11). Some authors, however, prefer a “lazy S” incision to minimize contracture; they feel the incision should stop 2 cm above the wrist to reduce the risk of

sensory disturbance and to permit comfortable wearing of a watch.<sup>36</sup> Preincision oximetry, Doppler, and anticoagulation may be used by surgeon preference before radial dissection. The hand is circumferentially prepped and draped with a rolled towel under the wrist and the arm is secured at 90 degrees to the OR table in neutral position.

Consider the forearm as three distinct zones: proximal, middle, and distal and identify surgical landmarks (Fig. 12). Proximally, the incision begins 2 cm distal to the bicipital tendon (the incision

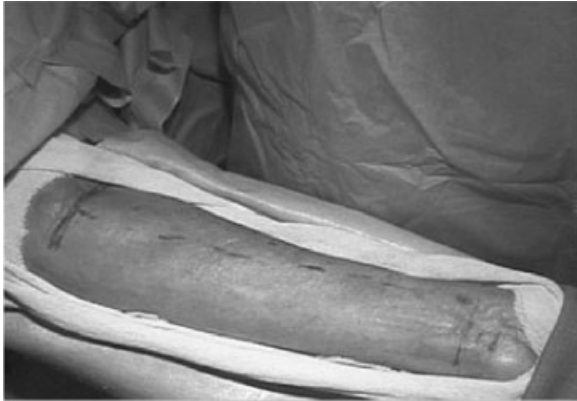

**Figure 9** Complete kits with lighted endoscopes and cautery and ligation equipment are available. (Courtesy of Cardioventions, Division of Ethicon, Inc., Somerville, NJ.)



**Figure 10** Minimal scarring, decreased complications and patient satisfaction are advantages of endoscopic graft harvesting. (Courtesy of Cardioventions, Division of Ethicon, Inc., Somerville, NJ.)



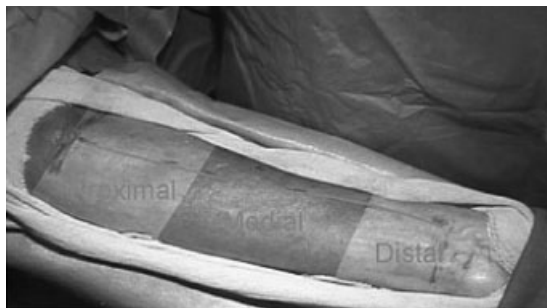


**Figure 11** Standard open RA graft harvesting incision. (Courtesy of Cardioventions, Division of Ethicon, Inc., Somerville, NJ.) RA, radial artery.

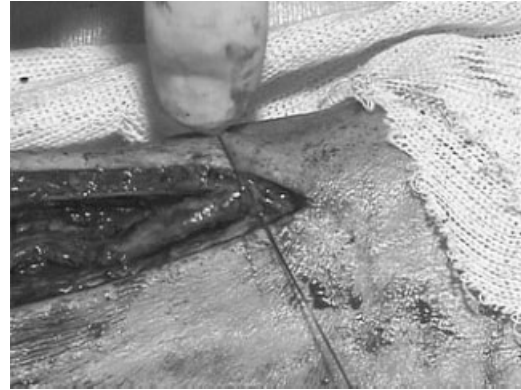plane should respect muscles of the middle zone), and distally the incision should end approximately 1 to 2 cm proximal to the radial styloid.

The subcutaneous tissue is divided distally and the RA is identified near the wrist. Fatty tissue is divided distal to proximal along the plane of RA. The incision should lie medial to the muscular triad in the medial section. Palpating the muscular triad in the medial section allows proper placement of the incision. The cutaneous branch of the radial nerve will be exposed occasionally, despite correct position of the skin incision, or it may be wrapped around the RA, in which case the nerve is moved gently to the side of the incision line.

After reverifying ulnar circulation, low-dose heparin (5000 U) is administered just prior to ligation. Ligation and division of the radial pedicle

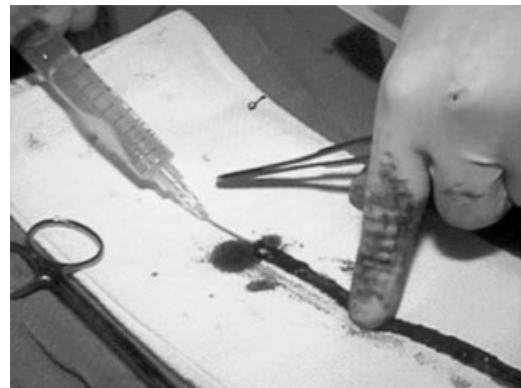

**Figure 12** Consider the forearm anatomy in three zones: distal, middle (vice medial), and proximal. (Courtesy of Cardioventions, Division of Ethicon, Inc., Somerville, NJ.)

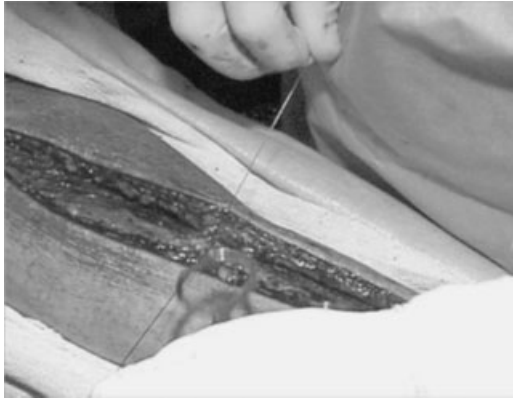

**Figure 13** Distal ligation of the radial pedicle. (Courtesy of Cardioventions, Division of Ethicon, Inc., Somerville, NJ.)

(proximal or distal end first) is performed based on surgeon preference (Fig. 13). Arterial pulsation in the stump and backbleeding are then verified. The graft is immediately flushed with heparinized saline to eliminate blood products and the ends prepared as per surgeon preference. Additionally, “popping” the artery (Fig. 14), as described by Shekar and Kavakonda<sup>1</sup> may be performed by introducing a small blunt needle and distending the artery “with pressure, using heparinized saline solution, until the artery visibly pops.” The artery is then plicated over the blunt needle, and the procedure is repeated. A similar process is also performed from the other end of the RA. After spasm of the vessel has been



**Figure 14** Flushing the artery with heparinized saline is an important step to remove blood products and prevent vasospasm. (Courtesy of Cardioventions, Division of Ethicon, Inc., Somerville, NJ.)



**Figure 15** The subcutaneous layer is closed without closing the deep fascial space. (Courtesy of Cardioventions, Division of Ethicon, Inc., Somerville, NJ.)

relieved in this manner, the vessel does not spasm again.” The graft may be stored temporarily in a heparinized saline solution.

For donor site closure, meticulous hemostasis is established and the wound is flushed with antibiotic solution. The subcutaneous layer is closed without closing the deep fascial space (Fig. 15), and finally a subcuticular technique may be used. The wound is wrapped with loose gauze and compression dressing is optional.

### RA—Endoscopic Harvesting Technique

Similar equipment is used as in the EVH systems, including a 30-degree endoscope, quality camera, monitor, and suction. Advancements in endoscopic clip appliers, bipolar scissors, and harmonic instruments have simplified this procedure. For example, Ethicon uses the WATCHBAND INCISION™ system allowing the surgeon to make a single incision small enough to be hidden behind a watchband. The HARMONIC SCALPEL™ (Fig. 16), using ultrasonic technology, and the CLEARGLIDE™ Endoscopic Vessel Harvesting system both allow harvest with no electrical current running to or through the patient. Similarly to endoscopic SV harvesting, this results in a significantly smaller scar. Specific techniques comparing pros and cons of various vendors’ particular instruments is out of



**Figure 16** The HARMONIC SCALPEL™ is an alternative method to bipolar cautery of small vessel branches. (Courtesy of Cardioventions, Division of Ethicon, Inc., Somerville, NJ.)

the scope of this article, but the issue of side branch ligation is an important consideration. The cardiovascular literature, however, does not report any increased complications when using bipolar cautery systems or the HARMONIC SCALPEL over traditional ligation or clipping.<sup>37</sup>

### POSTOPERATIVE CONSIDERATIONS

Pressure bandages are optional and are maintained for 12 to 24 hours. Perfusion and sensory and motor function should be assessed and the incision inspected prior to discharge. Close follow-up is important to assess for previous listed complications.

### CONCLUSIONS

Significant time may pass before future advances (e.g., gene therapy<sup>38</sup>) push long-term patency rates of vascular grafts closer to 100%. For now, reports in the cardiovascular literature<sup>39,40</sup> continue to grow in number regarding safety, complication, and patency rates for use of the RA with or instead of the SV, and for endoscopic harvest of both RA and SV grafts. With the benefits of faster healing, similar patency rates, and patient satisfaction, it is

hoped that these techniques will find their way into the "Future Neurosurgical Operative Environment."<sup>41</sup>

#### ACKNOWLEDGMENTS

No financial support was received in the preparation of this article. The images, especially those from [www.mypreceptor.com](http://www.mypreceptor.com) for the RA portion, were gratefully used with permission from Cardiovascular, a Division of Ethicon, Inc., Somerville, NJ.

#### DISCLAIMER

The views expressed in this article are those of the authors, and do not reflect the official policy or position of the Department of the Navy, Department of Defense, or the United States Government.

#### REFERENCES

1. Sekhar L, Kalavakonda C. Cerebral revascularization for aneurysms and tumors. *Neurosurgery* 2002;50:321-331
2. Eliason J, Netteville J, Guzman R, Passman M, Naslund T. Skull base resection with cervical-to-petrous carotid artery bypass to facilitate repair of distal internal carotid artery lesions. *Cardiovasc Surg* 2002;10:31-37
3. Reilly M, Perry M, Netteville J, Meacham P. Carotid artery replacement in conjunction with resection of squamous cell carcinoma of the neck: preliminary results. *J Vasc Surg* 1992;15:324-329
4. Conley J. Free autogenous vein graft to the internal and common carotid arteries in the treatment of tumors of the neck. *Ann Surg* 1953;137:205-214
5. Lougheed W, Marshall B, Hunter M, Michel ER, Sandwith-Smyth H. Common carotid to internal carotid bypass venous graft. Technical note. *J Neurosurg* 1971;34:114-118
6. Fisch UP, Olding DJ, Senning A. Surgical therapy of internal carotid artery lesions of the skull base and temporal bone. *Otolaryngol Head Neck Surg* 1980;88:548-554
7. Glasscock M, Smith P, Bond A, Whitaker S, Bartels L. Management of aneurysms of the petrous portion of the internal carotid artery by resection and primary anastomosis. *Laryngoscope* 1983;93:1445-1453
8. Spetzler R, Fukushima T, Martin N, Zabramski JM. Petrous carotid-to-intradural carotid saphenous vein graft for intracavernous giant aneurysm, tumor and occlusive cerebrovascular disease. *J Neurosurg* 1990;73:496-501
9. Wolfe SQ, Tummala RP, Morcos JJ. Cerebral revascularization in skull base tumors. *Skull Base* 2005;15:71-82
10. Levy M, Wang M, Aryan H, Yoo K, Meltzer H. Microsurgical keyhole approach for middle fossa arachnoid cyst fenestration. *Neurosurgery* 2003;53:1138-1145
11. Desai N, Cohen E, Naylor C, Fremes S. A randomized comparison of radial-artery and saphenous-vein coronary bypass grafts. *N Engl J Med* 2004;351:2302-2309
12. [http://www.osfhealth.com/rhi/Art\\_Endoscopic.htm](http://www.osfhealth.com/rhi/Art_Endoscopic.htm). Accessed May 25, 2005
13. Kubo S, Takimoto H, Yoshimine T. Endoscopically assisted harvesting of the superficial temporal artery: technical note. *Neurosurgery* 2003;52:982-984; discussion 984-985
14. Adcock O, Adcock G, Wheeler J, Gregory R, Snyder S, Gayle R. Optimal techniques for harvesting and preparation of reversed autogenous vein grafts for use as arterial substitutes: a review. *Surgery* 1984;96:886-894
15. Fremes S, Christakis G, Del Rizzo D, Musiani A, Mallidi H, Goldman B. The technique of radial artery bypass grafting and early clinical results. *J Card Surg* 1995;10:537-544
16. Possati G, Gaudino M, Prati F, et al. Long-term results of the radial artery used for myocardial revascularization. *Circulation* 2003;108:1350-1354
17. Meharwal Z, Trehan N. Functional status of the hand after radial artery harvesting: results in 3,977 cases. *Ann Thorac Surg* 2001;72:1557-1561
18. Khot U, Friedman D, Pettersson G, Smedira N, Li J, Ellis S. Radial artery bypass grafts have an increased occurrence of angiographically severe stenosis and occlusion compared with left internal mammary arteries and saphenous vein grafts. *Circulation* 2004;109:2086-2091
19. Possati G, Gaudino M, Prati F, et al. Long-term results of the radial artery used for myocardial revascularization. *Circulation* 2003;108:1350-1354
20. Lytle B. Prolonging patency—choosing coronary bypass grafts. *N Engl J Med* 2004;351:2262-2264
21. Cameron J, Trivedi S, Stafford G, Bett J. Five-year angiographic patency of radial artery bypass grafts. *Circulation* 2004;110 (suppl 1):II-23-II-26
22. Heller F, Wei W, Wei F. Chronic arterial insufficiency of the hand with fingertip necrosis 1 year after harvesting a radial forearm free flap. *Plast Reconstr Surg* 2004;114:728-731
23. Iida Y, Numata T, Shiba K, Nagata H, Terada N, Konno A. Hemodynamic changes of the hand after radial forearm flap harvesting. *Ann Plast Surg* 2002;49:156-160
24. Haerle M, Hafner H, Dietz K, Schaller H, Brunelli F. Vascular dominance in the forearm. *Plast Reconstr Surg* 2003;111:1891-1898
25. Majumdar T, Kaleekal T, Mulpuri R, Gonzalez J. Multiple saphenous vein graft aneurysms: a late complication of coronary artery bypass surgery. *Chest* 2004;126:934S-935S
26. Nwasokwa O. Coronary artery bypass graft disease. *Ann Intern Med* 1995;123:528-545

27. Sen C, Sekhar L. Direct vein graft reconstruction of the cavernous, petrous, and upper cervical internal carotid artery: lessons learned from 30 cases. *Neurosurgery* 1992;30:732-742; discussion 742-743
28. Parolari A, Rubini P, Alamanni F, et al. The radial artery: which place in coronary operation? *Ann Thorac Surg* 2000;69:1288-1294
29. Winterer J, Ennker J, Scheffler K, et al. Gadolinium-enhanced elliptically reordered three-dimensional MR angiography in the assessment of hand vascularization before radial artery harvest for coronary artery bypass grafting: first experience. *Invest Radiol* 2001;36:501-508
30. Meharwal Z, Trehan N. Functional status of the hand after radial artery harvesting: results in 3,977 cases. *Ann Thorac Surg* 2001;72:1557-1561
31. Ghahreman K. Microvascular surgery. In: Rand RW, ed. *Microneurosurgery*. St. Louis, MO: CV Mosby Co; 1978: 354-362
32. Vasilakis V, Dashwood M, Souza D, Loesch A. Human saphenous vein and coronary bypass surgery: scanning electron microscopy of conventional and "no-touch" vein grafts. *Vascular Disease Prevention* 2004;1:133-139
33. Fabricius A, Diegeler A, Gerber W, Mohr F. Functional and morphologic assessment of saphenous veins harvested with minimally invasive techniques using a modified laryngoscope. 2000;#2000-04157. Available at: [http://www.hsforum.com/stories/articleReader\\$231](http://www.hsforum.com/stories/articleReader$231). Accessed May 25, 2005
34. Swinamer S, Fox S, McKenzie F, et al. Endoscopic saphenous vein harvesting for CABG can be performed utilizing a reusable system with greatly reduced cost as compared to disposable systems [abstract]. 2004; Canadian Cardiovascular Congress. Available at: <http://www.pulsus.com/cc2004/abs/a411.htm>. Accessed May 25, 2005
35. Ali I, El-Khateeb O. Less invasive non-endoscopic saphenous vein harvesting: a simple technique and super results [abstract]. 2001; Canadian Cardiovascular Congress. Available at: <http://www.ccs.ca/society/congress2001/abstracts/abs/a034.htm>. Accessed May 25, 2005
36. Taggart D. The radial artery as a conduit for coronary artery bypass grafting. *Heart* 1999;82:409-410
37. Wright CB, Barner HB, Gao A, et al. The advantages of the Harmonic Scalpel for the harvesting of radial arteries for coronary artery bypass. *Heart Surg Forum* 2001;4:226-229; discussion 229-230
38. Cable D, Caccitolo J, Caplice N, et al. The role of gene therapy for intimal hyperplasia of bypass grafts. *Circulation* 1999;100:II-392-II-396
39. Davis Z, Garber D, Clark S, et al. Long-term patency of coronary grafts with endoscopically harvested saphenous veins determined by contrast-enhanced electron beam computed tomography. *J Thorac Cardiovasc Surg* 2004; 127:823-828
40. Connolly M, Torrillo LD, Stauder MJ, et al. Endoscopic artery harvesting: results of first 300 patients. *Ann Thorac Surg* 2002;74:502-505; discussion 505-506
41. Liu C, Spicer M, Apuzzo M. The genesis of neurosurgery and the evolution of the neurosurgical operative environment: part II—concepts for future development, 2003 and beyond. *Neurosurgery* 2003;52:20-35