

3. Teschke R. Drug-induced liver diseases. *Gastroenterology*. 2002;40(5):305-326.
4. Voicu Victor A, Macovei Radu, Avram Oana. Conduita medicală în intoxicațiile acute. În: Actualități în anestezie, terapie intensivă și medicație de urgență. Timișoara, 2006;280-293.
5. Nițescu Gabriela Vioreta. Afectarea hepatică și renală în intoxicațiile acute medicamentoase la copil. *Protocoale terapeutice. Rezumat al tezei de doctorat*. București, 2007.
6. Байкова ИЕ, Никитин ИГ. Лекарственные поражения печени. *РМЖ*. 2009;11(1):1-6.
7. Буеверов АО. Возможности лечения лекарственных поражений печени в условиях необходимости продолжения приема гепатотоксичных препаратов. *Леч. врач*. 2009;2:40-47.
8. Буеверов АО. Лекарственные поражения печени. *РМЖ*. 2001;9:13-14.
9. Радченко ВГ. Лекарственные поражения печени. *Новые Санкт – Петербургские врачебные ведомости*. 2004;4:25-29.
10. Скрипник ИН. Медикаментозные гепатиты. Современные аспекты диагностики и лечения. *Consilium medicum*. 2008;8.
11. Степанов ЮМ, Филипова АЮ, Филимонова АЮ, и др. Лекарственные поражения печени: патогенез, классификация, диагностика, лечение. *Провизор*. 2005;5.
12. Яковенко ЭП, Яковенко АВ, Иванов АН, и др. Лекарственно-индуцированные поражения печени. Диагностика и лечение. *Лечащий врач*. 2011;2:16-20.
13. Лозинский ЕЮ, Шмыкова ИИ, Лозинская ЛМ, и др. Лекарственная нефропатия. [lib.vgmu.ru/files/PMI](http://lib.vgmu.ru/files/PMI). 2005;5-10.

## Glycerol preserved skin allograft – the key for the effective wound bed preparation

\*O. Andreevscaia, A. De Mey, D. Franck, W. Boeckx

Queen Fabiola Children's University Hospital, Avenue Jean-Joseph Crocq, 15-1020, Brussels, Belgium  
Brugmann University Hospital, Place A. Van Gehuchten, 4, 1020, Brussels, Belgium

\*Corresponding author: [olga.andreevscaia@mail.ru](mailto:olga.andreevscaia@mail.ru)  
Manuscript received November 03; revised January 31, 2012

### Abstract

For spontaneous wound healing to occur, wound preparation must be optimised. This may be impaired by several factors. This paper presents the authors experience and philosophy regarding wound bed preparation of extensive and complicated wounds. After the removal of all devitalized tissue, angiogenesis of the wound bed is promoted by the temporary application of the glycerol preserved allograft. This study included all patients with burns and wounds, who were admitted to the Queen Fabiola Children's University Hospital in Brussels from January 2010 to November 2010 who had been treated with a glycerol preserved allograft. The results of the study showed the high effectiveness of these kinds of treatments: infection control, stimulation of angiogenesis, and granulation tissue formation.

**Key words:** allograft, glycerol preserved allograft, wound bed preparation, angiogenesis.

### Кожный аллотрансплантат, консервированный в глицероле – ключ к эффективной подготовке раневого ложа

Спонтанное заживление раны может быть нарушено различными неблагоприятными факторами. Раневое ложе должно быть подготовлено. В этой статье авторы поделились своим опытом и тактикой подготовки раневого ложа обширных и осложнённых ран. После удаления всех нежизнеспособных тканей, ангиогенез был стимулирован путём временной аппликации кожного аллотрансплантата, консервированного в глицероле. В данное исследование были включены пациенты с ожогами и ранами, поступившие в Детский Университетский Госпиталь Королевы Фабиолы в Брюсселе с января по ноябрь 2010 года, в лечении которых был использован кожный аллотрансплантат, консервированный в глицероле. Результаты показали высокую эффективность данного лечения: контроль инфекции, стимуляция ангиогенеза, формирование грануляционной ткани, предотвращение контрактур и др.

**Ключевые слова:** аллотрансплантат в глицероле, раневое ложе, ангиогенез.

### Introduction

The "natural" process of wound healing is always necessary, but not always sufficient to secure an efficient functional repair of damaged tissue. The repair of injuries involving an extensive loss of skin has long been recognized to be a surgical problem; one for which, in the majority of cases, the operation of skin grafting is a fully adequate solution.

The benefits of using skin allograft in burns have been widely proven in the published literature [1, 2, 3]. There are two main types of skin allograft, cryopreserved allograft and glycerol-preserved allograft (GPA), which differ in the methods of processing and storage.

The cryopreserved allograft (CPA) was first introduced to treat burn victims in 1979. It is processed by a controlled

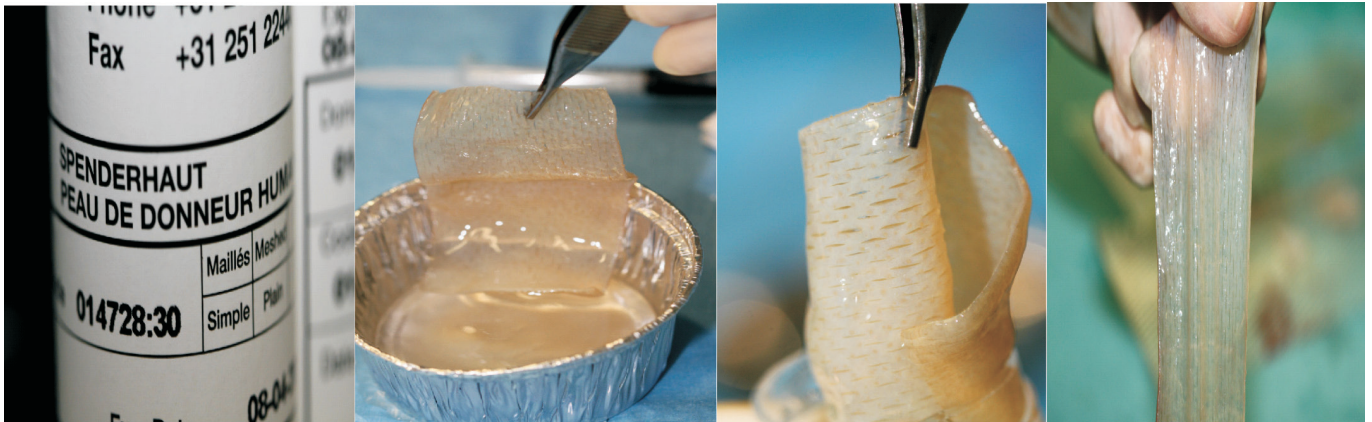


Fig. 1. Preparation of the skin allograft.

freezing process (0.5-5°C min/1) and may be stored in liquid nitrogen at -196°C or in a freezer at -80°C [2].

The glycerol preserved allograft (GPA) was introduced by the Euro Skin Bank in 1984 by Hoekstra [3]. It is preserved in 85% glycerol and can be stored at +4°C. The process of glycerolisation destroys the vital structures and thus, GPA is considered non-viable. Glycerol preservation is simpler, more cost-effective and possesses antibacterial and antiviral properties as well as suppressed immunogenicity in allograft [4].

GPA remains intact, if not vascularised. CPA, as mentioned by D. Herndon, disappears if not revascularised within 3 days, and also needs to be changed more frequently; it has very limited resistance to infection. In Europe, GPA is more commonly used in clinical practice.

According to Kreis [5], the use of GPA as a temporary, or permanent, skin substitute on fresh debrided wounds is accepted for:

1. Debrided burn wounds (partial thickness IIa and b).
2. Full-thickness burns after epifascial necrectomies.
3. Overlay of widely meshed autografts.
4. Vascularised dermal replacement.

The main advantage of GPA is its ability to cover and to adhere to the wound bed. Its potential to become incorporated into the healing tissue opens up new indications for use as a dermal substitute for preparing the wound surface for cultured autologous epithelium, as recorded by A. Munster, R. J. Spence, and others [6].

For many reasons in our clinic, GPA became the method of choice. It is based on our approach to wound management according to the clinical concept TIME, proposed by G. S. Schultz, R. G. Sibbald, V. Falanga et al. consisting of:

- Tissue necrosis treatment.
- Infection control.
- Moisture control.
- Epithelialization stimulation.

It prevents infection, moisture imbalance, stimulates epithelialisation. GPA firmly adheres to the wound bed and re-epithelialisation is stimulated. Re-epithelialisation can be complete, when it starts from the wound margins, and the angiogenesis is very good. Infection is reduced or very limited.

### Patients and methods

This study included all patients with burns and wounds, who were admitted in the children hospital HUDE RF in Bruxelles, and had been treated with a GPA from January 2010 to November 2010 (fig.1).

Apart from the utilisation of GPA, the patients were treated according to the same basic principles as other patients regarding local and general treatment. With regard to local wound care, topical application of Flammacerium® on non-operated deep partial and full thickness wounds was followed by excision and may be tangential [7].

Grafting was always performed during the same operative session. Four children, boys, with an average age of 5 years (range 1-11 years) with burns and wounds (Fournier syndrome, road accident) were included in this study (tab. 1). 9%-40% of their body surface area was affected (BSA) (average 23.5%) and with FTB 0-15% (average 7.25%). Burn depth was clinically assessed.

Fourteen surgical procedures were performed with GPA on the 4 patients (mean 3.5 per patient, range 2-8). Grafts were applied as a cover, either on excised wounds or on autografts in the sandwich technique. All utilized GPA were already meshed in the ratio 1:1.5 as provided by the Euro Skin Bank. As for the sandwich method, autografts were mainly meshed in the ratios 1:4 and 1:6. (fig. 2).

The total surface area of GPA utilized, according to the Euro Skin Bank measurements, was 5750 cm<sup>2</sup>.

### Results

#### Case 1: G. T., 5 years old.

The 5 years old patient was operated on by abdominal surgeons for Hirschsprung disease. He presented a necrotising fasciitis, or Fournier syndrome with a width of 20 cm, a height of 15 cm, and undermining of 4 cm on the left inguinal and hypogastric region. The patient was treated with GPH; three operations were performed at weekly intervals.

After rinsing the large infected wounds and debridement, 1310 cm<sup>2</sup> 1.5/1 meshed GPA were applied. This was then fixed with compressing foam. The goal is to leave the GPA for revascularization for one week and if all signs of infection had disappeared, the autograft could be applied. The

second intervention was performed at the second week post debridement (w.p.d.). The homograft take was 70%, with revascularization, without haematoma, infection and necrosis. Granulation tissue of a good quality was formed. 30% of the remaining wound was covered again with 230 cm<sup>2</sup> of GPA. At the third w. p. d., only 10% of the wound surface remained, the take rate was 90%, with a good adherence of the homograft and a good granulation of tissue; no haematoma, infection, and necrosis. The rest of the wound was covered with 90 cm<sup>2</sup> of GPA. After the third w.p.d., the wound was closed secondarily – 100% without infectious complications.

**Case 2: A. N., 10 months.**

The 10 month old patient was hospitalized for second and third degree flame burns on the leg, thigh and thorax (25% of the body mass contained second degree burns and 5% contained third degree burns). For three weeks, Flammacerium® dressings were applied, but in some places of the thorax, the thigh, and the leg the tissue did not heal. It was then decided to make a debridement and tangential excision and to place a GPA - 195 cm<sup>2</sup>. After the fourth w. p. b. (week post burn), we found a good GPA take - 70% with revascularization, good adherence of the homograft without haematoma, infection, and necrosis. On the thorax the angiogenesis was fair. This region was covered again with 90 cm<sup>2</sup> of the new GPA.

After the fifth w. p. b., we found a good GPA take - 85% at the level of the knee and the leg. At the level of the thorax, there was maceration and only partial GPA take. At the level of the thigh, the re-epithelialization was complete. The lower limb was covered with 190 cm<sup>2</sup> GPA. The rest of the lesions were covered with Flammacerium® dressings. The evolution was quite favorable without infectious complications. After the sixth w. p. b., only on the thorax, a zone of non-epithelialised tissue about 2 cm in diameter persisted. On the lower leg, three small zones of non-epithelialised tissue persisted. As complications with hypertrophic scars, knee contracture appeared and splinting was required to prevent it. The final graft take was excellent-98%. An outcome with total re-epithelialization without grafting was achieved after the sixth w.p.b.

**Case 3: W. L., 1.5 years old.**

The 1.5 years old patient was burned 40% of TBSA (25% - were second degree burns and 15% were third degree burns).

The face of the patient, after debridement, was covered with 195 cm<sup>2</sup> of GPA; other burned parts of the body were treated with Flammacerium® to obtain a leathery crust. At the second w. p. b., a tangential excision of the burns at the thorax and the left arm were also covered with 1065 cm<sup>2</sup> of GPA.

The results obtained at the third w. p. b. showed good evolution: the GPA at the level of the thorax, stomach, and arm (excluding the shoulder) had taken very well. 390 cm<sup>2</sup> of GPA were applied to the arm and the thigh.

At the fourth w. p. b. the evolution at the level of the arms, thigh, face, and thorax was very favorable (no infection, no complications, and good re-epithelialization). The shoulder was treated with 80 cm<sup>2</sup> of GPA. Two days later, the left part of the thorax was treated with 120 cm<sup>2</sup> of GPA. The good evolution of the burns required no grafting; there were no infection, and no complications. At the fifth w. p. b. of GPA application the right arm had almost healed, there were some adherent GPA. The skin of the left arm was swollen. On the thorax, there was good evolution; however, fibrous in some places. On the leg, the wound was tidy. 290 cm<sup>2</sup> of GPA were again applied on the open areas to improve the angiogenesis. The evolution at the sixth week showed complete healing of the right arm. Only a small zone (1.5 cm<sup>2</sup>) of the GPA of the face had not healed. On the anteromedial surface of the left knee, the arm, and the thorax there were three small zones that had not healed. To prepare the wound bed for autografting, 505 cm<sup>2</sup> of GPA were applied to the thorax and the left hand. Three days later a sandwich technique was performed on the thorax, the left arm, and the left leg (after one month of the treatment with GPA). There was good granulation tissue in the wound bed which was ready for autografting (fig. 3). The final autograft took after one week was 100%. However, a contracture in the elbow and axilla was appearing, which required prolonged splinting.

**Case 4: B.S., 11 years old.**

The 11 years old patient was hospitalised in the HUDERF emergency unit after a traffic accident. Upon physical examination, the patient presented a very deep dermabrasion of the lateral surface of the buttock (5\*4 cm, 2 cm deep). He also had a dermabrasion of the subcutaneous tissue on his back, right leg, and left heel (9% of the body surface). The patient was treated with Flammacerium® dressings. At the second

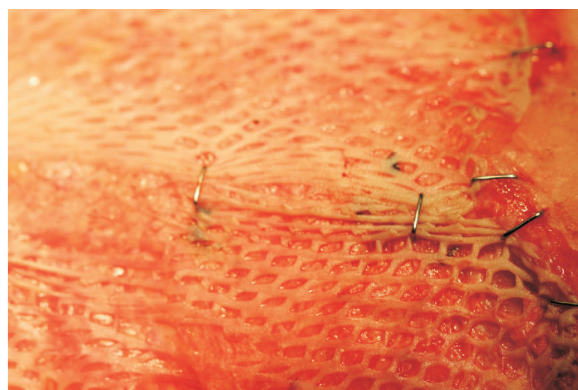
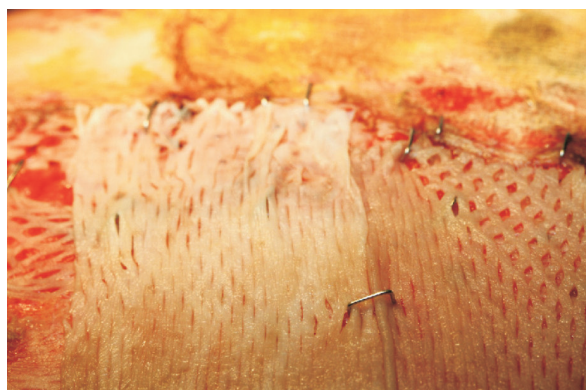
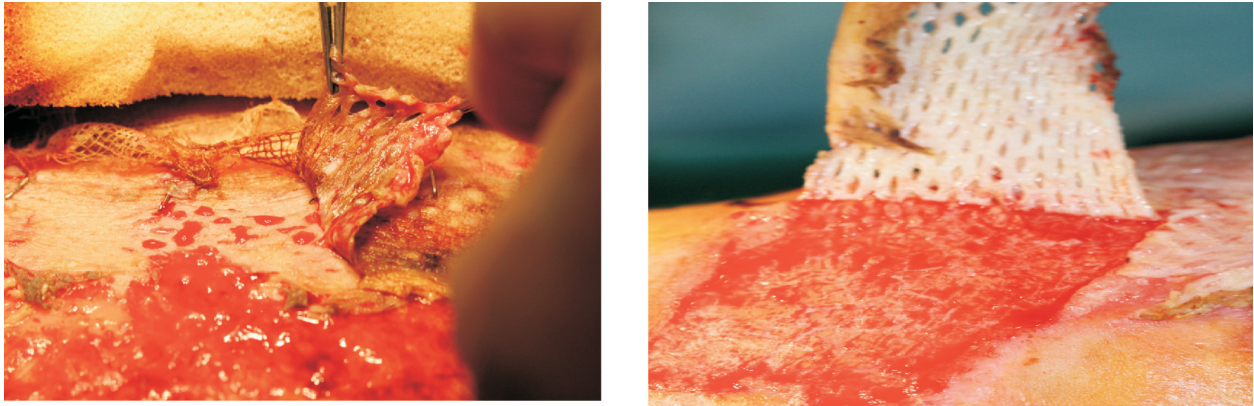


Fig. 2. The sandwich technique.



## CLINICAL CASES



**Fig. 3. The allografts applied on the chest were very well taken: no infection, good revascularisation.**

**Table 1**

### Postoperative results

Name Age	Patient T. 5 years			Patient N. 1 year			Patient L. 2 years								Patient B. 11 years	
TBSA %				30%			40%									
Total Body Surface Area	15% Width - 20 cm, Height - 15 cm, Undermining - 4 cm														9%	
III degree %				5%			15% (arms, left leg, thorax)									
Etiology	Necrotising fasciitis (Fournier syndrome)			Flame burn			Flame burn barbecue								Traffic accident	
Localisation	Inguinal region, left hypogastric			Right leg, right thigh, right thorax			Face, neck, thorax, upper limb, left thigh								Right gluteal region	
Number of operation	3			3			8								2	
Part of the body treated with the allografts	RI, RH	RI, RH	RI, RH	L T Th	T	L	Fc	Ab, T, A	A, Th	Sh	T	OA	T, A	T, A, L	F, H, Th	F, Th
Quantity of allografts, cm <sup>2</sup>	1310	230	90	195	90	90	260	1065	390	80	120	290	505	445	360	120
Postoperative results:																
% of Remaining wound	30 +/-	10 +	0 +	30 +/-	15 +/-	2 +	0 +	5 +	0 +	0 +	0 +	0 +	0% +	0% +	50% +/-	5% +
Adherence	-	-	-	-	-	-	-	-	-	-	-	-	-	-	-	-
Haematoma	+	+	+	+	+	+	+	+	+	+	+	+	+	+	+	+
Revascularization	-	-	-	-	-	-	-	-	-	-	-	-	-	-	-	-
Infection	-	-	-	-	-	-	-	-	-	-	-	-	-	-	-	-
Necrosis	-	-	-	-	-	-	-	-	-	-	-	-	-	-	-	-
Granulation Tissue																
-good	+	+	+	+	+	+	+	+	+	+	+	+	+	+	+	+
-fair																
-absent															+	
Epithelialization	+	+	+	+	+	+	+	+	+	+	+	+	+	+	+/-	+
Take rate, %	70	90	100	70	85	98	100	95	100	100	100	100	100	100	50	95
Complications	---			Hypertrophic scar, contracture			Contracture at the elbow and axilla								---	
Final grafts take, %	100%			98%			100%								95%	
Outcome	Complete wound closure in 3 weeks			Total reepithelialisation without grafting in 4 weeks			Sandwich technique after a month of treatment with GPA. Excellent take rate								Sandwich technique after 2 weeks of treatment with GPA. Excellent take rate	

RI – inguinal region; RH – hypogastric region; OA – open areas; L – leg; Fc – face; T – thorax; A – arm; Th – thigh; Ab – abdomen; Sh – shoulder; F – foot; K – knee.

w. p. b. after debridement, the GPA was applied (360 cm<sup>2</sup>). At the third w. p. b., it was noted a complete GPA take on the heel, very good revascularisation, a 50% take on the leg, and a failure of the homografts on the buttock. The debridement was performed and GPA was changed (120 cm<sup>2</sup>). At the fourth w. p. b., the buttock wounds were covered with the autografts. There was an excellent take of the autografts - 95%, without complications (tab. 1).

### Discussion

The properties of an ideal burn dressing can be summarized in four P's: protection, proteolytic effect, promotion of healing, and pain relieving. Glycerol preserved skin allograft possess several key characteristics of an ideal wound bed preparation, including good adherence to the wound bed, water vapour transport, antimicrobial characteristics, low toxicity and antigenicity, ease of application and removal, a long shelf life, and minimal storage requirements. There are other benefits of skin allograft application, such as decreased loss of water, electrolytes, and proteins. Skin allograft application also reduces pain and thus allows for exercise and ambulation, also decreasing the incidence of contractures [8].

The role of the GP skin allograft in wound bed preparation is very important: infection control; stimulation of angiogenesis; granulation tissue formation; biological dressing; wound bed preparation for skin grafting; testing of graft take.

GP skin allograft has a lot of advantages compared to cryopreserved one; it remains intact, if not vascularised, and is resistant to infection [9]. Cryopreserved skin allograft disappear if not revascularised within 3 days, and need to be changed more often, it also has no resistance to infection.

The GPA can be compared to other types of dressings such as a paraffin-impregnated dressing or silver sulphadiazine cream covered with gauze and elastic bandage. But, this kind of dressings has the following insufficiencies: long time use may be complicated by burn-wound infection and sepsis. A graft take on wound beds that have not been well prepared might end up with poor graft take. With the application of

GPA, we ensured that even in the extreme age group patients, such as children or the elderly, their wounds were optimised for the best chances of an autograft take at the first attempt [10]. Otherwise, autograft failure may lead to the grave consequence of repeated autografting with further waste of the donor sites, wound infection, sepsis, or even mortality. GPA is also considered in patients with whom frequent dressing changes have to be avoided, especially among the paediatric age group. The preserved dermal layer, even if it is thin, is crucial for spontaneous wound healing with minimal hypertrophic scarring, due to the reduced inflammatory response in the wound bed, as observed in our patients.

### References

1. Mackie David P. Postal survey on the use of glycerol-preserved allografts in clinical practice. *Burns*. 2002;28:S40-S44.
2. Vloemans AFPM, Middelkoop E, Kreis RW. A historical appraisal of the use of cryopreserved and glycerol-preserved allograft skin in the treatment of partial thickness burns. *Burns*. 2002;28:S16-S20.
3. Kreis RW, Vloemans AF, Hoekstra MJ, et al. The use of non-viable glycerol-preserved cadaver skin combined with widely expanded autografts in the treatment of extensive third-degree burns. *J Trauma*. 1989;29(1):51-4.
4. Richters CD, Hoekstra MJ, van Baare J. Immunogenicity of glycerol-preserved human cadaver skin in vitro. *J Burn Care Rehabil*. 1997;18(3):228-33.
5. Vloemans AFPM, Schreinemachers MCJM, Middelkoop E, et al. The use of glycerol-preserved allografts in the Beverwijk Burn Centre: a retrospective study. *Burns*. 2002;28:S2-S9.
6. Munster Andrew M, Weiner Steven H, Spence Robert J, et al. Cultured Epidermis for the Coverage of Massive Burn Wounds. *Ann. Surg*. 1990;211(6).
7. Vehmeyer-Heeman M, Holder C. Van, Nieman F, et al. Predictors of mortality: A comparison between two burn wound treatment policies. *Burns*. 2007;33(3):167-172.
8. Horch R, Stark GB, Kopp J, et al. Cologne Burn Centre experiences with glycerol-preserved allogeneic skin: Part I: Clinical experiences and histological findings (overgraft and sandwich technique). *Burns*. 1994;20(Suppl 1):S23-6.
9. Saegeman Veroniek SM, Ectors Nadine L, Lismont Daniel, et al. Short- and long-term bacterial inhibiting effect of high concentrations of glycerol used in the preservation of skin allografts. *Burns*. 2008;34(4):205-211.
10. Horch Raymund E, Jeschke Marc G, Spilker Gerald, et al. Treatment of second degree facial burns with Allografts - preliminary results. *Burns*. 2005;31:597-602.

