

Transcatheter aortic valve implantation. First experience of minimally invasive treatment in the Republic of Moldova

^{1,3}Marcel Abras, ^{1,3}Artiom Surev, ²Mariuca Vasa-Nicotera, ³Vitalie Moscalu,
^{1,3}Andrei Grib, ³Ion Popovici, ¹Catalina Beiu

¹Department of Internal Medicine, Cardiology, *Nicolae Testemitanu* State University of Medicine and Pharmacy
Chisinau, the Republic of Moldova

²Department of Cardiology, Cardiac Catheterization and Structural Heart Program
University Hospital of Frankfurt, Germany

³Department of Cardiac Catheterization, Institute of Cardiology, Chisinau, the Republic of Moldova

Authors' ORCID iDs, academic degrees and contributions are available at the end of the article

*Corresponding author: marcel.abras@usmf.md

Manuscript received on July 02, 2020; revised manuscript August 17, 2020; published online August 26, 2020

Abstract

Background: Aortic stenosis (AS) is the most prevalent primary heart valve disease and the third most prevalent cardiovascular disease in the world, having a severe and slowly progressive evolution. The implementation of Transcatheter Aortic Valve Implantation (TAVI) is necessary because the population is constantly ageing, and most elderly people have various comorbidities, which places them among patients with high surgical risk. The aim was to report immediate and 9 months follow-up results of first TAVI implantations in the Republic of Moldova.

Material and methods: Three patients with severe symptomatic AS and high surgical risk underwent TAVI implantation using Portico valves.

Results: The mean age was 76.7 ± 1.2 years, 2 women and 1 man. The mean Logistic EuroSCORE II was $5.68 \pm 0.67\%$. Procedural success was achieved in all (100%) patients. After the intervention, it was shown that the GP mean decreased by an average of 20.27 ± 1.61 mmHg, the Vmax of the jet through AoV decreased on average by 2.05 ± 0.19 m/s, and they were maintained all over the nine months follow-up period. Quality of life, using the TASQ (Toronto Aortic Stenosis Quality of Life) questionnaire, was improved by 62.3 ± 2.2 points.

Conclusions: TAVI, as a new minimally invasive method of treatment for aortic valve stenosis appears to be safe, with a low rate of early and late complications in elderly patients at high surgical risk, with good clinical outcomes at 9 months. Its implementation in the Republic of Moldova is welcome in the conditions of continuously ageing population and the prevalence of associated comorbidities.

Key words: aortic stenosis, high surgical risk, Transcatheter Aortic Valve Implantation, elderly patients.

Cite this article

Abras M, Surev A, Vasa-Nicotera M, Moscalu V, Grib A, Popovici I, Beiu C. Transcatheter aortic valve implantation. First experience of minimally invasive treatment in the Republic of Moldova. *Mold Med J.* 2020;63(3):58-65. doi: 10.5281/zenodo.3958567.

Introduction

Aortic stenosis (AS) is the most prevalent primary heart valve disease [1] and the third most prevalent cardiovascular disease in the world, having a severe and slowly progressive evolution [2]. This pathology is defined by fibro-calcific remodeling of the normal aortic valve (AoV) (tricuspid) or congenital abnormal AoV (bicuspid), which results in the narrowing of the valve opening through a degenerative mechanism. Its evolution is specific for elderly patients, who have other comorbidities and is associated with progressive heart dysfunction. Patients with severe symptomatic AS, without any intervention, reach a fatal rate of about 50% at 2 years and the only way to stop the progression to a terminal heart disease is valve replacement [2, 3].

A meta-analysis of studies conducted in Europe and USA concluded that the prevalence of AS is 12.4% among the population, and for those over the age of 75 years is 3.4% [4], so that more than 1 out of 8 people over the age of 75 suffer from this pathology [5]. As the population ages, AS

becomes an important issue both in terms of declining patients' quality of life and in terms of the impact on the health care system [5].

Until recently, the golden standard and the only solution in treating AS was surgical aortic valve replacement (SAVR). However, the risks associated with SAVR are increased in elderly patients and those with severe systolic heart failure or concomitant coronary heart disease, as well as in patients with comorbidities such as cerebrovascular and peripheral arterial disease, chronic renal disease and chronic respiratory failure. Approximately one third of the patients with AS are inoperable or have a high surgical risk with the SAVR method [5, 6].

Thus, in 2002, Alain Cribier came up with an alternative for the replacement of stenotic AoV, namely the Transcatheter Aortic Valve Implantation (TAVI) [7]. The introduction of the new method of treatment has revolutionized the management of aortic stenosis [8]. Several studies, where first-generation devices have been used, have established the superiority of TAVI compared to medical therapy

that includes valvuloplasty in patients at high surgical risk [8]. Subsequently, TAVI has been proposed as a valuable alternative to SAVR in an ever-widening spectrum of patients with severe symptomatic AS. The safety and efficacy of TAVI were initially established in high surgical risk patients in the PARTNER Study 1A, US CoreValve High-risk Trial who presented comparable clinical results [9] non-inferior to SAVR [8, 10].

This intervention is minimally invasive and is based on the percutaneous implantation of a self-expanding AoV prosthesis, replacing the dysfunctional native valve, through a catheter, using transfemoral approach (also the transapical or transaortic approach might be considered). Due to the indications of TAVI, this represents an excellent opportunity for patients with an increased or intermediate surgical risk, or those who are inoperable [11]. The basic indications for TAVI, respecting the clinical aspects, would be STS / EuroSCORE II > 4%, presence of severe comorbidities, age > 75 years, previously undergone cardiac surgery, patient fragility which is associated with increased morbidity and mortality after surgery and TAVI, reduced motility and conditions that would affect the post-procedural rehabilitation process. Also, the anatomical aspects of the patients are taken into account, first of all a favorable transfemoral access for TAVI, porcelain aorta, the presence of coronary bypass with previous sternotomy, possible patient-prosthesis mismatch, severe thoracic deformities, post-radiation thoracic sequelae (tab. 1) [1].

At this stage, companies producing new-generation TAVI devices are developing important technological refinements, including reduced size delivery systems, trying to avoid or minimize paravalvular leakage. Broadly speaking, for clinical use, there are two main categories of AoV transcatheter prostheses: balloon-expandable valves and self-expandable valves [8].

The Portico Valve System (St. Jude Medical; Minneapolis, Minnesota, USA) is a second-generation transcatheter AoV, a self-expandable prosthesis that consists of a trifoliate bovine pericardial valve and a porcine pericardial sealing cuff attached to a nitinol frame, all meant to reduce paravalvular leakage. The delivery system allows full resheathing and repositioning prior to complete valve deployment until 80-90% of deployment, which is potentially one of the

most important advantages of this transcatheter heart valve. At this stage, the annular section of the prosthesis has full contact, allowing the assessment of placement and hemodynamic function before its final release. In addition, the leaflets are designed to function at an intra-annular aortic position, which helps maintain hemodynamic stability during implantation [12].

As a result of a fruitful collaboration with the specialists of the University Hospital of Frankfurt, in October 2019, as a premiere for the Republic of Moldova, transcatheter AoV prostheses were implanted. Being the first team of doctors who performed TAVI in our country, we have the opportunity to report the data of a series of cases, with clinical follow-up at 9 months after the procedure.

Material and methods

I. The team

The team consisted of two cardiologists, a cardiovascular surgeon, an anesthesiologist and an echocardiographer. Interventional cardiologists underwent a training program in the University Hospital of Frankfurt. The first three cases were performed under the supervision of Doctor Mariuca Vasa-Nicotera, Frankfurt, Germany.

II. The patients

The first patients to benefit from the procedure were 2 women and a man, the mean age was 76.7 ± 1.2 years, with a severe degree of AoV calcification, who could not undergo SAVR due to the high surgical risk. Patients underwent coronary angiography, echocardiography and computed tomography to determine the coronary blood flow, structural cardiac parameters, AoV size and the surgical approach.

Patient No 1, woman, 79 years old.

She was admitted with severe AS documented following M-mode and two-dimensional echocardiography, with a mean pressure gradient of 58.33 mmHg and a maximal jet velocity through the AoV of 5.06 m/s, moderate AoV regurgitation, marked left ventricular (LV) myocardial hypertrophy with accelerated flow in the LV outflow tract, ejection fraction being 59% (fig. 1). On computed tomography was determined aortic valve with an annulus perimeter of 68.8 mm, its area of 363.8 mm², and a diameter of 21.5 mm (fig. 2). Also, the patient had a porcelain aorta (fig. 3). Coronary angiography revealed no stenotic lesions

Table 1

Indications for aortic stenosis interventions and the recommendations for choosing the type of intervention [1].

Symptomatic patients with aortic stenosis	Class	Level
The intervention is indicated for symptomatic patients with severe aortic stenosis, severe high gradient (AV Vmax >4 m/s or mean gradient >40 mm Hg)	I	B
Indicated in patients with low-flow low-gradient severe AS (<40 mmHg) with reduced ejection fraction and evidence of contractile reserve excluding pseudo-severe AS.	I	C
Intervention should be considered in patients with symptomatic low-flow low-gradient severe AS (<40 mmHg), with preserved ejection fraction, after careful confirmation of severe AS.	IIa	C
Intervention should be considered in patients with low-flow low-gradient severe AS with reduced ejection fraction without evidence of contractile reserve especially where CT calcium scoring confirms severe AS.	IIa	C

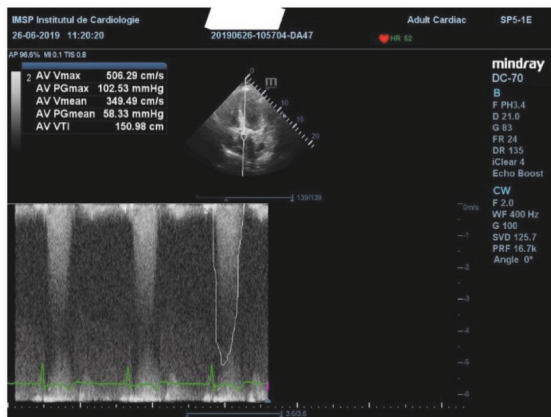


Fig. 1. Echocardiography, patient No 1

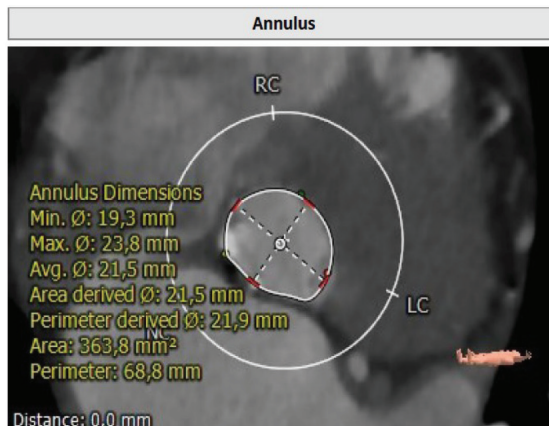


Fig. 2. CT of aortic valve, patient No 1

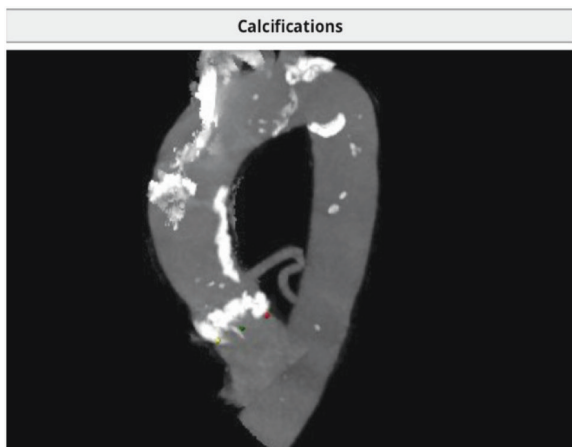


Fig. 3. CT, porcelain aorta, patient No 1

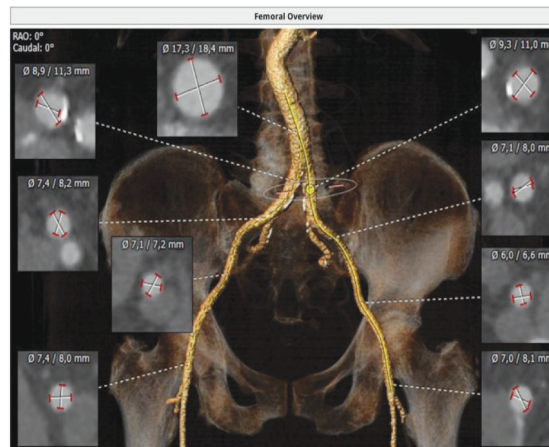


Fig. 4. CT, iliac arteries, patient No 1

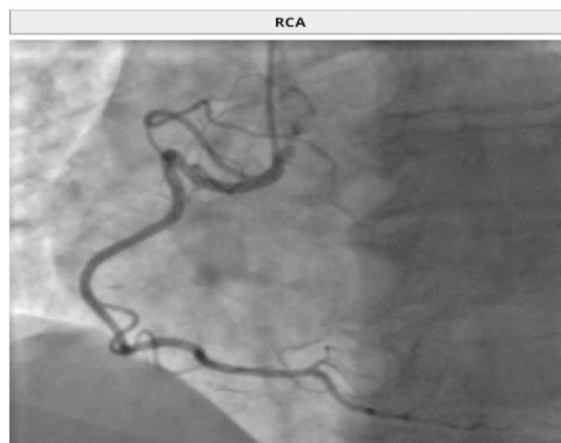


Fig. 5. Coronography, patient No 1

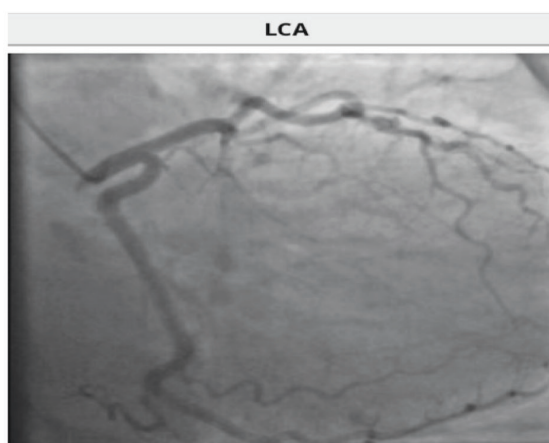


Fig. 6. Coronography, patient No 1.

of the coronary arteries (fig 5, 6). Calculated in advance, the patient had an Euroscore II of 6.14%.

The size of the selected valve, according to the above parameters, was 25 mm. After analysing the anatomical aspects of the iliac and femoral arteries (fig. 4), the approach for intervention was chosen, namely the right femoral one.

Patient No 2, man, 76 years old.

At admission, he presented with severe AS and several comorbidities such as dyslipidemia, type 2 diabetes, chronic bronchitis in partial remission, left renal cysts, right eye

blindness, obesity class II, discirculatory encephalopathy. Euroscore II calculated was 6.53%.

Following M-mode and two-dimensional real-time cardiac ultrasonography, AoV critical stenosis was determined with a mean pressure gradient at the aortic valve of 36.57 mmHg, the maximal aortic jet velocity being 3.84 m/s and the ejection fraction of the left ventricle 36% (fig. 7). The computed tomography showed an aortic valve annulus with a diameter of 24.7 mm, an area of 450.5 mm² and a perimeter of 77.9 mm (fig. 8, 9). Coronary angiography did not de-

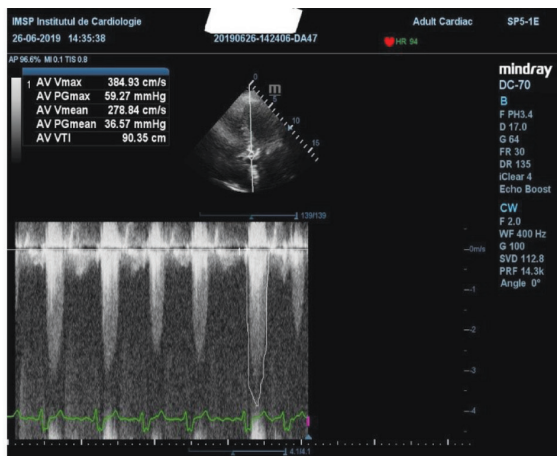


Fig. 7. Echocardiography, patient No 2

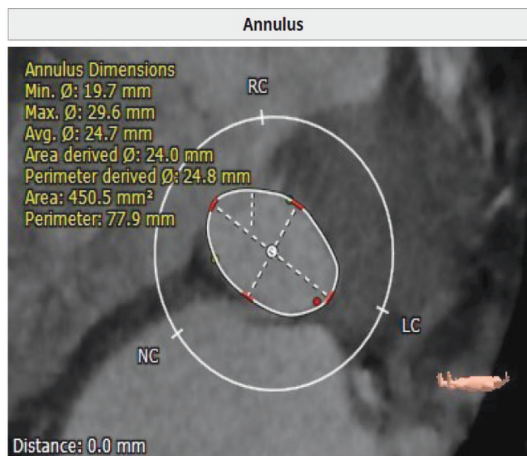


Fig. 8. CT aortic valve, patient No 2

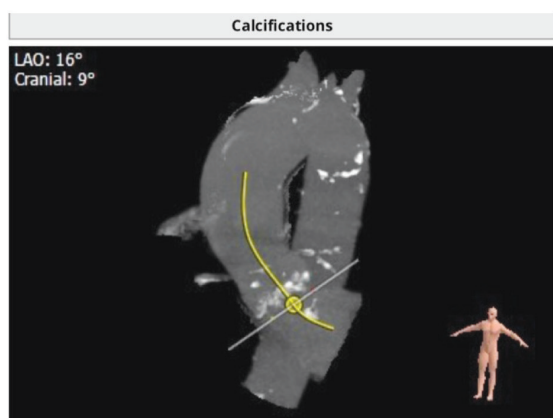


Fig. 9. CT, aorta, patient No 2

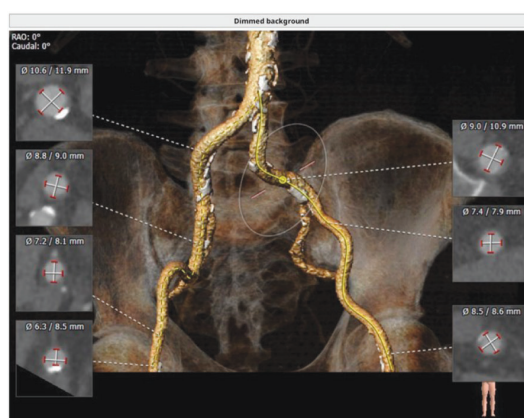


Fig. 10. CT, iliac arteries, patient No 2

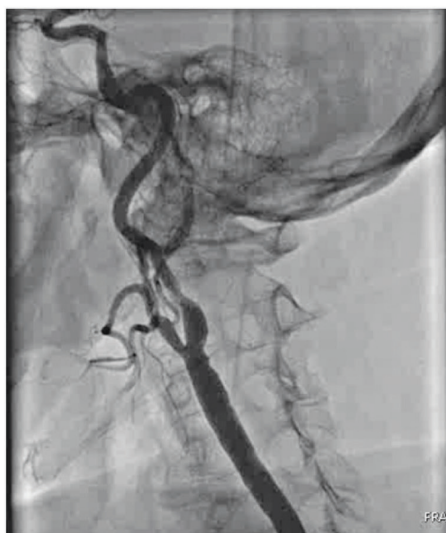


Fig. 11. Left carotid artery angiography, patient No 2

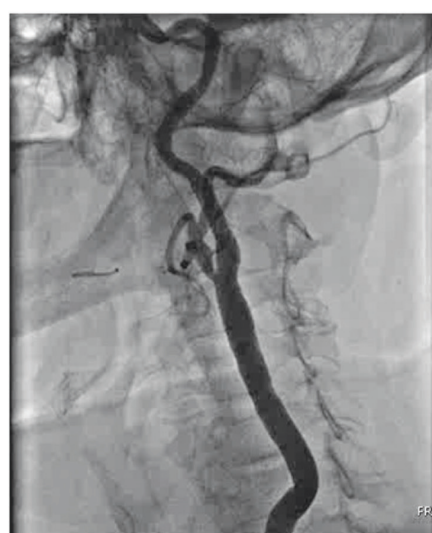

Fig. 12. Left internal carotid artery angiography, after angioplasty

termine stenoses on the coronary arteries but revealed critical stenosis with the appearance of unstable plaque on the left internal carotid artery (fig. 11). Two weeks before the procedure, the patient successfully underwent carotid angioplasty with self-expanding stent implantation (PROTEGE Rx) (fig. 12).

According to these data, the size of the valve should be 27 mm, but due to ellipticity of the valve, a 29 mm one was chosen. The geometric construction of the valve allows it to shape itself to various anatomical variations, but also to easily attach to the calcifications of the native valve, without deforming the nitinol frame. Analysing the anatomical as-

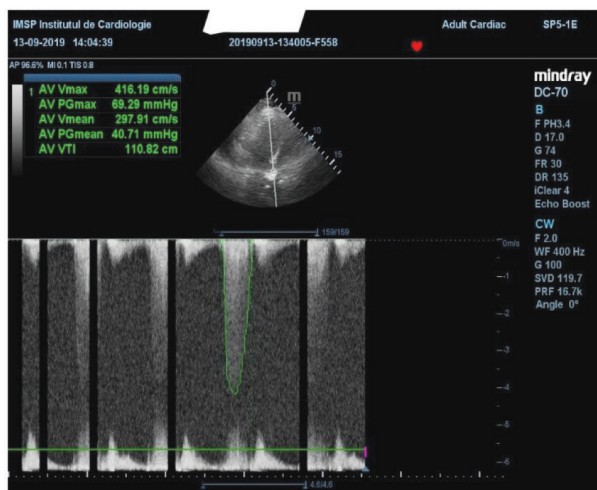


Fig. 13. Echocardiography, patient No 3

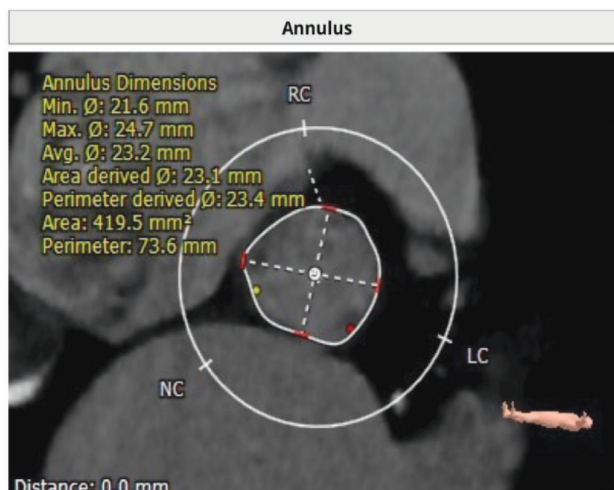

Fig. 14. CT of the aortic valve, patient No 3

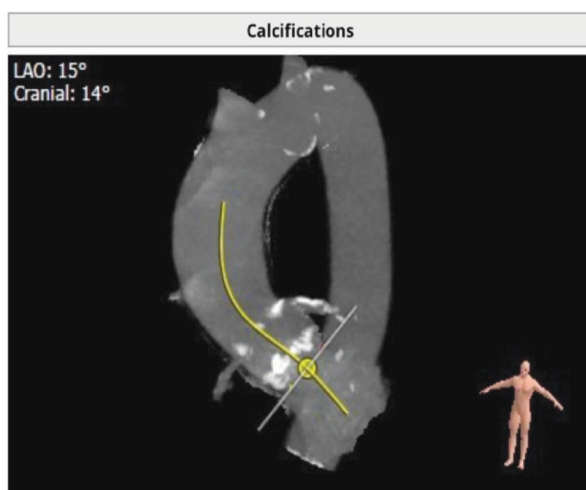


Fig. 15. CT of aorta, patient No 3

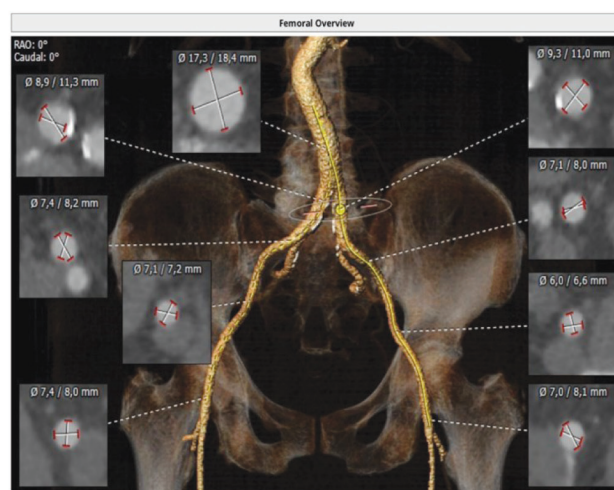


Fig. 16. Iliac arteries CT, patient No 3

pect of the iliac and femoral arteries (fig. 10), it was decided to select the approach for intervention – the left femoral.

Patient No 3, woman, 75 years old.

The patient was admitted with diagnosis of severe AS, left bundle branch block, permanent atrial fibrillation, high thromboembolic risk (CHADS VASc = 6), NYHA class III heart failure, stage III hypertension, very high additional risk, dyslipidemia, ischemic stroke endured in 2015. Euroscore II, calculated, was 4.36%. Following M-mode and two-dimensional real-time cardiac ultrasonography, severe AS with a mean pressure gradient of 40.71 mmHg was determined, the maximal jet velocity at AoV level being 4, 16 m / s, mild AoV insufficiency, moderate mitral valve and tricuspid valve insufficiency, ejection fraction of 55% (fig. 13). On the computed tomography, the aortic valve annulus has a perimeter of 73.6 mm, an area of 419.5 mm², and a diameter of 23.2 mm (fig. 14, 15). Coronary angiography does not determine stenotic lesions of the coronary arteries (fig. 17, 18). Analysing the above data, it was decided to implant a 27 mm valve. Examining the anatomical aspect of the iliac and femoral arteries (fig. 16), it was decided to select the approach for the intervention, right femoral artery.

I. Devices

Portico prosthetic valves, which were used for all 3 patients, consist of a self-expandable nitinol frame, with rhomboid spaces in which pericardial tissue of bovine or porcine origin is arranged, with an available diameter of 23 to 29 mm (tab. 2). This valve undergoes a Linx AC (anti-calcification) treatment, based on ethanol, which has been shown to be effective in reducing the calcification in animal tissues [12]. The mandatory component of the valve is a flexible and easy-to-navigate Portico delivery system, which has an 18Fr / 19Fr (6.0 / 6.5 mm) delivery sheath.

Table 2

Anatomical parameters of prosthetic valve selection

Portico Valve size	Aortic annulus diameter (mm)	Aortic annulus area (mm ²)	Aortic annulus perimeter (mm)
23 mm	19-21	277-346	60-66
25 mm	21-23	338-415	66-73
27 mm	23-25	405-491	72-79
29 mm	25-27	479-573	79-85

II. The procedure

Patients were given clopidogrel and aspirin prior to intervention, immediately before the procedure – antibiotics for the prophylaxis of potential infections, and unfractionated heparin (100 U/kg) throughout the procedure. All three patients underwent general anaesthesia.

The minimally invasive intervention was performed in a cardiac catheterization room, in sterile conditions. In all 3 cases, the transfemoral approach was used, the femoral artery being cannulated using the Seldinger technique with placement of the femoral sheath on the contralateral side, a femoral access was obtained for aortic angiography. Also, a venous access was made for a temporary pacemaker, later used for rapid ventricular pacing, its proper placement being verified by a rapid ventricular pacing test at the rate of 200 beats per minute. At the same time, the angiography of the aorta was made, choosing the optimal projection in which all the aortic cusps are aligned. Through the femoral artery, the valve delivery sheath was inserted (18F for the 25 mm valve, and 19F for the 27 mm and 29 mm valves). A left Amplatz catheter (AL) on a J-shaped tip guidewire was used to pass the arch of aorta, then this guidewire was changed to a straight-tipped one, the native aortic valve being crossed through the non-coronary cusp, then advancing the AL catheter into the left ventricle. To avoid perforation of the ventricle, the AL was changed on a pigtail catheter, and the straight guidewire, again, on a J-shaped type.

During a rapid ventricular pacing, 200 rpm, under fluoroscopic guidance, balloon valvuloplasty was performed (fig. 17), its role being in cracking the calcifications of the affected valve. After removing the balloon, the prosthetic valve and its delivery system were inserted through the delivery sheath, advanced through the descending aorta, carefully crossing the aortic arch, then the ascending aorta. Again, under fluoroscopic guidance, the valve was positioned accordingly (fig. 18). Rapid ventricular pacing was initiated, and when systolic pressure reached its lowest level, the aortic valve was expanded (fig. 19).

At the next stage, the pacing was stopped and a repeated angiography and echocardiography were performed, so that the good functionality of the valve and the lack of paravalvular regurgitation might be appreciated. Subsequently, it proceeded to the stage of releasing the valve from the delivery

system. One by one, the delivery system, the catheter and the delivery sheath were removed. At the time of removal, blood pressure was carefully monitored, with simultaneous injection of contrast, to rule out a possible vascular rupture.

Hemostasis after femoral arteriotomy was performed using the Perclose ProGlide occlusion system. After TAVI, patients had to take clopidogrel for 6 months, and aspirin for indefinite amount of time.

Echocardiography follow-ups were performed immediately after the procedure, at 24h, 1 week, 1 month, 3 months, 6 months and 9 months after implantation.

Quality of life (QoL) is an important consideration for aortic stenosis patients. The TASQ is questionnaire (Toronto Aortic Stenosis Quality of Life), is a QoL tool that was developed to evaluate the psychometric properties of patients who underwent TAVI. TASQ is a questionnaire of 16 items, with 4 subdivisions, namely: symptoms – 2 items, physical limitations – 4 items, emotional impact – 7 items, social limitations – 2 items and one item that reflects health expectations. For each item, patients should expose the impact of aortic stenosis on their quality of life scale anchored by “not very much” – 1 point, to “very much” – 7 points. Total scores can range from 16 to 112, with the highest reflecting a better quality of life [13]. The patients respond at this questionnaire before the intervention and at 9 months after it.

Results

Procedure results and complications

Procedural success was achieved among all (100%) patients included in this case series analysis. All patients underwent the procedure through the femoral approach, which was afterwards sutured using Perclose ProGlide device, without any further complications at the puncture site. Patient No 2 developed a complete atrioventricular block after the placement of the valvular prosthesis and needed a permanent cardiac stimulator to be implanted. Other peculiarities during the performance of TAVI did not interfere and no serious complications occurred in the recovery process of the patients (tab. 3). The average length of the hospital stay was 6 days.

Following TAVI, in all 3 patients who benefited from the intervention, the functional parameters of the heart improved considerably. Post-procedurally, the ventriculog-

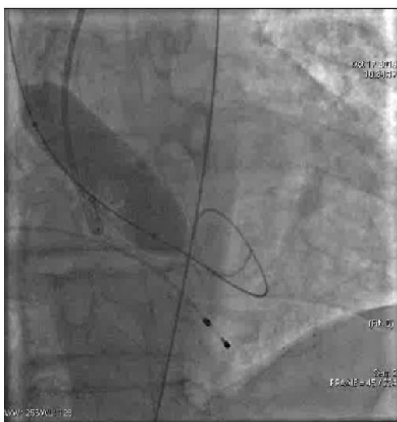

Fig. 17. Balloon valvuloplasty

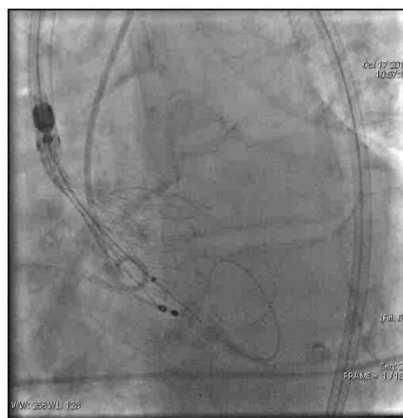


Fig. 18. Prosthetic valve positioning

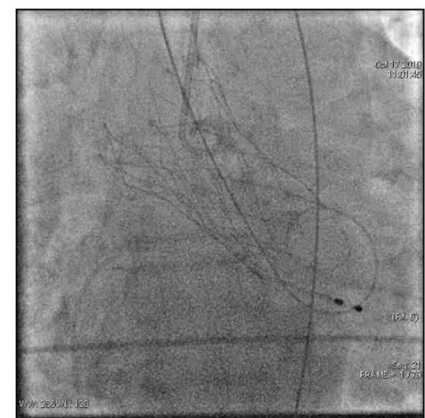

Fig. 19. Expanded prosthetic valve

raphy showed normal transvalvular flow at the AoV level, without mitral regurgitation, with a clearly improved ejection fraction.

Table 3**Possible post-procedural complications**

Aortic regurgitation > grade I	1/3
Paravalvular leak > mild	0/3
Valve embolization	0/3
Valve-in-valve implantation	0/3
Coronary obstruction	0/3
Myocardial infarction	0/3
Left ventricular perforation	0/3
Permanent pacemaker	1/3
Vascular complications in trans-femoral approach	0/3
Transient ischemic attack	0/3
Procedure-related death	0/3

One week after the intervention, following a repeated echocardiography, it was shown that the GP mean decreased by an average of 20.27 ± 1.61 mmHg, the Vmax of the jet through AoV decreased on average by 2.05 ± 0.19 m/s, with an aortic orifice, obviously of a normal size. At nine months the GP mean decreased by an average of 28.4 ± 3.21 mmHg, the Vmax of the jet through AoV decreased on average by 2.32 ± 0.03 m/s in patient 1, a mild paravalvular leak was found, but without any symptoms (tab. 4).

Quality of life was assessed using the TASQ (Toronto Aortic Stenosis Quality of Life) questionnaire. We can mention a growth in the perception of quality of life in patient 1 from 30 to 95 points, in patient 2 from 34 to 98 points and in patient 3 from 38 to 96.

Discussion

This first experience in the Republic of Moldova, regarding TAVI, gives results similar to the ones from other studies and centres with experience in performing these minimally invasive interventions [8, 12]. The success rate depends on a good training of the team, adequate selection of the patients and the proper choice of the valve prosthesis, as well as the careful supervision of an experienced proctor.

Until the implementation of TAVI in the Republic of Moldova, experience in minimally invasive approach on aortic pathology was only in the case of aortic coarctation [14]. The large number of patients with severe AS over the age of 75, with multiple comorbidities and high surgical risk, to whom the replacement of the valve by surgery is often refused, imposed the need to implement these interventions in the Republic of Moldova.

The Portico TAVI system study demonstrates that the treatment of elderly patients, with severe AS, using the full range of sizes of self-expandable, resheathable, repositionable and retrievable Portico valves leads to significant improvements in aortic valve function at 1 year. Importantly, the improvement was observed in the presence of a low rate of paravalvular regurgitation and new pacemakers implantations [12] similar to the results obtained in our patients. Conduction disorders that require implantation of a permanent pacemaker after TAVI are generally more common in patients who have implanted self-expanding transcatheter valves compared to those who have balloon-expandable devices. A large US registry reported a 30-day permanent pacemaker implantation rate of 25.1% among patients who received a Portico self-expanding valve, that is in line with pacemaker implantation rates reported for other TAVI self-expanding devices (22%-26%) [15].

Adequate hemodynamic performance was observed by echocardiographic evaluation, with stable hemodynamic characteristics between 30 days and 1 year of follow-up. Paravalvular regurgitation is a rare phenomenon, due to the better patient selection, using multidetector computed tomography system, continuous increasing of experience among the operators and the possibility of repositioning the device. No patients reported severe paravalvular regurgitation at one-year follow-up [8].

The symptoms associated with AS can lead to a much diminished quality of life, interfering in the patient's ability to integrate into normal daily activities but also in relationships with other people. Understanding the effect of the pathology on the patient's life is an essential step in planning the proper treatment that will optimize the management

Table 4**Survival, symptomatic (NYHA) and echocardiographic data, compared over time**

	Patient 1			Patient 2			Patient 3		
	IF	PP	9M	IF	PP	9M	IF	PP	9M
Survival	+	+	+	+	+	+	+	+	+
NYHA class	III	II	II	III	II	II	III	II	II
AVA (mm ²)	363.8	NA	NA	450.5	NA**	NA	419.5	NA	NA
MPG (mmHg)	58.33	36.0	23.6	36.57	16.4	12.3	40.71	22.4	14.5
Peak velocity (m/s)	5.06	3.0	2.7	3.84	1.6	1.5	4.16	2.3	1.9
Annulus (mm)	21.5	NA	NA	24.7	NA	NA	23.2		NA
Ejection fraction	59%	62%	62%	36%	44%	48%	55%	63%	63%
AR grade	II	II	II	II	II	II	I	I	I

*IF – initial features, PP – post-procedural, 9M – 9 months after the procedure, **NA – Non-appreciable,

AVA – aortic valve area, MPG – mean aortic valve pressure gradient, AR grade – grade of aortic valve insufficiency.

of the pathology and the quality of the results. Comparing the patients' responses before the intervention with those at 9 months after it, we can say with certainty that TAVI has changed their perception of life, giving them both satisfaction and hope to live as long as possible.

The implementation of TAVI in the Republic of Moldova is necessary because we can say that the population is constantly aging, and most elderly people have various comorbidities, which place them among patients with high surgical risk. This method is a minimally invasive alternative that gives us predictable and reproducible results, progressively becoming safe and effective. A multidisciplinary team approach is recommended in the management of the patients with AS, because the decisions that should be taken in this pathology are very complex [1].

However, the high costs of this intervention and the limited financial resources available in a developing country are the main impediments to the widespread application of this new method of treating AS in the Republic of Moldova.

Conclusions

Transcatheter aortic valve implantation, as a new minimally invasive method of treatment for aortic valve stenosis appears to be safe, with a low rate of early and late complications in elderly patients at high surgical risk, with good clinical outcomes at 9 months. Its implementation in the Republic of Moldova is welcome in the conditions of continuously aging population and the prevalence of associated comorbidities.

References

1. Baumgartner H, Falk V, Bax JJ, et al. 2017 ESC/EACTS Guidelines for the management of valvular heart disease. *Eur Heart J*. 2017;38(36):2739-2791. doi: 10.1093/eurheartj/ehx391.
2. Nathaniel S, Saligram S, Innasimuthu AL, et al. Aortic stenosis: an update. *World J Cardiol*. 2010 June 26;2(6):135-139. doi: 10.4330/wjc.v2.i6.135.
3. Lindman BR, Clavel MA, Mathieu P, et al. Calcific aortic stenosis. *Nat Rev Dis Primers*. 2016 Mar 3;2:16006. doi: 10.1038/nrdp.2016.6.
4. Osnabrugge RL, Mylotte D, Head SJ, et al. Aortic stenosis in the elderly:

- disease prevalence and the number of candidates for transcatheter aortic valve replacement: a meta-analysis and modeling study. *J Am Coll Cardiol*. 2013;62(11):1002-12. doi: 10.1016/j.jacc.2013.05.015.
5. Bouma BJ, van Den Brink RB, van Der Meulen JH, et al. To operate or not on elderly patients with aortic stenosis: the decision and its consequences. *Heart*. 1999 Aug;82(2):143-8. doi: 10.1136/hrt.82.2.143.
 6. Iung B, Cachier A, Baron G, et al. Decision-making in elderly patients with severe aortic stenosis: why are so many denied surgeries? *Eur Heart J*. 2005 Dec;26(24):2714-20. doi: 10.1093/eurheartj/ehi471.
 7. Cribier A, Eltchaninoff H, Bash A, et al. Percutaneous transcatheter implantation of an aortic valve prosthesis for calcific aortic stenosis: first human case description. *Circulation*. 2002;106(24):3006-3008. doi: 10.1161/01.cir.0000047200.36165.b8.
 8. Giordano A, Corcione N, Ferraro P, et al. Comparative one-month safety and effectiveness of five leading new-generation devices for transcatheter aortic valve implantation. *Sci Rep*. 2019;9(1):17098. doi: 10.1038/s41598-019-53081-w.
 9. Siontis GCM, Overtchouk P, Cahill TJ, et al. Transcatheter aortic valve implantation vs surgical aortic valve replacement for treatment of symptomatic severe aortic stenosis: an updated meta-analysis. *Eur Heart J*. 2019;40(38):3143-3153. doi: 10.1093/eurheartj/ehz275.
 10. Tzamalīs P, Alataki S, Bramlage P, et al. Comparison of valve durability and outcomes of transcatheter aortic valve implantation versus surgical aortic valve replacement in patients with severe symptomatic aortic stenosis and less-than-high-risk for surgery. *Am J Cardiol*. 2020;125(8):1202-1208. doi: 10.1016/j.amjcard.2020.01.015.
 11. Adams DH, Popma JJ, Reardon MJ, et al. Transcatheter aortic-valve replacement with a self-expanding prosthesis. *N Engl J Med*. 2014;370:1790-1798. doi: 10.1056/NEJMoa1400590.
 12. Linke A, Holzhey D, Mollmann H, et al. Treatment of aortic stenosis with a self-expanding, resheathable transcatheter valve: one-year results of the international multicenter Portico transcatheter aortic valve implantation system study. *Circ Cardiovasc Interv*. 2018;11:e005206. doi: 10.1161/CIRCINTERVENTIONS.117.005206.
 13. Styra R, Dimas M, Svitak K, et al. Toronto aortic stenosis quality of life questionnaire (TASQ): validation in TAVI patients. *BMC Cardiovasc Disord*. 2020;20(1):209. doi: 10.1186/s12872-020-01477-2.
 14. Popovici I, Liuba P, Surev A, Grib A, Abras M, Calenici E, Damascan S, Esanu A. Short-term clinical follow-up of the treatment of aortic coarctation with a new generation of device. *Rom J Cardiol*. 2018;28(2):160-167.
 15. Fadahunsi OO, Olowoyeye A, Ukaigwe A, et al. Incidence, predictors, and outcomes of permanent pacemaker implantation following transcatheter aortic valve re-plantation: analysis from the U.S. Society of Thoracic Surgeons/ American College of Cardiology TVT Registry. *JACC Cardiovasc Interv*. 2016;9(21):2189-2199. doi: 10.1016/j.jcin.2016.07.026.

Authors' ORCID iDs and academic degrees

Marcel Abras, MD, PhD, Associate Professor – <https://orcid.org/0000-0003-2640-978X>.
 Artiom Surev, MD, Assistant Professor – <https://orcid.org/0000-0002-8303-2256>.
 Mariuca Vasa-Nicotera, MD, PhD, Professor – <https://orcid.org/0000-0002-6794-4941>.
 Vitalie Moscalu, MD, PhD, Associate Professor – <https://orcid.org/0000-0001-7129-9298>.
 Andrei Grib, MD, Assistant Professor – <https://orcid.org/0000-0002-4627-3819>.
 Ion Popovici, MD, PhD, Associate Professor – <https://orcid.org/0000-0002-0371-0791>.
 Catalina Beiu, MD, Undergraduate – <https://orcid.org/0000-0002-8610-6441>.

Authors' contribution

AG, CB and IP acquired, interpreted the data, drafted the first manuscript, MA, AS, MN and VM performed most of the analyzed interventions, MA designed the trial and revised the manuscript critically. All the authors revised and approved the final version of the manuscript.

Funding

The study was supported by *Nicolae Testemitanu* State University of Medicine and Pharmacy. The authors are independent and take responsibility for the integrity of the data and accuracy of the data analysis.

Ethics approval and consent to participate

The research was approved by the Research Ethic Board research (protocol No 12 of September 20, 2019) of *Nicolae Testemitanu* State University of Medicine and Pharmacy. Written informed consent was obtained from all participants in the study.

Conflict of Interests: The authors have no conflict of interest to declare.