

ISSN 1392-0995, ISSN 1648-9942 (online)

DOI: <https://doi.org/10.15388/LietChirur.2017.1.10487><http://www.chirurgija.lt>

LIETUVOS CHIRURGIJA

Lithuanian Surgery

2017, 16 (2), p. 108–113

Iatrogenic colonic perforation by colonoscopy: outcomes of surgery at a single center

Jatrogeninė kolonoskopinė storosios žarnos perforacija: vieno centro chirurginio gydymo rezultatai

Edgaras Smolskas¹, Audrius Dulskas¹, Inga Kildušienė¹, Eugenijus Stratilatovas¹, Narimantas E. Samalavičius^{1,2}

¹ *National Cancer Institute, 1 Santariskių Str., LT-08660 Vilnius, Lithuania*

² *Clinic of Internal, Family Medicine and Oncology, Faculty of Medicine, Vilnius University, 2 Santariskių Str., LT-08661 Vilnius, Lithuania*
E-mail: audrius.dulskas@gmail.com

¹ *Nacionalinis vėžio institutas, Santariskių g. 1, LT-08660 Vilnius, Lietuva*

² *Vilniaus universiteto Medicinos fakulteto Vidaus ligų, šeimos medicinos ir onkologijos klinika, Nacionalinis vėžio institutas, Santariskių g. 2, LT-08661 Vilnius, Lietuva*
El. paštas: audrius.dulskas@gmail.com

Background

Although the incidence of iatrogenic colonoscopic perforation is low, it can result in severe complications and mortality. This study assessed the incidence and surgical management outcomes of iatrogenic colonic perforations.

Materials and Methods

We reviewed all the medical records of patients with colonic perforations during diagnostic or therapeutic colonoscopies from January 2007 to December 2016 at National Cancer Institute. We collected the patient's demographic data, colonoscopic reports, and data regarding the location of perforations, their treatment and outcome.

Results

16 186 colonoscopies were performed at National Cancer Institute. The overall perforation rate was 0.14% (23 of 16 186). Of the total 23 colon perforations, 20 were managed operatively. The most common location was the sigmoid colon, in 12 cases. The most used surgical technique was simple suture (11 cases) followed by resection with anastomosis (6 cases). Three patients died (one because of multiple organ failure caused by acute bronchopneumonia and two patients with intra-abdominal sepsis died due cardiopulmonary insufficiency).

Conclusions: If surgery and its associated morbidity can be avoided in cases of colonic perforation the negative impact of a colonoscopy-associated complication can be minimized considerably. Patients need to be informed of the complications of colonoscopy, and clinicians must be cautioned about the potential problems for patients with a high anaesthetic risk when performing the procedure.

Key words: colonoscopy, colonic perforation, peritonitis, iatrogenic injury

Ivadas

Nors kolonoskopinių gaubtinės žarnos perforacijų dažnis nėra didelis, tačiau jos gali lemti sunkias komplikacijas ar net mirtį. Šios studijos tikslas buvo įvertinti kolonoskopinių gaubtinės žarnos perforacijų dažnį ir jų chirurginio gydymo rezultatus.

Metodai

Retrospektyviai buvo peržiūrėti duomenys pacientų, kuriems atliekant diagnostinę ar gydomąją kolonoskopiją Nacionaliniame vėžio institute nuo 2007 m. sausio 1 d. iki 2016 m. gruodžio 31 d. įvyko gaubtinės žarnos perforacijos. Analizuoti pacientų demografiniai rodikliai, kolonoskopijos duomenys, informacija apie jų gydymą ir gydymo rezultatus.

Rezultatai

Iš viso Nacionaliniame vėžio institute minėtu laikotarpiu buvo atlikta 16 186 kolonoskopijos. Bendras kolonoskopinių gaubtinės žarnos perforacijų dažnis siekė 0,14 % (23 iš 16 186 pacientų). Iš šių 23 perforacijų 20 atvejų buvo taikytas chirurginis gydymas. Daugiausiai perforacijų įvyko riestinėje žarnoje (12 atvejų). 11 atvejų defektas žarnoje buvo užsiūtas, 6 atvejais atlikta žarnos rezekcija su pirmine anastomoze. Viena mirtis įvyko dėl ūmios bronchopneumonijos išsivysčius dauginiams organų disfunkcijos sindromui, kiti du pacientai, kuriems pasireiškė pilvo ertmės sepsis, mirė nuo kardiopulmoninio nepakankamumo.

Išvados

Jeigu kolonoskopinės gaubtinės žarnos perforacijos atvejais pavyktų išvengti operacijos ir ją lydinčių sunkių komplikacijų, tai leistų reikšmingai sumažinti kolonoskopijos komplikacijos padarinius. Visus pacientus prieš procedūrą būtina įspėti apie galimas komplikacijas, o gydytojai turi būti itin atidūs, jei pacientas priklauso didelės rizikos grupei.

Reikšminiai žodžiai: kolonoskopija, žarnos perforacija, peritonitis, iatrogeninis pažeidimas

Introduction

The widespread colorectal cancer screening program and the expansion of the indications for therapeutic endoscopy resulted in an increase number of complications associated with colonoscopy [1]. The most common complications which can occur during procedure are bleeding and perforation [2]. The risk of colonic perforation after diagnostic colonoscopy is estimated to be 0.03–0.9% and 0.15–2% for therapeutic colonoscopy [3–5]. Interventions performed during colonoscopy, such as biopsy, polypectomy, and endoscopic submucosal dissection may increase the rate of iatrogenic colonic perforation [6]. Although those complications are rare, but they can lead to leakage of bowel content into the peritoneal cavity and eventually to sepsis, with significant morbidity (up to 40%) and mortality (up to 25%) [4, 7, 8]. The site of colon perforation must be closed immediately to prevent complications. Traditionally, surgery has been the standard treatment, but nowadays non-invasive methods such as endoscopic clip closure has become popular for closing the site of iatrogenic colon perforation.

The aim of this retrospective study was to assess the sequela of colonic perforation in patients treated at National Cancer Institute.

Materials and methods

A retrospective review of the medical records of all patients, which underwent colonoscopies between January 2007 and December 2016 at the National Cancer Institute, was performed. Data including patient demographics, indications for colonoscopy, diagnostic and therapeutic interventions during the colonoscopy, mechanism of perforation, clinical presentations and physical findings of perforation, time from procedure to diagnosis, diagnostic tool, treatment, clinical outcomes and length of hospital stay, were collected by reviewing medical charts.

Colonoscopy was performed by licensed endoscopists. The diagnosis of perforation was made based on clinical presentation, physical examination and clinical evidence, such as a colonic wall defect found during the colonoscopy, or radiologic evidence, such as detection of free air on simple radiography or computed tomography. The mechanism of perforation was classified as trauma-related or polypectomy-related. The clinical outcomes were evaluated on the basis of the length of antibiotics use, postoperative complications, and length of hospital stay.

The data analysed by SPSS software, version 20.0 (SPSS, Chicago, IL). The chi-square test or Fisher's

exact test was used to analyse the qualitative variables. P-values < 0.05 were considered statistically significant.

Results

Between January 2007 and December 2016, 16 186 colonoscopies were performed at National Cancer Institute. The overall perforation rate was 0.14% (23 of 16 186). Because the absolute numbers of diagnostic and therapeutic procedures were not known, the perforation rates for the type of procedure could not be calculated. Of the total 23 colonic perforations, 20 (86.9%) were managed operatively.

The indications for endoscopy are shown in Table 1. The therapeutic procedures consisted of 9 polypectomies and 1 biopsy. Eleven of the patients were women and nine were men. The median age was 65.6 years (range 31 to 85). Eight patients (40%) had previous abdominal operations.

Table 1. Indications for endoscopy

Indications	Number of patients, n (%)
Polyps	8 (40%)
Follow up of underlying disease	4 (20%)
Rectal bleeding	2 (10%)
Abdominal pain	1 (5%)
Others	5 (25%)

Table 2. Treatment options for patients with iatrogenic colonic perforation

Type of surgery	Number of patients, n (%)
Primary repair	11 (55%)
Colon resection with primary anastomosis	6 (30%)
Colon resection with colostomy	3 (15%)

In eight cases (40%), perforation was noticed by the endoscopist through visualization of extra-intestinal tissue during the procedure. Most others perforations were diagnosed shortly after the procedure because of symptoms and signs of perforation. In the delayed diagnosis cases, the patients presented with abdominal pain (100%) and abdominal distention (45%). Pneumoperitoneum was found on X ray or abdominal computed tomography in seven patients (35%).

After colonic perforation diagnosis, 18 patients underwent immediate surgery, whereas two of the remaining patients initially underwent the Ovesco clipping, but a resection was performed 1 and 2 hours later respectively. 13 patients (65%) underwent surgery on the same day as the endoscopy, five (25%) on the second day and two (10%) more than 2 days after endoscopy. 10 of 11 (90.9%) perforations after diagnostic endoscopy were diagnosed and subjected to surgery the same day. This means that 6 of 7 (85.7%) perforations with a delayed presentation followed a therapeutic procedure. Eleven patients (55%) underwent primary repair of the perforation, six (30%) underwent colon resection with primary anastomosis, and three (15%) underwent colon resection with colostomy (Table 2).

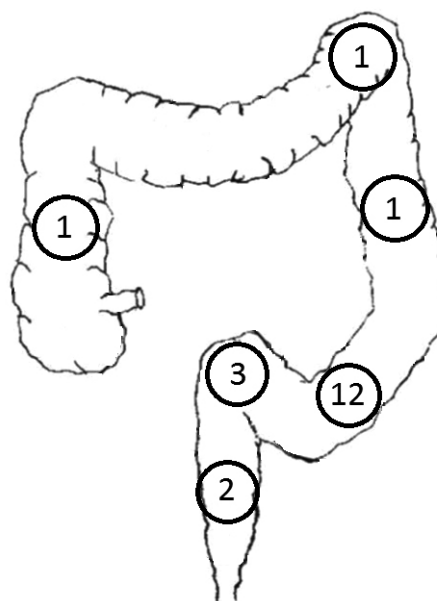


Figure 1. Prevalence of site of colonic perforation in patients undergoing colonoscopy

The sigmoid colon was the most frequent site of perforation (60%), followed by the rectosigmoid junction (15%), rectum (10%) and the descending colon, the ascending colon and the splenic flexure (5% each) (see Figure 1). The perforations throughout the colon were most commonly due to blunt injury in 55% of patients. Perforations from polypectomy and thermal injuries accounted for nine (45%) of 20 injuries, respectively.

Of the 20 patients after surgery, eleven (55%) had no complications and remaining nine patients (45%) developed complications. In total there were 19 complications. Complications classified according to the

Clavien-Dindo classification are presented in Table 3. No significant relationship between time to surgery ($p=0.285$), ASA ($p=0.642$) or patients age ($p=0.964$) and postoperative complication were found. The 30-day hospital mortality rate was of 15%. One death was because of multiple organ failure caused by acute bronchopneumonia and two patients with intra-abdominal sepsis died due cardiopulmonary insufficiency. For all the patients with perforation, the mean hospital stay was 15 days (range, 6–24 days).

Discussion

The involvement of anaesthesia services for colonoscopy sedation has increased accordingly, from 11.0% of colonoscopies in 2001 to more than 50% in 2015 [10–11]. Although the use of anaesthesia can improve colonoscopy outcomes, but it also leads to increased risk of colonic perforation. Wernli et al. determined that use of anaesthesia service was associated with a 13% increase in the risk of any complication within 30 days and was associated specifically with an increased risk of colonic perforation. However researchers observed the increased risk for perforation only among patients with polypectomy [12]. It can be explained by the absence of patient feedback, as a result increased colonic-wall tension from colonoscopy pressure may not be identified by the endoscopist. Consistent with our results at our institution the use of anaesthesia during colonoscopies was introduced in 2014 and it led to increased rate of colonic perforation. 30.4% colonic perforations occurred between 2007 and 2013 inclusive and 69.6% developed from 2014 to 2016.

Table 3. Complications of patients with iatrogenic colonic perforation classified according to the Clavien-Dindo classification [9]

Complication grade	Number of patients, n (%)
No complication	11 (55%)
I	1 (5%)
II	3 (15%)
III	2 (10%)
IIIa	1 (5%)
IIIb	1 (5%)
IV	0 (0%)
IVa	0 (0%)
IVb	0 (0%)
V	3 (15%)

Table 4. Relationship between time to surgery, age, ASA and postoperative complications

		Postoperative complications		p-value
		Yes	No	
Time to surgery	< 24 hours	6 (37.5%)	11 (62.5%)	0.285
	> 24 hours	3 (75.0%)	1 (25.0%)	
Age	< 65 years	4(44.4%)	5 (55.6%)	0.642
	≥ 65 hours	5 (45.5%)	6 (54.5%)	
ASA	ASA 1-2	5(38.5%)	8 (61.5%)	0.964
	ASA 3-4	4 (57.1%)	3 (42.9%)	

Most studies highlight the importance of early operative intervention for patients with suspected iatrogenic colonic perforation [13–15]. The type of procedure used will depend on the size of perforation, the time to diagnosis, the type of injury, the degree of faecal contamination, the presence of associated colon pathology, the patient status, the concomitant disease and the surgeon's experience [16, 17]. Primary repair of the colon is recommended for patients with perforations, which are <50% of bowel circumference, without significant faecal contamination and with no serious comorbidities. Resection with primary anastomosis should be attempted if the perforation site is large or concomitant pathology is present [17]. Resection and ileostomy or colostomy are used in patients with extensive faecal contamination, operative delay and multiple comorbidities [18]. The resultant inflammatory changes associated with feculent peritonitis clearly limit the operative options, precluding a single-stage procedure and resulting in faecal diversion in 38% of patients [7].

Perforations during diagnostic colonoscopy usually occur in the sigmoid or rectosigmoid junction due to the difficulty of traversing this convoluted segment of bowel due its anatomical characteristics of frequent redundancy or narrowing from diverticular disease or adhesions after previous pelvic operations [19]. Mechanical injuries tend to be generally large (>2 cm), more severe, causing greater contamination of the peritoneal cavity and more frequently lead to a faecal diversion [7]. Conversely, perforations due to therapeutic procedures tend to occur in the thinner walled area of the proximal colon. These perforations tend to be small and causing minimal faecal contamination. An experimental study on polypectomy in pigs found that the use of tungsten instead of steel snares was significantly associated with a lower depth of tissue injury, suggesting a potential effect on reducing the risk of perforation [20]. The improvement of laparoscopic techniques boosts the practice of laparoscopic repair for colonic perforations more widely [21]. Zhang et al. reported that laparoscopic primary perforation repair is a safe and feasible repair method [22]. Compared to the laparotomy, patients who underwent laparoscopic

repair had fewer perioperative complications [23]. These studies suggest laparoscopy as the initial approach for repairing iatrogenic colorectal perforation.

In our study 80% of perforations were diagnosed during the procedure or in the first 24 hours. According to the literature this rate seeks 65.1–78% [17]. All of these patients were admitted to our hospital already with peritonitis, that increases the need for surgery and probably incurs a worse prognosis. One of the reasons for delayed diagnosis of perforation may be related to the growing rate of therapeutic colonoscopies, because these perforations are usually smaller therefore it is more difficult to detect them [17]. Moreover, the patients could initially have gone to primary care units before being referenced to the tertiary hospital, postponing its diagnosis and approach.

In our study the postoperative morbidity and mortality rates were 45% and 15% respectively. Large series of colonoscopy induced perforations managed surgically reported a morbidity rate of 35% [4, 7]. The mortality rate in our study is fairly comparable to other reports which is up to 25% [7, 8]. Surgical site infection is the most common complication, while cardiopulmonary complications and multiple organ failure are the leading causes of death [7, 24]. Iqbal et al. noted that patients presenting after 24 hours have morbidity nearly twice as frequently as patients who present within 24 hours [7]. Our study demonstrated the same results, but we didn't find statistical significant relationship between time to surgery and postoperative complications. Several other factors are also known to influence outcome, namely, advanced age of patients, severe comorbidities, a large perforation site, poor bowel preparation, corticosteroid use, anticoagulant or antiplatelet therapy [7, 8, 25].

Conclusions

If surgery and its associated morbidity can be avoided in cases of colonic perforation the negative impact of a colonoscopy-associated complication can be minimized considerably. Patients need to be informed of the complications of colonoscopy, and clinicians must be cautioned about the potential problems for patients with a high-anaesthetic risk when performing the procedure.

REFERENCES

1. Paspatis GA, Dumonceau J-M, Barthet M, Meisner S, Repici A, Saunders BP, et al. Diagnosis and management of iatrogenic endoscopic perforations: European Society of Gastrointestinal Endoscopy (ESGE) Position Statement. *Endoscopy*. 2014; 46: 693–711.
2. Kavic SM, Basson MD. Complications of endoscopy. *Am J Surg*. 2001; 181: 319–32.
3. Wullstein C, Koppen M, Gross E. Laparoscopic treatment of colonic perforations related to colonoscopy. *Surg Endosc*. 1999; 13: 484–7.
4. Luning TH, Keemers-Gels ME, Barendregt WB, Tan AC, Rosman C. Colonoscopic perforations: a review of 30,366 patients. *Surg Endosc*. 2007; 21: 994–7.
5. Castellvi J, Pi F, Sueiras A, Vallet J et al. Colonoscopic perforation: useful parameters for early diagnosis and conservative treatment. *Int J Colorectal Dis*. 2011; 26: 1183–1190.
6. Panteris V, Haringsma J, Kuipers EJ. Colonoscopy perforation rate, mechanisms and outcome: from diagnostic to therapeutic colonoscopy. *Endoscopy*. 2009; 41: 941–951.
7. Iqbal CW, Cullinane DC, Schiller HJ, Sawyer MD, Zietlow SP, Farley DR. Surgical management and outcomes of 165 colonoscopic perforations from a single institution. *Arch Surg*. 2008; 143: 701–6.
8. Teoh AY, Poon CM, Lee JF, Leong HT, Ng SS, Sung JJ, Lau JY. Outcomes and predictors of mortality and stoma formation in surgical management of colonoscopic perforations: a multicenter review. *Arch Surg*. 2009; 144: 9–13.
9. Dindo D, Demartines N, Clavien PA. Classification of Surgical Complications: A New Proposal With Evaluation in a Cohort of 6336 Patients and Results of a Survey. *Annals of Surgery*. 2004; 240: 205–13.
10. Khiani VS, Soulos P, Gancayco J, et al. Anesthesiologist involvement in screening colonoscopy: temporal trends and cost implications in the Medicare population. *Clin Gastroenterol Hepatol*. 2012; 10: 58–64.
11. Inadomi JM, Gunnarsson CL, Rizzo JA, et al. Projected increased growth rate of anesthesia professional-delivered sedation for colonoscopy and EGD in the United States: 2009 to 2015. *Gastrointest Endosc*. 2010; 72: 580–6.
12. Wernli KJ, Brenner AT, Rutter CM, Inadomi JM. Risks associated with anesthesia services during colonoscopy. *Gastroenterology*. 2016; 150: 888–94.
13. Farley DR, Bannon MP, Zietlow SP, Pemberton JH, Ilstrup DM, Larson DR. Management of colonoscopic perforations. *Mayo Clin Proc*. 1997; 72: 729–33.
14. Clements RH, Jordan LM, Webb WA. Critical decisions in the management of endoscopic perforations of the colon. *Am Surg*. 2000; 66: 91–3.
15. Dafnis G, Ekblom A, Pahlman L, Blomqvist P. Complications of diagnostic and therapeutic colonoscopy within a defined population in Sweden. *Gastrointest Endosc*. 2001; 54: 302–9.
16. Mai CM, Wen CC, Wen SH, Hsu KF, Wu CC, Jao SW, et al. Iatrogenic colonic perforation by colonoscopy: a fatal complication for patients with a high anesthetic risk. *Int J Colorectal Dis*. 2010; 25: 449–54.
17. Lohsiriwat V. Colonoscopic perforation: Incidence, risk factors, management and outcome. *World Journal of Gastroenterology*. 2010; 16: 425–30.
18. Lin I, Wang J, King T. Incidence and management of iatrogenic colonoscopic perforations. *J Soc Colon Rectal Surgeon*. 2010; 21: 53–8.
19. Damore LJ, Rantis PC, Vernava AM, Longo WE. Colonoscopic perforations. Etiology, diagnosis, and management. *Dis Colon Rectum*. 1996; 39: 1308–14.
20. Galloro G, Magno L, Ruggiero S et al. Comparison between tungsten and steel polypectomy snares: evaluation of depth of colonic thermal wall injury in a pig model. *Endoscopy*. 2013; 45: 121–6.
21. Coimbra C, Bouffieux L, Kohnen L, Deroover A, Dresse D, Denoël A, Honoré P, Detry O. Laparoscopic repair of colonoscopic perforation: a new standard? *Surg Endosc*. 2011; 25: 1514–7.
22. Zhang YQ, Lu W, Yao LQ, Qin XY, Xu MD, Zhong YS, Li QL, Wu HF, Zhou PH. Laparoscopic direct suture of perforation after diagnostic colonoscopy. *Int J Colorectal Dis*. 2013; 28: 1505–9.
23. Bleier JI, Moon V, Feingold D, Whelan RL, Arnell T, Sonoda T, Milsom JW, Lee SW. Initial repair of iatrogenic colon perforation using laparoscopic methods. *Surg Endosc*. 2008; 22: 646–9.
24. Lohsiriwat V, Sujaritnanakarn S, Akaraviputh T, Lertakymanee N, Lohsiriwat D, Kachinthorn U. Colonoscopic perforation: A report from World Gastroenterology Organization endoscopy training center in Thailand. *World J Gastroenterol*. 2008; 14: 6722–6725.
25. Iqbal CW, Chun YS, Farley DR. Colonoscopic perforations: a retrospective review. *J Gastrointest Surg*. 2005; 9: 1229–35.