

ISSN 1392-0995, ISSN 1648-9942 (online)

<http://www.chirurgija.lt>  
LIETUVOS CHIRURGIJA  
*Lithuanian Surgery*  
2016, 15 (2-3), p. 121-125

# Giant breast malignant phyllodes tumor: a case report and literature review

## Gigantinis piktybinis filoidinis krūties navikas: klinikinio atvejo aprašymas ir literatūros apžvalga

Valerijus Ostapenko<sup>1</sup>, Andrejus Ostapenko<sup>1</sup>, Darius Dasevičius<sup>2</sup>, Edvinas Ostapenko<sup>3</sup>

<sup>1</sup> *National Cancer Institute, Santariskiu Str. 1, LT-08660 Vilnius, Lithuania*

<sup>2</sup> *National Pathology Center, Vilnius University Hospital Santariskiu Klinikos, Santariskiu Str. 2, Vilnius, Lithuania*

<sup>3</sup> *Faculty of Medicine, Vilnius University, M. K. Čiurlionio Str. 21, LT-03101 Vilnius, Lithuania*  
*E-mail: v.ostapenko@takas.lt*

<sup>1</sup> *Nacionalinis vėžio institutas, Santariskių g. 1, LT-08660 Vilnius, Lietuva*

<sup>2</sup> *Valstybinis patologijos centras, Vilniaus universiteto ligoninė Santariskių klinikos, Santariskių g. 1, Vilnius, Lietuva*

<sup>3</sup> *Vilniaus universiteto Medicinos fakultetas, M. K. Čiurlionio g. 21, LT-03101 Vilnius, Lietuva*  
*El. paštas: v.ostapenko@takas.lt*

---

### Introduction

Phyllodes tumors of the breast are rare and account for less than 1% of breast tumors. They occur over a wide age range with a median age of 45 years. Malignant transformation of a phyllodes tumor is a rare form of breast cancer accounting for just 0.5% of all breast cancers. A simple mastectomy is performed for giant phyllodes tumors (>10 cm), those that are multifocal, in cases of malignant phyllodes tumors, in cases of recurrence or in phyllodes of 'borderline' histology

### Case report

We report a rare case of a rapidly growing malignant giant phyllodes tumor of the young, 26 year-old white woman, who underwent successful combined treatment nipple-sparing mastectomy and irradiation in National Cancer Institute, Vilnius, Lithuania

### Conclusions

Multidisciplinary approach and modern imaging studies allows us to diagnose and successfully treat this rare pathological state. Scientific trials to delineate proper indications for combined treatment malignant phyllodes tumor of the young patients are needed.

**Key words:** malignant breast phyllodes tumors, combined treatment, nipple-sparing mastectomy

---

### Įvadas

Krūties filoidiniai navikai yra reta patologinė būklė, sudaranti mažiau negu 1 % krūties navikų. Filoidiniai navikai pasitaiko įvairaus amžiaus moterims, amžiaus vidurkis yra 45 metai. Filoidinių navikų malignizacija pasitaiko retai ir sudaro 0,5 % visų krūties navikų. Paprastoji mastektomija rekomenduojama esant gigantiniams filoidiniams navikams (>10 cm), navikų daugiažidiniškumui, ligos atsinaujinimui ir histologiškai patvirtintam paribiniam filoidiniam navikui.

### Klinikinis atvejis

Aprašome retą piktybinio filoidinio naviko atvejį 26 metų moteriai, kuri sėkmingai gydyta Nacionaliniame vėžio institute Vilniuje, derinant spenelį tausojančią mastektomiją ir aktinoterapiją.

### Išvados

Daugiadalykis atvejo aptarimas ir modernūs tyrimo metodai leidžia diagnozuoti ir sėkmingai gydyti šią retą patologiją. Reikalingi tolesni piktybiniais filoidiniais navikais sergančių jaunų pacienčių moksliniai tyrimai, naujos sudėtinio gydymo indikacijos ir gydymo standartai.

**Reikšminiai žodžiai:** piktybiniai filoidiniai krūties navikai, sudėtinis gydymas, spenelį tausojanti mastektomija

### Introduction

In 1838, Müller applied the term cystosarcoma phyllodes and described the leaf-like projection of the stroma into cystic spaces. The scientists used term sarcoma due to the sarcoma-like macroscopic findings of this tumor rather than to indicate its malignant potential [1]. Phyllodes tumors of the breast constitute fibroepithelial neoplasms that have a morphological resemblance to the intracanalicular fibroadenoma at the benign end of the spectrum, but with increased stromal cellularity and leaf-like architecture [2]. In 1931, Lee and Pack reported the first case of metastatic phyllodes tumor. [3]. In 1981, World Health Organization (WHO) presented classification of tumors of the breast, introduced the term phyllodes tumors (PT), criteria for diagnosis and grading of PT. According WHO PT classifies into benign, borderline and malignant grade categories based on a followings histological parameters: the degree of stromal cellularity and atypia, mitotic count, stromal overgrowth, and the nature of their tumor borders. [4]. A malignant PT shows marked stromal cellularity and atypia, has permeated margins, and has mitotic activity of at least 10/10 HPFs [2]. The size of the tumor in relation to the breast appears important as this usually determines the extent of surgery and the resulting specimen resection margins. Breast-conserving surgery not recommended in large multifocal PT because of the risk of inadequate local excision and associated high local recurrence [5].

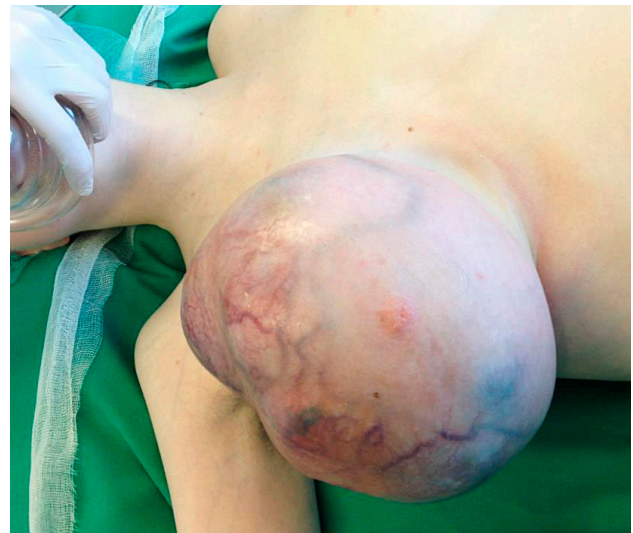### Case presentation

A 26-year-old white woman complained of a rapidly growing mass in her right breast over a period of 12 months. The patient noticed as a small painless lump in the upper-outer quadrant of her breast. In last

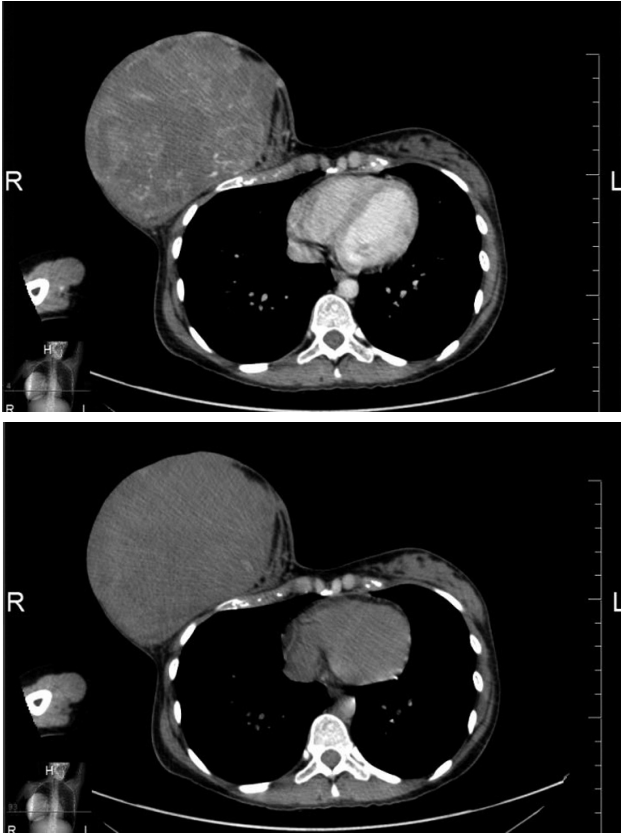6 months tumor rapidly increased in size, breast became swollen, inflamed. She had no family history of breast or ovarian cancer.

Her right breast was extremely large and heavy. On physical examination, she had a large mass measuring 19 cm × 18 cm involving the entire left breast with two areas of skin deepithelization measuring 11 mm × 8 mm and 7 mm × 4 mm (Figure 1). The whole breast moved freely over the muscle pectoralis major and there were no palpable axillary or supraclavicular lymph nodes. Her left breast was normal on palpation.

Breast ultrasound examination revealed a large heterogeneous solid mass with internal vascularity replacing left breast tissue. The size was difficult to define on ultrasonography due to its large size. Breast tumor was without signs of invasion to the chest wall and to the axillary, supraclavicular and infraclavicular lymph nodes. Ultrasound of the abdomen without pathology. Due to the large size of the tumor, we did not perform mammography.



**Figure 1.** Pre-operative view of the tumor



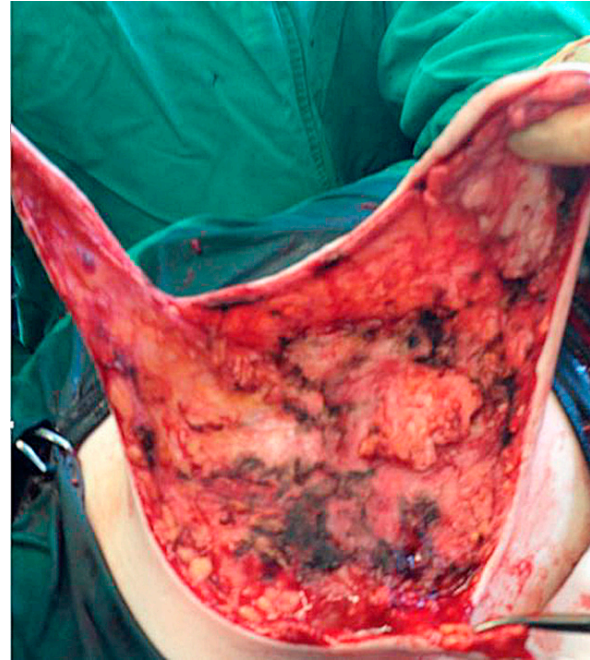
**Figure 2.** Chest CT scan

Chest and abdominal CT scan with ultravist 300 examination: right breast dimensions 174 mm × 123 mm × 166 mm round shape, well-defined margins, heterogeneous internal structure, consisting of lobules with blood perfusion and cavities of tissue destruction. Tumor without signs of invasion to the chest wall and axillary, supraclavicular and infraclavicular lymph nodes. Chest and abdomen CT scan – without pathology (Figure 2). Differentiate with tumor phyllodes and angiosarcoma.

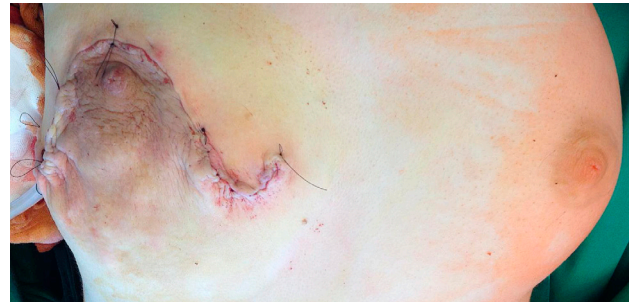We performed fine needle aspiration of the tumor and evacuated 75 ml of yellow fluid, small amount of lymphocytes on cytological examination.

Multidisciplinary team decision: nipple-sparing mastectomy (in case of free margins) with adjuvant radiotherapy

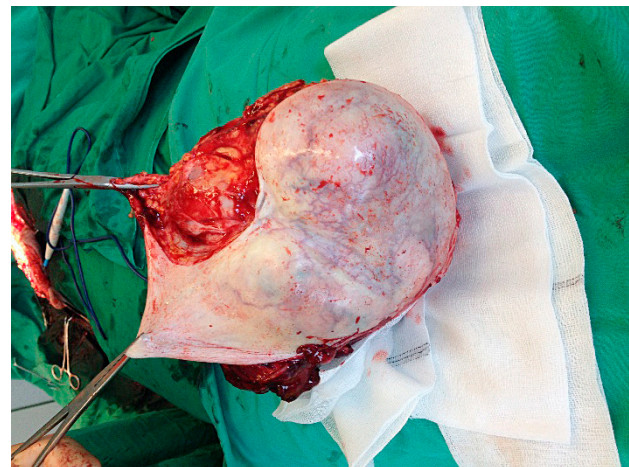
Surgical treatment. Patient underwent nipple-sparing mastectomy, removing breast with tumor with 1–2 cm circle margin of normal- appearing breast tissues (Fig. 3 and 4). Urgent retroareolar and margins pathologic (frozen section) examination did not revealed tumor.



**Figure 3.** Nipple-sparing mastectomy: dissection



**Figure 4.** Nipple-sparing mastectomy after completion



**Figure 5.** Macroscopic view of removed tumor

Post-operative period was without complication. Fig. 5 illustrates macroscopic view of removed tumor.

Final pathological examination – malignant phylloides tumor (18 cm). 54 Gy were realized in 27 fractions of post-operative radiotherapy

## Discussion

PT is rare breast neoplasm constituting from 0.3% to 0.9% of all breast tumors. According to Bernstein, the incidence of PT is 2.1 per one million people and usually PTs are benign. They occur over a wide age range with a median age of 45 years [7, 8]. The World Health Organization classified PTs into three subtypes: benign, borderline and malignant, according to the degree of stromal cell atypia, stromal overgrowth, the status of mitosis and the tumor margin [9]. The median size of PT is around 4 cm. Twenty percent of PT grows larger than 10 cm [10]. According to McDaniel and Crichlow, no more than 700 cases had been reported with tumor when they published their article in 1986 [7, 8] (Table).

Surgery is the standard initial treatment option for malignant PT. Tumor size is an important factor in predicting effect of local treatment [11]. The main options of local PT treatment are breast preserving operation with excision of normal breast tissue around the tumor (to obtain of at least a 1 cm margin

of normal-appearing breast tissue), and mastectomy [12]. Wide excision with a clear surgical margin is the preferred therapy for PT. A clear surgical margin is the only proven protective factor [13]. Contraindications for breast-conserving surgery include large tumors, multifocality, and malignancy because of their greater risk of recurrence [14]. Mastectomy for or malignant PT recommended in cases of giant tumors, if free margin cannot be achieved, or in cases of local tumor recurrence [15]. Nipple-sparing mastectomy for surgical management of giant malignant PT is rarely performed. Histological type is the most important predictor for metastatic spread, although it may not correlate with clinical behavior because both malignant and borderline tumors are capable of metastasizing. Stromal overgrowth, occurring in 29% of cases, was the only predictor of distant failure in multivariate analysis. With malignant tumors, 22% may give rise to haematogenous metastasis [14]. The risk of local recurrence increases in incompletely excised lesions. [10]. Using pooled cancer registry data, Vorherr et al estimated an overall five year survival rate of 80% for malignant PT [11]. The five-year survival for benign, borderline or malignant tumors is of 95.7% for benign tumors, 73.7% for borderline tumors, and 66.1% for malignant tumors [10]. Since the PT spread through

**Table.** Patient age, tumor diameter, histological types from all studies of PT with greater than 20 patients published 1975–1986

Study	City	No	Duration	Age (years; range)	Diameter (cm; range)	No (%) of histological type		
						Benign	Borderline	Malignant
Bennett <i>et al</i> <sup>60</sup>	Brisbane	30	1970–88	49 (20–75)	3.5 (1–30)	14 (47)	5 (17)	11 (37)
Chua <i>et al</i> <sup>7</sup>	Singapore	106	1978–86	30 (13–61)	NA	97 (92)	6 (6)	3 (2)
Ciatto <i>et al</i> <sup>10</sup>	Florence	59	1977–91	NA	NA	22 (37)	12 (20)	25 (42)
Cohn-Cedermark <i>et al</i> <sup>19</sup>	Stockholm	77	1958–86	50 (18–85)	NA	42 (55)	NC	35 (45)
Contarini <i>et al</i> <sup>28</sup>	Jacksonville	40	1963–80	41 (12–85)	6.1 (1–20)	23 (58)	NC	17 (42)
de Roos <i>et al</i> <sup>70</sup>	Cape Town	38	1975–96	44 (17–65)	8.0 (2–30)	15 (39)	11 (29)	12 (32)
Hines <i>et al</i> <sup>73</sup>	Chicago	25	1959–81	50 (16–82)	7.2 (2–15)	15 (60)	NC	10 (40)
Holthouse <i>et al</i> <sup>68</sup>	Perth	26	1983–94	46 (21–82)	NA	19 (73)	4 (15)	3 (12)
Iau <i>et al</i> <sup>11</sup>	Singapore	40	1985–95	38 (15–58)	5.2 (1–22)	33 (83)	2 (5)	5 (12)
Mangi <i>et al</i> <sup>28</sup>	Boston	40	1980–97	41 (17–74)	NA (5–28)	34 (84)	3 (8)	3 (8)
Moffat <i>et al</i> <sup>25</sup>	Nottingham	32	1975–90	52 (23–93)	5.9 (1–19)	23 (71)	4 (13)	5 (16)
Mokbel <i>et al</i> <sup>98</sup>	London	30	1978–98	49 (19–80)	4.6 (2–10)	21 (70)	2 (7)	7 (23)
Pietruszka and Barnes <sup>56</sup>	Pittsburgh	42	1945–77	44 (14–67)	5.0 (1–41)	18 (43)	5 (12)	19 (45)
Reinfuss <i>et al</i> <sup>22</sup>	Krakow	170	1952–88	52 (19–76)	7.0 (2–40)	92 (54)	19 (11)	59 (34)
Salvadori <i>et al</i> <sup>24</sup>	Milan	81	1974–83	44 (9–88)	NA	28 (34)	32 (40)	21 (26)
Stebbing and Nash <sup>8</sup>	London	33	1981–92	41 (15–67)	3.7 (1–18)	24 (73)	6 (18)	3 (9)
Zurrida <i>et al</i> <sup>73</sup>	Milan	216	1970–89	NA	NA	140 (64)	46 (21)	30 (14)

NA = data not published; NC = no borderline category.

Series that specifically studied only adolescent patients, benign or malignant tumours have been excluded.

the bloodstream, the lymph node metastases rates are very low (<5%). Thus, axillary dissection is unnecessary during the initial surgical intervention [10, 11, 12]. Radiotherapy is recommended for individuals with a high local recurrence risk. Chemotherapy is used to treat patients with a high systemic metastatic risk. The real role of adjuvant irradiation and chemotherapy is undefined and should be tested in prospective, randomized trials [10, 11, 12, 15, 16].

Our patient 11 months after operation is healthy and without signs of local progression or dissemination. According to data, presented in our article, nipple-sparing mastectomy and irradiation provide an optimal solution of wide local tumor control and cosmesis. In agreement with patient, breast reconstruction will be done one year

after surgery, if there will be no signs of local progression or dissemination.

## Conclusions

Complains on rapidly growing tumor of the breast, may be one of the earliest signs of malignant PT in young women. It is extremely important early perform standard clinical exam with full radiologic examination and core biopsy. Nipple-sparing mastectomy is rare in surgical management of giant malignant PT, but it provides an optimal solution of wide local tumor control and cosmesis. The adjuvant radiotherapy was administered in our case, but the real role of adjuvant irradiation and chemotherapy is undefined and should be tested in prospective, randomized trials.

## REFERENCES

- Müller J. *Über den feineren Bau und Die Formen der Krankhaften Geschwulste*. Berlin: G Reiner, 1838; 1: 54–57.
- Fiks A. Cystosarcoma phyllodes of the mammary gland – Muller's tumor. *Virchows Arch* 1981; 392: 1–6.
- Tan BY, Acs G, Apple SK, Badve S, Bleiweiss IJ, Brogi E et al. Phyllodes tumours of the breast: a consensus review. *Histopathology* 2016; 68(1): 5–21.
- Parker SJ, Harries SA. Phylloides tumours. *Postgrad Med J* 2001; 77: 428–435.
- Dyer NH, Bridger JE, Taylor RS. Cystosarcoma phyllodes. *Br J Surg* 1966; 53: 450–455.
- Lee BJ, Pack GT. Giant intracanalicular fibroadenomyxoma. *Am J Cancer* 1931; 15: 2.
- Bernstein L, Deapen D, Ross RK. The descriptive epidemiology of malignant cystosarcoma phyllodes tumors of the breast. *Cancer* 1993; 71: 3020–3024.
- Salvadori B, Cusumano F, Del Bo, R et al. Surgical treatment of phyllodes tumours of the breast. *Cancer* 1989; 63: 2532.
- Lakhani SR, Ellis IO, Schnitt SJ, Tan PH, van de Vijver MJ (eds). *WHO classification of tumours of the breast*. In: IARC WHO Classification of Tumours. Vol 4. Fourth edition. IARC Press, Lyon, 2012.
- Reinfuss M, Mitus J, Duda K, Stelmach A, Rys J, Smolak K. The treatment and prognosis of patients with phyllodes tumor of the breast: an analysis of 170 cases. *Cancer* 1996; 77: 910–916.
- Vorherr H, Vorherr UF, Kutvirt DM, Key CR. Cystosarcoma phyllodes: epidemiology, pathohistology, pathobiology, diagnosis, therapy, and survival. *Arch Gynecol* 1985; 236(3): 173–181.
- Sbeih MA, Engdahl R, Landa M, Ojutiku O, Morrison N, Depaz H. A giant phyllodes tumor causing ulceration and severe breast disfigurement: case report and review of giant phyllodes. *J Surg Case Rep* 2015; 12: 15–18.
- De Roos WK, Kaye P, Dent DM. Factors leading to local recurrence or death after surgical resection of phyllodes tumours of the breast. *Br J Surg* 1999; 86: 396–399.
- White DS, Irvine JE. Rapidly progressive multifocal phyllodes tumour of the breast: a case report and review of the literature. *Int J Surg Case Rep* 2013; 4(10): 901–903.
- Weledji EP, Enow-Orock G, Ngowe MN, Aminde L. Breast-conserving surgery is contraindicated for recurrent giant multifocal phyllodes tumours of breast. *World J Surg Oncol* 2014; 12: 213.
- Liang M, Ramaswamy B, Patterson CC, McKelvey MT, Gordillo G, Nuovo GJ, Carson WE. Giant breast tumors: Surgical management of phyllodes tumors, potential for reconstructive surgery and a review of literature. *World J Surg Oncol* 2008; 6: 117–125.