

ISSN 1392-0995, ISSN 1648-9942 (online)  
<http://www.chirurgija.lt>  
LIETUVOS CHIRURGIJA  
*Lithuanian Surgery*  
2015, 14 (3), p. 172-175

# Single-incision laparoscopic surgery for right hemicolectomy: two case reports

## Dešinėsios hemikolektomijos vieno pjūvio laparoskopinė operacija: dviejų atvejų aprašymas

Marius Kryžauskas<sup>1,2</sup>, Saulius Mikalauskas<sup>1,2</sup>, Mantas Drungilas<sup>1</sup>, Tomas Poškus<sup>1</sup>, Valdemaras Jotautas<sup>1</sup>, Eligijus Poškus<sup>1</sup>, Virgilijus Beiša<sup>1</sup>, Kęstutis Strupas<sup>1</sup>

<sup>1</sup> *Vilnius University Hospital "Santariškių klinikos", Santariškių Str. 2, LT-08661 Vilnius, Lithuania*

<sup>2</sup> *Equal contribution*

*E-mail: saulius.mikalauskas@santa.lt*

<sup>1</sup> *Vilniaus universiteto ligoninė "Santariškių klinikos", Santariškių g. 2, LT-08661 Vilnius*

<sup>2</sup> *Tolygus įnašas*

*El. paštas: saulius.mikalauskas@santa.lt*

---

Single incision procedures are evolving as part of minimally invasive surgery. In 2008, the SILS approach was first described for a right hemicolectomy. We report and describe the first two transumbilical single incision laparoscopic right hemicolectomies for benign disease, which were performed in Lithuania Vilnius University Hospital Santariskiu Klinikos.

**Key words:** SILS, right hemicolectomy

---

Vieno pjūvio chirurginės procedūros vystosi kaip minimaliai invazinės chirurgijos dalis. Dešinioji hemikolektomija, atlikta SILS būdu, pirmą kartą aprašyta 2008 metais. Mes aprašome pirmąsias dvi laparoskopines transumbilikalines vieno pjūvio dešiniąsias hemikolektomijas, atliktas Vilniaus universiteto ligoninėje Santariškių klinikos.

**Reikšminiai žodžiai:** SILS, dešinė hemikolektomija

---

### Introduction

Single incision procedures are evolving as part of minimally invasive surgery. The cosmetic advantage, less post-operative pain are proved by a randomized study while comparing single incision laparoscopic surgery (SILS) with conventional laparoscopic surgery (CLS) [1]. In 2008, the SILS approach was first described for a right

hemicolectomy [2, 3]. For colorectal procedures, the benefits from SILS may include faster post-operative recovery, less frequent usage of narcotics, and a shorter hospital stay as compared with CLS [4-6]. Oncological efficiency for applying SILS may not differ from CLS for the treatment of colorectal malignancy. However, a longer follow-up is needed to evaluate recurrence and overall survival rates [7].

We report the first two transumbilical single incision laparoscopic right hemicolectomies for benign disease using conventional straight and articulated laparoscopic instruments, which were performed in Lithuania Vilnius University Hospital Santariskiu Klinikos.

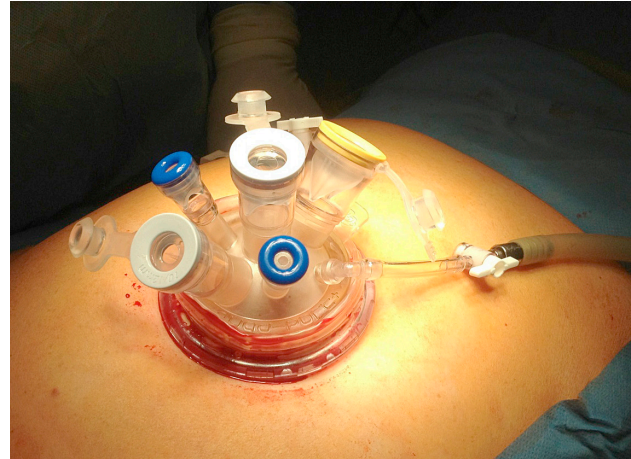
### Surgical technique

Under the general anesthesia the patient is placed in supine position and the bed is tilted toward the left and in a mild Trendelenburg's position. In the beginning, the surgeon stands on the left side and the assistance (camera holder) stands on the right side of the patient.

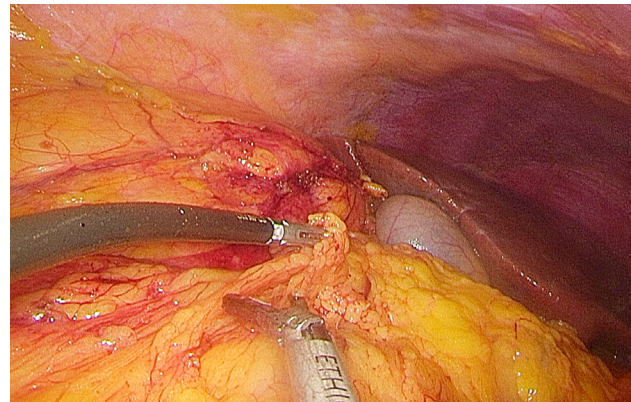
A small incision is made through the umbilicus, and the pneumoperitoneum of 12 mmHg is established using a Veress needle. A 10-mm port is inserted, and the abdominal cavity is explored to evaluate if the case is appropriate for the SILS procedure. The aponeurosis is enlarged up to 3 cm, and a single-port device is introduced.

For the first case, we used TriPort® (Olympus, Europe Holding GmbH, Hamburg, Germany) and for the second one we used QuadPort® (Olympus, Europe Holding GmbH, Hamburg, Germany) (Figure A). We performed operations using usual straight laparoscopic instruments combined with curved instruments.

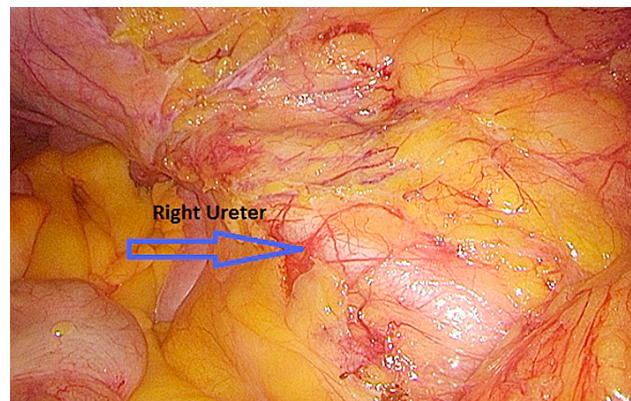
Dissection was performed using ultrasonic dissection (Ultracision ACE™, Ethicon Endo-Surgery, Cincinnati, OH, USA) from the lateral to medial side (the right colon flexure was released from adhesions and mobilized (Figure B), as well as the transverse colon was mobilized up to the middle colic artery). Also, the cecum and terminal ileum were mobilized identifying the right ureter (Figure C). High ligation of the ileocolic and right colic vessels was performed intracorporally. The right colon with the terminal ileum was grasped while the port device was removed and the bowel was extraperitonised (Figure D). Bowel resection and ileotransversostomy with the end-to-side anastomosis was performed extracorporeally using a running PDS 3/0 suture. The bowel with anastomosis and port device was reinserted into the abdominal cavity. The pneumoperitoneum was restored, the abdominal cavity was explored for the possible bleeding. Finally, the port device was removed, and an aponeurosis was closed with absorbable sutures; skin was closed with nonabsorbable



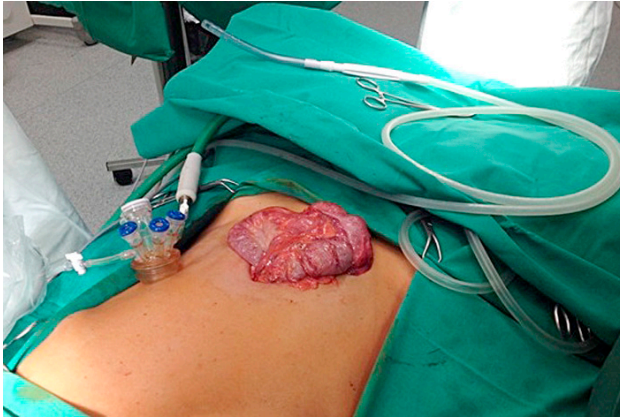**Figure A.** QuadPort® (Olympus, Europe Holding GmbH, Hamburg, Germany)



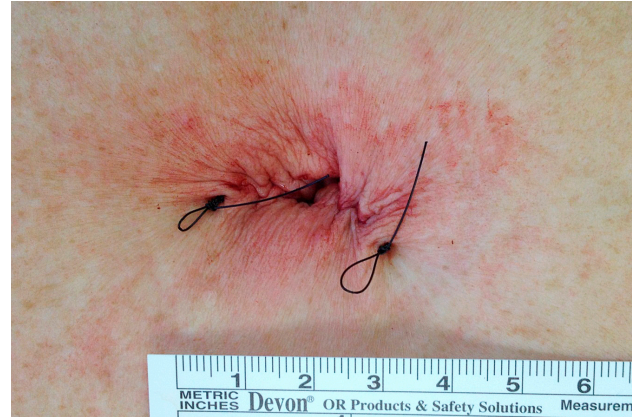**Figure B.** Mobilization of the right colon flexure



**Figure C.** Identification of the right ureter



**Figure D.** Extraperitonised bowel segment



**Figure E.** The wound after the operation

intracutaneous suture (Figure E). No drains were left intra-abdominally.

### Case report I

A 61-year-old female patient (BMI 19 kg/m<sup>2</sup>) made a fecal occult blood test due to the colorectal cancer screening program. After a positive test result, the patient was sent to colonoscopy procedure. The tumor of the ileocecal valve was identified, which was not possible to remove endoscopically. Biopsy specimens obtained from the region were diagnosed as a giant adenoma of *valvula Bauhini*. The SILS procedure was suggested, and the patient gave her informed consent for this surgical approach. The transumbilical SILS right hemicolectomy was undertaken successfully (the operative technique is described above). The total operative time was 115 min. No intra-operative or postoperative complications were recorded. Bowel movement recovered on day one. The fluid diet was started on the second postoperative day, while the normal low-residue diet was started on the third one. The patient was discharged on day 4 postoperatively. Macroscopically, the surgical specimen was 30 cm long (20 cm of the ascending colon with appendix veriformis and 10 cm of the ileum) with the 6×2.5 cm tumor of the Bauhini valve. Microscopically, the specimen of the ileocecal valve tumor was intramucosal adenocarcinoma in tubulovillious adenoma, pTIS N0. There were 12 harvested lymph nodes and no positive lymph nodes. Colonoscopy was performed after 1 year, and no recurrence was found.

### Case report II

A 65-year-old female patient (BMI 27.9 kg/m<sup>2</sup>) had 2 polypectomies of histologically confirmed tubulovillious adenoma in the cecum region. During the last colonoscopy, the recurrent flat polyp was identified. Due to its size (3 cm), flatness, laterally spread and submucosal fibrosis (resulting by previous polypectomies), the endoscopic removal was impossible. The SILS procedure was chosen, and the transumbilical SILS right hemicolectomy was performed successfully. The total operative time was 95 min. No intra-operative or postoperative complications were recorded. The postoperative period was identical to the case mentioned above. The patient was discharged on day 4 postoperatively. Macroscopically, the tumor was 3.5×2.7×0.4 of the cecum. Histologically, the specimen of the cecum tumor was a flat tubulovillious adenoma.

### Discussion

The first reports on colorectal resections through a transumbilical single-port access site were published in 2008 [2, 3] as a radical right hemicolectomy for a polyp with extracorporeal ileocolic anastomosis. We reported our two first cases of this approach – the first one for malignant tumor and the second one for a benign disease – tubulovillious adenoma.

The major disadvantage of this technique is the difficulty to expose the operative field and to be ergonomically favorable for the surgeon without instruments



“crowding” [8, 9]. To reduce the risk of “triangulation”, specifically designed instruments such as graspers with varying curvatures have been developed to facilitate the surgical dissection. To overcome these difficulties, it has been suggested that instruments of varying lengths be used to allow manipulation in different planes so as to minimize external collisions [8]. Due to that, advanced laparoscopic skills are needed before performing SILS. Moreover, experience with transanal endoscopic microsurgery (TEM) could improve the learning curve of SILS since it also involves working in a confined space with a risk of instrument “crowding” [10].

Knowing these problems, we performed SILS operations with standard straight laparoscopic instruments combined with curved graspers by proficient laparoscopic surgeons. With these instruments, we can obtain a good exposure, clear dissection plane, and good tractions and contra-tractions reproducing almost completely the technique used during equivalent traditional laparoscopic procedures. Moreover, using the single-incision approach, it is always possible to add two or more trocars to complete the dissection and using the incision-single incision to extract the specimen and to complete the anastomosis converting the SILS in a “traditional” laparoscopic procedure [11].

## REFERENCES

1. Bucher P, Pugin F, Buchs NC, Ostermann S, Morel P. Randomized clinical trial of laparoendoscopic single-site *versus* conventional laparoscopic cholecystectomy. *Br J Surg* 2011; 98: 1695–702.
2. Remzi FH, Kirat HT, Kaouk JH, Geisler DP. Single-port laparoscopy in colorectal surgery. *Colorectal Dis* 2008; 10: 823–26.
3. Bucher P, Pugin F, Morel P. Single port access laparoscopic right hemicolectomy. *Int J Colorectal Dis* 2008; 23: 1013–6.
4. Kim SJ, Ryu GO, Choi BJ, Kim JG, Lee KJ, Lee SC, Oh ST. The short-term outcomes of conventional and single-port laparoscopic surgery for colorectal cancer. *Ann Surg* 2011; 254: 933–40.
5. Papaconstantinou HT, Sharp N, Thomas JS. Single-incision laparoscopic right colectomy: a case-matched comparison with standard laparoscopic and hand-assisted laparoscopic techniques. *J Am Coll Surg* 2011; 213: 72–80.
6. Poon JT, Cheung CW, Fan JK, Lo OS, Law WL. Single-incision *versus* conventional laparoscopic colectomy for colonic neoplasm: a randomized, controlled trial. *Surg Endosc* 2012; 26: 2729–34.
7. Zhou YM, Wu LP, Zhao YF, Xu DH, Li B. Single-Incision *versus* conventional laparoscopy for colorectal disease: a meta-analysis. *Dig Dis Sci* 2012; 57: 2103–12.
8. Romanelli JR, Earle DB. Single-port laparoscopic surgery: an overview. *Surg Endosc* 2009; 23: 1419–27.
9. Wong MT, Ng KH, Ho KS, Eu KW. Single-incision laparoscopic surgery for right hemicolectomy: our initial experience with 10 cases. *Tech Coloproctol* 2010; 14(3): 225–8.
10. Gaujoux S, Bretagnol F, Ferron M, Pannis Y. Single incision laparoscopic colonic surgery. *Colorectal Dis* 2011; 13(9): 1066–71.
11. Boni L, Dionigi G, Cassinotti E, DiGiuseppe M, Diurni M, Rauseri S, Cantore F, Dionigi R. Single incision laparoscopic right colectomy. *Surg Endosc* 2010; 24(12): 3233–6.
12. Kim SJ, Ryu GO, Choi BJ, Kim JG, Lee KJ, Lee SC, Oh ST. The short-term outcomes of conventional and single-port laparoscopic surgery for colorectal cancer. *Ann Surg* 2011; 254: 933–40.
13. Champagne BJ, Lee EC, Leblanc F, Stein SL, Delaney CP. Single-incision *vs.* straight laparoscopic segmental colectomy: A case-controlled study. *Dis Colon Rectum* 2011; 54: 183–6.

Our experience in the SILS approach was successful, and we had no conversions and other complications. Colonic cancer resections with SILS may be technically difficult and were shown to last longer than CLS in previous reports [12, 13], but in selected patients it could be the method of choice. In our department, we have an overall median operation time of 105 min for SILS right-sided hemicolectomies.

The number of patients in our experience is too short to summarize the early and late complications, post-operative pain release and oncological efficiency comparing to CLS. Positive results of both undergone operations encourage us to continue for the further work developing SILS in colorectal surgery.

## Conclusions

Evaluating the minimal invasion of the method, its abilities and simplicity of conversion to “traditional” laparoscopic procedure, the SILS approach should be negotiable for right hemicolectomies in well-selected patients. Therefore, further studies are required to demonstrate the feasibility of this technique and its effectiveness with regard to oncological outcome.