

ISSN 1392-0995, ISSN 1648-9942 (online)
<http://www.chirurgija.lt>
LIETUVOS CHIRURGIJA
Lithuanian Surgery
2015, 14 (2), p. 97–104

Originalūs mokslo tiriamieji darbai

Implant and spinal mobility influence on the spinal curvature correction in adolescent idiopathic Lenke I type scoliosis

Implantų ir stuburo mobilumo įtaka stuburo iškrypimo korekcijai sergant jaunatvine idiopatine I tipo Lenke skolioze

Giedrius Bernotavičius¹, Kęstutis Saniukas¹, Justina Vaičiulėnaitė², Vykintas Sabaliauskas²

¹ Vilnius University, Faculty of Medicine, Gastroenterology, Nephrourology and Surgery Clinic, Santariškių Str. 2, LT-08661 Vilnius, Lithuania

² Vilnius University, Faculty of Medicine, M. K. Čiurlionio Str. 21, LT-03101 Vilnius, Lithuania
E-mail: giedrius.bernotavicius@vuw.lt

¹ Vilniaus universiteto Medicinos fakulteto Gastroenterologijos, nefrourologijos ir chirurgijos klinika, Santariškių g. 2, LT-08661 Vilnius

² Vilniaus universiteto Medicinos fakultetas, M. K. Čiurlionio g. 21, LT-03101 Vilnius
El. paštas: giedrius.bernotavicius@vuw.lt

Background and objective

There are still a few researches accomplished to evaluate the advantages and disadvantages of screw, hybrid, and hook techniques in the treatment of adolescent idiopathic scoliosis. As the results are controversial, researchers still look for optimally safe, least traumatizing and economically reasonable methods to treat spinal deformities. The aim of this study is to analyze postoperative spine deformity correction results for Lenke type 1 dependent on fixation type and preoperative bending films.

Patients and methods

A retrospective study was performed. Patients admitted to the Children's Hospital, Affiliate of Vilnius University Hospital Santariškių Klinikos Orthopedic Department in the period of 1994–2013 were included; 74 cases were analyzed. Three groups according to spine implants were generated. The first included patients treated with pedicle screw fixation, the second – hybrid, and the third – hook fixation. Inclusion criteria: the adolescent age group (10–18), idiopathic scoliosis Lenke I type who undergone posterior spinal fusion with pedicle screws; hybrid fixation and hook application were evaluated in order to compare curve correction dependence on fixation type and curve flexibility. Thoracic and lumbar curve measurements on the coronal plane were performed using the Cobb technique applied on anterior posterior radiographs taken before and two days after surgery. Also, to measure curve flexibility, preoperative passive standing bending films were analyzed. Curve degrees in preoperative passive bending films were compared with the remaining postoperative spinal curves in groups separately. The remaining postoperative curves were compared respectively.

Results

In total, 74 cases met the inclusion criteria, of them 67 (90.50%) girls and 7 (9.50%) boys. The mean preoperative thoracic Cobb angle was $51.07^\circ (\pm 6.20)$ in the screw group, $52.88^\circ (\pm 7.26)$ in the hybrid and $55.45^\circ (\pm 10.94)$ in the hook group. To compare the preoperative stiffness of the curves, the flexibility % was calculated, with no difference in the groups ($p > 0.05$). The mean postoperative thoracic Cobb curve angle was $15.81^\circ (\pm 5.28)$, $21.63^\circ (\pm 6.89)$, and $27.55^\circ (\pm 8.25)$, respectively. The mean correction of the thoracic curve was 68.87% in the screw group, 58.76% in the hybrid and 50.27% in the hook group. The mean preoperative lumbar curve Cobb angle was $32.07^\circ (\pm 5.73)$ in the screw group, $32.50^\circ (\pm 12.33)$ in the hybrid and $34.74^\circ (\pm 7.50)$ in the hook group. The mean postoperative lumbar curve Cobb angle was $7.59^\circ (\pm 6.63)$, $10.94^\circ (\pm 7.52)$, and $16.06^\circ (\pm 6.89)$, respectively. The mean correction of the lumbar curve was 75.58% in the screw group, 66.27% in the hybrid and 53.53% in the hook group. The fixation level according to groups: screw Th4-L1, hybrid Th3-L3, hook Th3-L3.

Conclusions

The thoracic curve tends to recover more than the curve remaining in the lateral bending film. Only screw fixation is able to correct the lumbar curve for the Lenke type 1 as it is expected in the remaining lateral bending curve. Thoracic and lumbar deformity using screw fixation recovers on the average by 20% more than hook and by 10% more than hybrid application. The pedicular screw construct is shorter and is able to correct the thoracic curve whatever the modifier type (A, B or C); however, the lumbar curve correction drops when the modifier type is B or C. The other operative methods are less effective to correct both thoracic and lumbar curves whatever the modifier type and also tend to lose the correction % for types 1B or 1C.

Key words: adolescent idiopathic scoliosis, pedicular screws, hook fixation, hybrid fixation, bending X-rays, flexibility

Darbo tikslas

Įvertinti Lenke I tipo stuburo deformacijos korekcijos rezultatų priklausomybę nuo fiksacijos būdo ir stuburo mobilumo.

Ligoniai ir metodai

Atlikta retrospektyvi vaikų, operuotų Vilniaus universiteto Vaikų ligoninės ortopedijos ir traumatologijos centre 1994–2013 metais dėl idiopatinės paauglių skoliozės, analizė. Išanalizuoti 74 atvejai. Ligoniai suskirstyti į tris grupes: I – atlikta nugarinė spondilodezė, pedikulinė fiksacija sraigtais, II – nugarinė spondilodezė, mišri fiksacija ir III – nugarinė spondilodezė, fiksacija kabliukais. Įtraukimo kriterijai: 10–18 metų amžiaus vaikai, turintys idiopatinę skoliozę pagal Lenke I tipo klasifikaciją. Jiems buvo atlikta užpakalinė spondilodezė su pedikuliniais sraigtais, kabliukais arba hibridinė fiksacija. Krūtininiai ir juosmeniniai stuburo iškrypimai koronarinėje plokštumoje buvo vertinti priekinėje ir užpakalinėje rentgenogramose ir matuoti prieš operaciją ir 2 dienas po operacijos naudojant Cobbo metodiką. Taip pat buvo įvertintos šoninio lenkimo rentgenogramos siekiant išmatuoti stuburo kreivės mobilumą prieš operaciją. Stuburo išlinkimas šoninio lenkimo rentgenogramose prieš operaciją buvo palygintas su stuburo iškrypimu po operacijos kiekvienoje grupėje.

Rezultatai

Iš 74 ligonių 67 (90,50 %) buvo mergaitės, 7 (9,50 %) berniukai. Prieš operaciją vidutinis krūtininis iškrypimas: $51,07^\circ (\pm 6,20)$ – I grupėje; $52,88^\circ (\pm 7,26)$ – II grupėje ir $55,45^\circ (\pm 10,94)$ – III grupėje. Siekiant palyginti stuburo kreivių standumą prieš operaciją, buvo apskaičiuotas mobilumo procentas ir nebuvo rasta statistiškai reikšmingo skirtumo tarp grupių ($p > 0,05$). Po operacijos vidutinis krūtininis iškrypimas I grupėje buvo $15,81^\circ (\pm 5,28)$, II grupėje – $21,63^\circ (\pm 6,89)$ ir III grupėje – $27,55^\circ (\pm 8,25)$. Stuburo iškrypimas atsisaisė 68,87 % – I; 58,76 % – II ir 50,27 % – III grupėje. Prieš operaciją vidutinis juosmeninis iškrypimas buvo $32,07^\circ (\pm 5,73)$ – I grupėje, $32,50^\circ (\pm 12,33)$ – II grupėje ir $34,74^\circ (\pm 7,50)$ – III grupėje. Po operacijos – atitinkamai $7,59^\circ (\pm 6,63)$, $10,94^\circ (\pm 7,52)$ ir $16,06^\circ (\pm 6,89)$. Stuburo juosmeninės dalies iškrypimas atsisaisė 75,58 % – I; 66,27 % – II ir 53,53 % III grupėje. I grupėje fiksacijos lygis buvo Th4-L1, II grupėje – Th3-L3, III grupėje – Th3-L3.

Išvados

Krūtininis iškrypimas atsitaiso daugiau, negu buvo tikimasi atlikus šoninio lenkimo rentgenogramas. Tik fiksacija sraigtais atitaiso juosmeninį iškrypimą tiek, kiek tikimasi atlikus šoninio lenkimo rentgenogramas. Fiksuojant sraigtais krūtininis ir juosmeninis iškrypimai atsitaiso vidutiniškai 20 % daugiau, negu fiksuojant kabliukais, ir 10 % daugiau, negu taikant mišrią fiksaciją. Pedikulinių sraigtų konstrukcija yra trumpesnė ir gali koreguoti krūtininį stuburo iškrypimą nepaisant išlinkimo tipo (A, B ar C), tačiau juosmeninio iškrypimo korekcija blogėja esant B ar C tipui. Kiti operacijos metodai yra mažiau veiksmingi koreguojant tiek krūtininį, tiek juosmeninį iškrypimą esant bet kuriam stuburo išlinkimo tipui ir yra susiję su korekcijos praradimu esant 1B ir 1C tipui.

Reikšminiai žodžiai: jaunatvinė idiopatinė skoliozė, pedikuliniai sraigčiai, fiksacija kabliukais, hibridinė fiksacija, šoninio lenkimo rentgenograma, mobilumas

Introduction

Spinal implant constructs have developed over years from *in situ* fusion and cast stabilization to non-segmental rods, to segmental wire fixation, to segmental hook fixation, to segmental screw fixation and to segmental hook and screw fixation [1]. Each improvement has to be estimated, and it is important to find out which surgical technique gives the best clinical benefits to the patient.

The use of pedicle screw in lumbar curves improved the correction and stabilization of various spinal deformities, and some studies supported the advantages of lumbar pedicle screws versus hook instrumentation [2, 3]. However, the use of pedicle screws in the thoracic spine was not as widely adopted in AIS because of the confined anatomic dimensions and morphologic distortion of scoliotic pedicles, the close proximity of the spinal cord to the concave pedicle, and the subsequent risk to the spinal cord and visceral structures with screw malposition. Nevertheless, the application of pedicular screws expands the potential of spinal deformity correction in three dimensions, requires better correction results, shorter fixation length and reduces the usage of thoracoplasty procedures as well as postoperative correction loss.

There were a few researches accomplished to evaluate the advantages and disadvantages of screw, hybrid, and hook techniques [1, 4, 5]. As the results are controver-

sial, researchers still look for optimally safe, least traumatizing and economically reasonable methods to treat spinal deformities. Therefore, the aim of this research is to evaluate the lateral bending radiographs and to compare them with the remaining curves, fixation length after operation, applying different surgical techniques in the Lenke I type scoliosis.

Materials and Methods

A retrospective chart review was done in the spine service of the Vilnius University Children's Hospital. All patients with operative AIS were analyzed from a single institutional database. Data collection was carried out prospectively and retrospectively in the screw group and retrospectively in the hybrid and hook groups. Inclusion criteria: children at the age of 10 to 18 with the Lenke type 1 were involved. Patients with congenital scoliosis were excluded from the analysis. The included 74 patients were analyzed and underwent posterior spinal fusion with pedicle screws (27) in 2012–2013, hybrid (16) in 2010–2011, and hook application (31) in the period 1994–2005.

Thoracic and lumbar curve measurements on the coronal plane were performed using the Cobb technique applied on posterior-anterior radiographs taken immediately before and two days after the operation. Also, to measure curve flexibility, preoperative passive

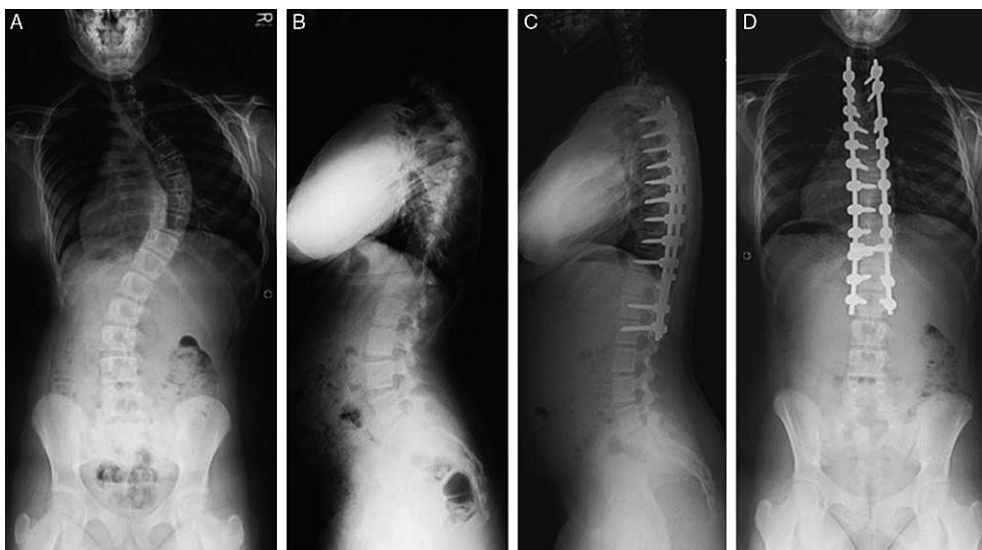


Figure 1. A–D, preoperative spine X-rays of a patient with screw instrumentation

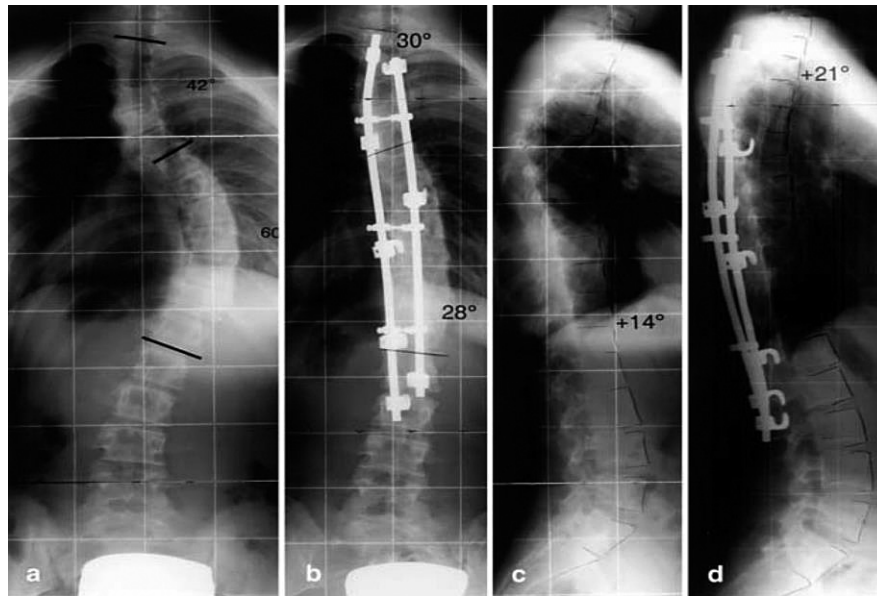


Figure 2. Preoperative spine X-rays of a patient with hooks instrumentation

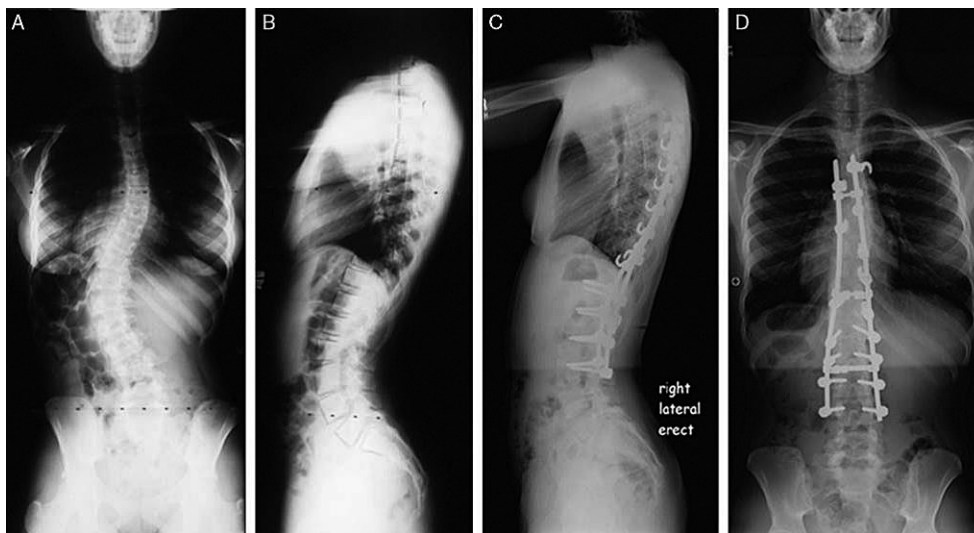


Figure 3. Preoperative spine x-rays of a patient with hybrid instrumentation

standing bending films were analyzed (Figure 4). These views were obtained upright with the patient leaning maximally to one side or the other. The bending film Cobb angle was compared with the neutral position.

All cases were subdivided into three groups according to the Lenke type 1 classification for idiopathic scoliosis A, B, and C modifier. These three modifier types were differentiated according to the curve apex deviation from the central line.

Curve degrees in preoperative passive bending films were compared with the remaining postoperative spinal curves in three groups separately. To compare the preoperative stiffness of the curves, the flexibility % was calculated as

$$\text{Flexibility \%} = \frac{\text{preoperative curve} - \text{lateral bending curve}}{\text{preoperative curve}} \times 100$$

Correction % was calculated as

$$\text{Correction \%} = \frac{\text{preoperative curve} - \text{lateral bending curve}}{\text{preoperative curve}} \times 100$$

The remaining postoperative curves and the correction % were compared among the groups. Various SAS procedures were applied to non-parametrical criteria for dependent and independent samples to perform the statistical analysis. Statistical significance was established at the $P < 0.05$ level.

and $30.19^\circ (\pm 8.29)$ in the hook group. Figure 3 represents the thoracic deformity mobility comparison to correction. It shows that curve correction is on average by 21% bigger than mobility in the screw group ($p < 0.0001$), 13% in the hybrid ($p < 0.0443$) and 5% in the hook group ($p < 0.2398$).

The mean lumbar bending Cobb angle was $9.81^\circ (\pm 4.98)$ in the screw group, $8.63^\circ (\pm 4.83)$ in the hybrid and $11.50^\circ (\pm 6.27)$ in the hook group. The lumbar de-

Table 1. Measurement and calculation results

Cobb angle		Screw	Hybrid	Hook
Preoperative	Thoracic	51.07° (±6.20)	52.88° (±7.26)	55.45° (±10.94)
	Lumbar	32.07° (±5.73)	32.50° (±12.33)	34.74° (±7.50)
Postoperative	Thoracic	15.81° (±5.28)	21.63° (±6.89)	27.55° (±8.25)
	Lumbar	7.59° (±6.63)	10.94° (±7.52)	16.06° (±6.89)
Lateral bending	Thoracic	26.93° (±8.3)	28.69° (±11.07)	30.19° (±8.29)
	Lumbar	9.81° (±4.98)	8.63° (±4.83)	11.50° (±6.27)
Mobility %	Thoracic	47.57%	45.80%	45.34%
	Lumbar	67.50%	67.98%	75.34%
Correction %	Thoracic	68.87%	58.76%	50.27%
	Lumbar	75.58%	66.27%	53.53%

Results

Among 74 patients with AIS who were operated on at the VUVL pediatric orthopedics and traumatology center, 67 (90.50%) were female and 7 (9.50%) male. The radiographic results are shown in Table 1. The mean preoperative thoracic Cobb angle was $51.07^\circ (\pm 6.20)$ in the screw group, $52.88^\circ (\pm 7.26)$ in the hybrid and $55.45^\circ (\pm 10.94)$ in the hook group. The mean postoperative thoracic Cobb curve angle was $15.81^\circ (\pm 5.28)$, $21.63^\circ (\pm 6.89)$, and $27.55^\circ (\pm 8.25)$, respectively. The mean preoperative lumbar curve Cobb angle was $32.07^\circ (\pm 5.73)$ in the screw group, $32.50^\circ (\pm 12.33)$ in the hybrid group, and $34.74^\circ (\pm 7.50)$ in the hook group. The mean postoperative lumbar curve Cobb angle was $7.59^\circ (\pm 6.63)$, $10.94^\circ (\pm 7.52)$, and $16.06^\circ (\pm 6.89)$, respectively.

The mean thoracic bending Cobb angle was $26.93^\circ (\pm 8.3)$ in the screw group, $28.69^\circ (\pm 11.07)$ in the hybrid

formity mobility comparison to correction: it shows that the curve correction is on average by 8% bigger than mobility in the group with screw fixation ($p < 0.295$) but by 2% and 22% smaller in the group with hybrid fixation ($p < 0.561$) and in the group with hook fixation ($p < 0.0001$), respectively (Table 2).

Consequently, the thoracic curve tends to recover more than the curve remaining in the lateral bending film, and only screw fixation is able to correct the lumbar curve as it is expected in the remaining lateral bending curve.

Table 2. The p significance between spine mobility and correction inside each group

	Screw	Hybrid	Hook
Thoracic	$P < 0.0001$	$P < 0.0443$	$P < 0.2398$
Lumbar	$P < 0.295$	$P < 0.561$	$P < 0.0001$

The mean correction of the thoracic curve was 68.87% in the screw group, 58.76% in the hybrid and 50.27% in the hook group. The mean correction % of the lumbar curve was 75.58% in the screw group, 66.27% in the hybrid and 53.53% in the hook group. Therefore, the thoracic and lumbar deformity using screw fixation recovers on the average by 20% more than hook and by 10% more than hybrid application (Table 3).

ing adolescent idiopathic scoliosis (AIS) was reported by Suk et al. in 1995 and Liljenqvist et al. in 1997. The technology has changed, but the goals of surgery for AIS remain the same: to halt curve progression and to correct deformity, maintain a balanced spine in the coronal and sagittal planes, preserve as many mobile spinal segments as possible, and prevent surgical complications such as junctional kyphosis, adding-on, and revision surgery [1, 4–12].

Table 3. The *p* significance for correction % among the groups

		Hybrid		Hook	
		Thoracic	Lumbar	Thoracic	Lumbar
Screw	Thoracic	P < 0.1188		P < 0.0026	
	Lumbar		P < 0.3205		P < 0.0083

The pedicular screw construct is able to correct the thoracic curve no matter how severe it is (A, B or C); however, lumbar curve correction drops when the modifier type is B or C. The other operative methods are less effective to correct both thoracic and lumbar curves despite the modifier type and also tend to lose correction % for type 1B or 1C. The pedicular screw construct is able to correct the thoracic curve no matter how severe it is (A, B or C); however, the lumbar curve correction decreases when the modifier type is B or C. The other operative methods are less effective to correct both thoracic and lumbar curves despite the modifier type and also tend to lose the correction % for types 1B or 1C.

The thoracic curve correction and fixation level comparison among the groups according to the Lenke I type in the group with the screw instrumentation fixation level was Th4-L1, and in the hybrid and hook group it was Th3-L3.

Discussion

Segmental instrumentation in spinal surgery was first introduced by Luque in 1982 when he combined the rods with sublaminar wires. The next significant development was the segmental hook–rod system designed by Cotrel-Dubousset. The use of pedicle screws in treat-

As to the analysis of what is the best implants to use, the debate extends from the mid-1990s. Discussions were held on the biomechanics of the operation and the safety of the complications, a three-dimensional deformity correction, improvement in clinical outcomes, and cost [1]. Authors argue whether the fixation with screws is more efficient than fixation with hooks. According to some studies, using screw fixation the possibility of mechanical deformation of the spine to correct three planes and between the two segments is higher than using hook fixation [2, 4, 13–15]. Yilmaz et al. [4] have discovered that pedicle screw and hybrid instrumentations provide a significantly greater spinal deformity correction than hook fixation in every radiographic measure and maintenance of the correction in the coronal and sagittal planes. HS An et al. [14] compared the stability of posterior hook-rod and pedicle screw configuration in an unstable burst-fracture model and have found that pedicle screw constructs are more stable than hook-rod systems.

For a long time, the use of screws in the thoracic and especially convex side was debatable. Morphological changes in the vertebrae, the spinal cord, aorta infringement are limited by the frequent use of screws in thoracic spinal curvature correction. The experience and tapping screws' precision and control of growth are

influenced by the increasing use of spinal screws in the treatment of deformities [2, 7, 16]. In literature, there are few scientific studies to look at the different fixation methods on the results of the correction. One of the first studies was done by Kim colleagues [17] who compared the use of hooks and screws adjusting spinal deformities. The authors' postoperative correction was better in the screw group as compared with the hooks. The correction was 76% and 50%. Our result is 74% and 49%, which validates the data. Suk and colleagues [18] presented data which compare the fixation screws and hooks with respect to all three planes of correction and a statistically significant difference. From these data, the screw fixation is much more effective. However, Karatoprak and colleagues state that the difference is not great, especially when using the hybrid sistem (hooks and screws) [19]. The correction of spinal deformity was 70.3% and 67.7%, respectively. Di Silverstre and colleagues [5] reported that using the screws, especially for large deformations of the spine, provides a greater correction in both planes, less post-operative correction of fixed spinal degrees of loss, and less revision surgery. Using only the screw fixation of the spine, the fixed number of segments is lower [2, 4]. The literature and our results confirm that the screw fixation of thoracic curvature recover the average of 25%, and this is by 20% more than with hook fixation ($p < 0.05$) [4, 17, 20, 21].

Rose and colleagues compared the minimum 2-year follow-up results of adult idiopathic scoliosis patients instrumented with pedicle screw and hybrid constructs with 34 patients in each group. Patients with pedicle screws had a significantly higher curve correction rate (55.6% vs. 40.1%), and the correction was maintained in both groups. However, coronal balance and blood loss were similar in both groups and so were the SRS outcome scores. What is more, patients in the hook / hybrid group had a better sagittal alignment in the last follow-up. [22].

Jaquith and colleagues made an interesting study [1] which compared the cost of spinal implants – hook and hybrid constructs and pedicle screw constructs in the

posterior spinal fusion in AIS. Pedicle screw instrumentation was more expensive overall, per fused level, and per the degree of correction. Also, more implants were used, but more levels were fused in the pedicle screw group than in the hook-hybrid group. Nevertheless, pedicle screws provided a significantly better correction of the major spinal curve.

According to our data, the postoperative deformity correction was much higher than expected from lateral bending radiographs. This can be explained by the fact that we use the lateral bending maneuver without mechanical action. Using the mechanical effects of X-rays to bend the larger planned correction and postoperative results are virtually identical [23]. We consider that using the mechanical action to perform the lateral bending radiographs before surgery is not as accurate as using a simple passing maneuver in order to determine fixation length and location. Summarizing the discussion, the spinal fixation with pedicle screws provided a better correction after surgery, and it is a safe technique but much more expensive than hook fixation. The preoperative assessment of spinal mobility must be carried out in order to plan the method of fixation and the size of the spinal fusion.

Conclusions

Thoracic curve tends to recover more than the curve remaining in the lateral bending film. Only fixation with pedicle screws is able to correct the lumbar curve for the Lenke type 1 as it is expected in the remaining lateral bending curve. Thoracic and lumbar deformity using screw fixation recovers on the average by 20% more than the hook and by 10% more than the hybrid application. Segmental pedicle screw instrumentation offers a significantly better curve correction as compared with the hybrid and hook instrumentation and has a shorter fusion level.

Statement of conflict of interests

The authors state no conflict of interests.

REFERENCES

1. Jaquith B, et al. Screws versus hooks: implant cost and deformity correction in adolescent idiopathic scoliosis. *J Child Orthop*. 2012; 6: 137–143.
2. Gaines RW Jr. The use of pedicle-screw internal fixation for the operative treatment of spinal disorders. *J Bone Joint Surg Am*. 2000; 82-A: 1458–1476.
3. Brown CA, Lenke LG, Bridwell KH et al. Complications of pediatric thoracolumbar and lumbar pedicle screws. *Spine*. 1998; 23: 1566–1567.
4. Yilmaz G, et al. Comparative analysis of hook, hybrid, and pedicle screw instrumentation in the posterior treatment of adolescent idiopathic scoliosis. *J Pediatr Orthop*. 2012; 32: 490–499.
5. Di Silverstre M, Bakaloudis G, Lolli F, et al. Posterior fusion only for thoracic adolescent idiopathic scoliosis of more than 80 degrees: pedicle screws versus hybrid instrumentation. *Eur Spine J*. 2008; 17: 1336–1349.
6. Dubousset J, Cotrel Y. CD-instrumentation in the treatment of spinal deformities. *Orthopade*. 1989; 18: 118–127.
7. Suk SI, et al. Segmental pedicle screw fixation in the treatment of thoracic idiopathic scoliosis. *Spine (Phila Pa 1976)*. 1995; 20: 1399–1405.
8. Crostelli M. Treatment of severe scoliosis with posterior-only approach arthrodesis and all-pedicle screw instrumentation. *Eur Spine J*. 2013.
9. Sun L, et al. Bilateral apical vertebral derotation technique by vertebral column manipulation compared with vertebral coplanar alignment technique in the correction of Lenke type 1 idiopathic scoliosis. *BMC Musculoskeletal Disorders*, 2013; 14: 175.
10. Suk SI, et al. Selective thoracic fusion with segmental pedicle screw fixation in the treatment of thoracic idiopathic scoliosis: more than 5-year follow-up. *Spine (Phila Pa 1976)*, 2005; 30: 1602–1609.
11. Akazawa T. Rod fracture after long construct fusion for spinal deformity: clinical and radiographic risk factors. *J Orthop Sci*; 2013.
12. Li Y, et al. Surgical site infection after pediatric spinal deformity surgery. *Curr Rev Musculoskelet Med* 2012; 5: 111–119.
13. Kuklo TR, et al. Accuracy and efficacy of thoracic pedicle screws in curves more than 90 degrees. *Spine (Phila Pa 1976)*. 2005; 30: 222–226.
14. An HS, Singh K, Vaccaro AR, et al. Biomechanical evaluation of contemporary posterior spinal internal fixation configurations in an unstable burst-fracture calf spine model: special references of hook configurations and pedicle screws. *Spine (Phila Pa 1976)*. 2004; 29: 257–262.
15. Deviren V, et al. Pedicle screw fixation of the thoracic spine: an *in vitro* biomechanical study on different configurations. *Spine (Phila Pa 1976)*. 2005; 30: 2530–2537.
16. Kim YJ, Lenke LG, Bridwell KH, et al. Free hand pedicle screw placement in the thoracic spine: is it safe? *Spine (Phila Pa 1976)*. 2004; 29: 333–342.
17. Kim YJ, et al. Comparative analysis of pedicle screw versus hook instrumentation in posterior spinal fusion of adolescent idiopathic scoliosis. *Spine (Phila Pa 1976)*. 2004; 29: 2040–2048.
18. Suk SI, Kim WJ, Lee SM, et al. Thoracic pedicle screw fixation in spinal deformities: are they really safe? *Spine*. 2001; 26: 2049–2057.
19. Karatoprak O, et al. Comparative analysis of pedicle screw versus hybrid instrumentation in adolescent idiopathic scoliosis surgery. *Int Orthop*. 2008; 32: 523–528
20. Yu, et al. Segmental correction of adolescent idiopathic scoliosis by all-screw fixation method in adolescents and young adults. minimum 5 years follow-up with SF-36 questionnaire. *Scoliosis* 2012; 7: 5.
21. Min K, et al. Posterior correction of thoracic adolescent idiopathic scoliosis with pedicle screw instrumentation: results of 48 patients with minimal 10-year follow-up. *Eur Spine J*. 2013; 22: 34.
22. Rose PS, Lenke LG, Bridwell KH, et al. Pedicle screw instrumentation for adult idiopathic scoliosis: an improvement over hook/hybrid fixation. *Spine (Phila Pa 1976)*. 2009; 34: 852–857.
23. Edward R. Westrick, MD, W. Timothy Ward, MD. Adolescent idiopathic scoliosis: 5-year to 20-year evidence-based surgical results. *J Pediatr Orthop*. 2011; 31: 61–67.