

## Peri-Operative Cataract Surgery Complications associated with Hepatitis C: an observational study

Suman Bhartiya<sup>1</sup>, Prachi Shukla<sup>2\*</sup>, Kopal Mithal<sup>2</sup>, Swati Agarwal<sup>3</sup>, Vijay Pratap Singh<sup>4</sup>

<sup>1</sup>Professor and Head, Department of Ophthalmology Muzaffarnagar Medical College, Muzaffarnagar, U.P., India

<sup>2</sup>Associate Professor, Department of Ophthalmology Muzaffarnagar Medical College, Muzaffarnagar, U.P., India

<sup>3</sup>Assistant Professor, Department of Ophthalmology Muzaffarnagar Medical College, Muzaffarnagar, U.P., India

<sup>4</sup>Senior Resident, Department of Ophthalmology Muzaffarnagar Medical College, Muzaffarnagar, U.P., India

Received: 09-06-2020 / Revised: 29-07-2020 / Accepted: 18-08-2020

### Abstract

**Introduction:** Small Incision Cataract surgery (SICS) is one of the most commonly performed surgery and the Hepatitis C virus infection in the country like ours is an upcoming health hazard. Undiagnosed asymptomatic HCV sero-positive cases outnumber the diagnosed cases. Hypocoagulability because of hepatitis, can cause detrimental effect on cataract surgery. **Objective:** To analyze the cataract surgery complications in HCV infected cases.

**Methods:** This was a prospective, observational study conducted in the department of Ophthalmology of Muzaffarnagar Medical College, Uttar Pradesh from January 2019 to January 2020. After taking permission from the ethical committee and informed-written consent from the patients, total 200 eyes of 158 patients having (116 unilateral and 42 bilateral) cataract and incidentally diagnosed positive for HCV infection were enrolled in the study.

**Results:** Out of 200 eyes, 48 eyes had no complications and 152 (76%) eyes had one or more complications like intra-operative bleed (68%), difficulty in wound closure (19.5%), post-operative AC reaction (61.5%), delayed healing (49%), hyphema (48%), leaky wound (37%) and keratitis (34%). **Conclusion:** Significant number of asymptomatic HCV sero-positive patients undergoing cataract surgery had peri-operative complications. It is recommended that pre-operative viral marker screening of all cataract patients should be done and measures to combat the difficulties during and after the surgery should be taken care of.

**Keywords :** HCV positive, Peri-Operative, Cataract Surgery.

This is an Open Access article that uses a fund-ing model which does not charge readers or their institutions for access and distributed under the terms of the Creative Commons Attribution License (<http://creativecommons.org/licenses/by/4.0>) and the Budapest Open Access Initiative (<http://www.budapestopenaccessinitiative.org/read>), which permit unrestricted use, distribution, and reproduction in any medium, provided the original work is properly credited.

### Introduction

Cataract has been the major cause of decreased vision and eventually may lead to blindness if remain untreated, so cataract surgery is the most commonly performed surgery worldwide [1], Hepatitis C virus (HCV), the causative agent of chronic liver disease is a major cause of morbidity and mortality across the world.

The prevalence of HCV globally is estimated to be 2-3% that is roughly 130-170 million people worldwide [2,3]. India contributes about 12-18 million HCV infected people as the prevalence here is about 0.5-1.5% [3], though geographical variation exists, as the Northeast part of India is considered as the hot spot of this infection [4]. One of the major presentations in HCV infection is liver involvement and more than 80% of acute liver disease leads to chronicity [5]. Not only the risk of exposure to health care workers is a problem, but also the complications associated with it during and after cataract surgery is also a point to ponder. It has been documented that majority of seropositive patients remain asymptomatic and so can go undiagnosed, but we have encountered the

\*Correspondence

**Dr. Prachi Shukla**

Associate Professor, Department of Ophthalmology  
Muzaffarnagar Medical College, Muzaffarnagar, U.P.,  
India.

**E-mail:** [prachipankajtyagi@gmail.com](mailto:prachipankajtyagi@gmail.com)

challenges in cataract surgeries of HCV positive cases. The impact of HCV infection on cataract surgery has not been studied in the past to the best of our knowledge, so this study was conducted in our department to explore the facts regarding this situation.

### Materials and Methods

This was a prospective, observational study conducted in the department of Ophthalmology of Muzaffarnagar Medical College, Uttar Pradesh from January 2019 to January 2020. Total 200 eyes of 158 patients having (116 unilateral and 42 bilateral) cataract and incidentally diagnosed HCV positive cases above the age of 20 years irrespective of gender were enrolled in the study. Permission from the ethical committee (MMC/PO/2019/39) and signed-informed consent from all the patients for investigations and cataract surgery was taken. Serological markers for HCV, HBsAg and HIV of all patients were tested. Meticulous slit lamp and fundus examination of the eyes were done to rule out any obvious cause for peri-operative complications. Inclusion criteria were the patients having any grade of cataract who were recently diagnosed to be HCV positive, but HIV and HBV negative. Patients having pre-existing bleeding disorders, rubeosis iridis, atrophic iris, complicated cataract were excluded from the study. Patients on acetylsalicylic acid tablet (Aspirin) or Warfarin (Coumadin) were asked to stop the medication 1 week prior to the surgery with permission of the treating physician.

### Surgical Steps

All the patients underwent small incision cataract surgery (SICS) in the major operation theatre by a common surgeon. SICS was preferred over phacoemulsification to avoid the transmission of infection from one person to another through phaco probe and tubing. The eyes were anesthetized using peribulbar injection of 2% xylocaine with 1:200,000 epinephrine prior to the SICS. Under strict aseptic condition, bridle suture was passed to fix the eye in downward gaze, then after making fornix based conjunctival flap from 10 to 2 O'clock, sclera was exposed and haemostasis was achieved by using gentle

and just adequate wet field cautery. Self sealing sclero-corneal tunnel was made 2mm behind the limbus which extended 1.5 mm into the clear cornea using the crescent knife. After making 1.5 mm corneal valvular side port entry, capsular staining and capsulorhexis were done. Internal corneal entry was made using 2.8mm angled keratome following which hydro-dissection, nuclear management, cortical matter aspiration was performed. After implantation of posterior chamber intra-ocular lens, anterior chamber wash, injection of air, hydration of side port and wound closure was done. Then bridle suture was removed and conjunctival flap repositioned and secured with the help of wet field cautery. Before patching of the eye, subconjunctival injection of Gentamycin 0.5ml and Dexamethasone 0.25 ml was given in the inferior fornix.

### Postoperative Regimen

On the day of surgery patients were prescribed oral Ibuprofen 400mg, Ciprofloxacin 500mg twice daily and Pantoprazole 40 mg once a day for five days. On the first post-operative day eye dressing was removed and E/D Moxifloxacin 0.5% and Prednisolone acetate 1% combination for 6 times, E/D Nepafenac 0.3% and carboxymethylcellulose sodium 0.5% drops 3 times per day were prescribed in uneventful cases. Antibiotic-steroid combination drop was tapered in 6 weeks duration, Nepafenac drop was continued on the same dosage till 6 weeks then stopped but lubricant drops were continued for long term. In case of some abnormal findings, treatment was changed accordingly. The patients were followed up post operatively on day 3, day 7, 4 weeks and 6 weeks.

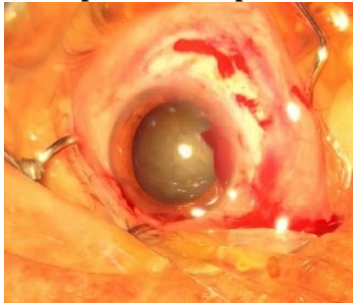### Observations

Small Incision Cataract Surgery (SICS) was done in 200 eyes of 158 newly diagnosed HCV positive patients attending the Ophthalmology OPD. Out of 158 patients 72 (45.56%) were males and 86 (54.43%) females between the age group of 20-80 years. Difficulties observed during surgeries and in post operative period in the patients are depicted in the table 1.

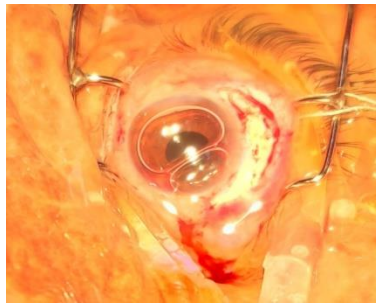
**Table 1: Intra-operative and post-operative complication**

Complications				
S. No.	Intra-operative	No. of Eyes	Post-operative	No. of Eyes
1.	Bleeding	136	AC reaction	123
2.	Difficulty in wound closure	39	Delayed healing	98
3.			Hyphema	96
4.			Leaking wound	74
5.			Keratitis	68

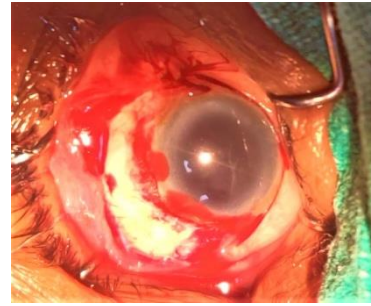
**Intra Operative Complications**



**Fig 1:Tunnel Bleed**



**Fig 2: Hyphema**

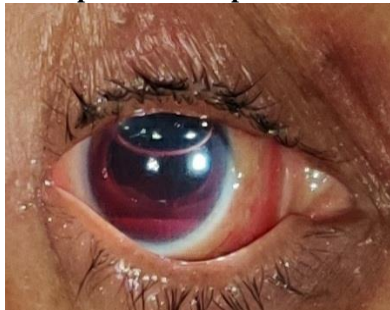

**Fig 3 :Excessive bleed**

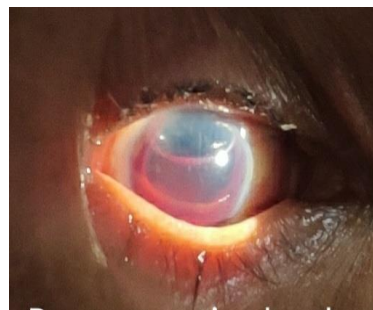**Table 2: Corrective measures to treat the complications**

Methods to correct the complications		
S. No.	Corrective Measures	No. of Patients
1.	Injection Tranexamic acid	31
2.	Intra-operative suture	28
3.	Post- operative Pressure Patch	74
4.	Post- operative suture	27
5.	Cautery in-side tunnel	08

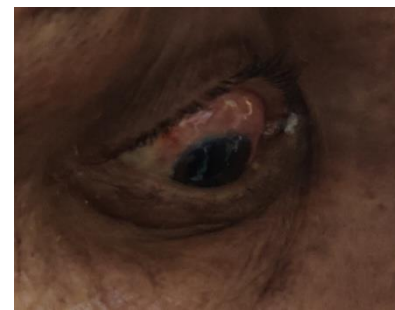**Post Operative Complications**



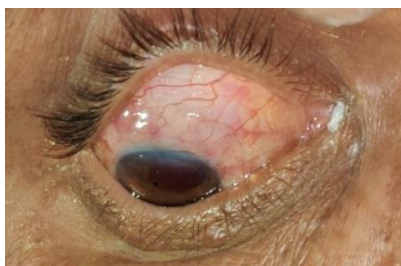
**Fig 4 :Hyphema**



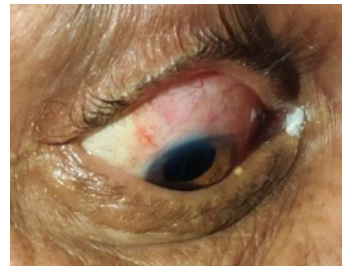
**Fig 5:Hyphema with Keratitis**



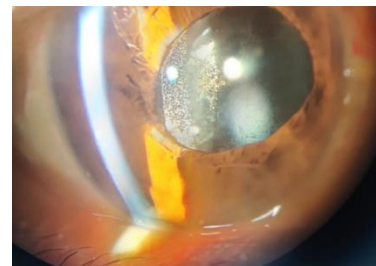
**Fig 6:Sub conjunctival bleb**



**Fig 7:Diffuse bleb and congestion**



**Fig 8 :Chemosis and congestion**



**Fig 9:AC reaction and pigments**

Out of 200 eyes 48 eyes had no complications and 152 (76%) eyes had one or more complications (table-1). In 78 out of 116 patients with singly operated eye and 37 out of 42 patients in which both eyes were operated

had some or the other complication in their operated eyes either in intra-operative or post-operative period. Commonest complication was intra-operative bleeding, that mostly was from the scleral tunnel in 136 (68%)

patients (Fig-1). Difficulty in stopping the continuous ooze was also faced in these cases. Even after the closure of the wound or in spite of putting air into the anterior chamber blood seepage into AC recurred and cautery was needed inside the tunnel in 8 (4%) eyes (Fig-2). In 31(15.5%) cases intra-operative intra venous injection of 100mg /ml Tranexamic acid was given to stop the bleeding (Table-2). In 39 (19.5%) cases due to excessive maneuvering, problem was encountered in wound closure and recurrent fluid or air egress and blood seepage into AC was observed. To seal the entry wound figure of 8 suture was applied in 28 (14%) cases (Table-2). On the first post-operative day 123 (61.5%) eyes presented with anterior chamber reaction (Fig-9), 96 (48%) eyes had hyphema (Fig-4, 5) and 74 (37%) eyes had leaky wound and keratitis of different severities was observed in 68 (34%) eyes (Fig-5). Out of 200 eyes 98 (49%) showed a delayed healing of the surgical wound, manifested by conjunctival congestion, conjunctival chemosis, shallow anterior chamber, positive seidel test and sub-conjunctival bleb formation. At 1 week follow-up, 27 (13.5%) eyes wound suturing was done to stop the leakage. These were the patients who presented with sub conjunctival bleb, even after putting pressure patch. In 96 (48%) eyes on the 1<sup>st</sup> post operative day hyphema was found out of which 87 (43.5%) eyes were those who had intra operative bleed too, but in 9 (4.5%) eyes in spite of uneventful surgery, hyphema was found on the first post operative day.

### Result

In this study 200 eyes of 158 newly diagnosed HCV positive patients having any grade of cataract were included. SICS was done and the impact of the HCV on the surgery and its outcome was observed. 152 (76%) eyes of 115 patients had complication during or after the Small Incision cataract surgery. Intra operative bleeding and difficulty in wound closure was found in 136 (68%) and 39 (19.5%) eyes respectively. In post operative period AC reaction was present in 123 (61.5%) eyes, delayed healing in 98 (49%) eyes, hyphema in 96 (48%) eyes, leaky wound in 74 (37%) eyes and keratitis in 68 (34%) eyes. Though the final outcome was not much affected, but the difficulty level to manage the complications and the morbidity duration was more for these patients and challenging for the operating surgeon.

### Discussion

There is definitely a scarcity of population based HCV studies in India. Estimated global prevalence of hepatitis C virus infection is 2-3% which accounts about 122 million to 185 million infected cases

worldwide. [6-11] It is seen that 80% of the patients develop chronicity in acute liver disease caused by HCV. [5] Many studies have been done in past to study the peri-operative complications in different types of major surgeries other than ocular surgery, in patients having chronic liver disease. It has been proved that chronic liver disease has detrimental effects on the surgical outcomes. [12-15] None of the studies have been conducted in the past to ensure the impact of diseased liver due to HCV in small incision cataract surgery (SICS). In this study different sets of challenges were found in majority of cases starting from the conjunctival flap formation till the wound closure, at the completion of the surgery. There might be some coagulation disorder which was hampering the blood clot formation. Anterior chamber reaction on the first post-operative day was seen in a larger number of cases than we routinely observe. This AC reaction might be because of the struggle done to stop the bleed, over instrumentation and more than normal time taken to accomplish the surgery. Reasons for keratitis and leaky wound were also assumed to be the same.

### Limitations

We should have done the liver function test and checked the coagulation profiles of the patients to give more conclusive results of this study. Exact correlation between diseased liver, excessive bleeding and delayed healing can only be made after the complete assessment of Liver Function Test, which has not been considered in our study.

### Conclusion

Cataract surgery in HCV infected patients is associated with a unique set of challenges. Careful pre-operative work-up is mandatory in all the positive cases because propensity for abnormal bleeding and delayed healing cannot be ignored. Preventive measures should be taken prior to cataract surgery like, assessment of coagulation profile and LFT to lower down the intra and post operative risks for complications.

### References

1. Acosta R, Hoffmeister L, Roman R, Comas M, Castells X. Systematic review of population based studies of the prevalence of cataracts. Arch Soc Esp Oftalmol 2006;81:509-16.
2. Mohd Hanafiah K.F., Groeger J., Flaxman A.D., Wiersma S.T. Global epidemiology of hepatitis C virus Infection: new estimates of age-specific



- antibody to HCV seroprevalence. *Hepatology*. 2013;57:1333–42.
3. Puri P, Anand AC, Saraswat VA, Acharya SK, Dhiman RK, Aggarwal R, et al. Consensus statement of HCV task force of the Indian national association for study of the liver (INASL). Part I: Status report of HCV infection in India. *J Clin Exp Hepatol* 2014;4:106-16.
  4. Mukhopadhyaya A. Hepatitis C in India. *J Biosci* 2008;33:465-73.
  5. Kwon YC, Ray RB, Ray R. 2014. Hepatitis C virus infection: establishment of chronicity and liver disease progression. *EXCLI J* 13:977–96.
  6. Shepard C.W., Finelli L., Alter M.J. Global epidemiology of hepatitis C virus infection. *Lancet Infect Dis*. 2005;5:558–67.
  7. Zanetti A. R., Global surveillance and control of hepatitis C. Report of a WHO consultation organized in collaboration with the Viral Hepatitis Prevention Board, Antwerp, Belgium. *J Viral Hepat*. 1999;6:35–47.
  8. Wasley A., Alter M.J. Epidemiology of hepatitis C: geographic differences and temporal trends. *Semin Liver Dis*. 2000;20:1–16.
  9. Sy T., Jamal M.M. Epidemiology of hepatitis C virus (HCV) infection. *Int J Med Sci*. 2006;3:41–46.
  10. Alter M.J. Epidemiology of hepatitis C virus infection. *World J Gastroenterol*. 2007;13:2436–41.
  11. Yen T., Keeffe E.B., Ahmed A. The epidemiology of hepatitis C virus infection. *J Clin Gastroenterol*. 2003;36:47–53.
  12. Friedman L.S. The risk of surgery in patients with liver disease. *Hepatology*. 1999;29:1617–23.
  13. Child C.G., Turcotte J.G. Surgery and portal hypertension. *Major Probl Clin Surg*. 1964;1:1–85.
  14. Durand F., Valla D. Assessment of the prognosis of cirrhosis: Child-Pugh versus MELD. *J Hepatol*. 2005;42(suppl 1):S100–S107.
  15. Malinchoc M., Kamath P.S., Gordon F.D., Peine C.J., Rank J., ter Borg P.C. A model to predict poor survival in patients undergoing transjugular intrahepatic portosystemic shunts. *Hepatology*. 2000; 31:864–71.

**Source of Support: Nil**

**Conflict of Interest: Nil**