

Acetabular fractures –Clinical outcomes of surgical management

K Meenakshi Sundaram^{1*}, K G Kandaswamy², R. Sathish kumar³

¹Associate Professor & Consultant, Department of Orthopaedics & Trauma Care, Vinayaka Mission's Kirupananda Variyar Medical College & Hospitals, NH-47, Sankari Main Road, Veerapandi Post Ariyanoor, Salem, Tamil Nadu, India

²Associate Professor & Consultant, Department of Orthopaedics & Trauma Care, Vinayaka Mission's Kirupananda Variyar Medical College & Hospitals, NH-47, Sankari Main Road, Veerapandi Post Ariyanoor, Salem, Tamil Nadu, India

³Junior Resident, Department of Orthopaedics & Trauma Care, Vinayaka Mission's Kirupananda Variyar Medical College & Hospitals, NH-47, Sankari Main Road, Veerapandi Post Ariyanoor, Salem, Tamil Nadu, India

Received: 02-06-2020 / Revised: 29-07-2020 / Accepted: 12-08-2020

Abstract

Introduction : The fractures of acetabulum concern 2% of fractures and it is difficult to be diagnosed and treated. Improvements in automobile safety, pre-hospital care, resuscitation and transport as well as standardized protocols for treatment have all contributed to improved survival after these devastating injuries. **Materials and methods :** The operative treatment of acetabular fractures was performed in Vinayaka Mission Kirupananda Variyar Medical College and Hospital from July 2010 to July 2019. 32 patients had an open reduction and internal fixation of an acetabular fracture. 25 were males and 7 were females, with an age ranging from 28 to 62 years (average: 36.7 years). The mechanism of injury was a motor vehicle accident in most cases (85%). The fractures were classified with Judet-Letournel classification. The patients were operated upon within 1-8 days (average: 4 days). The Kocher-Langenbeck surgical approach was used in 22 cases and ilioinguinal approach in 10 patients. Osteosynthesis was achieved with either lag screws alone or with a combination of lag screws and a buttress plate. Follow-up ranged from 6 months - 9 years (average: 3.8 years). **Results:** Clinical evaluation according to the D' Aubigne-Postel scoring system gave 23 excellent (71.9%), 6 good (18.8%), 2 fair (6.3%) and 1 poor (3.1%) results. Early postoperative complications included 1 case of unexplained bleeding through drain tube for 8 days and superficial wound infection in another 3 patients. **Conclusion :** Operative treatment of acetabular fractures although demanding, bears very good results.

Keywords: Acetabular fractures, surgical treatment, Judet-Letournel classification.

This is an Open Access article that uses a funding model which does not charge readers or their institutions for access and distributed under the terms of the Creative Commons Attribution License (<http://creativecommons.org/licenses/by/4.0>) and the Budapest Open Access Initiative (<http://www.budapestopenaccessinitiative.org/read>), which permit unrestricted use, distribution, and reproduction in any medium, provided the original work is properly credited.

Introduction

Over the last 20 years orthopaedic trauma surgeons have been facing with a growing number of patients

*Correspondence

Dr. K. Meenakshi Sundaram

Associate Professor & Consultant, Department of Orthopaedics & Trauma Care, Vinayaka Mission's Kirupananda Variyar Medical College & Hospitals, Salem, Tamil Nadu, India.

E-mail: meenakshiortho@gmail.com

with severe pelvic injuries. They are mainly caused by high energy road traffic accidents (90 %) and lead to post traumatic arthritis and avascular necrosis irrelevantly the type of the treatment.

Long-term goals in treating pelvic injuries involve the correction of deformity, prevention of late deformity and instability and restoration of pain-free function. Although there may always be unavoidable consequences of severe pelvic injury, surgeons must still question the way pelvic injuries are treated and

continue to explore controversies that may ultimately alter treatment regimens or outcomes[1-12].

The results of conservative orthopaedic treatment are very disappointing. It is difficult if not impossible, that the articular surface of acetabulum is completely restored or that sufficient stability is ensured which allows early mobilization of hip.

The surgical treatment is also difficult because of,

1. Deep location of the hip
2. The existence of serious neuro-vascular structures near the acetabulum
3. The special anatomy and topography of the hip[18]

Hence for open reduction and internal fixation of acetabular fractures, an appropriate approach and adequate visualization of the fracture lines are essential.

Acetabular fractures, especially displaced ones, constitute serious intra-articular injuries, caused by high-energy trauma and are often accompanied by posterior hip dislocation or other musculoskeletal injuries that may significantly affect the treatment protocol as well as the end-result [6,7,8]. Displacement of the fracture ends by more than 2 mm is known to increase the danger of post-traumatic arthritis and lead to a poor functional outcome. Surgical treatment of displaced acetabular fractures is considered the treatment of choice today, because it ensures the best possible anatomical reconstruction of the joint surface, thus increasing the chances of a satisfactory functional result[6, 8, 11, 15]. A turning point in the treatment of displaced fractures of the acetabulum, the pioneering work of Judet and Letournel that established the surgical treatment as method of choice. Most authors agree that the ideal goal of treatment is anatomic reduction of articular surface with mechanically and biologically sufficient stability that will allow early active mobilization of the joint. These targets can be achieved with the right timing with indicated material of osteosynthesis[8,11, 12, 13].Criteria for conservative management included displacement of the fracture ends by less than 5 mm and retained continuity of the acetabular dome as shown in three x-ray projections with no traction applied and a CT-scan [4,7,8,9, 14]The aim of this study is to present the results of surgical treatment of a series of acetabular fractures, to evaluate the functional outcome, as well as to establish the outcomes of surgical treatment in these fractures.

Materials and methods

Study design – Prospective observational study.

Study period - From July 2010 to July 2019.

Sample size - 32 acetabular fractures (25 males and 7 females) were managed in our hospital surgically. The age range was from 28-62 years, an average of 36.7 years.

Inclusion criteria

- 1) Skeletally mature patients
- 2) Closed acetabular fractures.
- 3) Patients with no co-morbidities.

Exclusion criteria

- 1) Skeletally immature patients
- 2) Compound fractures
- 3) Patients with co-morbidities.

The main cause of injury was road traffic accident (85% of cases). Pre-operative radiologic evaluation constituted of a plain AP view, iliac and obturator oblique view, judet view of the pelvis as well as CT-scan. The indication for surgery was based on the initial evaluation of these radiographs. Other factors that influenced surgical indication were presence of associated injuries and the general condition of the patient. Fractures were classified according to the Judet – Letournel classification⁸ and according to this 14 posterior column fractures (43.75%) 10 both column fractures (31.25%) and 8 anterior column with posterior wall fractures (25%) were included (Table 1). Fractures that were displaced by more than 5 mm with concomitant disruption of the bony continuity of the acetabular dome were treated surgically. Posterior dislocation of the hip was present in 9 patients (28.13%); eight were reduced with immediate closed reduction, one was reduced intra-operatively. Pre-operative skin traction was applied on all patients. Open reduction and internal fixation was performed 1-8 days following the initial injury (mean: 4 days). Kocher-Langenbeck approach was performed in 22 cases and ilioinguinal approach in 10 patients with involvement of anterior column. Before the surgery, patients were examined clinically and radiologically. Simple radiograph and computed tomography was applied for documentation of diagnosis and preoperative planning. The computed tomography with three dimensional technique is essential for a more detailed pre-operative planning (choice of approach, extent of displacement, evaluation of coexistence of loose bodies[13].The main operative goal was to achieve reconstruction of the anatomy of the innominate bone and the articular surface of the acetabulum. 22 patients were performed surgery with Kocher-Langenbeck approach and 10 patients were done with ilioinguinal approach. Fixation of the fracture was achieved with 4.0 mm or 3.5 mm interfragmentary screws combined with a

reconstruction plate in all fracture types. Intra-operative findings included loose intra-articular osteochondral fragments in 13 cases (40.63%), chondral lesion of either the acetabulum or the femoral head in 6 hips (18.75%) and depression of the articular cartilage of the acetabulum in 4 hips (12.5%). Physiotherapy exercises were started from the 1st day of surgery and mobilized to high sitting position with quadriceps training. Following the surgical drain removal, patients were mobilized with non-weight bearing using walker aid for 1 month, partial weight bearing for the following 3 weeks and started full weight bearing from 2 months onwards. Hip abductor and quadriceps strength training was continued through out these 2 months. All patients received low molecular weight heparin thromboprophylaxis for 2 months.

Results

The follow-up schedule was 3, 6 and 12 months post-operatively and subsequently at two years when the operative outcome had been finalized and final evaluation of fracture healing and functional outcome could be performed quite reliably. Post-operative follow-up ranged from 6 months to 5 years with a mean of 3.2 years. Fracture fixation outcome was radiologically evaluated with an AP X-ray of the pelvis from the mean displacement in the basic projection. And patients were functionally evaluated with the D'Aubigne-Postel scoring system¹² (Table- 5) with the parameters: the pain, the motion of the hip and the ability of walking. Fracture reduction and fixation was checked with early post-operative X-rays, while at a later stage X-rays helped in the evaluation of the presence of complications such as osteonecrosis, post-traumatic osteoarthritis and heterotopic ossification.

Based on the radiologic criteria used by Matta⁸ the result was considered excellent when the hip joint had a normal appearance on plain X-rays, good when a small degree of subchondral sclerosis, joint space narrowing and osteophytosis were present, fair when joint space was narrowed up to 50% and considerable osteophytes and subchondral sclerosis were present and poor when the joint space was narrowed by more than 50%, a degree of femoral head collapse as well as clear signs of osteoarthritis were present. Based on the above-mentioned radiologic criteria the result was excellent in 18 patients (56.25%), good in 10 (31.25%), fair in 2 (6.25%) and poor in 2 (6.2%) (Table-3). Clinical assessment was performed according to the D'Aubigne-Postel scoring system, with pain, ability to mobilize and joint mobility being evaluated. According to those criteria our results were excellent (17-18 points) in 23 patients (71.9%), good (15-16 points) in 6 (18.7%), fair (12-14 points) in 2 (6.3%) and poor (<12 points) in 1 (3.1%). (Table-4) Results were evaluated as regards the fracture. In this procedure it was evident that out of the 14 posterior column fractures 12 (85.71%) had an excellent or good result and the remaining 2 (14.28%) a fair or poor. Out of the 10 both column fractures 9 (90%) had an excellent or good result and the remaining 1 (10%) a fair or poor. Out of the 8 anterior column with poster wall fractures all (100%) had an excellent or good result. Immediate complication included uncontrollable bleeding in one patient through the suction drain which lasted for 7 days. There was superficial wound infection in 3 patients which were subsequently healed with appropriate antibiotics and wound care. Sciatic or other nerve paresis was not recorded. Late complications included femoral head osteonecrosis in one patient (Case 5) after 1 year of surgery. He has undergone a total hip replacement.

Table – 1: Judet – Letournel Classification of Fractures

Type	No.	%
Posterior column	14	43.75
Both Column	10	31.25
Anterior column + Posterior wall	8	25
Total	32	

Table - 2 Results as per Judet - Letournel grading of fracture

	Posterior Column	Both Column fracture	Anterior column + Posterior Wall	Total
Excellent + Good	12	9	8	29
Fair + Poor	2	1	0	3
Total	14	10	8	32

Table - 3 RESULTS (Radiological)

Grade	Displacement	No. of patients
Excellent	Anatomic 0 mm	18 (56.25%)
Good	0-1 mm	10 (31.25)%
Fair	2-3mm	2 (6.25%)
Poor	>3 mm	2 (6.25%)

Table - 4 RESULTS (Clinical - D'Aubigne-Postel scoring system)

Excellent (17-18 Points)	23 (71.9%)
Good (15-16 Points)	6 (18.7)%
Fair (12-14 Points)	2 (6.3%)
Poor (<12 Points)	1 (3.1%)

Table - 5 D'Aubigne-Postel evaluation

PAIN	MOVEMENT	WALKING	GRADE
Continuous	Ankylosis – in bad place	Impossible	0
Persistent nightly	Ankylosis - Movement < 40 % – Poor clinically	With crutches	1
Persistent in walking	Movement 50 – 60%, Flexion < 40°	With crutches	2
Permissible pain in walking	Movement 60-70%, Flexion 40° - 60°	With canes	3
Moderate in walking	Movement 70-80%, Flexion 80° - 90°	Good with cane	4
Light periodical	Movement 80° - 90° , Flexion 85° - 90°, Abduction 25°	Free without cane	5
Absent	Movement 80° - 90°, Flexion 90°	Physiologic	6

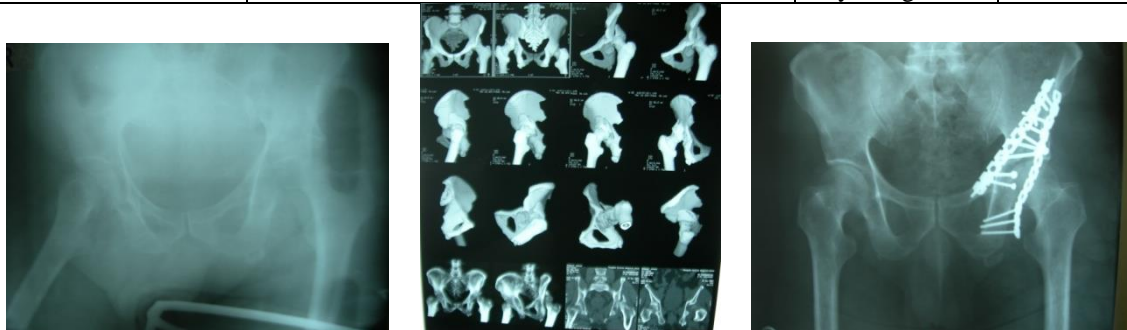


Fig 1:Representation of Case 1

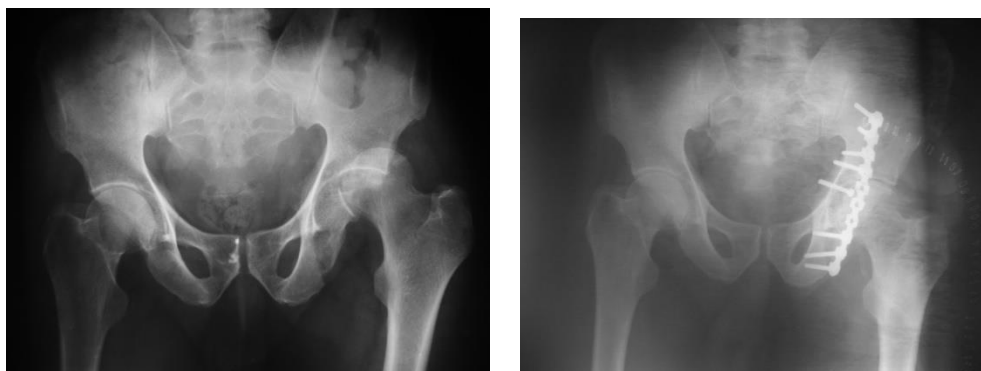

Fig 2: Representation of Case 2

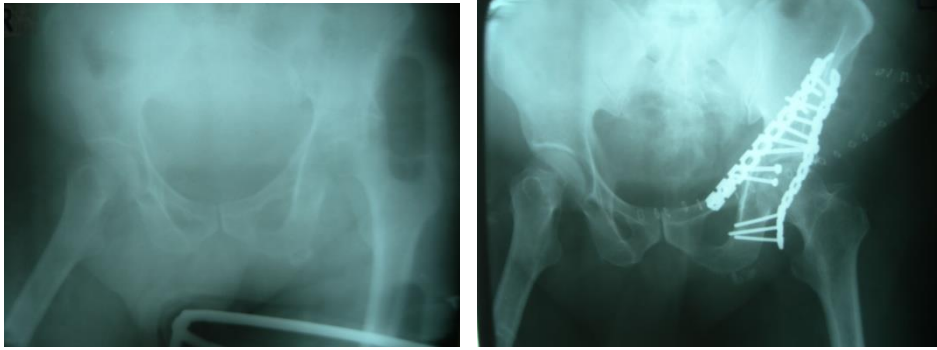


Fig 3: Representation of Case 3

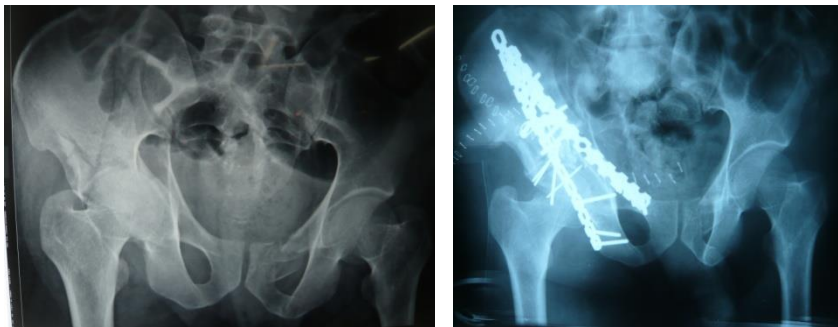

Fig 4: Representation of Case 4

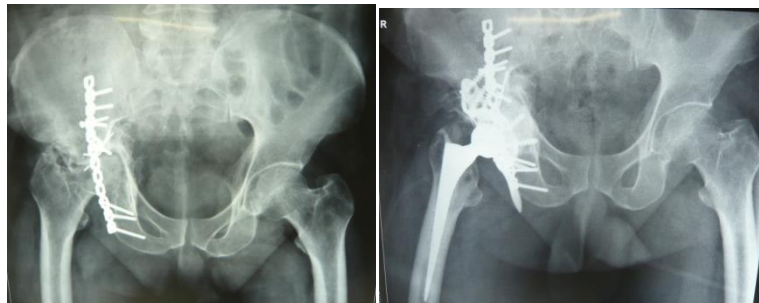

Fig 5: Representation of Case 5

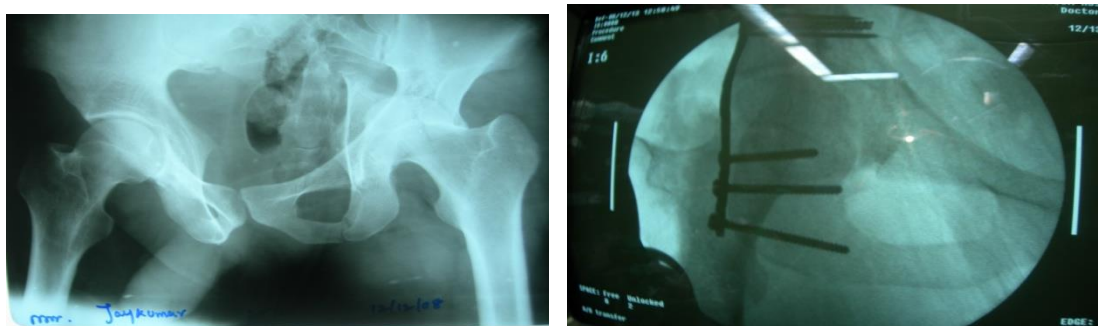


Fig 6:Representation of Case 6

Discussion

Surgical treatment of displaced acetabular fractures is beyond any doubt the treatment of choice, because it gives the better chances for anatomical reconstruction of the joint[6, 7, 8, 10, 15]. The goals of surgical treatment are the correction of significant deformity, prevention of late deformity and instability, and restoration of pain-free function[5, 7, 8, 13]. By far the commonest complication of these fractures is post-traumatic osteoarthritis of the hip, which often leads to a total hip replacement[5, 7, 8]. Other less frequent complications are osteonecrosis of the femoral head, osseous defects of the acetabulum, shortening of the affected limb and heterotopic ossification[1,3, 5,6,7,8,16] The main criterion for surgical management is the degree of displacement of the fracture ends of the acetabulum. In our series the criterion used for surgical management was a fracture displacement of more than 5mm. This was the criterion suggested by Matta⁸ and Johnson et al[4]. Patients in our series were operated upon between the 1st and 8th day following the initial injury, with a mean of 4 days. Delay of operative management was usually the case in polytrauma patients with various other injuries that were in ICU for prolonged periods of time. Most authors prefer to place the patient in a prone position for the approach of such fractures[6,8,10]. We feel that the approach and positioning we used, allow for adequate exposure for the fixation of the fractures of the posterior column of the acetabulum, which are the commonest fracture pattern. The goal of operative management was anatomic reduction of the fracture and subsequent stable internal fixation, with combination of interfragmentary screws and a reconstruction plate. Anatomic reduction was achieved in 18 (56.25%) of cases, which is considered to be very satisfactory[8,9,10,15]. The post-operative application of skeletal traction is a contentious issue and most authors nowadays suggest that it should not be used provided that the internal fixation achieved is rigid enough[7-9]. We have not used skeletal traction post-operatively in all our patients, which in turn would prolong their rehabilitation time and we feel that implementation of post-operative skeletal traction can be totally abolished in cases where internal fixation is stable enough. Our results were evaluated on the basis of both clinical and radiologic criteria, as well as according to fracture type[8,10,13]. Radiologic evaluation showed 88.5% of excellent or good results and 12.5% of fair or poor results, while clinical evaluation showed 90.6% of excellent or good results and 9.4% of fair or poor results. An analogy between

clinical and radiologic results was recorded in our cases, a fact supported by the literature as well^{7,8,13}. The rate of excellent and good results in our series 90.6% is considered very satisfactory. Similar results have been reported by Letournel and Matta[10,12,13,14]. If results were associated with the fracture type it was clear that simple fractures gave a better outcome than complex fractures, as expected, because in simple fractures anatomic reduction was achieved more often. Heterotopic ossification was not seen in our series of patients. The rates of heterotopic ossification reported by various authors in series of acetabular fractures surpass 50% in some series [2,3,5,8,15,17] Matta[12] in a series of 262 patients where no prophylaxis against heterotopic ossification was administered reports a rate of heterotopic ossification as high as 82%. We administered indomethacin to all of our patients and we believe it has drastically lowered the rate of heterotopic ossification. Indomethacin is believed to decrease the rate of this complication to about 30-45%. Femoral head osteonecrosis was recorded in one patient who subsequently underwent a total hip replacement. Matta reports a rate of femoral head osteonecrosis of 3%, while Moroni[33] brings it up to 7%[14] Post-traumatic osteoarthritis was recorded in 1 patient (5%) who underwent a total hip replacement. This rate of post-traumatic osteoarthritis is considered quite satisfactory, in view of the fact that rates of 20-55% are reported in the literature[4,7,8,10,13,16] The presence of posterior dislocation of the hip, a chondral lesion of the femoral head or the acetabulum, failure to obtain anatomical reduction and complex as opposed to simple fractures are thought to be the main predisposing factors for the advent of post-traumatic osteoarthritis and femoral head osteonecrosis.

Conclusion

In conclusion, we believe that surgical treatment of acetabular fractures leads to a satisfactory outcome, provided the operation is carried out by an experienced surgeon within the first few days following the initial injury and when anatomic reduction of the fracture is achieved.

References

1. Benum P. Fractures of The Acetabulum. Effort-European Federation of National Associations of Orthopaedics and Traumatology. 1995; 2 :98-109.

2. Bosse J.M., Reinert M., Ellwanger F., Slawson R., Mc Devitt. Heterotopic Ossification as a Complication of Acetabular Fracture. *J Bone and Joint Surg.* 1988; 70-A8:1231-1237.
3. Bray J.T., Esser M., Fulkerson L. Osteotomy of the Trochader in Open Reduction and Internal Fixation of Acetabular Fractures. *J Bone and Joint Surg.* 1987; 69-A5:711-717.
4. Brooker A., Bowerman J., Robinson R., Riley L. Ectopic Ossification Following Total Hip Replacement. *J Bone and Joint Surg.* 1973; 55-A: 1629.
5. Chip Routt L.M., Swionkowski F.M. Operative Treatment of Complex Acetabular Fractures. *J Bone and Joint Surg.* 1990; 72-A6:897-904
6. Deo D.S., Tavares R.K., Pandley K.R., EL-Saied G., Willett M.K., Worlock H.P. Operative management of acetabular fractures in Oxford. *Injury Int J Care Injured.* 2001; 12:581-586.
7. Goulet A.J, Bray J.I. Complex Acetabular Fractures. *Clin Orthop and Rel Res.* 1989; 240:9-20.
8. Judet T., Judet J., Letournel E. Fractures of the Acetabulum: Classification and surgical approaches for open reduction. *J Bone Joint Surg.* 1964; 46-A:1615.
9. Kaempfe F.A., Bone L.B., Border J.R. Open reduction and internal fixation at acetabular fractures heterotopic ossification and other complications. *J Orthop Trauma.* 1991; 5: 439
10. Letournel E. Acetabular Fractures. Classification and Management. *Clin Orthop.* 1980; 151: 81.
11. Matta M.J. Fractures of the Acetabulum: Accuracy of Reduction and Clinical Results in Patients Managed Operatively within Three Weeks after the Injury. *J Bone and Joint Surg.* 1996; 78-A(11): 1632-1645.
12. Matta M.J., Mehne K.D., Roffi R. Fractures of the Acetabulum. *Clin Orthop and Rel Res.* 1986; 205: 241-250.
13. Matta M.J., Anderson M.L., Epstein C.H., Hendrics P. Fractures of the Acetabulum. *Clin Orthop and Rel Res.* 1986; 205:230-240.
14. Moroni A., Caja L.V., Sabato C., Zinghi G. Surgical treatment of both - column fractures by staged combined ilioinguinal and Kocher - Langenbeck approaches. *Injury.* 1995; 26(4): 219-224.
15. Pantazopoulos T., Mousafiris. Surgical Treatment of Central Acetabular Fractures. *Clin Orthop and Rel Res.* 1989; 246: 57-64.
16. Panatazopoulos T.H., Nicolopoulos S.C. Moussafiris C. Surgical treatment of acetabular posterior wall fractures. *Acta Orthop Hell.* 1989; 40:87-95.
17. Bray J.T., Esser M., Fulkerson L. Osteotomy of the Trochader in Open Reduction and Internal Fixation of Acetabular Fractures. *J Bone and Joint Surg.* 1987; 69-A5: 711-717.
18. Deo D.S., Tavares R.K., Pandley K.R., EL-Saied G., Willett M.K., Worlock H.P. Operative management of acetabular fractures in Oxford. *Injury Int J Care Injured.* 2001; 12: 581-586.

Source of Support: Nil

Conflict of Interest: Nil