



THE AGA KHAN UNIVERSITY

eCommons@AKU

---

Department of Radiology

Medical College, Pakistan

---

11-2003

## Situs ambiguous

Saba Sohail

Mukhtiar Ahmed Memon

Allah Rakhiyo

Follow this and additional works at: [https://ecommons.aku.edu/pakistan\\_fhs\\_mc\\_radiol](https://ecommons.aku.edu/pakistan_fhs_mc_radiol)



Part of the [Cardiology Commons](#), and the [Radiology Commons](#)

---

## CASE REPORT

# SITUS AMBIGUOUS

Saba Sohail, Mukhtiar Ahmed Memon and Allah Rakhiyo

**ABSTRACT:** The case of a female child is described who presented with recurrent respiratory infections and "recurrent right subphrenic abscess." Detailed radiological work-up identified situs ambiguous abdominis with bronchiectasis, duodenal malrotation, umbilical hernia and spina bifida.

**KEY WORDS:** *Bronchiectasis. Duodenal malrotation. Isolated heterotaxy. Respiratory infections. Situs ambiguous abdominis. Subphrenic abscess. Umbilical hernia.*

## INTRODUCTION

Situs inversus is a rare condition with a frequency of 0.01%.<sup>1</sup> Situs inversus abdominis is a still rarer anomaly comprising a right-sided stomach and liver with left-sided cardiac apex. Its exact incidence is not known as only sporadic cases are reported in literature.<sup>2,3</sup> We are presenting a case of situs ambiguous that defied diagnosis until a targeted radiological work-up was done.

## CASE REPORT

A 10 years old girl child was referred from the pediatric outpatient department with history of fever, productive cough and dyspnoea for 15 days. She had multiple episodes of respiratory infections since early childhood and was repeatedly treated for right subphrenic abscess according to accompanying medical record. She was born of a consanguineous marriage and numbered third in 7 offspring. On examination, she had short stature and weighed only 23 kg at the age of 10 years. There was a small umbilical hernia since birth. Laboratory workup showed raised E.S.R., leukocytosis with neutrophilia and mild anemia (hemoglobin=9.7 GM %).

An erect x-ray chest in postero-anterior projection re-demonstrated an air-fluid level in the right subdiaphragmatic region as on previous x-rays. There were multiple small cavities at the lung bases bilaterally. The cardiac size and contour was normal with a left-sided aortic arch and cardiac apex. The fundal gas shadow and the spleen were not seen on the left side (Figure 1). Complimentary ultrasound of whole abdomen and barium meal examination was carried out. The barium examination showed a right-sided stomach and reverse sweep of duodenum without obstruction. Non-fusion of the bony arch of first sacral piece was also noted which was consistent with spina bifida (Figure 2). Ultrasound examination showed the stomach and spleen to be interposed between the liver and the right kidney. The liver, gall bladder and inferior vena cava were on the right side. Pancreas was normally located. No other spleen was found in the whole of abdomen (Figure 3).

Her other 6 siblings were reported to be in good health.

.....  
Department of Radiology, DMC and Civil Hospital, Karachi.

**Correspondence:** Dr. Saba Sohail, 131/1-O, Block II, P.E.C.H.S., Karachi-75400, Pakistan.

Received September 18, 2003; October 14, 2003.

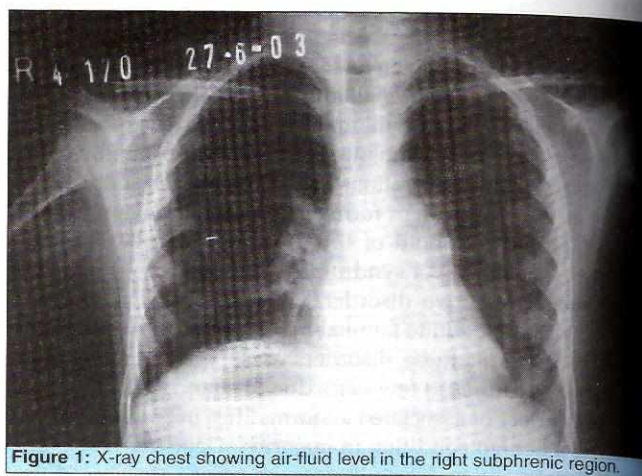


Figure 1: X-ray chest showing air-fluid level in the right subphrenic region.

Despite primary physician's and our combined counseling and persuasion, the parents refused further work-up offered, due to apprehension. The child was lost to follow-up after the treatment of presenting episode of respiratory infection.

## DISCUSSION

The term situs refers to spatial orientation of viscera. It is usually used in the context of cardiac and visceral connections.<sup>4</sup> A myriad of variations is described. Situs solitus is the normal condition of a left-sided heart, left sided aorta, atrioventricular and bronchial concordance along with right-sided liver, gallbladder and an uninterrupted inferior vena cava.<sup>4</sup> Abnormalities include situs inversus (a mirror image relative to the situs solitus,<sup>4,5</sup> heterotaxy syndromes (a variety of asplenia and polysplenia syndromes associated with variable viscerocardiac concordance and discordance), and isolated heterotaxy. The last is an asymptomatic condition

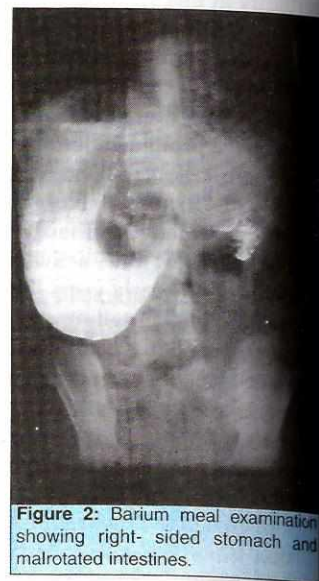

Figure 2: Barium meal examination showing right-sided stomach and malrotated intestines.

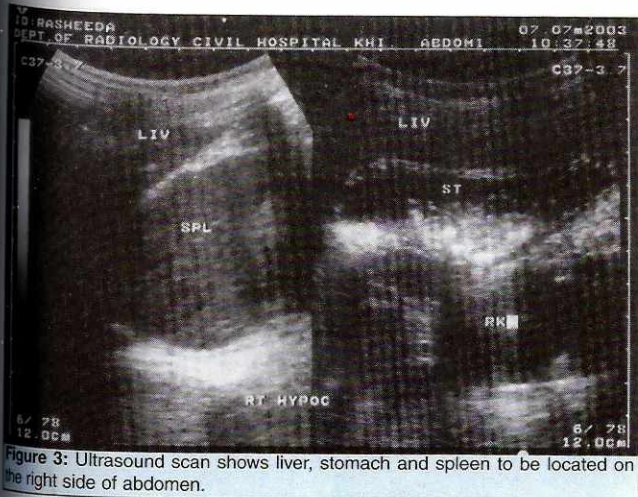


Figure 3: Ultrasound scan shows liver, stomach and spleen to be located on the right side of abdomen.

where only the stomach is left sided and no other abnormality is detected. The others are an abnormal arrangement of organs and vessels as opposed to the orderly arrangement typical of situs solitus and inversus.<sup>5</sup>

However, the patient under discussion was different in having an ectopic but not accessory spleen. Bronchiectatic changes might have been a result of either repeated pulmonary infections as or be part of the spectrum of the immotile cilia syndrome. This is a group of genetic disorders caused by deficiency in diene arms impairing ciliary moment by leading to sino-pulmonary infections, situs inversus and sub-fertility.<sup>7-9</sup> As regards situs inversus and ambiguous, an exhaustive list of associated cardiovascular, spleno-pancreatic, urinary, genital, pulmonary and skeletal abnormalities have been described.<sup>1,4</sup> Those having specific association with situs inversus abdominis include tracheoesophageal fistula, intestinal malrotation, duodenal webs and internal hernias.<sup>3,4</sup> The patient under discussion showed intestinal malrotation, umbilical hernia and spina bifida. None was symptomatic.

The basic differentials of the above described plain x-ray of chest include a right subphrenic abscess, infected hepatic cyst and Chiladitti syndrome.<sup>4,10</sup> The condition is verified on an upper gastrointestinal barium series, noting the mucosal pat-

tern of the gas-filled viscus and of course the ultrasound of upper abdomen. Further work-up should include identification of VATERS (vertebral, anorectal, tracheoesophageal, renal and skeletal) anomalies. Levocardia may be congenital in 56%.<sup>1</sup> This may well be the case in our rather underinvestigated patient who was lost to follow-up due to parental apprehension. This behavior on the part of parents emphasizes the need for adult co-operation in the management of these patients. Regarding prenatal diagnosis, mild fetal ventriculomegaly is described as a positive predictive sign of Kartagener's syndrome and Situs inversus.<sup>10</sup>

## REFERENCES

1. Dahnert W. Radiology review manual. 5th ed. Philadelphia, Lippincott, Williams and Wilkins; 2003: 581-2.
2. Shenoy VG, Jawala SA, Oak SN, Kulkarni BX. Esophageal atresia with tracheoesophageal fistula associated with situs inversus. *Pediatric Surg Int* 2001; **17**: 538-9.
3. Iuchtman M, Golan Y, Heldenberg D, Kessler FB. Situs inversus abdominis in association with duodenal obstruction and inguinal hernia. *Am J Perinatal* 1993; **10**: 255-7.
4. Grainger RG. Congenital heart disease: general principles. In: Grainger and Allison's Diagnostic Radiology. 3rd ed. New York: Churchill Livingstone 1997, 668.
5. Walter MA, Burger P, Pfisterer M, Muller-Brand J, Zellweger M. Situs inversus completus: *Eur J Nucl Mol Imag*; 2003; **30**: 1202.
6. Gelfand WD. The stomach. In Grainger and Allison's Diagnostic Radiology. 3rd ed. New York: Churchill Livingstone, 1997, 961.
7. Meyers MA. Diagnostic radiology of the abdomen. 3rd ed. New York: Springer-Verlag 1991, 466-7.
8. Bankwalla A, Kazi M, Kanjee A. Atopic dermatitis in a patient with Kartagener's Syndrome. *J Pak Assoc Derm*; 2001; **11**: 64-8.
9. Ahmed J, Choudri AN. Situs inversus: uncommon condition, two case reports. *J Baqai Med Univ* 2001; (1-2): 50-1.
10. Wessels MW, Den Hollander NS, Willens PJ. Mild fetal cerebral ventriculomegaly as prenatal marker for Kartagener's syndrome. *Prenat Diag* 2003; **23**: 239-42.

