



THE AGA KHAN UNIVERSITY

eCommons@AKU

Section of Neurosurgery

Department of Surgery

8-8-2020

Arteriovenous malformation with associated multiple flow-related distal anterior cerebral artery aneurysms: A case report with poor outcomes

Ummey Hani

Muhammad Ehsan Bari

Syed Sarmad Bukhari

Follow this and additional works at: https://ecommons.aku.edu/pakistan_fhs_mc_surg_neurosurg



Part of the [Neurology Commons](#), [Neurosurgery Commons](#), and the [Surgery Commons](#)



Case Report

Arteriovenous malformation with associated multiple flow-related distal anterior cerebral artery aneurysms: A case report with poor outcomes

Ummey Hani¹, Muhammad Ehsan Bari², Syed Sarmad Bukhari²

¹Sindh Medical College, Jinnah Sindh Medical University, ²Department of Neurosurgery, Aga Khan University Hospital, Karachi, Sindh, Pakistan.

E-mail: Ummey Hani - hanitariq96@hotmail.com; Muhammad Ehsan Bari - ehsan.bari@aku.edu; Syed Sarmad Bukhari - sarmad.bukhari@aku.edu



*Corresponding author:

Dr. Muhammad Ehsan Bari,
Department of Neurosurgery
Aga Khan University Hospital,
Karachi, Sindh, Pakistan.

ehsan.bari@aku.edu

Received : 21 January 2020

Accepted : 06 July 2020

Published : 08 August 2020

DOI

10.25259/SNI_27_2019

Quick Response Code:



ABSTRACT

Background: Low-grade arteriovenous malformations (AVMs) associated with multiple flow-related distal anterior cerebral artery (DACA) aneurysms are rare occurrences. Here, we present a case of a frontal AVM with three associated DACA aneurysms arising from a single feeder.

Case Description: A 36-year-old male presented to us in the ER with acute-onset dysphasia and altered mental status. Head computed tomography and angiogram showed a spontaneous intracerebral hemorrhage with intraventricular extension and revealed a Spetzler Martin Grade II AVM, being fed by two feeders, with the major feeder from the DACA bearing three flow-related aneurysms. As the patient awaited digital subtraction angiography, his Glasgow Coma Scale dropped and he underwent emergency embolization with Onyx. This was followed by external ventricular drainage. The patient's neurological status did not improve, and he died following a complicated clinical course.

Conclusion: Multiple DACA aneurysms are a case of both clinical and anatomical rarity and to avoid complications in the clinical course, one must be judicious about the time spent between symptom onset and embolization.

Keywords: Embolization, Intracranial aneurysm, Intracranial arteriovenous malformation

INTRODUCTION

Flow-related aneurysms in the region of distal anterior cerebral artery (DACA) are a rare occurrence, accounting for 9% of the total intracranial aneurysms with multiple aneurysms on the same vessel are rarer.^[4] DACA aneurysms are known to have a poor clinical course and greater morbidity and mortality in contrast to other intracranial aneurysms.^[10] We present an unusual case of a low-grade arteriovenous malformation (AVM) with three associated DACA aneurysms arising from a single feeder to an AVM from the left callosomarginal artery.

CASE PRESENTATION

A 36-year-old male with no known comorbidities presented to the emergency room with the complaints of sudden onset aphasia, persistent vomiting, and bilateral lower limb weakness for

This is an open-access article distributed under the terms of the Creative Commons Attribution-Non Commercial-Share Alike 4.0 License, which allows others to remix, tweak, and build upon the work non-commercially, as long as the author is credited and the new creations are licensed under the identical terms.

©2020 Published by Scientific Scholar on behalf of Surgical Neurology International

the past 1 day. On examination, he had a Glasgow Coma Scale (GCS) of 11/15 (E3V2M6). His proximal and distal lower limb powers were 3/5. Rest of the examination was unremarkable. His history was significant for an episode of seizure 1 month back, with symptoms of altered mental state during the fit that resolved spontaneously within a few minutes. Computed tomography (CT) angiogram [Figure 1] revealed a compact AVM in the left frontal lobe, three aneurysms in the DACA distribution, intraventricular hemorrhage involving the 3rd and 4th ventricles, venous drainage to large vein draining the superior sagittal sinus, and poor vascular blush in the territory of the left ACA, suggestive of an infarct. He was admitted to a high dependency unit for observation.

The patient was awaiting digital subtraction angiography for almost 2 days when his GCS suddenly dropped to 5/15, with pupils bilaterally equal, dilated, and nonreactive. He underwent emergency intubation and was shifted to the intensive care unit (ICU). Head CT without contrast and CT angiogram revealed redemonstration of subarachnoid hemorrhage from the proximal largest aneurysm with intraventricular extension predominantly along the corpus callosum, with effaced basal cisterns and an interval increase in both hydrocephalus and cerebral edema [Figure 2]. The patient was shifted to interventional radiology suite for emergency coiling of the aneurysm and subsequent insertion of an external ventricular drain (EVD) for secondary hydrocephalus in the space of the next 5 h following decreased consciousness. The decision to prioritize coiling over EVD placement was influenced by the risk of repeat hemorrhage from suddenly decompressing the ventricles.

Angiography revealed a Spetzler-Martin Grade 2 AVM, being fed by two vessels, and draining into the superior sagittal sinus through the superficial cortical veins. The major feeder arose from left callosomarginal artery and a minor feeder from the left MCA. The nidus measured 18 × 14 mm in diameter. The angiogram also revealed multiple flow aneurysms on the feeder from left callosomarginal artery, with the largest aneurysm, 14 × 8 mm in size, at the callosomarginal bifurcation. Pericallosal artery, with a relatively sluggish blood flow, was seen arising from its neck, because of which this aneurysm was not embolized. The nidus and rest of the flow aneurysms were embolized using the onyx [Figure 3a and b].

The immediate postprocedural period was uneventful and uncomplicated. The patient, nevertheless, did not regain consciousness and was shifted to the ICU on controlled mechanical ventilation for further management and observation. Postoperative angiogram did not reveal any significant spasm. However, the patient's neurological status did not improve, and he died in the hospital following a complicated clinical course.

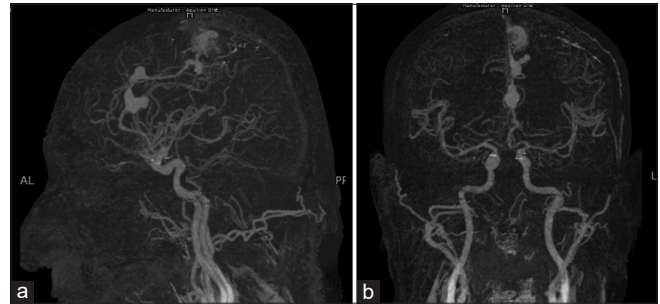

Figure 1: Head computed tomography angiogram at the time of presentation revealing a compact arteriovenous malformation in the left frontal lobe and three aneurysms in the distal anterior cerebral artery region. (a) Sagittal view, (b) coronal view.

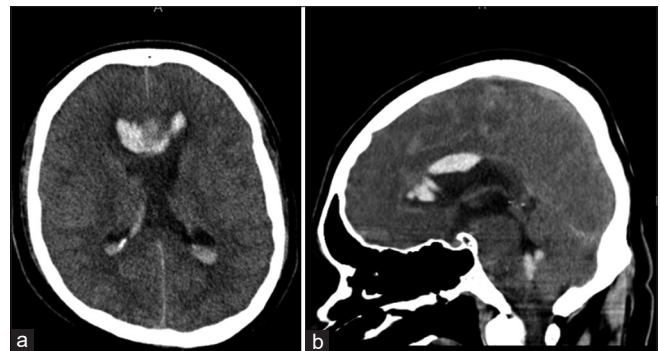


Figure 2: Head computed tomography without contrast showing redemonstrations of subarachnoid hemorrhage from the proximal largest aneurysm, effaced basal cisterns and an interval increase in both hydrocephalus and cerebral edema. (a) Axial view, (b) sagittal view.

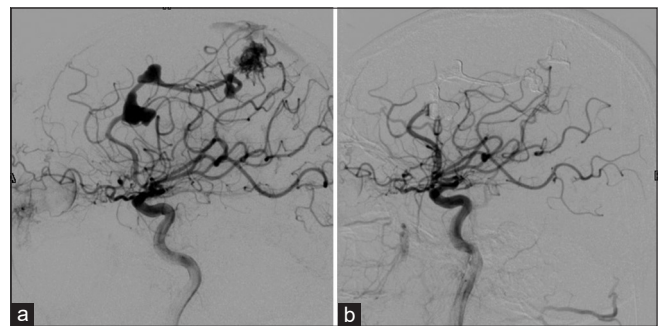

Figure 3: Digital subtraction angiogram before (a) and after (b) embolization of the malformation.

DISCUSSION

DACA aneurysms are usually associated with anterior cerebral artery anomalies and coexist with unrelated multiple aneurysms at different locations.^[6] However, the occurrence of multiple saccular aneurysms and a low-grade AVM in the distribution of DACA has not been reported yet. A study by Sekerci *et al.* in 2011 showed that majority of DACA aneurysms were saccular, with 90% of them appearing at the

pericallosal-callosomarginal artery bifurcation and 40% of the time occurring with multiple aneurysms at other sites of the cerebral circulation.^[10] Kozyrev *et al.* reported a case of three flow-related aneurysms occurring in A3, A4, and A5 segments of the parent left DACA, a rare occurrence, like ours, in their hospital's database of 600 patients with DACA aneurysms.^[4]

DACA aneurysms have an anatomic index that makes them difficult to occlude and hence, results in adverse outcomes. These aneurysms have broad bases and wide necks with originating branches. The small caliber of the parent artery, distal location of the aneurysm resulting in lack of anatomic landmarks, and a very small size^[6,8] make them poor endovascular targets. Hung *et al.* reported that only 13% of patients with AVMs at their center presented with flow-related aneurysms that were usually located in the posterior fossa and presented at increased age.^[3] They also reported greater rates of SAH at presentation in patients with flow-related aneurysms, akin to a study by Sekerci *et al.* in 2011.^[10] In another study by Platz *et al.*, a greater association with hemorrhage at presentation (61%), and thus, poor outcomes, was reported in patients with AVM-associated aneurysms.^[9] ICH is more frequent with DACA aneurysms ranging from 17% to 73% compared with those aneurysms in other locations.^[8] Wisoff and Flamm noted that patients with good grade did not have ICH, while ICH and clinically significant vasospasm were observed in patients with high-grade AVMs.^[14] Orz reported 20% of his patients to have unfavorable outcomes due to infarction in the DACA territories, with other risk factors including ICH and rebleeding before treatment.^[8]

Bleeding at presentation and rebleeding before and/or after intervention are associated with poor prognosis. Lee *et al.* reported the risk factors of spontaneous hemorrhage and rebleeding before treatment. These included AVMs with hemorrhage at initial presentation, deep venous drainage, and/or by a single draining vein, AVMs smaller than 2 cm in size, and coexisting aneurysms. Smaller AVMs are high risk for bleeding because of associated increased intra-arterial pressure.^[5] A prospective analysis by Signorelli *et al.* also reported rebleeding, both before and after intervention, resulting in poor outcomes. In their study, out of the four patients whose AVM bled before intervention, three developed new-onset neurological deficits, with one dying after 2 months secondary to rebleed.^[11] In their prospective study, Vergouwen *et al.* noted that many patients scheduled for late aneurysm treatment rebled while awaiting treatment, while earlier aneurysm treatment resulted better outcomes.^[13]

The endovascular management of AVMs and aneurysms has its own set of complications which need to be reviewed carefully in the context of each lesion's unique anatomy. Li *et al.* described acute rerupture after coil embolization

as rerupture within 3 days after treatment, resulting in the worst prognoses.^[7] Incomplete occlusion of the initial aneurysm was a major factor in acute rebleed. Other risk factors included the presence of a hematoma adjacent to a ruptured aneurysm, aneurysmal outpouchings, and poor Hunt-Hess grade at the time of treatment, and the location of the aneurysm in an anterior communicating artery.^[7] In another retrospective analysis, Platz *et al.* noted that 37% of the patients at his center developed significant recurrence of treated aneurysms secondary to partial obliteration of the AVM.^[9]

In 2014, Platz *et al.* reported lower complication rates in AVMs treated by occlusion through surgery or liquid embolization agents, over coiling.^[9] Lately, because of its low precipitation rate and nonadhesive properties, Onyx is being considered a breakthrough embolic agent for the embolization of AVMs. However, in 2015, Crowley *et al.* reported unexpected postprocedural morbidity and mortality in 8.6% of the 105 patients undergoing embolization with Onyx at their center. Oddly, he also reported no significant differences of outcome following embolization of a higher Spetzler Martin Grade AVM with Onyx or embolizing with another technique.^[1] Comparable to this, in Van Rooij *et al.*'s list of factors that resulted in successful embolization with Onyx, small- and medium-sized AVMs of 1–3 cm in size were a major influence. Other factors of success included being fed by vessels from a single vascular territory, not being located in brainstem or deep structures, and readily accessible arterial feeders using microcatheters.^[12] In 2016, de Castro-Afonso *et al.*^[2] reported a complication rate of 13% in their study cohort, where intracranial hemorrhage topped the list. They contributed these complications to situations including the premature occlusion of draining vein, high volume of Onyx injected, and microwire perforation during AVM catheterization or at the end of embolization by an arterial tear caused by catheter retrieval.^[14]

CONCLUSION

The natural history of these lesions is rupture and rebleed if untreated. Their treatment is fraught with difficulties due to the management of two complex vascular pathologies. DACA aneurysms tend to be small with broader bases making them difficult to approach endovascularly. Their management should be expedient.

Declaration of patient consent

Patient's consent not required as patients identity is not disclosed or compromised.

Financial support and sponsorship

Nil.

Conflicts of interest

There are no conflicts of interest.

REFERENCES

- Crowley RW, Ducruet AF, Kalani MY, Kim LJ, Albuquerque FC, McDougall CG. Neurological morbidity and mortality associated with the endovascular treatment of cerebral arteriovenous malformations before and during the Onyx era. *J Neurosurg* 2015;122:1492-7.
- de Castro-Afonso LH, Nakiri GS, Oliveira RS, Santos MV, Dos Santos AC, Machado HR, *et al.* Curative embolization of pediatric intracranial arteriovenous malformations using Onyx: The role of new embolization techniques on patient outcomes. *Neuroradiology* 2016;58:585-94.
- Hung AL, Yang W, Jiang B, Garzon-Muvdi T, Caplan JM, Colby GP, *et al.* The effect of flow-related aneurysms on hemorrhagic risk of intracranial arteriovenous malformations. *Neurosurgery* 2019;85:466-75.
- Kozyrev DA, Jahromi BR, Thiarawat P, Choque-Velasquez J, Ludtka C, Goehre F, *et al.* Three distal anterior cerebral artery aneurysms in the same branch associated with five additional intracranial aneurysms. *Surg Neurol Int* 2017;8:62.
- Lee KW, Lin YC, Lo CP, Liu CC. Intracerebral hemorrhage following endovascular embolization of brain arteriovenous malformation with a combination of Onyx and n-butyl cyanoacrylate: A case report. *Clin Imaging* 2012;36:375-8.
- Lehecka M, Porras M, Dashti R, Niemelä M, Hernesniemi JA. Anatomic features of distal anterior cerebral artery aneurysms: A detailed angiographic analysis of 101 patients. *Neurosurgery* 2008;63:219-28; discussion 228-9.
- Li K, Guo Y, Zhao Y, Xu B, Xu K, Yu J. Acute rerupture after coil embolization of ruptured intracranial saccular aneurysms: A literature review. *Interv Neuroradiol* 2018;24:117-24.
- Orz Y. Surgical strategies and outcomes for distal anterior cerebral arteries aneurysms. *Asian J Neurosurg* 2011;6:13-7.
- Platz J, Berkefeld J, Singer OC, Wolff R, Seifert V, Konczalla J, *et al.* Frequency, risk of hemorrhage and treatment considerations for cerebral arteriovenous malformations with associated aneurysms. *Acta Neurochir (Wien)* 2014;156:2025-34.
- Şekerci Z, Şanlı M, Ergün R, Oral N. Aneurysms of the distal anterior cerebral artery: A clinical series. *Neurol Neurochir Pol* 2011;45:115-20.
- Signorelli F, Gory B, Pelissou-Guyotat I, Guyotat J, Riva R, Dailler F, *et al.* Ruptured brain arteriovenous malformations associated with aneurysms: Safety and efficacy of selective embolization in the acute phase of hemorrhage. *Neuroradiology* 2014;56:763-9.
- Van Rooij WJ, Jacobs S, Sluzewski M, Van der Pol B, Beute GN, Sprengers ME. Curative embolization of brain arteriovenous malformations with onyx: Patient selection, embolization technique, and results. *AJNR Am J Neuroradiol* 2012;33:1299-304.
- Vergouwen MD, Jong-Tjien-Fa AV, Algra A, Rinkel GJ. Time trends in causes of death after aneurysmal subarachnoid hemorrhage: A hospital-based study. *Neurology* 2016;86:59-63.
- Wisoff JH, Flamm ES. Aneurysms of the distal anterior cerebral artery and associated vascular anomalies. *Neurosurgery* 1987;20:735-41.

How to cite this article: Hani U, Bari ME, Bukhari SS. Arteriovenous malformation with associated multiple flow-related distal anterior cerebral artery aneurysms: A case report with poor outcomes. *Surg Neurol Int* 2020;11:232.