

This is a non-final version of an article published in final form in “James, A., von Oertzen, T. J., Norbury, R., Huppertz, H. J., & Brandt, K. R. (2018). Left entorhinal cortex and object recognition. *Neuroreport*, 29(5), 363-367.”

THIS DIFFERS FROM THE FINAL PUBLISHED ARTICLE, SO PLEASE REFER TO THAT ONE IF YOU WISH TO CITE THIS PAPER.

Neuroreport can be accessed online via this website address:

<https://journals.lww.com/neuroreport/>

This is the final peer-reviewed manuscript, embargoed until 21st March 2019.

Left entorhinal cortex and object recognition (*Running Head*)

Adele **James**^a

Tim J. **von Oertzen**^{b, c}

Ray **Norbury**^a

Hans-Juergen **Huppertz**^d

Karen R. **Brandt**^a

^a Department of Psychology, Whitelands College, University of Roehampton, London, SW15
4JD, United Kingdom

^b Atkinson Morley Neuroscience Centre, St. George's Hospital, London, United Kingdom

^c Department of Neurology 1, Neuromed Campus, Kepler Universitaetsklinikum, Linz,
Austria

^d Swiss Epilepsy Centre, Klinik Lengg, Zuerich, Switzerland

Correspondence address Adele James, Department of Psychology, Whitelands College,
University of Roehampton, London, SW15 4JD, United Kingdom, adele_roe@outlook.com

Conflicts of interest - none declared.

Funding – The present research was supported by a grant from the University of Roehampton and the authors wish to thank the University for supporting their work. The funding source had no involvement in the preparation and submission of this article.

Text body – 16,555 characters (including spaces)

The present research explored the role of the medial temporal lobes in object memory in unique patient MR, who has a selective lesion to her left lateral entorhinal cortex. Two experiments explored recognition memory for object identity and object location in MR and matched Controls. The results showed that MR had intact performance in an object location task ($MR = .70$, Controls = .69, $t(6) = .06$, $p > .05$), but was impaired in an object identity task ($MR = .62$, Controls = .84, $t(6) = -4.12$, $p < .05$). No differences in correct recollection or familiarity emerged. These results suggest a differential role of the entorhinal cortex in object recognition memory. The current research is therefore the first patient study to demonstrate the role of the lateral entorhinal cortex in object identity recognition and suggests that current medial temporal lobe theoretical models concerning both object and recognition memory need a theoretical rethink to account for the contributions of the entorhinal cortex in these processes.

Keywords: entorhinal cortex, recollection, familiarity, object recognition, memory

Introduction

A current issue within cognitive neuropsychological research concerns the role of the medial temporal lobes in both memory and perception. Mnemonic-perceptual theories have suggested that the medial temporal lobes are involved in both these processes, with the perirhinal cortex responsible for object identity recognition and the hippocampus being interested in spatial perception [1], [2]. However, the role of the entorhinal cortex, which is situated between the hippocampus and perirhinal cortex, in both object recognition and spatial perception remains little understood. This is partly due to the complete lack thus far of patients with damage focal to the entorhinal cortex. Hence the present research aims to shed light onto the role of the entorhinal cortex in these processes in a unique patient MR, who has a selective lesion to her left entorhinal cortex.

Regarding object recognition, the two streams hypothesis proposes that different and distinct ‘what’ and ‘where’ pathways exist in the brain [3], [4]. Part of these ‘what’ and ‘where’ streams ultimately reach the medial temporal lobes, where the information they contain is bound into a single, unified representation by the hippocampus [5]. Although these ‘what’ and ‘where’ streams are initially perceptual, it is believed that they become endowed with mnemonic information as they enter the medial temporal lobes. Given the location of the entorhinal cortex between the perirhinal cortex and the hippocampus, it has been speculated that this area may also be involved in perceptual-mnemonic processes [6]. Relatedly, subdivisions may also exist within the entorhinal cortex, where the lateral part has a visuo-perceptual role and the medial part has a visuo-spatial role [7], [8]. Furthermore, it has been found that lateralisation occurs for object encoding such that object identity encoding was lateralised left, while spatial encoding was lateralised right within the medial temporal lobes [9], [10].

As well as having a role in perception, the medial temporal lobes also underpin recognition memory and the subjective experiences which accompany successful retrieval, namely recollection and familiarity, or ‘remembering’ and ‘knowing’. Recollection involves the retrieval of contextual information whereas familiarity is acontextual retrieval. Although there is dispute whether these processes are independent or not, the evidence for these being a dual process is strong at the brain level. Compelling fMRI evidence has demonstrated that the hippocampus underpins recollection whereas the perirhinal cortex supports familiarity [5], [11]. Patient studies have also been invaluable in supporting the dual-process model in finding a clear double dissociation between remembering and knowing. [12 - 15].

At present, there has been no specific role suggested for the entorhinal cortex in any theoretical recognition memory models, although recent research in healthy adults has suggested that this area has a selective role in familiarity rather than recollection-based judgements [13]. Recent research on patient MR, who has a selective lesion to her left entorhinal cortex, demonstrated impaired familiarity for words but performed normally in the recognition of non-words and faces [14]. Additionally, her recollection was unimpaired across these entire stimuli. Relatedly, recent research [15] has explored these processes in relation to material type in the medial temporal lobes, finding that the rhinal cortices responded preferentially to object familiarity, but not to scenes or faces, whilst the hippocampus was not material-specific but did respond to recollection for all category types. The aims of the present research are therefore to investigate the role of the entorhinal cortex in object recognition and associated subjective experiences, in MR and her Control group.

Method

The research gained ethical approval from the National Research Ethics Service and the University of Roehampton Ethics Committee. All participants, including MR, gave written

informed consent. MR and eight Controls took part in the research. Control participants were healthy females, all of whom had fluent English and were matched to MR on handedness, age, years of education and a range of neuropsychological intelligence profiling, as detailed in previous research [14]. All measures were tested using Crawford's modified t -test, which is suitable for single case studies with a small control group [16] and all $p > .05$. Participants were given monetary compensation for their travel and participation.

Patient MR

MR's clinical profile is more fully described elsewhere [14]. Briefly, she is a right-handed female who was 51 years old at the time of testing. At the age of 36 she began to experience seizures, and MRI investigations identified a small cavernoma on her left parahippocampal gyrus. To localise the lesion in relation to the entorhinal cortex, coronal images were compared with published references to the delineation of the entorhinal cortex [17] and, to exclude any atrophy of the mesial temporal structures, automated volumetric assessment was performed according to previously described methods [18]. This found that the volumes of MRs medial temporal lobes are in-line with aged-matched Controls and, despite her cavernoma, there is no atrophy present in this area. Imaging analysis was only performed for MR and is shown in Figure 1.

Experiment 1: object identity

Participants gave written informed consent and were given a verbal description of the experiment. Then, they were trained on the remember/know/guess paradigm, using instructions closely modelled on previous work [19]. This experiment was designed to explore object identity memory by manipulating the identity of objects from scenes. A practice block using stimuli from the SUN database [20] was given to participants so they could familiarise themselves with the demands of the experiment and to ensure they fully understood the method.

After finishing, participants were given the opportunity to ask any questions before proceeding to the experiment proper.

Here, memory was tested for objects embedded in different 48 3D scenes adapted from previous work [21]. Each scene was visually rich in colour, with shadows and lighting detail. All scenes depicted a real-life environment, e.g. a kitchen. In a trial, participants were shown a fixation cross for 1000ms before being shown a scene for 10 seconds, followed by a pattern mask of patchwork colours for 200ms. Following this scene presentation, an object was then presented centrally on an olive-green background. In half of the trials, this object was taken from the initial scene (true trial), and in the other half the object was not present in the initial scene (false trial). False trials used objects picked from the same practice trials of previous research [21], which were not used in the present experiment. Participants were asked to decide if the object was in the scene or not. If they agreed, they were then asked to make a remember/know/guess decision. If the participant initially indicated that the object was not in the scene, then the experiment skipped to the next trial. Presentation of trials was randomised and responses were collected via keyboard. After the experiment was completed, participants were fully debriefed, thanked for their time, paid and dismissed.

Experiment 2: object location

The procedure was almost identical to that of Experiment 1 and took place on average almost 4 weeks after Experiment 1. However now, rather than the target object being presented in the centre of the screen, a true object's location was manipulated. Again, half of the trials were true (the object is presented in the same location as it was in the initial scene) and half false (the object is moved to a false alarm position.). Only the location of the object was manipulated in the present experiment to ensure that this task was only exploring object-location memory. Other than this manipulation, the trials were virtually the same as described

in the object identity experiment. Participants were asked ‘Was this object located here in the scene?’, where key presses indicated a yes/no, and asked if they remember / know / guess if they answered ‘yes’. The debrief, payment, thanking and dismissal was the same as previously.

Results

One participant was excluded from both experiments for floor performance. Results from the two experiments were analysed using the proportion of hits minus false alarms for overall recognition, remember, and know responses. Guesses were too low to analyse but all subjective measure results are included in Table 1. All results were analysed using Crawford’s modified t -test [16]. In line with other similar patient research [22], remember responses acted as an index of recollection, while a correction of independence was applied to know responses [$F = K(1-R)$] in order to get an estimate of familiarity [23]. This correction of independence assumes that recollection and familiarity are distinct, where recollection is proposed to be a categorical threshold process, while familiarity is a continuous signal-detection process [24]. These data were also analysed without the correction of independence (hits minus false alarms).

Experiment 1: object identity

Three trials were excluded from the analysis as the objects chosen may have been semantically linked to their respective scene, for example, a living room scene which contained a lamp had a different lamp shown as the false alarm object, which could therefore have raised the false alarm rate. All analyses are two-tailed unless otherwise stated.

The analysis on overall recognition performance (hits-false alarms) found that MR was significantly impaired in comparison to Controls (MR = .62, Controls = .84, $t(6) = -4.12$, $p < .05$, one-tailed). Additionally, analysing overall recognition memory using d' , based on signal detection theory [25], showed that MR was also impaired when compared to Controls ($t(6) = -$

3.11, $p < .05$). MR's response criterion was measured using the criterion location measure (C) [14], which revealed that MR had no shift in response criterion when compared to Controls ($t(6) = 1.03$, $p > .05$). Further analyses revealed no significant differences in recollection (MR = .58, Controls = .63, $t(6) = -.29$, $p > .05$), nor in familiarity (MR = .10, Controls = .30, $t(6) = -.75$, $p > .05$, one-tailed).

Given MR's impairment in overall recognition performance, separate analyses on hits and false alarms were carried out to determine where the nature of her impairment was located. These analyses found that, in terms of hits, MR was impaired in overall recognition (MR = .67, Controls = .86, $t(6) = -2.96$, $p < .05$) but performed within normal range for recollection (MR = .63, Controls = .64, $t(6) = -.06$, $p > .05$) and familiarity (MR = .11, Controls = .30, $t(6) = -.71$, $p > .05$, one-tailed). The analyses on overall false alarms showed no differences between MR and the Controls (MR = .05, Controls = .02, $t(6) = .94$, $p > .05$), nor were any differences found for recollection (MR = .05, Controls = .01, $t(6) = 1.87$, $p > .05$), and neither group made any false know responses, hence familiarity rates are not calculated.

Experiment 2: object location

One trial was excluded from analysis as the location of the object coincided where a similar object was in the original scene. Analysis was the same as described in Experiment 1. The results revealed that there were no significant differences between MR and the Controls for overall recognition memory, (MR = .70, Controls = .69, $t(6) = .06$, $p > .05$). Her d' score was also normal in this task when compared to Controls ($t(6) = -.30$, $p > .05$), as was her C score ($t(6) = -1.09$, $p > .05$). However, MR had significantly lower recollection compared to Controls, (MR = .33, Controls = .52, $t(6) = -2.54$, $p < .05$). There were no significant difference between MR and the Controls for the measure of familiarity (MR = .43, Controls = .25, $t(6) = .77$, $p > .05$).

Given MR's impairment for overall remember responses, separate analyses on hits and false alarms were carried out in order to explore this further. For hits, the analysis found that MR was within normal range for recollection responses ($MR = .42$, Controls = $.54$, $t(6) = -1.40$, $p > .05$) and familiarity ($MR = .50$, Controls = $.33$, $t(6) = 1.14$, $p > .05$). Analysis of false alarms found that MR's overall scores were normal ($MR = .13$, Controls = $.07$, $t(6) = .80$, $p > .05$), although the analysis revealed that MR gave significantly more false recollection responses ($MR = .09$, Controls = $.02$), $t(6) = 3.27$, $p < .05$) but had normal levels of false familiarity ($MR = 0$, Controls = $.03$, $t(6) = -.56$, $p > .05$).

Discussion

The aim of the present research was to explore the role of the left entorhinal cortex in object recognition. The findings demonstrated that MR was impaired in recognising an object's identity, but had normal object location memory. The remaining results found that MR generally performed similarly to the Controls in terms of recollection and familiarity, although she did report significantly more false remember responses in the Where experiment. Her impairment therefore primarily only affects object identity recognition, while her spatial memory is spared.

Perceptual-mnemonic theories would suggest that the perirhinal cortex underpins object perception, whereas the hippocampus underpins spatial perception [1], [2]. As far as the authors are aware, no such perceptual-mnemonic theory has yet formally suggested a role of the entorhinal cortex in object processing, although there is existing neuroimaging evidence on healthy participants suggesting that it does have a role to play in object processing [9]. More recent work using a higher strength scanner has also broadly supported this notion [8], although the precise nature of the human entorhinal cortex has yet to be fully understood. Lastly,

research has found that object identity and object location processing is lateralised to the left and right hemispheres, respectively [9 - 10]. Taken together, these findings on healthy participants strongly suggest that the entorhinal cortex has a role in object perception. Moreover, the present patient research implicates the entorhinal cortex as being part of the ‘what’ pathway, thus extending research on patients with perirhinal cortex damage who have been found to be impaired in recognising an object’s identity. Furthermore, this result is supported by MR’s imaging that demonstrates she has no atrophy within this area and that there are no volumetric differences within her medial temporal lobe regions compared to age-matched Controls. As her impairment can be confidently deduced to the cavernoma on the lateral part of her left entorhinal cortex, this strongly suggests that this area is integral for object identity recognition.

The present research explores the first single case study on a patient with a selective lesion to the left entorhinal cortex in object recognition memory. Such populations offer obvious localisation of function advantages in memory research, although caution must be taken not to over-interpret the present findings. Further investigation is required to solidify the role of the entorhinal cortex. For example, it would be of interest to see how a patient with a lesion to their right entorhinal cortex might perform in these object memory tasks, as this would shed light on whether the crux of MR’s object identity impairment is due to verbal labelling processes that are left-dominant. A patient with such damage may therefore be unimpaired as MR’s performance suggests that object recognition is resolved by the left, and not the right, hemisphere.

In sum, the present research has demonstrated for the first time a unique relationship between the entorhinal cortex and object identity but not object location memory. Furthermore, given the generally normal correct recollection and familiarity levels demonstrated in patient

MR, our results suggest that the role the entorhinal cortex has to play in object identity recognition is based mainly on quantitative aspects of recognition memory. Furthermore, this appears to be restricted to the lateral part of the left entorhinal cortex. These findings suggest a theoretical re-think of the role of the entorhinal cortex in mnemonic-perceptual accounts of the medial temporal lobes.

303 Acknowledgements – We are grateful to MR for her very willing cooperation and interest in
304 our research.

305

306

307

308

309

310

311

312

313

314

315

316

317

318

319

320

321

322

323

324

325

326

327

328

329 **References**

- 330 [1] K. S. Graham, M. D. Barense, and A. C. H. Lee, “Going beyond LTM in the MTL: a
331 synthesis of neuropsychological and neuroimaging findings on the role of the medial
332 temporal lobe in memory and perception.,” *Neuropsychologia*, vol. 48, no. 4, pp. 831–
333 53, Mar. 2010.
- 334 [2] A. C. H. Lee, M. D. Barense, and K. S. Graham, “The contribution of the human
335 medial temporal lobe to perception: bridging the gap between animal and human
336 studies.,” *Q. J. Exp. Psychol. B.*, vol. 58, no. 3–4, pp. 300–25, 2005.
- 337 [3] M. a Goodale and a D. Milner, “Separate visual pathways for perception and action.,”
338 *Trends Neurosci.*, vol. 15, no. 1, pp. 20–5, Jan. 1992.
- 339 [4] M. Mishkin, L. G. Ungerleider, and K. A. Macko, “Object vision and spatial vision :
340 two cortical pathways,” pp. 414–417, 1983.
- 341 [5] R. a Diana, A. P. Yonelinas, and C. Ranganath, “Imaging recollection and familiarity
342 in the medial temporal lobe: a three-component model.,” *Trends Cogn. Sci.*, vol. 11,
343 no. 9, pp. 379–86, Sep. 2007.
- 344 [6] B. A. Kent, M. Hvoslef-Eide, L. M. Saksida, and T. J. Bussey, “The representational–
345 hierarchical view of pattern separation: Not just hippocampus, not just space, not just
346 memory?,” *Neurobiol. Learn. Mem.*, 2016.
- 347 [7] Z. M. Reagh and M. a Yassa, “Object and spatial mnemonic interference differentially
348 engage lateral and medial entorhinal cortex in humans.,” *Proc. Natl. Acad. Sci. U. S.*
349 *A.*, Sep. 2014.
- 350 [8] H. Schultz, T. Sommer, and J. Peters, “The Role of the Human Entorhinal Cortex in a
351 Representational Account of Memory,” vol. 9, no. November, pp. 1–8, 2015.
- 352 [9] P. S. F. Bellgowan, E. a Buffalo, J. Bodurka, and A. Martin, “Lateralized spatial and
353 object memory encoding in entorhinal and perirhinal cortices.,” *Learn. Mem.*, vol. 16,
354 no. 7, pp. 433–8, Jul. 2009.

- 355 [10] W. M. Kelley, F. M. Miezin, K. B. Mcdermott, R. L. Buckner, M. E. Raichle, N. J.
356 Cohen, J. M. Ollinger, E. Akbudak, T. E. Conturo, A. Z. Snyder, and S. E. Petersen,
357 “Hemispheric Specialization in Human Dorsal Frontal Cortex and Medial Temporal
358 Lobe for Verbal and Nonverbal Memory Encoding,” vol. 20, pp. 927–936, 1998.
- 359 [11] A. P. Yonelinas, “The Nature of Recollection and Familiarity: A Review of 30 Years
360 of Research,” *J. Mem. Lang.*, vol. 46, no. 3, pp. 441–517, Apr. 2002.
- 361 [12] K. R. Brandt, J. M. Gardiner, F. Vargha-Khadem, A. D. Baddeley, and M. Mishkin,
362 “Impairment of recollection but not familiarity in a case of developmental amnesia,”
363 *Neurocase*, vol. 15, no. 1, pp. 60–5, 2008.
- 364 [13] A. de Vanssay-Maigne, M. Noulhiane, A. D. Devauchelle, S. Rodrigo, S. Baudoin-
365 Chial, J. F. Meder, C. Oppenheim, C. Chiron, and F. Chassoux, “Modulation of
366 encoding and retrieval by recollection and familiarity: mapping the medial temporal
367 lobe networks,” *Neuroimage*, vol. 58, no. 4, pp. 1131–8, Oct. 2011.
- 368 [14] K. R. Brandt, M. W. Eysenck, M. K. Nielsen, and T. J. von Oertzen, “Selective lesion
369 to the entorhinal cortex leads to an impairment in familiarity but not recollection,”
370 *Brain Cogn.*, vol. 104, pp. 82–92, 2016.
- 371 [15] A. Kafkas, E. M. Migo, R. G. Morris, M. D. Kopelman, D. Montaldi, and A. R.
372 Mayes, “Material specificity drives medial temporal lobe familiarity but not
373 hippocampal recollection,” *Hippocampus*, vol. 209, pp. 1–20, 2016.
- 374 [16] J. R. Crawford and D. C. Howell, “Comparing an Individual ’ s Test Score Against
375 Norms Derived from Small Samples *,” vol. 12, no. 4, pp. 482–486, 1998.
- 376 [17] R. Insausti, K. Juottonen, H. Soininen, A. M. Insausti, K. Partanen, P. Vainio, M. P.
377 Laakso, and a Pitkänen, “MR volumetric analysis of the human entorhinal, perirhinal,
378 and temporopolar cortices,” *AJNR. Am. J. Neuroradiol.*, vol. 19, no. 4, pp. 659–71,
379 Apr. 1998.
- 380 [18] H. J. Huppertz, J. Kröll-Seger, S. Klöppel, R. E. Ganz, and J. Kassubek, “Intra- and

- interscanner variability of automated voxel-based volumetry based on a 3D probabilistic atlas of human cerebral structures,” *Neuroimage*, vol. 49, no. 3, pp. 2216–2224, 2010.
- [19] S. Rajaram, “Remembering and knowing: two means of access to the personal past,” *Mem. Cognit.*, vol. 21, no. 1, pp. 89–102, Jan. 1993.
- [20] J. Xiao, J. Hays, K. A. Ehinger, and A. Torralba, “SUN database : Large-scale scene recognition from abbey to zoo,” *IEEE Conf.*, 2010.
- [21] A. Hollingworth, “The relationship between online visual representation of a scene and long-term scene memory,” *J. Exp. Psychol. Learn. Mem. Cogn.*, vol. 31, no. 3, pp. 396–411, May 2005.
- [22] B. Bowles, C. Crupi, S. M. Mirsattari, S. E. Pigott, A. G. Parrent, J. C. Pruessner, A. P. Yonelinas, and S. Köhler, “Impaired familiarity with preserved recollection after anterior temporal-lobe resection that spares the hippocampus,” *Proc. Natl. Acad. Sci. U. S. A.*, vol. 104, no. 41, pp. 16382–7, Oct. 2007.
- [23] A. P. Yonelinas and L. L. Jacoby, “Dissociating automatic and controlled processes in a memory-search task: Beyond implicit memory,” *Psychol. Res.*, vol. 57, no. 3–4, pp. 156–165, 1995.
- [24] A. P. Yonelinas and L. L. Jacoby, “The process-dissociation approach two decades later: convergence, boundary conditions, and new directions,” *Mem. Cognit.*, vol. 40, no. 5, pp. 663–80, Jul. 2012.
- [25] J. G. Snodgrass and J. Corwin, “Pragmatics of measuring recognition memory: applications to dementia and amnesia,” *J. Exp. Psychol. Gen.*, vol. 117, no. 1, pp. 34–50, 1988.

Figures and tables (to be inserted by journal)

Table 1.

Proportion of hits and false alarms for MR and Controls as a function of experiment type.

	Hits			False alarms		
	Remember	Know	Guess	Remember	Know	Guess
<i>Exp. 1:</i>						
MR	.63	.04	0	.05	0	0
Controls	.64 (.16)	.13 (.15)	.10 (.06)	.01 (.02)	0 (0)	.01 (.02)
<i>Exp. 2:</i>						
MR	.42	.29	.13	.09	0	.04
Controls	.54 (.08)	.15 (.07)	.08 (.08)	.02 (.02)	.03 (.05)	.02 (.03)

Note. Standard deviations in parentheses

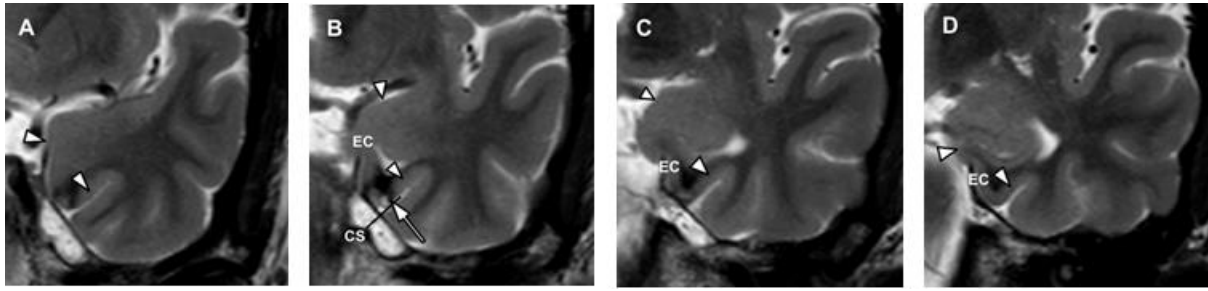


Figure 1. T2-weighted coronal imaging of MRs cavernoma (white arrow, EC = entorhinal cortex; CS = collateral sulcus). Orientation of the coronal images is perpendicular to the longitudinal axis of the hippocampus and slice thickness is 2 mm. Following previous protocol [17], this series of images shows the landmarks used to identify the hippocampal and rhinal cortical areas. It would appear that MR's cavernoma and its surrounding hemosiderin halo (surrounding susceptibility artefact = black) covers the lateral part of the left entorhinal cortex, as in [7].