

Introduction

The last decade has seen an increase in caesarean section (CS) rates in Ireland and internationally with a concomitant rise in the incidence of caesarean scar ectopic. Greater awareness of the common sonographic presentations of caesarean scar ectopic at different gestational ages may improve detection rates and reduce morbidity (Timor-Tritsch et al, 2012).

CS rates Ireland

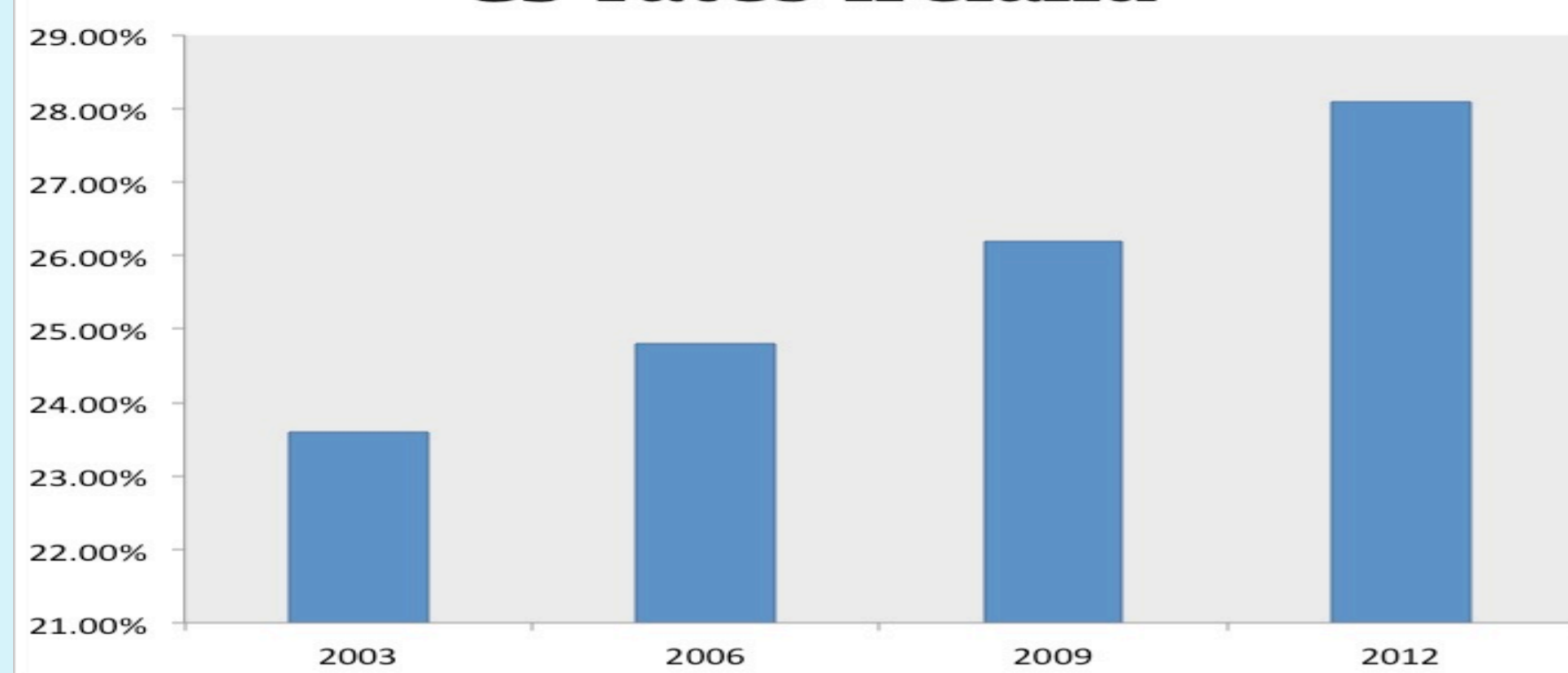


Table 1: Rising Caesarean section rates in Ireland (E.S.R.I., 2013).

The prevalence of caesarean scar ectopics is thought to be 1 in 2000 pregnancies causing significant morbidity and mortality (Siczko et al, 2014). Defined as implantation of the fetus within the scar, it is thought to occur due to a fistula developed between the scar and the endometrium. The potential for uterine rupture causing massive haemorrhage is caused by trophoblastic invasion from the implantation site without the supportive myometrium (Jungkman and Anderson, 2015).

Four cases identified in an Irish tertiary referral centre over 4 years demonstrate the differing presentations of caesarean scar ectopic and the management dilemmas discussed in the setting of Irish legislation in relation to termination of pregnancy.

Ultrasound Appearance

1. Empty uterine endometrial cavity and cervical canal.
2. Gestational sac (GS) +/- embryo located anteriorly at the level of the CS scar above the internal cervical os.
3. Appearance of a thin myometrium anterior to the GS adjacent to the bladder.
4. The presence of GS bulging out of the uterine wall contour.
5. Colour Doppler demonstrating evidence of prominent trophoblastic vessels surrounding the caesarean scar. (Zosmer et al, 2015)

Trans-vaginal scanning (TVUS) greatly expedites diagnosis due to higher resolution imaging of the implantation site (Siczko et al, 2014).

Case 1

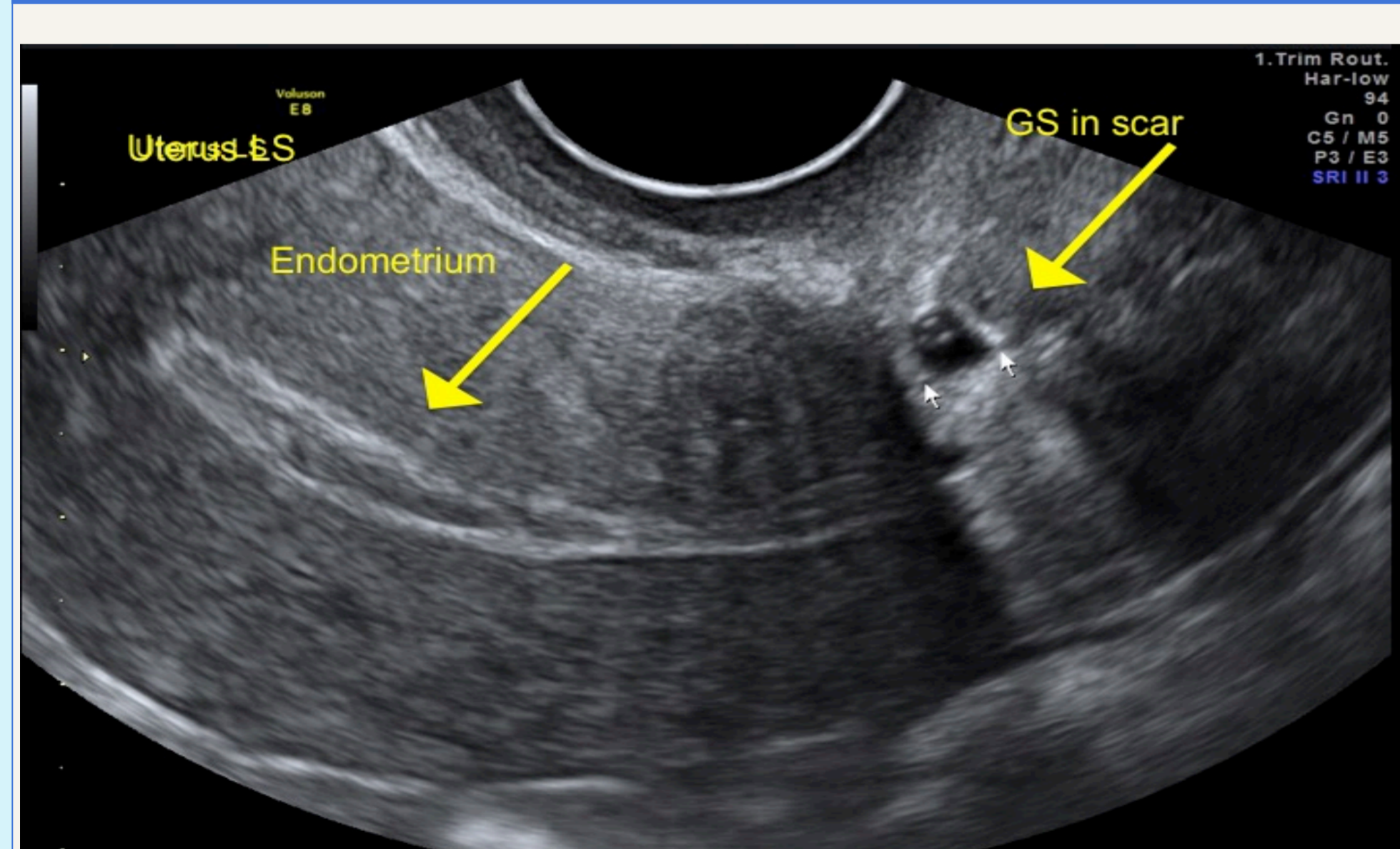


Figure 1: TV Longitudinal view of the uterus

38 yr. old G3 P2: 2 previous CS. She presented with brown PV spotting and back pain at 6 weeks gestation. TVUS demonstrated an empty thin fundal endometrium with a gestational sac containing only a yolk sac positioned in the CS scar (Fig.1). There was absence of vascular flow on colour Doppler, as mentioned by Siczko et al (2014), suggestive of a failing pregnancy.

Management decision was delayed to await serial β Hcg. Expectant management was continued as the serial β Hcg decreased from 595miu/ml to <2miu/ml in 2 weeks, and ultrasound demonstrated no sac visible in the uterus or scar. Symptoms resolved after 2 weeks and she went on to have an intrauterine pregnancy 1 year later, delivered at term by elective CS.

This case demonstrates the identification of a caesarean scar pregnancy in the first trimester, however no intervention was needed due to the failing pregnancy.

Case 2

38 yr. old G4 P3, 2 vaginal deliveries, 1 previous CS and 1 ERPC for miscarriage. Presented to E.P.A.U. at 7 weeks gestation, reporting mild pelvic cramping. A TVUS identified a GS containing a live embryo within the caesarean scar. β Hcg was 9775mIU/ml.

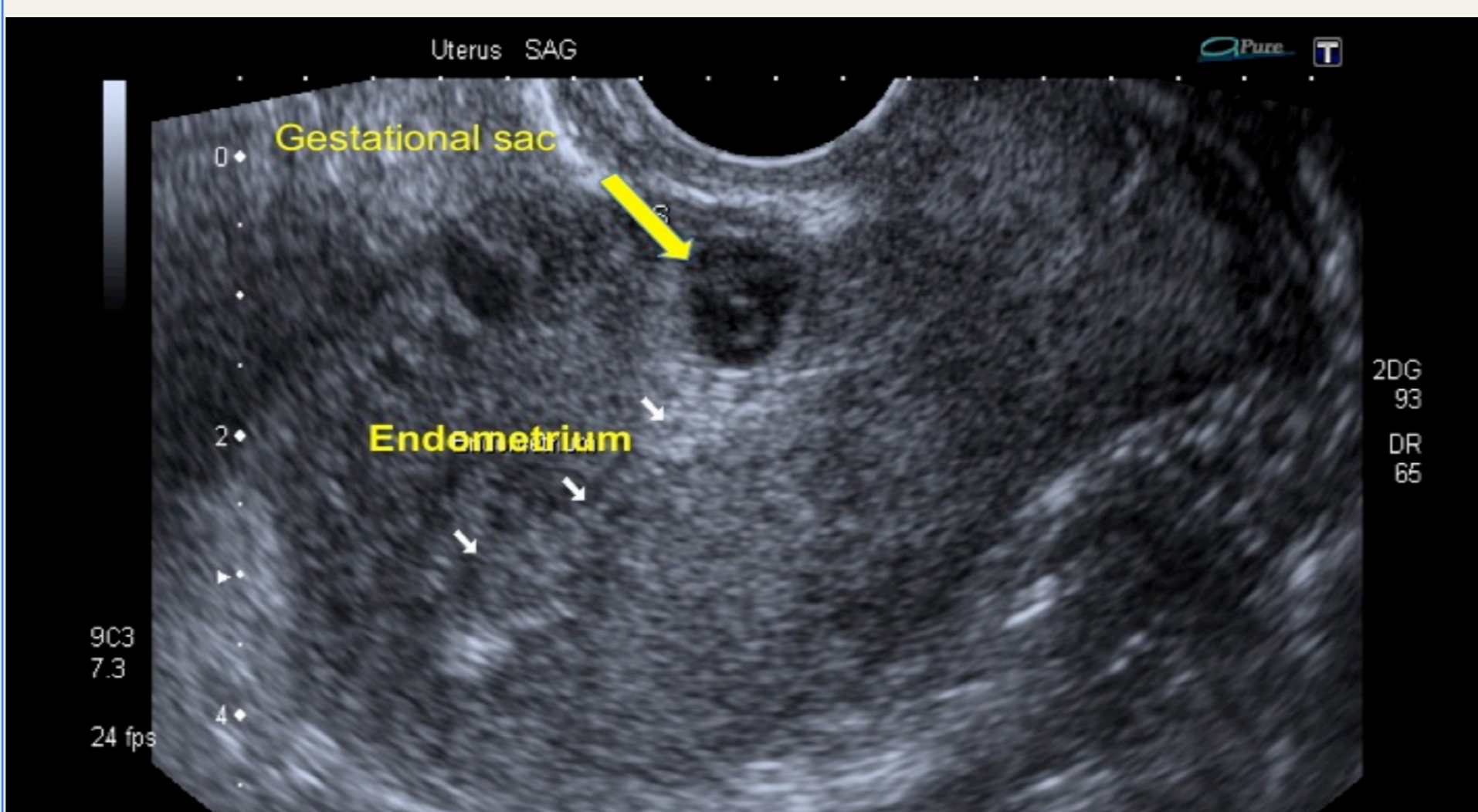


Figure 2: GS seen separate from the endometrial cavity in the lower uterus at the level of the CS scar.

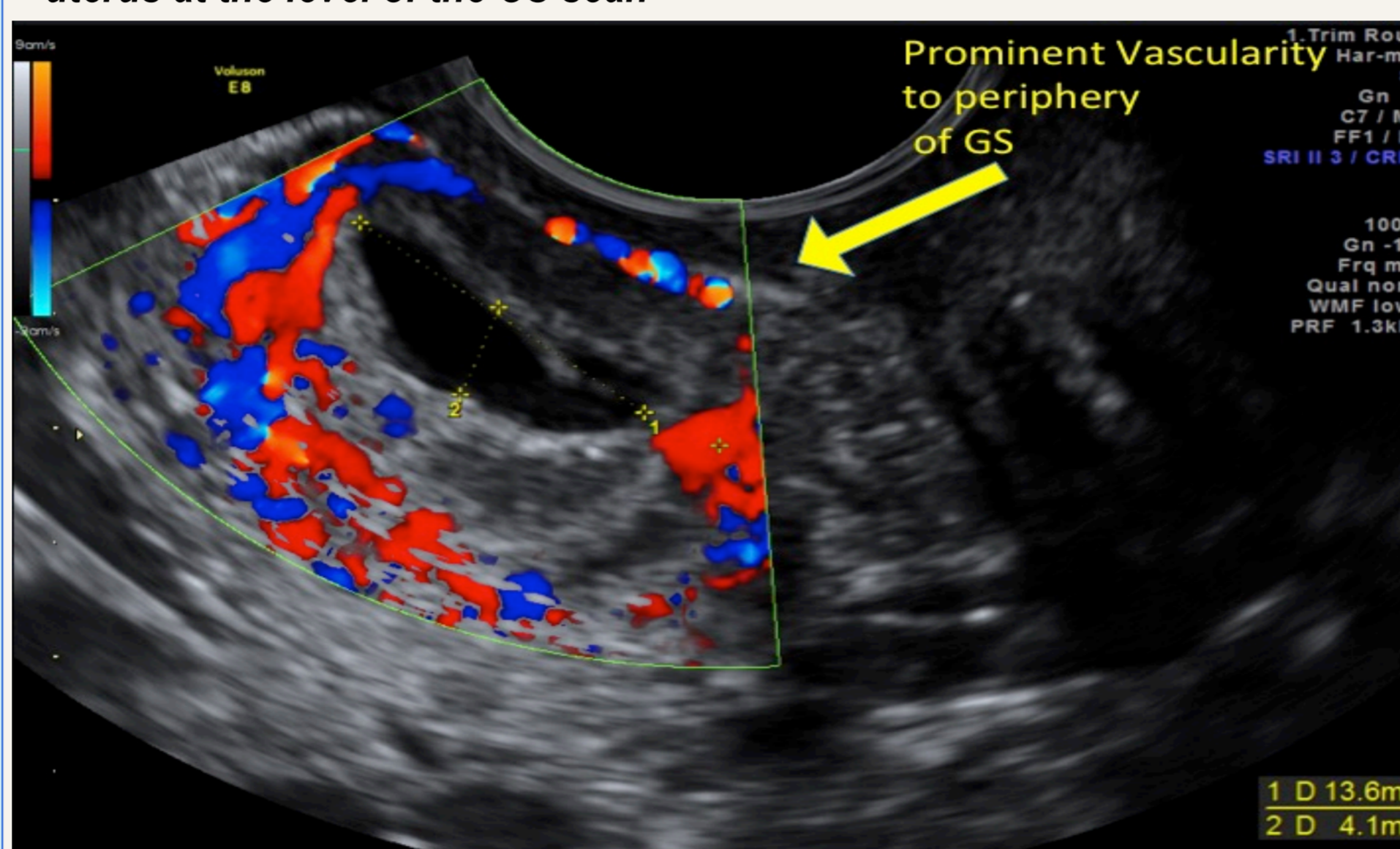


Figure 3: The GS surrounded with significant trophoblastic flow on colour Doppler (myometrial-bladder interface absent).

The risks of continuing the pregnancy versus termination of pregnancy was discussed. Maternal request was to preserve fertility, and medical treatment of intramuscular methotrexate was given, with outpatient surveillance, involving serial scanning and β Hcg monitoring. A second dose of methotrexate was needed after one week as β Hcg was 7831mIU/ml. She remained haemo-dynamically stable, and a scan revealed involution of the scar after 2 months and no β Hcg detected. She proceeded to have a miscarriage then a successful intrauterine pregnancy 2 years later.

Case 3

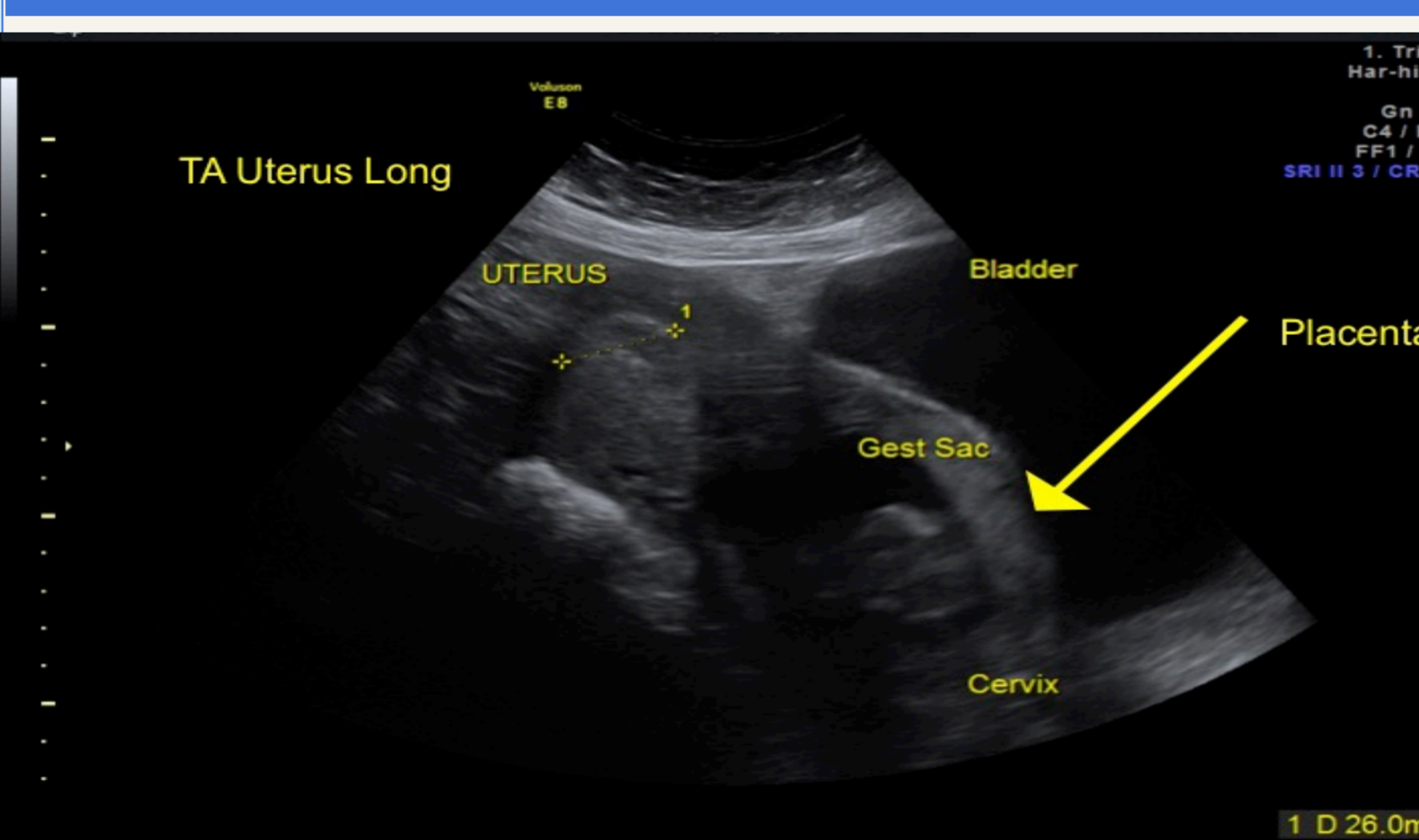


Figure 4: Transabdominal ultrasound (TAUS) assessment

36 yr. old, G3P2, 2 previous CS, referred from a regional center with suspicion of scar ectopic. She had occasional light bleeding and pelvic cramping at 14 weeks gestation. TAUS and TVUS demonstrated a live fetus within the CS scar area with the GS extending into the bladder (Fig.4).

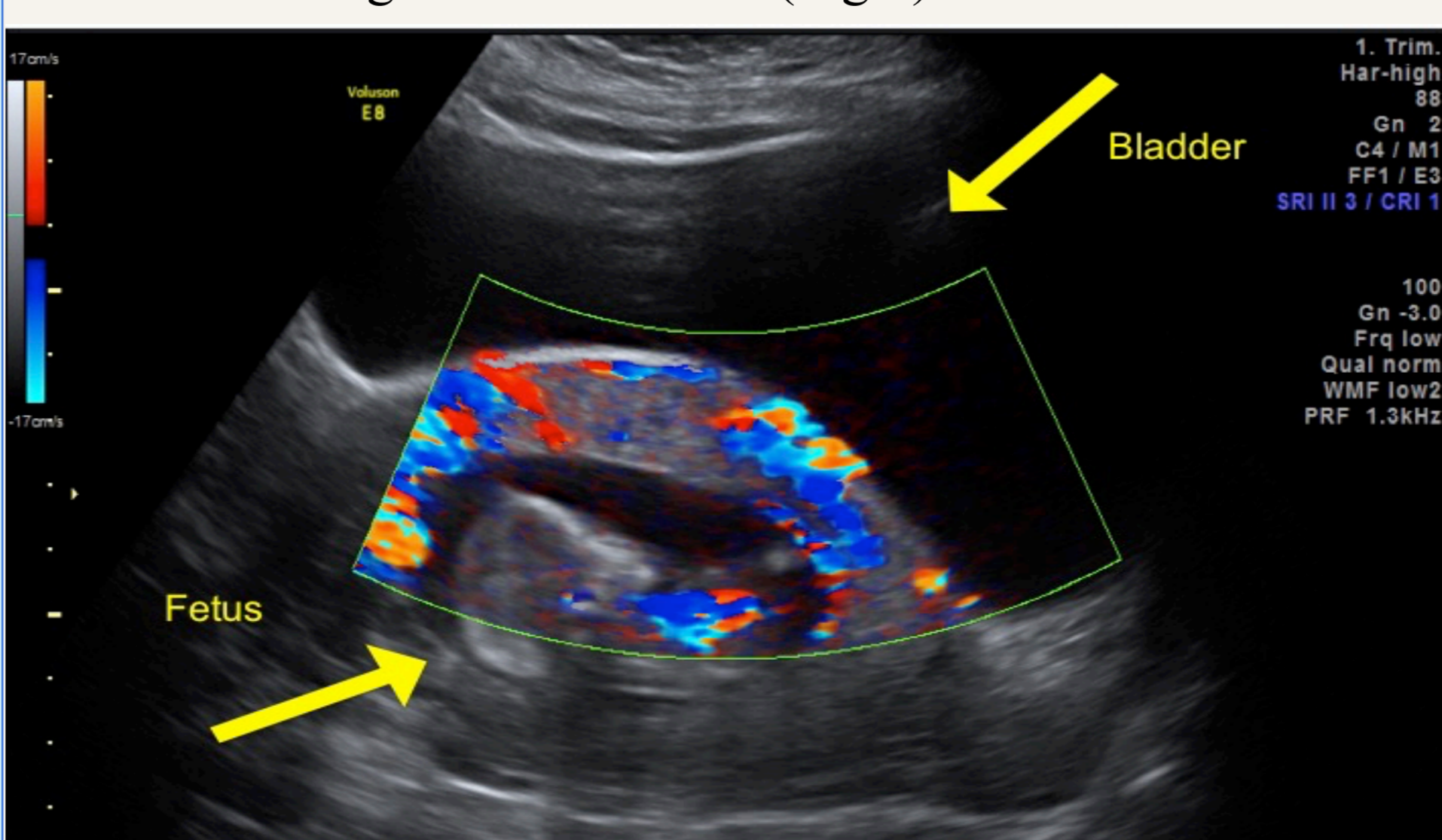


Figure 5: TAUS demonstrating Color Doppler showing marked circumferential peri-trophoblastic vascularity, surrounding the GS.

The decision was made to proceed with hysterectomy due to the degree of bladder involvement, risk of rupture and the presenting chance of life threatening hemorrhage.

Caesarean scar pregnancy

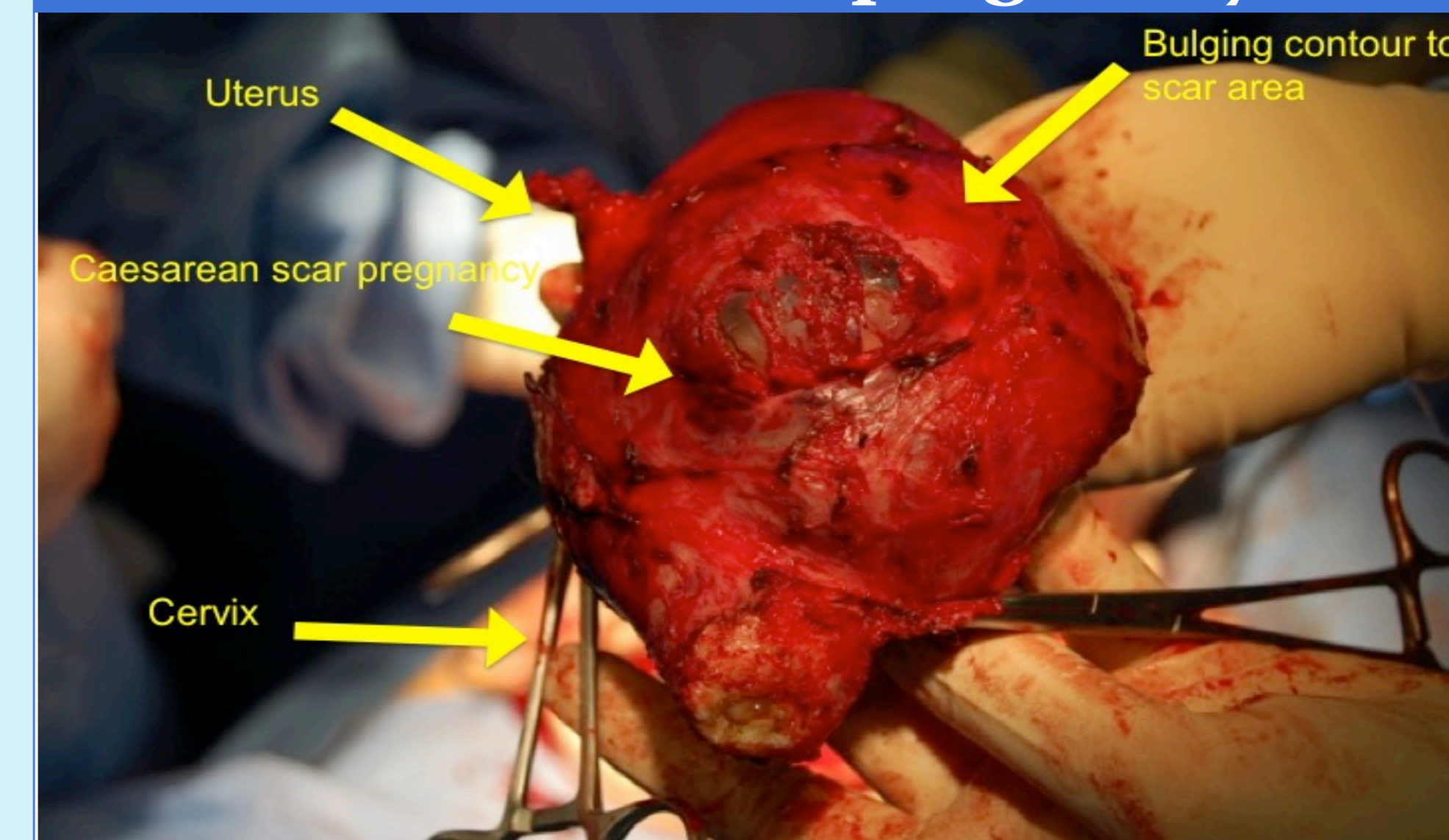


Figure 6: Pathology image case 3. The appearance of the bulging diverticulum containing the fetus, placental parenchyma, and membranes. A Total Abdominal Hysterectomy with conservation of ovaries, with bilateral salpingectomy and partial cystectomy was performed. Intercervical tamponade was needed to provide "internal iliac artery organ tamponade". The woman was discharged from hospital on day 4, with follow up confirming no long term bladder issues.

Case 4

39 yr. old G6P5, 3 previous CS. Presented at 16 weeks gestation from a regional center with substantial vaginal blood loss and pain and was haemo-dynamically unstable. A live fetus was seen on TVUS with the placenta identified to the anterior uterine wall and evidence of absent myometrium between the sac and the maternal bladder. An emergency hysterectomy was performed, she received 6 units of blood, and ICU care required for 3 days. Pathology showed morbidly adherent placenta to the CS scar.

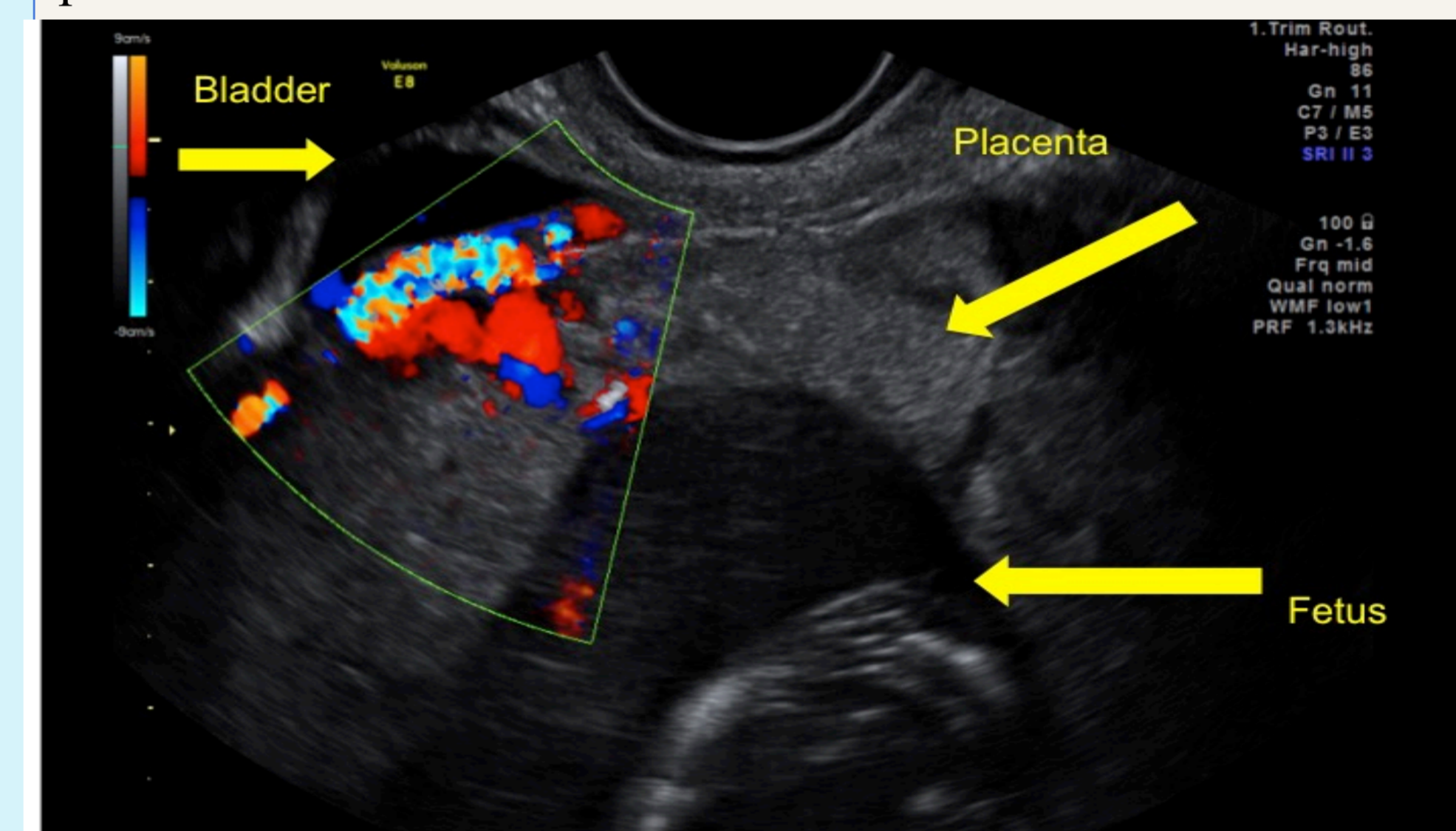


Figure 7: TVUS demonstrates the loss of the hypoechoic interface between the placenta and the myometrium, the suggestion of invasion of trophoblastic vessels.

Management

The management options in Caesarean scar ectopic pregnancy include expectant management, methotrexate, suction curettage, and hysterectomy. The use of methotrexate or expectant management can be advantageous to reduce morbidity and preserve future fertility if Caesarean scar ectopic is detected in the first trimester (Zosmer et al, 2015).

Irish law currently states that termination of pregnancy is only permissible when there is a real and substantial risk to the life of the mother (Protection of Life during Pregnancy Act, 2013). Jurkovic (2014) questions whether there is strong enough evidence to conclude that all cases should be terminated as some may progress to a normal pregnancy. The challenge is to discriminate between those at risk using ultrasound predictors as Timor-Tritsch et al (2012) discuss how acute emergency can develop of uterine abruption, massive hemorrhage or morbidly adherent placenta with a poor obstetric outcome after the first trimester.

These cases demonstrate the critical decision making required to manage challenging cases within the current Irish legislative framework to successfully save these women's lives.

Conclusion

The knowledge of the ultrasound presentation of caesarean scar ectopic is an essential skill for all obstetric sonographers for accurate diagnosis of this dangerous complicated pregnancy in the current climate of high rates of CS delivery.

References

1. Economic and Social Research Institute (2013) Perinatal Statistics Report 2012; Dublin, Available at: www.esri.ie/news/perinatal-statistics-report-2012/ accessed 10/10/15.
2. Jungkman, O. and Anderson, J. (2015) 'Importance of early detection of Caesarean Scar Ectopic Pregnancy', *Journal of Diagnostic Medical Sonography*, 31 (5), pp. 318-321.
3. Jurkovic, D. (2014) 'Caesarean scar pregnancy and placenta accreta', *Ultrasound Obstetric and Gynaecology*, 43, pp. 361-362.
4. Siczko, D., Edwards, H., Heggis, K. and White, D. (2014) 'Caesarean scar ectopic pregnancy: a case report', *Ultrasound*, 22, pp. 126-128.
5. Timor-Tritsch, I., Monteagudo, A., Santos, R., Tsybaly, T., Pineda, G. and Arslan, A. (2012) 'The diagnosis, treatment and follow up of caesarean scar pregnancy', *American Journal of Obstetrics and Gynecology*, 44, pp. 1-13.
6. Zosmer, N., Fuller, J., Shaikh, H., Johns, J. and Ross, J.A. (2015) 'Natural history of early first-trimester pregnancies implanted in Caesarean scars', *Ultrasound Obstetric and Gynaecology*, 46, pp. 367-375.