

METHODS OF RADIAL DIAGNOSTICS IN VASCULAR DEMENTIA

Prof. V.N. Sokolov, L.V. Anishchenko, G.M. Rozhkovskay,
V.M. Tsvigovsky, T.K. Dorofeeva, Y.V. Stasiuk,
E.P. Ovcharenko, A.I. Mudrova, V.D. Sokolova

Odessa National Medical University,
Diagnostic Center "South Ukrmedteh", Ukraine



ABSTRACT — The structure of all dementias is vascular dementia (VD) — the second by frequency among the elderly people. So, according to C.P. Ferri, M. Prince, (2005), VD is 16% of the structure of all dementias at the elderly people. The incidence of VD is 6–12 cases per one thousand population aged over 70 years. According to official statistics by Ministry of Health of Ukraine, the country has registered 25.5 thousand people with VD, the incidence of 4600 new cases per year, and mortality was 20.5%. The prevalence of vascular dementia increases with age and it is estimated at 1,5–4,8%. According to statistics, 1 case of dementia occurs in 350 healthy individuals, and by 2040 it will already be observed at 1 of 85 persons. Vascular diseases may lead to a number of cognitive impairment from mild to severe, and early detection of deficiency allows the doctor to intervene before dementia occurs. We conducted the study of vascular disorders of the brain using CT and MRI to patients with severe dementia and those who had vascular disorders leading to dementia, such as aneurysms, AVMs, vascular disorders in neoplastic diseases. In the study of disease pathology and cognitive changes of dementia there was found the fact that the changes are usually associated with the changes in the anterior and posterior cerebral arteries and their territories, most often in the thalamus. Other strategic targets: the basal ganglia, the knee of the internal capsule, hippocampus, mamillary bodies and brains of the bridge. For subcortical vascular dementia characterized by loss of small cerebral vessels, the so-called lacunar infarcts. It is the emergence of lacunar infarcts associated step-like progression of the disease. In vascular dementia we have identified the following changes: atrophy (cortical and / or subcortical regions), ventricular enlargement, heart attacks (usually over large areas), gaps of different sizes, hemorrhage, leucomalacia and vascular anomalies (thrombotic plaque, atherosclerosis).

KEYWORDS — vascular diseases, cognitive impairment, lacunar infarct, CT, MRI, PET.

INTRODUCTION

Problem of vascular dementia devoted countless works both in Russia, Ukraine and Europe (N.N. Yakhno; B. Mankovsky; P.V. Chuyskaya;

S.P. Markin; I.V. Damulin; M. Forstein, J. Morris et al.) creates numerous scales, supposedly allows differential diagnosis of vascular dementia from degenerative diseases and, in particular, Alzheimer's and other Bisingera (Pick's disease, Hunting, Parkinson): Ischemic Scale Khachin (1975) rating scale psychological status — M. Folstein et al., 1975; clinical rating scale J.Morris1993; common scale violations B.Reisberg et al., 1982; neuropsychological tests Folstein et al., 1975 test hours Drawing S. Lovestone et Ganthier, 2011.

In index HIC-10 (1998), under the dementia (F-00-F03) understood syndrome, brain disease chronic or progressive nature, with severe disorders of the cerebral cortex, including memory, thinking, orientation, awareness, language, erudition, reasoning without obscuring the memory. Cognitive dysfunction often accompanied by a lack of emotional control, social behavior, or motivation (sometimes accompanied by a disorder of cognitive function).

Most often, dementia syndrome occurs in vascular disorders of the brain (F01) due to cerebral infarction, including hypertensive disease.

In clinical practice and literature attempts to differentiate these diseases, using a scale of ischemic Khachin, Romana et al. (1993), and others. However, it is now believed that all these scales have a high specificity but low sensitivity. Roman scale is more sensitive, but also not able to differentiate between these diseases. Attempts to use a number of other methods that would allow for the early stages of the disease carry differential diagnosis and start timely treatment, which is quite justified and possible.

With the introduction into clinical practice of neuroimaging such as CT, MRI, fMRI, PET allowed

to revise the existing views on the problem of how to identify the morphological features of this disease, and their differentiation. First, we should recognize that vascular dementia (SD) are chronic disorders of cerebral blood flow and Discirculatory encephalopathy (YES).

The objective of our research was to identify with the above methods of characteristic morphological changes in the structure of the brain, their location, the size, the study of association cortex, subcortex, the establishment of differential diagnostic features for vascular discirculatory encephalopathy various etiologies (aneurysms, AVMs, tumor lesions of the brain, various vasculopathy).

In our research, we strictly adhere to the classification of vascular dementia, established categorization of ICD-10 (1998), which are divided into cortical dementia, subcortical, mixed and unexplained etiology.

METHODS

We used a CT scanner ASTENYON-SUPER 4 (firm Toshiba), staffed workstation «VITREA-2» and «VITREA-3» firm "VITAL IMAGES Inc." (U.S. and Avanto MRI T1, 5 (Siemens).

Patients were a number of vessels staining to identify existing vascular pathology :100—150 ml of nonionic contrast medium (350.0—370.0 mg I/ml). Bolus 3.0–3.5–4.0 ml/sec., Slice thickness of 0.5 mm. Scan delay: start automatically with bolus SURE START (define a region of interest in which the measured intensity of the staining of blood vessels, when the specified threshold is automatically started helical scanning), delay time (10–20 seconds).

In the study of the internal structure of the method, we used a three-dimensional representation of a (3D volume rendering); shaded surface display method (surface shaded display); method of maximum intensity projection (MIP); method minimum intensity projection (Min IP). The main focus is on the most modern method — a three-dimensional representation of a (volume rendering). Majority of patients we treated, underwent a virtual angiography.

Virtual CT angiography can detect potential causes of acute ischemia, such as arterial stenosis high degree of plaque ulceration or aneurysm with partial thrombosis, which can take thrombolytic therapy or cancellation it. Virtual endoscopy — a method of 3D images without the introduction of the endoscope. It creates perspective views on means of central projection beam instead parallel. orientation in space is performed using reformatting (MPR) and by the virtual-endoscopic images.

The results showed that, of the surveyed patients with severe cognitive impairment in patients with

Discirculatory encephalopathy (108 pers.), The share of Alzheimer's disease (AD) with late-onset (senile dementia of Alzheimer's type-pass) account for almost half of the cases of dementia in old age (52 people). At the same time, 23% (30 people). Installed mild dementia (a simple form) and 12% (22 pers.) — Symptomatic dementia (surrender).

Accordingly, the recommendations of national age psychiatry we have traditionally identified the following clinical forms of Alzheimer's disease: late-onset simple form with a predominance in the clinical symptoms of cognitive impairment, paranoid form with mnestic and intellectual decline, paranoid form with a tendency to formation of delusion, false memories and konfabulation products, the combination of signs of cognitive decline konfabulation intelligence-intensive products.

When surrender with Alzheimer disease violation of higher cortical functions reaches a degree of focal cortical disorders.

In the study of disease pathology and cognitive changes in dementia was found that the changes tend to be associated with changes in the anterior and posterior cerebral arteries and their territories, most often in the region of the hippocampus, mamillary cells, tonsils. Other strategic sites included the anterior cortex, basal ganglia, the knee of the internal capsule (Fig. 1–3).

With vascular dementia we have revealed the following changes: atrophy (cortical and/or subcortical), pronounced ventricular enlargement — infarcts (usually in large areas), different sizes of the gap and leukomalacia (Fig. 4–5).

CT can detect early signs of cerebral infarction, which are listed below:

- Loss of differentiation between gray and white matter — the smoothness of cortical gyri, — reduced density of cortical gyri — the existence of linear bands hipertensiv affected thrombosis vessels.

Recommended primary research performed without contrast, to avoid the risk of secondary hemorrhage in the area of infarction in the case of the introduction of contrast.

With the introduction of contrast (CTA) can determine the location of occlusion, get detailed information about the topography of the surrounding vascular network, which is very important when planning surgical intervention (Fig. 6).

When using the CT perfusion could specify basic parameters patfiziologich stroke. Application of spiral CT endoscopy examination of the inside of the vessel lumen can provide information on the nature of the stenosis, its size, and most importantly to assess the morphology rather density identified in stenosis-

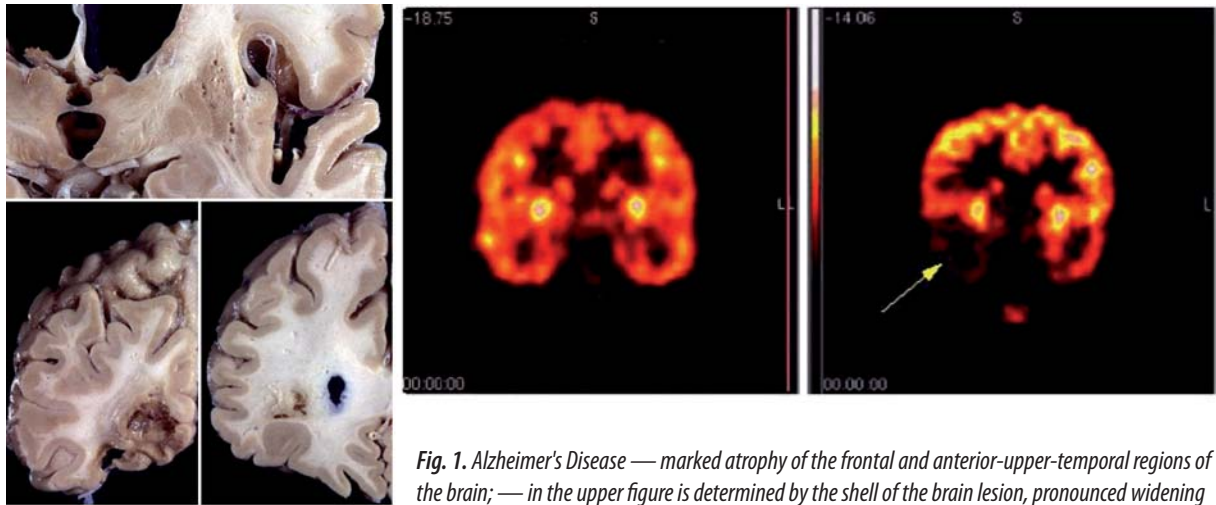


Fig. 1. Alzheimer's Disease — marked atrophy of the frontal and anterior-upper-temporal regions of the brain; — in the upper figure is determined by the shell of the brain lesion, pronounced widening of the brain ventricles and third ventricle; in the lower left figure marked paorazhenie hippocampus; — in the lower figure marked the defeat of white matter in the outer capsule and the globus pallidus; a left lower panel norm lower right figure hippocampal lesion (OFEKT)

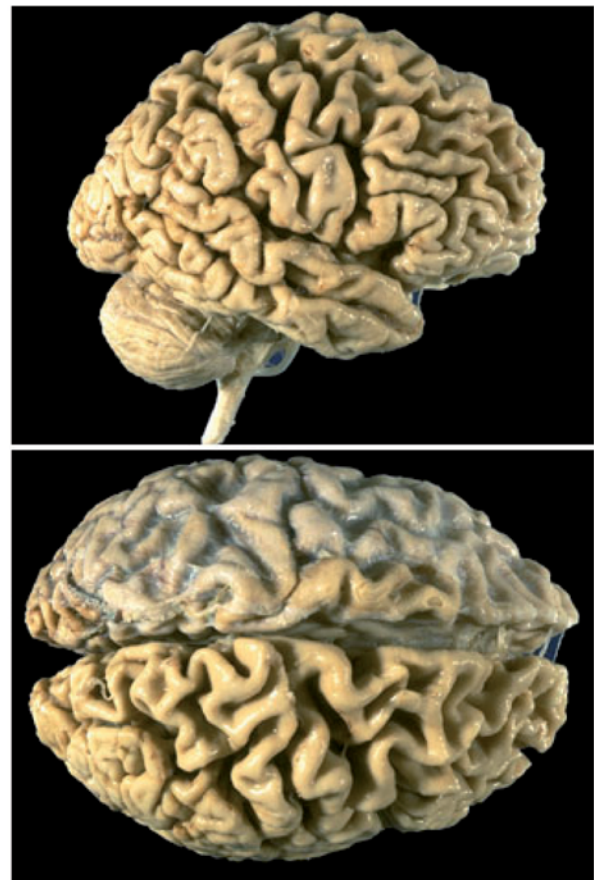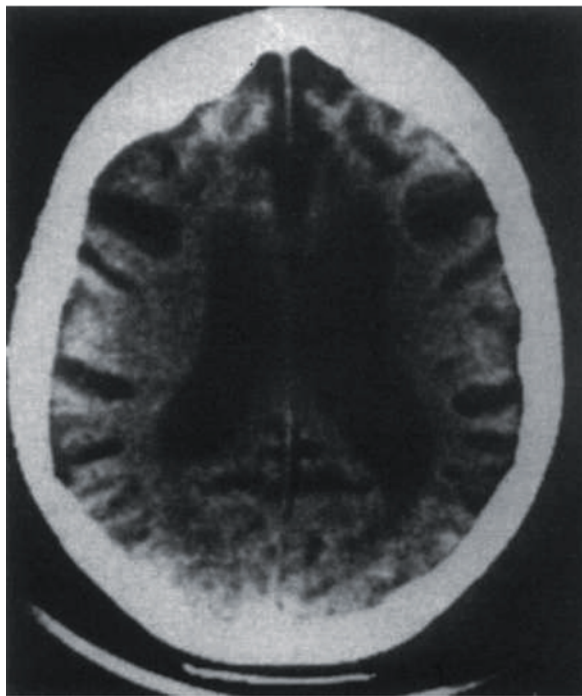


Fig. 2. Alzheimer's Disease. A marked atrophy of the frontal-temporal otodelov brain ventricular enlargement smoothing plotnosti between white and gray matter of the brain; A marked atrofiya front frontal and superior temporal regions of the brain

ing vessel thrombus, which was extremely important for intravenous thrombolytic therapy. MRI and CT scans as well as gives the same practical evaluation of

lesions of the vasculature, especially in the first 3 hours after the alleged insult. CT usually reveals a stroke in 18–24 hours. However, MRI is inferior CT espe-

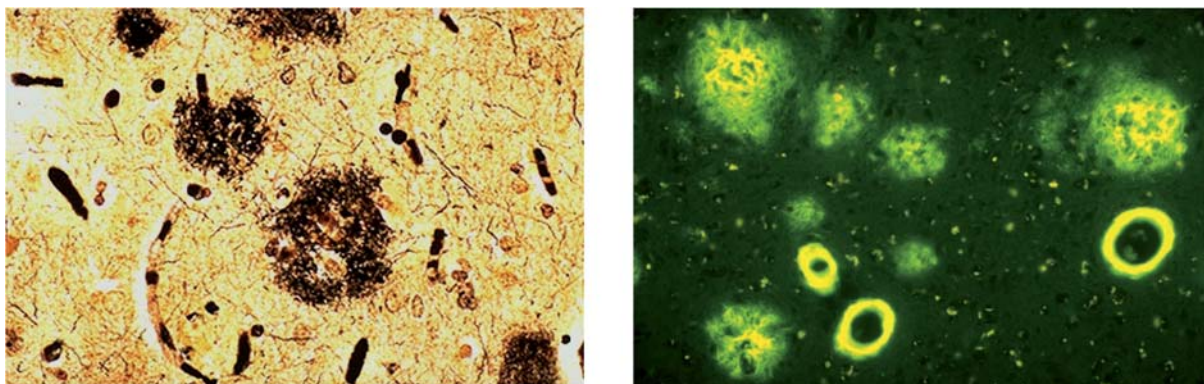


Fig. 3. Alzheimer's Disease — left to neurofibrillary tangles in the structure of the hippocampus; right-amyloid angiopathy, degenerative presynaptic terminals of astrocytes as "senile plaques"

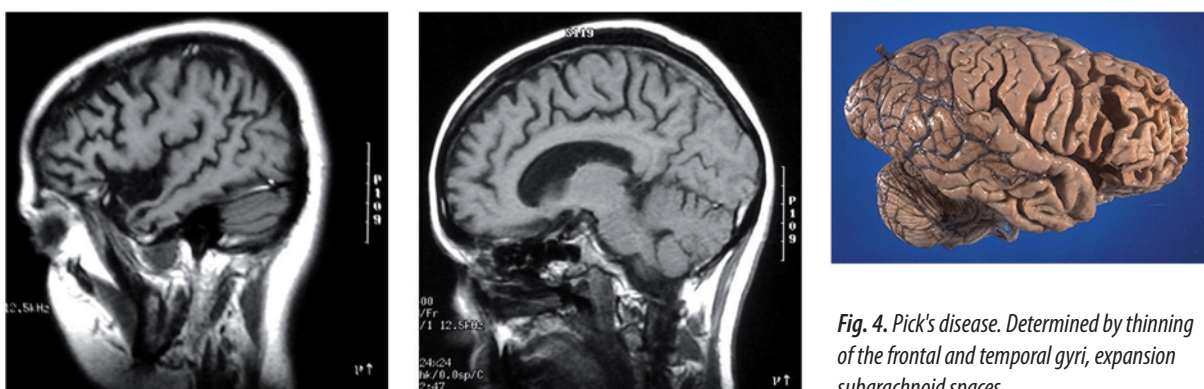


Fig. 4. Pick's disease. Determined by thinning of the frontal and temporal gyri, expansion subarachnoid spaces

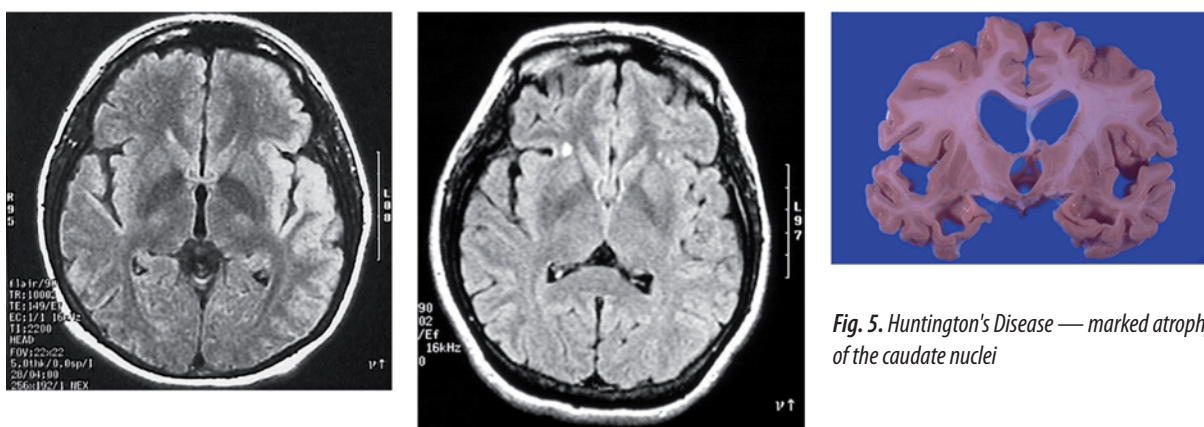


Fig. 5. Huntington's Disease — marked atrophy of the caudate nuclei

cially in the study of patients in an unconscious state, with contraindications to MRI (presence of cardiac defibrillators, pacemakers, artificial metal implants). At subcortical brain lesions, mainly white matter on CT and MRI showed a decrease the density of the white matter, mainly in the zone of the anterior horns

of the ventricles of the brain (periventricular space.) we noted interesting patterns in the clinical picture, the white matter lesions in the projection of the globus pallidus(Fig. 7–8). With the localization of stroke contour medial globus pallidus movement disorder marked by foot, the localization on the lateral dis-

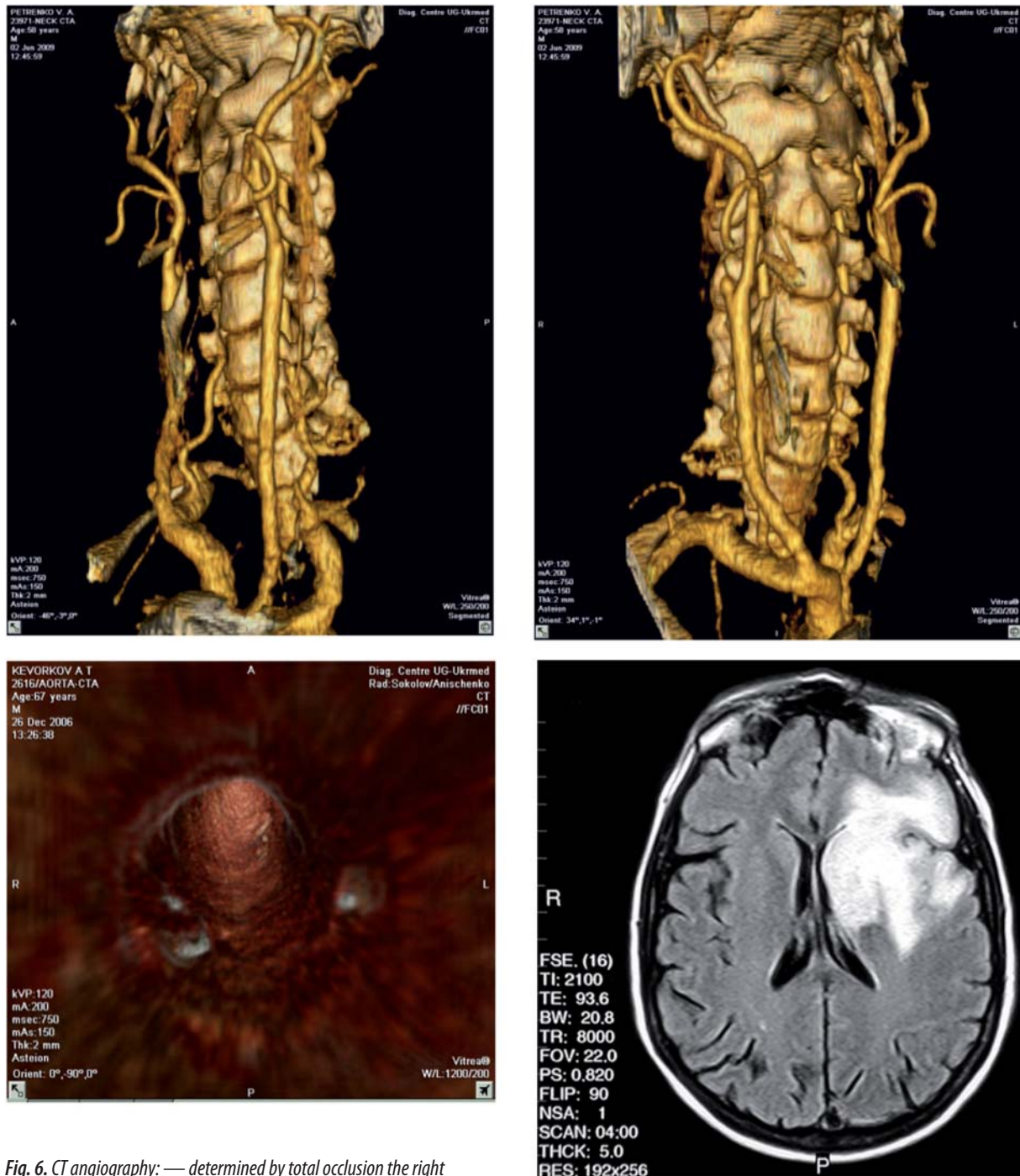


Fig. 6. CT angiography: — determined by total occlusion the right internal carotid artery narrowing to 50% the left internal carotid artery; — spiral angiography revealed intravascular plaque: ischemic stroke in the fronto-temporal areas of the brain with cortex and subcortical lesions, ventricular compression and displacement the midline to the right

sent observed movement disorders by hand, and the localization of stroke in the area of the thalamus were observed oculomotor disturbances. The nature of these changes may persist long after the acute stroke

(monitoring of patients was conducted for 10, 20, 45 days and 3 months). These terms are marked cognitive impairment (loss of memory, intellect, preservation of motor disorders in varying degree, depending on the size of the stroke occurred. Some patients were impaired control of pelvic organs.

Here we should note the following, in some patients, even without a history of stroke were observed

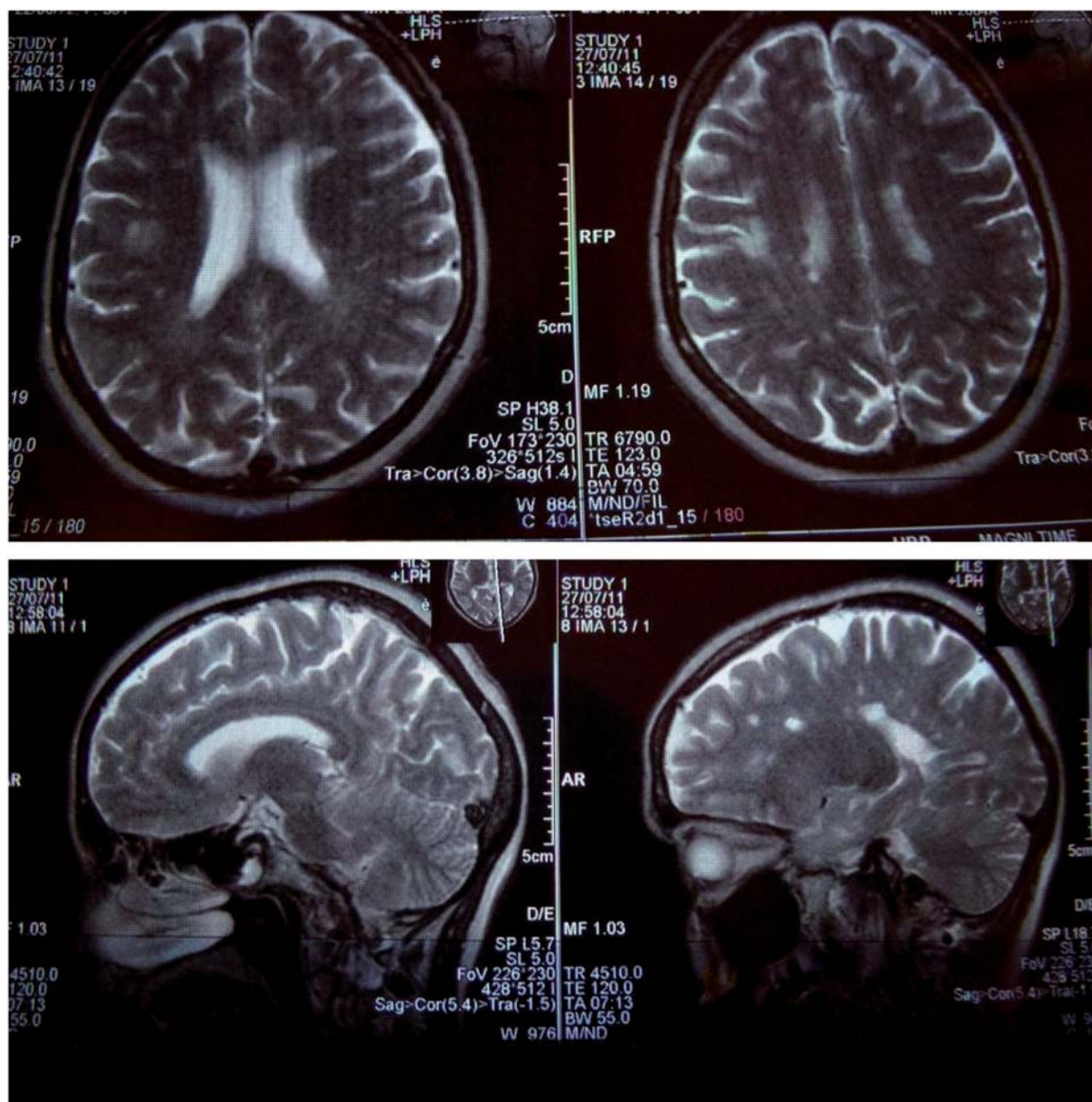


Fig. 7. MRI in T1, T2, T2 trim-weighted images in the white matter of the frontal-temporal-parietal regions of the brain, mainly in relation to the periventricular lateral ventricles, in the corpus callosum and in the pons are determined by multiple foci of various shapes and sizes with hyperintense signal at T2VI

similar symptoms of cognitive impairment (bradykinesia, gait disorders (apraxia), some pseudobulbar violations even more pronounced than in patients with stroke. During the CT and MRI are we have seen the expansion of the ventricles, the expansion of subarachnoid space, in some cases even leukoencephalopathy, moderate atrophy of the anterior fronto-temporal regions of the

brain. In these cases, we have exhibited a diagnosis of atherosclerotic dyscirculatory encephalopathy.

Often lacunar infarctions on CT or MRI detected in cerebellum. Patients complained of visual and oculomotor disorders, structural analysis and coordination, vestibular disorders. When performing CT angiography of the vertebral vessels were observed in varying degrees of severity of the aneurysm, the excesses of the internal carotid outside the skull their occlusion.

CT and PT M allow us to estimate the changes in the structure of the brain with the same accuracy. Leukoencephalopathy detected by CT in 90% of cases, the expansion of the ventricles of the brain in 100%, lacunar

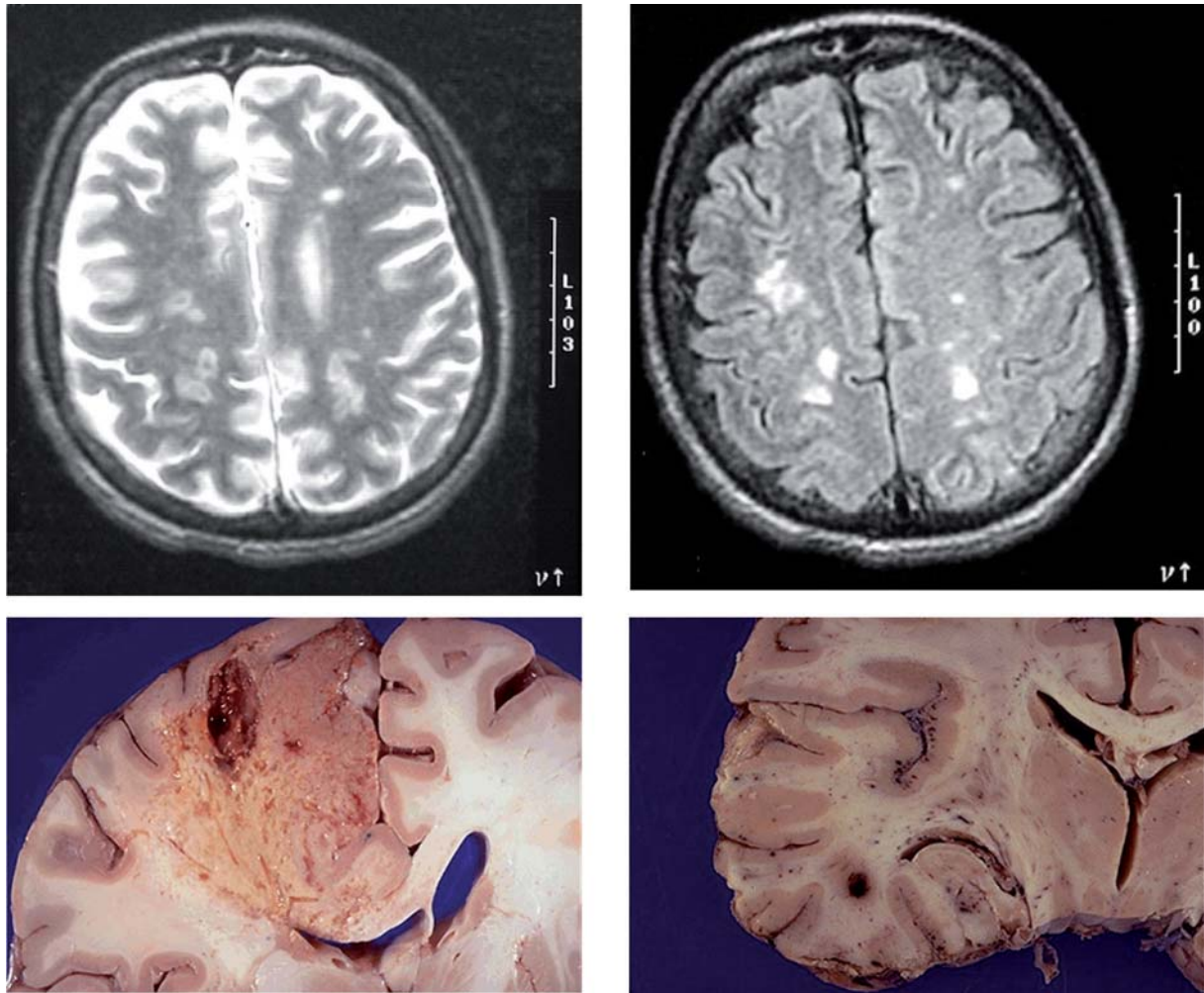


Fig. 8. CT - defined: — lacunar infarctions in the projection of the cortex and white matter of the brain; atrophy of the anterior structures, fronto-temporal lobe; — leukoareoz in periventricular regions of the brain

infarctions in 100% of cases, the nuclei of white matter damage in 100% cases. Leukoareoz MRI reveals almost all patients with vascular dementia. Changes are well detected by MRI in the structures of the hippocampus, the tonsils of the brain stem (Fig. 9–10).

SPECT, fMRI, PET showed that vascular dementia is characterized by the presence of multiple zones of hyperperfusion and asymmetrical hypometabolism.

Assessing possible methods of beam diagnostics for detection of vascular dementia, we identified the following changes:

- lacunar infarctions in the projection of the white matter of the brain;
- ventricular enlargement, atrophy of anterior structures, fronto-temporal lobe.

CONCLUSION

Multislice CT angiography is a fairly modern method in clinical practice and in the foreign medicine, this method has long been the "gold standard" in the examination of patients with vascular disease of the brain. With virtually no contraindications for the study (only idiosyncrasy of iodine-containing preparations), this method provides a very clear picture of the vascular bed, both in two-, and three-dimensional projection, to relate it to the bone structure. Revealed vascular disorders are not always accompanied by cognitive changes and their evaluation should be a whole range of additional studies (EEG, rheoencephalography, clinical research methods).

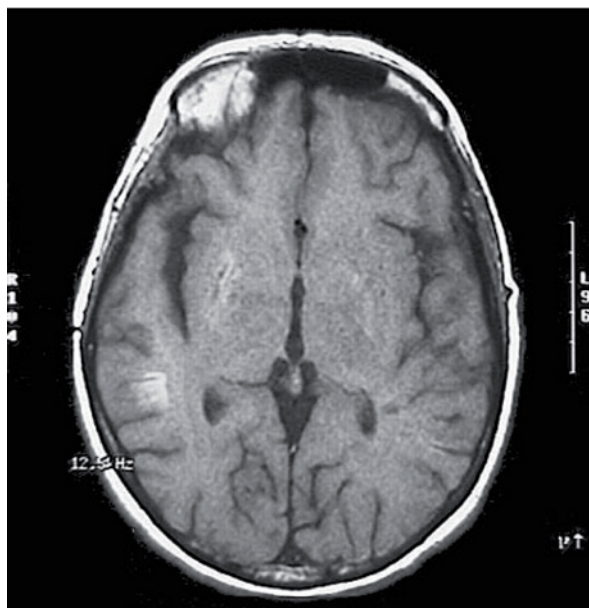


Fig. 9. MRI-defined: — Loss of differentiation between gray and white matter; — smoothness of cortical gyri; Lacunar infarcts in the shell on both sides; — reduction in the density of cortical gyri; — existence of linear bands giperdensivnyh affected thrombosis

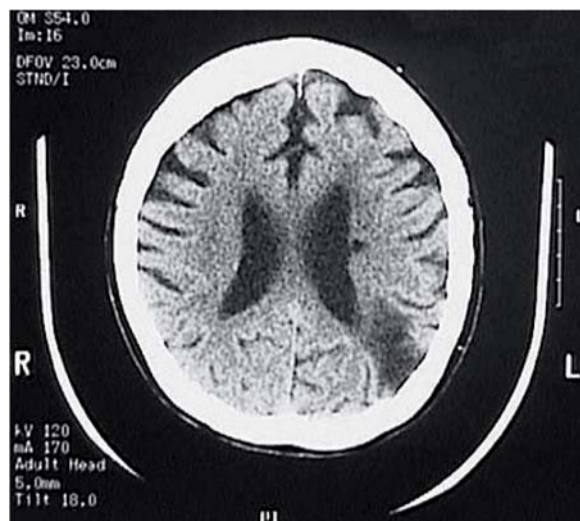


Fig. 10. Zone malacia in the localization thalamus by MOVED

REFERENCES

1. **CHUI H.C. DEMENTIA.** Review of correlation and vascular disorders of the brain. Arch. Neurol. 1989, 46 (7): 806–14.
2. **ROCCA WA, HOFFMAN, BRAYNE C, ET AL** The prevalence of vascular dementia in Europe: facts and fragments from 1980–1990 studies. EURODEM prevalence Research Group Neurol 1991, 30 (6): 817–24.
3. **TOMLINSON BE, ROTH M.** Dementia in the elderly. J Neurol prof. 1970, 11: 205–.
4. **HOFMAN, OTT, BRETELER M, ET AL.** Atherosclerosis, the prevalence of dementia and Alzheimer's disease in a study vRotterdam. Lancet. 1997, 349:151–4.
5. **HACHINSKI VC, ILIFF LD, ZILHKA E SOAVT.** Narushenie and cerebral blood flow and dementia. ArchNeurol. 1975, 32 (9): 632–7.
6. Magnetic resonance imaging of the elderly in 3301. Stroke, 1996, 27 (8): 1274–82.
7. **DAMULIN IV** Alzheimer's disease and vascular dementia. Ed. N.N.Yahno. – M., 2002, 85 p.
8. **NN YAKHNO** Cognitive disorders in neurological clinic. // Neurology. Journal. – 2006. – T.11, Appendix 1. – P. 4–12.
9. **YAKHNO NN, DAMULIN IV** Circulatory (vascular) encephalopathy. // Ross. honey. Journal. – 1999. – N.5. – C. 3–7.
10. **ROMAN G.C.** Clinical Forms of Vascular Dementia. / In: Vascular Dementia: Cerebrovascular Mechanisms and Clinical Management. Ed. by R.H.Paul et al. – Totowa: Humana Press, 2005. – P.7–21.
11. **REISBERG B., FRANSSEN E.H., HASAN S.M. ET AL.** Retrogenesis: clinical, physiologic, and pathologic mechanisms in brain aging, Alzheimer's and other dementing processes. // Eur. Arch. Psychiatry Clin. Neurosci. – 1999. – Vol. 249 (Suppl.3). – P.III/28–III/36.