



ELSEVIER



Phase 1 Lymfactin[®] Study: Short-term Safety of Combined Adenoviral VEGF-C and Lymph Node Transfer Treatment for Upper Extremity Lymphedema



Pauliina Hartiala^{a,*}, Sinikka Suominen^b, Erkki Suominen^a,
Ilkka Kaartinen^c, Juha Kiiski^d, Tiina Viitanen^a, Kari Alitalo^e,
Anne M Saarikko^{b,**}

^a Department of Plastic and General Surgery, Turku University Hospital and University of Turku, Turku, Finland

^b Department of Plastic Surgery, Helsinki University Central Hospital and University of Helsinki, Helsinki, Finland

^c Department of Reconstructive Plastic Surgery, Karolinska University Hospital, Stockholm, Sweden

^d Department of Plastic Surgery, Tampere University Hospital and University of Tampere, Faculty of Medicine and Life Sciences, Tampere, Finland

^e Wihuri Research Institute and Translational Cancer Medicine Program, Biomedicum Helsinki, University of Helsinki, Helsinki, Finland

Received 17 April 2019; accepted 9 May 2020

KEYWORDS

Lymphedema;
Breast reconstruction;
Reconstructive surgery;
Microvascular lymph node transfer;
VEGF-C

Summary

Objective: To study the safety and tolerability of Lymfactin[®] treatment combined with microvascular lymph node transfer surgery in patients with upper limb lymphedema.

Background: Upper limb lymphedema is a common clinical challenge after breast cancer surgery and/or radiotherapy. Lymfactin[®] is an adenovirus type 5-based gene therapy involving expression of human vascular endothelial growth factor C (VEGF-C) in the damaged tissue. It aims to correct deficient lymphatic flow by promoting the growth and repair of lymphatic vessels.

* Corresponding author: Dr. Pauliina Hartiala, Department of Plastic and General Surgery, Turku University Hospital, Kiinamylynkatu 4-8, FI 20521 TURKU, FINLAND, Tel: +358 2 3130063

** Corresponding author: Dr Anne M Saarikko, Department of Plastic Surgery, Helsinki University Central Hospital, Topeliuksenkatu 3-5, PO Box 266, FI 00029, HELSINKI, FINLAND

E-mail addresses: pauliina.hartiala@tyks.fi (P. Hartiala), anne.saarikko@hus.fi (A.M. Saarikko).

<https://doi.org/10.1016/j.bjps.2020.05.009>

1748-6815/© 2020 British Association of Plastic, Reconstructive and Aesthetic Surgeons. Published by Elsevier Ltd. This is an open access article under the CC BY-NC-ND license. (<http://creativecommons.org/licenses/by-nc-nd/4.0/>)

Methods: In Phase I, Lymfactin[®] was combined with microvascular lymph node transfer surgery to study the safety and tolerability of Lymfactin[®] and the biodistribution of the viral vector in patients with upper limb lymphedema.

Results: Fifteen patients with breast cancer-associated secondary lymphedema of the upper arm were recruited between December 2016 and February 2018. Three patients received a lower dose (1×10^{10}) and 12 a higher dose (1×10^{11}) of viral particles, respectively. No dose-limiting toxicities were observed, and the study was completed with the pre-determined maximum dose. Commonly reported adverse events during the 12-month follow-up were common cold, fever, gastroenteritis, pain in the operation area, headache, muscle ache and elevated liver enzymes. Serious adverse events consisted of two erysipelas infections in the lymphedema arm (requiring hospitalization) and one hematoma of the flap donor site.

Conclusions: After 12 months' follow-up, results indicate that Lymfactin[®] is well tolerated. The study continues with a 36-months efficacy and 5 years safety follow-up of the patients. The oncological safety aspects of Lymfactin[®] will require a longer follow-up period.

© 2020 British Association of Plastic, Reconstructive and Aesthetic Surgeons. Published by Elsevier Ltd. This is an open access article under the CC BY-NC-ND license. (<http://creativecommons.org/licenses/by-nc-nd/4.0/>)

Introduction

The treatment of breast cancer often includes axillary lymph node dissection followed by radiation therapy. The incidence of lymphedema is more than 20% in patients who have undergone axillary lymph node dissection.¹ The risk significantly increases in patients receiving radiotherapy^{1, 2}. Initial lymphedema often develops into chronic lymphedema, a progressive disease characterized by the accumulation of interstitial fluid, leading to pitting edema of the affected limb and gradually to irreversible accumulation of fibro-adipose tissue and non-pitting edema. During the past decade, vascularized lymph node transfer surgery (VLNT) has been gaining popularity. This procedure seems to provide at least some benefit to the patients.³⁻⁷ However, lymphoscintigraphic studies have shown that autologous lymph nodes incorporate only at a low frequency into the existing lymphatic vasculature,^{4, 8} so most of the operated patients must continue using compression garments.

Vascular endothelial growth factor C (VEGF-C) is the most selective growth factor that stimulates the formation of new lymphatic vessels in a process called lymphangiogenesis. Adenoviral VEGF-C gene transfer results in transient VEGF-C overexpression in the targeted tissue.^{9,10} During the first two weeks after the transfer, it stimulates robust growth of lymphatic capillaries in experimental models. Thereafter, the adenoviral vector is eliminated by the host immune system, and VEGF-C down-regulation leads to the regression of some of the generated lymphatic vessels.¹⁰ However, the newly formed vessels with lymphatic flow stabilize and mature into collecting lymphatic vessels spontaneously over the course of six months.⁹⁻¹²

Several studies have shown that the transplantation of VEGF-C transfected lymph nodes results in the restoration of a functional lymphatic network in the damaged area.^{9,11,13,14} In these experimental studies, a combined growth factor treatment with lymph node transfer was used to incorporate lymph nodes into the pre-existing lymphatic vessel network in the affected axillary/inguinal area. The

rationale for using VEGF-C with lymph node transfer is that VEGF-C increases successful lymphatic vessel anastomosis that incorporates the transferred nodes. In a porcine model, administration of Lymfactin[®] in the fat tissue surrounding the single inguinal lymph node promoted the growth of afferent and efferent lymphatic vessels, resulting in improved lymphatic flow, as seen in postoperative lymphangiography.^{11,12} In this large animal model, regrown lymph vessels spanned a much wider gap and often became attached to the lymph node, both afferently and efferently.^{12,13}

In secondary lymphedema associated with the treatment of breast cancer, the affected lymphatic network is usually restricted to the axillary area.¹⁵ Results from the above-mentioned experimental models suggest that in this setting, expression of the VEGF-C vector for 1-2 weeks is sufficient to rebuild damaged lymphatic vessels. Once the newly formed lymphatic vasculature becomes functional, the lymphatic vessels stabilize and further mature into collective lymphatic vessels in the target tissue.

Human lymph nodes express VEGF-C, which is also found in the axillary wound exudate after microvascular lymph node transfer.^{4,5} Results from preclinical lymphedema models employing VEGF-C or VEGF-D have demonstrated the ability of these factors to induce growth of new lymphatic vessels,^{16,17} thus providing a biological basis for VLNT surgery. Not all patients benefit from VLNT, which may partly be explained by the temporal and spatial differences in lymph node VEGF-C expression.^{5,18} Recent studies have shown that in addition to VEGF-C, lymphangiogenesis is regulated by a coordinated expression of pro- and anti-inflammatory cytokines.¹⁹⁻²¹ Further, fibrosis, scarring and a Th2-dominant CD4 T cell immune response are known to be key inhibitors of lymphatic regeneration.^{21,22} Thus, combining VLNT surgery and Lymfactin[®] provides a promising approach for a curative treatment of secondary lymphedema. Lymphedema is a debilitating condition, and no curative treatment is available at the moment. VLNT surgery has become a popular treatment of lymphedema, although the results of surgery are variable.⁶ In this article, we present the short-term safety and

tolerability results of the Lymfactin® Phase I trial, where microsurgical lymph node transfer (VLNT) surgery and adenoviral VEGF-C treatment were combined.

Methods

The study protocol was approved by the Finnish Medical Agency (FIMEA) and the Ethics Committee (EC) of Helsinki Hospital District. The study identifier number at ClinicalTrials.gov is NCT02994771.

Patient selection

Female patients aged 18-70 years with secondary lymphedema associated with the treatment of breast cancer were eligible for inclusion in the study. Their body mass index had to be between 18 and 32. The criteria required that the initial staging of their cancer was N0 or N1 with only intracapsular lymph node metastasis present in \leq three lymph nodes. At least 2 years of breast cancer treatment and/or the end of chemotherapy and/or radiotherapy (excluding endocrine and/or aromatase inhibitor treatment) without evidence of recurrent or active breast cancer were required.

The criteria regarding lymphedema required the patients a) to have undergone sentinel lymph node biopsies and/or lymph node resection in the axilla on the affected side of their breast cancer with b) regular garment use as a compression treatment for lymphedema in the affected arm, and to have c) the volume of the affected arm be over 10% larger than the unaffected arm following 7 days without compression garments, d) the presence of pitting edema in the affected arm without compression garments, and e) lymphedema symptoms for \leq 5 years.

Exclusion criteria included an initial N2/N3 or T4 staging of breast cancer or an inflammatory breast cancer at the time of the original diagnosis, evidence or history of a neoplasm other than breast cancer (except basal cell carcinoma or cervical *in situ* carcinoma), pregnancy, lactation and previous treatment or participation in a trial of a gene therapy product.

Study design

This was a first-in-human Phase I multi-center, open-label, uncontrolled dose escalation study to evaluate the safety, tolerability and biodistribution of the vector of a single dose of Lymfactin® in female patients with secondary lymphedema associated with breast cancer treatment. Treatment with Lymfactin® was combined with VLNT surgery. The study-related procedures to assess the effects of Lymfactin® were standardized across all participating sites.

Two dose cohorts were included: Cohort 1 with the dose of 1×10^{10} vp (or 6×10^8 plaque forming units [pfu]) aimed at testing the safety/tolerability and Cohort 2 with the dose of 1×10^{11} vp (or 6×10^9 pfu) aimed to be the therapeutic dose. The protocol included detailed dose escalation strategies in the presence or absence of dose limiting toxicities (DLT). In the absence of DLT's, the first patient in Cohort 1

was monitored for DLT's for 30 days post dosing. Thereafter, two additional patients were dosed and monitored for 30 days. After this, the dose escalation continued in Cohort 2 with similar within cohort monitoring as described for the Cohort 1. Once this was completed, additional 9 patients were included in the Cohort 2. In total, 3 and 12 patients were treated in Cohort 1 and 2.

Study visits and data collection

At screening, a written informed consent was obtained. Demographic data, medical history, history of breast cancer, and history of lymphedema were recorded at the screening visit (Visit 1A). A complete physical examination was carried out at the screening visit (Visit 1A), at Days 0 (Visit 2) and 7, and at Months 1, 3, 6 and 12 (Visits 4-8A). A PET-CT scan of the chest and abdomen 45-15 days before treatment was performed as the final screening procedure.

Blood and urine samples for the determination of clinical chemistry, hematology and urinalysis parameters were collected at screening and at Days 0, 7, 30, 90 and 180 and as clinically indicated.

Adverse events (AEs) and serious adverse events (SAEs) were carefully collected and graded using the Common Terminology Criteria for Adverse Event Version 4.03 (CTCAE 4.03).

Limb volume was quantified using the method described by Brorson²³. Limb diameter was calculated every 4 cm starting from the wrist and the volume difference of arms calculated using a truncated cone formula. Quantitative lymphoscintigraphy (40MBq of technetium-labeled sulfur nanocolloid 99mTc-Nanocoll, GE healthcare) with calculation of the transport index was used for lymphatic function measurement²⁴.

Operative technique and administration of Lymfactin®

The VLNT flap based on the superficial circumflex iliac vessels was raised as previously described.^{4,5,25} For some patients, this was combined with breast reconstruction using a lower abdominal flap (DIEP or ms-TRAM flap). A two-team surgical approach was used. Simultaneously, the axillary scar was removed and the recipient thoracodorsal vessels or its branches were prepared.

Lymfactin® concentrate was stored below -60°C before thawing and dilution with sterile saline for the administration. Once diluted, the solution was stored at $2 - 8^{\circ}\text{C}$ until administration within 4 hours of the dilution. After the lymph node flap was raised, the flap was positioned on a sterile table and Lymfactin® was administered *ex vivo* as a perinodal injection into the fat tissue of the flap containing the lymph nodes. The solution was injected into the proximal and the distal parts of the flap at 2 - 4 injection sites each avoiding the flap pedicle. Superficial circumflex iliac vessels were anastomosed to thoracodorsal vessels or their branches, and in the case of simultaneous breast reconstruction, inferior epigastric vessels were anastomosed to internal mammary or thoracodorsal vessels. Lymphatic vessels were not anastomosed.

To minimize possible donor site morbidity,^{25,26} reverse sentinel node mapping was performed using Technetium isotope injection (40MBq of technetium-labeled sulfur nanocolloid (99mTc-Nanocoll, GE healthcare) in a volume of 0.1-0.2 ml) and gamma imaging. The injection was placed intradermally between the first and second digit in the donor foot. During the operation, the sentinel nodes were detected with a gamma detector, and dissection near these nodes was avoided.

Clinical flap monitoring and, in addition, tissue oxygen sensor (Licox®, GMS, Kiel-Mielkendorf, Germany) in some patients were used to monitor the perfusion of the flap for three to four days postoperatively. Manual lymphatic drainage was started two weeks postoperatively, and it continued twice a week for three months after the surgery. For the first 12 months postoperatively, all patients used an elastic compression dressing on the treated arm 24 hours per day.

Study objectives

The primary aim of the study was to evaluate the safety and tolerability of a single dose of Lymfactin® administered as a perinodal injection in association with VLNT surgery in patients with secondary lymphedema associated with the treatment of breast cancer. For the long-term safety results, the patients are monitored annually up to 5 years post-treatment using CT scans of the chest and abdomen and contact via telephone. The secondary objectives were to establish the appropriate safe and well-tolerated dose of Lymfactin® for use in future studies in patients with secondary lymphedema and to determine the biodistribution of the Lymfactin® vector in blood and the development of Lymfactin®-specific antibodies following a single dose. Efficacy will be monitored up to 36 months post-treatment using volumetry measurements, lymphoscintigraphy and Lymphedema Quality of Life Inventory questionnaires (LQOLI).

Biodistribution (PCR) and analysis of Lymfactin®-specific antibodies

The presence of the Lymfactin® genome was analyzed from blood samples taken at baseline and at 7, 30 and 90 days after treatment (please see supplementary methods for protocol). The concentration of anti-Lymfactin® antibodies (IgG) was analyzed from serum samples taken at baseline and at 30, 90 and 180 days after treatment (please see supplementary methods for protocol).

Results

Participants

Between December 2016 and February 2018, 15 female postmastectomy lymphedema patients were included in the study. One patient did not pass screening due to unexpected findings in PET-CT and was therefore not included

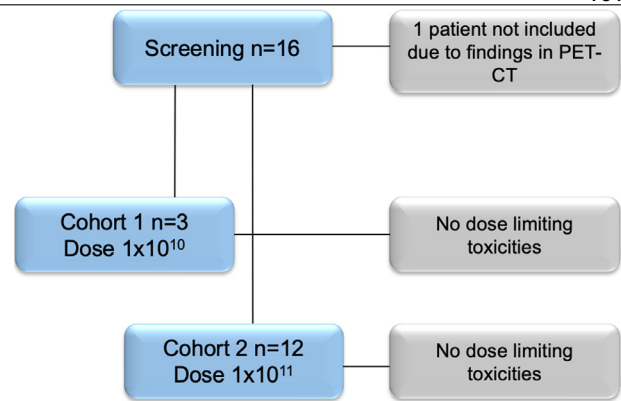


Figure 1 Flow diagram of patient screening, treatment and retention of 16 study participants with breast cancer treatment-associated secondary lymphedema. One patient was not included because of abnormal findings in PET-CT imaging. Patients were enrolled in two different dose groups: Cohort 1 received a dose of 1×10^{10} and Cohort 2 a dose of 1×10^{11} viral particles. There were no further withdrawals from the study.

Table 1 Patient characteristics.

	Cohort 1	Cohort 2
Age (y)	52.7±15	55.5±6.7
Weight (kg)	68.3±8.6	76.3±12.7
Height (m)	1.7±0.1	1.6±0.1

in the study (Figure 1). There have been no further withdrawals. Patient characteristics are summarized in Table 1. The mean age of the patients was 54.9 ± 8.3 . The mean height was 165 ± 6.2 cm and weight 74.7 ± 12.2 kg. The mean body mass index was 27.1 ± 3.7 . Breast cancer and lymphedema history are presented in Table 2. Breast cancer TNM staging of the patients was T1N0M0 (2/15), T1N1M0 (3/15), T2N0M0 (1/15) or T2N1M0 (9/15). Surgery (lumpectomy/mastectomy and sentinel node biopsy/axillary dissection) was the primary treatment method (15/15). Of the patients, 11 of the 15 had received radiation therapy and 14 had undergone chemotherapy as additional adjuvant treatments for breast cancer. The average volume difference preoperatively was 590 ± 504 ml with compression and the average transport index of the affected arm in lymphoscintigraphy was 32.1 ± 12.7 .

Operation

A total of 15 patients with stage I or II upper extremity lymphedema underwent VLNT. Of these, 10 patients underwent simultaneous breast reconstruction and VLNT and 5 VLNT only. One patient needed a re-operation due to hematoma of the flap donor site. There were no flap losses and no re-operations were needed regarding microvascular anastomoses.

Table 2 Breast cancer and lymphedema history.

cohort	Screening number	Year of cancer diagnosis	TNM staging	Radiotherapy	Chemotherapy	Year of first lymphedema symptoms	Number of skin infections in the past 12 months	Volume difference of arms before treatment (ml)	Transport index of affected arm before treatment	Date of surgery and treatment	Operation type
C1	101	2014	T2N1M0	yes	yes	2015	0	466	45	011016	VLNT-BR
C2	102	2011	T1N0M0	yes	no	2014	0	567	45	040317	VLNT-BR
C2	103	2010	T1N1M0	no	yes	2013	0	978	18	050417	VLNT
C2	104	2015	T1N1M0	yes	yes	2015	0	751	11	130517	VLNT-BR
C2	105	2014	T2N1M0	yes	yes	2015	0	491	21	230917	VLNT-BR
C2	106	2013	T1N1M0	yes	yes	2013	0	88	45	291117	VLNT
C2	107	2013	T2N1M0	yes	yes	2013	0	938	45	030218	VLNT-BR
C1	201	2014	T1N0M0	no	yes	2015	0	380	41	141216	VLNT
C1	202	2013	T2N1M0	yes	yes	2014	0	61	28	180117	VLNT-BR
C2	203	2013	T2N1M0	no	yes	2014	0	232	13.8	291117	VLNT-BR
C2	204	2015	T2N0M0	no	yes	2016	0	178	42	100118	VLNT-BR
C2	205	2015	T2N1M0	yes	yes	2016	0	737	24.4	170118	VLNT-BR
C2	301	2014	T2N1M0	yes	yes	2015	0	184	21.8	300817	VLNT-BR
C2	302	2014	T2N1M0	yes	yes	2015	0	2057	45	131217	VLNT
C2	303	2014	T2N1M0	yes	yes	2016	1	750	24.5	100118	VLNT

Safety profile

According to the dose escalation protocol, 3 patients were included in Cohort 1 and they received the lower dose of 1×10^{10} vp. No DLTs were observed during the follow-up time, so the next patients were included in Cohort 2 and received a dose of 1×10^{11} vp, which was the pre-determined maximum dose. No DLTs were observed in Cohort 2, and the study was completed with the pre-determined maximum dose. A total of 15 patients received study treatment.

AEs are listed in Table 3. Of all patients, 11 (73.3%) had adverse events during the screening period before treatment (data not shown), 10 (66.7%) during the hospital stay (Table 3A) and 15 (100%) during the follow-up visits (Table 3B). The most common adverse events were common cold, fever, gastroenteritis, pain in the operation area, headache, muscle ache and elevated liver enzymes. All adverse events to date (minimum follow-up 12 months) are listed in Table 3. The follow-up is longer for Cohort 1 patients as they were treated first, resulting in a larger number of AEs. The safety profiles for Cohort 1 and 2 were similar. There were a total of three SAEs: two erysipelas infections requiring hospitalization and one postoperative hematoma in the groin. No deaths or breast cancer recurrences occurred during the 12-month follow-up. One patient presented with basal cell carcinoma during the follow-up.

Clinically significant elevations of liver enzyme values (P-ALAT, P-ASAT, P-AFOS, P-Bil) were detected in four patients (one patient in Cohort 1 and three in Cohort 2) pre- and post-treatment (Figure 2A-D). In all cases, the liver enzymes normalized within a few weeks. Single abnormal liver enzyme values were also detected in six other patients. However, none of these were considered clinically relevant by their treating physician. No other clinically relevant abnormalities were found in the laboratory results. The lymphocyte, monocyte and neutrophil counts were normal following treatment (Figure 2E-G). One patient had elevated lymphocyte and monocyte values at the time of screening, and one patient had an elevated neutrophil count at 90 days. However, these were normalized in the follow-up.

Biodistribution of the vector and Lymfactin®-specific antibodies

Lymfactin® treatment did not result in detection of the viral genome in any of the patients' blood (data not shown), nor was there an increase in the concentration of Lymfactin®-specific antibodies post-treatment (Figure 3). It should be noted that there was high variability in antibody concentrations before treatment, most likely because Lymfactin® has an identical viral capsid with human adenovirus serotype 5 (Ad5). Thus, previous exposure to Ad5 and especially any recent adenoviral infection would have a major effect on the concentration. In one patient, the concentration was very high before treatment, likely due to a recent Ad5 infection. In another patient, the concentration increased between 90 and 180 days post-treatment, also likely because of an adenoviral infection rather than an effect of the Lymfactin® treatment. In conclusion, it seems that there was no significant immune activation because of Lymfactin® after its local administration.

Table 3A Adverse events during treatment and hospital stay.

Primary System Organ Class	Lowest Level Term	C1 (N=3)	C2 (N=12)	Total (N=15)
Total	Total	4 3 (100.0)	9 7 (58.3)	13 10 (66.7)
Gastrointestinal disorders	Total		1 1 (8.3)	1 1 (6.7)
	Oral aphthae		1 1 (8.3)	1 1 (6.7)
General disorders and administration site conditions	Total		1 1 (8.3)	1 1 (6.7)
	Medical device site burn		1 1 (8.3)	1 1 (6.7)
Infections and infestations	Total		1 1 (8.3)	1 1 (6.7)
	Common cold		1 1 (8.3)	1 1 (6.7)
Injury, poisoning and procedural complications	Total	2 2 (66.7)		2 2 (13.3)
	Post-operative hematoma	1 1 (33.3)		1 1 (6.7)
	Post-operative pain	1 1 (33.3)		1 1 (6.7)
Investigations	Total	1 1 (33.3)	5 4 (33.3)	6 5 (33.3)
	Elevated liver enzymes	1 1 (33.3)	3 3 (25.0)	4 4 (26.7)
	Hemoglobin low		2 2 (16.7)	2 2 (13.3)
Reproductive system and breast disorders	Total		1 1 (8.3)	1 1 (6.7)
	Abnormal menstruation		1 1 (8.3)	1 1 (6.7)
Vascular disorders	Total	1 1 (33.3)		1 1 (6.7)
	Hypertension	1 1 (33.3)		1 1 (6.7)

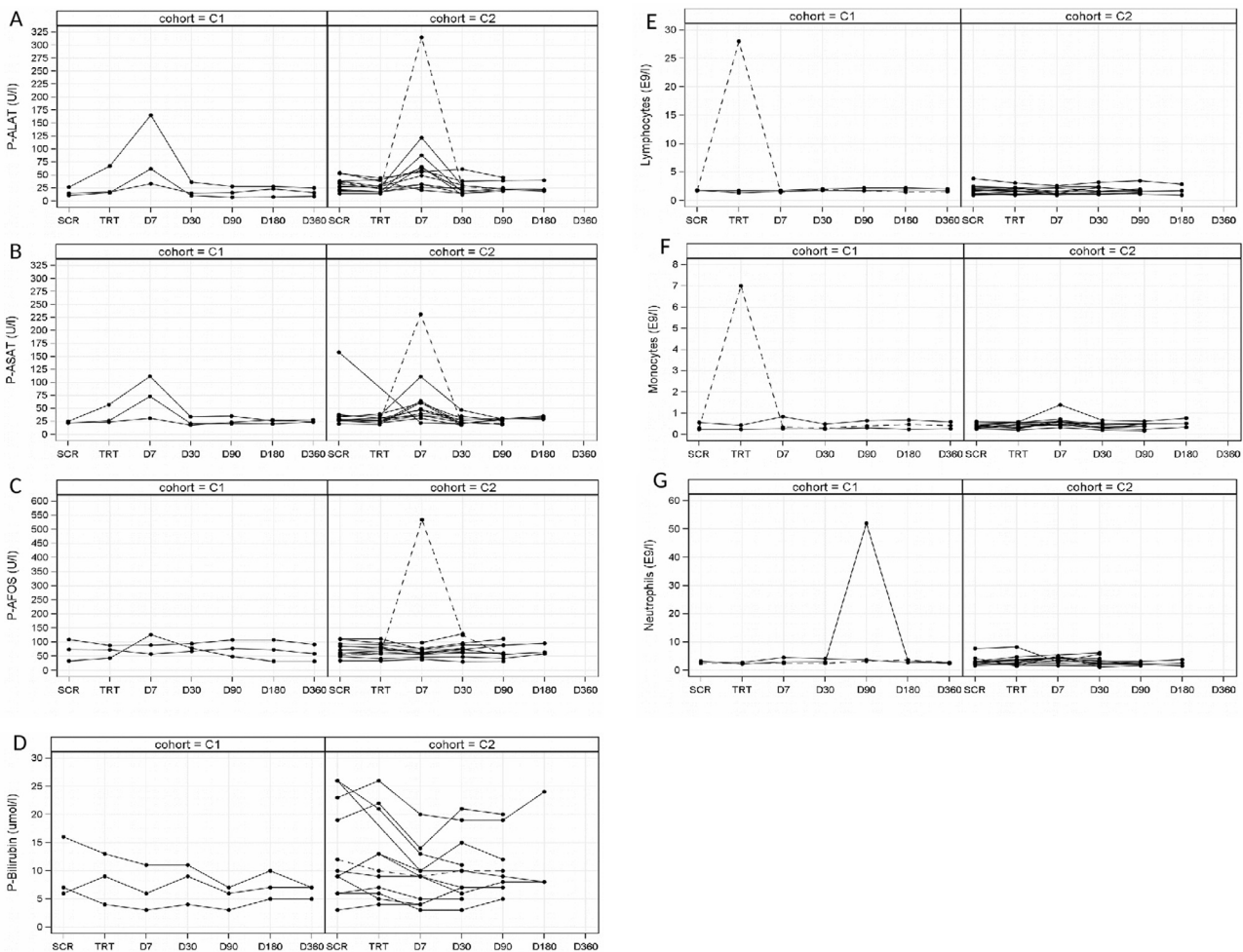


Figure 2 Kinetics of P-ALAT (A), P-ASAT (B), P-AFOS (C), P-Bil (D) values during screening, treatment and follow-up. There was an increase in liver enzyme concentrations at Day 7 after treatment in 4 patients. Patient 301 with a grade 2 increase is marked with the dashed line. Kinetics of peripheral blood lymphocyte (E), monocyte (F) and neutrophil (G) counts during screening, treatment and follow-up. One patient had elevated monocyte and lymphocyte count prior to treatment (dashed line) and one patient at 90 days after treatment. These were normalized during the follow-up.

Table 3B Adverse events during follow-up.

Primary System Organ Class	Lowest Level Term	C1 (N=3)	C2 (N=12)	Total (N=15)
Total	Total	23 3 (100.0)	55 12 (100.0)	78 15 (100.0)
Cardiac disorders	Total		1 1 (8.3)	1 1 (6.7)
	Sinus arrythmia		1 1 (8.3)	1 1 (6.7)
Gastrointestinal disorders	Total	1 1 (33.3)	7 4 (33.3)	8 5 (33.3)
	Abdominal pain		1 1 (8.3)	1 1 (6.7)
	Constipation		2 1 (8.3)	2 1 (6.7)
	Diarrhea		1 1 (8.3)	1 1 (6.7)
	Tooth decay		1 1 (8.3)	1 1 (6.7)
	Tooth pain		1 1 (8.3)	1 1 (6.7)
	Upper abdominal pain	1 1 (33.3)		1 1 (6.7)
	Vomiting		1 1 (8.3)	1 1 (6.7)
General disorders and administration site conditions	Total	4 1 (33.3)	2 2 (16.7)	6 3 (20.0)
	Fever	4 1 (33.3)	2 2 (16.7)	6 3 (20.0)
Immune system disorders	Total		1 1 (8.3)	1 1 (6.7)
	Allergy to arthropod bite		1 1 (8.3)	1 1 (6.7)
Infections and infestations	Total	4 2 (66.7)	13 10 (83.3)	17 12 (80.0)
	Common cold		1 1 (8.3)	1 1 (6.7)
	Erysipelas		3 3 (25.0)	3 3 (20.0)
	Flu	3 1 (33.3)	5 5 (41.7)	8 6 (40.0)
	Infected skin atheroma	1 1 (33.3)		1 1 (6.7)
	Otitis		1 1 (8.3)	1 1 (6.7)
	Post-operative infection		1 1 (8.3)	1 1 (6.7)
	Sinusitis		2 2 (16.7)	2 2 (13.3)
Injury, poisoning and procedural complications	Total	2 1 (33.3)	5 3 (25.0)	7 4 (26.7)
	Drain site complication		2 1 (8.3)	2 1 (6.7)
	Post-operative fistula		1 1 (8.3)	1 1 (6.7)
	Post-operative swelling	1 1 (33.3)		1 1 (6.7)
	Wound complication		1 1 (8.3)	1 1 (6.7)
	Wound decomposition		1 1 (8.3)	1 1 (6.7)
	Wound dehiscence	1 1 (33.3)		1 1 (6.7)
Investigations	Total		1 1 (8.3)	1 1 (6.7)
	Elevated liver enzymes		1 1 (8.3)	1 1 (6.7)
Metabolism and nutrition disorders	Total	1 1 (33.3)		1 1 (6.7)
	Hypercalcemia	1 1 (33.3)		1 1 (6.7)
Musculoskeletal and connective tissue disorders	Total	4 2 (66.7)	3 3 (25.0)	7 5 (33.3)
	Bursitis		1 1 (8.3)	1 1 (6.7)
	Muscle spasm	1 1 (33.3)		1 1 (6.7)
	Joint pain		1 1 (8.3)	1 1 (6.7)
	Muscle ache	2 1 (33.3)		2 1 (6.7)
	Pain in (r) foot		1 1 (8.3)	1 1 (6.7)
	Shoulder pain	1 1 (33.3)		1 1 (6.7)
Neoplasms benign, malignant and unspecified	Total	1 1 (33.3)	1 1 (8.3)	2 2 (13.3)
	Basal cell carcinoma	1 1 (33.3)		1 1 (6.7)
	Keratoacanthoma		1 1 (8.3)	1 1 (6.7)
Nervous system disorders	Total	2 1 (33.3)	12 4 (33.3)	14 5 (33.3)
	Headache	2 1 (33.3)	11 3 (25.0)	13 4 (26.7)
	Sensory loss		1 1 (8.3)	1 1 (6.7)
Psychiatric disorders	Total		1 1 (8.3)	1 1 (6.7)
	Depression		1 1 (8.3)	1 1 (6.7)
Respiratory, thoracic and mediastinal disorders	Total		2 1 (8.3)	2 1 (6.7)
	Cough		1 1 (8.3)	1 1 (6.7)
	Sniffles		1 1 (8.3)	1 1 (6.7)
Skin and subcutaneous tissue disorders	Total	4 2 (66.7)	6 5 (41.7)	10 7 (46.7)
	Blisters		1 1 (8.3)	1 1 (6.7)

(continued on next page)

Table 3B (continued)

Primary System Organ Class	Lowest Level Term	C1 (N=3)	C2 (N=12)	Total (N=15)
	Dry skin		1 1 (8.3)	1 1 (6.7)
	Dry skin face		1 1 (8.3)	1 1 (6.7)
	Erythema of extremities	2 1 (33.3)		2 1 (6.7)
	Hair loss	1 1 (33.3)		1 1 (6.7)
	Hidradenitis		1 1 (8.3)	1 1 (6.7)
	Pruritus		1 1 (8.3)	1 1 (6.7)
	Scar pain		1 1 (8.3)	1 1 (6.7)
	Sugillation	1 1 (33.3)		1 1 (6.7)

Presented as number of events, number of patients, (percentage of all patients).

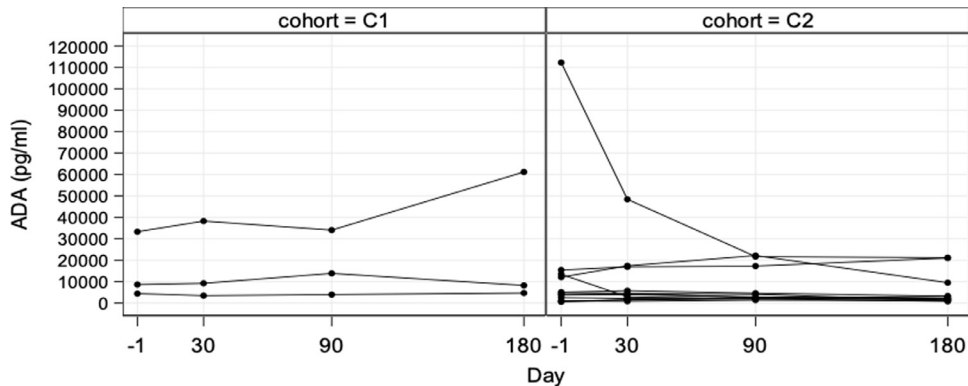


Figure 3 Lymfactin®-specific IgG concentrations of the patients during screening, treatment and follow-up.

Discussion

We present the short-term safety results of a Phase I multi-center study of the prolymphangiogenic growth factor Lymfactin® in female patients with breast cancer-associated lymphedema. Lymfactin® was combined with VLNT surgery after complete scar removal from the axilla. There were no dose-limiting toxicities, thus all the patients in Cohort 2 received the pre-determined maximum dose.

The combination of VLNT and Lymfactin® treatment has many theoretical advantages (Figure 4). First, the surgical operation includes the removal of all axillary scar tissue. The lymph node flap provides healthy adipose tissue, lymph nodes and lymphatic vessels to the axillary region, thus filling the vessel gap and replacing the fibrotic scar in the axilla with healthy, well-vascularized tissue. The perinodal injection of VEGF-C growth factor induces rapid lymphangiogenesis, followed by a maturation of the lymphatic network over several months.⁹ A longer follow-up will reveal the final safety and efficacy of this novel treatment.

The general condition of the treated patients was good during follow-up, with normal vital signs and physical examination. The reported AEs in hematology and clinical chemistry may be due to concomitant treatment, long-lasting and extensive surgical operations, and the use of both anesthetics and strong analgesics, which have been reported to induce transient elevation of liver transaminases.^{27,28} Adenoviruses are cleared from the bloodstream mainly by Kupffer cells in the liver,²⁹ which may cause inflammatory responses and also lead to the temporary ele-

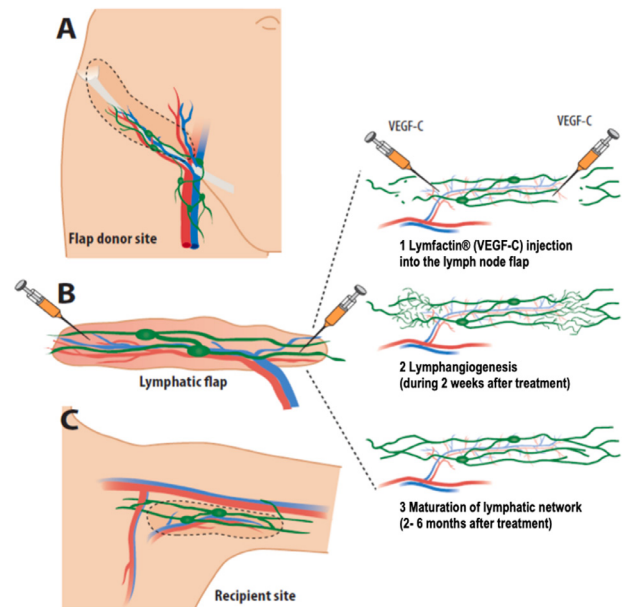


Figure 4 Operation and treatment protocol. A) Lymphatic tissue from the lower abdominal wall is harvested as a vascularized free flap. B) Lymfactin® is injected into the distal edges of the lymphatic flap to enhance lymphangiogenesis and subsequent lymphatic network maturation. C) The lymphatic flap is inserted into the axilla to replace the excised scar tissue.

vation of liver enzymes. Based on previous studies, the relationship between adenoviral therapy and the elevation of the liver enzymes is not well established. In a study using a single dose of replication-deficient adenoviral gene therapy locally (dose 2×10^{10} plaque-forming units), no elevation of liver enzymes could be detected.³⁰ This is consistent with a study using oncolytic adenovirus therapy. Three doses (1×10^{12} viral particles per dose) were administered *i.v.* within five days, and no adverse events related to liver enzyme elevation were reported.³¹ However, in a study using repeated local injections of replication-competent oncolytic adenoviral gene therapy in solid tumor treatment, elevated liver enzymes were noted in roughly 20% of the patients. In this study, the overall dose was 2.7×10^{11} – 2.7×10^{12} viral particles, and viral genome was detected in the bloodstream. In the present study, Lymfactin[®] DNA was not detected in the bloodstream of the patients, and the treatment did not increase the serum IgG antibody titer against the vector. Based on these results, the systemic presence of Lymfactin[®] seems limited. Thus, it is unlikely that the elevation of the liver enzymes would be a result of the adenoviral vector.

In this article, we present the safety results after 12-months follow-up. At this stage it can be deduced that Lymfactin[®] in combination with VLNT surgery is safe immediately after the operation and during short-term follow-up and no SAEs were regarded drug- or vector-related. We chose to publish the early safety results because we feel that plastic surgeons treating lymphedema need to be aware of this novel trial and promising safety result short-term on. However, the ultimate safety results and especially the oncological safety of Lymfactin[®] will require a long 5-year follow-up and a larger patient population. In the Phase I trial, one can not separate the effects of the VLNT surgery and Lymfactin[®] treatment as all patients have received Lymfactin[®] treatment. The Phase II trial, a randomized placebo controlled trial, aims to answer the question about efficacy of this novel treatment as half of the patients are randomized to receive only placebo in combination with VLNT surgery.

As the next phases of the study will require larger patient populations, breast cancer recurrence will inevitably occur in at least some of these patients. Loco-regional breast cancer recurrence rates vary depending on tumor subtype. A recent article reported an overall rate of 1.6–5% during a mean follow-up of 69.5 months.³² The highest rates have been reported for triple-negative subtypes of breast cancer (7.4%).³³ Although VEGF-C expression is associated with a poor prognosis and increased metastasis risk in some cancer types, for breast cancer, the data is controversial.^{34–37} In this study, Lymfactin[®] was injected into the healthy lymphatic tissue flap *ex vivo* to minimize the theoretical effects on the dormant tumor cells in the patient's axilla.

At the moment, no curative treatment is available for lymphedema patients. Thus, Lymfactin[®] treatment combined with lymph node transfer surgery could offer new hope for lymphedema patients. A randomized placebo controlled Phase II study, in which the patients will be evaluated for the efficacy and safety of Lymfactin[®] for several years, is now ongoing.

Conflicts of interest, funding and ethical approval

PH, SS, ES, IK, JK, TV and AS have received honoraria for participating in advisory boards of Herantis Pharma Plc. (Espoo, Finland). KA has been a consultant for Herantis Pharma Plc. This trial was supported by Herantis Pharma Plc. (Espoo, Finland). The sponsor has been responsible for trial management and has also reviewed this manuscript.

The research protocol was approved by the Ethical Committee of Helsinki University Hospital.

Acknowledgements

We wish to thank the patients participating in this study, the study nurses, and operating room and plastic surgery ward personnel at all participating centers. Statistical analysis of the data was performed by Tommi Pesonen at 4Pharma (Turku, Finland).

Supplementary materials

Supplementary material associated with this article can be found, in the online version, at [doi:10.1016/j.bjps.2020.05.009](https://doi.org/10.1016/j.bjps.2020.05.009).

References

- DiSipio T, Rye S, Newman B, Hayes S. Incidence of unilateral arm lymphoedema after breast cancer: A systematic review and meta-analysis. *Lancet Oncol* 2013;14:500-15.
- Byun HK, Chang JS, Im SH, et al. Risk of lymphedema following contemporary treatment for breast cancer: An analysis of 7617 consecutive patients from a multidisciplinary perspective. *Ann Surg* 2019.
- Becker C, Assouad J, Riquet M, Hidden G. Postmastectomy lymphedema: Long-term results following microsurgical lymph node transplantation. *Ann Surg* 2006;243:313-15.
- Saaristo AM, Niemi TS, Viitanen TP, Tervala TV, Hartiala P, Suominen EA. Microvascular breast reconstruction and lymph node transfer for postmastectomy lymphedema patients. *Ann Surg* 2012;255:468-73.
- Viitanen T, Visuri M, Hartiala P, et al. Lymphatic vessel function and lymphatic growth factor secretion after microvascular lymph node transfer on lymphedema patients. *Plastic and Reconstructive Surgery Global Open, PRS GO* 2013;1:1.
- Ozturk CN, Ozturk C, Glasgow M, et al. Free vascularized lymph node transfer for treatment of lymphedema: A systematic evidence based review. *J Plast Reconstr Aesthet Surg* 2016;69:1234-47.
- Raju A, Chang DW. Vascularized lymph node transfer for treatment of lymphedema: A comprehensive literature review. *Ann Surg* 2015;261:1013-23.
- Leppäpyskä I, Suominen E, Viitanen T, et al. Novel combined surgical treatment for chronic lymphedema patients: Simultaneous lymph node transfer and liposuction, accepted for publication. *Ann Plast Surg* 2019.
- Tammela T, Saaristo A, Holopainen T, et al. Therapeutic differentiation and maturation of lymphatic vessels after lymph node dissection and transplantation. *Nat Med* 2007;13:1458-1466.

10. Saaristo A, Veikkola T, Tammela T, et al. Lymphangiogenic gene therapy with minimal blood vascular side effects. *J Exp Med* 2002;196:719-30.
11. Lahtenvuo M, Honkonen K, Tervala T, et al. Growth factor therapy and autologous lymph node transfer in lymphedema. *Circulation* 2011;123:613-20.
12. Honkonen KM, Visuri MT, Tervala TV, et al. Lymph node transfer and perinodal lymphatic growth factor treatment for lymphedema. *Ann Surg* 2012.
13. Visuri MT, Honkonen KM, Hartiala P, et al. VEGF-C and VEGF-C156S in the pro-lymphangiogenic growth factor therapy of lymphedema: A large animal study. *Angiogenesis* 2015;18:313-26.
14. Tervala TV, Hartiala P, Tammela T, et al. Growth factor therapy and lymph node graft for lymphedema. *J Surg Res* 2015;196:200-7.
15. Tervala T, Suominen E, Saaristo A. Targeted treatment for lymphedema and lymphatic metastasis. *Ann N Y Acad Sci* 2008;1131:215-24.
16. Baker A, Kim H, Semple JL, et al. Experimental assessment of pro-lymphangiogenic growth factors in the treatment of post-surgical lymphedema following lymphadenectomy. *Breast Cancer Res* 2010;12:R70.
17. Saaristo A, Karkkainen MJ, Alitalo K. Insights into the molecular pathogenesis and targeted treatment of lymphedema. *Ann N Y Acad Sci* 2002;979:94-110.
18. Viitanen TP, Visuri MT, Sulo E, Saarikko AM, Hartiala P. Anti-inflammatory effects of flap and lymph node transfer. *J Surg Res* 2015;199:718-25.
19. Alitalo K. The lymphatic vasculature in disease. *Nat Med* 2011;17:1371-80.
20. Ristimäki A, Narko K, Enholm B, Joukov V, Alitalo K. Proinflammatory cytokines regulate expression of the lymphatic endothelial mitogen vascular endothelial growth factor-C. *J Biol Chem* 1998;273:8413-18.
21. Avraham T, Zampell JC, Yan A, et al. Th2 differentiation is necessary for soft tissue fibrosis and lymphatic dysfunction resulting from lymphedema. *FASEB J* 2013;27:1114-1126.
22. Zampell JC, Yan A, Elhadad S, Avraham T, Weitman E, Mehrara BJ. CD4(+) cells regulate fibrosis and lymphangiogenesis in response to lymphatic fluid stasis. *PLoS One* 2012;7:e49940.
23. Brorson H, Hoijs P. Standardised measurements used to order compression garments can be used to calculate arm volumes to evaluate lymphoedema treatment. *J Plast Surg Hand Surg* 2012;46:410-15.
24. Weiss M, Baumeister RG, Hahn K. Post-therapeutic lymphedema: Scintigraphy before and after autologous lymph vessel transplantation: 8 years of long-term follow-up. *Clin Nucl Med* 2002;27:788-92.
25. Sulo E, Hartiala P, Viitanen T, Maki M, Seppanen M, Saarikko A. Risk of donor-site lymphatic vessel dysfunction after microvascular lymph node transfer. *J Plast Reconstr Aesthet Surg* 2015;68:551-8.
26. Viitanen TP, Maki MT, Seppanen MP, Suominen EA, Saaristo AM. Donor-site lymphatic function after microvascular lymph node transfer. *Plast Reconstr Surg* 2012;130:1246-53.
27. Mirrakhimov AE, Voore P, Halytskyy O, Khan M, Ali AM. Propofol infusion syndrome in adults: A clinical update. *Crit Care Res Pract* 2015;2015:260385.
28. Bowdle A, Richebe P, Lee L, Rostomily R, Gabikian P. Hypertriglyceridemia, lipemia, and elevated liver enzymes associated with prolonged propofol anesthesia for craniotomy. *Ther Drug Monit* 2014;36:556-9.
29. Schiedner G, Hertel S, Johnston M, Dries V, van Rooijen N, Kochanek S. Selective depletion or blockade of kupffer cells leads to enhanced and prolonged hepatic transgene expression using high-capacity adenoviral vectors. *Mol Ther* 2003;7:35-43.
30. Hedman M, Hartikainen J, Syvanne M, et al. Safety and feasibility of catheter-based local intracoronary vascular endothelial growth factor gene transfer in the prevention of postangioplasty and in-stent restenosis and in the treatment of chronic myocardial ischemia: Phase II results of the kuopio angiogenesis trial (KAT). *Circulation* 2003;107:2677-83.
31. Garcia-Carbonero R, Salazar R, Duran I, et al. Phase 1 study of intravenous administration of the chimeric adenovirus enadenotucirev in patients undergoing primary tumor resection. *J Immunother Cancer* 2017;5 71-017-0277-7.
32. Keruakous AR, Sadek BT, Shenouda MN, et al. The impact of isolated tumor cells on loco-regional recurrence in breast cancer patients treated with breast-conserving treatment or mastectomy without post-mastectomy radiation therapy. *Breast Cancer Res Treat* 2014;146:365-70.
33. McGuire A, Lowery AJ, Kell MR, Kerin MJ, Sweeney KJ. Locoregional recurrence following breast cancer surgery in the trastuzumab era: A systematic review by subtype. *Ann Surg Oncol* 2017;24:3124-32.
34. Gao S, Ma JJ, Lu C. Prognostic significance of VEGF-C immunohistochemical expression in breast cancer: A meta-analysis. *Tumour Biol* 2014;35:1523-9.
35. Maanon J, Perez D, Rhode A, et al. High serum vascular endothelial growth factor C predicts better relapse-free survival in early clinically node-negative breast cancer. *Oncotarget* 2018;9:28131-40.
36. Zhang Z, Luo G, Tang H, Cheng C, Wang P. Prognostic significance of high VEGF-C expression for patients with breast cancer: An update meta analysis. *PLoS One* 2016;11:e0165725.
37. Wang J, Guo Y, Wang B, et al. Lymphatic microvessel density and vascular endothelial growth factor-C and -D as prognostic factors in breast cancer: A systematic review and meta-analysis of the literature. *Mol Biol Rep* 2012;39:11153-65.