



PETAVERS PAPER

Survival and complications in cats treated with subcutaneous ureteral bypass

N. J. KULENDRA^{1,*}, K. BORGEAT^{2,†}, H. SYME³, H. DIRRIG AND Z. HALFACREE³

^{*}North Downs Specialist Referrals, Friesian Buildings 3&4, The Brewerstreet Dairy Buisness Park, Brewer Street, Bletchingley RH1 4QP, UK

[†]Department of Cardiology, Langford Vets Langford House, Langford, Bristol BS40 5DU, UK

[‡]Department of Clinical Science and Services, The Royal Veterinary College, Hawkshead Lane AL7 9TA, UK

Corresponding author email: nkulendra@rvc.ac.uk

OBJECTIVES: To report the complications and factors affecting outcome for cats following placement of a subcutaneous ureteral bypass (SUBTM).

MATERIALS AND METHODS: In this retrospective study, complications, the presence of a urinary tract infection and survival time were recorded following subcutaneous ureteral bypass placement. Factors affecting survival time were assessed using a Kaplan Meier curve and log rank test.

RESULTS: Ninety-five cats had 130 subcutaneous ureteral bypasses placed. Ten cats did not survive to discharge. Forty cats died or were euthanised after discharge (42%); the median survival time of these cats was 530 days (range 7 to 1915). Minor complications occurred in 18 cats (19%) and major complications occurred in 46 cats (48%), the majority of which were after hospital discharge. Twenty-seven cats were diagnosed with a urinary tract infection (UTI) post-operatively. A significant association between long-term survival and creatinine at presentation was identified. The median survival time for cats presenting with creatinine concentration $\geq 440 \mu\text{mol/L}$ (International Renal Interest Society stage acute kidney injury (AKI) 4 and 5) was 530 days (95% CI 273–787 days), compared to a median survival time of 949 days (95% CI 655–1243 days; Log Rank $P=0.024$) for those cats presenting with creatinine $< 440 \mu\text{mol/L}$ (International Renal Interest Society stage AKI 1–3).

CLINICAL SIGNIFICANCE: In this population of cats, subcutaneous ureteral bypass placement was associated with an approximately 10% in-hospital mortality and a high complication rate. Most complications were manageable, resulting in an overall median survival time of over 2 years.

Journal of Small Animal Practice (2020)

DOI: 10.1111/jsap.13226

Accepted: 4 August 2020

INTRODUCTION

Ureteral obstruction is an increasingly diagnosed condition in cats (Hardie & Kyles 2004, Wormser *et al.* 2016). Although calcium oxalate urolithiasis is the most common underlying aetiology, strictures, circumcaval ureters, neoplasia and iatrogenic ligation after neutering can also lead to obstruction (Zaid *et al.* 2011, Horowitz *et al.* 2013, Steinhaus *et al.* 2015).

Ureterotomy, ureterectomy and neoureterocystostomy can be associated with high complication rates (22 to 31%) and so

alternative techniques have been explored (Hardie & Kyles 2004; Wormser *et al.* 2016, Kyles 2005). Double pigtail ureteral stents allow passive ureteral dilation and help to prevent stricture formation (Horowitz *et al.* 2013, Berent *et al.* 2014, Wormser *et al.* 2016). However, they are challenging to place because of the small diameter of the ureteral lumen. Dysuria associated with sterile cystitis is a frequently noted complication (33 to 35%) (Berent *et al.* 2014, Kulendra *et al.* 2014, Berent *et al.* 2018) affecting quality of life and occasionally resulting in euthanasia (Kulendra *et al.* 2014).

The subcutaneous ureteral bypass (SUB) (Norfolk Vet Products n.d.) is an extra-anatomic device consisting of a locking loop nephrostomy catheter connected to a cystostomy catheter via a subcutaneous port.

The aim of this retrospective study was to evaluate factors affecting the outcome of cats that had SUBs placed secondary to benign ureteral obstruction and describe any complications encountered.

MATERIALS AND METHODS

Medical records were searched (July 2018) using Clinical Records Information System software (keywords: feline, ureteral obstruction, SUB). Cats were included in this study if they were diagnosed with ureteral obstruction and had surgery to place a SUB between April 2012 and June 2017. Cats with ureteral obstruction secondary to trauma, neoplasia or ureteral ligation were excluded.

A diagnosis of ureteral obstruction was made if there was evidence of renal pelvic dilation over 3 mm or hydroureter on ultrasound [the ureters are not normally identified so any fluid inside them is defined as dilated (Debruyne *et al.* 2012)]. If it was difficult to differentiate ureteral obstruction from pyelonephritis on ultrasound, an antegrade pyelogram was performed pre-operatively as this technique was proven to be 100% sensitive and specific in detecting obstructions (Adin *et al.* 2003). Antegrade pyelography was performed under anaesthesia and once a diagnosis of an obstruction was made, cats were taken to surgery immediately. Diagnostic imaging findings have been reported elsewhere (Dirrig *et al.* 2020).

Information recorded included whether obstruction was uni- or bilateral, for bilateral obstructions whether two separate SUBs or a PantsPort™ (two nephrostomy catheters connected to a single shunting port and cystostomy catheter) was placed, imaging modality used for diagnosis and whether urethral catheterization was performed.

Haematological and biochemical information recorded included packed cell volume (PCV), creatinine and potassium at presentation and discharge. Urine culture was performed either preoperatively via cystocentesis or intra-operatively through the catheter placed in the renal pelvis prior to SUB placement.

The surgery was performed as outlined by Norfolk Vet Products (Norfolk Vet Products 2019) using the original version of the SUB in all cases. The SUB training course was not available at the start of the study period. Surgery was performed by an ECVS or ACVS boarded diplomate or a resident under their direct supervision. Intraoperative fluoroscopy involved an initial pyelogram using diluted iohexol (Omnipaque™; GE Healthcare, Little Chalfont). Further images were obtained to check the position of the guide wire and nephrostomy catheter. A SUB flush using diluted iohexol was used to check for patency and leaks once the device was in place and glued prior to closure of the abdomen. Before August 2014, a long length (1 to 5 cm) of tubing was placed in the subcutaneous space between the port and the body wall. After this date, minimal tubing (<1 cm) or the

blue boots were used to transverse the body wall; the remaining nephrostomy and cystostomy tubing was left loose inside the abdomen. Ports were placed midway between the last rib and the pelvis just lateral to the linea alba.

Procedural information recorded included any technical complications, surgical time, anaesthesia time and whether a urinary catheter was placed. Urine for bacterial culture was obtained by pyelocentesis during SUB placement prior to contrast administration. Perioperative antibiotics were given in all cases; either cefuroxime or based on previous sensitivity results if a urinary tract infection (UTI) was diagnosed pre-operatively. If an active urine sediment or positive urine culture was obtained antibiotics were continued post-operatively based upon culture and sensitivity results otherwise no antibiotics were given.

Serial biochemical analysis and PCV was performed every 12 to 24 hours post-operatively; if the cat was clinically showing signs of hypovolaemia, hypotension or inappropriate mentation, the frequency of performing these tests was increased at the discretion of the clinician. Any cat with increasing creatinine (approximately >5%) or elevated potassium on subsequent biochemistry tests had a contrast study of the SUB system performed under anaesthesia or sedation to check for leaks or blockages; if the SUB was patent and not kinked and the cat had increasing creatinine and potassium, it was assumed the cat had an acute kidney injury.

Cats were evaluated 2 weeks post-operatively where a haematology and biochemistry was performed. Three months post-operatively a haematology, biochemistry, urinalysis and culture were performed along with a fluoroscopic contrast study to evaluate the patency of the SUB under sedation. Iohexol was diluted 50:50 with sterile saline and 1 to 3 mL was injected into the subcutaneous port using a Huber needle aseptically. Once patency was confirmed, the port was then flushed gently with sterile saline (2 to 10 mL), which was at the discretion of the attending clinician. If there was blockage of the device, multiple attempts were made to flush the device. After the publication of the revised Norfolk Vet Products guidelines (Norfolk Vet Products n.d.), the renal pelvis was monitored carefully to avoid over distension. If the SUB was blocked, urine was obtained via cystocentesis for urine culture. Patency of the system, complications, creatinine and overall survival were recorded. Cats were staged according to the International Renal Interest Society (IRIS) grading system ("International Renal Interest Society," 2019) three months post-operatively. Post-operative catheter failure was classified as the catheter snapping, a hole in the catheter or the cystostomy catheter detaching from the Dacron cuff; all resulting in uroabdomen.

Follow up appointments were advised every 3 months but were at the owners' discretion. Cats were followed up from 1 to 6 years post-operatively, either via hospital admissions or telephone follow up with the referring veterinarians or the owners. Procedural complications were recorded and classified as major (infection or technical problem resulting in revision surgery, removal of the SUBs or death/euthanasia) or minor (infection or technical problem which resolved with none or minor treatment, not involving revision surgery, removal of the SUBs or death). An infection was recorded as resolved if there was a negative bacterial culture taken after cessation of antibiotics from a sample obtained either

through the subcutaneous port or via a cystocentesis sample if the SUB was blocked or if the SUB was removed, taken 7 days after stopping antibiotics. Cause of death or euthanasia was recorded where appropriate. Date of last contact (either alive or dead) was noted.

Statistical analysis

A Shapiro–Wilk test revealed that the continuous data were not normally distributed; this was confirmed by visual inspection of a histogram for each data set. Descriptive data are reported as median (range). Analysis of survival was performed using Kaplan Meier curves and log rank tests. To look for associations between continuous variables (potassium concentration, PCV, creatinine) and survival, the variable was explored using previously established reference intervals. PCV was divided into three groups: <25%, 25 to 45% and >45%. Potassium was divided into three groups: <3.5 mmol/L, 3.5 to 5.8 mmol/L and >5.8 mmol/L. Creatinine was divided based on the IRIS classification cut-off for stage 4 of acute kidney injury (groups of <440 and ≥400 μmol/L; www.iris-kidney.com/guidelines/grading). For comparisons where statistically significant differences in survival between groups were detected, log rank hazard ratios for death were calculated. Statistical significance was set at $P < 0.05$.

RESULTS

Ninety-nine cats had SUBs placed between April 2012 and June 2017; four of these cats were excluded as the obstruction was secondary to iatrogenic ligation following ovariohysterectomy surgery (three cats) or trauma (one cat) leaving 95 cats enrolled in the study. Sixty cats had unilateral SUBs placed (left 32 cats, right 28 cats) and 35 cats had bilateral SUBs placed (pant port eight cats, two independent SUBs 27 cats).

Seventy-eight cats had ultrasound performed to reach a diagnosis; 13 cats had ultrasound and an antegrade pyelogram, two cats had ultrasound and radiographs, one cat had a computed tomographic (CT) scan and one had ultrasound and a CT.

Pre-operative blood test results

Median creatinine at presentation was 734 μmol/L (range 127 to 2070) [reference interval (R.I.) 53 to 212 μmol/L]; 92% cats had creatinine >140 μmol/L at presentation (to convert μmol/L to mg/dL, divide by factor 88.42). Median potassium concentration at presentation was 4.9 mmol/L (2.3–11.2) [R.I. 3.4–5.6 mmol/L]; 29% were hyperkalaemic (>5.8 mmol/L) at presentation. Median PCV was 30% (range 16 to 47) (R.I. 25 to 45%); 26% were anaemic at presentation.

Surgical time

Median surgical time was 115 minutes (range 45 to 420) and median anaesthesia time was 185 minutes (range 95 to 530).

Technical difficulties

It was challenging to achieve glue adhesion between the catheters, blue boots and legs of the port in four cats due to excessive

urine production; the glue required a dry field to form a seal. This was in accordance with the original guidelines; the most recent update recommends no glue is applied at the junction between the catheters and port. To halt the flow of urine past the joint, two cats had digital occlusion of nephrostomy catheter temporarily and in two cats, a Huber needle was placed in the port to relieve some pressure (recorded as minor complications).

During surgery, there was urine leakage at the junction of the kidney and nephrostomy catheter in five cats; this was identified by intra-operative fluoroscopy demonstrating contrast leaking underneath the renal capsule. The catheter was advanced further gently into the renal parenchyma and more glue was applied, in case there was a fenestration sat inside the parenchyma. In one cat, this did not resolve the leakage but no further action was taken and there were no consequences (classified as four minor complications). In the fifth cat, a peninsular flap of the transverse abdominus muscle was wrapped around the junction of the kidney and catheter, then sutured to itself (classified as minor complication). A Jackson Pratt drain was placed for 48 hours and no further leakage was noted (daily peripheral and fluid creatinine values were compared). Glue was applied liberally in all cases.

There was profuse haemorrhage from the renal pelvis intra-operatively (assumed trauma to renal vein branch) in three cats. One cat had no consequences as a result (minor complication). In one cat, the nephrostomy catheter became obstructed with blood clots, which required revision surgery 24 hours later (major complication); the catheter was flushed and unblocked but the catheter re-obstructed and the cat was euthanised. The third cat had a nephrostomy catheter replaced intra-operatively at a different site as blood clots partially obstructed the catheter (minor complication).

In two cats, the tip of the nephrostomy catheter coiled through the dorsal surface of the kidney, which was not identified at the original surgery. In one cat this was identified 2 days post-operatively by subcapsular contrast leakage; the nephrostomy catheter was partially withdrawn and the hole in the kidney sealed with a Dacron cuff and glue. In another cat, this was identified 10 days post-operatively; the cat was euthanised for financial and welfare reasons (both major complications). To avoid this, in subsequent cases, intra-operative fluoroscopy was carefully scrutinised after coiling the pigtail of the nephrostomy catheter to identify any subcapsular leaks.

The pigtail of nephrostomy catheter was difficult to coil in the renal pelvis and folded back on itself in two cats. This was identified intra-operatively in one cat where the catheter was replaced (minor complication). In the other cat, this led to obstruction of the nephrostomy catheter post-operatively once the renal pelvis decreased in size (Fig 1A,B). A revision surgery was declined by the owners and the cat was euthanised (major complication). Subsequently, if at intra-operative fluoroscopy, a backwards coil was noted, the nephrostomy catheter was discarded and a new one placed.

One cat had a very small renal pelvis diameter (3 mm) but marked proximal ureter dilatation and so the pigtail was placed loosely in the proximal ureter via the lateral aspect of the kidney (not recorded as a complication).

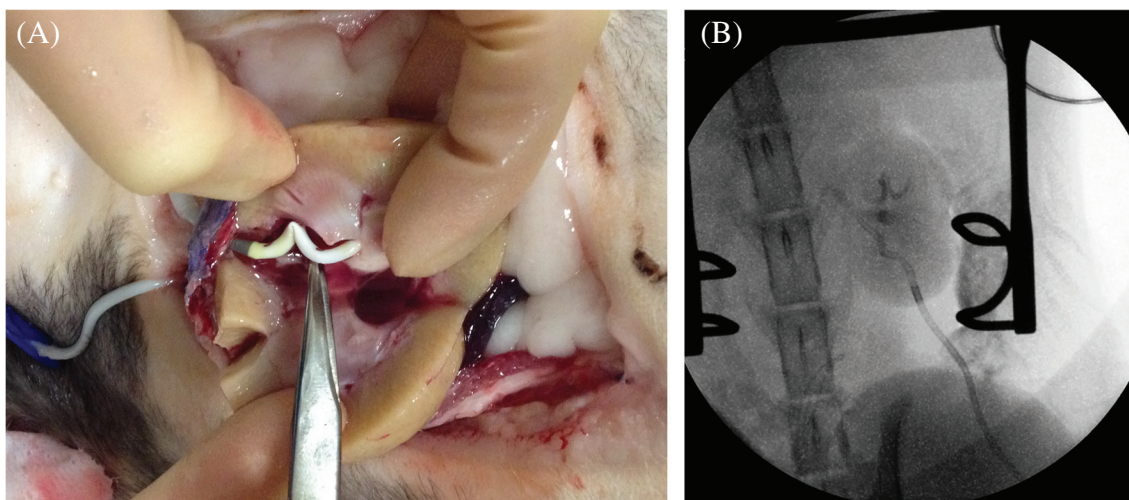


FIG 1. (A) Post-mortum picture of a kidney transected longitudinally. The black radio-opaque marker is located just within the renal parenchyma and all perforations are proximal to this point. When the locking string of the nephrostomy tube was tightened, the tube became fixed in a “W” shape rather than a pigtail. Once the renal pelvis size reduced in the weeks following surgery, the proximal holes became obstructed by the kink and the nephrostomy tube was unable to drain. (B) The original fluoroscopic image allowed retrospective identification the backwards kink. This image shows the “W” shape of the tip of the nephrostomy tube within the renal pelvis after tightening of the locking loop. The black radio-opaque marker can be seen inside the renal parenchyma in the correct position

Leakage from the pre-operative antegrade pyelogram site occurred in another cat, which was unable to be sealed with glue. A Jackson Pratt drain was placed for post-operative management; further leakage was not observed and the drain was removed after 48 hours (minor complication). In another case, subcapsular leakage of contrast was identified around the nephrostomy catheter intraoperatively, which was unable to be sealed. Again, a Jackson Pratt drain was placed intra-abdominally and there were no apparent consequences, with successful drain removal after 32 hours (minor complication).

Post-operative blood test results

Median creatinine at discharge was 215 $\mu\text{mol/L}$ (range 69 to 1157) and 3 months post-operatively was 205 $\mu\text{mol/L}$ (105 to 1014). IRIS categorisation of creatinine scores was 1 (six cats; 17%), 2 (21 cats; 60%), 3 (seven cats; 20%), 4 (one cat; 3%).

In-hospital mortality

Ten cats did not survive to discharge (10.5%); of these cats the median survival was 3 days (range 1 to 9). Two cats had obstruction of the nephrostomy catheter by blood clots. Three had an acute kidney injury on recovery from anaesthesia (recorded as major complications). Four cats were euthanised due to deteriorating renal function and one cat suffered a cardiopulmonary arrest 2 days after surgery, despite decreasing creatinine (recorded as a major complication, although possibly unrelated).

Out of hospital mortality

Of the 85 cats that survived to discharge, nine were lost to follow up. Forty-one cats died or were euthanised after discharge (42%); the median survival time of these cats was 530 days (range 7 to 1915). Identifiable causes of euthanasia or death after discharge included chronic kidney disease (11), unrelated disease (nine),

infection (seven), catheter blockage (six), cardiopulmonary arrest after revision surgery to remove an infected SUB (one), and severe cystitis caused by cystostomy catheter irritation on bladder mucosa (1; recorded as major complication). In six cats, no cause of mortality was identified.

Urinary tract infections

Pre-operative or intra-operative urine culture

Twelve cats were diagnosed with a UTI pre- or intra-operatively (see Fig 2). All cats diagnosed with a UTI were discharged with oral antibiotics depending on culture results for a period of 4 to 6 weeks at the discretion of the clinician. Repeat urine culture was obtained 1 week after stopping the antibiotics.

The outcome of these cats are presented in Fig 3. Three cats had resolution of the infection (*Escherichia coli*, *Bacillus* and *Enterococcus* spp. infections; minor complications); the cat with *E. coli* infection had a subsequent infection with *Staphylococcus* spp., which required SUB removal (major complication).

Urinary catheters were placed in 10 cats to monitor urine output post-operatively as there was evidence of severe hypotension intra-operatively; none of these cases had post-operative UTIs.

Post-operative urine culture results

Twenty-seven cats were diagnosed with a UTI post-operatively (Fig 2); 14 cats were female and 13 were male. Four of these cats had resolution of the infection (two cats with *E. coli*, one with *E. coli* and Diphthoid bacteria, one cat with *Enterococcus* spp.; minor complications). One cat had an *E. coli* UTI, which became a multidrug resistant *E. coli* and *Enterococcus* infection diagnosed 20 months after surgery. The SUB was removed 23 months after the original surgery where a portion of jejunum was adhered to and commu-

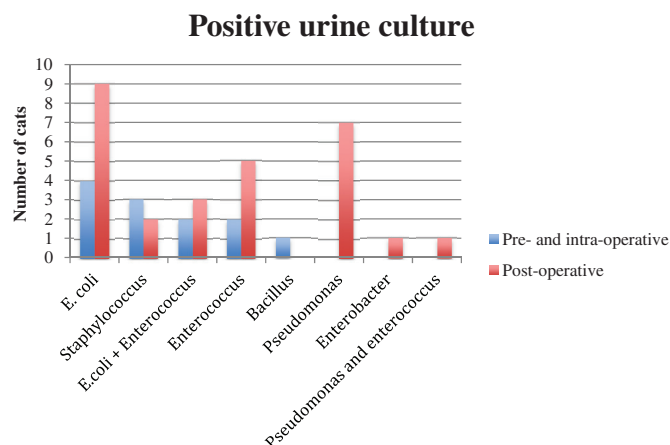


FIG 2. Bar chart illustrating the number of cats diagnosed with a specific bacterial UTI. Cats were grouped into whether the infection was diagnosed pre- or intra-operatively or at any point post-operatively from either cystocentesis or pyelocentesis samples

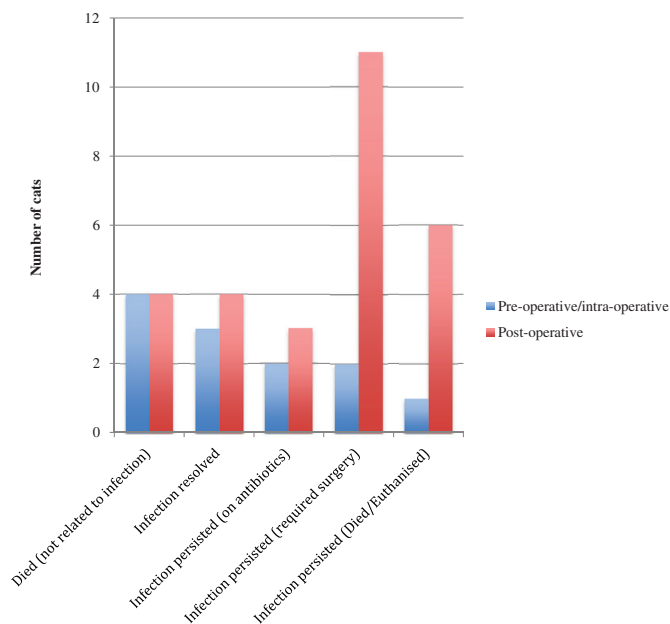


FIG 3. Bar chart illustrating the outcome of cats diagnosed with a UTI either pre-operatively/intra-operatively or post-operatively

nicating with the bladder at the site of the cystostomy catheter (enterovesicular fistula). The SUB was removed and a resection and anastomosis plus partial cystectomy performed (major complication); the SUB was not replaced. The UTI did not reoccur.

Revision surgery

Thirty-two revision surgeries were performed in 26 cats (all classified as major complications). Reasons for revision surgery included infection (13 cats; 14%), kinked catheter (five cats; 5%), catheter failure (five cats; 5%), blocked catheter (four cats; 4%), subcutaneous urine leakage (two cats; 2%), blood clots (two cats; 2%) and subcapsular urine leakage (one cat; 1%). Four cats (4%) had multiple revision surgeries: one cat underwent three revision surgeries and three cats underwent two revision surgeries. The cat that had three surgeries had a subcapsular leak caused by dorsal perforation

of the nephrostomy catheter tip, a fractured cystostomy catheter which was replaced and a ureteronephrectomy and SUB removal following multidrug resistant *E. coli* UTI; the cat was alive at study completion 1809 days after the original surgery. There were nine cases (9.5%) where a revision surgery was advised but the owners declined further surgery for financial or welfare reasons.

The site of kinking of the catheter consistently was at the point where the catheter crossed the abdominal wall. Before the surgical technique for placement of the port tubing at that level was changed (see Materials and Methods), 6 of 30 (20%) of the cats that had SUBs placed experienced an episode of kinking [causing obstruction in four cats (major complication)]. Kinks occurred a median of 326 days after the original surgery (range 87 to 828 days). Following a change in surgical technique, where only a minimal length of tubing (<1 cm) remained subcutaneously, only 6 of 65 (9%) of the cats experienced kinking of their SUB [causing obstruction in three cats (major complication)].

Overall complication rates

Minor complications occurred in 18 cats (19%) and major complications occurred in 46 cats (48%), the majority of which were after hospital discharge. Fourteen cats (15%) had a complication related to technical or iatrogenic complications, including the seven cats that had kinks prior to changing the technique, six cats that had blocked catheters, one cat had the cystostomy catheter snap, and in one cat the cystostomy catheter became detached from the Dacron cuff on the bladder.

When cats were divided into cases that occurred in the first, second and third time periods of the study, the major and minor complication rates combined were 36.4, 27.2 and 36.4%, respectively.

Survival analysis

Of the 95 cats where follow-up data were available, 51 cats were dead at the time of data analysis; an event rate of 54%. The remainder were alive (n=35) or lost to follow up (n=9). Median survival time for all cats post-operatively was 820 days (range 1 to 1915 days). A significant association between long-term survival and creatinine at presentation was identified. The median survival time for cats presenting with creatinine concentration $\geq 440 \mu\text{mol/L}$ (International Renal Interest Society acute kidney injury [AKI] grade 4 and 5) was 530 days (95% CI 273 to 787 days), compared to a median survival time of 949 days (95% CI 655 to 1243 days; Log Rank $P=0.024$) for those cats presenting with creatinine $< 440 \mu\text{mol/L}$ (IRIS stage AKI 1 to 3).

There was no statistically significant association between survival time and either potassium ($P=0.28$) or PCV ($P=0.056$) and survival time. Nor was a significant association detected between survival and number of SUBs placed (unilateral *versus* bilateral; $P=0.384$). There was no significant association between cats experiencing blockage, infection or requirement for revision surgery and survival time.

DISCUSSION

In this population of cats undergoing SUB placement to treat benign ureteral obstruction, the major complication rate was

48%; most of which (32/46) occurred after discharge from hospital. With adequate monitoring and addressing complications as they occurred, long-term survival was favourable, with a median survival time exceeding 2 years. This suggests that the majority of complications are manageable.

The high overall complication rate is likely to reflect a number of factors, including human factors (such as the learning curve of staff, and the fact that the procedure was performed by all members of faculty rather than a single operator) and also device-related factors (blockage due to mineralisation or blood clots, or infection). In addition, we have chosen to report any complication that occurred for the remainder of a cat's life, rather than impose a time limit or consider late complications differently. Although, because of the phenomenon of a learning curve, it makes sense that complication rate would be lower if more recent patient data were analysed, the incidence of complications in the first and last third of our study period was the same (with the exception of kinked tubing). This suggests two possibilities: first, as some technical challenges are overcome, more will arise. For example, in the second half of the study, the number of kinks was substantially lower due to a change in technique. Secondly, a proportion of device-related complications are simply unavoidable, such as mineralisation and infection. In addition, other complications such as the enterovesicular fistula were not related to technical errors or a learning curve. The current study includes cases that had the original SUB placed; an updated version (SUB 2.0™) has been developed which has a SwirlPort™ that is larger than the original subcutaneous port and a locking loop cystostomy catheter; this may have a lower rate of blockage, so could help reduce complication rates overall.

It is likely that complication rates from different centres will be reported differently, which argues for the creation of a centralised database of patients undergoing the SUB procedure. If appropriately used, this could provide large-scale data on complications from centres worldwide and allow a more complete analysis of factors in a standardised way, and help identify any issues with particular components or batches of equipment, in addition to assisting surgeons in better understanding what level of complications are occurring in other centres as part of clinical audit.

The high complication rate must be taken in light of the fact that the majority of cats would have been euthanised after diagnosis of ureteric obstruction bilaterally or unilateral obstruction with an end stage contralateral kidney. It highlights the importance of owner communication and informed consent as there is the ongoing aftercare with regards to SUB flushes, a chance of a revision surgery or developing a persistent UTI. This transparent reporting of complications from our centre highlights that careful intra-operative scrutiny of the fluoroscopic images, strict adherence to the current SUB guidelines and strict aseptic technique are all essential. Although SUB placement is a clean-contaminated procedure (or contaminated if there is a UTI present), it may be prudent to consider using antibiotics perioperatively as infection of devices can be catastrophic. There are certainly technical difficulties that have been avoided in subsequent cases, such as the backwards coiling of the nephrostomy catheter.

Two cats in this study had obstruction of the nephrostomy catheter by blood clots. At the original surgery, there was profuse haemorrhage after placement of the initial catheter and an antegrade pyelogram also revealed contrast in the renal vein. Both cats had a revision surgery to replace the nephrostomy catheter but the blockage recurred 1 day and 3 days post-operatively and the cats were euthanised. The use of tissue plasminogen activator (TPA) infusion into the SUB prior to replacing the nephrostomy catheter has been described (Norfolk Vet Products n.d.); this was not available in the hospital during the study period but would be used in subsequent cases should the complication occur again.

Catheter kinks represented a high proportion of complications, however the change in technique to have minimal tubing in the subcutaneous space meant the rate reduced from 13 to 2%. This may represent the normal learning curve when a new technique is introduced, however it is possible that placing a shorter length of tubing through the body wall may reduce the incidence of kinking. Originally, approximately 1-5 cm of tubing was placed in the subcutaneous space; once the guidelines changed, less than 1 cm was left in the subcutaneous space. However, because kinking was still noted despite the change in technique, adhering to the most recently published guidelines is still recommended. For bilateral obstructions, the use of a "pants" port is no longer recommended because of the increased chance of obstruction caused by a single cystostomy catheter.

Careful scrutiny of intra-operative images was essential to avoid some of the initial complications encountered such as the nephrostomy catheter puncturing the dorsal wall of the kidney, back bending of the nephrostomy catheter and subtle urine leakage. If there was any haemorrhage following placement of the nephrostomy catheter, the tube was gently flushed. If blood clots obstructed the catheter then it was replaced. Glue was applied liberally with care to ensure it encircled the joints between the Dacron cuff and the kidney/bladder, both catheters and the port and the catheters and blue boots. The guidelines have changed and it is no longer recommended to use glue between the blue boots and the port; although there were cases where there was urine leakage at the junction of both the cystostomy catheter and nephrostomy catheter with the port prior to glue placement despite cutting the pigtail suture flush with the end of the tubing.

An association between higher creatinine concentration and reduced survival time has previously been reported (Horowitz *et al.* 2013, Kulendra *et al.* 2014, Berent *et al.* 2018). Here, creatinine $\geq 440 \mu\text{mol/L}$ (IRIS stage IV and V AKI) at presentation had a shorter survival time than cats with lower creatinine. This highlights the utility of creatinine pre-operatively in case selection. One recent study (Berent *et al.* 2018) reported that post-operative IRIS stage was associated with survival, but if pre-operative creatinine concentration were useful, as appears to be the case based on our data, then this would assist the clinician in decision making and managing owner expectations.

The incidence of post-operative infection was found to be high in this population [27/85 cats surviving to discharge (31%)]. Cats with chronic kidney disease are prone to infection with an incidence of 17 to 33% (Mayer-Roenne *et al.* 2007,

Bailiff *et al.* 2008, Reynolds & Lefebvre 2013, Kopečný *et al.* 2017), therefore the incidence in our population of cats is not unexpected. It is hypothesised that the implant acts as a nidus for bacteria. The SUB device is constructed of polyurethane catheters with Dacron cuffs and the port is made from titanium (Norfolk Vet Products n.d.). Polyurethane is used commonly for urinary catheters in humans and bacteria are able to form a biofilm on this material (Francolini & Donelli 2010). Biofilm-based infections are associated with higher levels of bacterial resistance compared to infections elsewhere (Francolini & Donelli 2010). In this study, there were four cats where the bacteria [*E. coli* (two) and *Pseudomonas* (two)] developed anti-microbial resistance. Three of these cats required SUB removal and one cat died from bacterial sepsis. Cats were advised to have the SUB removed if the infection became multi drug resistant, they had multiple episodes of pyrexia and inappetance secondary to the infection, there was a deterioration in creatinine and increased renal pelvis size or if the infection persisted despite prolonged antibiotic usage.

The current procedural recommendations include flushing the SUB prior to discharge with tetra-EDTA (T-FloLoc™; Norfolk Vet Products), which is an antibacterial solution that prevents biofilm production and is also an anticoagulant. It is possible that this solution may have prevented infections in the population of cats in this study, had it been recommended for use at that time. If there is partial blockage of a catheter, the current recommendations involve flushing with T-FloLoc, however, if the catheter is completely blocked then it is unlikely that the solution will be able to clear the obstruction. A blocked catheter is only replaced if the ureter is obstructed (as observed on an antegrade pyelogram) or if there is evidence of ongoing and clinically significant UTI. If the ureter is patent, the blocked catheter can be left in situ as long as there is no ongoing UTI. The rate of chronic UTI in the Norfolk Vet Products guidelines was 8%; the use of tetra-EDTA (T-FloLoc; Norfolk Vet Products) for SUB flushing may have reduced the rate of catheter mineralisation and bacterial colonisation and is now recommended on all SUB flushes at this hospital.

The decision to remove a SUB device was not undertaken lightly because of the chance of re-obstruction of the ureter. Prior to removal, the patency of the ureter was documented on injection of iohexol into the shunting port or via antegrade pyelogram. Removal consisted of dissecting out the subcutaneous port, uncoiling the pigtail catheter and gently removing it from the kidney. A horizontal mattress suture of 4/0 PDS was placed in the renal capsule to prevent urine leakage. A partial cystectomy enabled the cystostomy catheter to be removed in its entirety. In four cases, severe pyelonephritis and renal abscess formation meant a ureteronephrectomy had to be performed. Antibiotics were continued in these cats until a negative culture was obtained by cystocentesis. In two cats, after SUB removal, there was persistence of the UTI. As the bacteria were only sensitive to nephrotoxic antibiotics and the cats were not clinically affected, no further therapy was advised. When the SUB is removed, there is often mineralised debris associated with the nephrostomy catheter and it is possible remaining debris acts as a nidus for infection inside the renal pelvis.

Only three cats had clinical signs of dysuria following the surgery and is comparable to the 8% reported in the study by Berent *et al.* (Berent *et al.* 2018). This is significantly lower than the incidence of dysuria following ureteral stent placement where 40% of cats were affected and 3 of 26 were euthanised due to the severity of the signs (Kulendra *et al.* 2014). Cats undergoing ureteral surgery where stents were placed had a higher rate of urinary tract signs compared to cats that did not have stents placed (Wormser *et al.* 2016). Two out of three cats with SUBs that had dysuria only showed mild signs, which is likely due to the fact that the part of the implant that lies within the bladder is situated at the apex. In cats, the ureteral openings are located caudally and the stents likely irritated the proximal ureter as well as the bladder. One cat in this study was euthanised as a result of lower urinary tract signs; at necropsy, an ulcer in the mucosa of the bladder was identified as a result of erosion from the tip of the cystostomy catheter. The tip of the cystostomy catheter had not been shortened. The design of the tip of the cystostomy catheter has subsequently been modified to a pigtail tip, which means that it is unlikely to rub on the bladder mucosa.

In one case, a novel complication was reported whereby a loop of jejunum formed a fistula with the bladder at the level of the cystostomy catheter. This cat had a blocked nephrostomy catheter 18 months after the original surgery and developed dysuria. *Enterococcus faecalis* and *E. coli* were cultured from a urine sample obtained from the shunting port. The cat had persistent clinical signs and the SUB was removed after 6 weeks of unsuccessful antibiotic therapy following demonstration of patency of both ureters. The fistula was not identified on positive contrast radiography immediately prior to the revision surgery.

Limitations of the study were typical of a retrospective case series; related to the accuracy of record keeping and the inherent variability of data collection and case management. Biochemical analysis was performed on multiple analyzers, which may have affected results. The follow up was inconsistent; in most cases it was performed at routine or emergency appointments. In some cases, follow up was performed at referring veterinarian's practices and information was obtained from telephone conversations or electronic records.

In summary, ureteral obstruction remains a challenging condition to manage. In this population of cats, SUBs were associated with a high prevalence of complications but a median survival time exceeding 2 years, suggesting that most complications were manageable. Greater creatinine concentration at discharge and at 3 months post-operatively was associated with a worse prognosis.

Conflict of interest

None of the authors of this article has a financial or personal relationship with other people or organisations that could inappropriately influence or bias the content of the paper.

References

- Adin, C. A., Herrgesell, E. J., Nyland, T. G., *et al.* (2003) Antegrade pyelography for suspected ureteral obstruction in cats: 11 cases (1995-2001). *Journal of the American Veterinary Medical Association* **222**, 1576-1581. <http://doi.org/10.2460/javma.2003.222.1576>

- Bailliff, N. L., Westropp, J. L., Nelson, R. W., et al. (2008) Evaluation of urine specific gravity and urine sediment as risk factors for urinary tract infections in cats. *Veterinary Clinical Pathology* **37**, 317-322. <http://doi.org/10.1111/j.1939-165X.2008.00065.x>
- Berent, A. C., Weisse, C. W., Todd, K., et al. (2014) Technical and clinical outcomes of ureteral stenting in cats with benign ureteral obstruction: 69 cases (2006-2010). *Journal of the American Veterinary Medical Association* **244**, 559-576. <http://doi.org/10.2460/javma.244.5.559>
- Berent, A. C., Weisse, C. W., Bagley, D. H., et al. (2018) Use of a subcutaneous ureteral bypass device for treatment of benign ureteral obstruction in cats: 174 ureters in 134 cats (2009-2015). *Journal of the American Veterinary Medical Association* **253**, 1309-1327. <http://doi.org/10.2460/javma.253.10.1309>
- Debruyn, K., Haers, H., Combes, A., et al. (2012) Ultrasonography of the feline kidney: technique, anatomy and changes associated with disease. *Journal of Feline Medicine and Surgery* **14**, 794-803. <http://doi.org/10.1177/1098612X12464461>
- Dirrig, H., Lamb, C. R., Kulendra, N., et al. (2020) Diagnostic imaging observations in cats treated with the subcutaneous ureteral bypass system (SUB™). *Journal of Small Animal Practice* **61**, 24-31
- Francolini, I. & Donelli, G. (2010) Prevention and control of biofilm-based medical-device-related infections. *FEMS Immunology and Medical Microbiology* **59**, 227-238. <http://doi.org/10.1111/j.1574-695X.2010.00665.x>
- Hardie, E. M. & Kyles, A. E. (2004) Management of ureteral obstruction. *Veterinary Clinics of North America - Small Animal Practice* **34**, 989-1010. <http://doi.org/10.1016/j.cvsm.2004.03.008>
- Horowitz, C., Berent, A., Weisse, C., et al. (2013) Predictors of outcome for cats with ureteral obstructions after interventional management using ureteral stents or a subcutaneous ureteral bypass device. *Journal of Feline Medicine and Surgery* **15**, 1052-1062. <http://doi.org/10.1177/1098612X13489055>
- International Renal Interest Society. (2019) <http://www.iris-kidney.com>. Accessed 27th August 2020
- Kopecny, L., Palm, C. A., Drobatz, K. J., et al. (2017) Risk factors for urinary tract infections in cats after ureteral stent and ureteral bypass placement. *Journal of Veterinary Internal Medicine* **31**, 1225-1361. <http://doi.org/10.1111/jvim.14778>
- Kulendra, N. J., Syme, H., Benigni, L., et al. (2014) Feline double pigtail ureteric stents for management of ureteric obstruction: short- and long-term follow-up of 26 cats. *Journal of Feline Medicine and Surgery* **16**, 985-991. <http://doi.org/10.1177/1098612X14531763>
- Kyles, AE, Hardie, EM, Wooden, BG, et al. (2005) Management and outcome of cats with ureteral calculi: 153 cases (1984-2002). *Journal of the American Veterinary Medical Association* **226**, 937-944.
- Mayer-Roenne, B., Goldstein, R. E. & Erb, H. N. (2007) Urinary tract infections in cats with hyperthyroidism, diabetes mellitus and chronic kidney disease. *Journal of Feline Medicine and Surgery* **9**, 124-132. <http://doi.org/10.1016/j.jfms.2006.09.004>
- Norfolk Vet Products. (n.d.). The SUB A Subcutaneous Ureteric ByPass System Norfolk Vet products. (2019) <http://norfolkvetproducts.com/products/sub/> Accessed August 2020
- Reynolds, B. S. & Lefebvre, H. P. (2013) Feline CKD: pathophysiology and risk factors – what do we know? *Journal of Feline Medicine and Surgery* **1**(S1), 3-14. <http://doi.org/10.1177/1098612X13495234>
- Steinhaus, J., Berent, A. C., Weisse, C., et al. (2015) Clinical presentation and outcome of cats with circumcaval ureters associated with a ureteral obstruction. *Journal of Veterinary Internal Medicine* **29**, 63-70. <http://doi.org/10.1111/jvim.12465>
- Wormser, C., Clarke, D. L. & Aronson, L. R. (2016) Outcomes of ureteral surgery and ureteral stenting in cats: 117 cases (2006-2014). *Journal of the American Veterinary Medical Association* **248**, 518-525. <http://doi.org/10.2460/javma.248.5.518>
- Zaid, M. S., Berent, A. C., Weisse, C., et al. (2011) Feline ureteral strictures: 10 cases (2007-2009). *Journal of Veterinary Internal Medicine* **25**, 222-229. <http://doi.org/10.1111/j.1939-1676.2011.0679.x>