



Allsop, S., Gandhi, S., Ridley, N. T. F., & Spear, M. (2020). Implementing ultrasound sessions to highlight living anatomy for large medical student cohorts. *Translational Research in Anatomy*, 22 (2021), [100088]. <https://doi.org/10.1016/j.tria.2020.100088>

Publisher's PDF, also known as Version of record

License (if available):
CC BY-NC-ND

Link to published version (if available):
[10.1016/j.tria.2020.100088](https://doi.org/10.1016/j.tria.2020.100088)

[Link to publication record in Explore Bristol Research](#)
PDF-document

This is the final published version of the article (version of record). It first appeared online via Elsevier at <https://doi.org/10.1016/j.tria.2020.100088> . Please refer to any applicable terms of use of the publisher.


University of Bristol - Explore Bristol Research

General rights

This document is made available in accordance with publisher policies. Please cite only the published version using the reference above. Full terms of use are available: <http://www.bristol.ac.uk/red/research-policy/pure/user-guides/ebr-terms/>

Contents lists available at [ScienceDirect](https://www.sciencedirect.com)

Translational Research in Anatomy

journal homepage: www.elsevier.com/locate/tria

Implementing ultrasound sessions to highlight living anatomy for large medical student cohorts



Sarah Allsop^{a,*}, Sanjay Gandhi^b, Nicholas Ridley^c, Michelle Spear^a

^a School of Anatomy, Faculty of Health Sciences, University of Bristol, Southwell Street, Bristol, BS2 8EJ, UK

^b Radiology Department, North Bristol NHS Trust, Southmead Hospital, Southmead Road, Westbury-on-Trym, Bristol, BS10 5NB, UK

^c Radiology Department, Great Western Hospitals NHS Trust, Marlborough Road, Swindon, SN3 6BB, UK

ARTICLE INFO

Keywords:

Anatomy
Undergraduate medical education
Ultrasound
Medical students
Radiology
Curriculum development

ABSTRACT

Background: There is an intrinsic link between radiology and anatomy and the importance of being able to convert knowledge from 3D structure to 2D image, and vice versa. Medical students must learn how to use anatomical knowledge to interpret radiological images, and with the increasing use of point-of-care ultrasound in clinical practice, the ability to interpret ultrasound scans is becoming more of a core skill for graduating doctors.

Rationale: Several recent systematic reviews of the literature have been undertaken showing the benefits of incorporating ultrasound in anatomy teaching, including appreciation of the dynamic nature of living anatomy, better understanding of anatomical structure, and improved motivation to study. However, there is a lack of consensus in the way ultrasound teaching should be incorporated into undergraduate medical anatomy.

Approach: This article reflects on a pilot of integrating ultrasound into the medical undergraduate anatomy teaching in the School of Anatomy at the University of Bristol. It shares the experience and how some of the challenges cited in the literature have been approached.

Recommendation: To help others negotiate the challenges of implementing this valuable teaching experience, a 'Six Step Model' for developing a live ultrasound pilot for undergraduate medical anatomy is offered: Expertise, Education, Ethics, Environment, Equipment, Enlist.

1. Introduction

1.1. Ultrasound in medical education and practice

The interpretation of radiology images, including ultrasound, is a key way medical students will use anatomical knowledge throughout their careers [1,2]. There is growing use of ultrasonography at the point of care in clinical medical practice, especially in improving the safety of clinical procedures, for example chest drain and central line insertion [3]. Advantages of ultrasonography include that it is non-invasive, has no exposure to ionising radiation, is quick to perform (by a skilled operator) and produces high quality images on devices which can be easily portable.

The use of ultrasound within undergraduate medical education is also longstanding, with practical ultrasound teaching being reported in the literature since the 1990's [4,5]. Live ultrasound has the added advantage of showing the movement of structures and the dynamic status of the human body, features which may be lost in the traditional

teaching setting of the anatomy cadaver lab.

Integration of ultrasound within medical curricula was reported in around 62% of US Medical Schools in a national survey in 2014 [6]. In the UK, the current literature is suggestive that many UK based institutions are also incorporating ultrasound teaching into their curricula, both in anatomy and point of care ultrasound training [7–9]. The UK General Medical Council's national guidance document for undergraduate training, Outcomes for Graduates (2018), makes no specific mention of radiological techniques, but more generally recommends that medical graduates must understand the principles behind choosing appropriate investigations for their patients and must be able to interpret the results [10].

Whilst this leaves scope for individual medical schools to develop and innovate, it does not give a strong message as to the place of ultrasound within the curriculum. The literature highlights variability in how ultrasound teaching is incorporated in different institutions, including differences in topics, methods and amount and timing of delivery [11–13]. Regardless of the delivery style, ultrasound teaching is

* Corresponding author.

E-mail address: sarah.allsop@bristol.ac.uk (S. Allsop).

<https://doi.org/10.1016/j.tria.2020.100088>

Received 14 May 2019; Received in revised form 5 September 2020; Accepted 9 September 2020

Available online 12 September 2020

2214-854X/ © 2020 The Authors. Published by Elsevier GmbH. This is an open access article under the CC BY-NC-ND license (<http://creativecommons.org/licenses/by-nc-nd/4.0/>).

reported as being well received by medical students [14–16].

Ultrasound is also being used, both as a teaching tool and as training for use diagnostically [17]. Patel et al. (2017) showed that those programmes implementing such teaching earlier, were aiming to support students to become familiar with interpreting imaging, introduce them to ultrasound technology, and were using the technique as an adjunct to other teaching modalities in anatomy. Those programmes using ultrasound teaching later were more likely to be doing so in a clinical setting, demonstrating point of care ultrasound to teach more practical ultrasound skills to students [12]. Regardless of setting interpreting the visualised anatomy remains central.

1.2. Incorporating ultrasound in medical anatomy teaching

Using ultrasound within anatomy teaching in undergraduate medical education has been explored by multiple approaches over the past 30 years [5]. Whilst there is both agreement and evidence that ultrasound should be integrated into medical undergraduate anatomy teaching [6,12], there is limited consensus on when and how this should happen [11]. There is variation seen between institutions, ranging from single teaching sessions to whole courses and in delivery methods, from watching short video clips, through to independently performing scans. Feedback is consistent across the methods, with students reporting ultrasound useful and interesting in enhancing anatomy education, and in linking anatomy knowledge to clinical practice [7,12,18]. However, there remains limited evidence on the long term impact of the integration of ultrasound teaching [11–13,19].

Examples of institutions who have published their ultrasound curricula include West Virginia University School of Medicine, University of South Carolina School of Medicine, Ohio State University, and at School of Medicine at Leeds, UK [20–23].

1.2.1. Advantages of using ultrasound to teach anatomy

The list of key advantages cited in one of the first reported uses of ultrasound for anatomy teaching by Teichgräber et al. (1996), still holds as an excellent list today [4]. These are quoted directly as:

- *Juxtaposition of dynamic topography of anatomy on the living and static topographic situation in cadavers*
- *Comparison of the topography of young adults and of elderly individuals (anatomy of cadavers)*
- *Juxtaposition of a modern imaging method and a classical anatomic dissection*
- *Accurate determination of organ sizes*
- *Comparison of cross-sectional ultrasound images and anatomical cadaver cross-sections*
- *Depiction of topographical relations of vessels and organs, with consideration of physiological phenomena (e.g. respiratory variations of the portal vein)*
- *Motivation to study anatomy, since more clinically oriented teaching encourages the students to strengthen their knowledge in anatomy*
- *Improvement of the three-dimensional anatomical imagination*

Table 1

Challenges of using ultrasound to teach anatomy.

Curriculum/Teaching issues	Equipment issues	Participant issues
Time available in curricula [14]	Availability of equipment [15]	Difficulty of interpreting images [24]
Focus of teaching, for core focus on anatomy or training on how to use ultrasound [25]	Size of viewing screen/quality of image on ultrasound machines [16]	Potential safety hazards from repeated scanning of individuals [26]
Training and competency issues of staff [8]		Discovery of pathology/conditions in volunteer models requiring further investigation [26]
Hands-on versus demonstrated teaching [12]		
Cohort/class sizes [15]		

1.2.2. Challenges of using ultrasound to teach anatomy

With decreasing space within modern medical curricula for any single discipline and increasing student numbers, innovation can be difficult. Examples of challenges when incorporating live ultrasound teaching into anatomy cited in the literature are summarised in Table 1.

Much of the literature offers recommendations about how to manage some of these challenges, and Griksaitis et al. (2014) [27] offers an excellent set of twelve tips for implementing ultrasound teaching in the undergraduate medical curriculum.

In this article we share our experience, how we dealt with challenges during our initial pilot of live ultrasound into the medical anatomy curriculum at the University of Bristol School of Anatomy and offer a model for integrating live ultrasound sessions in anatomy.

1.3. Ultrasound use during medical anatomy teaching at the University of Bristol

Medical anatomy teaching at Bristol is led by a skilled team of educators with both anatomical and clinical experts. Most of the anatomy teaching is delivered in the first two years of the medical programme. A multi-modal approach is used, utilising cadaveric, pathological and osteological specimens alongside modern radiological imaging techniques, as well as online resources, textbooks and student workbooks. Topographical and applied anatomy are taught together, including surface anatomy, and the anatomical knowledge underpinning safe clinical examination and procedures. This aims to guide medical students to learn anatomy in the context of their future medical practice.

Prior to 2016, our students had limited exposure to live ultrasound during the early years of medical training, and none during anatomy teaching. At that time there was a drive from the medical school to increase the amount of ultrasound teaching for medical students. Over a 2-year period a pilot was undertaken to introduce a live ultrasound demonstration as part of the radiology section of the gastrointestinal anatomy teaching for year 2 medical students. The 30-min live ultrasound demonstration was incorporated into a 1-h session, where the students also had stations on radiographs, computerised tomography (CT) and magnetic resonance images (MRI). Whilst these later modalities were already incorporated into all medical anatomy practicals, the ultrasound session was novel within the session.

2. Methodology: Setting up a live abdominal ultrasound session

In order to set up our live ultrasound session, we considered several key components in the planning process. The outline requirements for this are summarised in Fig. 1, which is then expanded throughout the following methods section. We explain our rationale and discussion of decisions alongside our methodology to support the reader in understanding our choices during the development process.

2.1. Expertise: Ultrasound champions

A collaboration was established between the radiology lead for the medical programme and a member of academic staff in Anatomy (the

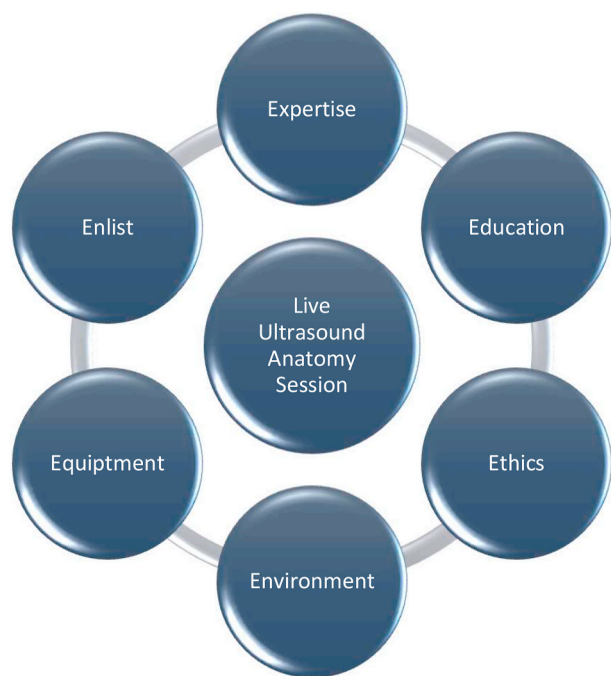

Fig. 1. Outline requirements for the live ultrasound teaching sessions during anatomy teaching of year 2 medical students at the University of Bristol.

medical anatomy team lead), to develop the live ultrasound session. Identifying ‘ultrasound champions’ with expertise, leadership and accountability for teaching has been determined as one of the key steps to initiating a program [15,21,28]. We chose to have an ultrasound champion in both clinical radiology and anatomy to bring together shared expertise, and avoid the difficulty cited by some institutions of having a single champion becoming a single point of failure, should they be unavailable [15].

2.2. Education: Core focus and Intended Learning Outcomes (ILOs)

2.2.1. Aims

The aim of the live ultrasound demonstration was to support the students understanding of living anatomy. It is important to note that we were not aiming to teach students how to perform an ultrasound scan, as developing competence in even a single type of ultrasound scanning takes significant time and training [29]. Instead the focus of the session was to visualise living anatomy, allowing students to contextualise their knowledge, and gain an insight into the value of this scanning modality [25]. This distinction is important for both the faculty and the students, so that expectations and resource requirements are clear from the start.

The abdominal scan was chosen for the pilot session as it is less likely than some other scans to cause undue distress to the volunteer models, who can be draped to preserve dignity; only their abdomen need be exposed. A thoracic scan to include the heart was ruled out due to the intimate nature of this scan. The anatomy visualised during the teaching scans was in line with the recommendations from the British Medical Ultrasound Society guidelines (p49-50) for abdominal ultrasound examination principles [30], with the exclusion of pelvic anatomy. All scans were performed using external transducers.

2.2.2. The ILOs for the session were as follows

- To consider the indications for ultrasound scanning*
- To discuss the cost vs benefits of ultrasound scanning over other modalities*
- To review the appearance of abnormalities on ultrasound scans e.g.

calculi, hernias, aneurysms*

- To view a live abdominal ultrasound scan, identifying the structure and appearance of the major abdominal organs (liver, kidneys, gallbladder, spleen, pancreas, small and large intestine, bladder) and associated blood vessels

* These outcomes were covered in self-directed learning using on-line and workbook resources, not during the live demonstration.

2.3. Ethics: Obtaining appropriate approvals

2.3.1. Programme approval

The plan for the pilot was put forward to the Medical School Programme Management Committee by the ultrasound champions, to ensure top-down senior support, and following evaluation, agreement for expansion of the model into more sessions within the programme. The experience of those institutions who have implemented larger ultrasound training programmes is that this approach is paramount to the successful implementation of innovations at a strategic and administrative level [28]. We set up our pilot with a single session. The recommendation of starting small, with a view to gradually increasing the number of sessions, makes agreement, timing, and funding, more achievable [21,31].

2.3.2. Ethical review

The pilot was conducted under University of Bristol Ethical Approval Number: 44883. This included all plans for consenting both participating staff and volunteers. As part of this process, information sheets were provided for all staff and students to detail the expectation of the scans, how any issues would be dealt with, and where to go to ask for help or advice. Due to asking students to act as volunteers in front of their peers, it was of importance to us that they could understand fully the expectation of the scanning process, and that they knew they could leave the pilot at any stage without negative consequence on their coursework (See also section 2.6.2 on volunteer models.).

2.4. Environment: location, timing, cohort, class size

2.4.1. Location

Bristol School of Anatomy is a large centre with both human and veterinary anatomy teaching facilities and a postgraduate clinical anatomy training unit on site. With the agreement of the Centre Manager we secured two private rooms to run the scanning sessions over a 1.5-day period. These rooms were large enough to have 10–20 observing students, with an examination couch for the volunteer model, a full-size scanner and the clinician performing the scan. The room doors were also obscured using screens to ensure privacy of the sessions from the corridors outside. Each room was also equipped with a large visual screen to allow images from the ultrasound scanner to be projected at an increased size.

2.4.2. Timing

Our pilot was incorporated within the curriculum in 2016 and 2017. There was no ‘extra’ time made available for the session, so an existing session in year 2 was reworked to incorporate it. This aligns with the experience in the literature of introducing live ultrasound into pre-existing anatomy teaching sessions [27]. The basic topographical regional anatomy of the abdomen and pelvis had already been covered in prior practicals during the year 1 of the programme. The students had also had an introduction to the basics of radiological modalities including ultrasound during their year 1 teaching. As preparation for the session, students had to revisit these year 1 learning materials, to support development of a constructivist approach to learning; whereby the student increases their depth of understanding by building on what has come before [32]. This spiralled learning is a key approach to all of our medical anatomy teaching.

2.4.3. Cohort

The year 2 cohort at the time of the pilot was 250 students. Given the cohort size and time available, it was not practicable to offer all students 'hands-on' experience of scanning. Whilst 'hands-on' time may be considered beneficial to the students in terms of their understanding and enjoyment of the session, it is acknowledged in the literature that it is not always possible [27,29]. We therefore opted for a demonstrated scan.

2.4.4. Class size

Usually our medical students are taught anatomy in large groups (n = 80–90) with the teaching delivery repeated three times each week to accommodate the whole cohort. The ultrasound sessions were delivered to smaller groups (n = 10–20) for two key reasons. Firstly, to allow students to view both the images projected from the scanner and the probe in the hand of the person performing the scan, to aid understanding of how images are obtained, and improving visuospatial orientation [27]. Secondly, this smaller class size was felt to be less intimidating for the volunteer models. Some teaching models in the literature propose performing a live scan in a full lecture theatre, i.e. to the whole cohort in one sitting, which is useful where the availability of rooms, equipment or personnel prohibits reducing the class size [8], but for the reasons given above, we would recommend smaller class sizes as an optimal approach.

2.5. Equipment: scanner choice and availability

Loan of equipment for our pilot was kindly donated by Toshiba Medical. This allowed us to use full size, high quality scanning machines, Aplio 500 (used in 2016) and Aplio i900 (used in 2017), which have optimal picture resolution, a difficulty cited by some programs using portable devices for ultrasound sessions [8,16]. However the image quality of portable devices has improved dramatically over the past few years. Bearing in mind the complexity and cost of full ultrasound machines, consideration for purchasing cheaper, simplified and more portable machines for the longer term may be both sustainable and fit for purpose. Other equipment required is an examination couch with appropriate drapes, ultrasound gel and wipes.

2.6. Enlist: Recruiting your faculty and volunteer models

2.6.1. Faculty

We enlisted clinicians with sonography experience to perform all scans. All clinical personnel were recruited by the clinical ultrasound champion and were working junior doctors training in radiology (Faculty for the Anatomy Ultrasound Teaching Session, 2017 shown in Fig. 2). These doctors were well placed to consent the volunteers and to answer their questions. Additionally, should there be unexpected findings on any of the scans, these clinicians could counsel the volunteers and organise appropriate follow-up as required. All teaching staff participating in the pilot were fully consented for their participation in the pilot and any subsequent research/publication of the work (see 2.3.2 Ethical Review).

Some studies have investigated training anatomy staff to perform the scans [33]. This was not possible during our pilot due to limitations in availability of clinical staff and equipment to facilitate such training. Running ultrasound demonstrations with experienced staff has also been shown to improve the perceived value of the experience by students [15]. Having clinically qualified and experienced staff performing the scans was also reassuring to our volunteer models.

2.6.2. Volunteer models

We recruited student volunteers from the year 2 cohort to act as the models. A comprehensive information pack was made available to all volunteers prior to signing up (see 2.3.2 Ethical Review). All volunteers were fully counselled and consented for their participation and were free to leave at any point without any negative consequence.

To limit the exposure to multiple examinations, several volunteers were recruited for each 3 h teaching session, with each volunteer being scanned for 1 h only (two 30 min demonstration scans). Each volunteer was asked to starve for 4–6 h prior to the scans to optimise visibility of the abdominal organs, aid distension of the gallbladder and reduce intestinal gas [30]. The detail of the teaching scans is given in section 2.2. Some studies have suggested that it is important for the volunteer to be able to see the scanner image so that they can learn whilst participating. We took this a step further by asking the volunteers to attend with their usual study group to learn and then to attend a different group as a volunteer. We felt this would mean the student did not have




Fig. 2. Faculty for the Anatomy Ultrasound Teaching Session, 2017. Front row L–R: Dr Sarah Allsop (Medical Anatomy Lead 2013–2019), Dr Lucinda Frank, Dr Lucy Boyle. Back row L–R: Prof. Sanjay Gandhi (MBChB Programme Radiology Lead), Dr Jacob Whitworth, Dr Matthew Jaring, Dr John Spillane (consent obtained for image publication).

to try to perform two roles at one time and could fully engage in the learning during their own taught session.

All volunteers were pre-scanned prior to the teaching scanning sessions (see 2.6.3 Pre-scanning).

2.6.3. Pre-scanning

One of the significant challenges cited in the literature is the potential for pathology, or unexpected conditions such as pregnancy, to be found in the 'healthy' volunteers during the scans [15,27]. Pre-scanning of volunteer models prior to the teaching scans is recommended to ensure any abnormalities found in advance can be followed-up [27].

We completed all the pre-scans at a local NHS healthcare site by the trained clinical radiology staff linked to the pilot and coordinated by the clinical ultrasound champion. This meant that any unexpected pre-scan findings could be more easily counselled and offered NHS follow-up. Whilst no incidental findings have been made in any of our pre-scans to date, having a clear protocol reassures volunteers how this situation would be dealt with. Where direct expert counselling of subjects is not possible due to the location or the inexperience of staff performing the pre-scans, we concur with Griksaitis et al. [27] in recommending consultation of the formal guidance from the Royal College of Radiologists (2011) [34].

3. Results and discussion

3.1. Running the sessions

During the 2-year pilot, on all occasions we were able to include live ultrasound scans of the abdomen within the radiology teaching sessions. In order to accommodate the whole student cohort, at least 12 individual scanning sessions were performed each time. All volunteers were pre-scanned with no abnormalities found. Teaching scans went well with good visualisation of abdominal organs and vasculature for teaching purposes. From the feedback taken from the volunteers, they reported no issues with taking part and tolerated being scanned for around 1 h with minimal discomfort. Volunteers reported that they appreciated being able to attend a separate session where they could concentrate on their own learning when not being a volunteer.

3.2. Student feedback

Questionnaires looking at student perceptions of the teaching sessions were collected during 2016 in the first year of the pilot, including feedback on all aspects of the teaching session including teaching on radiographs, CT and MRI as well as the live ultrasound demonstration. Overall student feedback was very positive and revealed that the sessions were both 'enjoyable' and 'useful'. For most students, it was their first exposure to learning using ultrasound techniques, and 60% of students said they would like to have more live ultrasound teaching. Over 90% of students agreed that learning radiology interpretation skills in anatomy teaching will help their future practice.

Reviewing the qualitative data taken at the time, some students were particularly inspired by being taught directly by radiology trainees, as they felt they could ask more in-depth questions. Several articles discuss that student feedback varies dependent upon the confidence and expertise of staff delivering the sessions [15,33]. For our pilot we enlisted local radiology trainees as faculty during the sessions and to perform the scans. This was appreciated by our students, and the faculty also gained teaching experience for their own continued professional development. The challenge with this model is the availability of these staff to attend the teaching sessions, due to clinical service commitments.

Some studies overcome this by using anatomists who have been trained to carry out the scans; and whilst some studies have initially shown less favourable feedback with sessions run by less experienced staff [15], good outcomes have been shown when structured training is

put in place for anatomists to develop scanning proficiency [35]. Other studies have looked at models with paired anatomists and clinicians, thus extending the expertise of the overall faculty for the sessions [33]. As these models offer more flexibility within the training, future expansion of our own programme will bear these factors in mind.

Other students were less satisfied by the sessions, as they found the anatomy difficult to recognise due to unfamiliarity with the ultrasound scanning format, and difficulty understanding the orientation of the scan and the probe. Some institutions have improved understanding of the scanning technique itself, by running online training in advance of the teaching session [23]. This is particularly true if the design of the set-up is for the students to be 'hands on' with the scanner, where they require some prior education in how the machine itself works [12,23]. The development of additional online learning materials about the technique could improve the student's preparation for the sessions.

Some students also commented that they would like to try performing the scan themselves rather than only observing. Whilst several institutions have managed to incorporate a more haptic experience for their students during teaching sessions in anatomy [7,27], the practicability with our cohort size and available time within the curriculum, equipment and staffing currently prohibits this approach. This has also been the experience of other institutions unable to offer such individualised teaching exposure to ultrasound with large cohorts [8]. A perhaps more practicable time to introduce hands-on ultrasound experience is during clinical placements, where students can learn 'point of care' ultrasound training with healthcare professionals, as part of a spiral ultrasound curriculum.

4. Limitations

At the time of publication, our live ultrasound session evaluation has considered the student perception, rather than impact data on their educational attainment. Now these sessions are established, further studies can be implemented.

5. Reflection on lessons learnt

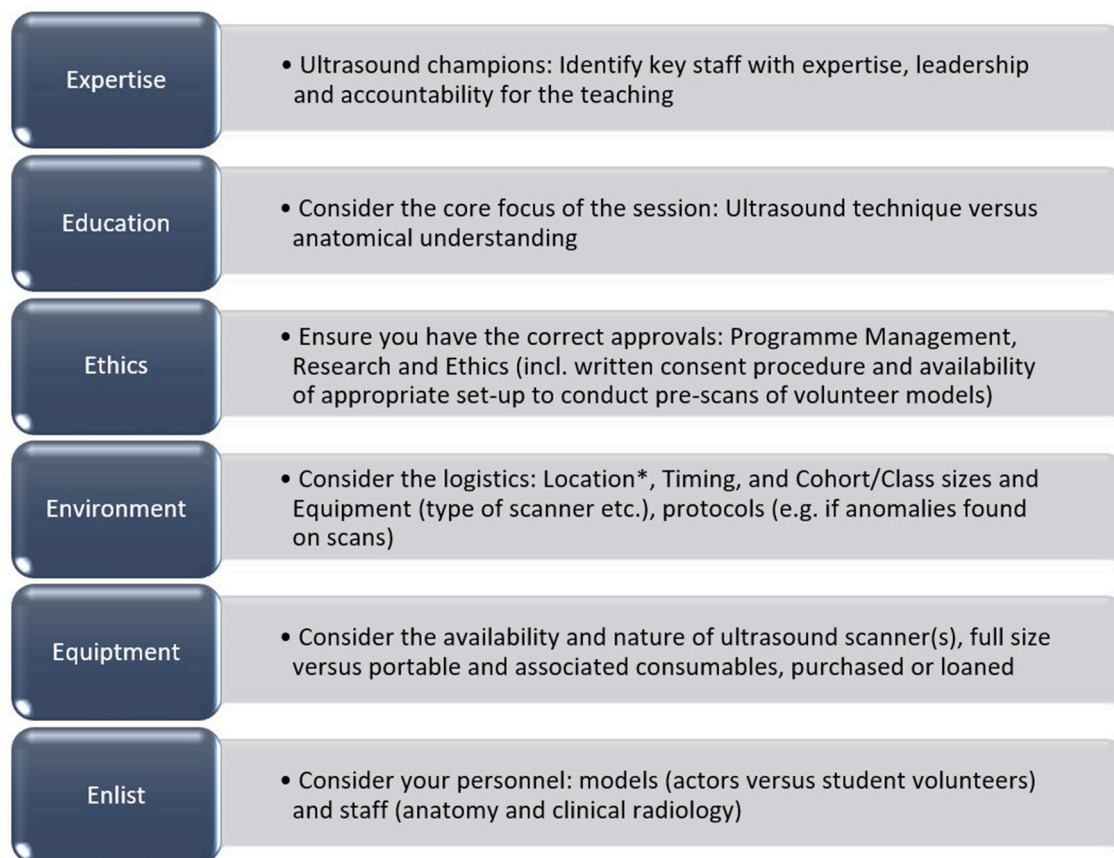
Since the time of the initial pilot, these sessions have become fully embedded in the medical curriculum. We continued to run the sessions in a similar way to the set up during the pilot, until 2020 when the purchase of an ultrasound machine by Bristol Medical School, allowed us to run the practicals without relying on loaned equipment. The School of Anatomy has also opened a new Imaging Suite with a bespoke ultrasound room, which facilitates a specifically designed environment for such teaching.

Following the medical curriculum review (MB21) at Bristol Medical School from 2020, the abdominal ultrasound practicals were relocated in the programme from year 2 to year 1. This meant a slightly changed emphasis due to a reduction in the preceding knowledge of the students attending the class. However, we have still seen very positive feedback from students on the experience, and similar qualitative comments as previously around interest and desire for more ultrasound exposure. Impact studies on the implementation of changes made to our teaching will need to be investigated as the curriculum review moves forward.

A further unexpected consideration at the time of publication is the changes needed for close proximity teaching in light of the covid-19 pandemic [36]. As higher education across the world changes focus to a more online delivery, we are exploring a number of options for maintaining our anatomical ultrasound teaching, including streaming of sessions (subject to the necessary ethical permissions) and additional online materials.

6. Six step model

Using our experience and considering the literature, we provide a six step model for consideration when implementing a pilot of live



*Location should include safety of close proximity teaching in light of covid-19

Fig. 3. Six Step Model for developing a live ultrasound pilot for undergraduate medical anatomy.

ultrasound sessions within anatomy teaching within a medical curriculum (see Fig. 3).

7. Conclusion and future

Our experience showed that it is both possible and desirable to implement live ultrasound sessions as an adjunct to the teaching of anatomy to early years medical students. Students enjoy the experience and can appreciate the benefit of seeing living anatomy to both complement their learning in the cadaver laboratory and link the anatomy with the clinical context of their future practice. Feedback revealed they would like more sessions, more time, and more opportunity to be hands-on. Our experience mirrors that of other institutions who have also run similar sessions.

The time and effort of implementing this type of innovation should not be underestimated, and it is important to ensure top-level support from the relevant Programme Leads and Heads of Departments at an early stage. Key staff acting as ultrasound champions will allow improved communication and direction between the clinical and anatomy staff, and the senior management ensuring a collaborative approach.

Whilst live ultrasound teaching is becoming more prevalent in medical undergraduate curricula, there remains limited research on the long term impact of this teaching [13]. As more research on the impact of the implementation of full ultrasound programmes becomes available, the evidence for wider integration of such curricula will be made clearer [11].

At Bristol, as part of the medical curriculum review, we aim to expand the number of living anatomy teaching sessions utilising live ultrasound within the year 1 and 2 curriculum with sessions on the heart, musculoskeletal system, and the vasculature of the neck. The delivery

of these sessions must now consider any restrictions on close proximity teaching during the covid-19 pandemic. Modifications to teaching in higher education are likely to be affected long after the peaks of the pandemic and thus we are likely to see further innovation in anatomy ultrasound delivery over the coming months and years.

Funding

This work was funded by the University of Bristol. This research did not receive any specific grant from funding agencies in the public, commercial, or not-for-profit sectors.

Consent for photography

All individuals in the photograph (Fig. 2) have given written consent for this image to be published.

Declaration of competing interest

None.

Acknowledgements

We would like to thank Head of School Professor Michelle Spear and School Manager Kate Sparey for their support of the pilot and the use of the facilities at the Vesalius Clinical Training Centre and Imaging Suite at the School of Anatomy at the University of Bristol. We would also like to thank the Medical Programme at the University of Bristol for their overall support of this pilot.

We would like to thank Mair Howe, Erica Oliver, Donna Holdcroft

and Helen Lockyer at Toshiba Medical for providing the loan of ultrasound scanners for our pilot in 2016 (Ultrasound Scanner: Aplio 500) and 2017 (Ultrasound Scanner: Aplio i900). We would like to thank both local NHS trust radiology departments for supporting this pilot by facilitating the pre-scans on site at their facilities.

We would like to thank Dr Nick Ridley for coordinating the teaching in 2016–17 and recruiting the radiology registrar's, Dr Amit Parekh, Dr Noor Ali, Dr Lucy Hilder and Dr Matt Jarring who delivered the teaching and Dr Mathuri Sakthithasan, Dr Noor Ali and Dr Iara Sequeiros who conducted the pre-scans on site at the University of Bristol NHS Trust. We would like to thank Professor Sanjay Gandhi for coordinating the teaching in 2017–18, conducting the pre-scans on site at North Bristol NHS Trust and recruiting the radiology registrars, Dr Becky Hunt, Dr Matt Jarring, Dr Lucy Boyle, Dr Lucinda Frank, Dr Jacob Whitworth and Dr John Spillane who delivered the teaching.

We would also like to thank the staff who have been involved in the delivery of the project since the time of the pilot at the School of Anatomy at Bristol, Dr Daniel Baumgardt, Dr Sara Sulaiman and Mr Charlie Tanner.

References

- [1] C.P. Orsbon, R.S. Kaiser, C.F. Ross, Physician opinions about an anatomy core curriculum: a case for medical imaging and vertical integration, *Anat. Sci. Educ.* 7 (4) (2014) 251–261, <https://doi.org/10.1002/ase.1401>.
- [2] K. Sugand, P. Abrahams, A. Khurana, The anatomy of anatomy: a review for its modernization, *Anat. Sci. Educ.* 3 (2) (2010) 83–93, <https://doi.org/10.1002/ase.139>.
- [3] C.R. Peabody, D. Mandavia, Deep needle procedures: improving safety with ultrasound visualization, *J. Patient Saf.* 13 (2) (2017) 103–108, <https://doi.org/10.1097/PTS.0000000000000110>.
- [4] U.K. Teichgraber, J.M. Meyer, C. Poulsen Nautrup, D.B. von Rautenfeld, Ultrasound anatomy: a practical teaching system in human gross anatomy, *Med. Educ.* 30 (4) (1996) 296–298, <https://doi.org/10.1111/j.1365-2923.1996.tb00832.x>.
- [5] S. So, R.M. Patel, S.L. Orebaugh, Ultrasound imaging in medical student education: impact on learning anatomy and physical diagnosis, *Anat. Sci. Educ.* 10 (2) (2017) 176–189, <https://doi.org/10.1002/ase.1630>.
- [6] D.P. Bahner, E. Goldman, D. Way, N.A. Royall, Y.T. Liu, The state of ultrasound education in US medical schools: results of a national survey, *Acad. Med.* 89 (12) (2014) 1681–1686, <https://doi.org/10.1097/ACM.0000000000000414>.
- [7] M. Swamy, R.F. Searle, Anatomy teaching with portable ultrasound to medical students, *BMC Med. Educ.* 12 (2012) 99, <https://doi.org/10.1186/1472-6920-12-99>.
- [8] M.D. Stringer, L.J. Duncan, L. Samalia, Using real-time ultrasound to teach living anatomy: an alternative model for large classes, *N. Z. Med. J.* 125 (1361) (2012) 37–45 <http://www.nzma.org.nz/journal/125-1361/5322/>, Accessed date: 27 March 2019.
- [9] M.J. Griksaitis, M.A. Sawdon, G.M. Finn, Ultrasound and cadaveric dissections as methods for teaching cardiac anatomy: a comparative study, *Anat. Sci. Educ.* 5 (1) (2012) 20–26, <https://doi.org/10.1002/ase.259>.
- [10] GMC, Outcomes for graduates 2018, https://www.gmc-uk.org/-/media/documents/outcomes-for-graduates-a4_pdf-77470228.pdf, Accessed date: 28 March 2019.
- [11] J.J. Davis, C.E. Wessner, J. Potts, A.K. Au, C.A. Pohl, J.M. Fields, Ultrasonography in undergraduate medical education: a systematic review, *J. Ultrasound Med.* 37 (11) (2018) 2667–2679, <https://doi.org/10.1002/jum.14628>.
- [12] S.G. Patel, B. Benninger, S.A. Mirjalili, Integrating ultrasound into modern medical curricula, *Clin. Anat.* 30 (4) (2017) 452–460, <https://doi.org/10.1002/ca.22864>.
- [13] Z. Feilchenfeld, T. Dornan, C. Whitehead, A. Kuper, Ultrasound in undergraduate medical education: a systematic and critical review, *Med. Educ.* 51 (4) (2017) 366–378, <https://doi.org/10.1111/medu.13211>.
- [14] B. Brown, S. Adhikari, J. Marx, L. Lander, G.L. Todd, Introduction of ultrasound into gross anatomy curriculum: perceptions of medical students, *J. Emerg. Med.* 43 (6) (2012) 1098–1102, <https://doi.org/10.1016/j.jemermed.2012.01.041>.
- [15] D. Patten, Using ultrasound to teach anatomy in the undergraduate medical curriculum: an evaluation of the experiences of tutors and medical students, *Ultrasound* 23 (1) (2015) 18–28, <https://doi.org/10.1177/1742271X14542173>.
- [16] J. Ivanusic, B. Cowie, M. Barrington, Undergraduate student perceptions of the use of ultrasonography in the study of "living anatomy", *Anat. Sci. Educ.* 3 (6) (2010) 318–322, <https://doi.org/10.1002/ase.180>.
- [17] S.D. Solomon, F. Saldana, Point-of-care ultrasound in medical education—stop listening and look, *N. Engl. J. Med.* 370 (12) (2014) 1083–1085, <https://doi.org/10.1056/NEJMp1311944>.
- [18] S.M. Dreher, R. DePhilip, D. Bahner, Ultrasound exposure during gross anatomy, *J. Emerg. Med.* 46 (2) (2014) 231–240, <https://doi.org/10.1016/j.jemermed.2013.08.028>.
- [19] U. Tarique, B. Tang, M. Singh, K.M. Kulasegaram, J. Ailon, Ultrasound curricula in undergraduate medical education: a scoping review, *J. Ultrasound Med.* 37 (1) (2018) 69–82, <https://doi.org/10.1002/jum.14333>.
- [20] J. Minardi, H. Ressetar, T. Foreman, K. Craig, M. Sharon, J. Bassler, S. Davis, A. Machi, S. Cottrell, N. Denne, N. Ferrari, K. Landreth, B. Palmer, G. Schaefer, R. Tallaksen, D. Wilks, D. Williams, Longitudinal ultrasound curriculum incorporation at West Virginia university school of medicine: a description and graduating students' perceptions, *J. Ultrasound Med.* 38 (1) (2019) 63–72, <https://doi.org/10.1002/jum.14662>.
- [21] R.A. Hoppmann, V.V. Rao, F. Bell, M.B. Poston, D.B. Howe, S. Riffle, S. Harris, R. Riley, C. McMahon, L.B. Wilson, E. Blanck, N.A. Richeson, L.K. Thomas, C. Hartman, F.H. Neuffer, B.D. Keisler, K.M. Sims, M.D. Garber, C.O. Shuler, M. Blaivas, S.A. Chillag, M. Wagner, K. Barron, D. Davis, J.R. Wells, D.J. Kenney, J.W. Hall, P.H. Bornemann, D. Schrifft, P.S. Hunt, W.B. Owens, R.S. Smith, A.G. Jackson, K. Hagon, S.P. Wilson, S.D. Fowler, J.F. Catroppo, A.A. Rizvi, C.K. Powell, T. Cook, E. Brown, F.A. Navarro, J. Thornhill, J. Burgis, W.R. Jennings, J.B. McCallum, J.M. Nottingham, J. Kreiner, R. Haddad, J.R. Augustine, N.W. Pedigo, P.V. Catalana, The evolution of an integrated ultrasound curriculum (iUSC) for medical students: 9-year experience, *Crit. Ultrasound J.* 7 (1) (2015) 18, <https://doi.org/10.1186/s13089-015-0035-3>.
- [22] D.P. Bahner, N.A. Royall, Advanced ultrasound training for fourth-year medical students: a novel training program at the Ohio State University College of Medicine, *Acad. Med.* 88 (2) (2013) 206–213, <https://doi.org/10.1097/ACM.0b013e31827c562d>.
- [23] R.J. Wakefield, A. Weerasinghe, P. Tung, L. Smith, J. Pickering, T. Msimanga, M. Arora, K. Flood, P. Gupta, S. Bickerdike, J. McLaughlan, A. Uttley, J. Wilson, T. Evans, S. Wolstenhulme, T.E. Roberts, The development of a pragmatic, clinically driven ultrasound curriculum in a UK medical school, *Med. Teach.* 40 (6) (2018) 600–606, <https://doi.org/10.1080/0142159X.2018.1439579>.
- [24] F.A. Fakoya, Integrating ultrasound technology into teaching gross anatomy: point of order!, *Med. Educ. Online* 18 (2013) 20888, <https://doi.org/10.3402/meo.v18i0.20888>.
- [25] M.J. Griksaitis, M.P. Scott, G.M. Finn, Comment on letter by Nicholls et al.—Ultrasound: a hands-on and kinaesthetic approach to anatomy education, *Med. Teach.* 36 (7) (2014) 644, <https://doi.org/10.3109/0142159X.2014.917289>.
- [26] J.C. McLachlan, D. Patten, Anatomy teaching: ghosts of the past, present and future, *Med. Educ.* 40 (3) (2006) 243–253, <https://doi.org/10.1111/j.1365-2929.2006.02401.x>.
- [27] M.J. Griksaitis, M.P. Scott, G.M. Finn, Twelve tips for teaching with ultrasound in the undergraduate curriculum, *Med. Teach.* 36 (1) (2014) 19–24, <https://doi.org/10.3109/0142159X.2013.847909>.
- [28] A.T. Chiem, Z. Soucy, V.A. Dinh, M. Chilstrom, L. Gharahbaghian, V. Shah, A. Medak, A. Nagdev, T. Jang, E. Stark, A. Hussain, V. Lobo, A. Pera, J.C. Fox, Integration of ultrasound in undergraduate medical education at the California medical schools: a discussion of common challenges and strategies from the UMEcali experience, *J. Ultrasound Med.* 35 (2) (2016) 221–233, <https://doi.org/10.7863/ultra.15.05006>.
- [29] D. Nicholls, L. Sweet, J. Hyett, Comments on "Twelve tips for teaching with ultrasound in the undergraduate curriculum", *Med. Teach.* 36 (7) (2014), <https://doi.org/10.3109/0142159X.2014.909020> 643.
- [30] B.M.U.S. Guidelines for professional ultrasound practice, Society and College of Radiographers and British Medical Ultrasound Society (2015), https://www.bmus.org/static/uploads/resources/GUIDELINES_FOR_PROFESSIONAL_ULTRASOUND_PRACTICE.pdf, Accessed date: 28 March 2019.
- [31] R.A. Hoppmann, V.V. Rao, M.B. Poston, D.B. Howe, P.S. Hunt, S.D. Fowler, L.E. Paulman, J.R. Wells, N.A. Richeson, P.V. Catalana, L.K. Thomas, L. Britt Wilson, T. Cook, S. Riffle, F.H. Neuffer, J.B. McCallum, B.D. Keisler, R.S. Brown, A.R. Gregg, K.M. Sims, C.K. Powell, M.D. Garber, J.E. Morrison, W.B. Owens, K.A. Carnevale, W.R. Jennings, S. Fletcher, An integrated ultrasound curriculum (iUSC) for medical students: 4-year experience, *Crit. Ultrasound J.* 3 (1) (2011) 1–12, <https://doi.org/10.1007/s13089-011-0052-9>.
- [32] R.M. Harden, What is a spiral curriculum? *Med. Teach.* 21 (2) (1999) 141–143, <https://doi.org/10.1080/01421599979752>.
- [33] J.P. Smith, J.L. Kendall, D.F. Royer, Improved medical student perception of ultrasound using a paired anatomy teaching assistant and clinician teaching model, *Anat. Sci. Educ.* 11 (2) (2018) 175–184, <https://doi.org/10.1002/ase.1722>.
- [34] RCR, The Royal College of Radiologists, Management of incidental findings detected during research imaging, https://www.rcr.ac.uk/system/files/publication/field_publication_files/BFCR%2811%298_ethics.pdf, (2011), Accessed date: 28 March 2019.
- [35] R.A. Jurjus, K. Dimorier, K. Brown, F. Slaby, H. Shokoohi, K. Boniface, Y.T. Liu, Can anatomists teach living anatomy using ultrasound as a teaching tool? *Anat. Sci. Educ.* 7 (5) (2014) 340–349, <https://doi.org/10.1002/ase.1417>.
- [36] K.E. Darras, R.J. Spouge, A.B.H. de Bruin, A. Sedlic, C. Hague, B.B. Forster, Undergraduate radiology education during the COVID-19 pandemic: a review of teaching and learning strategies, *Can. Assoc. Radiol. J.* (2020), <https://doi.org/10.1177/0846537120944821>.