

DR. ESTHER DEMPSEY (Orcid ID : 0000-0002-7653-4653)

Article type : Main research article

**A report on the impact of rapid prenatal exome sequencing on the clinical management of 52 ongoing pregnancies; a retrospective review.**

E Dempsey<sup>a,b</sup>, A Haworth<sup>c</sup>, L Ive<sup>c</sup>, R Dubis<sup>c</sup>, H Savage<sup>c</sup>, E Serra<sup>c</sup>, J Kenny<sup>a</sup>, F Elmslie<sup>a</sup>, E Greco<sup>d,e</sup>, B Thilaganathan<sup>f,g</sup>, S Mansour<sup>a,b</sup>, T Homfray<sup>a</sup>, S Drury<sup>c</sup>

<sup>a</sup> South West Thames Regional Genetics Service

<sup>b</sup> School of Biological and Molecular Sciences, St George's University of London

<sup>c</sup> Congenica Ltd, Biodata Innovation Centre, Wellcome Trust Genome Campus, Hinxton, CB10 1DR, UK

<sup>d</sup> Harris Birthright Centre, King's College London

<sup>e</sup> Barts Health NHS Trust

<sup>f</sup> Fetal Medicine Centre, St George's Hospital, London

<sup>g</sup> Vascular Biology Unit, St George's University of London

**Corresponding Author**

Dr Esther Dempsey

South West Thames Regional Genetics Service

Cranmer Terrace

London

SW17 0RE

This article has been accepted for publication and undergone full peer review but has not been through the copyediting, typesetting, pagination and proofreading process, which may lead to differences between this version and the [Version of Record](#). Please cite this article as [doi: 10.1111/1471-0528.16546](https://doi.org/10.1111/1471-0528.16546)

This article is protected by copyright. All rights reserved

Tel: 07786441934

Esther.dempsey@.nhs.net

### **Running title**

The impact of prenatal exome sequencing

### **Abstract**

#### **Objective**

Studies have shown Prenatal Exome Sequencing (PES) improves diagnostic yield in cases of fetal structural malformation. We have retrospectively analysed PES cases from two of the largest fetal medicine centres in the UK to determine the impact of results on management of a pregnancy.

#### **Design**

A retrospective review of clinical case notes.

#### **Setting**

Two tertiary fetal medicine centres.

#### **Population**

Pregnancies with fetal structural abnormalities referred to clinical genetics via a multidisciplinary team.

#### **Methods**

We retrospectively reviewed the notes of all patients who had undergone PES. DNA samples were obtained via chorionic villus sampling or amniocentesis. Variants were filtered using patient specific panels and interpreted using American College of Medical Genetics guidelines.

#### **Results**

A molecular diagnosis was made in 42% (18/43) ongoing pregnancies, and of this group there was a significant management implication in 44% (8/18). A positive result contributed to the decision to terminate a pregnancy in 16% (7/43) of cases. A negative result had a significant impact on management in 2 cases by affirming decision to continue pregnancy.

### **Conclusions**

We demonstrate that the results of PES can inform pregnancy management. Challenges include variant interpretation with limited phenotype information. These results emphasise the importance of the MDT and collecting phenotype and variant data. As this testing is soon to be widely available we should look to move beyond diagnostic yield as a measure of the value of PES.

### **Funding**

Esther Dempsey is funded by a peer-reviewed grant from the British Heart Foundation (FS/18/78/33932). This study did not receive specific funding.

### **Keywords**

Exome Sequencing, Prenatal genetic testing

### **Tweetable Abstract**

Prenatal exome sequencing can aid decision making in pregnancy management; review ahead of routine implementation in NHS.

### **Introduction**

Approximately 3.5% of pregnancies are affected by a major fetal structural malformation(1). Abnormal karyotype (number and appearance of chromosomes) accounts for 14% of sonographically detected structural birth defects(2). Chromosome Micro-Array (CMA), which detects smaller structural variation within the chromosomes, diagnoses a further ~6%(3). These

Accepted Article

approaches leave the majority of cases undiagnosed. As many single-gene disorders can present in-utero, it was postulated that exome sequencing could provide additional diagnosis, owing to its greater resolution and demonstrated utility in diagnosing postnatal cases such as developmental disorders[1]. Initial studies focused on highly selected and phenotypically homogenous cohorts which showed high diagnostic yield, up to 80% for select phenotypes such as skeletal anomalies [2–5]. When broader inclusion criteria are applied, diagnosis is made in ~10% [6,7]. It is becoming apparent that early routine adoption of PES is with carefully ascertained patients across a spectrum of phenotypes [8].

Exome sequencing analyses the ~1% portion of the genome which provide instructions for making proteins. It is important for the requesting physician to be aware of test limitations. For example, some exome tests focus only on a subset of medically relevant genes, but as new gene discoveries continue apace, this can reduce the potential to make a diagnosis compared to a full exome [9].

Considerations for implementation of prenatal diagnostic exome and genome wide sequencing, are summarised in joint position statements [10,11]. Debate is ongoing whether secondary findings in the parental genome of the ACMG 59 genes (for which clinical evidence that pathogenic variants may result in disease that might be prevented or treated) should be returned [12].

Molecular diagnosis in cases of structural malformation allows for greater diagnostic accuracy and can have implications for management of pregnancy; whilst studies are limited in this area, decision making has reportedly been impacted in up to 70% [13–16].

Since 2018 we have undertaken exome sequencing in 110 cases of fetal anomaly. The work presented here focuses on those where PES was undertaken in an ongoing pregnancy and aims to quantify the added value of PES and describe the challenges of its implementation in advance of this service becoming routinely available throughout England in the near future.

## Methods:

Patient selection:

Ongoing pregnancies with ultrasound detected fetal anomaly with a high likelihood of being explained by a single-gene disorder, and where the result may influence management of the pregnancy, labour or early neonatal care were referred to clinical genetics after discussion at a multidisciplinary team meeting (fetal medicine specialists, neonatologists, radiologists, pathologists, genetic scientists and clinical geneticists). All cases undergoing PES were reviewed by an experienced clinical geneticist often with concomitant ultrasound scanning.

All PES was undertaken in the context of a normal or uninformative CMA over the period 2018-2020.

Phenotypes considered to be likely attributable to a single-gene disorder included skeletal dysplasias, fetal oedema/hydrops, multisystem fetal disorders (with absence of known cause), neurological abnormalities (including abnormalities of fetal posture), and specific types of isolated cardiac malformations. Human phenotype ontology (HPO) terms were assigned to each case by clinical geneticist and/or genetic scientist.

Patients were not involved in the development of the research. This study did not receive specific funding.

Exome sequencing, data analysis and variant interpretation

DNA was extracted from chorionic villus sample (CVS), amniotic fluid (AF), fetal blood or tissue. Parental samples were sequenced where possible. Exome sequencing was performed using Exome CG (Nonacus, UK) or Clinical Research Exome version 2 (Agilent Biosystems, USA) as per manufacturer's instructions. Exome libraries were pooled and sequenced on an Illumina platform (NextSeq 500 or Novaseq). Data was processed using DRAGEN Bio-IT Platform (Edico Genome, Illumina) and variant analysis and interpretation performed with the clinical decision support platform Congenica™ (Congenica Ltd, UK). Variants were excluded based on minor allele frequency (>0.005), non-protein altering consequence and, where relevant, mode of inheritance. Patient specific gene panels relevant to the reported phenotype were applied to filter variants in a stratified manner based on most likely disease causing and smallest number of genes first. Variant interpretation was performed by two scientists, following American College of Genetics

and Genomics guidelines [17]. Secondary findings were not considered. Variants of uncertain significance (VUS) were returned to the referring clinician and discussed between relevant members of the MDT.

#### Analysis of impact of results

Analysis of clinical impact was undertaken by retrospective review of clinical notes. Results considered to have a 'significant impact on management' were those which directed further fetal investigations, referrals to other specialists, changes to the management of labour, or treatment of the neonate. Those results contributing to a decision to terminate a pregnancy are considered separately. Those results which did not appear to alter management of pregnancy were considered primarily informative.

#### Results

52/110 patients were offered prenatal exome sequencing in the context of an ongoing pregnancy. Results were returned to this group with an average turnaround time of 17 working days, reducing to <14 days in the second year. 9/52 pregnancies were terminated after the decision to initiate prenatal exome sequencing (Figure 1). In 43 cases pregnancy continued at least to the point of receiving a PES result. Genetic diagnosis was made during the course of pregnancy in 18/43 (42%). Additional diagnosis was made after the birth of the child in one case (see case 24). There were significant implications for management in 8/18 cases (44%); diagnosis was primarily informative in three (3/18;17%). A positive result contributed to the decision to undergo termination of pregnancy in seven cases (7/18;39%) (See table S1 for full phenotype, genotype and impact information). VUS were identified in 13 cases (median VUS=0; range 0-6). 78% (25/32) trios and 40% (4/10) singletons had 0 VUS. In 4 cases VUS were subsequently reclassified as disease causing based on clinical phenotype (*ALPL*, *KCNJ2*, *SLC6A9*, *LZTR1*).

No genetic diagnosis was made in 25/43 (58%) pregnancies that continued to or beyond the point of receiving the PES result. In 2/25 (8%), a negative result had significant management implications, directly contributing to the parents' decision to continue a pregnancy. In 9/25 (36%) a negative result was documented as reassuring. Those couples who felt reassured by a

negative result tended to be those where the fetus had an ambiguous phenotype which could be explained by something other than a single-gene disorder.

Overall there was minimal clinical impact of a negative exome assuming that parents planned to continue a pregnancy in the absence of a genetic diagnosis (see table S2).

Considering the cohort as a whole, a result with a significant management implication was identified (positive or negative) in 10/43 (23%) cases, a result that was primarily information providing in 12/43 (28%) cases and a result that contributed to the decision to undergo TOP in 7/43 (16%) cases.

The following cases exemplify the utility and challenges of PES amongst our cohort.

Case 1 (Table S1, Figure 2) – Prenatal diagnosis facilitates early therapeutic intervention

Singleton pregnancy with unremarkable family history. On 20 week anomaly ultrasound scan the fetus was noted to have bilaterally short femurs and an angulation of the right femur, suggesting *in-utero* fracture (Figure 2). Amniocentesis was undertaken and the parents counselled that the baby most likely had osteogenesis imperfecta (type 3). By 27 weeks gestational age (GA) there was evidence of further fractures on ultrasound scanning. PES identified two variants of uncertain clinical significance in the gene causing hypophosphatasia, *ALPL*. Further testing revealed bi-parental inheritance of the variants and paternal low alkaline phosphatase levels. Low alkaline phosphatase levels confirmed carrier status in the father (maternal alkaline phosphatase levels are uninformative in pregnancy). Identification of a low alkaline phosphatase level allowed the variants to be reclassified to 'likely pathogenic' using the ACMG guidelines. The pregnancy was referred to tertiary paediatric endocrinology for consideration of treatment with enzyme replacement therapy, asfotase alfa. The baby was born in good condition and treatment with asfotase alfa was initiated soon after birth. The child is under ongoing follow-up and it is expected that early instigation of enzyme replacement therapy will lead to improved outcomes.

Case 4 – Severe diagnosis informs labour management

The first ongoing pregnancy of a consanguineous couple was referred to clinical genetics at 22 weeks GA. Family history was unremarkable but the pregnancy was complicated by severe maternal nausea and vomiting. The anomaly scan identified predominantly rhizomelic shortening of the long bones with abnormal calcification in the joints (Figure 2). The fetal chest was slightly narrow, the mid-face flat and there was mild polyhydramnios. The parents were counselled about the possibility of chondrodysplasia punctata which could either be related to the severe vomiting (and subsequent vitamin K deficiency) or a more severe autosomal recessive metabolic disorder [18]. PES was requested to provide more information considering the vastly differing prognosis. The fetus was homozygous for a known pathogenic two base pair deletion in *GNPTAB* confirming a diagnosis of mucopolysaccharidosis type II (i-cell disease) [19] This condition is associated with extremely poor prognosis with most affected individuals dying from respiratory failure in early childhood. For reasons of faith the couple were not able to consider a termination of pregnancy. Multidisciplinary discussions between fetal medicine, obstetrics, paediatrics, genetics and the parents resulted in a plan for limited monitoring in labour (avoiding emergency caesarean section to spare the maternal uterus for future pregnancies) and minimal resuscitatory effort in the event that the baby was born in poor condition. The baby died during labour. The parents are able to use the PES result for preimplantation genetic diagnosis in a future pregnancy.

Case 34 (Table S2, Figure 2)– Negative PES result influences continuation of pregnancy

First referred to clinical genetics at 22+6 weeks gestation due to the finding of an isolated ventricular septal tumour this was the second ongoing pregnancy of a non-consanguineous couple with one healthy older child. The couple were counselled that most fetal cardiac tumours in this position are rhabdomyomas. Cardiac rhabdomyomas are suggestive of Tuberous Sclerosis Complex (TSC) but this is only a definitive diagnosis if they become multiple. TSC is a syndrome characterised by cutaneous and renal abnormalities as well as intellectual disability and epilepsy. The parents felt unable to continue a pregnancy that was likely to result in a child with a severe intellectual impairment. PES was undertaken specifically to look at the genes, *TSC1* and *TSC2*, which are implicated in 85% of TSC cases [20]. No causal variants were identified and the parents continued the pregnancy. The baby was born in good condition and reviewed at 5 months of life



by a clinical geneticist with TSC expertise. The child is developing normally and is seizure free. She has no cutaneous stigmata of TSC. She will be followed up by cardiology in view of her rhabdomyoma and will have a brain MRI at 2 years of age (brain tubers are better visualised at this age when myelination is complete).

#### Case 5 – Exome diagnosis informs management for mother and baby

This pregnancy, conceived by *in-vitro* fertilisation, was the first ongoing pregnancy of a non-consanguineous couple. The family history was unremarkable and the pregnancy uncomplicated. Maternal medical history was significant only for ventricular ectopics. On the 20 week anomaly scan the fetus was identified as having isolated micrognathia. On examination the mother was also observed to have mild micrognathia. The couple were counselled that differential diagnosis included Pierre-Robin sequence, Stickler syndrome and Treacher-Collins Syndrome (which may also explain the maternal micrognathia). Given the similarities between maternal and fetal phenotype PES was performed on maternal DNA, thus mitigating the very small risk of complications related to invasive testing of pregnancy. A heterozygous variant of uncertain significance in *KCNJ2* was identified. Given the maternal history of ventricular ectopics, and a further maternal examination that revealed digital anomalies, the *KCNJ2* variant was considered likely pathogenic and suggestive of a diagnosis of Anderson Tawil Syndrome. The baby was confirmed to have the same variant postnatally. Micrognathia was mild as would be expected in this condition. Treatment for ventricular arrhythmias can be commenced when appropriate to prevent sudden death.

#### Case 24 (Table S2, Figure 2)– PES data used to make postnatal diagnosis

A private gender scan at 17 weeks gestation identified micrognathia in the first ongoing pregnancy of unrelated parents. Family history was unremarkable and the pregnancy had been uncomplicated to that point. The couple were advised that there were no other features suggestive of a syndromic cause but that a cleft palate/ Pierre Robin sequence could not be excluded. Despite the lack of suggestive features the parents remained concerned about the possibility of a syndromic cause. The parents were counselled that it was less likely that there would be a genetic explanation for the micrognathia if a PES did not identify any abnormalities

in those genes associated with this condition. A panel of genes associated with micrognathia were studied with no mutations identified. The parents were informed of the negative exome result and were reassured. On postnatal review the baby was identified as having a cleft palate and initially needed SCBU nursing with nasopharyngeal airway and nasogastric feeding. The baby failed the newborn hearing screen and was subsequently diagnosed with profound sensorineural hearing loss. Exome data was revisited in light of the postnatal phenotype and compound heterozygous pathogenic mutations in *MYO7A* were identified which had both been previously described in cases of Usher syndrome type 1B [21]. It is likely that the baby will develop severe visual loss in addition to the other problems. The micrognathia and cleft palate are possibly coincidental or may represent a novel expansion of the Usher phenotype.

Discussion:

#### Main Findings

Exome sequencing informed management of pregnancy in cases with and without a molecular diagnosis.

Trio exomes (testing samples from both parents and fetus) were preferentially employed (74.4% (32/43) of this cohort, 2.3%(1/43) duo and 23.3% (10/43) proband only) as this aids variant interpretation and increases rate of diagnosis [22]. Paradoxically we found diagnostic rate in singleton exomes significantly higher (64%) than trios (34%; including one duo and one quad). We believe this reflects confidence of the referring clinician in the genetic nature of the presentation and often a clear idea of the underlying diagnosis (e.g. in cases of Noonan syndrome).

Further studies are needed to determine if the proportion of pregnancies terminated with a genetic diagnosis is higher than that in pregnancies with similar fetal anomalies without a diagnosis. Considering the cohort of patients who continued a pregnancy to the point of receiving PES results, TOP rate was higher amongst the group with a molecular diagnosis (7/18, 35%) compared to those with no exome diagnosis (3/25, 12%). It is our experience that the main

determinant of a couple's decision to end a pregnancy is the perceived severity of malformations and the fetal medicine specialist's counselling regarding prognosis.

We have shown a negative PES result can be reassuring to the patients. Patients are reassured with caution and counselled that absence of a molecular genetic diagnosis is not equivalent to absence of a severe problem, genetic or otherwise. It is essential that patients understand this at the point of giving consent for testing. We found negative exomes to be reassuring in the context of a mild phenotype where there is credible evidence that the malformation could be environmental in aetiology.

#### Strengths and Limitations

PES increases diagnostic yield and can provide diagnosis which may not be considered based on available phenotype information. Using a stratified gene-panel approach, expedited targeted analysis is facilitated which can be followed by sequential panel testing if negative. This approach limits the number of VUS and incidental findings. Genomic data can be re-interrogated in light of additional phenotype information. It is our understanding that a 'gene agnostic' approach (analysing all genes associated with developmental disorders) will be used when PES services are co-ordinated nationally, however testing will be initially limited to a smaller range of phenotypes.

VUS were reported and led to a subsequent diagnosis in 2 cases (*ALPL*, *KCNJ2*). Variants were re-classified where additional phenotype information became available (through imaging or biochemical analysis) and the 'likely pathogenic' threshold was reached. The authors believe it is valuable to report these variants as the analysing scientist may not receive all available clinical information and additional phenotype information may become available to the clinician between referral and return of PES results.

Phenotyping via ultrasound is limited compared to higher resolution modalities available in the post-natal setting and cannot provide the phenotypic granularity that comes from clinical examination e.g. ophthalmic reviews or cognitive development assessment. 3D ultrasound imaging is increasingly helpful in assessment of facial dysmorphism. Fetal brain MRI in the third

trimester can reveal structural brain malformations or delays in brain maturation that are not visible on ultrasound imaging.

The majority of cases remain undiagnosed. Structural malformations may have environmental (including infective) aetiologies. In other cases genetic causes may be undetectable by this type of sequencing, e.g. methylation and intronic (non-coding DNA) mutations. Whole genome sequencing (which includes non-coding regions) will identify a proportion of these patients when it becomes routinely available.

More work is needed to address psychological impact of these tests on couples who are experiencing difficult pregnancies[23]. Couples we have worked with have reported feeling vindicated in their decision to end a pregnancy once a genetic diagnosis has been made. Almost all couples struggle over the decision to terminate a pregnancy especially in the third trimester. A PES diagnosis can add weight to the evidence that a fetus has a significant disability and thus supports parents and clinicians in their decision to have or facilitate a post-24 week termination.

Ideally genetic diagnosis would be made earlier in pregnancy. Our ability to make an early diagnosis is limited by several factors including natural history of the condition, imaging technology, UK screening schedule and genetic technology. Cost of PES prohibits it from being applied before or simultaneously to microarray, even where a chromosomal cause is thought to be unlikely. As genetic technology rapidly advances it is foreseeable that the cost of PES will reduce and that copy number analysis can be undertaken via exome sequencing. Further into the future it is likely that cell free-fetal DNA from the maternal bloodstream can be used, avoiding the small risk of invasive testing complications[24]

Interpretation

PES diagnosis impacted management of 44%(8/18) of pregnancies in our cohort. When including those cases which remained without a diagnosis, PES impacted management in 23% (10/43). Other studies suggest clinical impact or influence on management in 26%-70% [13,14,25], however number of ongoing pregnancies at time of PES and resulting impact is smaller in these studies and the exact definition of clinical impact and management varies.

### Conclusions

Results gained from PES can have a significant impact on the management of a pregnancy, labour or neonate. However an actionable molecular diagnosis is only made in a minority of cases, even in a highly selected cohort. PES is not a panacea for all prenatal malformations and needs to be applied in the context of prior experience and expertise.

Where a diagnosis is made in-utero the neonate is spared of invasive and costly investigations and it affords the opportunity for parents to prepare for the birth. Parents utilise diagnostic information to reach-out to support groups and other parents with similarly affected children. Some parents will choose to end a pregnancy once a severe genetic diagnosis has been confirmed. Parallel advances in gene editing approaches is raising the potential of *in utero* gene therapy, where genetic disease could be treated before the onset of irreversible pathology and rescue diseases which are perinatal lethal or cause severe morbidity [26,27]. These techniques will rely on accurate genomic diagnosis in-utero.

The ability to obtain meaningful phenotypic information in the prenatal context is severely impaired. The identification of a mutation in a fetus which causes a well-documented post-natal phenotype may be a novel (and possibly more severe) expansion of the known phenotype or a coincidental finding. As fetal imaging advances rapidly it is essential that the genetics community records prenatal phenotype data that can be used to identify and expand our knowledge of prenatal genotype-phenotype correlations.

PES is soon to be available throughout England. We have been selective of cases/phenotypes in which PES was undertaken so as to limit the burden of VUS and due to limited availability. As

understanding in interpretation of PES increases, and costs reduce, we anticipate inclusion of cases with milder or more ambiguous phenotypes. We believe that the knowledge of the genetic diagnosis in such ambiguous cases will add more value than in those where the phenotype leads to a high degree of suspicion of a particular diagnosis. Under these circumstances we should not rate the effectiveness of testing by the diagnostic yield but by the value the results add to the management of those pregnancies and the clarity they provide to the parents.

#### **Disclosure of interests**

A Haworth, L Ive, R Dubis, H Savage, E Serra and S Drury are employees of Congenica Ltd. The remaining authors have no disclosures or conflicts of interest. Completed disclosure of interest forms are available to view online as supporting information.

#### **Contribution to authorship**

ED devised and drafted the article with significant contributions from SD, TH, and SM critically appraised the article and contributed to the content. Patients were under the care of EG, BT, JK, FE, SM and TH. Genomic analysis was undertaken and interpreted by AH, LI, RD, HS, ES and SD. All authors contributed to the final version of the article.

#### **Details of ethics approval**

All women involved gave consent to genomic testing in accordance with local policy for diagnostic procedures. This project is classed as a 'service evaluation' and does not require HRA/REC review.

#### **Funding**

ED is funded by peer-reviewed grant from the British Heart Foundation (FS/18/78/33932). This study did not receive specific funding.

#### **REFERENCES**

- 1 Deciphering Developmental Disorders Study {fname}. Large-scale discovery of novel genetic causes of developmental disorders. *Nature* 2015;**519**:223–8.

doi:10.1038/nature14135

2

EA Normand ABSN. Clinical exome sequencing for fetuses with ultrasound abnormalities and a suspected Mendelian disorder. *Genome Med* 2018;**10**.

3

Greenbaum L, Pode-Shakked B, Eisenberg-Barzilai S, *et al*. Evaluation of Diagnostic Yield in Fetal Whole-Exome Sequencing: A Report on 45 Consecutive Families. *Front Genet* 2019;**10**. doi:10.3389/fgene.2019.00425

4

Han J, Yang Y, He Y, *et al*. Rapid prenatal diagnosis of skeletal dysplasia using medical trio exome sequencing: Benefit for prenatal counseling and pregnancy management. *Prenat Diagn* 2020;:pd.5653. doi:10.1002/pd.5653

5

Best S, Wou K, Vora N, *et al*. Promises, pitfalls and practicalities of prenatal whole exome sequencing. *Prenat Diagn* Published Online First: 2018. doi:10.1002/pd.5102

6

Lord J, McMullan DJ, Eberhardt RY, *et al*. Prenatal exome sequencing analysis in fetal structural anomalies detected by ultrasonography (PAGE): a cohort study. *Lancet* 2019;**393**:747–57. doi:10.1016/S0140-6736(18)31940-8

7

Petrovski S, Aggarwal V, Giordano JL, *et al*. Whole-exome sequencing in the evaluation of fetal structural anomalies: a prospective cohort study. *Lancet* 2019;**393**:758–67. doi:10.1016/S0140-6736(18)32042-7

8

Dempsey E, Pryce J, Thilaganathan B, *et al*. Diagnosis of fetal abnormalities using exome sequencing: translating research into practice. *Ultrasound Obstet Gynecol* 2019;:uog.21959. doi:10.1002/uog.21959

9

Bamshad MJ, Nickerson DA, Chong JX. Mendelian Gene Discovery: Fast and Furious with No End in Sight. *Am. J. Hum. Genet.* 2019;**105**:448–55. doi:10.1016/j.ajhg.2019.07.011

10

Joint Position Statement from the International Society for Prenatal Diagnosis (ISPD), the Society for Maternal Fetal Medicine (SMFM), and the Perinatal Quality Foundation (PQF) on the use of genome-wide sequencing for fetal diagnosis. *Prenat Diagn* 2018;**38**:6–9. doi:10.1002/pd.5195

11

Monaghan KG, Leach NT, Pekarek D, *et al*. The use of fetal exome sequencing in prenatal diagnosis: a points to consider document of the American College of Medical Genetics and Genomics (ACMG). *Genet Med* doi:10.1038/s41436

12

Amor DJ, Chitty LS, Van den Veyver IB. Current controversies in prenatal diagnosis 2: The

59 genes ACMG recommends reporting as secondary findings when sequencing postnatally should be reported when detected on fetal (and parental) sequencing. *Prenat Diagn* Published Online First: 24 February 2020. doi:10.1002/pd.5670

13 Deden C, Neveling K, Zafeiropopoulou D, *et al.* Rapid whole exome sequencing in pregnancies to identify the underlying genetic cause in fetuses with congenital anomalies detected by ultrasound imaging. *Prenat Diagn* 2020;**40**:972–83. doi:10.1002/pd.5717

14 Corsten-Janssen N, Bouman K, Diphhoorn JCD, *et al.* A prospective study on rapid exome sequencing as a diagnostic test for multiple congenital anomalies on fetal ultrasound. *Prenat Diagn* 2020;:pd.5781. doi:10.1002/pd.5781

15 MA Koning MHPA van S. From diagnostic yield to clinical impact: a pilot study on the implementation of prenatal exome sequencing in routine care. *Genet Med* 2019;**21**:2303–10.

16 Becher N, Andreasen L, Sandager P, *et al.* Implementation of exome sequencing in fetal diagnostics—Data and experiences from a tertiary center in Denmark. *Acta Obstet Gynecol Scand* 2020;**99**:783–90. doi:10.1111/aogs.13871

17 Richards S, Aziz N, Bale S, *et al.* Standards and guidelines for the interpretation of sequence variants: a joint consensus recommendation of the American College of Medical Genetics and Genomics and the Association for Molecular Pathology. *Genet Med* 2015;**17**:405–23. doi:10.1038/gim.2015.30

18 Toriello H V., Erick M, Alessandri JL, *et al.* Maternal vitamin K deficient embryopathy: Association with hyperemesis gravidarum and Crohn disease. *Am J Med Genet Part A* 2013;**161**:417–29. doi:10.1002/ajmg.a.35765

19 Velho RV, Harms FL, Danyukova T, *et al.* The lysosomal storage disorders mucopolipidosis type II, type III alpha/beta, and type III gamma: Update on GNPTAB and GNPTG mutations. *Hum Mutat* 2019;**40**:842–64. doi:10.1002/humu.23748

20 Tyburczy ME, Dies KA, Glass J, *et al.* Mosaic and Intronic Mutations in TSC1/TSC2 Explain the Majority of TSC Patients with No Mutation Identified by Conventional Testing. *PLoS Genet* 2015;**11**. doi:10.1371/journal.pgen.1005637

21 Jacobson SG, Aleman TS, Sumaroka A, *et al.* Disease boundaries in the retina of patients with usher syndrome caused by MYO7A gene mutations. *Investig Ophthalmol Vis Sci*



2009;**50**:1886–94. doi:10.1167/iovs.08-3122

22 Lee H, Deignan JL, Dorrani N, *et al.* Clinical exome sequencing for genetic identification of rare mendelian disorders. *JAMA - J Am Med Assoc* 2014;**312**:1880–7.

doi:10.1001/jama.2014.14604

23 Hodgson J, McClaren BJ. Parental experiences after prenatal diagnosis of fetal abnormality. *Semin Fetal Neonatal Med* 2018;**23**:150–4. doi:10.1016/j.siny.2017.11.009

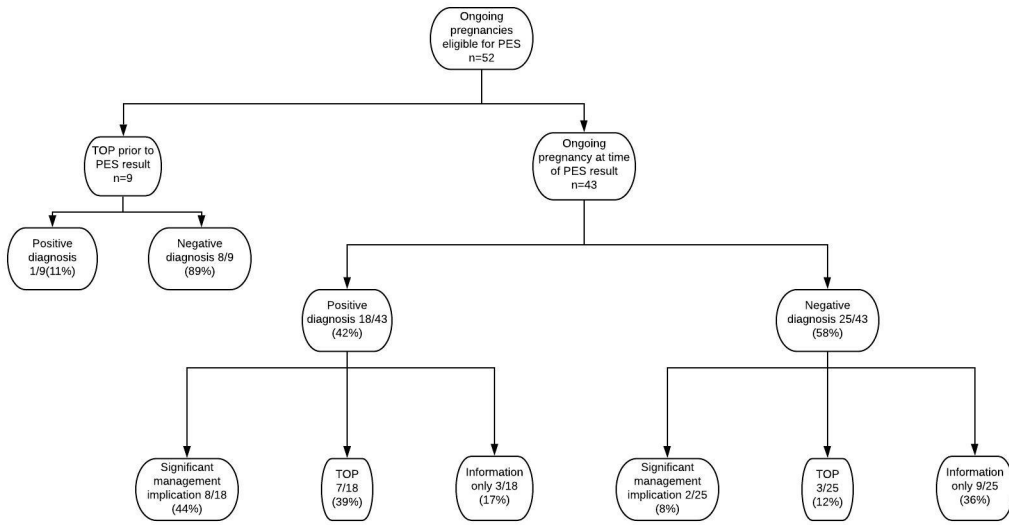
24 Drury S, Hill M, Chitty LS. Cell-Free Fetal DNA Testing for Prenatal Diagnosis. In: *Advances in Clinical Chemistry*. Academic Press Inc. 2016. 1–35. doi:10.1016/bs.acc.2016.05.004

25 De Koning MA, Haak MC, Adama Van Scheltema PN, *et al.* From diagnostic yield to clinical impact: a pilot study on the implementation of prenatal exome sequencing in routine care. *Genet Med* doi:10.1038/s41436-019

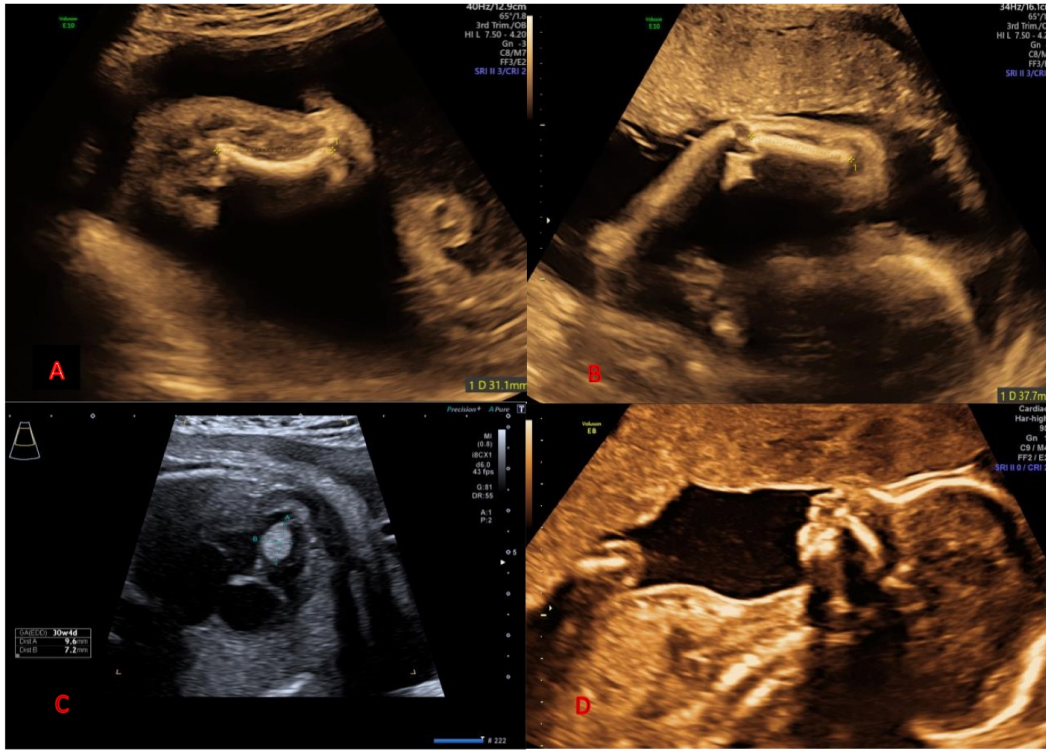
26 Peranteau WH, Flake AW. The Future of In Utero Gene Therapy. *Mol Diagn Ther* 2020;**24**. doi:10.1007/s40291-020-00445-y

27 Sagar R, Götherström C, David AL, *et al.* Fetal stem cell transplantation and gene therapy. *Best Pract. Res. Clin. Obstet. Gynaecol.* 2019;**58**:142–53.

doi:10.1016/j.bpobgyn.2019.02.007



bjo\_16546\_f1.jpeg



bjo\_16546\_f2.jpg