

Primary Immunoglobulin G4-Related Laryngeal Disease: A Case Series and Review of Literature

Elizabeth F Maughan^{1*}, Joshua Michaels^{2*}, Benjamin Miller¹, Justin Weir³, Alan Salama⁴, Elinor Warner², Khalid Ghufour², Gurpreet Sandhu¹ and Chadwan Al Yaghchi¹

¹Department of Otolaryngology, Imperial College Healthcare NHS Trust, London, UK.

²Department of Otolaryngology, Barts Health NHS Trust, London, UK. ³Department of Pathology,

Imperial College Healthcare NHS Trust, London, UK. ⁴Department of Nephrology, Royal Free

London NHS Foundation Trust, London, UK.

Clinical Medicine Insights: Case Reports

Volume 13: 1–6

© The Author(s) 2020

Article reuse guidelines:

sagepub.com/journals-permissions

DOI: 10.1177/1179547620960197



ABSTRACT

OBJECTIVE: Immunoglobulin G4-related disease (IgG4-RD) is an increasingly recognised cause of various systemic fibro-inflammatory conditions. However, laryngeal involvement as a primary feature is extremely rare. We aimed to report on a case series of such patients and examine the global literature relating to laryngeal involvement.

METHODS: Having previously reported a case of IgG4-RD laryngeal pseudotumour, we describe a case series of further 4 patients with primary laryngeal IgG4-RD managed by our UK quaternary airway service and provide a brief overview of laryngeal IgG4-RD.

RESULTS: Including our cases, 14 cases of primary laryngeal IgG4-RD have been reported. Vocal cord involvement is relatively uncommon. Repeat biopsies may be required to achieve histological diagnosis. Remission is achievable by commencement of immunomodulatory treatment, following which laryngeal reconstruction may be necessary.

CONCLUSION: Laryngeal involvement is a rare presentation of IgG4-RD, itself a rare and difficult-to-diagnose condition. A high and prolonged index of suspicion is necessary from both surgical and pathological specialists for correct diagnosis and management.

KEYWORDS: Laryngeal fibrosis, IgG4-RD, IgG4-related disease

RECEIVED: February 23, 2020. **ACCEPTED:** August 27, 2020.

TYPE: Case Report

FUNDING: The author(s) received no financial support for the research, authorship, and/or publication of this article.

DECLARATION OF CONFLICTING INTERESTS: The author(s) declared no potential conflicts of interest with respect to the research, authorship, and/or publication of this article.

CORRESPONDING AUTHOR: Chadwan Al Yaghchi, Department of Otolaryngology, Charing Cross Hospital, Fulham Palace Rd, Hammersmith, London W6 8RF, UK. Email: chadwan.alayaghchi@nhs.net

Introduction

Much progress has been made in our understanding of Immunoglobulin G4-related disease (IgG4-RD) over the last decade, a chronic inflammatory disorder that unites a variety of conditions previously thought to be unrelated. The condition was first identified in 2003 in association with autoimmune pancreatitis, and has since been described in almost every organ system. Although almost 75% of cases are reported in Japanese populations, reported cases have been found in almost all ethnic groups.¹ There is a clear male predominance (61%–80%), though this varies depending on the affected organ and most cases typically present between the fifth and seventh decade of life.² Diagnosis has previously relied on the presence of 4 histological features, namely dense polyclonal lymphoblastic infiltrates (with a high percentage of IgG4-positive plasma cells), storiform fibrosis, obliterative phlebitis and mild-to-moderate tissue eosinophilia.³ However, with the advent of sensitive immunological biomarkers and advanced imaging, there are increasing subsets of patients where combinations of serum IgG4 levels, clinical features and radiological findings (eg, sausage-shaped pancreas or periaortitis affecting the infra-renal

aorta) are sufficient to make a diagnosis of IgG4-related disease in absence of biopsy.⁴ IgG4-RD is well known amongst otolaryngologists, but whilst head and neck manifestations of IgG4-RD are common,⁵ organ specific diagnostic criteria are lacking, and primary laryngeal involvement is rarely reported.⁶ Having previously reported a case of IgG4-RD causing laryngeal pseudotumour,⁷ here we report a case series of a further 4 patients with laryngeal IgG4-RD managed in our quaternary airway service over an 8-year period and review the global literature related to primary laryngeal involvement.

Case 1

A 52-year-old female presented to her local ENT department in 2014 with progressive dyspnoea and biphasic stridor. She was a never-smoker with no prior medical problems or intubation episodes. Flexible nasendoscopy (FNE) revealed marked supraglottic stenosis and interarytenoid fibrosis with normal mobile vocal cords. IgG serology at presentation was normal. Over 3 years she underwent quarterly microlaryngobronchoscopy, steroid injection and balloon dilatation (MLB&D) and laser excision of interarytenoid fibrosis with transient symptomatic relief. Biopsies of sclerotic tissue demonstrated inflammation with fibrosis, plasma cell infiltrates, and increased IgG4

* Joint-first authors.



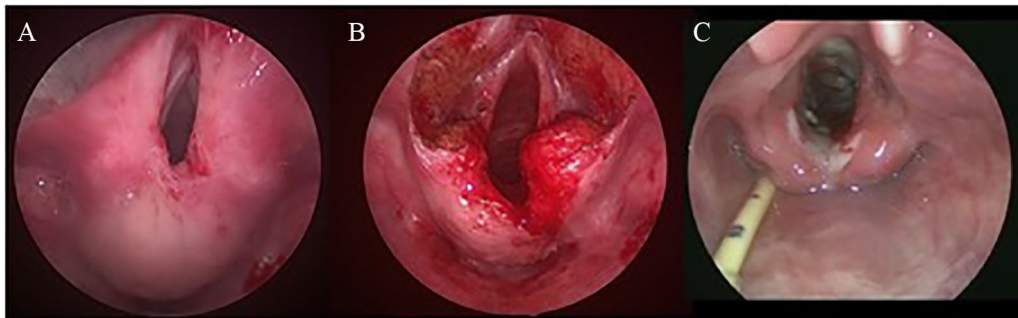


Figure 1. Intraoperative images of Case 1's supraglottic stenosis (A) pre-laryngotracheal reconstruction (LTR), (B) during LTR and (C) on removal of stent 2 weeks post-laryngotracheal reconstruction.

plasma cells consistent with a diagnosis of IgG4-RD. She was commenced on oral prednisolone and azathioprine, later switched to methotrexate, however her relapses continued to increase in frequency and severity, she was referred to our tertiary service in 2017 for further management.

At presentation to us, she underwent MLB&D, during which amorphous supraglottic scarring was noted and re-biopsied. Histologic analysis revealed moderate lymphoplasmocytic infiltrate and prominent stromal fibrosis with associated IgG4 plasma cells and an IgG4:IgG ratio of 80% in keeping with IgG4-RD. Serum IgG levels were normal. Ongoing medical optimisation was planned prior to laryngotracheal reconstruction, however she presented with acute worsening of symptoms from complete glottic obstruction before this could be completed. A surgical tracheostomy was performed following awake fiberoptic intubation, and she underwent endoscopic laryngotracheal reconstruction shortly after this acute episode (Figure 1). Following division and excision of interarytenoid and supraglottic scarring and balloon dilatation, an Eliacher stent covered with a split skin graft was inserted. The stent was removed at 2 weeks with a much-improved calibre of supraglottic airway. She was systemically well post operatively, although she struggled to maintain adequate oral intake with evidence of aspiration on fiberoptic endoscopic evaluation of swallow (FEES) and underwent insertion of a radiologically inserted gastrostomy (RIG) for feeding. She has had one further MLB which demonstrated a clear supraglottic airway, healthy glottis, and minor posterior interarytenoid granulations which were injected with steroid. Following an intensive course of voice and swallowing rehabilitation, she reverted back to normal oral intake, the RIG tube was removed and she returned to full time employment. She remains under annual follow up.

Case 2

A previously fit and well 15-year-old female presented via the emergency department in 2011 with a very short history of dyspnoea and biphasic stridor following unsuccessful treatment for presumed asthma. FNE revealed subglottic stenosis with mobile vocal cords and an urgent CT scan confirmed concentric soft tissue narrowing of the subglottis to 4 mm. She subsequently underwent emergency tracheostomy and laser

MLB&D with symptomatic relief. Histology from the initial procedure had demonstrated chronic inflammation without underlying granulomatous disease, and an autoimmune screen at the time was negative.

Despite oral prednisolone, repeated MLB&D every 6 to 8 weeks provided only transient relief from restenosis, and a decision was made to perform a laryngotracheal reconstruction with posterior rib graft augmentation. Airway diameter augmentation was achieved using autologous rib graft posteriorly and a sternohyoid flap with split skin graft. This significantly improved her airway and she was discharged on prednisolone with the tracheostomy in situ. A postoperative baseline CT was performed which demonstrated extension of disease to involve the right hemilarynx, perilaryngeal fat and arytenoid cartilage. Histology from surgical specimens demonstrated inflammation with marked plasmacytosis and polyclonality on immunostaining, although immunocytochemistry for IgG4 was within normal limits (IgG:IgG4 less than 25%, 27 IgG4+ cells/high power field). Serological IgG and IgM levels were noted to be raised although IgG4 subclass have been within normal limits. With a presumptive diagnosis of IgG4-RD, she was managed with azathioprine and courses of rituximab by co-author AS.

Surveillance in ENT clinic has demonstrated stable appearances in her airway reconstruction, with a partial return of right vocal cord mobility, and she was decannulated the following year. Over the last 5 years peristomal tracheal scarring has warranted laser resection and the insertion of serial tracheal stents with adjuvant sirolimus therapy. Histologically, this recurrent stenosis has been demonstrated to be granulation and scar tissue unrelated to the previous IgG4-RD. She remains well with a good voice, receiving intermittent stent changes, and is presently studying medicine.

Case 3

A 76-year-old male non-smoker was referred to our ENT department from Gastroenterology colleagues in 2014 with dysphagia and dysphonia following an oesophagogastroscopey, which had demonstrated laryngeal swelling in addition to gastritis and *Helicobacter pylori* infection. He is a retired carpenter with historic asbestos exposure and hypothyroidism, but no

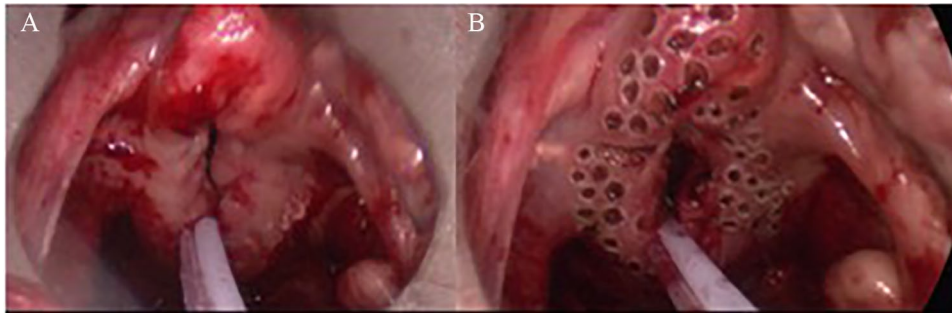


Figure 2. Intraoperative images of supraglottic stenosis in Case 4 (A) pre-treatment and (B) following laser 'pepperpotting' to release the tight supraglottic fibrosis.

recent intubation episodes. FNE demonstrated supraglottic swelling, which was also seen as nonspecific oedema on CT imaging. He underwent MLB&D with laser debulking and steroid injection. Histology demonstrated florid subepithelial lymphoid infiltrate including numerous polyclonal plasma cells, 20% of which were positive for IgG4 (50 IgG+ cells/high power field). His serum IgG4 levels have always remained within the normal range, whilst his autoimmune screen is consistently positive for P3 only.

Following a diagnosis of IgG4-RD, the patient was repeatedly offered immunomodulatory treatment and further surgery for restenosis. However, he has declined almost all medical intervention over a 30-month period due to a combination of personal bereavement and high level of fear regarding the risks of medication-associated side effects. He consented to a single MLB&D with steroid injection and laser pepperpotting of the supraglottis⁸ in July 2017, with histological findings consistent once again with IgG4-RD. Discussion within the Airway multidisciplinary team in December 2018 decided that, with the untreated progression of the disease, further surgery would likely need to be an extensive reconstruction with likely compromise of voice and swallow. Although his symptoms have continued to deteriorate, he continues to decline all treatment and we continue with a 'watch-and-wait' approach to his care.

Case 4

A 49-year-old male non-smoker presented to us from his local ENT department in 2015 with a 2-year history of progressive hoarseness and inspiratory stridor unresponsive to a first locally-performed MLB and laser epiglottoplasty in 2016. An autoimmune serology screen at this time was negative and his past medical history consisted of gastroesophageal reflux and allergic rhinitis only. He had undergone a single intubation episode around the time of symptom onset for revision septoplasty. FNE demonstrated supraglottic scarring and an anterior web with restricted arytenoid movement bilaterally. He underwent MLB&D with laser pepperpotting of the supraglottis (Figure 2). He developed recurrent supraglottic stenosis 1 year later requiring repeated MLB&D every 4 to 6 months, but histology demonstrated only chronic inflammation and fibrosis despite repeated staining including for IgG4. However, IgG4

positive staining was finally confirmed on biopsies sent in February 2019, showing that most infiltrating of plasma cells expressed IgG4.

Following this, a diagnosis of IgG4-RD was made and the patient was commenced on oral Prednisolone and reviewed by AS, but no further systemic site of disease has yet been identified. His IgG serology has remained within range at 0.9 throughout with a negative ANCA screen.

Discussion

IgG4-RD is an increasingly recognised systemic phenomenon with potential clinical manifestations throughout almost all organ systems.⁶ It is characterised by a fibro-inflammatory infiltration and enlargement of the affected organ with abundant IgG4-positive plasma cells (Figure 3), together with raised serum IgG4 levels (which are present at negligible levels in normal tissues).⁹ Recently, a classification system for IgG4-Related Disease was approved by the American College of Rheumatology in order to better appreciate true cases of IgG4-RD rather than its differential diagnostic counterparts. This system uses a scoring system where an allocated score of greater than or equal to 20 must be achieved alongside the present of entry criteria and lack of exclusion criteria.¹⁰ Using this classification criteria, our cases score 26, 23, 21 and 12 respectively. It is important to note, that within this classification system, there is no allocated points score for inflammatory disease of the trachea, yet other organ involvement carries associated points the increase the statistical likelihood of diagnosis. This may highlight the rarity of such pathology given its exclusion, but in doing so makes such a diagnosis more difficult in our cohort of patients. Therefore, such a classification system may benefit from consideration of IgG4-related tracheal pathology. An alternative measure of disease severity would be to use the Responder Index detailed by Wallace et al.¹¹ Each indexed value corresponds to the disease severity within each affected organ and the urgency of treatment. Our 4 cases of tracheal IgG4-RD respectively scored 4, 6, 6 and 4 – low scores due to the sole presence of disease in the trachea but doubled due to the urgency of IgG4-RD of the airway. Whilst these scores can be compared with the entire spectrum of IgG4-RD, they provide only a snapshot assessment of the disease – and therefore




Figure 3. (A) Haematoxylin & Eosin (H&E) staining of laryngeal biopsy demonstrating fibrosis with plasma cell infiltrates. Immunostaining demonstrating (B) Widespread IgG positivity and (C) IgG4 positive cells within the submucosa.

any staggered presentation of multi-organ disease may be missed simply due to the specific time constraints of when disease presence can be scored. Nonetheless, such a Responder Index has a key role in assessment disease prevalence and severity in clinical trials as well as providing a reminder to the medical community of the clinical urgency that IgG4-RD of the trachea can present with.

The pathogenesis of IgG4-RD is still heavily debated with elevated IgG4 serum peptides being a diagnostic rather than explanatory factor. However, the general consensus on pathophysiology is that obstructive phlebitis develops secondary to fibrotic changes within the affected organ's microstructure.¹² Head and neck manifestations of IgG4-RD are relatively common and have been reported in a variety of subsites, including the salivary and lacrimal glands, orbits, thyroid gland, lymph nodes and sinonasal cavities.¹³ However, laryngeal involvement as a primary presentation appears to be extremely rare. A comprehensive review of the literature regarding laryngeal manifestations of IgG4-RD was conducted on 1st November 2019 using the Web of Science database starting with the search term "IgG4" AND "larynx". To date, 14 cases of primary laryngeal IgG4-RD were identified including the 5 cases our group have described to date (summarised in Table 1).

In line with most reported cases, our patient series have generally responded positively to management with steroids or other immunosuppressants, allowing for eventual establishment of a stable tracheostomy-free airway. Our previously reported case of a 22-year-old female student with complete subglottic occlusion from IgG4-related pseudotumour also underwent successful laryngotracheal reconstruction with eventual tracheostomy decannulation once steroid medication had been commenced.⁷ Early response to steroids has been shown to be of prognostic significance in systemic IgG4-RD and helps to confirm the diagnosis.⁹ In the majority of reported primary laryngeal cases, patients did not progress to further systemic manifestations, a notable exception being that of Masterson et al,¹⁴ who reported an IgG4-related parapharyngeal pseudotumour which initially responded to 6 months of oral steroid therapy allowing for successful tracheostomy decannulation, the disease progressed to involve gallbladder, lungs, pelvis, omentum, eyes and temporal bone before histological diagnosis was reached 7 years later. Given the rarity of

the presentation, the condition may mimic a variety of malignant or inflammatory conditions.⁹ Indeed, Shaib et al¹⁵ reported 2 cases of laryngeal IgG4-RD whose findings were initially attributed to vasculitides, before histological diagnosis confirmed IgG4-RD.

It is interesting to note that the ACR classification criteria for IgG4-RD specifically mentions a lack of response to glucocorticoid treatment in their exclusion criteria. And whilst it is generally understood that inflammatory conditions respond well to glucocorticoids, the extent to which they induce remission varies amongst the spectrum of inflammatory disorders. For the spectrum of IgG4-related diseases, glucocorticoids remain the first line treatment inducing remission in 82% to 100% patients depending on organ involvement and the presence of systemic features.² Beyond remission, low dose maintenance steroid therapy remains useful, however there is poor evidence for the use of immunosuppressants. Only in refractory or complicated disease is there any benefit. Our case series describes IgG4-RD of the trachea, which in period of high disease severity can cause significant airway compromise. It is for this reason that definitive surgery is considered once patients enter glucocorticoid-induced remission.

A variety of laryngeal subsites may be affected. Interestingly, the vocal cords themselves appear to be relatively spared in comparison to the supraglottis and subglottis at presentation, although they can become fixed as the fibrotic process of the disease progresses. Those cases that do report vocal cord involvement also appear to be patients with wider extralaryngeal disease involvement.^{14,15} The median reported follow-up amongst the case report literature is of 2 years (range 9 months-8 years). Follow-up by PET with fluorodeoxyglucose has been shown to be helpful in monitoring treatment response to steroids and could have a role to play in follow-up of these cases.¹⁶ These studies however must be interpreted with caution as the correlation between fluorodeoxyglucose uptake and IgG4-RD activity is not matched equivocally with that of lymph node uptake.¹⁷

Diagnosis of IgG4-RD is based on a combination of clinical, biochemical and histopathological findings, which characteristically demonstrate lymphocyte and plasmacyte infiltration and fibrosis with raised IgG4 plasma cells.^{3,18}

Table 1. Summary of published cases of laryngeal IgG4-RD.

AUTHOR	GENDER	AGE AT ONSET (YEARS)	TIME TO DIAGNOSIS	EXTENT OF DISEASE AT PRESENTATION	MEDICAL HISTORY	OTHER SYSTEMIC INVOLVEMENT	SURGICAL MANAGEMENT	MEDICAL MANAGEMENT	OUTCOME (FOLLOW UP)
Current series	Female	52	3 y	Supraglottitis, Cords intact	Nil	Nil	MLB&Ds and resections Tracheostomy LTR, RIG	Prednisolone Azathioprine Methotrexate	Partial remission Decannulated (4y)
Current series	Female	15	10 mo	Subglottitis, Cords involved	Nil	Nil	MLB&Ds and resections Tracheostomy LTR + tracheal stent	Prednisolone Azathioprine Rituximab	Partial remission Decannulated (8y)
Current series	Male	76	7 mo	Supraglottitis, Cords minimally involved	Hypothyroid, AF, OA, Raynaud's	Probable plasma cell mucositis	MLB&D × 2 Patient declined all further treatment	Declined	Symptoms slowly deteriorating (5y)
Current series	Male	47	2 y	Supraglottitis, Cords minimally involved	GORD, allergic rhinitis	Nil	MLB&Ds	Prednisolone initially	Symptoms stable post commencement of steroids (9mo)
Virk et al ⁷	Female	19	3 y	Subglottitis, Cords involved	Nil	Nil	Tracheostomy LTR	Prednisolone	Partial remission Decannulated (3y)
Reder et al ²⁰	Male	38	20y	Vallecula to pyriform, Cords intact	Nil	Nil	MLB & laser resection	Prednisolone Rituximab	Complete resolution (2y)
Reder et al ²⁰	Male	62	4 mo	Base of tongue to pyriform, Cords intact	IBD, PSC, Colorectal cancer	Biliary	Nil	Prednisolone Rituximab	Partial remission (1 y)
Reder et al ²⁰	Female	44	6 y	Unilateral pharyngeal wall, Cords intact	Nil	Nil	Nil	Prednisolone Rituximab	Complete resolution (15 mo)
Khoo et al ²¹	Male	62	2 mo	Aryepiglottic folds, Cords intact	Nil	Nil	Nil	Prednisolone	Complete resolution (9 mo)
Masterson et al ¹⁴	Female	51	7 y	Nasopharynx to hypopharynx, Cords involved	Nil	Gallbladder, lung, pelvis, omentum, eye, temporal bone	MLB & resections Tracheostomy	Prednisolone Mycophenolate	Partial remission Decannulated (1y)
Volker et al ²²	Male	56	6 mo	Supraglottitis, Cords intact	Nil	Nil	MLB & laser resection	Prednisolone	Partial remission (2y)
Shaib et al ¹⁵	Male	56	12y	Subglottic stenosis, Cords involved	Nil	Lung, prostate	MLB&Ds Tracheostomy	Prednisolone Azathioprine	Partial remission (2y)Lifelong tracheostomy
Shaib et al ¹⁵	Male	41	16y	Laryngopharynx, Cords intact	Nil	Genital ulceration	Nil	Prednisolone	Complete remission (2y)
Ferrante et al ²³	Female	70	1 mo	Nasopharynx, Supraglottitis, Cords intact	Sjögren's, RA	Nil	Tracheostomy Gastrostomy	Prednisolone	Complete remission (16mo)

Abbreviations: y, years; mo, months.

Importantly, IgG4 plasma levels may remain within normal range,⁹ a finding common to the cases we report here. In addition, tissue infiltrates of plasma cells are likely to decrease over time as fibrosis increases, and histopathological findings may become less specific in patients with established disease,⁹ potentially further increasing time to diagnosis and correct medical therapy. In the wider IgG4-RD related literature, 90% of cases have reported to go into remission with appropriate medical therapy, with an annual relapse rate of 11%.¹⁹ Timely biopsy is therefore likely to be key in confirming the diagnosis and intervening with medical therapy prior to the onset of fibrosis. In our fifth case, multiple biopsies had stained negative for IgG4 involvement over a period of several years before a positive histological sample was found. This may be due to sampling error within a heterogenous fibro-inflammatory mass, and therefore multiple and repeated biopsy may be necessary to achieve a diagnosis.

Conclusion

Here we report 4 further cases of primary laryngeal IgG4-RD managed by our specialist airway service over an 8-year period with a variety of different laryngeal manifestations. Immediate management is to establish a safe airway, either by endoscopic procedures or tracheostomy depending on local experience. Multiple and/or repeated biopsies may be necessary to achieve a histological diagnosis. Most patients should recover good aerodigestive function with immunomodulatory medication, but following medical disease control, individualised reconstructive techniques are often required to establish a satisfactory stable airway.

Authors' Contributions

EM and JM authored the manuscript, BM and EW collected data, JW reviewed histopathology sections, AS reviewed medical management sections, KG, GS and CAY surgical management, review and edit of the manuscript.

Informed Consent

Written informed consent for anonymised patient information and images to be published has been provided by all patients and can be provided on request.

REFERENCES

1. Stone JH, Zen Y, Deshpande V. IgG4-related disease. *N Engl J Med*. 2012;366:539-551.
2. Wallace ZS, Deshpande V, Mattoo H, et al. IgG4-related disease: clinical and laboratory features in one hundred twenty-five patients. *Arthritis Rheumatol*. 2015;67:2466-2475.
3. Deshpande V, Zen Y, Chan JK, et al. Consensus statement on the pathology of IgG4-related disease. *Mod Pathol*. 2012;25:1181.
4. Brito-Zerón P, Bosch X, Ramos-Casals M, Stone JH. IgG4-related disease: advances in the diagnosis and treatment. *Best Pract Res Clin Rheumatol*. 2016;30:261-278.
5. Takano K, Yamamoto M, Takahashi H, Himi T. Recent advances in knowledge regarding the head and neck manifestations of IgG4-related disease. *Auris Nasus Larynx*. 2017;44:7-17.
6. Khosroshahi A, Wallace Z, Crowe J, et al. International consensus guidance statement on the management and treatment of IgG4-related disease. *Arthritis Rheumatol*. 2015;67:1688-1699.
7. Virk JS, Stamatoglou C, Kwame I, Salama A, Sandison A, Sandhu G. IgG4-sclerosing pseudotumor of the trachea: a case report and review of the literature. *Arch Otolaryngol Head Neck Surg*. 2012;138:864-866.
8. Butler CR, Nouraei SR, Mace AD, Khalil S, Sandhu SK, Sandhu GS. Endoscopic airway management of laryngeal sarcoidosis. *Arch Otolaryngol Head Neck Surg*. 2010;136:251-255.
9. Kamisawa T, Zen Y, Pillai S, Stone JH. IgG4-related disease. *Lancet*. 2015;385:1460-1471.
10. Wallace ZS, Naden RP, Chari S, et al. The 2019 American College of Rheumatology/European League against rheumatism classification criteria for IgG4-related disease. *Ann Rheum Dis*. 2020;79:77-87.
11. Wallace ZS, Khosroshahi A, Carruthers MD, et al. An international multispecialty validation study of the IgG4-related disease responder index. *Arthritis Care Res (Hoboken)*. 2018;70:1671-1678.
12. Cheuk W, Chan JK. IgG4-related sclerosing disease: a critical appraisal of an evolving clinicopathologic entity. *Adv Anat Pathol*. 2010;17:303-332.
13. Fujita A, Sakai O, Chapman MN, Sugimoto H. IgG4-related disease of the head and neck: CT and MR imaging manifestations. *Radiographics*. 2012;32:1945-1958.
14. Masterson L, Del Pero MM, Donnelly N, Moffat D, Rytina E. Immunoglobulin G4 related systemic sclerosing disease involving the temporal bone. *J Laryngol Otol*. 2010;124:1106-1110.
15. Shaib Y, Ton E, Goldschmeding R, Tekstra J. IgG4-related disease with atypical laryngeal presentation and Behçet/granulomatous polyangiitis mimicking features. *BMJ Case Rep*. 2013;2013:bcr2013009158.
16. Ebbo M, Grados A, Guedj E, et al. Usefulness of 2-[18F]-fluoro-2-deoxy-d-glucose-positron emission tomography/computed tomography for staging and evaluation of treatment response in IgG4-related disease: a retrospective multicenter study. *Arthritis Care Res (Hoboken)*. 2014;66:86-96.
17. Berti A, Della-Torre E, Gallivanone F, et al. Quantitative measurement of 18F-FDG PET/CT uptake reflects the expansion of circulating plasmablasts in IgG4-related disease. *Rheumatology*. 2017;56:2084-2092.
18. Umehara H, Okazaki K, Nakamura T, et al. Current approach to the diagnosis of IgG4-related disease—Combination of comprehensive diagnostic and organ-specific criteria. *Mod Rheumatol*. 2017;27:381-391.
19. Yamamoto M, Yajima H, Takahashi H, et al. Everyday clinical practice in IgG4-related dacryoadenitis and/or sialadenitis: results from the SMART database. *Mod Rheumatol*. 2015;25:199-204.
20. Reder L, Della-Torre E, Stone JH, Mori M, Song P. Clinical manifestations of IgG4-related disease in the pharynx: case series and review of the literature. *Ann Otol Rhinol Laryngol*. 2015;124:173-178.
21. Khoo JF, Batt M, Stimpson P, Safdar A. Supraglottic immunoglobulin-G4 related plasma cell granuloma: case report and literature review. *Head Neck*. 2014;36:E57-E9.
22. Völker HU, Scheich M, Zettl A, Hagen R, Müller-Hermelink HK, Gattenlöhner S. Laryngeal inflammatory myofibroblastic tumors: different clinical appearance and histomorphologic presentation of one entity. *Head Neck*. 2010;32:1573-1578.
23. Ferrante SS, Wang L, Kurant D, Daniero JJ. Laryngeal immunoglobulin G4-related disease resulting in severe airway obstruction. *JAMA Otolaryngol Head Neck Surg*. 2017;143:426-427.