

NCBI Bookshelf. A service of the National Library of Medicine, National Institutes of Health.

Heemskerk D, Caws M, Marais B, et al. Tuberculosis in Adults and Children. London: Springer; 2015.

Chapter 3 Clinical Manifestations

In this chapter we will review the clinical manifestations of tuberculosis disease.

3.1. Primary Tuberculosis

Primary (initial) infection is usually indicated by tuberculin skin test (TST) or interferon-gamma release assay (IGRA) conversion, which reflects a delayed type hypersensitivity reaction to protein products of *M. tuberculosis*. TST conversion usually occurs 3–6 weeks after exposure/infection; guidelines for its correct interpretation can be found at: <http://www.cdc.gov/tb/publications/factsheets/testing/skintesting.htm>. Primary infection remains undiagnosed in the majority of cases, as symptoms are mild, non-specific and usually self-resolving. A primary (Ghon) complex is formed, consisting of a granuloma, typically in the middle or lower zones of the lung (primary or Ghon focus) in combination with transient hilar and/or paratracheal lymphadenopathy and some overlying pleural reaction. The primary complex usually resolves within weeks or months, leaving signs of fibrosis and calcification detectable on chest X-ray. In general the risk of disease progression following primary infection is low, but young children and immunocompromised patients are at increased risk.

The natural history of a re-infection event is not well described, since we have no good measure of its occurrence. We know it is likely to be common in TB endemic areas, since molecular epidemiological evidence suggests that many disease episodes (the vast majority in some settings) result from currently circulating strains, representing recent infection/re-infection. A re-infection event probably triggers very similar responses to those observed with primary (first-time) infection and the risk of subsequent disease progression seems to be substantially reduced. However, re-infection is likely to occur multiple times during the lifetime of an individual living in a TB endemic area, which explains its large contribution to the disease burden observed.

Reactivation disease or post-primary TB are often used interchangeably for TB occurrence after a period of clinical latency. However, since reactivation disease is clinically indistinguishable from progressive primary disease or re-infection disease (DNA fingerprinting is required to distinguish reactivation from re-infection) the terminology is not descriptive or clinically useful. True reactivation disease is often preceded by an immunological impetus. Patients with immunocompromise due to severe malnutrition, HIV-infection, chronic hemodialysis, immunosuppressive therapy, diabetes or silicosis etc. are at increased risk.

3.2. Pulmonary Tuberculosis

TB symptoms are usually gradual in onset and duration varying from weeks to months, although more acute onset can occur in young children or immunocompromised individuals. The typical triad of fever, nightsweats and weightloss are present in roughly 75, 45 and 55 % of patients respectively, while a persistent non-remitting cough is the most frequently reported symptom (95 %) (Davies et al. 2014). Approximately 20 % of active TB cases in the US are exclusively extrapulmonary (EPTB), with an additional 7 % of cases having concurrent pulmonary and EPTB (Peto et al. 2009).

3.2.1. Parenchymal Disease

Patients with cavitory lung disease typically present with (chronic) cough, mostly accompanied by fever and/or nightsweats and weightloss. Cough may be non-productive or the patient may have sputum, that can be mucoid, mucopurulent, blood-stained or have massive haemoptysis. Other symptoms may be chest pain, in patients with subpleural involvement, or dyspnoea, however rare. Upon auscultation, the findings in the chest may be disproportionately normal to the findings on chest X-ray. The results of the chest X-ray may be critical for treatment initiation for those patients who are sputum smear negative. In particular in low resource countries, chest X-ray interpretation is often done by non-expert medical staff, and missed diagnosis is common. Typical findings include normal chest X-ray, focal upper lobe opacities, diffuse opacities, consolidation, reticulonodular opacities, cavities (Fig. 3.1a), nodules, miliary pattern (Fig. 3.1b), intrathoracic lymphadenopathy, pleural effusion. In HIV-infected patients, smear yield is lower and radiological abnormalities may be less typical, frustrating diagnosis. Severely

immune-suppressed patients and young children are less likely to present with cavitation on chest X-ray, and more frequently have miliary (disseminated) disease.

3.2.2. Endobronchial Tuberculosis

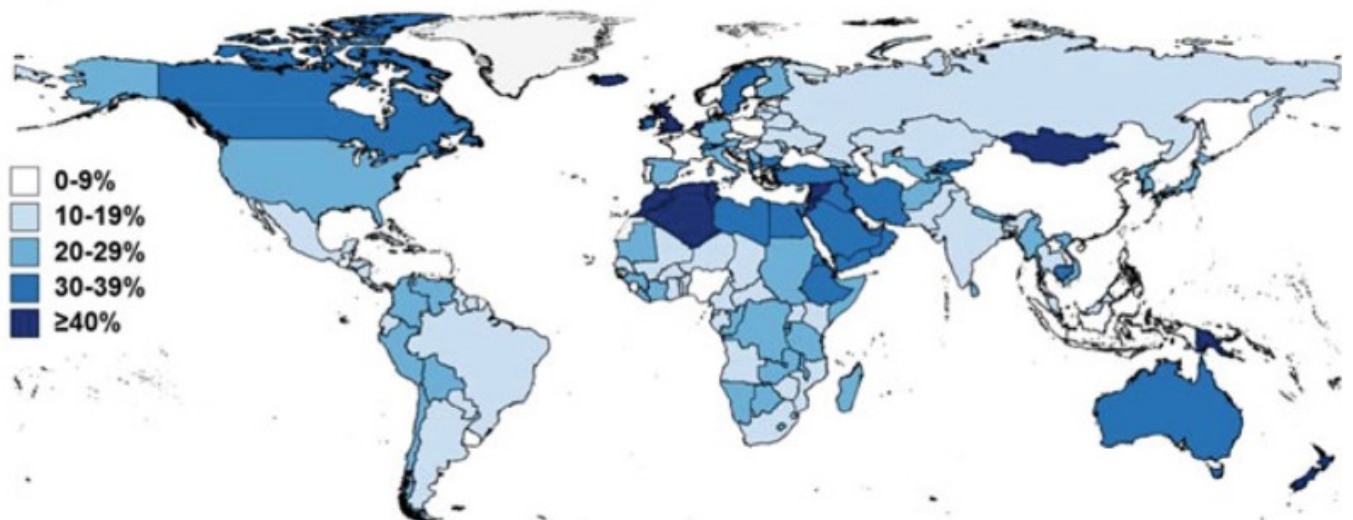
Endobronchial TB is a specific form of pulmonary TB affecting the trachea and major bronchi. It is often misdiagnosed as bronchial asthma or bronchial malignancy. If unrecognized, the endobronchial lesions progress and cause stenosis. Symptoms are as those of pulmonary TB, however examination may include wheezing and dyspnoea may be more prominent. There may be a female predominance, with a male: female ratio of 1:2 (Qingliang and Jianxin 2010; Xue et al. 2011). Bronchoscopy and biopsy is the most useful diagnostic tool and to establish a prognosis depending on which histological subtype is found. Sputum smear and culture should be performed, but varying test sensitivities are reported. Early therapy is needed in order to prevent strictures, treatment with standard first-line short-course regimen (see Treatment section), but treatment prolongation may be considered on a case by case basis, for those patients with intractable disease (Xue et al. 2011).

3.2.3. Intra-Thoracic Lymphnode Disease

Following first-time infection the regional lymph nodes form part of the primary (Ghon) complex. Progressive disease may occur within these affected regional lymph nodes and is typically seen in young children. Symptoms are similar to those described for other forms of pulmonary TB, although the cough is rarely productive or the sputum blood-stained. Young children are unable to expectorate and the organism load is greatly reduced compared to adults with lung cavities, which complicates diagnosis (Perez-Velez and Marais 2012). Enlarged peri-hilar and/or paratracheal lymph nodes may obstruct large airways with resultant collapse or hyperinflation of distal lung segments, form cold abscesses with persistent high fever, or erode into surrounding anatomical structures such as the pericardium leading to TB pericarditis. Peri-hilar and/or paratracheal lymph node enlargement with/without airway compression is the cardinal sign of intra-thoracic lymph node disease. Lymph nodes may also erupt into the airways with aspiration of infectious caseum leading to lobar consolidation and an expansile caseating pneumonia if the airway is completely obstructed.

3.3. Extra-Pulmonary Tuberculosis

Proportion of TB cases that were EPTB, 2011



3.3.1. Pleural Tuberculosis

Between 3 and 25 % of TB patients will have tuberculouspleuritis or pleural TB. As with all forms of extrapulmonary TB, incidence is higher in HIV-infected patients. In some high burden countries, TB is the leading cause of pleural effusions. Typical presentation is acute with fever, cough and localized pleuritic chest pain. It may follow recent primary infection or result from reactivation. If part of primary infection, the effusion may be self-limiting. However, if it occurs in pregnancy it signals a potential risk to foetus, since recent primary infection is frequently associated with the occult dissemination. TB pleural effusions are usually unilateral and of variable size. Approximately 20 % of patients have concurrent parenchymal involvement on chest X-ray, however CT-scans have higher sensitivity and may

detect parenchymal lesions in up to 80 % of patients (Light 2010). HIV infected patients may present with atypical symptoms, often with less pain and longer duration of illness and more generalized signs.

Pleural fluid is mostly lymphocytic with high protein content. Bacillary load is generally low and smear is typically negative, although this may be higher in HIV positive patients, in whom diagnostic yield from smear may be as high as 50 %. Elevated levels of adenosine deaminase (ADA) may be indicative; sensitivity and specificity estimates from a meta-analysis of published studies were 92 and 90 % respectively, with a cut-off value of 40U/l (Liang et al. 2008). However ADA levels can be increased in other diseases, such as empyema, lymphomas, brucellosis, and Q fever, and the test cannot differentiate between these diseases. A negative result suggests that TB is unlikely, but should always be interpreted in the clinical context. Pleural biopsy may show granuloma in the parietal pleura and are highly suggestive of TB, even in the absence of caseation or AFB. Stain and culture of the pleural biopsy is reported to have a higher yield than pleural fluid (positive results in approximately 25 and 56 % of biopsies respectively) (Light 2010).

3.3.2. Miliary Tuberculosis

Miliary TB can occur during primary infection and in post-primary disease. It indicates dissemination of disease and arises from the haematogenous spread of bacilli, which may occur shortly after primary infection or from any active disease site. Miliary granulomas are 1–3 mm in diameter (the size of a millet seed (Latin: milia)), are widespread and may be found in any visceral organ (Davies et al. 2014). In immunocompetent patients, miliary TB accounts for approximately 3 % of TB cases and is more commonly found in immunocompromised patients (>10 % of HIV-infected patients) and in young children (Sharma et al. 2005).

Clinical symptoms are mostly constitutional, including malaise, fever, weightloss, sweats, anorexia. Pulmonary signs may be similar but often less pronounced than in uncomplicated pulmonary TB. If the brain is involved, neurological symptoms may include headache, reduced consciousness and cranial nerve palsies. Involvement of other organs usually does not elicit localized symptoms. In immunocompromised patients physical signs may be less apparent and include dyspnoea, wasting, lymphnode enlargement, hepatosplenomegaly, cutaneous lesions. These patients are more at risk of meningeal involvement. Cutaneous involvement is rare (tuberculosis miliaria cutis), but if present may provide a valuable clue to the diagnosis. Rare complications including adult respiratory distress syndrome (ARDS), pneumothorax, cardiac and multi-organ dysfunction have been described. Due to the non-specific symptomatology, miliary TB is often only be discovered at post-mortem. A chest radiograph is pivotal in diagnosis, but is notoriously treacherous (Fig. 3.1b). A high index of suspicion is needed to be able to perceive the fine nodular lesions in more obscure cases. In uncertain cases, (high resolution) CT-scan is more sensitive in detecting the miliary lung nodularity (Sharma et al. 2005). Miliary TB may be accompanied by consolidation (30 %), parenchymal lung cavities (3–12 %), or mediastinal and/or hilar lymphadenopathy (15 %) on chest X-ray (Sharma et al. 2005). A missed diagnosis is grave, as untreated miliary TB often leads to TB meningitis and can be rapidly fatal.

Rapid diagnostic confirmation is not easily achieved, since cough is often non-productive, the sensitivity of conventional sputum smear is low. Smear may be performed on other bodily fluids such as gastric fluid, urine, cerebrospinal fluid, bronchial lavage and pleural fluid. Sputum culture may be positive in 30–60 % of patients. Tissue biopsy or fine needle aspiration may be indicated and should be sent for smear and biopsies examined for granulomatous disease. In tissue biopsies (liver, bonemarrow, transbronchial, pleura or lymphnode) confirmation rate is high and a diagnosis may be found in up to 83 % of cases.

3.3.3. Extra-Thoracic Lymphnode Disease

Cervical lymphadenitis (scrofula) is the most common form of extra-pulmonary TB. In the middle-ages it was known as ‘the King’s evil’ because it was believed the touch of royalty could cure the disease. Before the pasteurization of milk, the more likely causative agent was *Mycobacterium bovis*, which is non-distinguishable from *M. tuberculosis* on ZN stain. Some non-tuberculous mycobacteria (NTM) are known to cause lymphadenitis: *Mycobacterium scrofulaceum*, *Mycobacterium avium-intracellulare complex*, *Mycobacterium malmoense*, *Mycobacterium fortuitum*, *Mycobacterium chelonae* and *Mycobacterium kansasii*, of which *Mycobacterium avium-intracellulare complex* is the most common causative agent (Handa et al. 2012). The route of entry is thought to be through ingestion, via the oropharyngeal mucosa or tonsils, or through skin abrasions.

In the US, lymphadenitis accounts for 40 % of extra-pulmonary TB cases. The most common site is the cervical region, followed by mediastinal, axillary, mesenteric, hepatic portal, peripancreatic, and inguinal lymphnodes (Rieder et al. 1990). Lymph node involvement may follow first-time infection as part of the primary (Ghon) focus, with

subsequent haematogenous or lymphatic spread, with reactivation of a dormant focus or with direct extension of a contiguous focus.

The patient usually presents with a palpable (lymph node) mass greater than 2 × 2 cm and mostly in the cervical area (60 %), either in the jugular, posterior triangle or supraclavicular region, with or without fistula or sinus formation (Handa et al. 2012). Other complications are overlying violaceous skin inflammation and cold abscess formation. Tenderness or pain is not typically described, unless there is secondary bacterial infection. Generalised constitutional symptoms and pulmonary symptoms or signs may be absent, but are more often reported in HIV-infected patients. The differential diagnosis includes bacterial adenitis, fungal infection, viral infection, toxoplasmosis, cat-scratch disease, neoplasms (lymphoma, metastatic carcinoma, Hodgkin's disease, sarcoma), sarcoidosis, drug reactions and non-specific hyperplasia.

The history is important and chest X-ray should be obtained but may be normal in the majority. TST may be helpful in non-endemic countries, reported positive in over 85 % of patients, however it may be negative in patients with HIV infection and non-tuberculous lymphadenitis (Razack et al. 2014).

Diagnosis is classically confirmed by excisional biopsy and histological and microbiological examination. Incisional biopsy has been associated with increased risk of sinus tract formation and is not recommended. Caseating granulomatous inflammation with Langhans and giant cells is highly suggestive of TB. Positive culture from biopsies are reported in between 60 and 80 %, with even higher rates reported fine needle aspiration biopsy (FNAB), which has replaced more invasive biopsies as the diagnostic procedure of choice (Handa et al. 2012). The diagnosis of lymph node TB can be achieved with a combination of FNAB cytology (detection of epithelioid cells), AFB smear, PCR and culture in over 80 % of cases (Razack et al. 2014).

3.3.4. Central Nervous System Tuberculosis

The most common clinical manifestation of central nervous system (CNS) TB is tuberculous meningitis (TBM). Other entities are CNS tuberculoma, which may be present without symptoms or rarely with seizures, tuberculous encephalopathy (rare, only described in children) and tuberculous radiculomyelitis. Pathogenesis is thought to be through a two-step process, in which haematogenous spread leads to a tuberculous focus (Rich focus) in the brain, which then invades and release bacilli in the subarachnoid space (Donald et al. 2005). In HIV-infected patients and young children it is more often associated with miliary disease, which may indicate more direct haematogenous spread in these patients. TBM is the most lethal form of TB. Almost a third of HIV uninfected patients, and more than half of patients that are co-infected with HIV die from TBM, despite treatment. Half of the survivors suffer from permanent neurological impairment (Thwaites et al. 2004).

Early recognition and appropriate treatment are key to improved outcome. Early symptoms are non-specific, including the suggestive triad of fever, night sweats and weight loss and headache of increasing intensity. A duration of symptoms (headache and fever) of more than 5 days should prompt clinicians to include TBM in the differential diagnosis. In the more advanced stages patients become more confused, present with reduced consciousness, hemiplegia, paraplegia and urinary retention (seen with spinal involvement) and cerebral nerve palsies, most frequently involved is nerve VI (up to 40 % of cases), but also III and VII. Seizures are not frequently a presenting symptom in adults (seen in less than 5 % of cases), however often reported in children (50 % of TBM cases). Movement disorders may be seen and are associated with typical basal ganglia involvement. Upon examination, nuchal rigidity is typically less pronounced than in acute bacterial meningitis. Sixth nerve palsy is pathognomonic (Thwaites and Tran 2005).

Diagnosis is often based on a clinical algorithm rather than mycobacterial isolation. Typical features on cerebral imaging on presentation are basal meningeal enhancement, hydrocephalus, and tuberculoma solitary or multiple (MRI shown in Fig. 3.1d). Cerebral infarction may occur during treatment, mostly in the basal ganglia, or paradoxical tuberculoma may form. The cerebrospinal fluid (CSF) is paucibacillary, thus diagnosis confirmed by AFB smear of the CSF is relatively rare (less than 20 % in most laboratories). CSF cellularity is typically lymphocytic (although neutrophils may predominate in the early stages), has raised protein content and moderately raised lactate (typically between 3 and 8 mmol/l), in contrast with bacterial meningitis in which lactate is generally higher. Raised ADA may aid diagnosis, however is not specific, particularly for the differentiation of bacterial meningitis (Tuon et al. 2010). If TBM is suspected, large volumes (>6 ml) of CSF should be drawn and concentrated by centrifugation in order to facilitate microbiological confirmation. Meticulous examination of the smear for up to 30 min can significantly increase detection to over 60 % of those clinically diagnosed (Thwaites et al. 2004).

In contrast to pulmonary TB where sputum smear is less often positive in HIV-infected individuals, CSF is more often positive in HIV-infected individuals with TBM. Liquid culture still provides the 'gold standard' (positive cultures found in approximately 65 % of clinical TBM cases), however results take 2–4 weeks and should not be awaited for treatment initiation. Xpert MTB/RIF is more sensitive than conventional smear and WHO currently recommends this PCR based test for the diagnosis of TBM (Nhu et al. 2013; World Health Organization 2013). The current treatment guidelines are extrapolated from pulmonary regimens, with durations varying from 9 to 12 months of at least 4 first-line agents and including adjunctive corticosteroids (Prasad and Singh 2008; Chiang et al. 2014). However a recent study suggests that the addition of fluoroquinolones and higher doses of rifampicin may improve treatment outcome, since CSF penetration of most of the first-line TB drugs (particularly rifampicin, streptomycin and ethambutol) is poor (Ruslami et al. 2012). Surgical intervention may be indicated in cases with severe non-communicating hydrocephalus and large tuberculomas.

3.3.5. Tuberculous Pericarditis

Cardiac TB most frequently involves the pericardium. TB endocarditis or involvement of the myocardium is extremely rare. Clinical progression is characterized by insidious onset, classically with a presentation with fever of unknown origin. Upon examination a pericardial friction rub may be auscultated. ECG changes consist of diffuse ST elevations, without reciprocal changes, T wave inversion, PR segment deviations. Typical changes as found in acute pericarditis (The PR-segment deviation and ST-segment elevation) are only found in roughly 10 % of cases (Mayosi et al. 2005). Usually the rise in erythrocyte sedimentation rate (ESR) and C-reactive protein (CRP) are less marked compared to the same parameters measured in viral or bacterial pericarditis. A chest X-ray may reveal left pleural effusion, however this is a non-specific finding. Echocardiogram is central in diagnosis, revealing effusion and if present, tamponade. Confirmation of diagnosis is by demonstration of AFB in the pericardial aspirate by smear. In pericardial TB the sensitivity of smear is 15–20 % and of mycobacterial culture 30–75 % (Gooi and Smith 1978). The presence of cardiac tamponade is the most predictive sign of later development of constrictive pericarditis.

The optimal treatment duration remains uncertain, but suggested treatment regimens range from 6 to 12 months. The addition of corticosteroids as an adjuvant to prevent further accumulation of fluid and the development of constrictive pericarditis is recommended (Fowler 1991; Mayosi et al. 2005). Open surgical drainage may be indicated to prevent tamponade, however little data exists on the benefit of closed percutaneous drainage (Reuter et al. 2007).

3.3.6. Spinal Tuberculosis

Spinal TB can cause deformities, typically kyphosis, in extreme forming a gibbus, which can result in paraplegia. Depictions of sufferers are found originating from Ancient Egypt 5000 years ago. Since the late 18th century it became known as Pott's disease. After haematogenous spread, tuberculous spondylitis develops, initially affecting a single vertebra, but with progressing of infection, softening may result in wedging or collapse of the vertebral body and subligamentous spread may involve adjacent vertebrae (Jung et al. 2004). Cold abscesses formation or severe spinal angulation may cause compression of the spinal cord with neurological sequelae. In rare instances bacilli may be released into the subarachnoid space, leading to meningitis, or an abscess may drain externally with sinus formation (Cheung and Luk 2013).

MRI is the imaging modality of choice (Fig. 3.1c) (Jung et al. 2004). Evidence of pulmonary TB or other organ involvement, should heighten suspicion and provides an opportunity for the collection of samples for microbiological examination. Confirmation of diagnosis relies on the detection of AFB on CT-guided tissue biopsies or abscess aspirates. Treatment regimens are as for pulmonary TB, however some advocate longer duration of treatment. Based on the results of a series of randomized clinical trials conducted by the MRC Working party on TB of the spine, spanning a period of 15 year follow up, it is currently accepted that early and mild disease, without significant neurological deficits, may be treated conservatively with anti-tuberculous chemotherapy without operative intervention. Patients treated with debridement alone or combined with spinal fixation (with anterior strut graft) had the tendency to earlier resolution of abscesses, earlier bony fusion and less kyphotic deformity (Mak and Cheung 2013). It is important to identify the poor prognostic factors that are associated with severe kyphosis development, such as the degree of vertebral body loss before treatment, and the separation of facet joints, to identify patients that would benefit for operative intervention by reducing kyphotic deformity.

3.3.7. Other Forms of Extra-Pulmonary Tuberculosis

Tuberculous arthritis, almost always affects only a single joint, usually the hip and knee. It can be diagnosed by examination of synovial fluid or synovial tissue biopsies. Gastrointestinal TB may mimic Crohn's disease, both clinically and radiographically. Preferred sites are the ileocecum, ileum and jejunum and is usually associated with peritonitis. Barium contrast studies can reveal ulceration, strictures, bowel wall thickening, skip lesions and fistulae. In endemic countries, diagnosis is usually made on clinical suspicion. Biopsies may be useful in establishing the diagnosis (Nagi et al. 2002, 2003).

Urogenital TB is notoriously asymptomatic. TB of the urinary tract, occasionally causes flank pain or present with a renal or pelvic mass. Persistent "sterile" pyuria on urine analysis, especially early morning samples, require further investigation with urine AFB smear, PCR and culture. Further investigations include intravenous urography (Merchant et al. 2013a, b).

Laryngeal TB is one of the most infectious forms of TB. Sputum smear is reported positive in up to 70 % of cases. It can result from primary infection with infected droplet nuclei or secondary to pulmonary disease. Hoarseness and dysphagia can be among the presenting signs. Laryngeal TB can be primary, when bacilli directly invade the larynx or secondary from bronchial spread of advanced pulmonary TB (Benwill and Sarria 2014). It presents with hoarseness and dysphagia, or chronic cough if associated with pulmonary TB (Michael and Michael 2011). It should be differentiated from laryngeal malignancy. TB can potentially affect any organ in the human body, further discussion of all rare forms fall beyond the scope of this chapter.

Figures

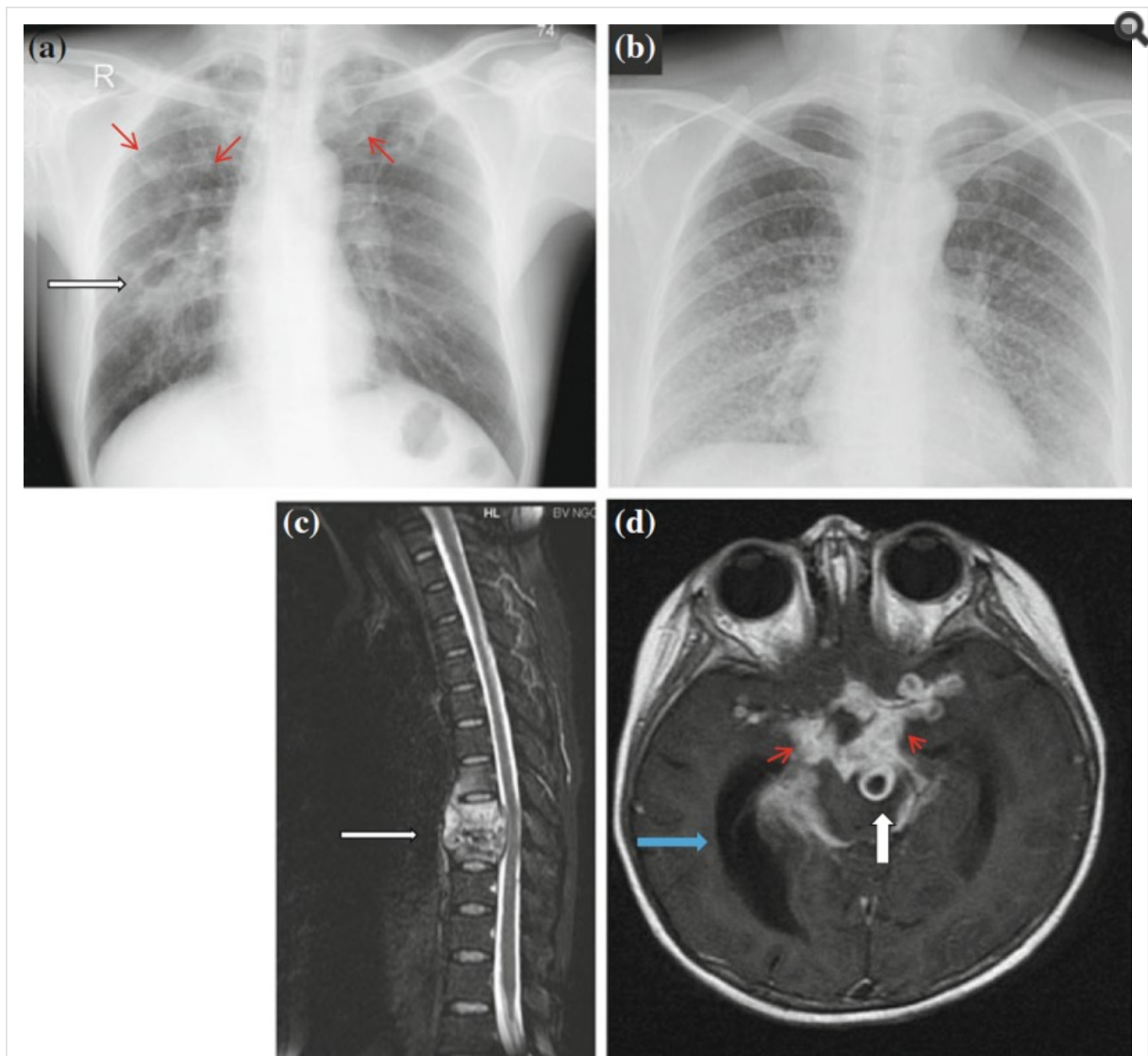


Fig. 3.1 a Chest X-ray showing cavitary lung lesions (*white arrow*) and upper lobe opacities (*smaller red arrows*) in 46 year old male. b Chest X-ray with the classic ‘scattered millet seed’ appearance of miliary TB 49 year old female. c Magnetic resonance image (MRI) of a 35 year old female with spinal TB, showing destruction of thoracic vertebral bodies (T8 and T9) and compression of the spinal cord. d MRI scan showing tuberculoma (*large white arrow*), basal meningeal enhancement (*small red arrows*) and hydrocephalus (*blue arrow*) in a 2 year old child with tuberculous meningitis

© The Author(s) 2015.

All commercial rights are reserved by the Publisher, whether the whole or part of the material is concerned, specifically the rights of translation, reprinting, reuse of illustrations, recitation, broadcasting, reproduction on microfilms or in any other physical way, and transmission or information storage and retrieval, electronic adaptation, computer software, or by similar or dissimilar methodology now known or hereafter developed.

The use of general descriptive names, registered names, trademarks, service marks, etc. in this publication does not imply, even in the absence of a specific statement, that such names are exempt from the relevant protective laws and regulations and therefore free for general use.

The publisher, the authors and the editors are safe to assume that the advice and information in this book are believed to be true and accurate at the date of publication. Neither the publisher nor the authors or the editors give a warranty, express or implied, with respect to the material contained herein or for any errors or omissions that may have been made.

This chapter is distributed under the terms of the Creative Commons Attribution Noncommercial License, which permits any noncommercial use, distribution, and reproduction in any medium, provided the original author(s) and source are credited.

Monographs, or book chapters, which are outputs of Wellcome Trust funding have been made freely available as part of the [Wellcome Trust's open access policy](#)

Bookshelf ID: NBK344404